ICONOGRAPHY OF SENSORY NERVE ENDINGS

ICONOGRAPHY
OF SENSORY
NERVE
ENDINGS

ICONOGRAPHY OF SENSORY NERVE ENDINGS

by

A. ÁBRAHÁM

Member of the Hungarian Academy of Sciences

Akadémiai Kiadó, Budapest 1981

Translated by

T. Bodor

English translation edited by

B. Csillik

Professor of Anatomy

Szeged University Medical School

ISBN 963 05 2316 7

Printed in Hungary

Contents

Preface

Sensory nerve endings are receptors which perceive stimuli arriving from various sources and transmit them to the central nervous system. The stimuli can be either useful or harmful for the individual. Some of the stimuli originate from within the body (organs, tissues and cells) and are perceived by the interoceptors; others, perceived by the exteroceptors, arrive from the environment.

Primitive or more complicated interoceptors can be found in all organs. They transmit information to the nerve cells in the centres and inform them about the current state, i.e. the normal or pathological function of the organs. This information initiates and maintains central control whereby the balanced function of the body is ensured. If the receptors are destroyed, the organ becomes isolated from the integrity of the body. Without the receptors reflexes are also abolished and the efferent nervous connections between the cortex and the periphery are severed.

The exteroceptors are the "guardians" of the body. The environment keeps changing and causes the individual to undergo changes all the time. Otherwise the living structure becomes lifeless: it petrifies or is broken down into its elements. In the course of phylogenesis intricate exteroceptor systems have developed reacting specifically to touch, sound, light, taste, smell and temperature. They amplify the energy of the stimulus and enable the animal to avoid danger. Exteroceptors form the basis of conditioned reflexes and voluntary movements serving the purposes of adaptation and survival. With insufficient exteroceptors the organism is not able to adapt to environmental changes, and departs from life.

In this atlas the receptors of some organs and organ systems are displayed. With a few exceptions, the figures are original drawings made from my own histological preparations which are available in my collection at Szeged.

I hand over my book, the result of the research work of long decades, to those who are interested in the structure and function of the nervous system, with the desire that they find as much pleasure in reading it as I found when I made the slides and was bending over the lens of the microscope. Doing that I wish to thank my pupils, my co-workers and everybody who helped me in accomplishing this work. I am grateful to the editorial staff and printing office of the Hungarian Academy of Sciences for the careful presentation of my book.

Szeged, 1980.

The Author

Introduction

Before leafing through the histological pictures of this atlas, the reader might be interested in the experiences I obtained while working with neurohistological techniques. This account would no doubt be incomplete without reference to my first attempts to use vital methylene blue staining. Methylene blue staining had been introduced by Ehrlich in the last century and from the early twentieth century was successfully used by a number of outstanding scientists (Dogiel, Cajal, Schabadasch, and Hillarp, among others) for the demonstration of neural elements. I myself first applied methylene blue for staining the nervous system of *Opisthodiscus diplodiscoides* a trematode residing in the cloaca of the marsh-frog. After a thorough wash, the living worms were transferred to Petri dishes containing methylene blue solution. The animals behaved and moved normally in the solution and stayed alive for some days. During this time, methylene blue gradually precipitated and was deposited on the skin of the animals, whereas the solution became quite clear. In spite of this coat the worms continued to move about. Yet I did not see any sign of their nerve trunks having absorbed the dye. The animals were then put into a saturated ammonium molybdate solution for fixation and histological sections were prepared after rinsing, dehydration and embedding. I found that none of the neural elements of either the peripheral or the central nervous system had been stained. I repeated this procedure several times using various dilutions of methylene blue, but virtually without any success. Therefore I decided to study the animals in their natural environment assuming that their nervous system might in this case take up the stain. The rectum of the frog was excised, ligated and filled with frog faeces, worms and a methylene blue solution, and in this way I managed to stain and visualize nerve trunks and even the large nerve cells.

This was followed by experiments with vital staining of the peripheral nervous system and especially the receptors of crayfish (Amphipoda). Specimens of *Carinogammarus roeseli* and *Niphargus puteanus* were used, but mainly *Carinogammarus* since representatives of the *Niphargus* genus were difficult to obtain; these latter animals dwell in cave waters and deep wells. On the other hand, Carinogammari are common both in lakes and rivers; they can be easily collected and kept alive in an aquarium. Initially the same method as with *Opisthodiscus* was applied, i.e. the animals were placed in a diluted methylene blue solution, but although the animals tolerated the dye well and survived in the solution for a long time, their nervous system had remained unstained. However, I did not lose heart and carried on. Finally I tried to take the animals out of the methylene blue solution after they had stayed there for a long time, to bisect them in a dilute methylene blue solution on a slide, and then to expose them to the air. A few minutes later I placed the cephalothoracal part with two pairs of antennae under the microscope and I think I will never forget the wonderful picture I saw. Nature had revealed to me something that would have remained undiscovered save for the events described above. Within a few seconds all the nerve fibres passing to the roots of pili and even those within the pili turned blue in the antennae of the bisected but surviving animals. Life persisted, the antennae were still moving and all the nerve fibres having assumed a bright blue colour, became well visible. I was fascinated by the sight – but not for long. Being afraid that this wonderful spectacle would soon disappear, I quickly severed the antennae and the feet for fixation in a saturated ammonium molybdate solution. Fixation and preservation were rather difficult since both the antennae and the extremities were covered with a relatively thick calcareous chitin crust limiting the diffusion of the fixative. Ammonium picrate proved to be more suitable for this purpose and with its help relatively well-fixed preparations could be made, which could be preserved in glycerine for a considerable period of time. Of course, these specimens were not lasting, yet they were suitable for intensive study and – if necessary – also for photography or drawing.

In my studies of the mammalian nervous system with methylene blue, a number of additional difficulties cropped up. Applying the supravital method, I placed pieces of different organs in a dilute methylene blue solution, but this was a "hit or miss' strategy. More often a miss than a hit. I failed to reproduce the beautiful pictures published mainly by Russian neurohistologists. I also did intravital methylene blue staining, mainly in kittens. There was plenty of material since my enthusiastic students brought in the little stray animals they found in different districts of Budapest. To tell the truth, the results were far from encouraging. Larger nerve trunks stained well, but in most cases the terminals remained unstained. That is why I abandoned this technique in my studies on mammals and started to use silver impregnation, which had been a more reliable method.

Nevertheless, methylene blue staining was more successful in frogs, although this was not an easy task either. First I tried to stain different organs of frogs by the supravital technique, however without any success. Later I used the technique of cannulating the heart of anesthetized frogs and perfusing the animal with a dilute methylene blue solution. It soon turned out that this was not a feasible approach either. Here and there the tissues turned blue, and nerve trunks, nerve branches and even the nerve fibres were stained in some areas, still the terminal connections I was most interested in were not visualized. I did not look for the terminals because I was a neuronist, but because I wanted to see the evidence of the neuron doctrine and because I wanted to study the function of the neuron. One day, however, there was a breakthrough at last. It was early spring and we were collecting green toads (*Bufo viridis* Laur). As I scrutinized these animals which had that far withstood staining, the idea occurred to me to try to inject a large amount of dilute methylene blue into the abdominal cavity of the animal prior to exsanguination. This I did with the intention of studying the organs under the microscope later simply by opening the abdominal cavity. The animals injected with methylene blue and bled to death by decapitation were then put into a dish. Six hours later their abdominal cavity was opened, then their oral cavity and, suprisingly, the mucous membrane was found to have turned blue mainly on the surface of the hard palate. I excised the mucosa of the hard palate which I knew to be richly innervated, and after a few minutes, a great number of nerve trunks, smaller nerve fascicles, a rich nerve plexus and even single nerve fibres connecting various members of the system became visible under the microscope. I fixed the specimen in ammonium molybdate and mounted it. Even now, forty years later, these slides demonstrate the nerves most beautifully. In some cases I scraped off the stratified epithelium before mounting the specimen, in order to obtain a thinner membrane. In this way, the neuronal elements had been given a sharper outline. I have to say, however, that in spite of the perfection of these pictures, I did not succeed in demonstrating the connection between the nerve fibres and the epithelium or rather between the axons and the epithelial tactile corpuscles. These difficulties could be overcome only by using Bielschowsky's modified silver impregnation technique.

I have obtained a vast experience with silver impregnation procedures which I do not intend to discuss here (the reader is referred to papers published both in Hungarian and in international journals and congress publications). I have developed two methods for neurohistological investigations. One of them, called Bielschowsky-Ábrahám technique, is a quick, easy, and reproducible modification of Bielschowsky's original method. The other, called Ábrahám's method, is basically new, and is the result of long experimentation. It consists of the following steps:*

1. Fixation in 10 per cent formalin for 2–3 months. For this purpose the use of neutral formalin is recommended; although specimens fixed in acidic formalin are also well impregnated. Short fixation jeopardizes the success of impregnation, whereas prolonged fixation has numerous advantages. In many cases excellent preparations were obtained from specimens kept in the fixative for several years.
2. Washing in running water for 15 minutes.
3. Washing in distilled water for 15 minutes.
4. Cutting by freezing microtome. Thickness of the section should be 20–40 μm. Thicker sections (50 μm or more) are needed if we want to impregnate the whole area of nerve fibre end-ramifications or terminals.
5. Sections are placed in distilled water for 15 minutes.

---

* Both methods have been described in my book *Microscopic Innervation of the Heart and Blood Vessels in Vertebrates Including Man* (Akadémiai Kiadó, Budapest and Pergamon Press, Oxford 1969). A description of Ábrahám's method can also be found in *Zeitschrift für wissenschaftliche Mikroskopie* (**67**, 183–189, 1965–66).

6. Impregnation in a 20 per cent silver nitrate solution for 10 minutes.

7. Washing in distilled water. Thin sections are only rinsed in distilled water, but thicker sections or those impregnated for over 10 minutes should be washed in distilled water for a longer period. It is advisable to agitate the sections about in the water.

8. Impregnation in ammoniacal silver solution for 3–5 minutes or longer until the sections become brown. Maximum allotted time is 10–15 minutes. The ammoniacal silver solution is prepared as follows: 2 drops of 40 per cent sodium hydrate is added to 10 ml 20 per cent silver nitrate solution. A brownish precipitate is formed; this should be dissolved by successive addition of a 25 per cent ammonium hydroxide solution. Make up the volume to 100 ml with distilled water.

9. The sections are transferred into a dilute acetic acid solution for 1–2 seconds. This is prepared from 5 drops of concentrated (glacial) acetic acid dissolved in 100 ml distilled water.

10. Reduction in 10 per cent neutral formalin for 20 minutes. The solution should be exchanged 2–3 times. In this reducing agent, nerve cells and nerve fibres become black while the rest of the section remains pale yellow. The quality of the impregnation will be better if the sections are kept in the reducing solution for a longer time. The progress of impregnation should be checked under the microscope.

11. Gold impregnation, dehydration, mounting. Using this method, nerve cells, axons, dendrites and terminals exhibit clear and sharp contrasts.

Plates

Plate 1

Well-shrimp *(Niphargus puteanus)*, male, gnathopod

Vital methylene blue staining

Several nerve fibres branch off from the nerve trunks running along the gnathopod. Two of these nerve trunks are composed of sensory fibres (ns) while the third one consists of motor fibres (nm). Though the primary sensory cells (a) occur all along the sensory fibres, they are especially numerous at the base of the larger groups of bristles. Sensory cells have two processes: the peripheral process (d) runs to the bristles, while the central one (c) is directed towards the central nervous system. This plate clearly displays the entire receptor system. The chitinized sickle-shaped formation joined to the ultimate segment of the leg is a characteristic part of the gnathopod; it can be moved like the blade of a pocketknife. The sensory nerve fibres enter both the sickle-shaped claw (b) and the single bristles on the outer side of the claw. Primary sensory cells cannot be detected in every bristle of the extremity, in spite of the excellent staining. Nerve fibres innervating the muscles of the leg and motor nerve terminals resembling bunches of grapes (tm) are distinctly stained.

Ethology and coenology

Taxonomically this animal belongs to the suborder of the water-fleas (Gammarinea), and it dwells in cave waters, lakes and wells. It has no eyes and is white in colour. The body is laterally compressed. The first antenna, which possesses an accessory flagellum of 1 to 4 segments, is much longer than the second one. The antennal stem of the latter is five-segmented and the long flagellum lacks an accessory flagellum. The mandible commonly bears a palp. The thorax comprises seven free segments, four pairs of walking legs are directed forward and the remaining three pairs backward. The walking legs are simple and some of them have lamellate branchia at their base. The first and second pairs of legs are, in fact, gnathopods. The first three segments of the abdomen bear the cleft legs, the branches of which are articulated and supplied with long swimming bristles. The legs of the last three abdominal segments are called uropods, their bacilliform branches consist of two segments. Since the animal has no eyes, it is obvious that the chitin bristles of the oral organs and extremities and even the microscopical hairs covering the tergits are innervated. These nerve fibres and their terminals in and around the bristles are receptors.

There are more than 50 species of the well-shrimps *(Niphargus)*. These animals are considered to have survived in underground waters, relicts of Tertiary seas, wherefrom they have re-emerged and in recent times populate dark and cold natural waters.

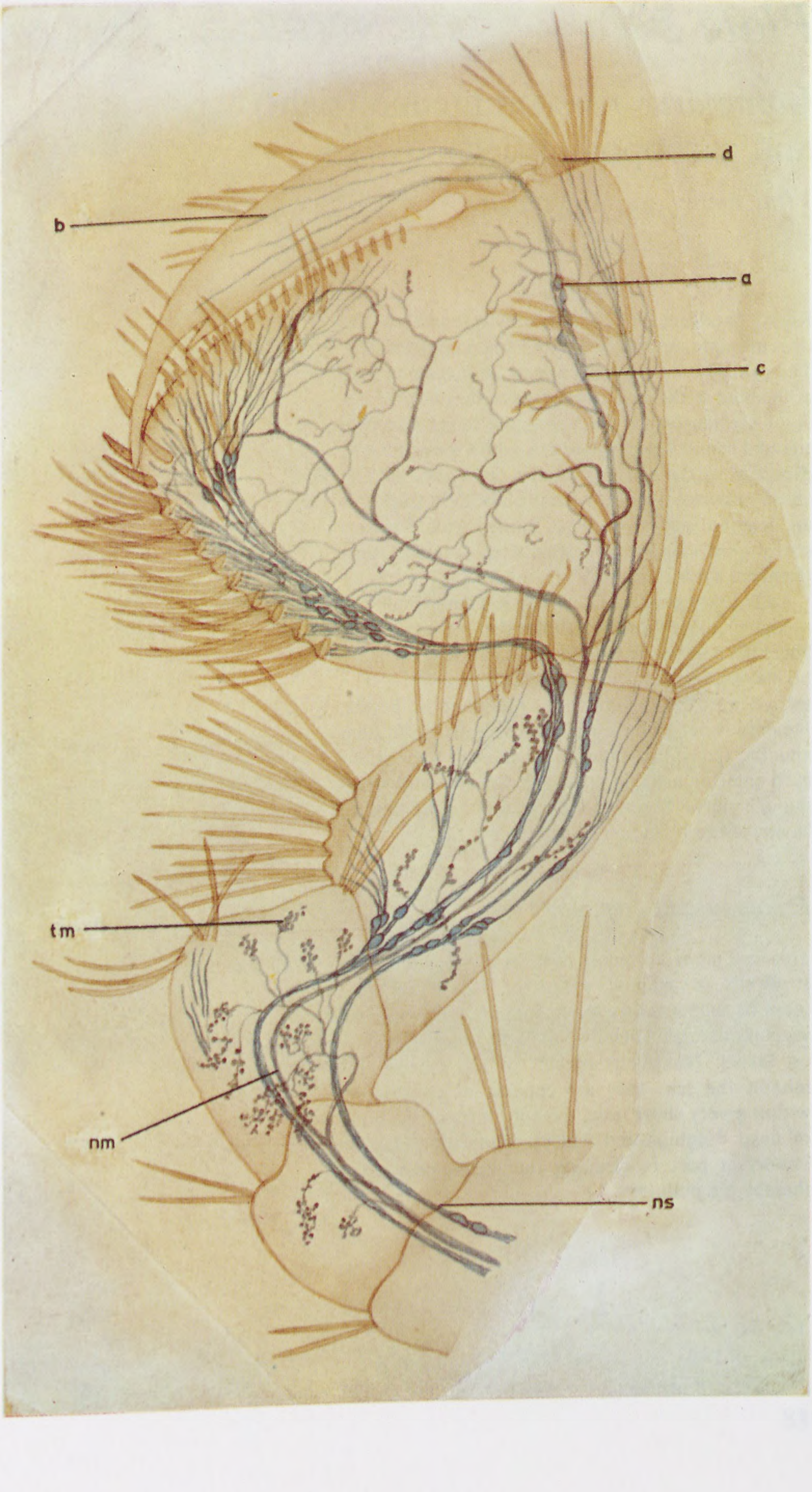
d
b
a
c
tm
nm
ns

Plate 2

Gammarus roeseli antenna (right) and carpopodite (left)

Vital methylene blue staining

Right: flagellum (e) of the second antenna and the two ultimate segments of the antennal stem (h). The primary sensory cells appear in large numbers at the base of the bristles (a). One of the two processes of the sensory cells is connected to the centrally situated sensory nerve fibre (c), while the other one proceeds to the sensory bristles (b, f and g). The chitin bristles (d) tend to diminish both in thickness and length towards the end of the flagellum. Primary sensory cells cannot be seen here; perhaps they remained unstained in this region.

Left: lower aspect of the female's carpopodite at a higher magnification. Note the sensory nerve fibres (b) and the sensory bristles (d). Each sensory bristle is supplied by a separate nerve fibre. The second antenna is especially abundant in nerves. Numerous nerve fibres are present both in the stem and the flagellum; these fan out near the surface each entering a single bristle. With successful staining the nerve fibres can be traced in the central cavity of the bristle almost up to the tip.

Ethology and coenology

This species is common both in rivers and lakes. It dwells in shallow waters of lakes and can often be found under stones, logs and decomposing vegetal material. They live on plant remains, mainly on leaves. Numerous species of the Gammarids inhabit the sea; they are capable of consuming, within a very short time, the soft parts of the body of dead dolphins and whales. Thus they play an important part in cleaning the water, preventing thereby air pollution.

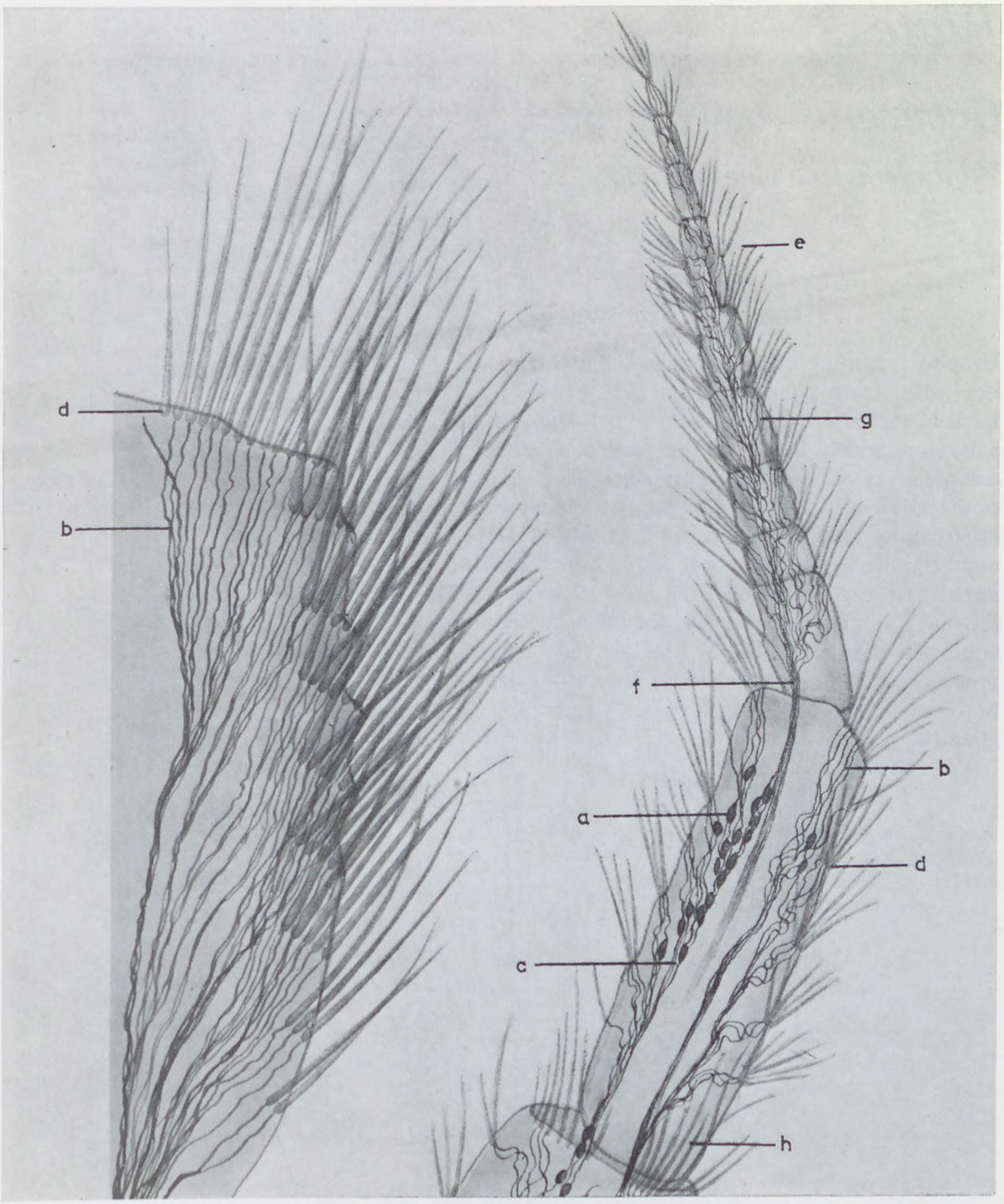
d
b
e
g
f
b
a
d
c
h

Plate 3

Gammarus roeseli uropod

Vital methylene blue staining

Uropod consisting of a basipodite and two exopodites with their characteristic ciliate bristles (a). Each of the latter are composed of a long, central axis, from which, like from the shaft of a feather, a dense array of parallel cilia branches off. The cilia of the adjacent bristles are interwoven to form a rigid structure resembling the tail of birds. A great number of nerve fibres can be found in both exopodites. These are enlarged at the base of the bristle (b), having entered the cavity, they can be traced almost to the end of the bristles (d). The central processes of the sensory cells (c) form thick nerve fibres which run to the appropriate cerebral ganglion.

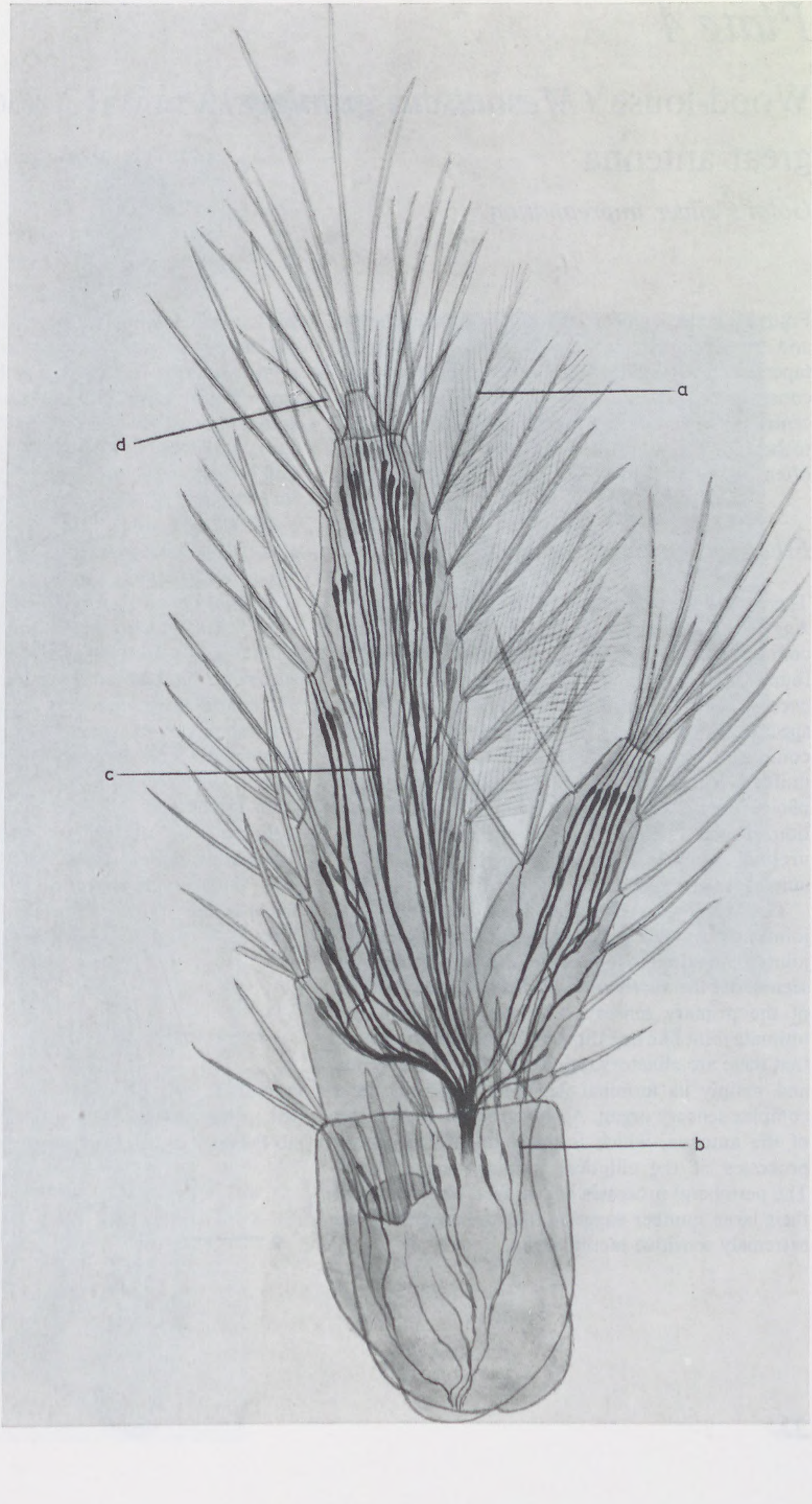
a
d
c
b

Plate 4

Wood-louse *(Mesoniscus graniger)* great antenna

Golgi's silver impregnation

Four ultimate segments (a) of the antennal stem and the antennal flagellum (b) with its markedly tapering chitin bristles (c). The antennal nerve (d), consisting of several fascicles (e), runs along the centre of the antenna. Primary sensory cells (f) are to be found among the fascicles. The nerve fibres often bear thickenings i.e. "varicosities" (g).

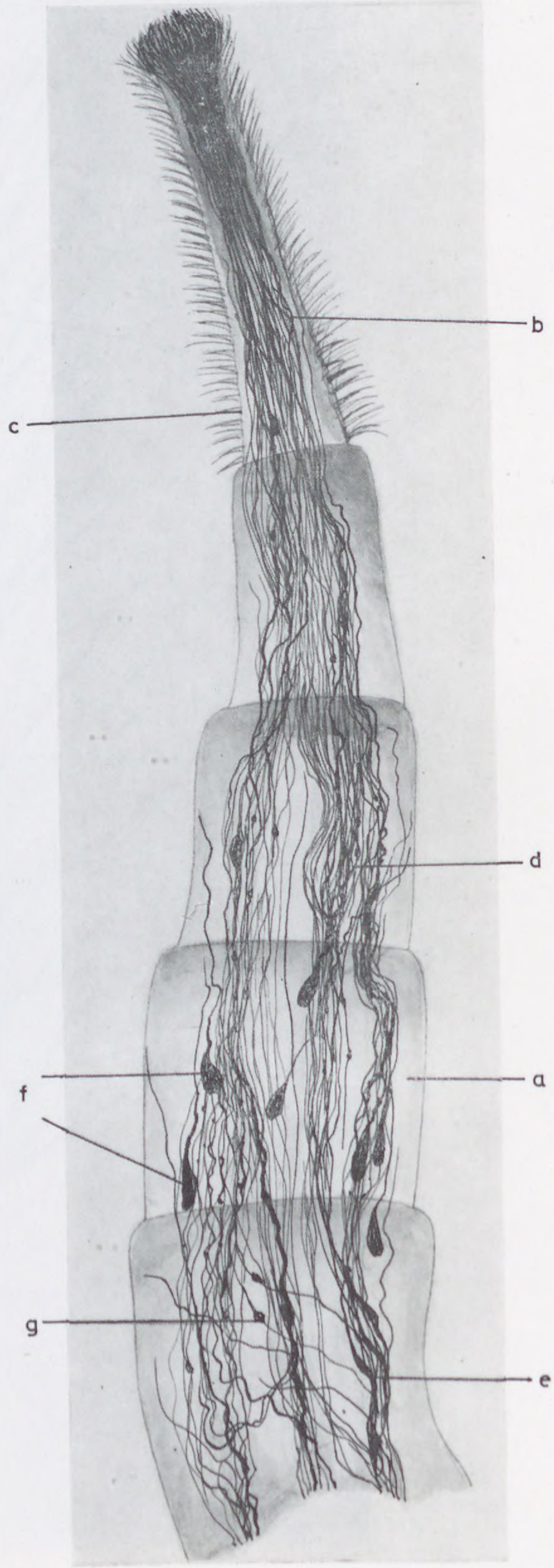

Ethology and coenology

The wood-louse, described by Pál Kitaibel from the Aggtelek Cave in Hungary, is small, and white in colour. It mostly dwells in caves but can also be found elsewhere on calciferous soil. Occasionally it occurs under andesite stones. The body of this species is dorsoventrally depressed; the thorax is composed of seven distinct segments, and its legs are uniform. The six pairs of legs borne by the abdomen play a role mainly in copulation, but also in respiration. The ultimate abdominal leg is the so-called uropod equipped with bacilliform branches. The animal is very quick on the leg.

The larger pair of antennae consists of several joints; the smaller one is shorter, and has only two joints. The ultimate joint is tubular and can only be seen under the microscope. The peripheral processes of the primary sensory cells stick out from this ultimate joint like fine threads. It has been suggested that these are olfactory receptors. The great antenna and mainly its terminal flagellum, functions as a complex sensory organ. A nerve runs along the axis of the antenna, which is made up of the central processes of the elliptical primary sensory cells. The peripheral processes are, in fact, receptors, and their large number suggests that the antenna is an extremely sensitive tactile organ.

Plate 5

Grasshopper *(Acrida hungarica)* antenna

Iron haematoxylin-eosin staining

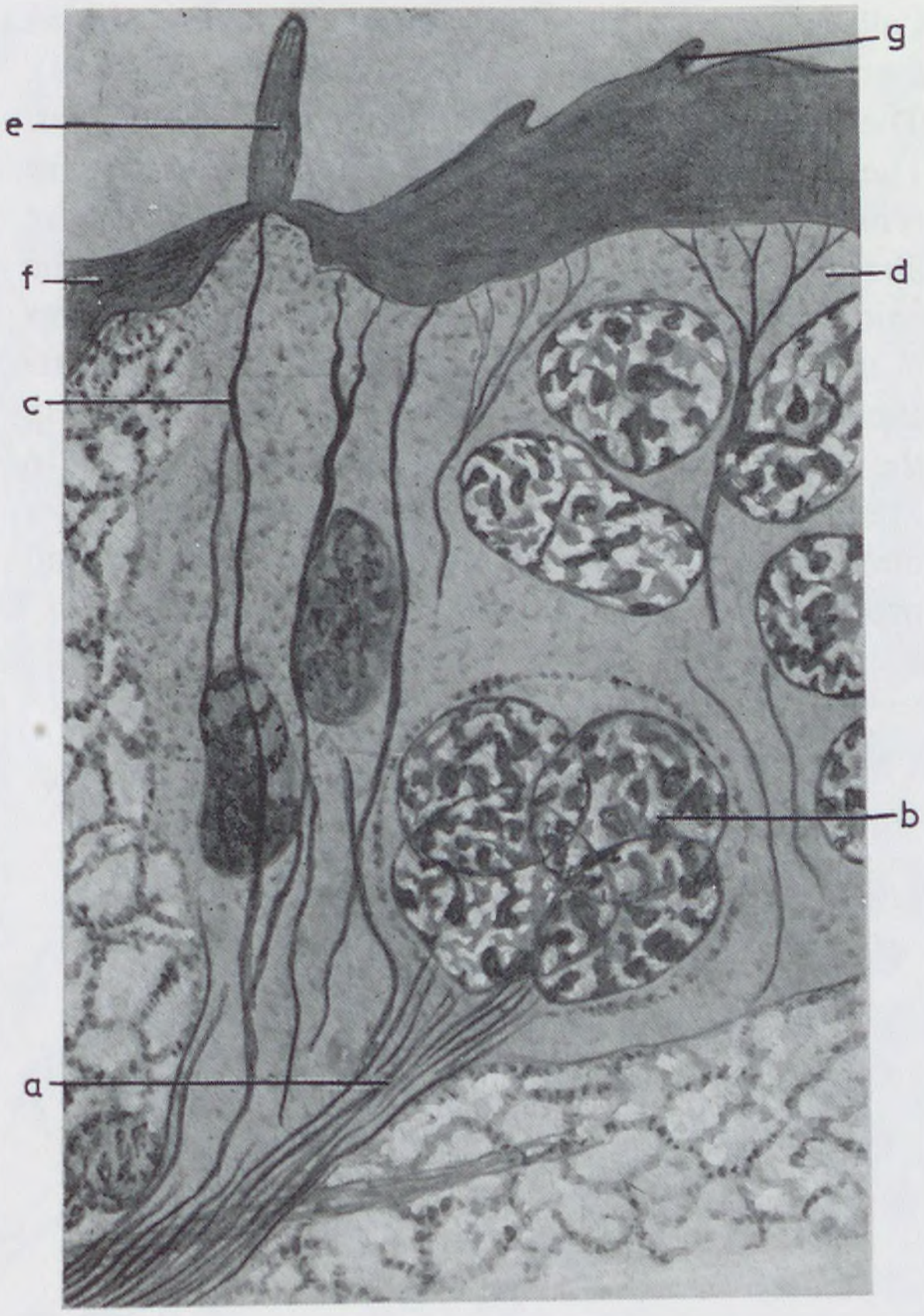

Sensory nerve (a) of the antenna. Some fibres of the nerve approach the secondary sensory cells (b) which are arranged in groups and enveloped by a sheath of fine connective tissue fibres. Single nerve fibres (c) branch off from the sensory nerve and pass through the intercellular spaces of the hypodermis (d) entering a chitin bristle (e). The thick chitin cuticle (f) covering the epidermis is composed of chitin protrusions (g) and of chitin lamellae in a shingle-like arrangement. The nerve enters the bristle where the chitin layer is very thin. Although the receptors are more difficult to demonstrate in this species than in the analogous organs of the crayfish, Heidenhain's iron haematoxylin-eosin staining and Golgi's silver impregnation method enabled us to detect various clusters of sensory cells, e.g. the Johnston's organ of the scolopal organs, in the antenna of Acridiidae, Locustidae and Coleoptera. These sensory organs play an important role in mechanoreception and olfaction. The antennae of some species of Lepidoptera are also quite peculiar, but their functional importance is rather inadequately known at present. Electron microscopic and electrophysiological investigations of the antenna (and mainly of the antennal flagellum) may yield information in this respect.

Ethology and coenology

This grasshopper is common all over Southern Europe. The frons is a spike-like prominence; the three-edged antennae are articulated in a socket on each side of the head.

Plate 6

Carp *(Cyprinus carpio)* skin

Bielschowsky–Gros silver impregnation

Cellular layers of the epidermis (a). Note the various forms of the epithelial cells (c) and their nuclei (d). The corium (b) is directly attached to the epidermis. The connective tissue bundles (e) and cells (f) vary remarkably both in form and density. The nerve fibres (g) form an extensive, loose plexus near the epidermis. One of the thick nerve fibres terminates in a special formation (h). This is the first appearance of a primitive corial sensory organ, which – in the course of phylogeny – has developed into Meissner's corpuscles of the primates through a number of forms differing in size, structure and proportions.

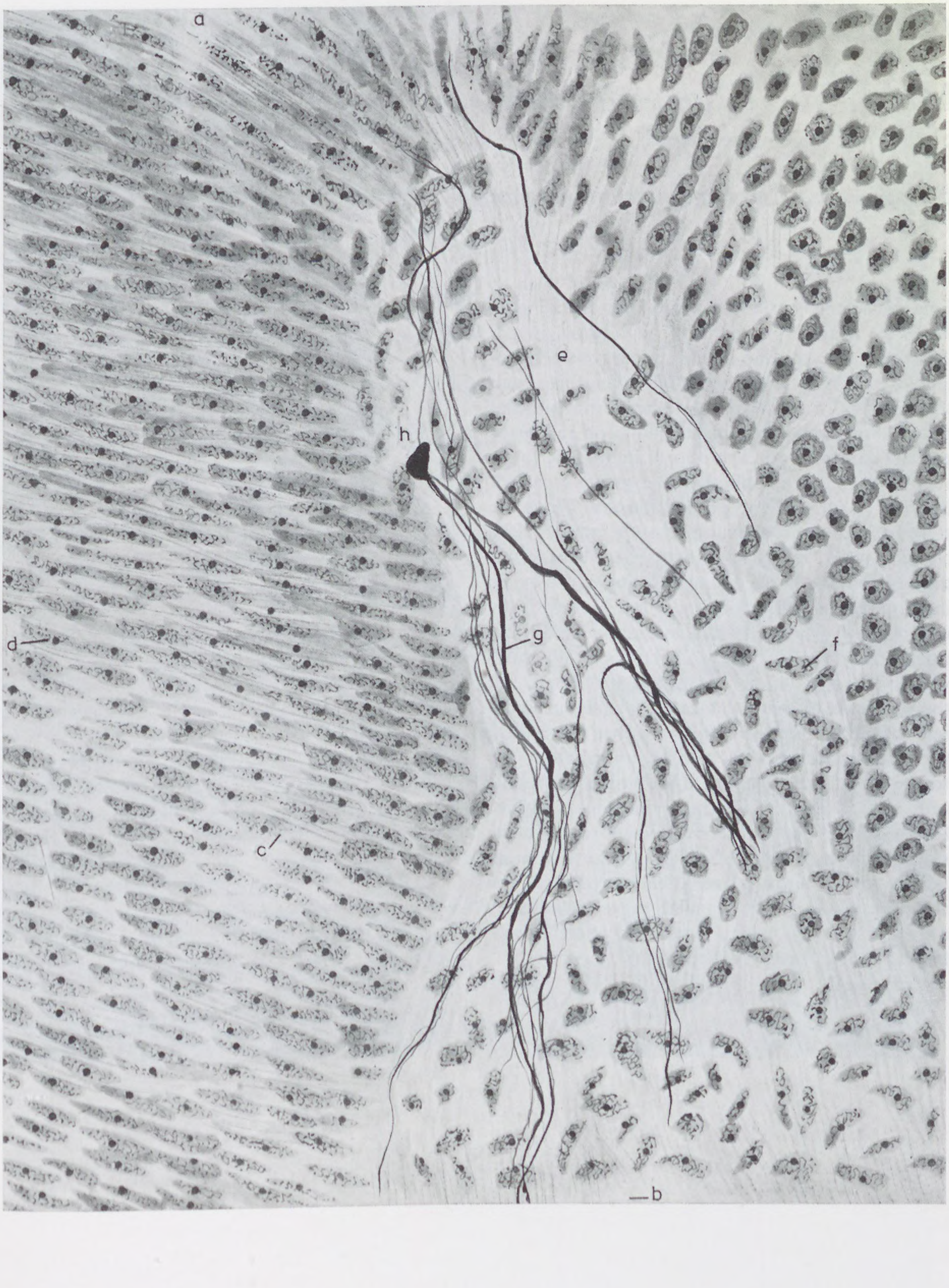
a
e
h
d
g
f
c
b

Plate 7

Marsh-frog *(Rana ridibunda)* skin of the sex pad

Bielschowsky–Ábrahám silver impregnation

Epidermis and corium (b) with two thick nerve fibres (c) densely packed with neurofibrils in the upper corial layer. One of the two nerve fibres extends deeply into the epithelium (d), then turns back towards the basal layer. Another intraepithelial nerve fibre terminating in an end-knob (e) has a parallel course. While it is almost impossible to reveal sensory nerve endings in the greatest part of the frog's skin, the sex pad and the skin above the sternum, i.e. areas receiving sensory input for the clasping reflex, are richly innervated. This fact indicates that the nerve endings of the skin play an important role in the clasping reflex. However, the rest of the frog's skin is not insensitive either, because the upper layer of the corium is richly innervated. Encapsulated nerve endings are absent, but the fine nerve plexuses indicate that the corium is responsible for the sensitivity of the frog's skin. Also the tactile maculae of the corium contribute to the sensitivity of the skin. These are groups of tactile cells located right under the epithelium: primitive forerunners of the special cells which occur in the skin of snakes. A more sophisticated form appears in the skin of birds as tactile end-corpuscles. The structure of the tactile maculae suggests that they are sensory organs, even though their afferent nerve fibres have not been revealed so far.


e
b
d
c
c
e

Plate 8

Green lizard *(Lacerta viridis)* skin

Bielschowsky–Gros silver impregnation

The upper part of the plate shows the epidermis (a), while in the bottom, the corium (b) can be seen. The epidermis is made up of the stratum germinativum, stratum spinocellulare (c) and, topmost, the horny layer (d), which is lamellated and dark in colour. The undulating nerve fibres (e) are contained by the lower part of the epithelium and terminate in round or elliptical knobs (f).

Ethology and coenology

Lizards have reached a higher level of phylogeny due to their terrestrial life. A large number of nerve fibres and loosely structured round bulbs are found among the cells of the epidermis of these extremely sensitive animals. The fine structure of these intraepithelial bulbs can only be discerned under the electron microscope. In the green lizard the innervation of the corium is similar to, if not more abundant than, that of the frog. This is due partly to the requirements of terrestrial life and partly to the chromatophores which crowd the corium, although they are not involved in reception. The tactile maculae, which are plentiful in the frog's skin, are missing in the lizard; probably they are transformed as a result of terrestrial life.

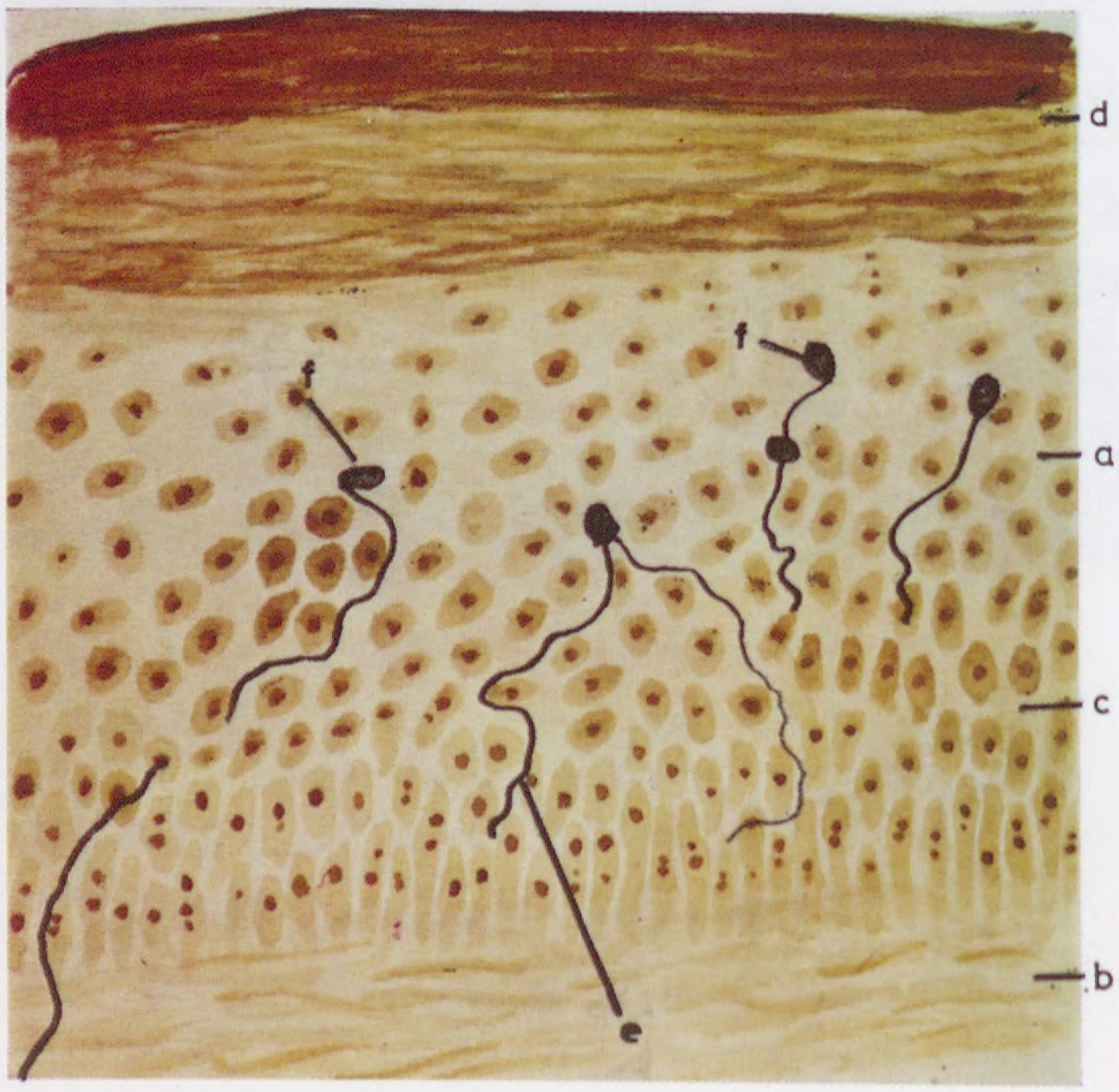

Plate 9

Grass snake *(Natrix natrix)* skin

Bielschowsky–Gros silver impregnation

Large connective tissue cells (c) with elongated nuclei and round nucleoli (a) and pigment cells with branching processes (b). The long, thick nerve fibre (d) equipped with varicosities of different sizes (e) breaks up into several branches. The branches form glomeruli and/or continue as longer sensory endings. These latter fine axons are closely related to the connective tissue cells. Another sensory system which consists of fine end-ramifications and larger neurofibrillar end-lamellae (f) is associated with the former. This rich innervation is related to the remarkable sensitivity of the skin of this animal.

Ethology and coenology

The common snake is a widely distributed animal. It moves very quickly and can be found in large numbers on the shores of lakes. The skin is especially sensitive, which is partly due to the innervated connective tissue papillae located in the vicinity of the mandible and in the oral cavity. The flexible articulation of the cranial bones enables larger snakes to swallow sizeable living frogs. In addition to the skin, also the intestines of this animal are eminently suitable for histological studies.

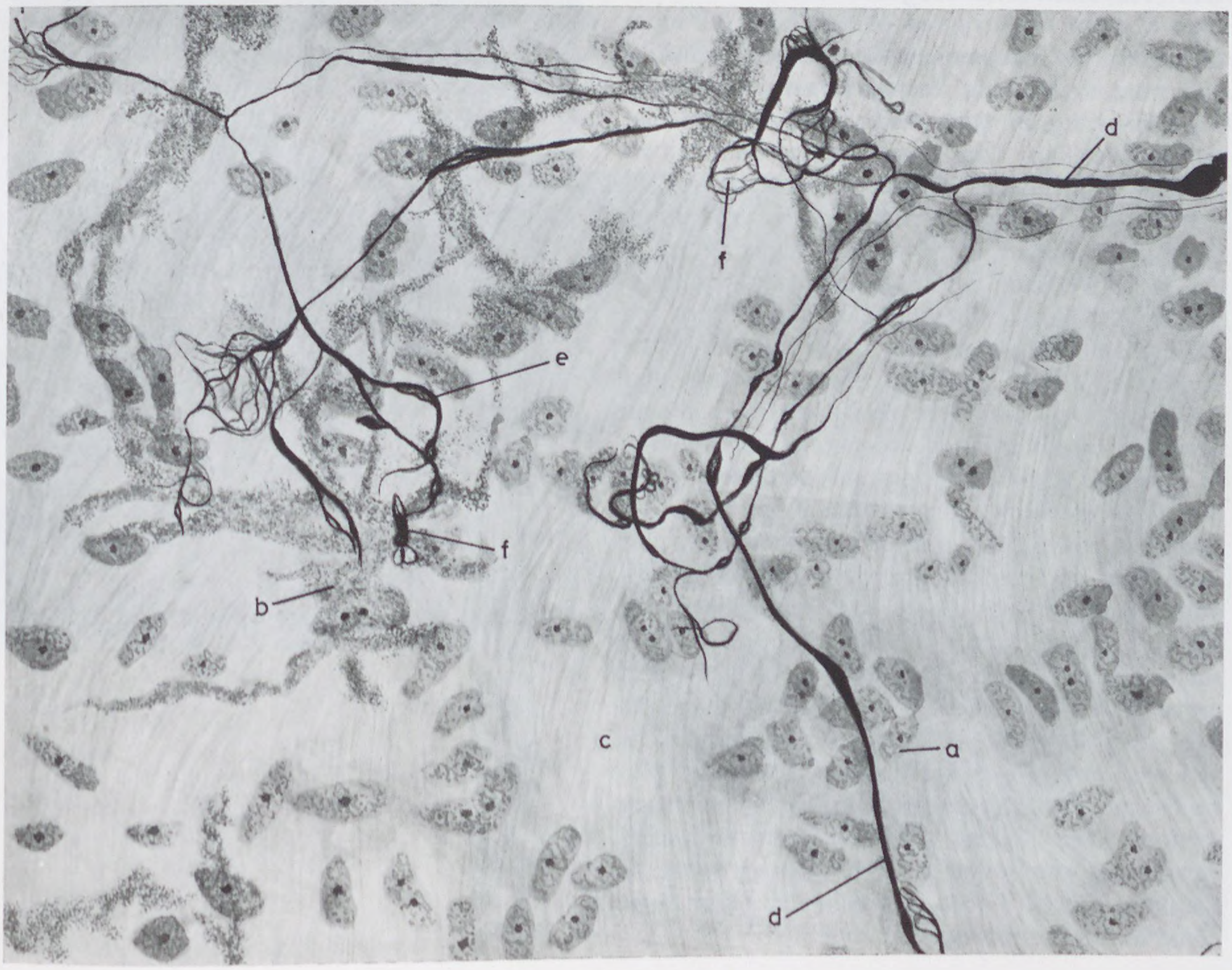

Plate 10

Dog *(Canis familiaris)*, cross-section of the nose skin

Bielschowsky–Gros silver impregnation

Stratum germinativum (c) and stratum corneum (d) of the epidermis (a). Connective tissue papillae (e) of the corium protrude into the epidermis. The corium (b) is composed of collagenous fibres; among them elongated nuclei of connective tissue cells are arranged in a line. From the corium thick and wavy nerve fibres (f) enter the epithelium where they send off several branches which terminate in the superficial layer of the stratum germinativum as intraepithelial fibres (g) with end-knobs (h).

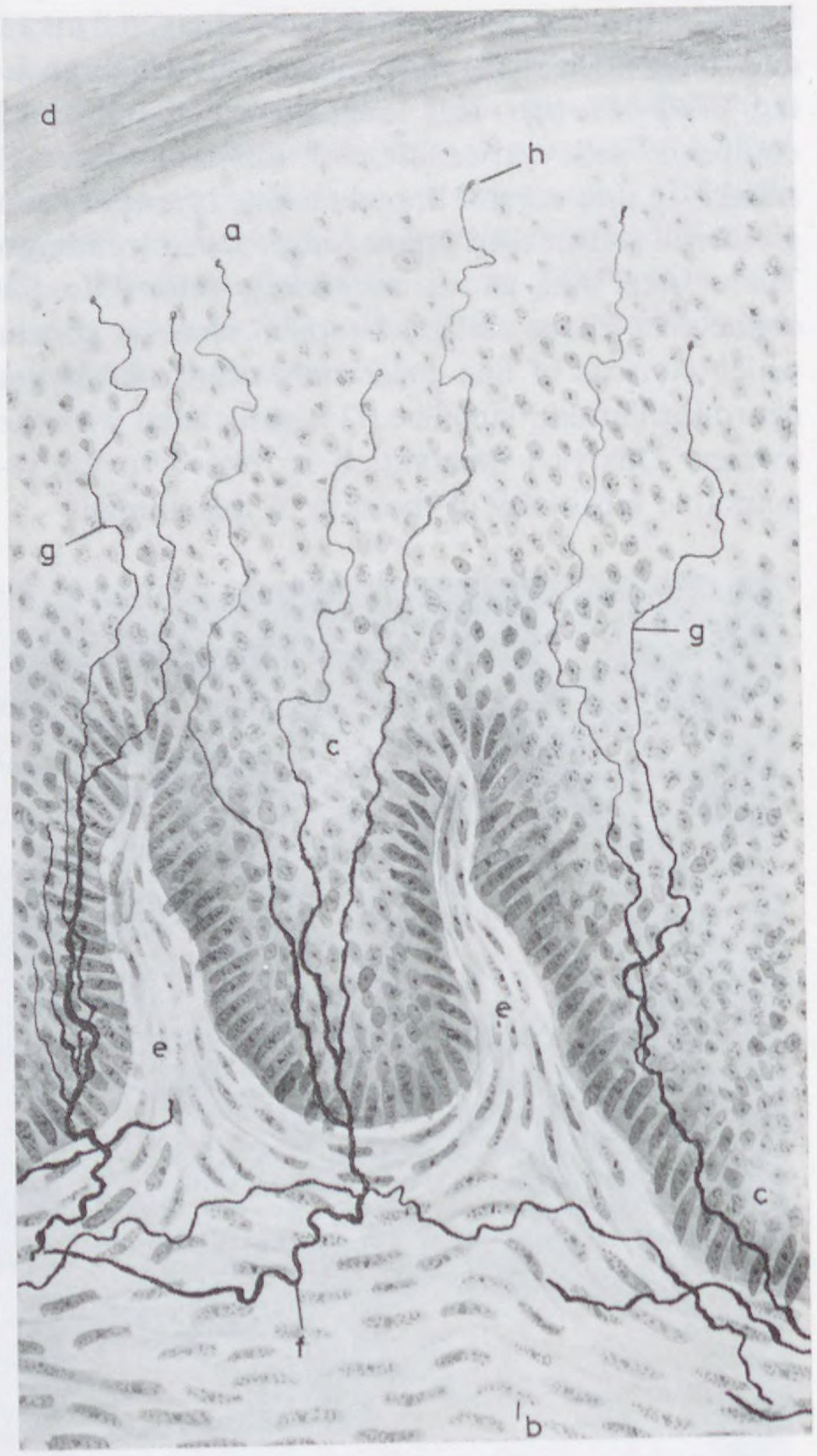

General neurohistological comments

Generally, the mammalian skin is more sensitive and more abundant in receptors than that of lower vertebrates, e.g. birds. It has to be emphasized that the mammalian skin does not contain either Grandry's corpuscles or Herbst's corpuscles. Instead, it has various free and encapsulated corial coils, dendritic end-ramification systems, Krause's end-bulbs, Pacinian corpuscles and Meissner's corpuscles. Numerous intraepithelial nerve fibres can be revealed in some areas of the epidermis. In certain animals and in special areas, Merkel's corpuscles, a few of which are also found in the human skin, can be seen. Eimer's corpuscles are common in the snout of a Madagascarian insectivore *(Centetes ecaudatus)* and in the snout of the mole *(Talpa europaea)*. The nose skin of some mammals (hedgehog, cattle and dog) proved to be most suitable for the investigation of intraepithelial nerve fibres. The pigmented snout skin is not suitable for such purposes, since it is very difficult to distinguish nerve fibres from pigmented epithelial elements against the dark background of the epidermis. The yellowish nose skin of the dog and cattle proved to be the most suitable for beautiful and convincing sections. The highest number of intraepithelial nerve fibres were found in the hedgehog's snout. In the skin of the cat's nose, intraepithelial nerve fibres could hardly be impregnated.

Plate 11

Dog *(Canis familiaris)* nose skin

Bielschowsky–Gros silver impregnation

Innervation of an epithelial peg (a). Not infrequently the thick nerve fibre entering the epithelial peg forms a coil-like plexus in the deeper part. Elongated nuclei of the cells of the stratum cylindricum can be seen at the base and along the sides of the peg, while in the middle also the cells of the stratum spinosum are present. Both sides of the epithelial peg are bordered by corial papillae (b). Within the corium, connective tissue fibres and elongated nuclei of the connective tissue cells can be distinguished. From the corium a thick nerve fibre (c) extends deep into the epithelium, then it recurves and ramifies; the terminal arborization, interwoven with nerve fibres of different origin, forms an abundant intraepithelial plexus (d). Tapering terminal axons of the plexus terminate as bulbous thickenings (e) between the epithelial cells.

General neurohistological comments

This type of the intraepithelial nerve endings is very rare; a similar structure can only be found in the stratified squamous epithelium of the mammalian cornea. In most cases the intraepithelial nerve fibres arriving from the stratum cylindricum extend towards the surface of the epithelium without branching. Branching and recurving intraepithelial nerve fibres can be found in the puppy's nose skin and in the epithelium of the human epiglottis. Nerve fibres which innervate the epidermis of the nose skin (and stratified epithelia in general) are uniformly thick and run parallel up to the superficial layers. A significant difference in the diameters of the nerve fibres could be revealed only in the cattle's nose skin, where thick nerve fibres give off short collaterals.

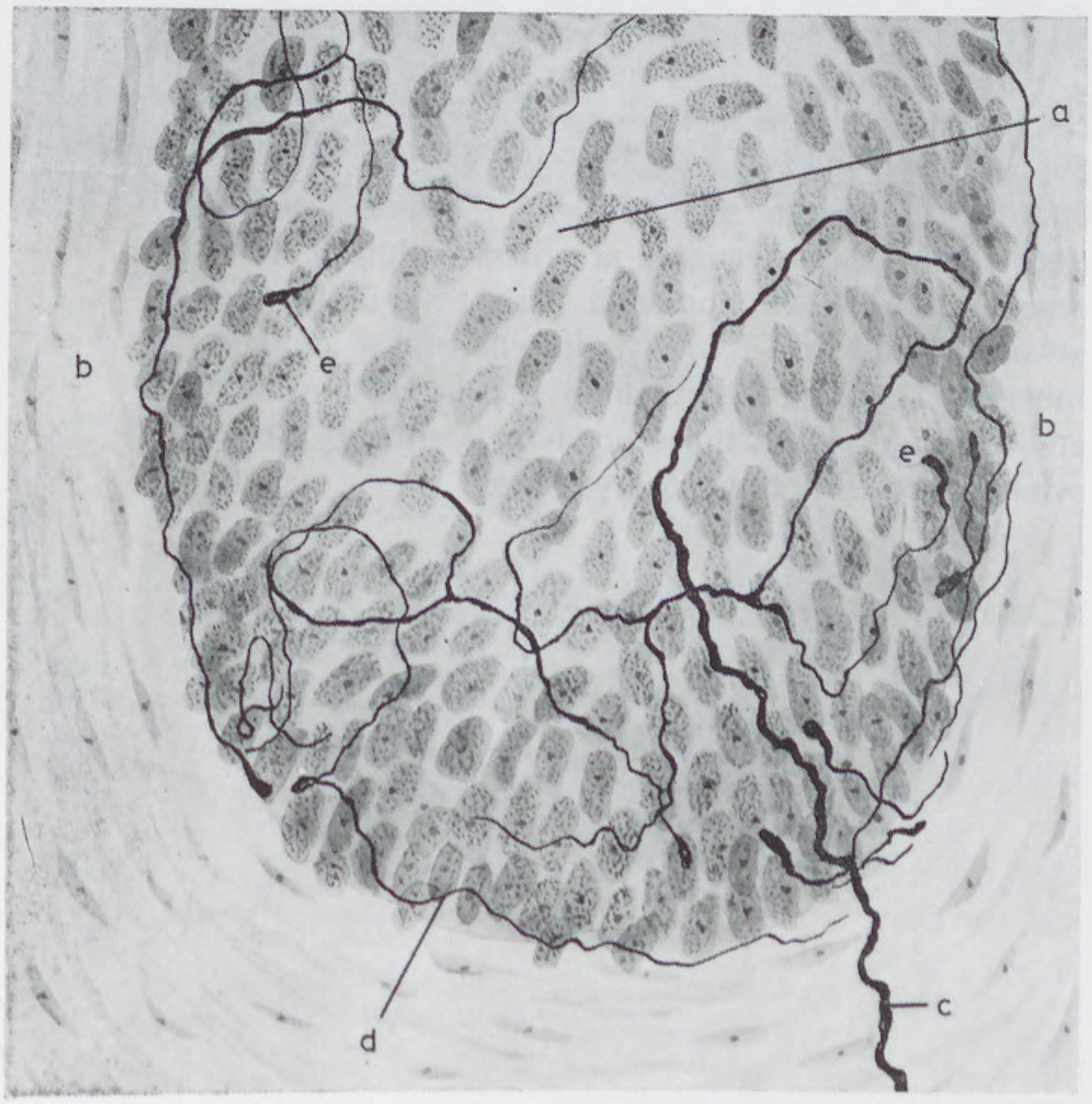

Plate 12

Dog *(Canis familiaris)* nose skin

Bielschowsky–Gros silver impregnation

Nerve fibres (c) passing through the intercellular spaces of the stratum germinativum (a), and terminating near the stratum corneum (b) as knob-like thickenings (d). Some of the end-knobs are densely structured, in other ones the neurofibrils are clearly recognizable. Several nerve endings appear to enter epithelial cells and approach the nucleus (e). It should be emphasized that light microscopic pictures are never authentic as regards the relation between the nerve fibre and the cytoplasm of the epithelial cell. Electron microscopic investigations have revealed that the nerve fibres proceed in the intercellular spaces, and a trough-like impression appears on the cell surface where the nerve fibre is in contact with the epithelial cell. This relationship has been demonstrated in the epithelial cells and nerve fibres of the mammalian cornea. However, to fully clarify the relation between the cells of the stratified squamous epithelium and the intraepithelial nerve fibres, further investigations of serial electron microscopic sections are required. It would be important to know whether or not the nerve endings disintegrate together with the horny cells and whether new synapses are formed during the regeneration of the epithelial tissue. Similarly, it awaits clarification whether all cells of the richly innervated stratified epithelium should be considered sensory or only those which have entered into synaptic connection with nerve fibres.

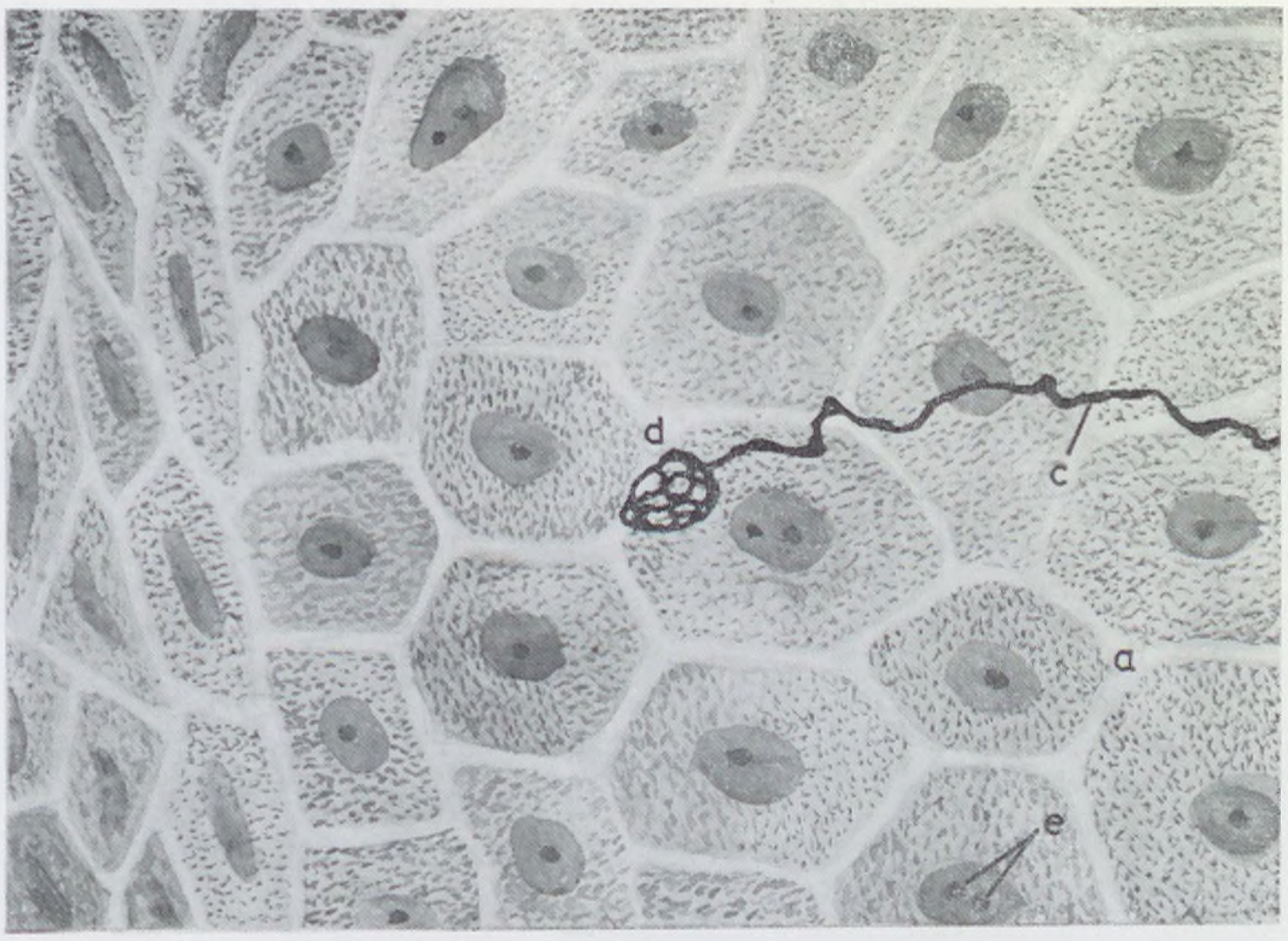
d
c
a
e


a
b
d
c

Plate 13

Dog *(Canis familiaris)* nose skin

Bielschowsky–Gros silver impregnation

Innervation of a sinus hair of the dog. The corium (a) and the nerve fibres are connected to the sinus hair. The root sheaths (b) are weakly impregnated to ensure demonstration of the nervous elements. In the right lower corner a nerve trunk (c) approaches the root of the sinus hair. This nerve trunk is composed of several finer and thicker varicose nerve fibres. Note the free endings of the fine nerve fibres (d) in the spaces between the cells of the root sheaths in the upper part of the plate. Under normal conditions, the sinuses (e) on the right are filled with blood. At elevated arterial pressure their blood content markedly increases, thus the nerve fibres are pressed against the central hair shaft.

Coenology

These sinus hairs are remarkable both in their structure and function. When the nerve fibres that surround broom-like the lower part of the hair follicles are pressed by the dilated sinuses against the hair shaft, the animal immediately perceives the slightest mechanical stimulus (touch, motion or air current). This is important in the tactile exploration of the animal. Such sinus hairs occur in Canidae, where they are found only in the labial area, and in cats, where they constitute the whiskers. Dogs, too, have sinus hairs in their whiskers, but less than the cat. Their structure is generally the same with the difference that the cat's whiskers are long, thick and pointed and reach deep into the corium. The base of the hairs is surrounded by sinuses which are cylindrical and run parallel to the hair follicle and the root sheaths. The function can be well observed in the cat responding even to the slightest noise when standing in the corner and waiting for the mouse to appear. As to the extreme sensitivity of the whiskers of the cat a popular belief holds that the tomcat whose whiskers are severed runs away from the house. Although this is rather a fancy tale, it may have some truth in it.

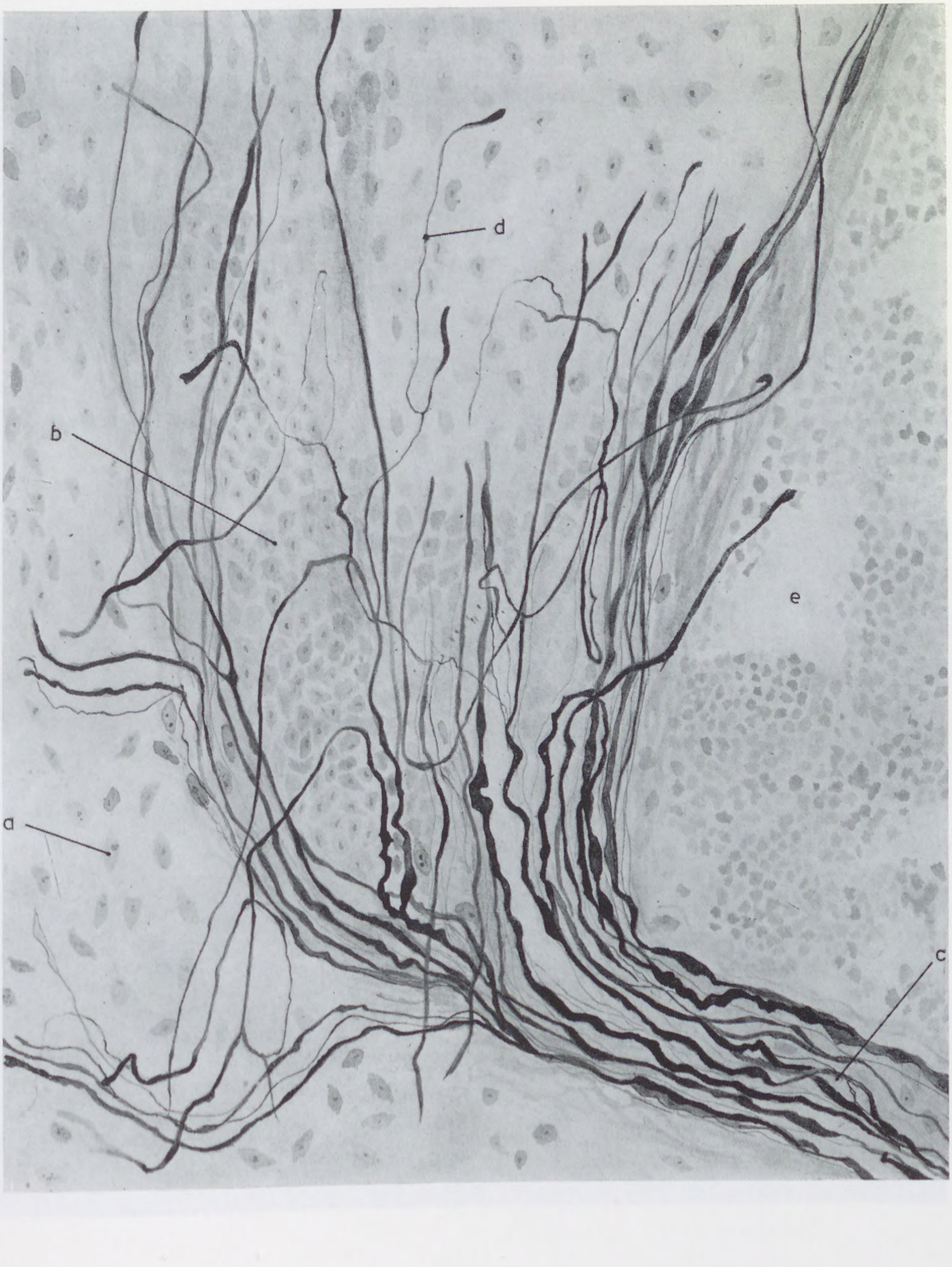
d
b
e
a
c

Plate 14

Hog *(Sus scrofa domestica)* snout

Bielschowsky–Ábrahám silver impregnation

Epithelial peg (upper right corner) in which the characteristic layers of the epidermis, mainly the stratum basale and stratum spinosum (a), can be seen. In these two layers, especially in the lower part of the stratum spinosum, Merkel's tactile cells (b) are arranged in groups. Their nuclei are round and smaller than those of the adjacent epithelial cells. Nerve fibres (d) run to each Merkel's cell. Some fibres of the subepidermal corial plexus (e) are thick and wavy, and contain neurofibrils (f); they bear several varicosities of different size. The nerve fibres enter the epidermis, pass through the intercellular spaces of the stratum basale and run to Merkel's cells. The branches are widened and form chalice-like nerve terminals which surround a large part of Merkel's cells (c). In well-impregnated preparations the loose neurofibrillar structure of the terminal nerve fibres running to Merkel's cells can clearly be seen; these surround the tactile cells in a petal-like formation. In the adjacent part of the corium numerous arteries and veins (g) can be found among the thick collagenous fascicles (h). Generally also the periphery, where nerve fibres and sensory endings are abundant, is richly supplied with blood vessels.

The snout skin of the hog is suitable for electron microscopic investigation of Merkel's cells since these are arranged in clusters here.

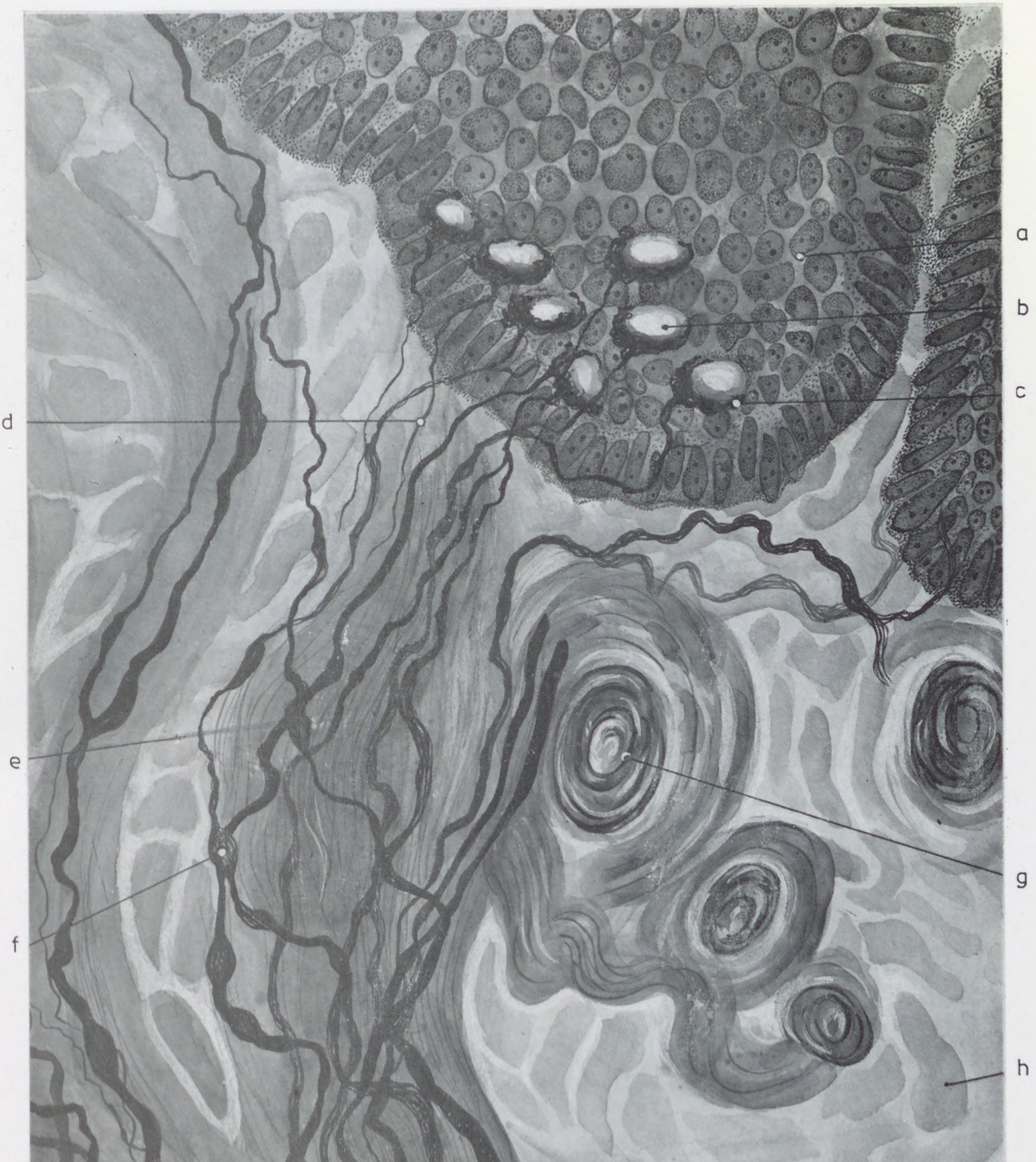
a
b
c
d
e
f
g
h

Plate 15

Hog *(Sus scrofa domestica)* snout skin

Jabonero's silver impregnation

1. A fascicle of thick nerve fibres runs through the corium and enters the hair follicle which is located in the upper right corner of the picture. The nerve fibres show a parallel arrangement, then they ramify at the base of the follicle and form a horse-tail-like terminal system around the follicle and the root sheaths.

2. The radix of the sinus hair is surrounded by a system of terminal sensory fibres.

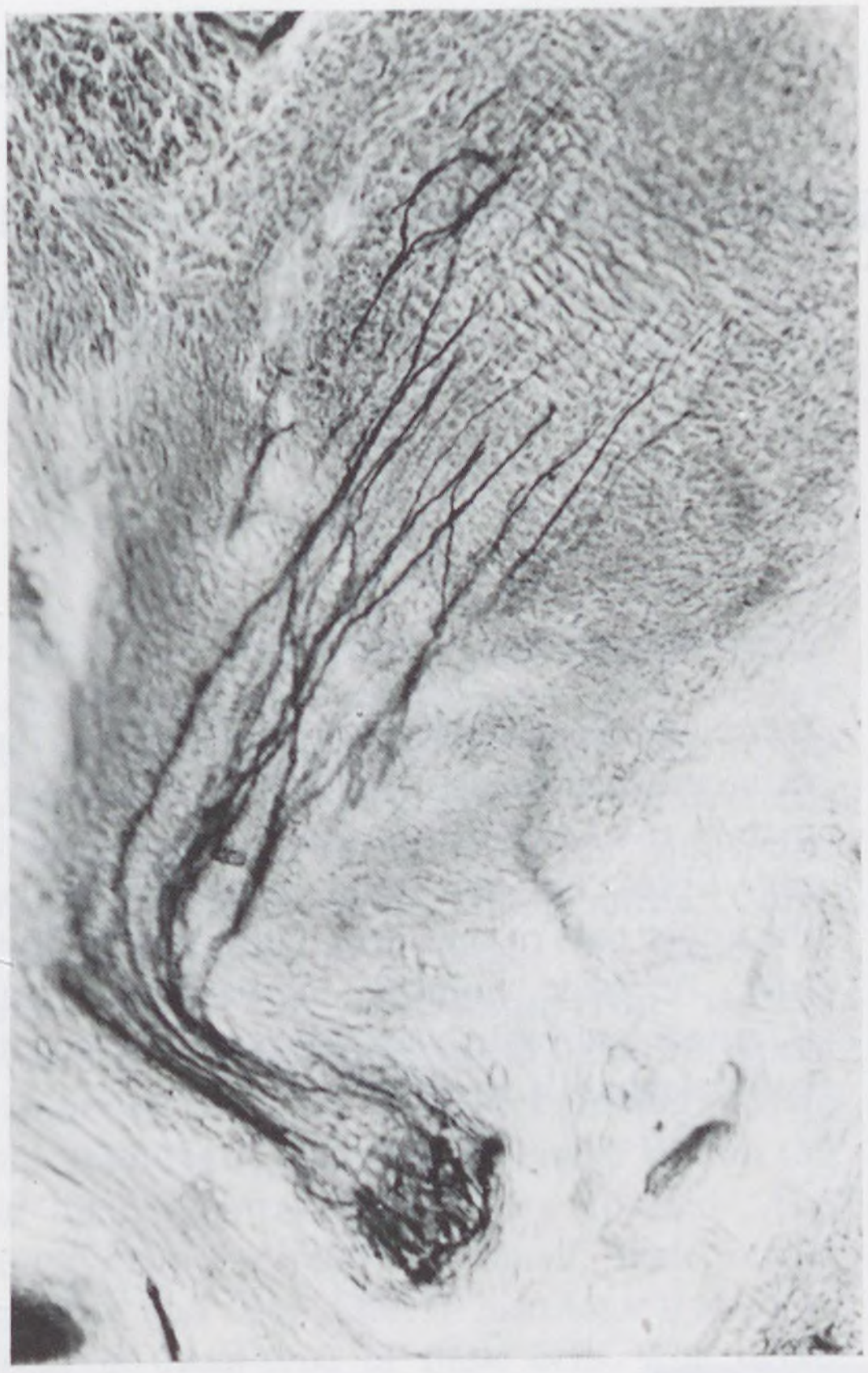

1

2

Plate 16

Indian elephant *(Elephas maximus)* trunk

Bielschowsky–Gros silver impregnation

The epidermis (a) with large elongated nuclei (b) containing dense, eccentric, darkly impregnated nucleoli (c). Nerve fibres of different thickness (d) zigzag between the epithelial cells. The nerve fibres show varicosities packed with neurofibrils and terminate in extremely large intraepithelial endings (e) forming distinct coil-like structures. A loosely interwoven tangle of neurofibrils forms these intraepithelial sensory terminals (e). In rare cases the neurofibrils of the terminal are rearranged and the nerve fibre continues as an ultraterminal fibre (f). Branching or recurving intraepithelial nerve fibres are not to be found in the elephant's trunk.

Functional neurohistology

It is well known that the elephant's trunk functions as a sensitive tactile organ. This sensitivity is due mainly to the great number of intraepithelial sensory fibres, but the corial corpuscles abundant in the upper part of the corium also play an important role. A large number of variously structured Krause's end-bulbs were found in the corium of a baby elephant's trunk.

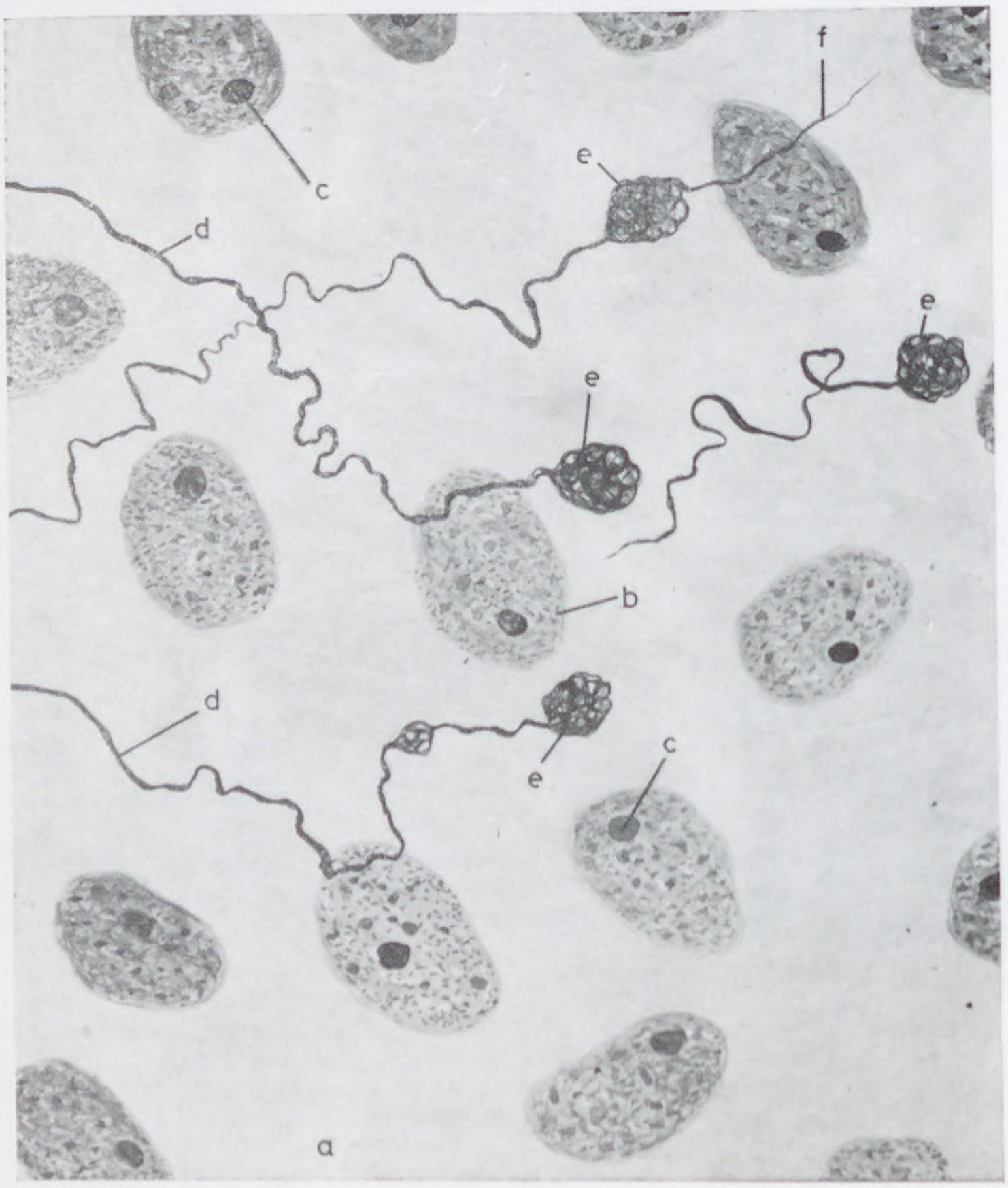

Plate 17

Common mole *(Talpa europaea)* snout

Electron micrograph

Nerve fibres in cross-section. Note Schwann's cells, the axons (A) with the neurofilaments (Nf) in cross-section, and the myelin sheath (My). The round perikarya (P) of the Schwann's cells contain cisterns of the endoplasmic reticulum (Er) and ribosomes (R) arranged in clusters. M – mitochondria; Cm – membrane of Schwann's cells; N – nuclei of Schwann's cells; Chr – chromatin; Nm – nuclear membrane. The nerve fibres of Eimer's corpuscle are surrounded by a thin, less differentiated capsule supplied abundantly with blood vessels. Within the capsule many Schwann's cells are located. The Schwann's cells are relatively small, their nuclei are eccentric and they differ in histological appearance from the usual type of these cells. The nerve fibres are surrounded by collagenous fibres (Co).

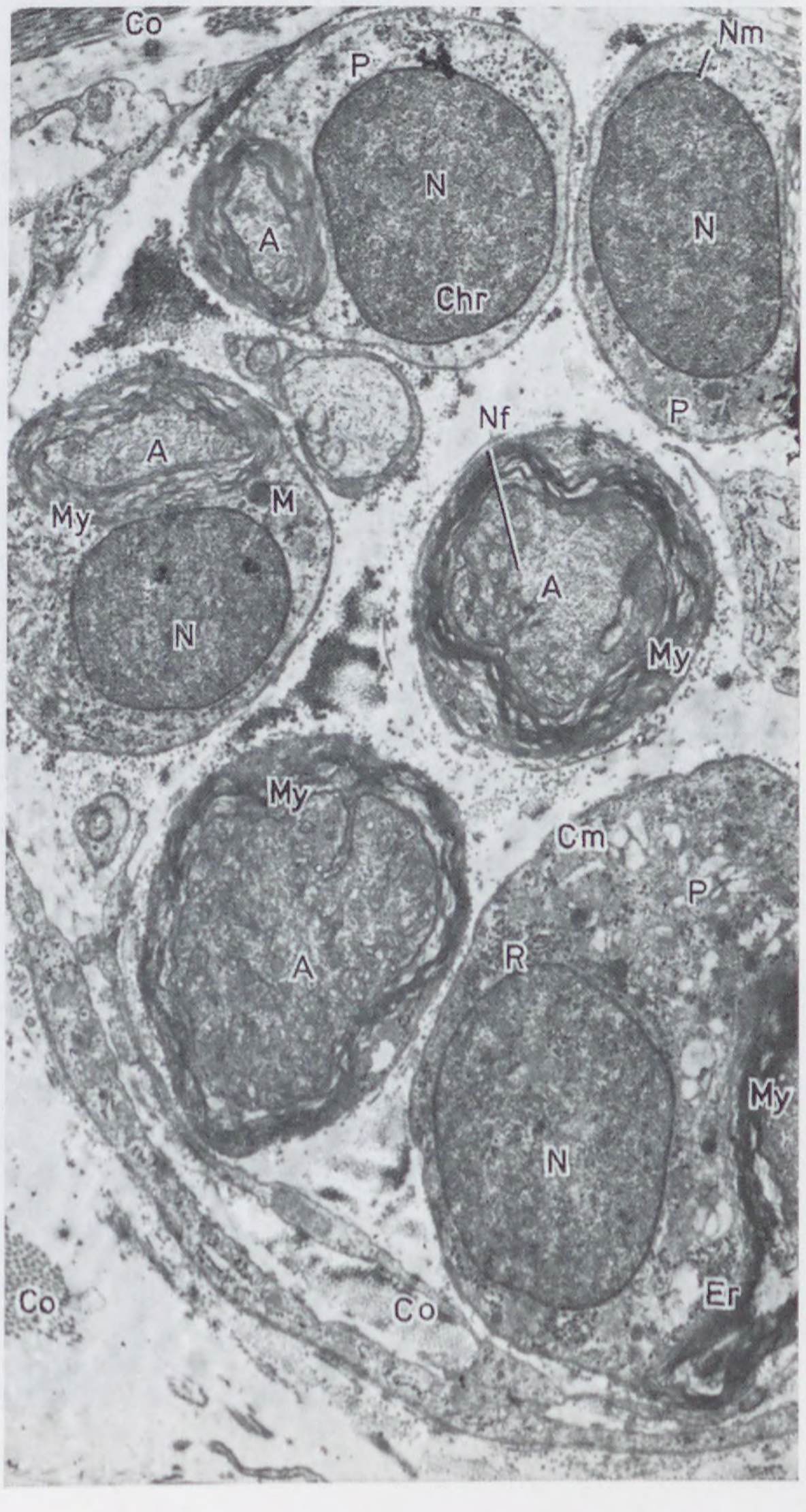

Plate 18

Hedgehog *(Erinaceus europaeus)*; cross-section of the nose skin; lamellar body

Electron microscopic preparation

The skin of the hedgehog, like that of all vertebrates, is composed of corium and epidermis. These two layers are separated by a thin basal membrane.

The lamellar nerve ending located in the corium is a special receptor organ. It consists of two parts: the lamellar system and the disk-like nerve ending. The lamellar system is composed of 6 to 7 concentrically arranged lamellae (L) surrounding the nerve fibre. Some of the lamellae may ramify (Ra). Some of them pass round the nerve fibre, while others turn back and terminate within the lamellar system itself (Kn). Within the lamellae elliptical mitochondria (M) can be seen. Exocytosis (Ex) is characteristic of all lamellae. The cisterns of the endoplasmic reticulum (Er) and the lines of ribosomes (R) are apparent in the lamellae. The non-myelinated terminal portion of the nerve fibre (A) is limited by the axolemma (Al). A wide intercellular space (Sp) can be seen between the axolemma and the cytolemma (Cm) of the immediately adjacent lamellae. The homogenous axoplasm contains vesicles of various size, some of which are round and dark (V) while others are ovoid (Vo) or asymmetrical. In the vicinity of the axolemma, ovoid, elongated and asymmetrical cristate mitochondria (M) can be seen in large numbers. The lamellar body undoubtedly has the function of a tactile organ.

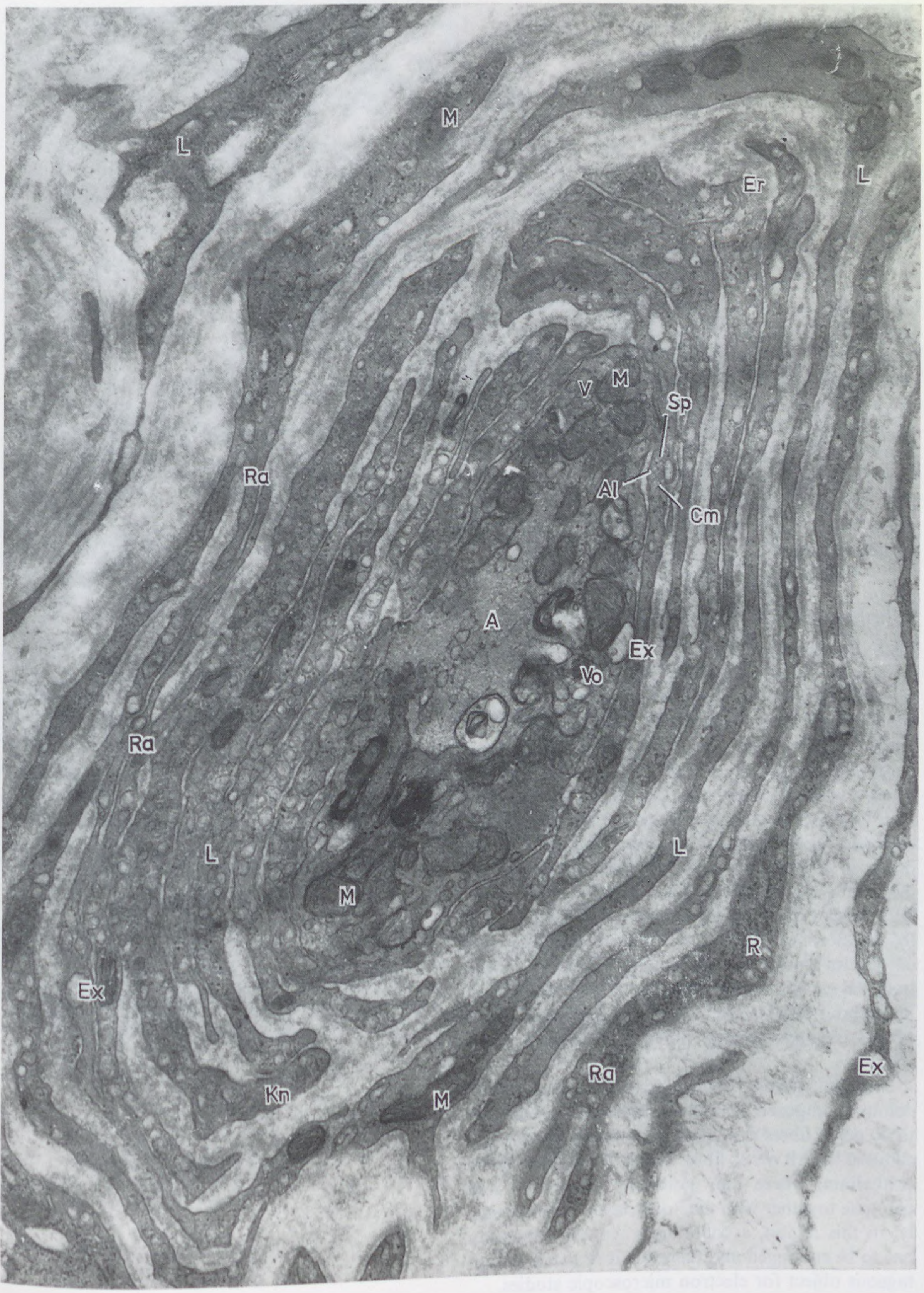
M
L
Er
L
V
M
Sp
Ra
Al
Cm
A
Ex
Vo
Ra
L
L
M
R
Ex
Kn
M
Ra
Ex

Plate 19

Common mole *(Talpa europaea)* snout

Bielschowsky–Ábrahám silver impregnation

On the right: epidermis, including the epithelial pegs flanked by connective tissue papillae, the stratum corneum (a) and the subjacent stratum germinativum (b). On the left: corium (c) with connective tissue fibres, the nuclei of the connective tissue cells (g), and abundant nerve fibres. The thick myelinated fibres (d) converge towards the epidermis and continue in Eimer's corpuscle (e). Some fibres maintain their parallel course throughout the epidermis. These nerve fibres also enter the horny layer and terminate there (f).

Ethology, coenology and functional neurohistology

In 1871 Eimer described tactile corpuscles in the snout of the mole (known as Eimer's corpuscle). Since the eyes of this animal are rudimentary, these corpuscles function as important tactile organs. Their abundant innervation suggests that, in addition to a tactile sensory function, they are in fact complex sensory organs satisfying the less-known needs of underground life. Besides the mole, the New Guinean insectivore *Centetes escaudatus* is the only species in which Eimer's corpuscles have been found. Sensory structures reminiscent of Eimer's corpuscles are present in the nose skin of the hedgehog, the cattle and the dog. The mole's snout contains about 5,000 Eimer's corpuscles and the number of the connected nerve fibres is estimated to be 150,000.

Essentially, each Eimer's corpuscle is an epithelial column composed of sensory cells among which 20 to 40 nerve fibres run upwards to the surface of the snout skin. All nerve fibres reach the surface of the epithelium, where they gradually degenerate and exfoliate together with the horny layer. Consequently, in this region, a continuous synapse formation has to be envisaged and therefore it is a very advantageous object for electron microscopic studies.

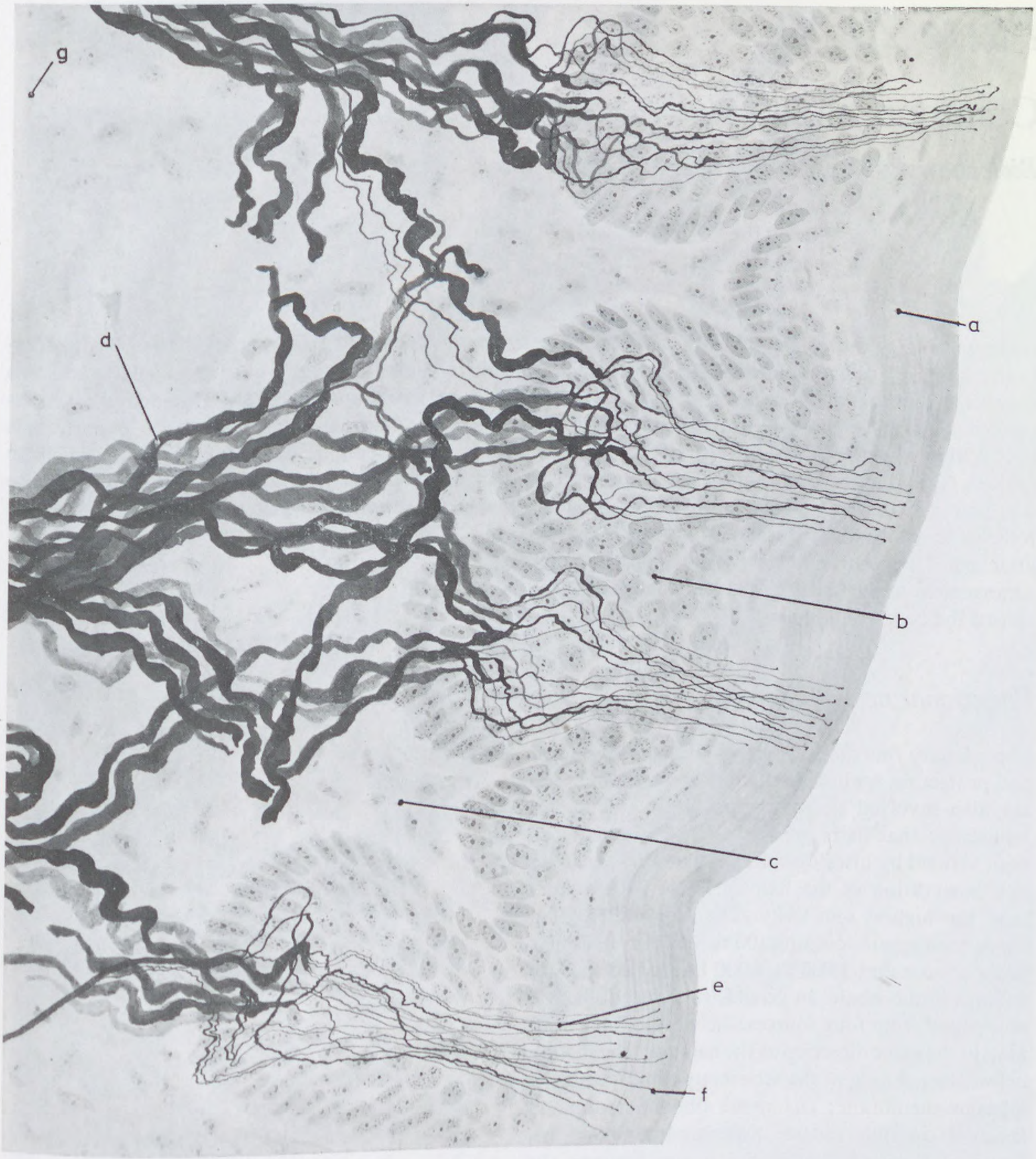
g
a
d
b
c
e
f

Plate 20

Common mole *(Talpa europaea)* skin

Bielschowsky–Ábrahám silver impregnation

Impregnated section of the mole's facial skin. The horny layer (d) of the epidermis (a) protrudes between the hairs. The lower layer of the epidermis, packed with nuclei, is the stratum germinativum (c). Within the thick corium (b) numerous hair follicles (e) and sebaceous glands (h) are to be seen. The hairs (g) are immediately bordered by the hair follicles to which the external root sheaths (f) are attached. Thick nerve fibres (i) showing a parallel arrangement in the hair follicles and root sheaths (j) run to the base of the hairs.

Functional neurohistology

The primary function of hairs is thermal insulation and protection against mechanical impacts, but they are also involved in perception. It is a common knowledge that hairs are "sensitive", and this has been verified by histological investigations revealing rich innervation of the hair follicles. Tactile hairs have the highest sensitivity. The hair follicle of a single tactile hair contains 100 to 180 nerve endings in the mouse and 3,000 to 4,000 lamellated sensory endings in the whale. In general each hair follicle is innervated from four sources: *(i)* nerve fibres running in the same direction as the hair and terminating below the opening of the sebaceous glands, near the vitreous membrane; *(ii)* nerve fibres surrounding the hair ring-like outside the vitreous membrane. Some of them also enter the spaces between the epithelial cells of the outer root sheath and terminate in disk-like structures; *(iii)* vasomotor fibres innervating the blood vessels of the hair follicle; and *(iv)* those innervating the blood vessels of the papillae. Sensory nerve endings can only be found in the papillae of the largest tactile hairs. The innervation of hairs is equally well developed in animals and in man, but especially abundant in species where the hairs also serve as tactile organs. This function is especially well established in the Felidae and in blind animals living underground like the mole-rat *(Spalax typhlus)* and the common mole *(Talpa europaea)*.

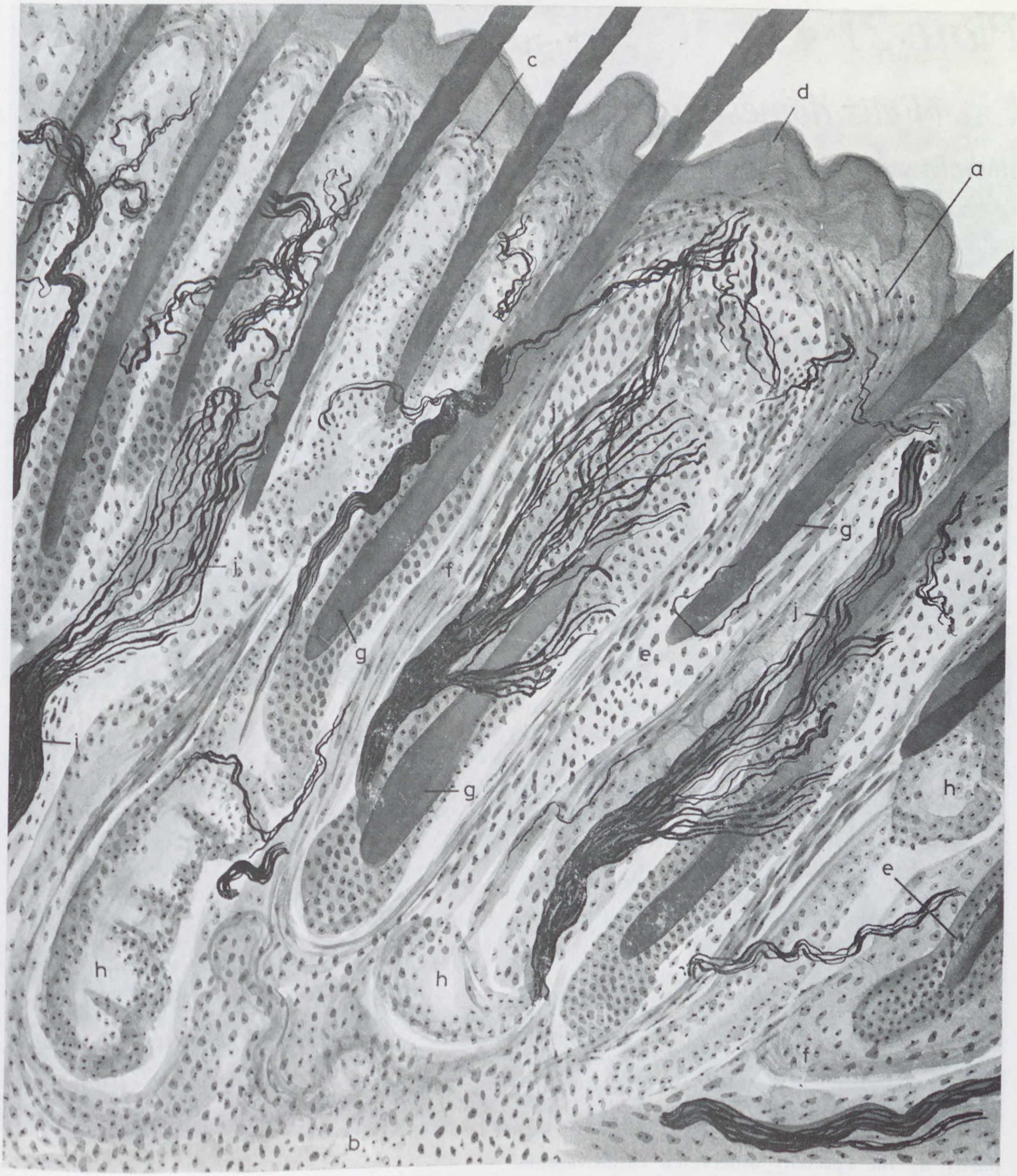
c
d
a
g
j
f
j
g
e
i
g
h
h
h
h
e
f
b

Plate 21

Cat *(Felis domestica)* skin

Bielschowsky–Gros silver impregnation

Longitudinal section of a hair (a) and a hair follicle. The hair has a medullary substance, a homogeneous cortical substance and the cuticle with overlapping elongated scales resembling the tiles of a roof. The hair follicle (b) with its typical nucleus joins the lower part of the hair. These structures with their nerve supply are located in the corium (c) in which, besides the innervated one, four other hairs with parts of their root sheaths are also visible.

In the lower left corner two nerve fascicles are shown. Each consist of thick myelinated nerve fibres (d) running upwards and joining the hair follicle and the root sheaths. Some nerve fibres run upwards within the hair follicle and, after having lost their myelin sheaths, break up into fine branches which closely surround the hair follicle (e). In this way the slightest distortion of the hair induces nerve impulses. Other nerve fibres terminating at the lower part of the hair follicle surround them, forming loop-like or concentric fibre systems (f).

Functional neurohistology

The arrangement of nerve fibres around the hair follicles proves that the facial hairs of the cat function as sensory organs. The silver-impregnated sections show that even the pelage cannot be considered as a mere cover serving for protection and keeping the animal warm. Cats are vigilant, wary, and quick animals. These capacities are ensured partly by the specially innervated cardiovascular system, and partly by the hairs, mainly by those of the face.



1

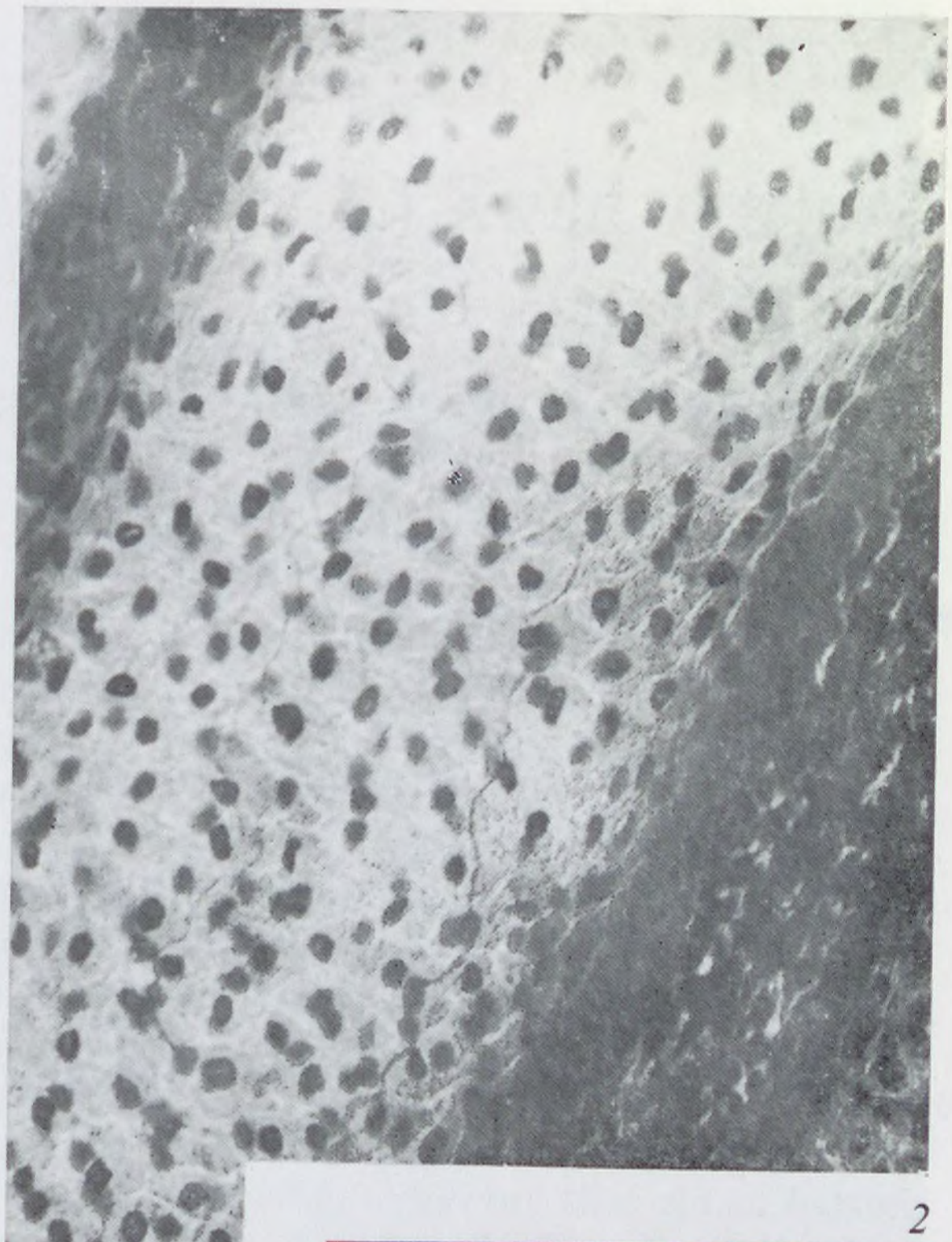

2

3

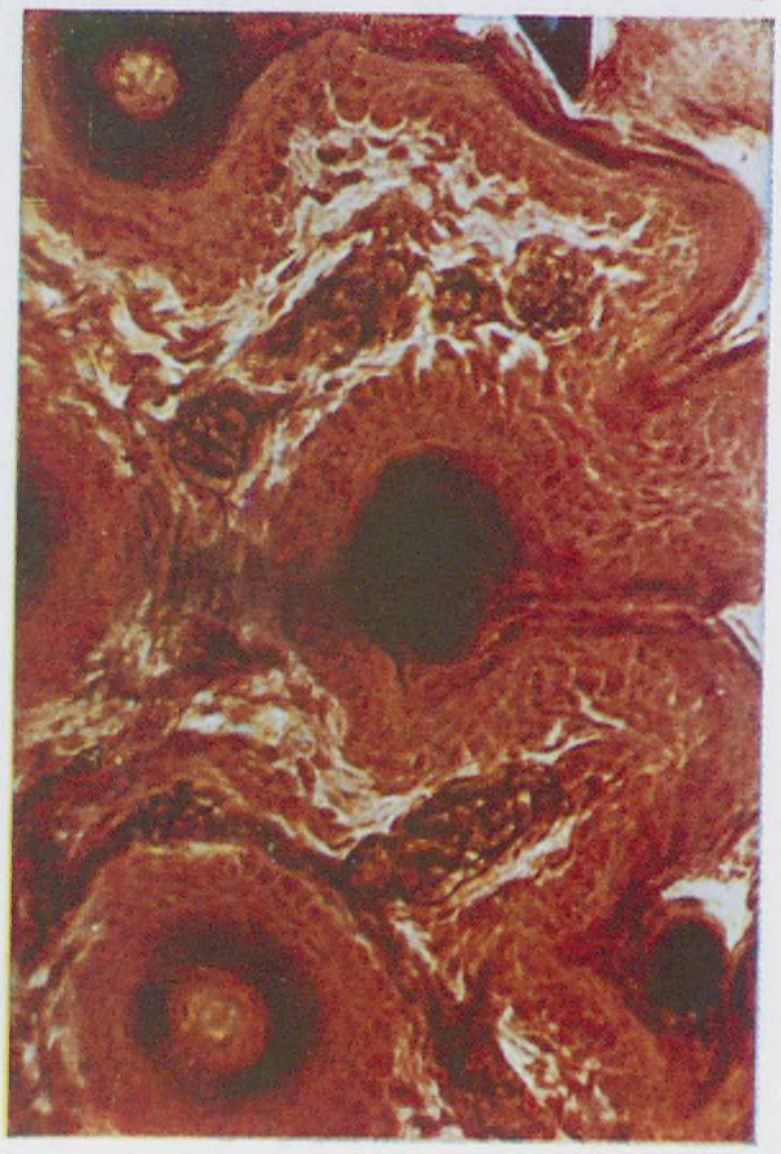

4

Plate 26

Sparrow hawk *(Accipiter nisus)* skin. The calamus

Bielschowsky–Ábrahám silver impregnation

Connective tissue fascicles (a) are in a parallel arrangement in the vicinity of the feather. Between the fascicles numerous nuclei of connective tissue cells (b) are found. Note the calamus and the papilla (c) in the lower right corner of the picture. Thick, convoluted nerve fibres (d) run to the papilla; their tapering terminal branches have ring-shaped nerve endings. These terminal branches belong to a thick nerve fibre (e); in addition, fine fibres (f) originating from an adjacent elongated Herbst's corpuscle (g) can also be seen. The lamellae and the centrally situated tactile cells are only faintly discernible in the Herbst's corpuscle. Presence of the nerve fibres innervating the calamus and the papilla suggests that the small and densely distributed feathers of the head constitute, besides serving for protection, also a sensory organ.

Ethology and coenology

The sparrow hawk is one of the smaller predator birds, inhabiting the open country-side rich in spruce and meadow-grove. Nesting in small woods and parks, in winter it moves temporarily into towns to hunt the common sparrow. It feeds on little birds as well as on mice and other small mammals. The sparrow hawk kills the prey on the ground.

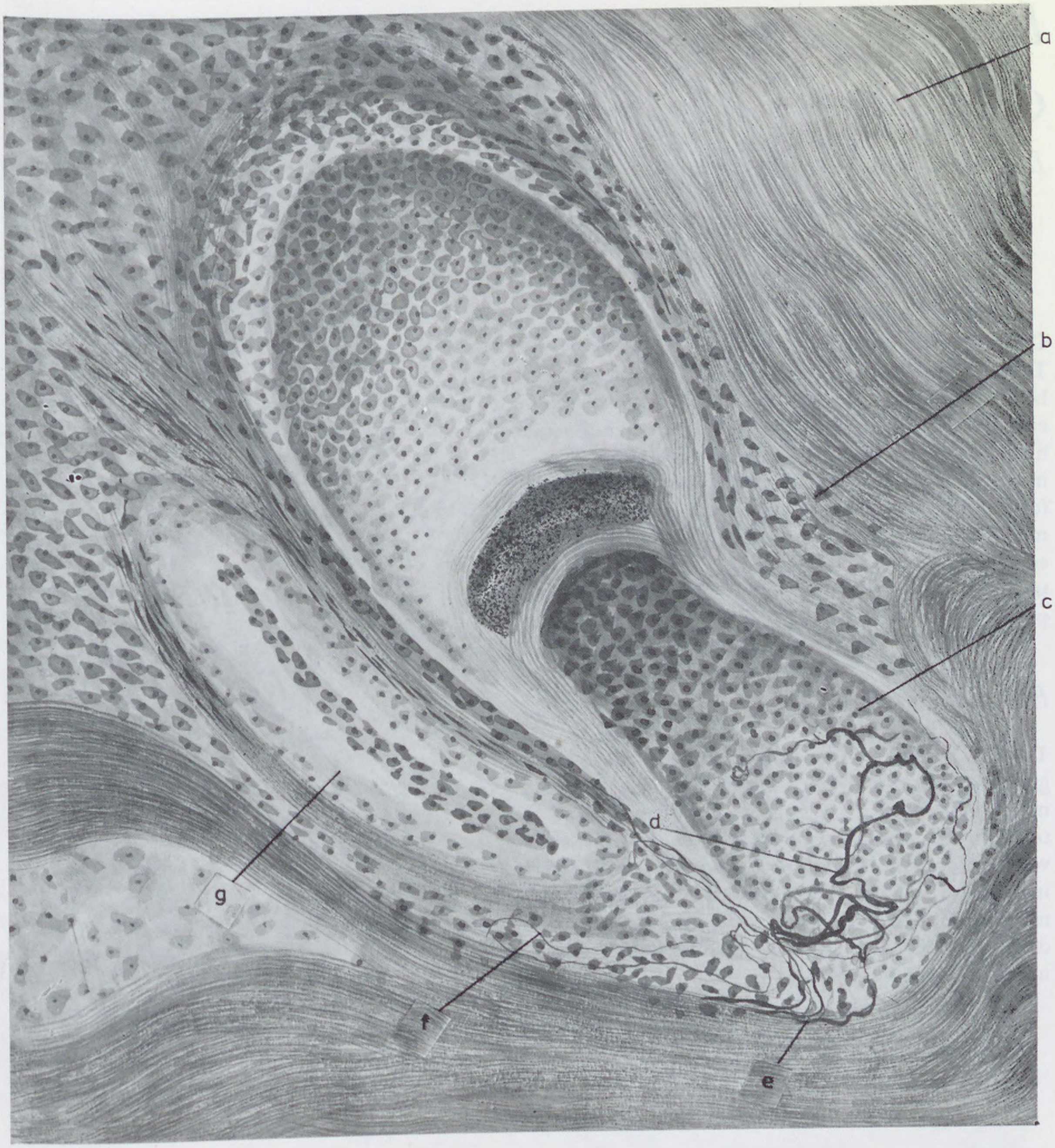
a
b
c
d
g
f
e

Plate 27

Greylag *(Anser anser)* cere

Bielschowsky–Ábrahám silver impregnation

On the left the epidermis (a) of the cere is shown. The stratum germinativum is much thicker in the beak than in other skin surfaces covered with feathers. The corium is composed of connective tissue fibres (b). Nerve fibres of various diameter (c) form nerve plexuses. Fine vertically running nerve fibres (d) leave the nerve plexus (e) and enter the epidermis. Two Grandry's corpuscles (g) surrounded by connective tissue capsules can be seen. Bean-shaped tactile cells (f) are to be found within each corpuscle.

Ethology and coenology

The greylag likes large, abandoned waters overgrown by sedge and bulrush as well as free waters mainly in the neighbourhood of meadows and cultivated land. A migratory bird, it builds a loosely woven nest from leaves and stems of sedge usually in reeds or willows. The greylag prefers vegetable material like the tip of grass blades, trefoil, dandelion, cabbage leaves, peas and lentils, picked up while standing or walking.

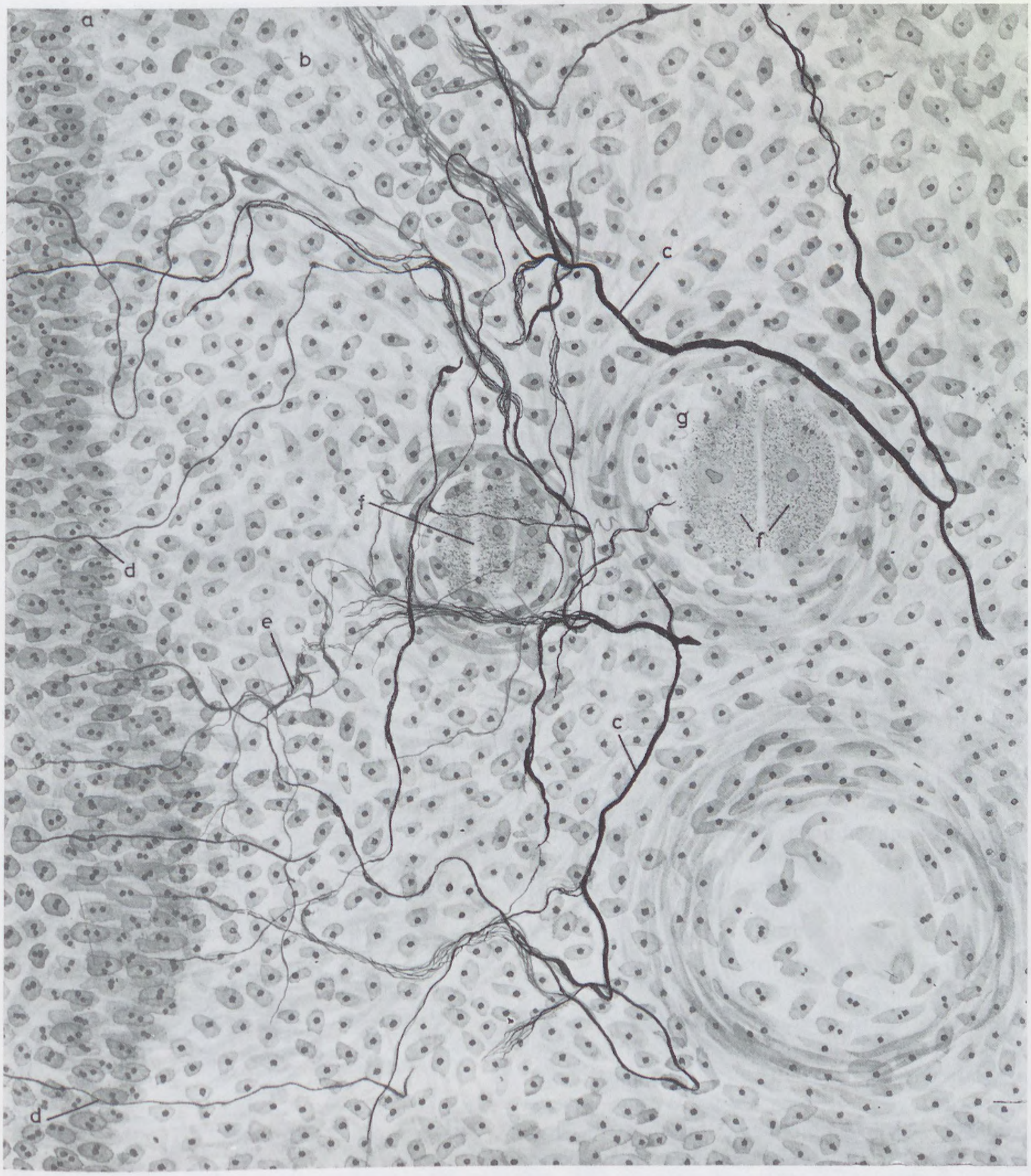
a
b
c
g
f
f
d
e
c
d

Plate 28

Mallard *(Anas platyrhyncha)* cere

Bielschowsky–Ábrahám silver impregnation

On the left: epidermis (a) (stratified flattened epithelium) consisting of stratum cylindricum and stratum granulosum. On the right: collagenous fibres and many connective tissue cells. The nuclei of the connective tissue cells (b) are lined up occasionally. Grandry's corpuscles (c) consisting of two tactile cells are characteristic components of the corium.

The long, bean-shaped cells join each other with their concave surfaces. The terminal portion of a nerve fibre enters the corpuscle and ends in a disk-like thickening between the two cells. Grandry's corpuscles are generally considered to be tactile organs. Occasionally only one tactile cell, surrounded by connective tissue capsule, can be seen. Not infrequently, however, three or four tactile cells may occur in one corpuscle (above), called "multiple Grandry's corpuscles". The tactile cells (d) have prominent nuclei (e) and nucleoli (f). Thick nerve fibres (g) approach Grandry's corpuscles which form loosely structured plexus.

Ethology and coenology

A migratory bird, the mallard is extremely ravenous; it eats the leaf-tips, buds, shoots and seeds of the various Gramineae and uliginous plants; it also likes corn and tuberous fruits. Worms, insects, molluscs, fish and amphibians belong to its non-vegetarian food. Mallards build nests in dry places among bushes or undergrowth but live also in nests vacated by predatory birds and crows. Its simple hollow nest is built of stem and leaves of plants and is lined with fluff.

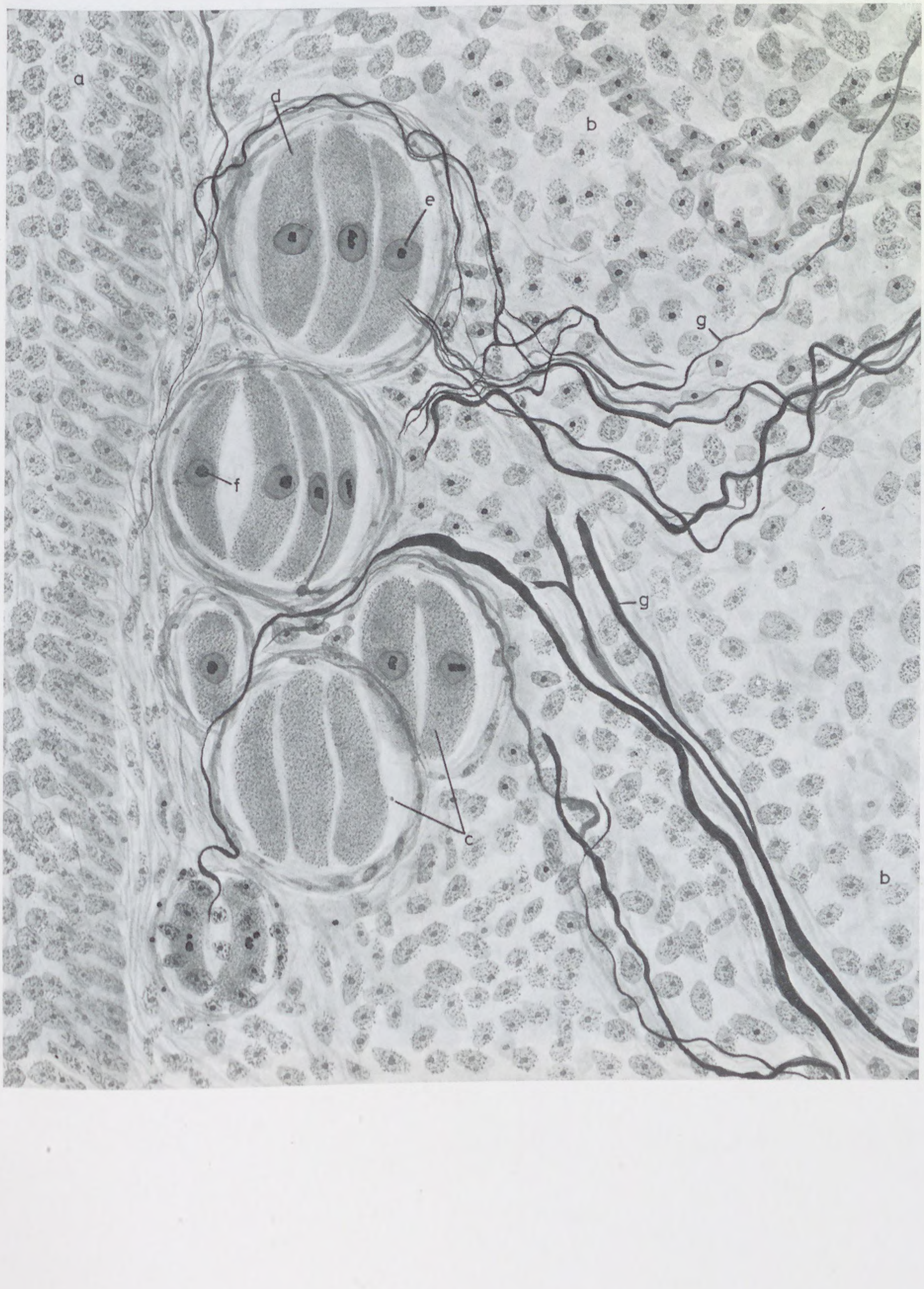
a
d
b
e
g
f
g
c
b

Plate 29

Mallard *(Anas platyrhyncha)* cere

Bielschowsky–Ábrahám silver impregnation

Grandry's corpuscles and Herbst's corpuscles often occur jointly in the cere of aquatic birds. On the left epidermis (a), while on the right the corium with nuclei of various connective tissue cells (b) and thick connective tissue fibres can be seen. Note two Herbst's corpuscles (c) (top left) situated close to each other. In both corpuscles, tactile cells (f) and a concentric lamellar system can easily be distinguished. Connective tissue capsules surround the corpuscles. A third Herbst's corpuscle is visible at the bottom of the picture. The tactile cells (f), the lamellar system and the connective tissue capsule are well discernible. Nine structurally different Grandry's corpuscles (d) are scattered in the left part of the picture; some of them are fragmentary due to the tangentional sectioning. In complete Grandry's corpuscles tactile cells (g) and nerve fibres (e) are clearly visible.

General neurohistology

The large number of receptors found in birds is surprising, especially since these do not occur in reptiles even in a primitive form. The function of Grandry's and Herbst's corpuscles is still unclear. It can be assumed that the completely different structure of the two corpuscles reflects their diverse functional differences, probably related to aquatic life.


a
c
f
b
c
g
e
e
b
g
d
f
c

Plate 30

Mallard *(Anas platyrhyncha)* cere

Bielschowsky–Ábrahám silver impregnation
Coloured photomicrographs

1. The epidermis can be seen at the bottom. Cross-sections of three Grandry's corpuscles appear in the adjacent connective tissue; two of them are complete while only a small part of the third one can be seen (upper right corner). The capsules of the Grandry's corpuscles consist of connective tissue cells and fibres. The capsule is well visible around the largest corpuscle in the centre. This central Grandry's corpuscle is composed of three tactile cells, thus it is a corpuscle innervated by two nerve fibres. The other two corpuscles contain only two tactile cells with a single nerve fibre. The large round nuclei and dark nucleoli of the tactile cells can be clearly seen.

2. Note dark annular bodies in the connective tissue, corresponding to the cross-sections of Grandry's corpuscles.

3. In the upper left corner of the picture the epidermis is shown while the rest is occupied by the corium. In the lower left part nerve trunks containing numerous nerve fibres can be seen. Nerve fascicles and nerve fibres originating from the nerve trunks run to Grandry's corpuscles situated near the epidermis.

1

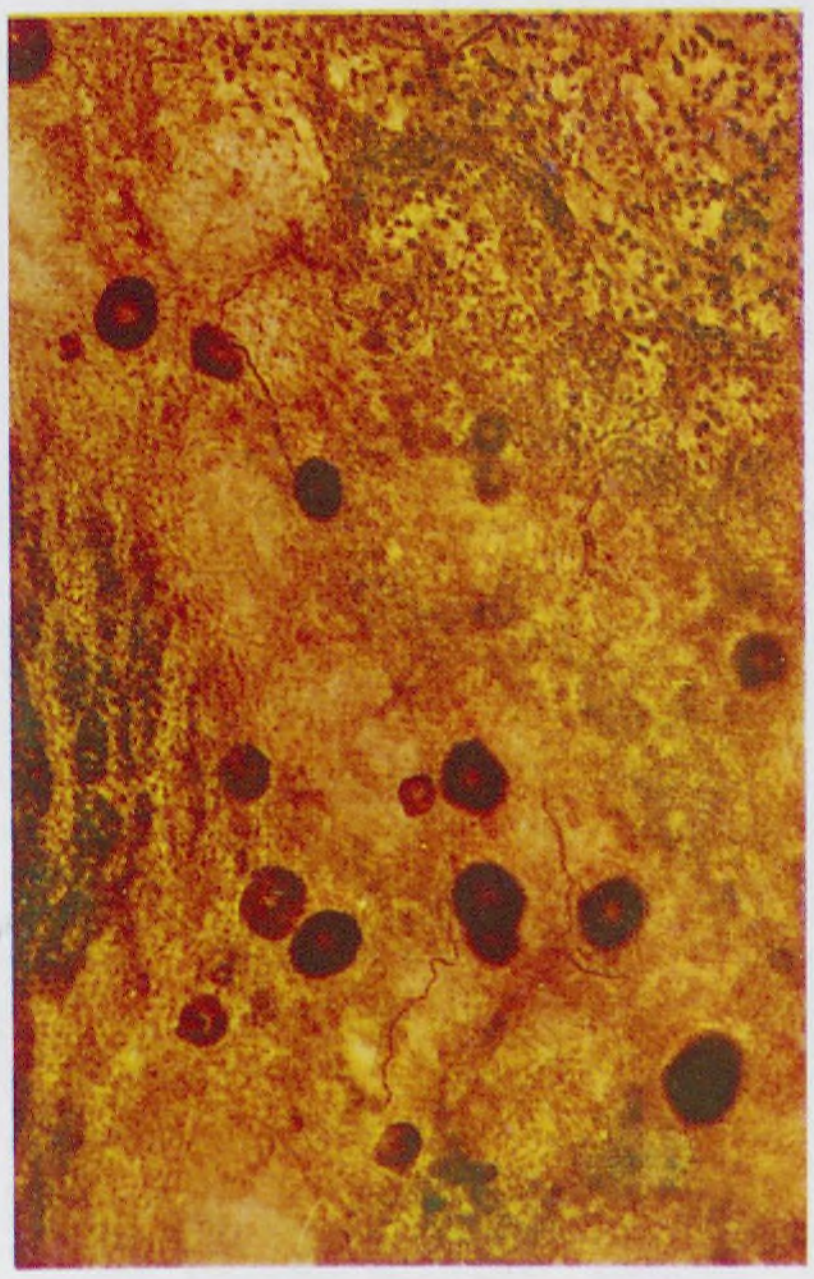

2

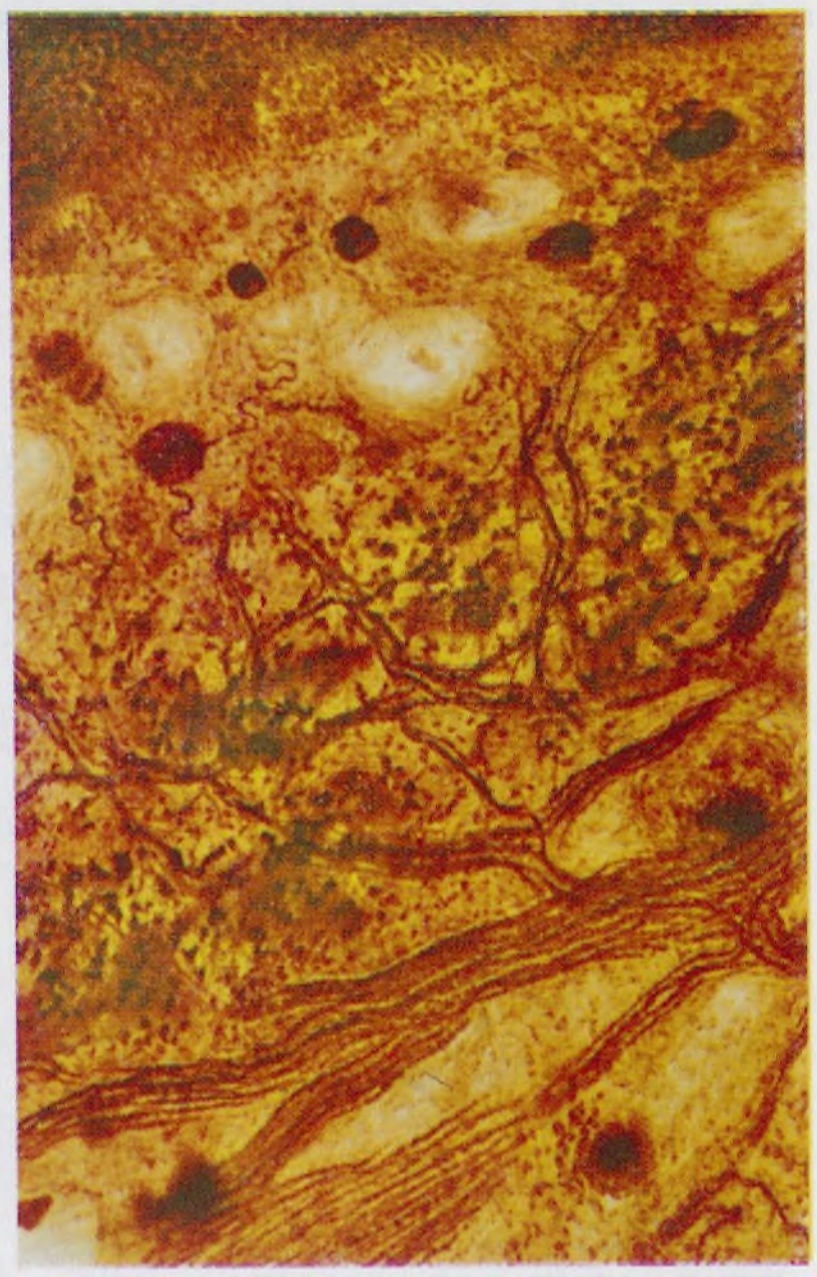

3

Plate 31

Ultrastructure of the bicellular form of Grandry's corpuscle

The round tactile cells in the cere of the duck are in close connection with the collagenous fibres of the capsule. In the cytoplasm of the sensory cells (Tc) numerous cristate mitochondria (M) and a well-developed Golgi apparatus (G) can be seen. The cisterns of the endoplasmic reticulum (Er) are short and narrow, equipped with ribosomes (R). The cytoplasm is packed with dense core vesicles (Vd) arranged in groups or in lines. The wavy nerve fibre (A) passes between the two sensory cells. Ap – axoplasm, Al – axolemma, Cm – cytolemma of the tactile cells. It is remarkable that in the axoplasm of the afferent nerve fibres the mitochondria are arranged linearly forming a chain. Spherical vesicles (V) appear usually close to the axolemma. The axon is thickened and divides into two branches (Rf). At the site of branching ovoid vesicles (Vo) are visible. The terminal portion of the axon is loaded with clear vesicles (Vc) but no mitochondria are to be seen.

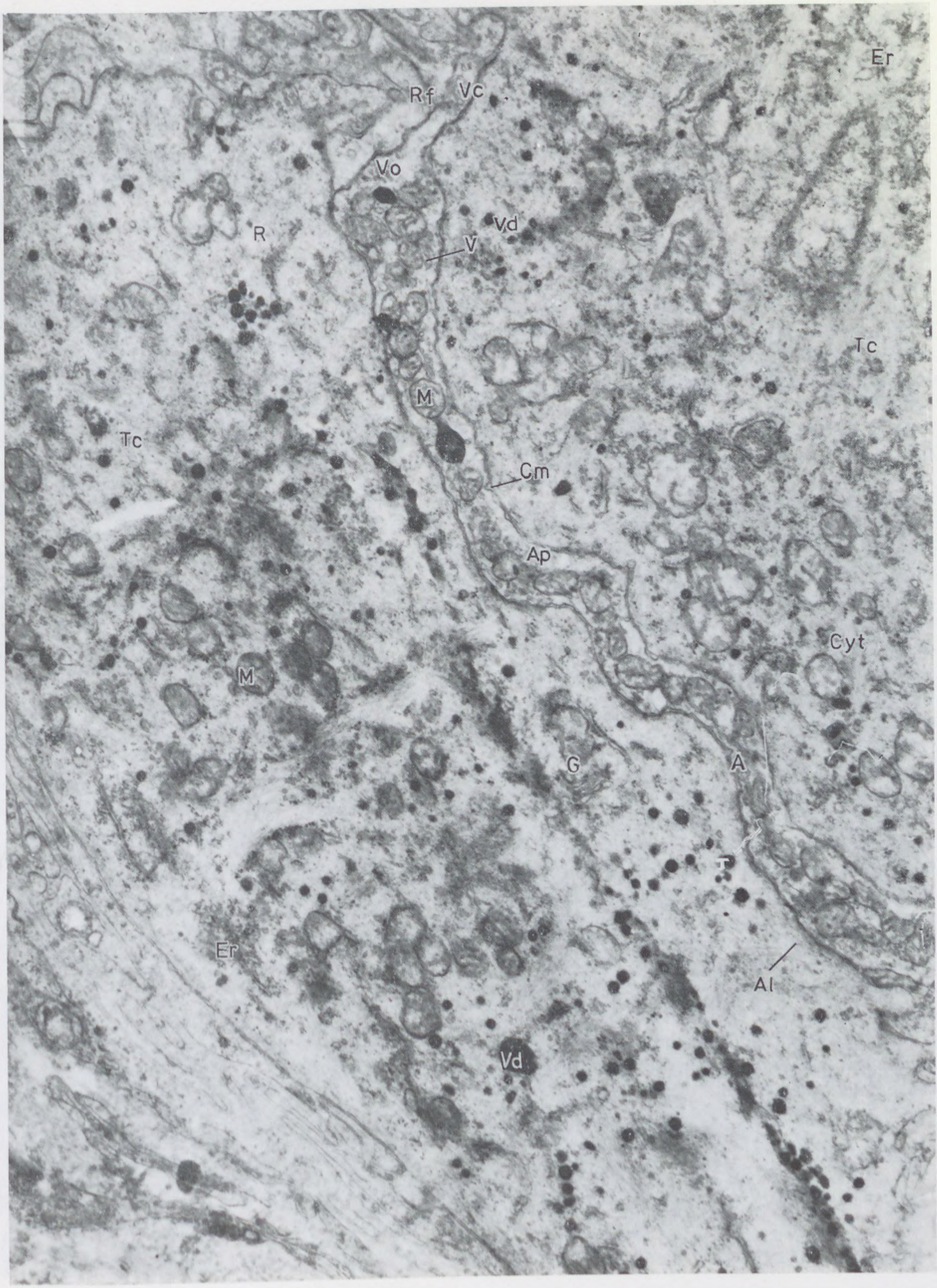
Er
Rf
Vc
Vo
Vd
R
V
Tc
M
Tc
Cm
Ap
M
Cyt
G
A
Er
Al
Vd

Plate 32

Ultrastructure of the unicellular form of Grandry's corpuscle

In the cere of the duck the majority of Grandry's corpuscles belong to the bicellular form; corpuscles consisting of three cells are less common; those of four and five cells are even more scarce and the unicellular form is a rarity. The unicellular form consists of a single tactile cell, an axon and a tactile disk. Cell membrane (Cm) of the tactile cell surrounds the cytoplasm in which mitochondria (M) are present in large numbers, but also the cisterns of the endoplasmic reticulum (Er) together with ribosomes (R) and dense core vesicles (Vd) can often be found. Thread-like fascicles (Sp) are characteristic of the tactile cells in unicellular Grandry's corpuscles. The axon (A) joining the large tactile disk (Nt) is similar to that of the bicellular form shown in Plate 31. There is a wide space (S) between the axolemma (Al) and the cytolemma (Cm). The axoplasm (Ap) is densely packed with mitochondria (M). Clear vesicles (Vc) are subjacent to the axolemma. Mitochondria are long and uniform in structure. In the rounded end of the tactile disk a membrane-limited elliptical body (Eb) filled with vesicles can be seen. The connection between the tactile disk and the tactile cell is a parallel contact. Presynaptic and postsynaptic membrane thickenings (Sy) are only seen on the margin of the disk. A capsule (Ca) consisting of variously thickened connective tissue fibres (Co) covers the axolemma of the disk. Satellite cells (Sa) with large nuclei (N) are also found in the capsule. Chromatin substance (Chr) appears in irregular nodular form both under the nuclear membrane and in the centre of the nucleus of the satellite cells.

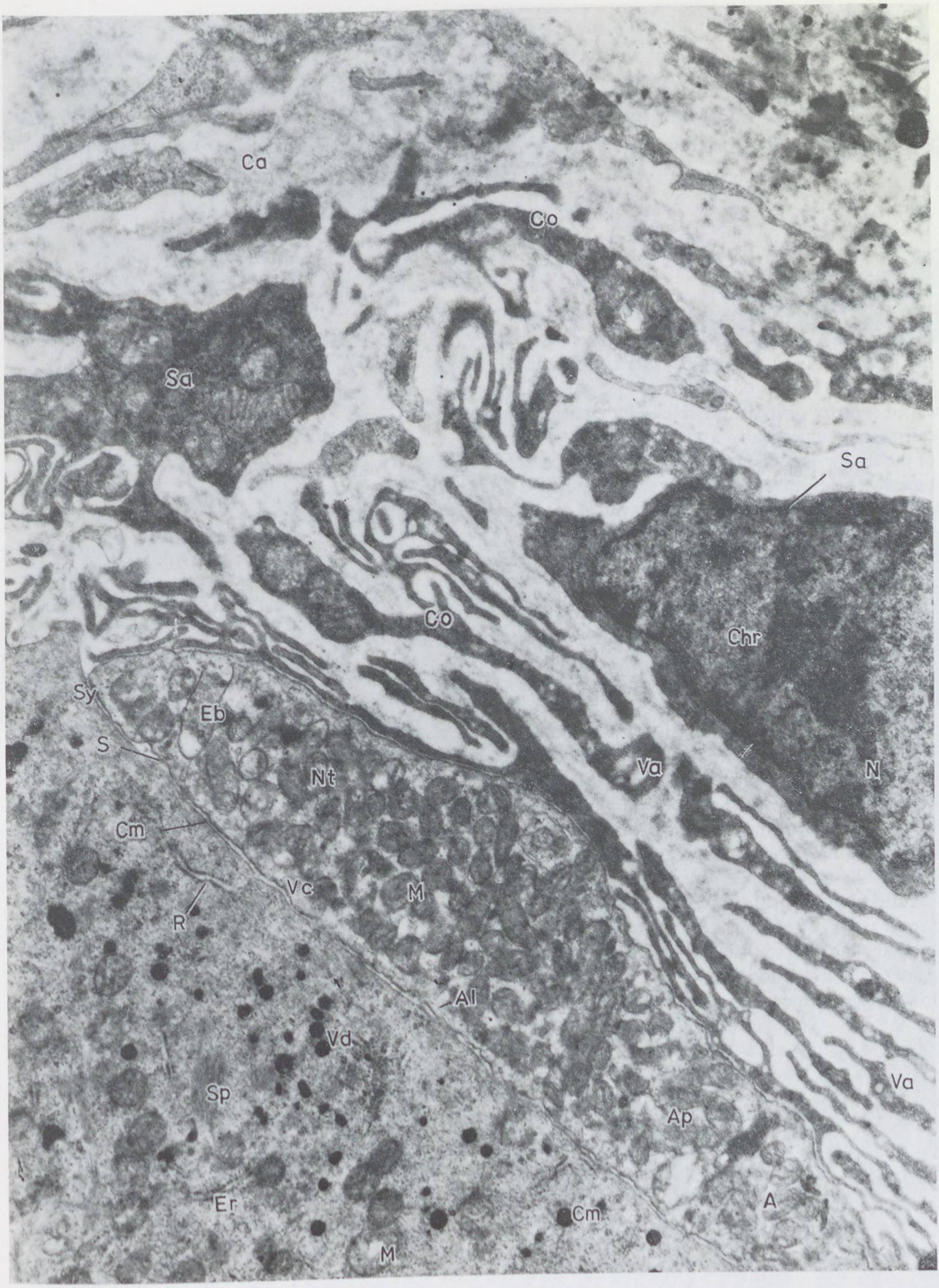
Ca
Co
Sa
Sa
Chr
Co
Sy
Eb
S
Nt
Va
N
Cm
Vc
M
R
Al
Vd
Va
Sp
Ap
Er
A
Cm
M

Plate 33

Ultrastructure of the inner bulb of Herbst's corpuscle

Three characteristic ultrastructural elements can be distinguished in Herbst's corpuscle: the inner bulb, the internal cavity and the lamellated capsule.

The inner bulb is composed of two rows of cells called sensory or indicator cells. The nuclei of these cells are symmetrically arranged along both sides of the sensory nerve ending. The cells are polygonal, tapering at both ends (cell processes – Tc). Their nuclei are surrounded by a thin layer of cytoplasm (Cy). The cisterns of the endoplasmic reticulum (Er) are wide. The inner side of the polygonal nuclei is segmented (N). The outer surface of the cells joins the internal cavity (Ic) from which they are separated from it only by a homogeneous basement membrane (Im). Several lamellar processes (Pr) originate from the internal surface of the membrane. Some of the processes have a narrow base and then expand, while others have wide bases and then rapidly become thin. The processes running to the nerve fibre have parallel courses (A). The lamellae of each cell interdigitate with those of other cells on both sides of the nerve fibre. In the cross-section of the corpuscle the lamellae show a concentric arrangement while in longitudinal sections they appear as a parallel system. In the lower left corner of the picture a cell (Tc) of the internal cavity can be seen; the lamellar process (Pr) originating from this cell passes around the inner bulb. The axon (A) is in the lower right corner.


Ic
Pr
Tc
Cy
Im
Er
N
Pr
Tc
L
L
Pr
A

Plate 34

Ultrastructure of the inner bulb of Herbst's corpuscle

Herbst's corpuscle is innervated by a single, wavy myelinated nerve fibre, which loses both myelin and Schwann's sheaths before approaching the inner bulb. The terminal portion of the nerve fibre is smooth. It becomes thicker towards its end, and terminates in a terminal disk (Nt). The nerve fibre and the terminal disk are surrounded by the axolemma (Al); the cytolemma (Cm) of the processes is also seen. The terminal disk contains a few mitochondria (M) with longitudinal cristae. Nerve fibre and terminal are packed with spherical vesicles; some of them are usual empty vesicles (Sv), but larger round vesicles (Ve) and dense core (Vd) vesicles, too, arranged in clusters, can be distinguished. The latter are very similar to neurosecretory granules. In addition, there are large round multivesicular bodies (Mb) loaded with vesicles of various size. Numerous neurotubuli (Tu) can be seen in the axoplasm, mostly in the vicinity of the terminal disk. The axolemma (Al) is separated from the cytolemma (Cm) of the processes by a cleft. The width of the cleft is uniform all along. The cleft between the membranes is empty. Fusion of the adjacent membranes or synaptical thickenings are absent. The nerve ending is a good example of how the afferent fibre is connected to the sensory cells. Considering that every sensory cell of the inner bulb possesses twenty or more processes, some of them branched, and that the lamellar system of every cell is associated with those of other cells, each sensory cell of the corpuscle represents a highly sophisticated and complex system.

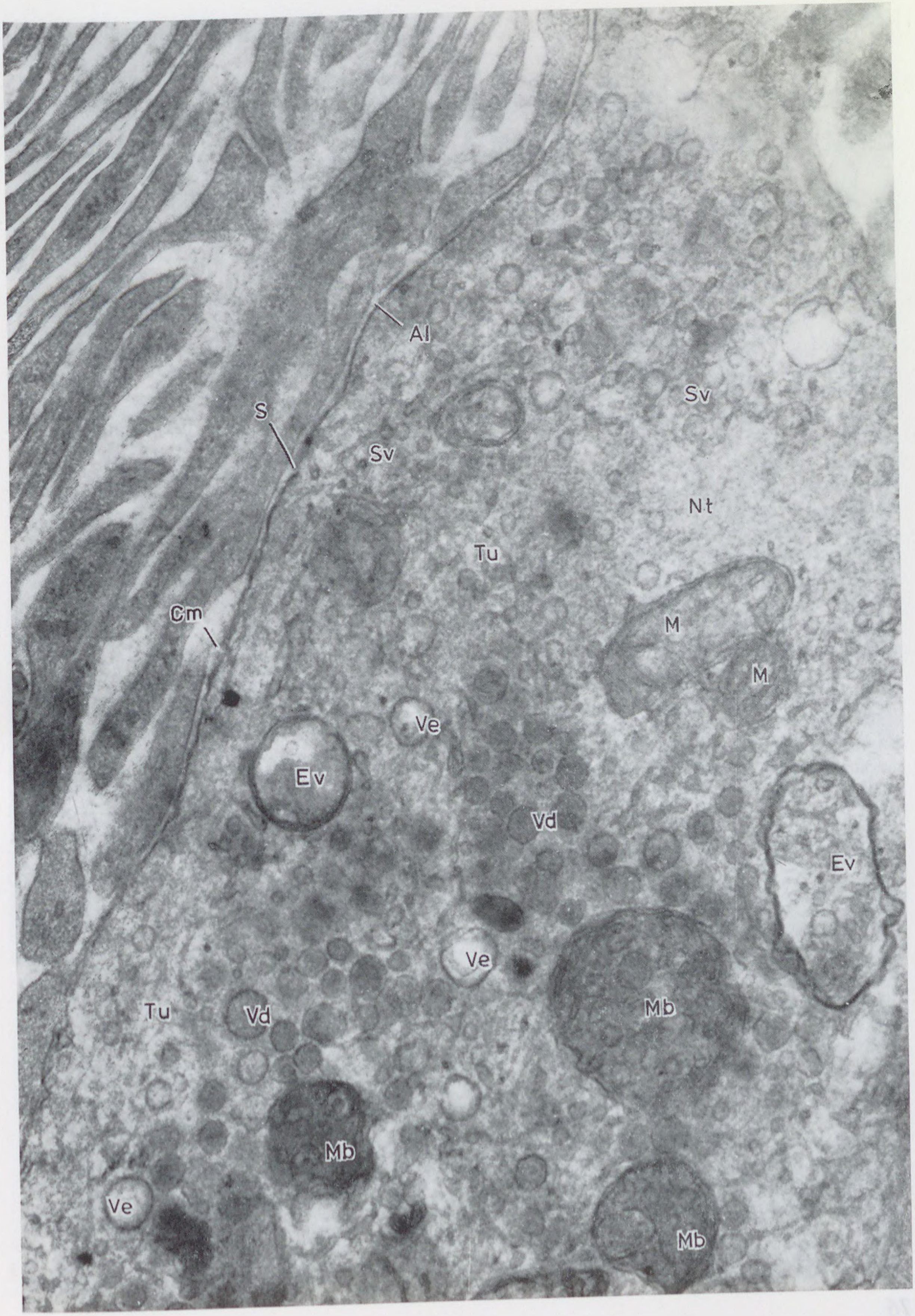
Al
S
Sv
Sv
Nt
Tu
Cm
M
M
Ve
Ev
Vd
Ev
Ve
Mb
Tu
Vd
Mb
Ve
Mb

Plate 35

Ultrastructure of the internal cavity of Herbst's corpuscle

The internal cavity (Ic) is composed of several lamellae of varying thickness which are separated by fluid-filled spaces. The lamellae belong to the cells of the internal cavity. These fibroblast-like cells (Lc) are connected to one another by their processes. Passing around the inner bulb, these processes enter the internal cavity. Extensive endoplasmic reticulum (Er), surrounded partly or entirely by ribosomes (R), mitochondria (M), Golgi apparatus (G) and, occasionally, vesicles (Ve) can be seen in the lamellar processes. Frequently the processes send off lateral branches (Pr). The elongated nuclei of the cells (N) are poor in chromatin (Chr). The cytoplasm is scanty, containing rows of free ribosomes (R) not attached to the cisternal systems. Numerous myelinated nerve fibres can be found in the internal cavity which are probably collaterals of the nerve fibre innervating the corpuscle. It is even more likely that independent myelinated nerve fibres proceed into the internal cavity. Among the lamellae multivesicular bodies (Mb) are often found.

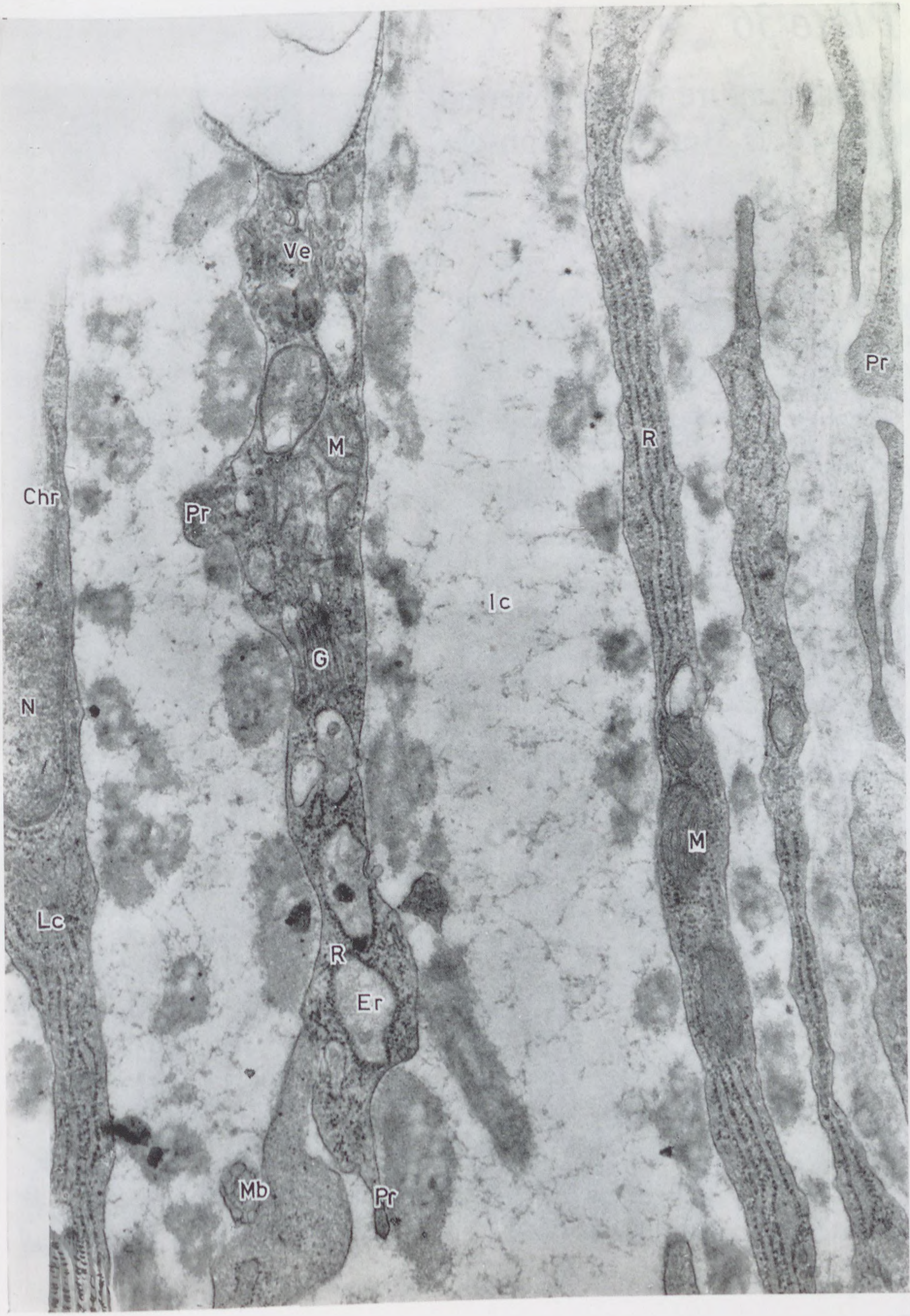
Ve
Pr
M
R
Chr
Pr
Ic
G
N
M
Lc
R
Er
Mb
Pr

Plate 36

Ultrastructure of the external capsule of Herbst's corpuscle

In the duck the external capsule is composed of 10 to 13 concentric lamellae (L) which are separated by bundles of collagenous fibres (Co) also running concentrically. The collagenous fibres vary in thickness depending on the width of the spaces between the lamellae. Their number increases towards the stratum laxum corii. The lamellae are relatively narrow but they become wider towards the internal cavity. The cytoplasm of the cells of the lamellae shows a spongoid structure and contains many vesicles (Ve) varying in size and form. Nuclei (N) are elongated; part of the chromatin is attached to the nuclear membrane while the majority is distributed in spots in the nuclear substance. The lamellar system, located in the stratum compactum, is surrounded by the loose fibrillar system and fibroblasts (Fb) of the stratum laxum corii (Sl). The rounded or occasionally ovoid mitochondria (M) with their irregularly arranged cristae and the vesicular cisterns of the endoplasmic reticulum (Er) are characteristic features of these fibroblasts.

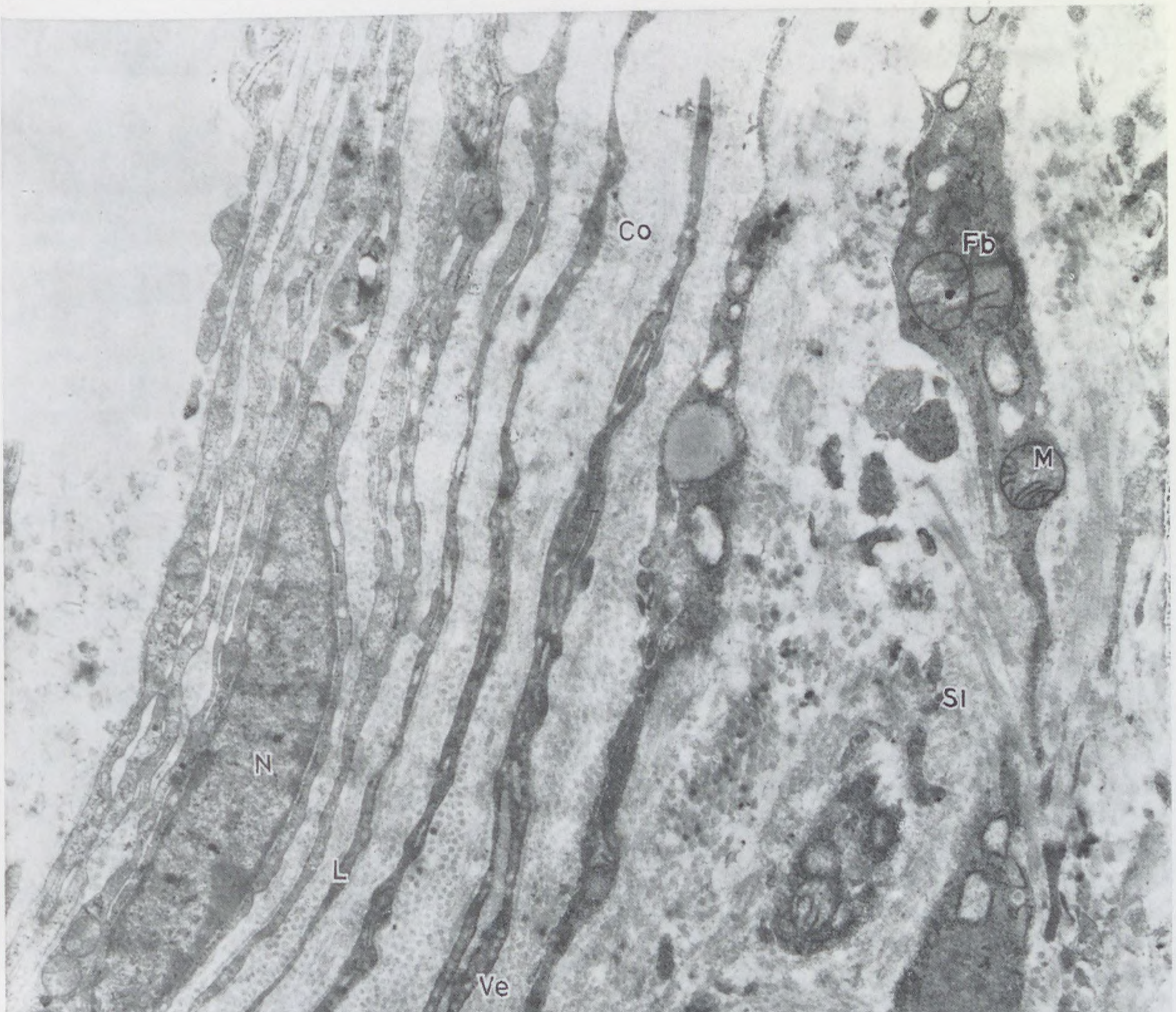
Co
Fb
M
N
L
Sl
Ve
N
Fb
Er
Co
M

Plate 37

Human upper lip

Bielschowsky–Gros silver impregnation

The corium (a) contains variously directed connective tissue fascicles (b), nerve fibres of various sizes (d) forming fascicles, and a nerve fascicle (e) running to the end-coil (f). The latter is enclosed by a capsule composed of connective tissue elements (c).

Functional neurohistological comments

The presence of numerous receptors varying both in form and localization in the upper and lower lips of humans are in line with the specific and complex sensory function of the lips. The upper lip is even richer in receptors than the lower one, due to the special terminal coils located at the base of the hairs. The peripheral ramification of these nerve coils comes close to the epithelium, occasionally even entering the basal layers of the epithelium. The receptors of the upper and lower lips of numerous higher mammalian species are less developed than those of the human lips. Maybe the abundant sensory innervation of the lips is related with speech, since the lips play an important role in the production of speech sounds. Sensory end-organs vaguely resembling the receptor apparatus of the human lips have only been found in the upper lip of horses in the subepithelial connective tissue and in the lower part of the connective tissue papillae.

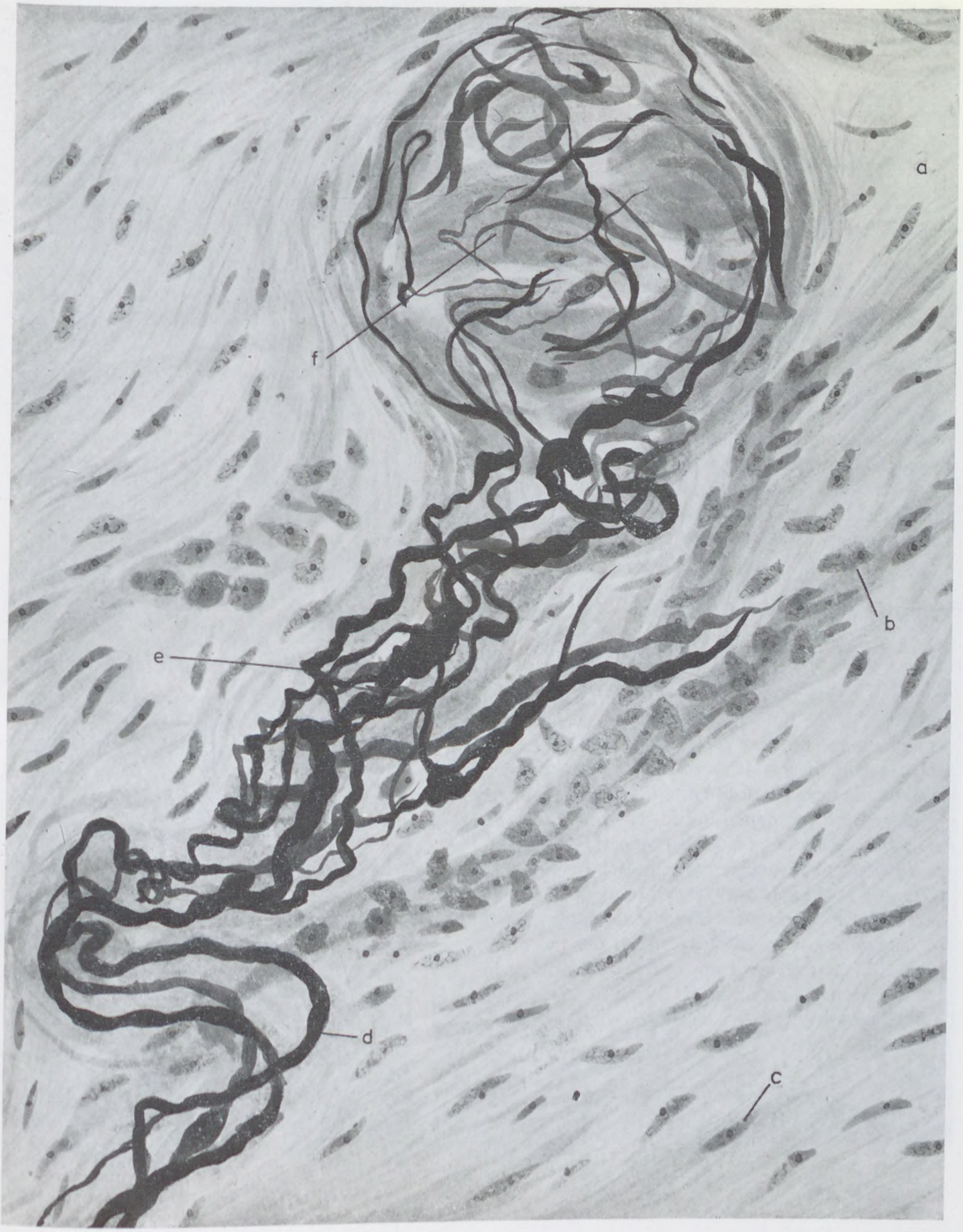
a
f
b
e
d
c

Plate 38

Human lower lip

Bielschowsky–Gros silver impregnation

Stratified epithelium of the mucous membrane (a). On the right the lamina propria (b) can be found with the connective tissue fibres and the nuclei of connective tissue cells (e). In the lower right corner lamellated nerve endings (j) and the elongated cells of the stratum germinativum (c) are arranged side by side. The nerve fibre (g) which branches off the nerve fascicle (f) running beneath or partly within the epithelium has characteristic varicosities (h) and nerve endings (i) (c–epithelial cell nuclei).

Comparative and functional neurohistological comments

It has to be mentioned that no forerunners of the receptors in the human upper lip can be found in other vertebrates. Not even the mammals possess any nerve endings which could be compared either in structure or in localization to the receptors found in man. Both the upper and lower lips of humans are rich in receptors, especially the parts covered by mucous membrane. There are also intraepithelial receptors in the mucosa covered parts and in their vicinity, but their number does not reach that found in mammals with a sensitive snout. On the other hand, different receptor apparatuses are present in the connective tissue papillae, such as loose coils and expanded plexus-systems of varying density.

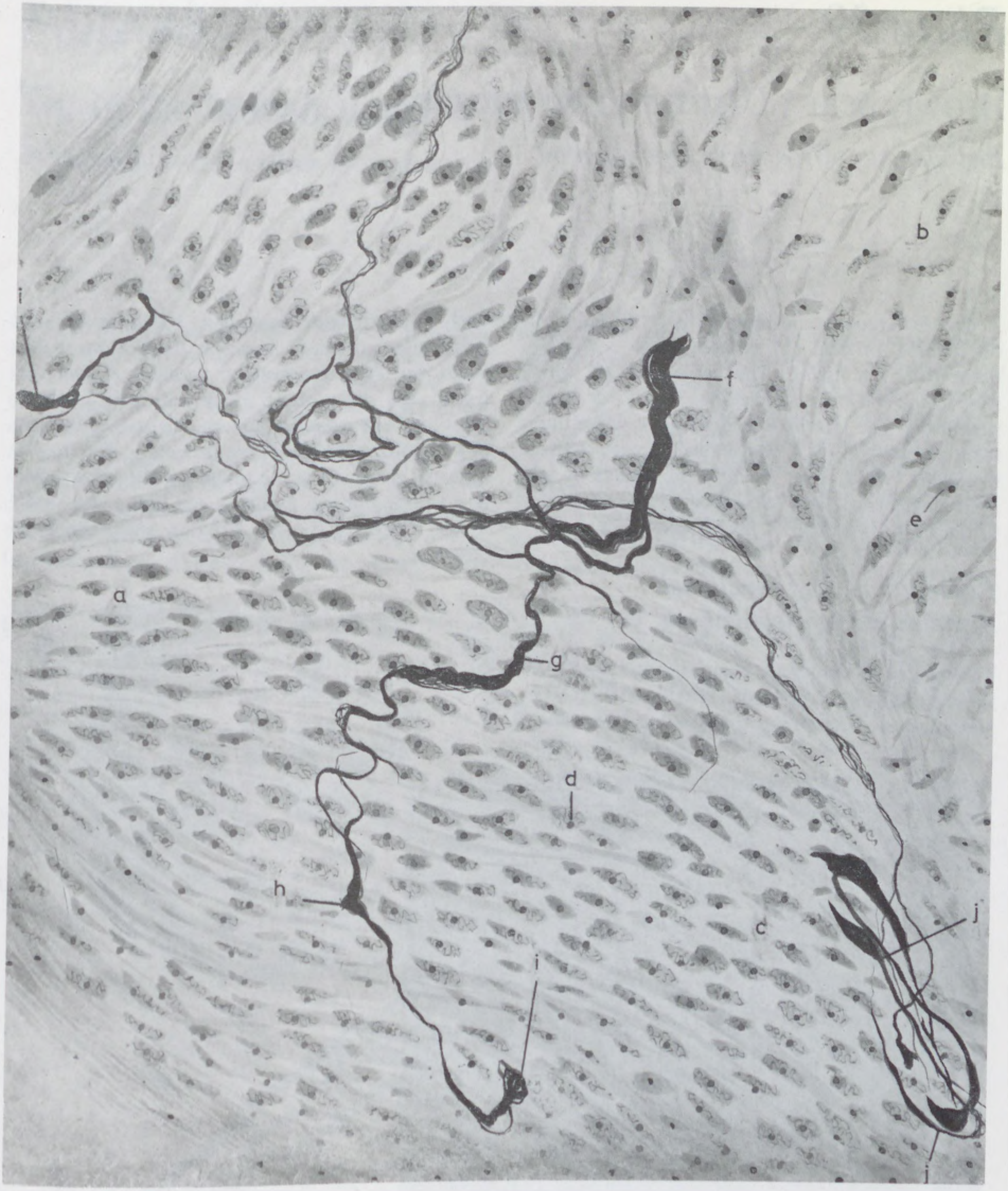
b
i
f
e
a
g
d
h
c
j
i
j

Plate 39

Brown bear *(Ursus arctos)* tongue

Bielschowsky–Gros silver impregnation

A double Krause's end-bulb (c) is separated from the lamina propria (a), composed of connective tissue (b), by a fissure. The nerve fibre (e) which runs to the end-bulb is enveloped by a thick myelin sheath (d). The terminal branchings of nerve fibres form an end-coil (f). Collagenous connective tissue fibres (g), which pass in different directions and form concentrical lamellae, are clearly demonstrated in the capsules of both Krause's end-bulbs.

Comparative and functional neurohistological comments

The tongue of mammals is more motile and more sensitive than that of birds. According to our investigations, special receptor structures occur only rarely in the mammalian tongue. Extensive coil-like formations have been found at the bottom of the fungiform and circumvallate papillae. A fine coil system, the structure of which indicated a special function, was revealed underneath the epithelium of a fungiform papilla of the hedgehog. The double Krause's end-bulb in the tongue of the brown bear is a unique finding. Krause's end-bulbs also occur in the tongue of the cat, but they show the usual structure.

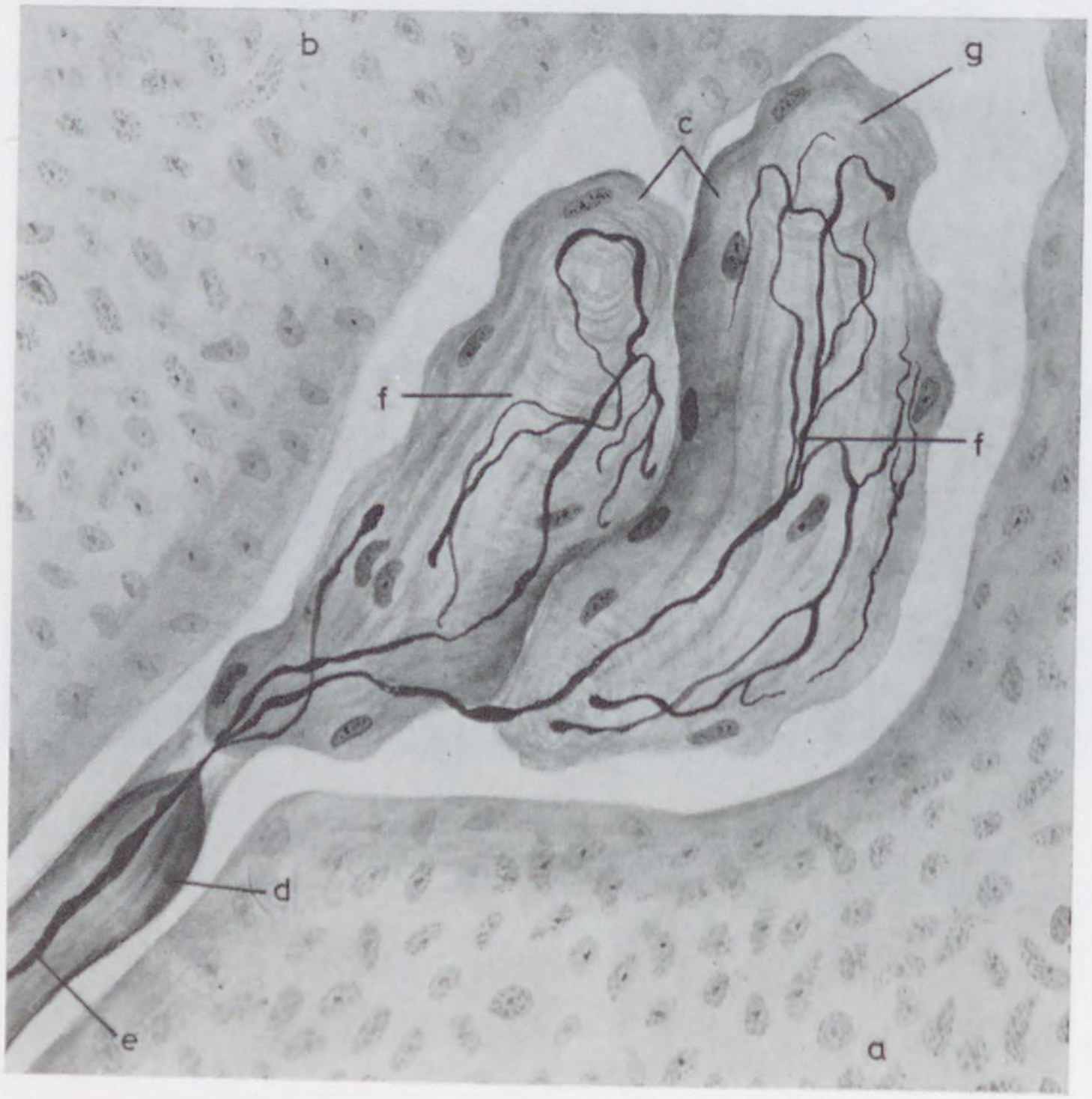

Plate 40

Tip of the human tongue

Bielschowsky–Gros silver impregnation

Bundles of collagenous fibres (d) and elongated nuclei of connective tissue cells (e) can be seen in the connective tissue papillae (b) protruding into the epithelium (a). The thick nerve fibres (f) terminate in three different end-coils (g). The first type of coil (g_1) (upper right corner) exhibits a loose structure. The terminal branches of the nerve fibre curve back, gradually taper off and disappear among the connective tissue fibres. The second type of coil (g_2) has a dense structure. Here, the terminal portions of the nerve fibres are densely interwoven; they become thin towards their ends and disappear among the connective tissue. The third type of coil (g_3) is an elongated corpuscle consisting of a few nerve fibres. Containing several elongated tactile cells arranged side by side, it is surrounded by a capsule of connective tissue fibres. Presumably, the various nerve end-systems represent specialized sensory structures but they may also be different forms of the same type of receptor (E – epithelial nucleus).

Plate 41

Tip of the human tongue

Bielschowsky–Gros silver impregnation

Numerous parallel running thick nerve fibres (d) can be seen in the connective tissue papilla (a) composed of nuclei of connective tissue cells (b) and collagenous connective tissue fibres (c). Five end-coils (e) are arranged side by side at the end of the nerve fibres right on the epithelial border. The majority of the coils form closed systems but some of them send off ultraterminal fibres (f) running towards the free surface of the epithelium.

Functional neurohistological comments

The human tongue is rich in receptors, much richer than that of any other mammalian species. Abundant nerve fibre plexuses are present in the tongue especially in the dorsal region subjacent to the stratified epithelium. The epithelium seems to lack nerve fibres, the superficial layer of the stratified non-keratinizing epithelium is shed depending on the rate of cell division of the underlying layers. The filiform and fungiform papillae in the anterior part of the back of the tongue are abundant in receptors. A great variety of coil systems of different size can be found here. The number of receptors gradually decreases towards the root of the tongue. The tip of the human tongue is exceedingly rich in receptors and it is undoubtedly unique in this respect. The tall connective tissue papillae of this contain nerve coils and coil systems varying widely in form. These bouquet-like formations of the sensory system amaze the observer with their beauty and harmony.

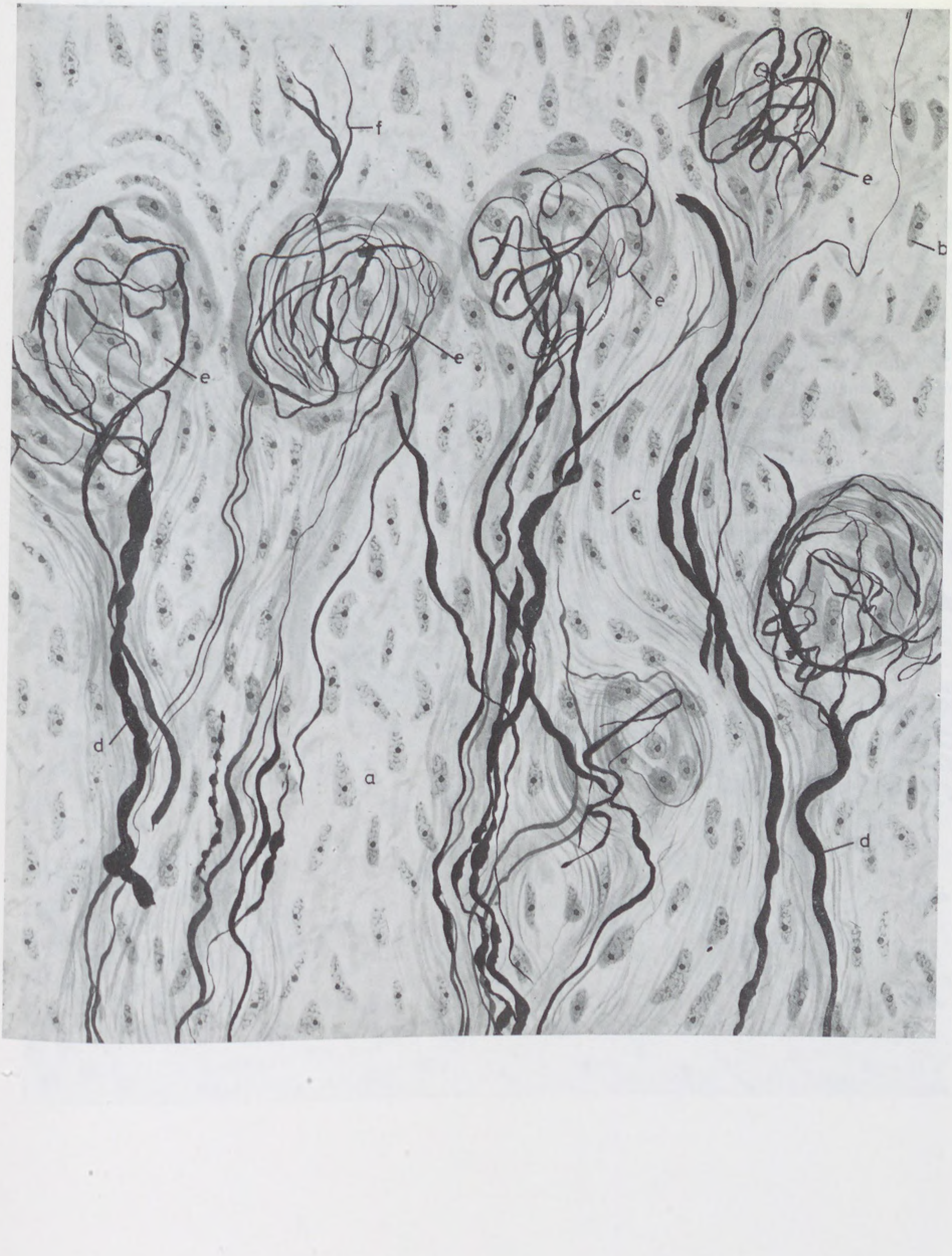
f
e
e
e
e
b
e
c
d
a
d

Plate 42

Tip of the human tongue

Bielschowsky–Gros silver impregnation

An elaborate terminal nerve fibre coil system (h) can be seen in the connective tissue papilla (b) located below the epithelium (a). The receptor comprises several smaller individual terminal systems. Variously structured nuclei of connective tissue cells (d), connective tissue fascicles (e) composed of fine fibres and a capillary (f) are also found in the papilla. The papillae of the human tongue contain large, elongated end-systems of terminal nerve fibres. They resemble encapsulated terminal glomeruli.

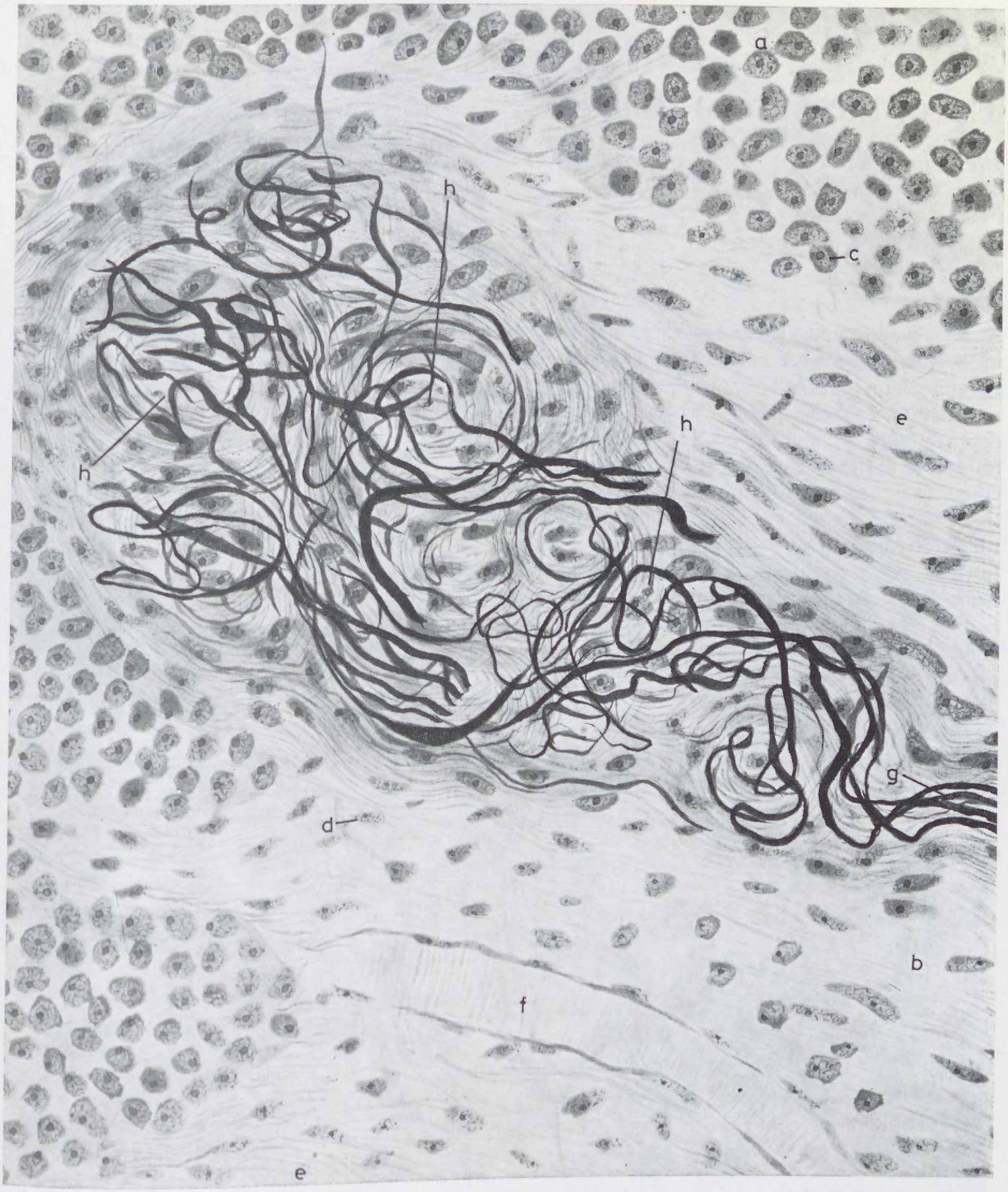
a
h
c
h
h
e
g
d
b
f
e

Plate 43

Tip of the human tongue

Bielschowsky–Gros silver impregnation

A special and complicated receptor system is located in the connective tissue papilla (b) protruding into the epithelium (a). The layers of the stratum germinativum (c), epithelial lamellar systems undergoing desquamation (d), and the nuclei of epithelial cells (e) can be distinguished in the epithelium. In the connective tissue papilla the nuclei of connective tissue cells (f) can be seen. The lower part of the picture shows strongly varicose, branching nerve fibres (g) from which variously localized and structured nerve fibre coils (h) arise in the upper region of the papilla. The different fibre coils form a chain. These complex nerve endings obviously serve for perception of specific sensory modalities.


d
a
h
h
e
f
b
a
h
h
h
c
g
f

Plate 44

Cattle *(Bos taurus)* dental pulp

Bielschowsky–Ábrahám silver impregnation

The pulp (a) is made up of loose connective tissue. Nuclei of connective tissue cells (b) are found among the parallel running connective tissue fascicles. Nerve fascicles (c) composed of both thick (d) and thin (e) smooth-edged fibres may be distinguished, but varicose fibres (f) also appear. The two types of fibres form loosely structured coil systems (g) from which further fibres emerge which run longitudinally or transversely in the pulp. Blood vessels (h) can often be found in the ground tissue. Special receptors cannot be discerned on the border of the pulp and dentin. A large number of fibres enter the dentin from the fine nerve end-coils located on the edge of the pulp and proceed in the dentinal canals over a considerable distance. These extremely fine fibres are varicose and terminate in end-knobs.

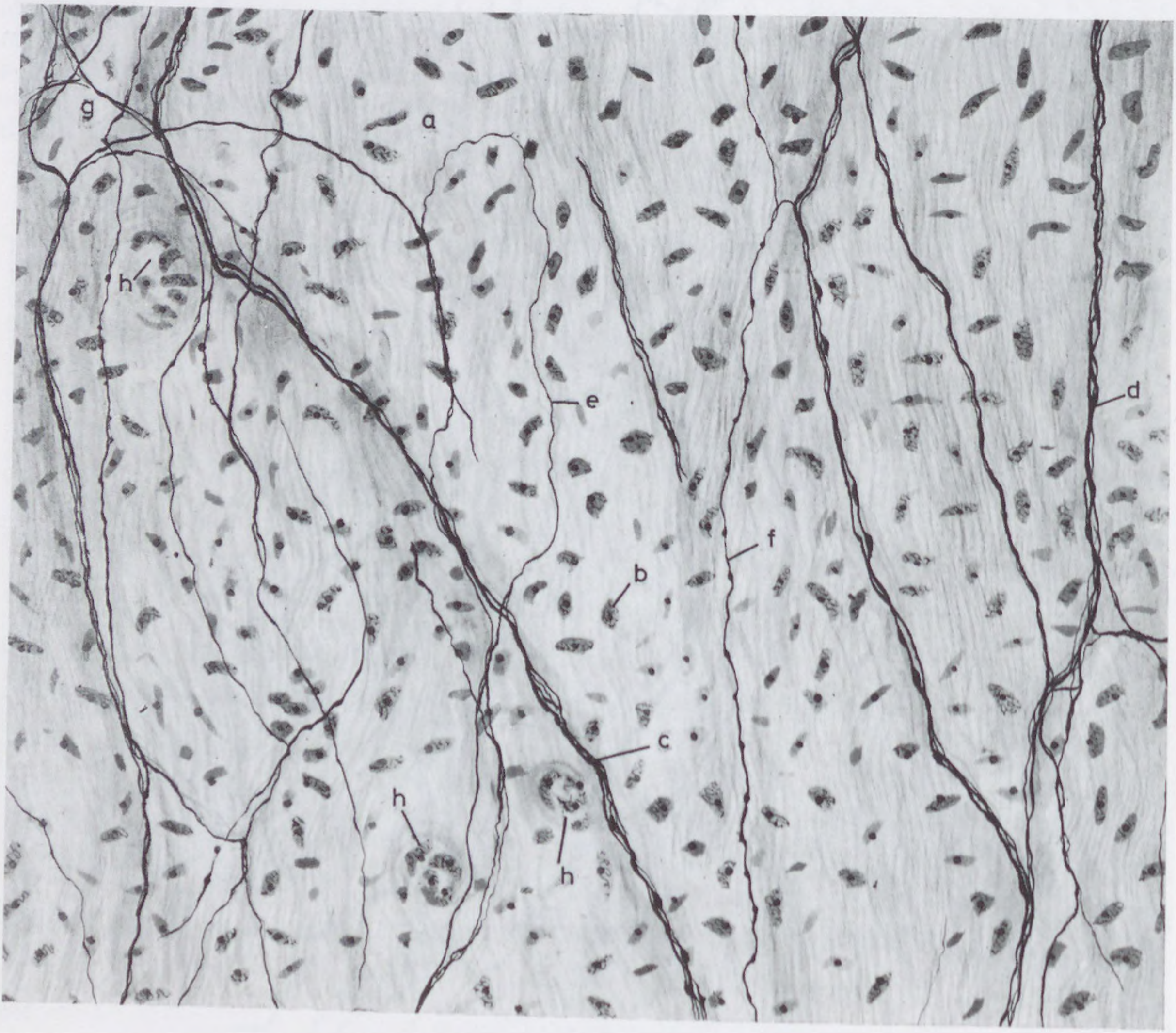

Plate 45

Cattle *(Bos taurus)* dental pulp

Bielschowsky–Ábrahám silver impregnation

Two capillaries filled with blood cells can be discerned in the longitudinally sectioned incisor pulp. On the side of these capillaries lightly stained collagenous fascicles and small nuclei of connective tissue cells are seen. On the right of the picture thick nerve trunks are apparent, some fibres of which leave the trunk to join another one. Loosely arranged nerve fibres can be seen on the extreme left. No special end-formations appear in the pulp.

Plate 46

Nerve fibres in the human dentin and predentin

Romanes–Hattyasy technique

(Dr. Hattyasy's preparation from the left lower lateral incisor of a twelve-year-old boy)

Globularly calcified dentin (D) and the layer of predentin (Pd) composed mainly of collagenous fibres. Both types of dentin are traversed by the dentinal canals (Dc) running from the bottom to the top of the picture at regular distances. Along the lower margin of the predentin the limiting membrane (ml), considered to be the product of the odontoblasts (Ob), can be seen. The latter are located in the lower part of the pictures. The Raschkowian nerve plexus, from which unmyelinated axons originate, lies under the odontoblast layer. (Bouin fixation; decalcination with sodium citrate. Frozen section; impregnation according to the Romanes–Hattyasy method).

1. In the predentin a fine nerve fibre (A) terminating in a larger varicosity (Vx) is visible. These varicosities are highly characteristic of the nerve fibres in the predentin. Their function and origin are still unknown. They had first been considered to be artefacts, then, synapses. In fact, the varicosities of the sensory nerve fibres contain many mitochondria. In the nerve fibres of the dentin the varicosities usually appear in the dentinal canals. Probably the axon gets into contact with the odontoblast processes running in the dentinal canal.

2. The nerve fibre which accompanies Thomes's fibre in the dentinal canal, travels from the odontoblast layer towards the calcified dentin. It emits a fine fibre (extreme left) with varicosities at some of the dentinal canals. Two nerve fibres emerge from one of the varicosities and continue their course in the dentinal canal.

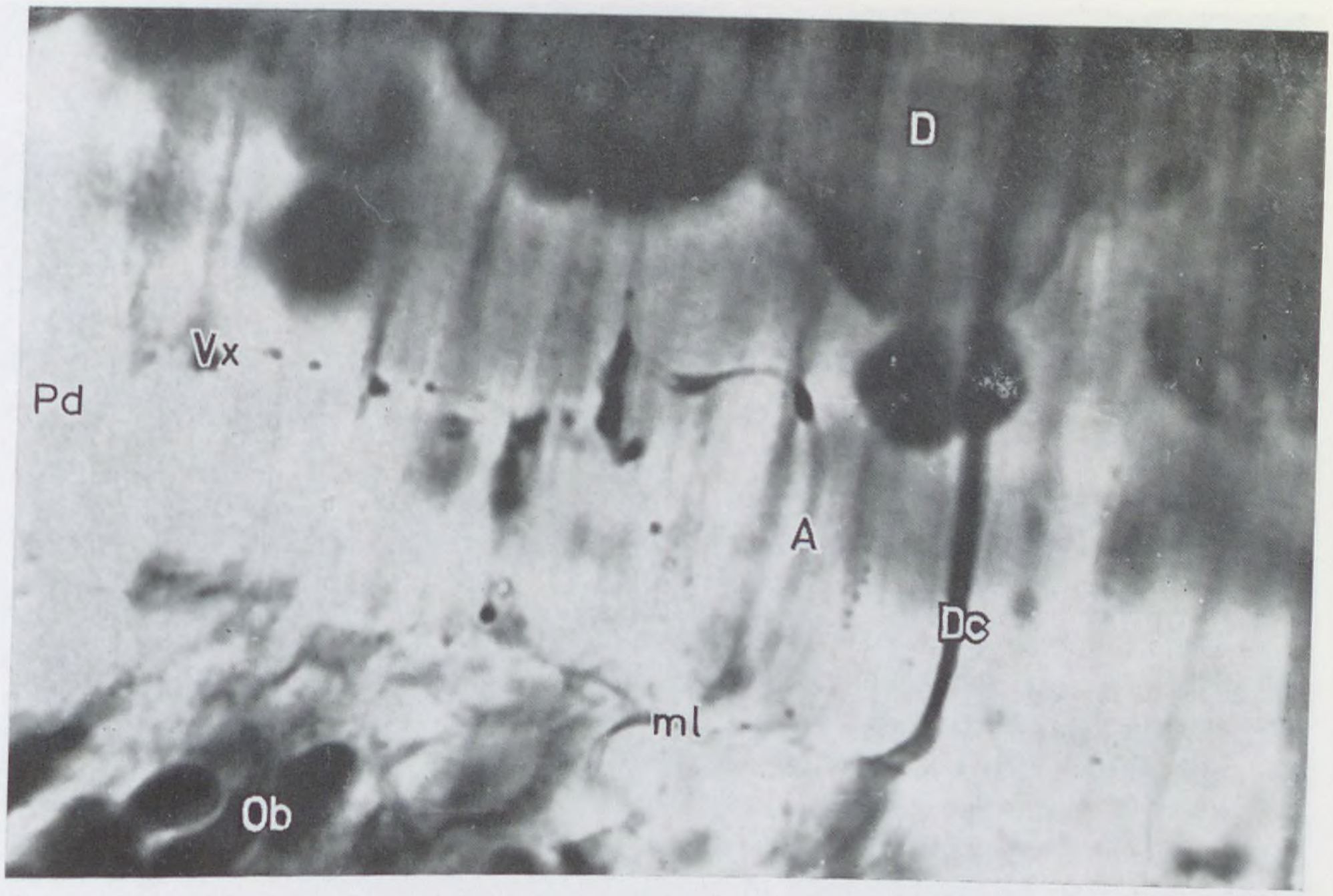

1

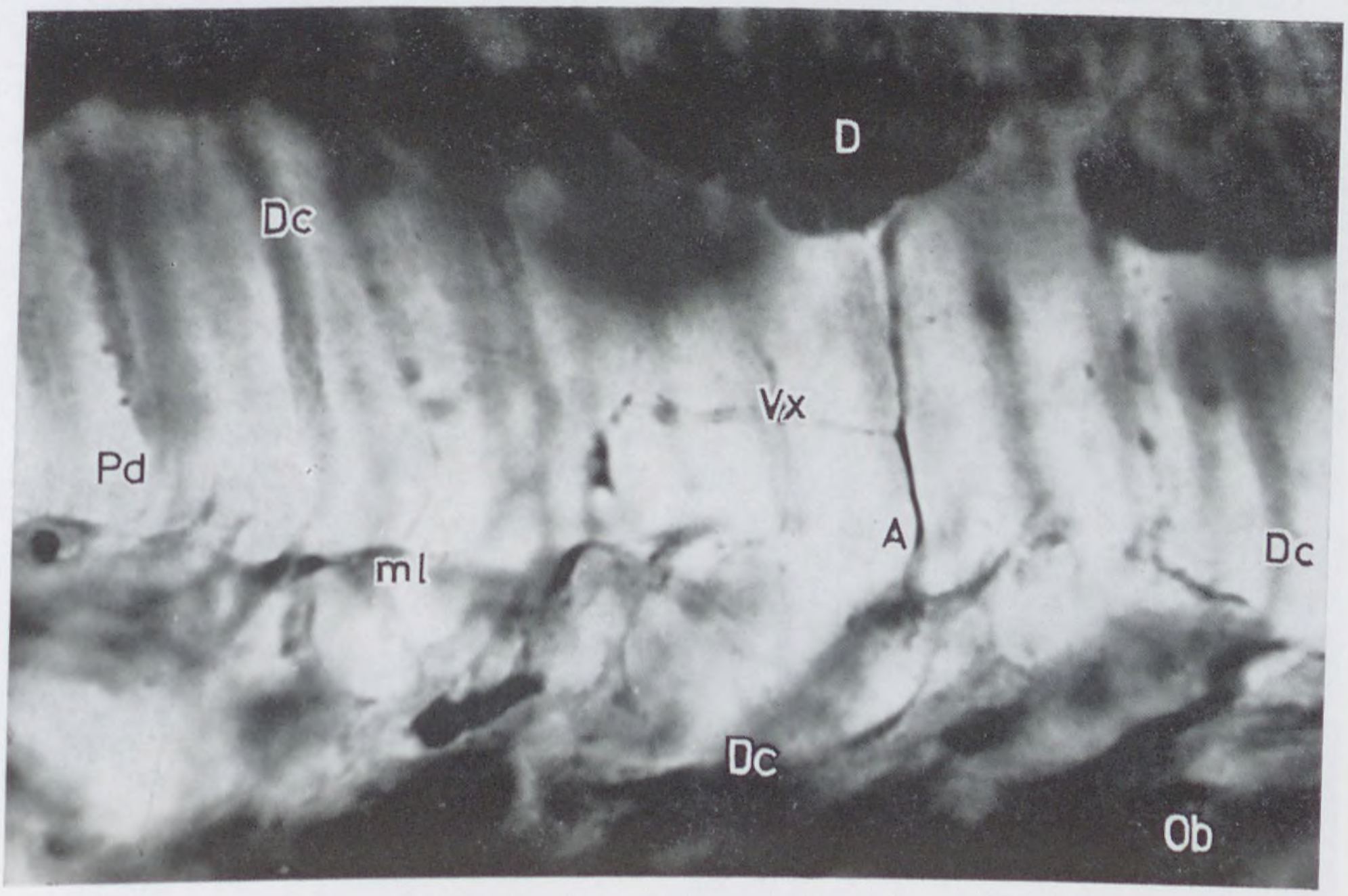

2

Plate 47

Ultrastructure of the human dental pulp

Dr. Hattyasy's electron micrograph

Coronal part of the dental pulp of a five-year-old child with several fibroblasts (F) containing characteristic fine filaments (Cf). The fibroblast in the lower part of the picture shows cisterns of endoplasmic reticulum (ER) and ribosomes (R). Groups of collagenous fibrils (Co) occur among the elongated processes of fibroblasts. The cytoplasm of a Schwann's cell (Sch) with numerous ribosomes and a mitochondrion (M) can be seen in the middle of the picture.

The cross-section of a thin nerve fibre (A_1) is surrounded by the superficial membrane of Schwann's cell. The oblique section of a larger axon (A_2) is adjacent the cell. In this axon a larger mitochondrion (M) and a large dense core vesicle (dcv) are visible.

A light profile of unknown character (X) can be seen between one of the axons (A_2) and the fibroblast.

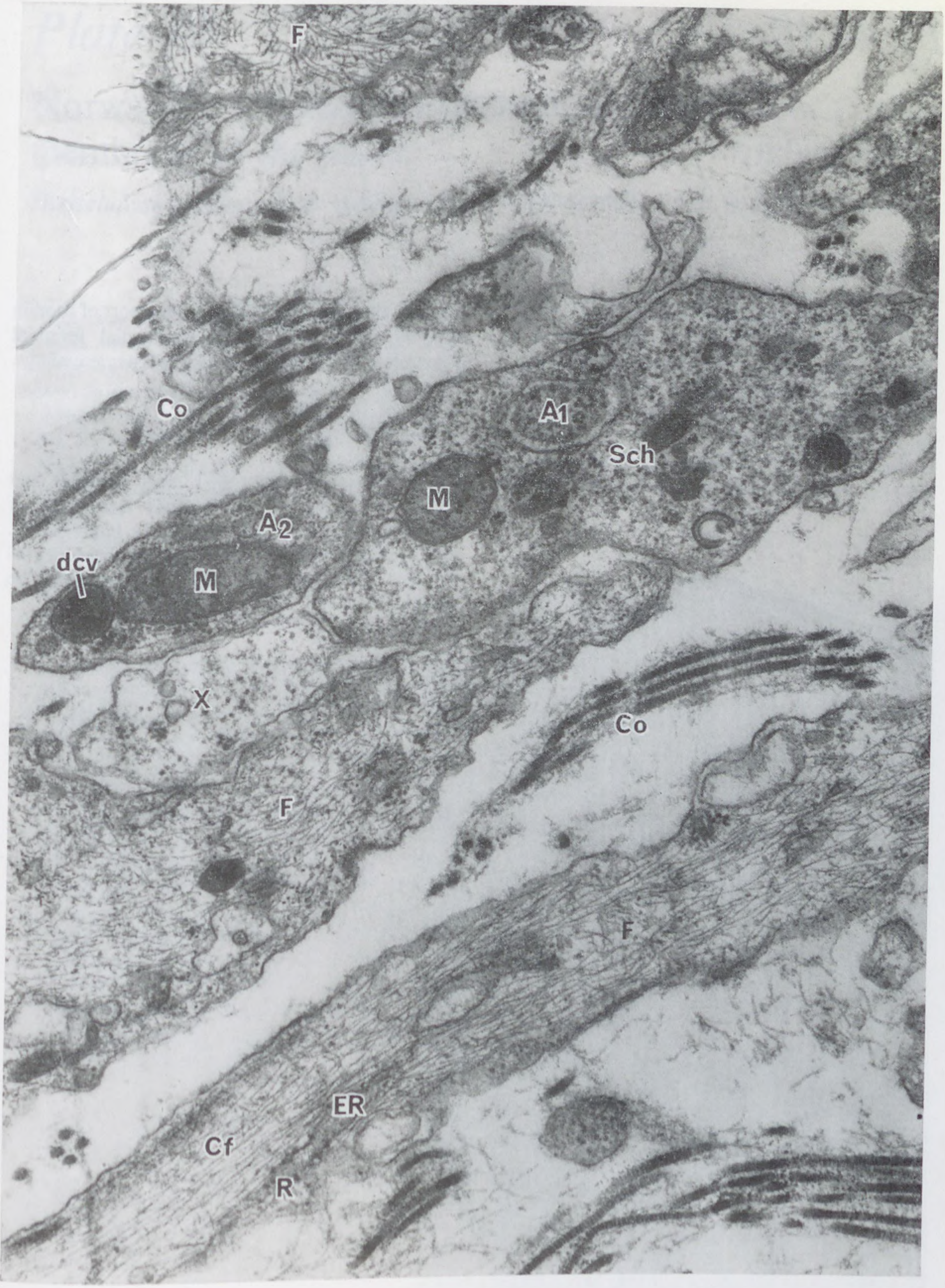
F
Co
A1
Sch
M
A2
dcv
M
X
Co
F
F
ER
Cf
R

Plate 48

Dog *(Canis familiaris)* mucous membrane of the palate

Bielschowsky–Gros silver impregnation

A connective tissue papilla (c) derived from the lamina propria (d) protrudes into the epithelium (a). Nerve fibres (e) entering the connective tissue papilla form a loose glomerulus (f) from which intraepithelial fibres (g) project into the basal layers of the epithelium (b). In mammals, the mucous membrane of the palate, the epithelium of which undergoes desquamation in advanced age, has an important receptor function, related to the transport of food in the oral cavity. The few intraepithelial terminal branches are devoid of specialized nerve endings.

Neurohistological comments

Nerve fibres, especially their finer branches and terminals innervating the mucous membrane of the hard palate, are only imperfectly impregnated. The intraepithelial end-rings and the corial neurofibrillar end-lamellae can only exceptionally be revealed.

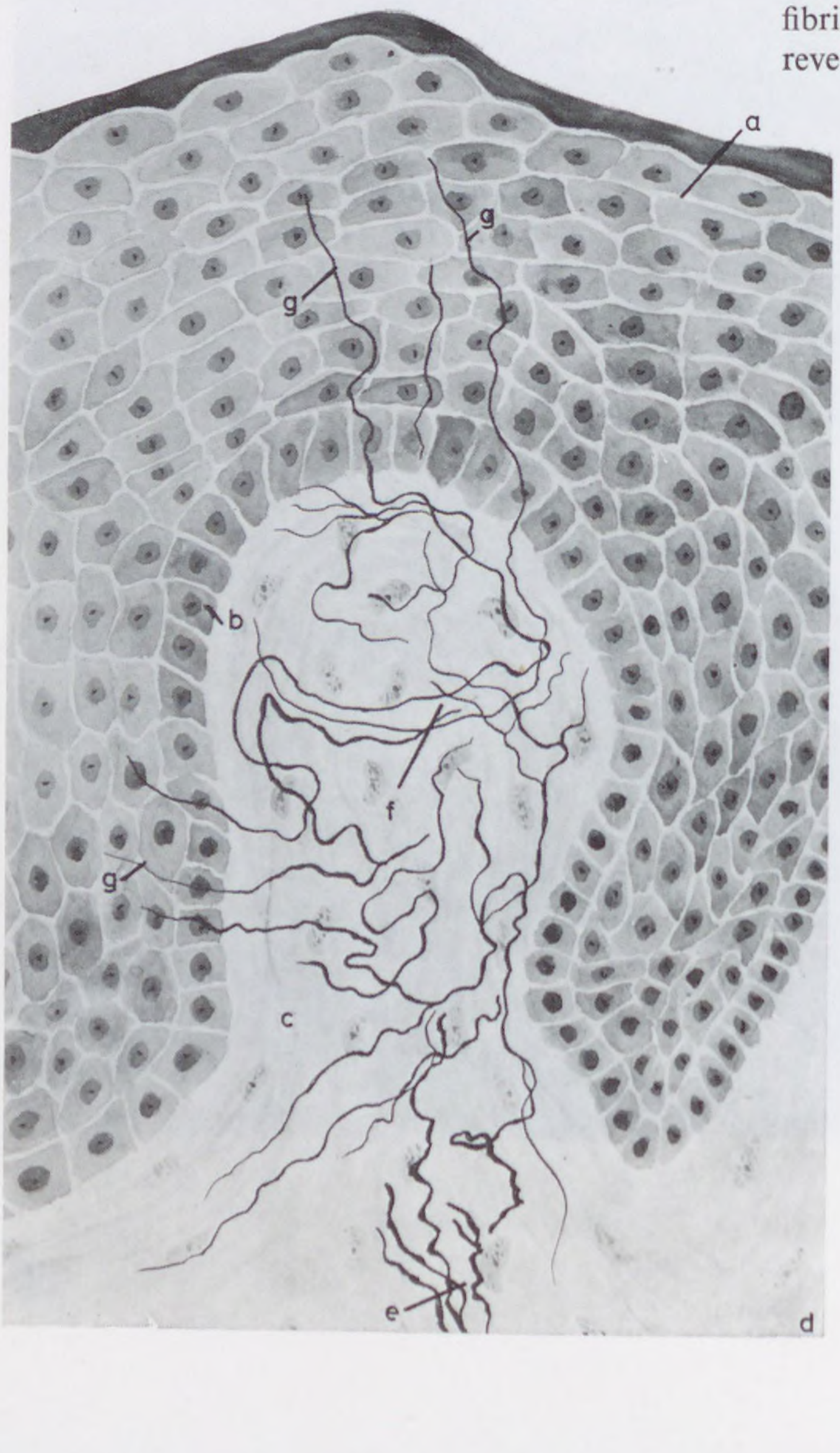

Plate 49

Norway rat *(Rattus norvegicus)* mucous membrane of the palate

Bielschowsky–Gros silver impregnation

Connective tissue fascicles (b) and nuclei of connective tissue cells (c) can be seen in the lamina propria (a). The thick nerve fibres (d) running upwards in the picture constitute a loose plexus after manyfold ramification. Fine smooth fibres originate from the plexus and terminate in pear-shaped structures (e). In the majority of the terminal structures the neurofibrillar end-glomerulus (f) is strongly stained.

Functional and comparative neurohistological comments

The mucous membrane of the palate plays an important role in nutrition, therefore it carries various receptor apparatuses the development of which depends both on the type and quality of the diet of the animals as much as on their dentition. The receptors are characteristic of the species but also reflect phylogenetic trends dependent on the feeding habits as well as on environmental changes. Thus, in a wider sense, these receptors bear the marks of the development of life on earth This connection has been proved by paleontological and comparative anatomical studies on the dentition of mole-rats (Spalacidae). It has been proved that changes in food supply, which in turn are the result of changed geometeorological conditions, bring about corresponding changes in the organs connected with the intake of food.

Plate 50

Human palatine tonsil

Jabonero's silver impregnation

Nuclei of connective tissue cells (b) in the connective tissue capsule (a) of the tonsil. Lymphoid tissue (c) with uniformly round lymphocytes (d) can be distinguished in small clusters or in expanded fields. The wavy fibres (f) of a nerve fascicle (e) enter the lymphoid tissue to terminate there. The arborization of a small artery (g) can be seen on the right.

Functional neurohistological comments

Although the palatine tonsils are devoid of receptors, inflammatory processes of the tonsil and the immediate neighbourhood are exceedingly painful. This fact can be explained in two ways. First, a relatively high number of nerve fibres enter the connective tissue surrounding the tonsil. These fine, smooth-edged nerve fibres pass alongside the lymphoid tissue or may even enter the latter. Also thick, wavy nerve fibres with repeated varicosities can often be found. The neurofibrils are well impregnated in the varicose regions. – Second, the fine ramifications of the branchings of the thick fibres can also be traced in the tonsillar tissue where they end. It is impossible to decide even on the basis of our best preparations whether there are any kind of special nerve endings which establish a connection between the nerve fibres and the reticular fibre system forming the framework of the lymphoid tissue. The fact that nerve fibres enter the lymphoid tissue and terminate there suggests that these fibres are, in fact, the very receptors of the tonsil.

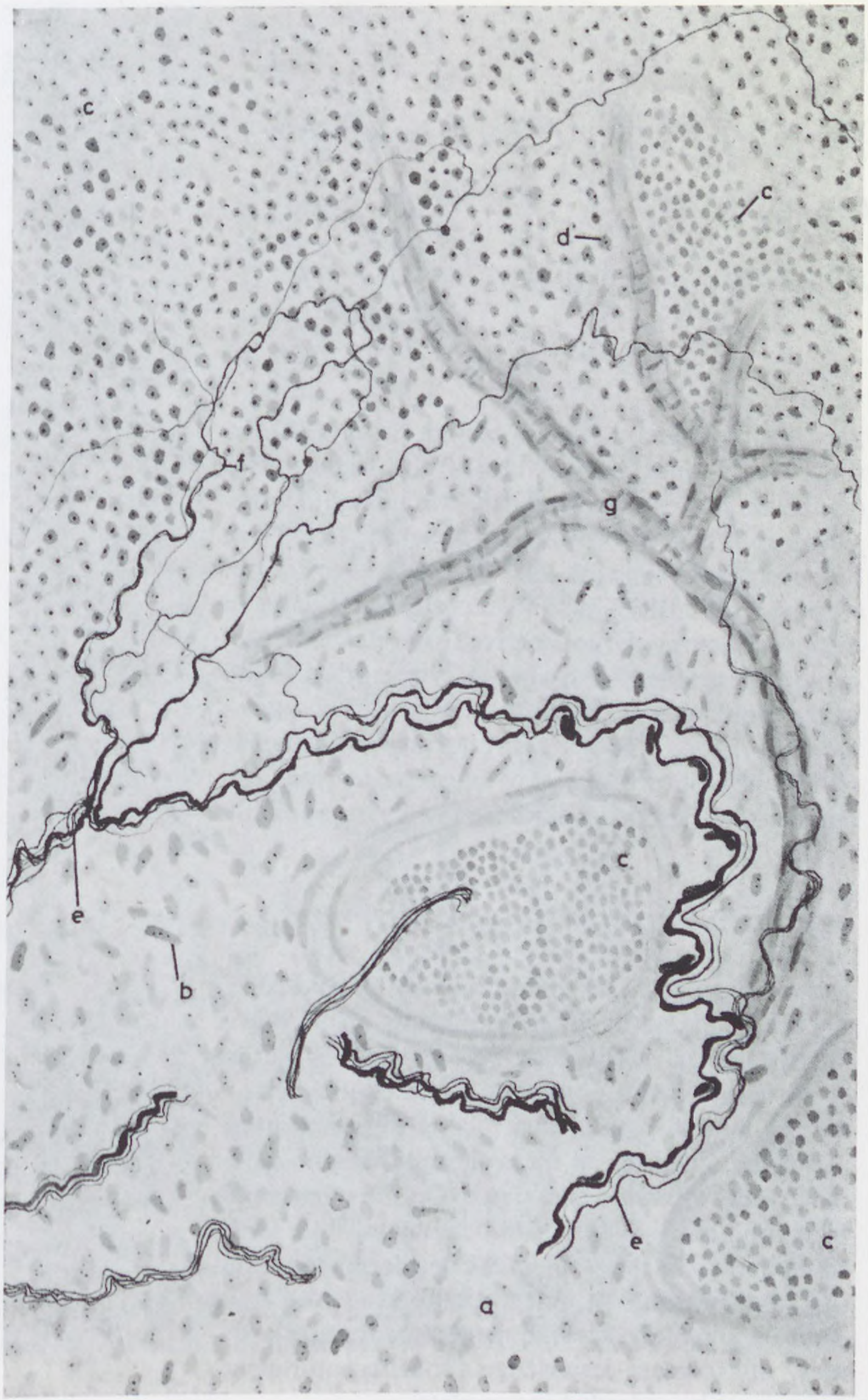
c
c
d
f
g
e
c
b
e
c
a

Plate 51

Black stork *(Ciconia nigra)* esophagus

Ábrahám's silver impregnation

Stratified epithelium (a) and lamina propria (b). In the latter a thick nerve fibre of the vagus nerve (c) can be seen; its wavy and fine branches (d) project deeply into the epithelium to terminate as free bulbous thickenings (e). The branches have several elliptical varicosities (f) and taper off gradually to disappear among the connective tissue elements. Receptor apparatuses of a similar type can be found in the esophagus of the black-headed gull *(Larus ridibundus)*, too. Though neurofibrillar end-lamellae of the nerve fibres were not impregnated, one can assume that here, too, similar lamellae are present.

Functional neurohistological comments

It is a remarkable fact that intraepithelial and corial nerve endings occur in the esophagus of birds in a few species only. This may be due to the structure of the tissues of the esophagus. Reflexes arising from the esophageal region must play a very important role in the nutrition of birds since, having no teeth, they swallow food in big lumps. On the other hand, their food mostly consists of hard matter like seeds, roots, shoots, living frogs, etc. Considering the seemingly sparse sensory innervation of the esophagus of birds, and the special requirements for reflex activities, our present knowledge about receptor structures must be regarded incomplete.

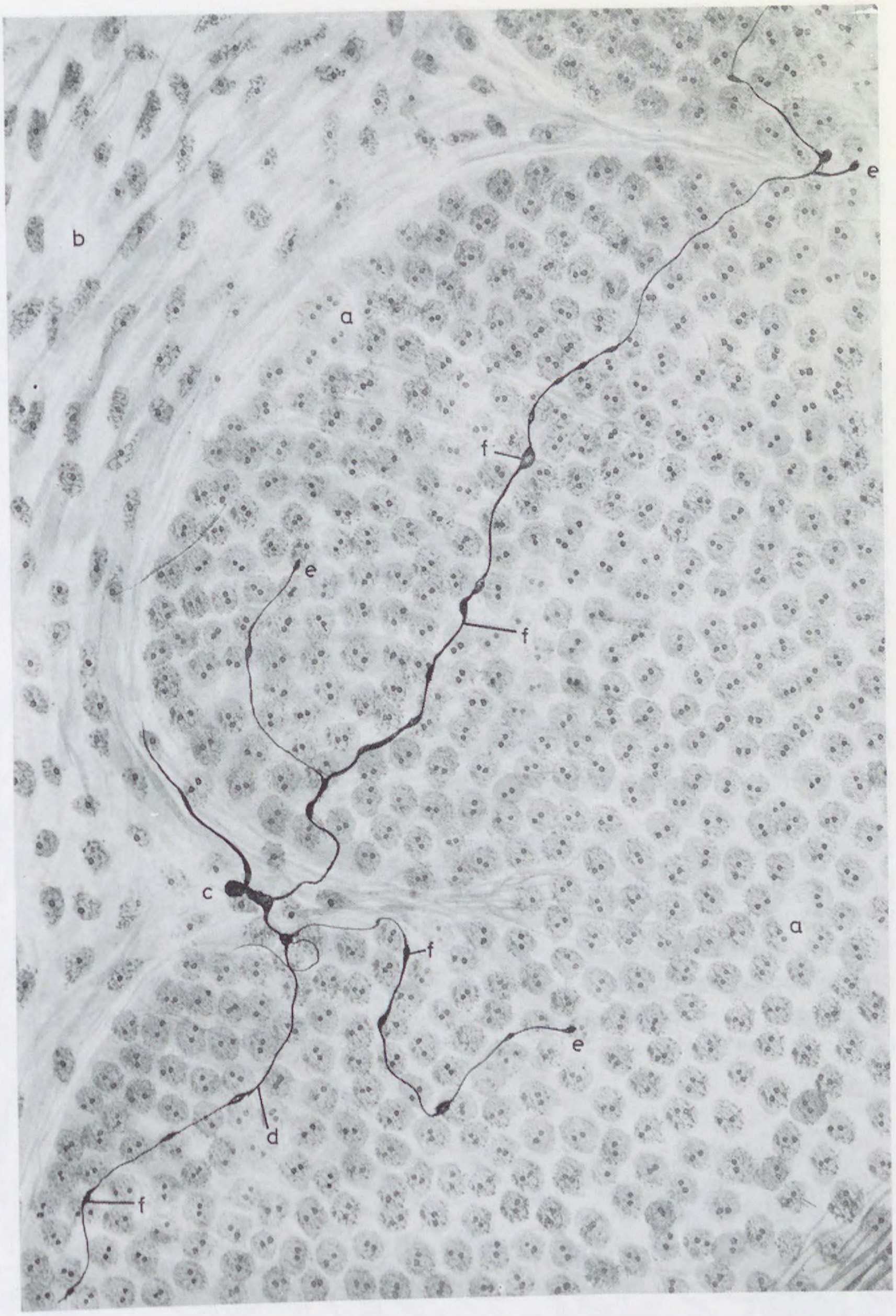
e
b
a
f
e
f
c
f
a
e
d
f

Plate 52

Mallard *(Anas platyrhyncha)* esophagus

Bielschowsky–Gros silver impregnation

(Dr. Milochin's preparation)

A portion of the lamina propria (c) surrounded partly by the smooth muscle layer (a). The nuclei of the smooth muscle cells (b) are well visible. A thick nerve fascicle (d) (lower left corner) enters the lamina propria. Also the myelin sheath (f) of some nerve fibres (e) can be studied. The fine terminal nerve fibres (g) end in large neurofibrillar end-lamellae (h) of variable size and structure.

Functional and comparative neurohistological comments

Fascicles of thick nerve fibres terminating in large neurofibrillar end-lamellae have been described first in the esophagus of Cyclostomata and later in birds, reptiles and mammals. The neurofibrillar end-lamellae appear in clusters. These nerve terminals are sensitive to pressure acting on the inside of the wall of the esophagus.

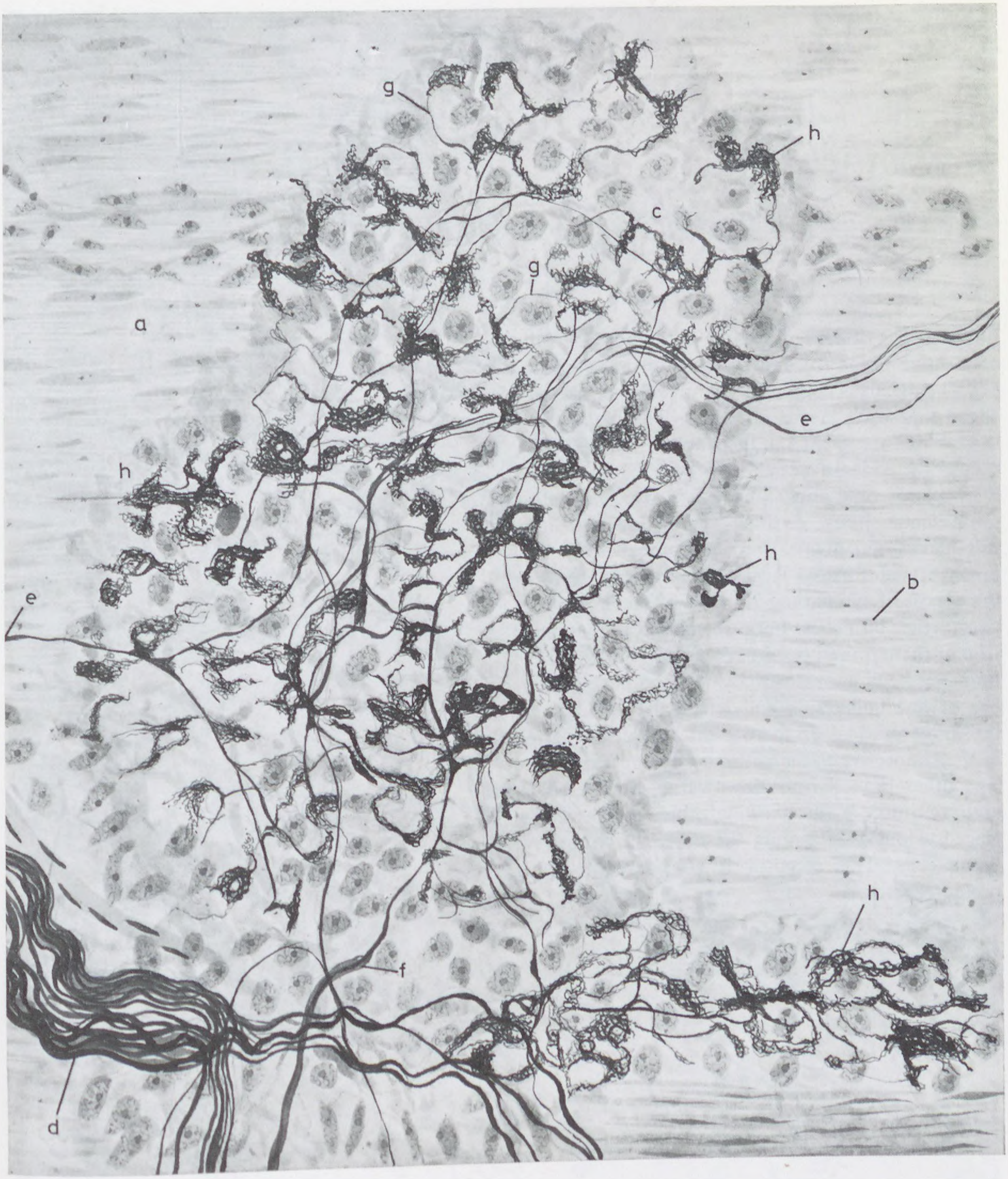
g
h
c
g
a
e
h
h
b
e
h
f
d

Plate 53

Greylag *(Anser anser)* proventriculus

Ábrahám's silver impregnation

Large plexus of nerve fibres (c) at the border of the connective tissue (b) and the smooth muscle layer (a). The plexus is composed mainly of fine, smooth-edged and wavy nerve fibres (d). The majority of these fibres are located in the smooth muscle, where they form a dense network; on the basis of their light-microscopic appearance, they are classified as sympathetic fibres. A thick nerve fibre (e) enters this plexus and divides into two branches (f). The upper branch forms a large loop at a distance from the plexus of sympathetic fibres and breaks up into two further branches. Loop formation is characteristic of the terminal portion of sensory fibres. These branches bear several varicosities, and have a number of fine collaterals and terminal ramifications, the latter gradually tapering off and disappearing in the connective tissue without any end-structures. The other branch runs downwards, doubles back and continues in fine terminal fibres which can be traced a long way among the nuclei of connective tissue cells. This receptor is considered to be a pressoreceptor.


d
e
f
c
d
a
f
b
c
f
d

Plate 54

Black stork *(Ciconia nigra)* proventriculus

Ábrahám's silver impregnation

A large fascicle (c) containing wavy nerve fibres, most of which are thin, can be seen in the loose connective tissue (b) protruding into the smooth muscle layer (a). The nerve endings (g) differ from each other both in size and structure. They are neurofibrillar end-lamellae in which the neurofibrils form a dense network. In the lower right corner two ganglion cells (h) are shown, with neurofibrils in their cytoplasm. The round nuclei are excentrically situated, like in most sympathetic nerve cells (d – nerve fibre of medium size, e – varicosity, f – branching point of nerve fibre).

Functional and comparative neurohistological comments

The localization and the structure of these sensory systems suggest that they are the receptor elements of the smooth muscle of the proventriculus. They are classified as baroreceptors responding to stimuli arising as a result of tension in the muscle layers. Their function is to inform the sensory regions of the medulla about the consistency and localization of food passing the glandular stomach. Unlike the proventriculus, the stomach and the bowels are poor in receptor apparatuses, the only exceptions being the gizzard (ventriculus) of aquatic birds, where a large number of receptors can be found.


a
f
d
e
g
c
b
g
h
h

Plate 55

Black stork *(Ciconia nigra)* proventriculus

Ábrahám's silver impregnation

An elaborate and peculiar receptor system can be found in the connective tissue (d) located adjacent to the smooth muscle tissue (e) of the proventriculus. Nerve fibres of various course and thickness (a), terminating in end-lamellae (c), can be seen to form peculiar rings (b). Such rings can regularly be found in the proventriculus. They are, in fact, anastomosing terminal branches of single sensory fibres. Such unusual histological formations were described also by Russian neurohistologists. The question arises as to the significance of these rings, and why they only occur in the receptor system of the proventriculus of birds. For the time being, we cannot give a definite answer to these questions.

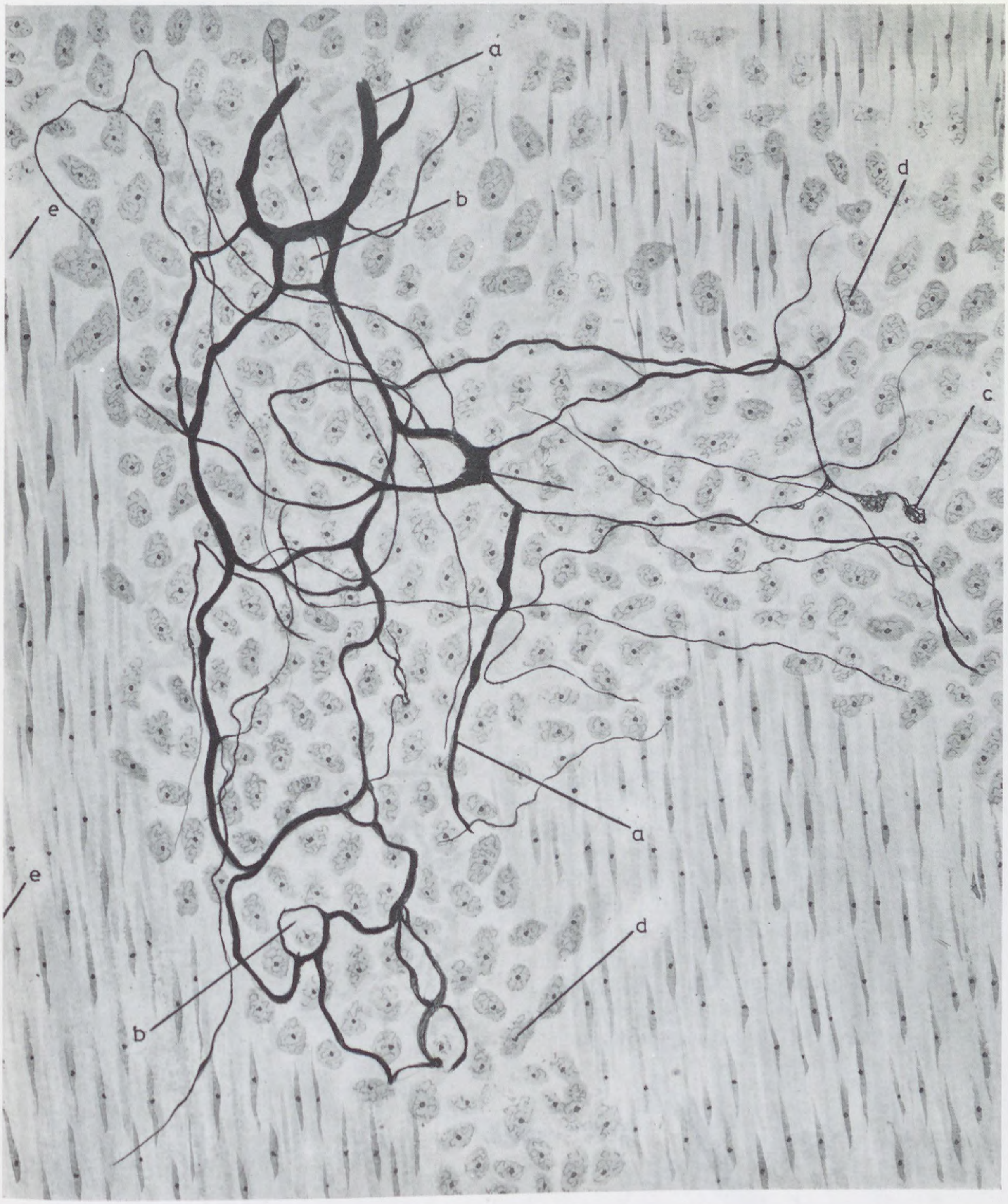
a
b
e
d
c
a
e
d
b

Plate 56

Black stork *(Ciconia nigra)* proventriculus

Ábrahám's silver impregnation

Connective tissue lamellae (a) containing large, round nuclei, with smooth muscle tissue (b) between them. Three fascicles of sympathetic nerve fibres (c) can be seen in the connective tissue (right). Wavy fibres of uniform thickness run parallel to the smooth muscle fascicles. Note the thick sensory nerve fibre (d) at the bottom, sending off two branches which supply two connective tissue fascicles. After multiple ramifications the thick fibres form preterminal fibres of varying length (e), and terminate in irregularly structured end-lamellae (f). The thick and wavy neurofibrils (g) are especially well impregnated in this picture; they are found in the end-lamellae and also in some places of the nerve fibres. The receptor system located mostly in the connective tissue shows many characteristic features rarely found in the receptors of the proventriculus. These are: varicosities arranged in lines, enlarged nerve fibre segments, and fine smooth collateral branches running to the end-lamellar system without changing in diameter. The latter occasionally ramify and form "colonies". The terminal system is in connection with the sympathetic fibres at the border of the connective tissue and the smooth muscle cells. It follows from its localization that this is a baroreceptor system which informs the higher nerve centres about the distension of the stomach. It might also play a role in nociception.

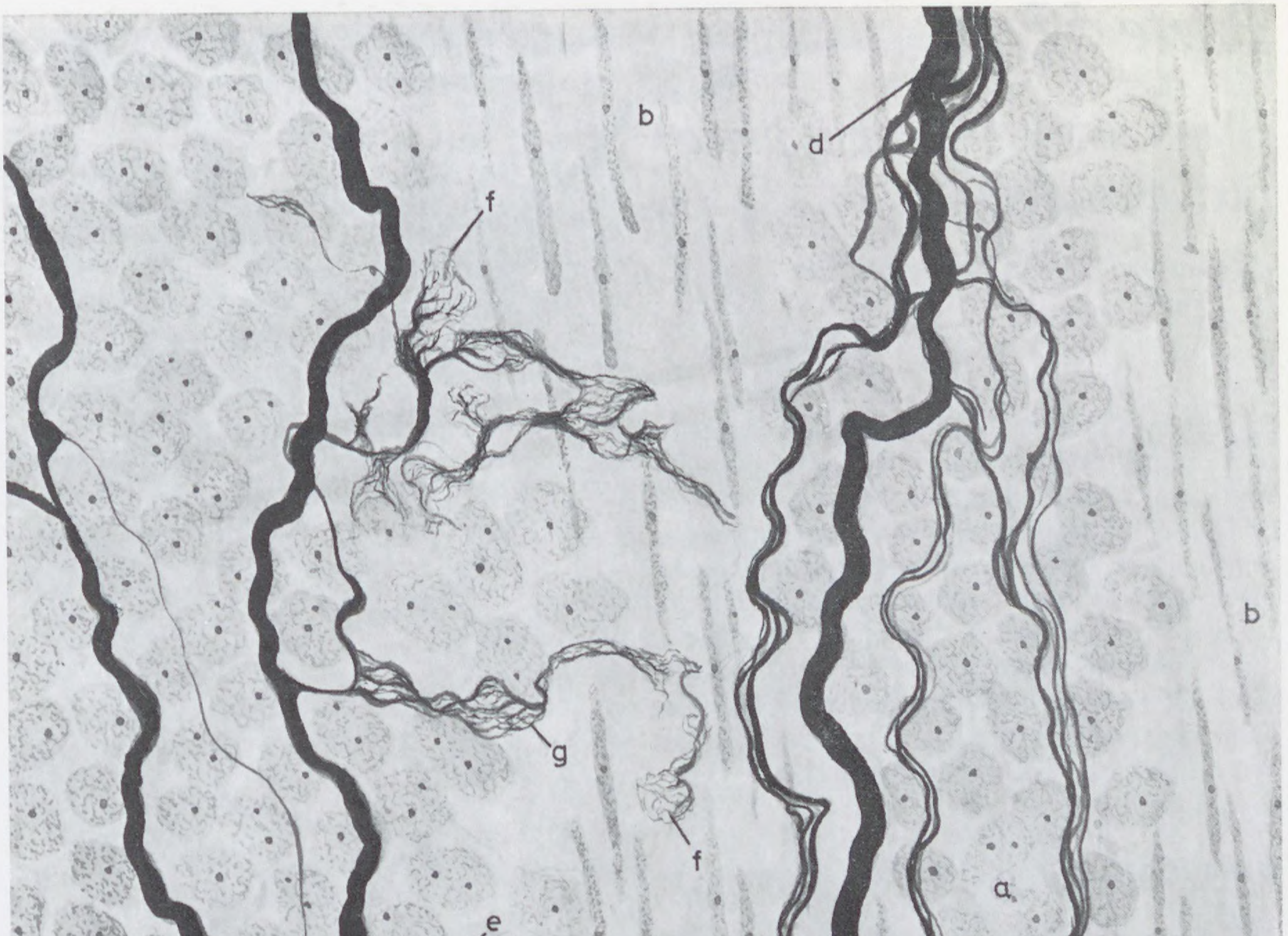
b
d
f
b
g
f
a
e
c
c
d
g
c
a
d

Plate 57

Black stork *(Ciconia nigra)* proventriculus

Ábrahám's silver impregnation

Smooth muscle tissue (b) with transverse connective tissue stripes (a) characterized by dark round nuclei. A portion of the submucosal plexus (c), with nerve cells (d) and fibre plexuses is seen in the upper part of the picture. A thick sensory nerve fibre (e) emerging at the right upper corner forms a special receptor system (f). Note the varicosities (g), some of them with well-stained neurofibrils. Otherwise the whole terminal system is characterized by abundant branchings, large, ovoid neurofibrillar varicosities, and the absence of neurofibrillar lamellae.

Functional neurohistological comments

This receptor structure is very rare, even in storks. It can be assumed that some of the vagal fibres in the proventriculus form baroreceptor end-systems which inform the central nervous system about the pressure prevailing in the proventriculus. Another group of the vagal fibres subserves receptor functions related to the smooth muscle. Since the greatest part of this sensory terminal system is to be found in the smooth muscle, as also shown by this picture, it should be regarded as belonging to the sensory apparatus of this tissue.


e
c
d
b
f
f
g
f
b
a

Plate 58

Lesser black-backed gull *(Larus fuscus)* proventriculus

Ábrahám's silver impregnation

Connective tissue (a) enclosed by a narrow frame of smooth muscle (b). The centrally situated dense nucleoli of the smooth muscle nuclei exhibit argentophilia. In the connective tissue fine sympathetic fibres (c) meander among the terminal sensory fibres. The thick sensory nerve fibre (d) is extremely rich in collaterals; characteristic tri- or quadrangular flat thickenings are visible at their origin. The branches of the thick sensory nerve fibre form an elaborate receptor apparatus (e); the terminal fibres end in neurofibrillar end-lamellae (f).

Comparative neurohistological comments

Receptors found in the proventriculus of the lesser black-backed gull are usually similar to those demonstrated in this picture; their elongated form is in sharp contrast with that described previously in the proventriculus of the black stork. These sensory fibres are thick, and generally smooth. Long segments of the fibres can usually be traced in stained preparations. The end-ramifications are long and fine; the lamellar thickenings at the branching points seem to be a standard feature.

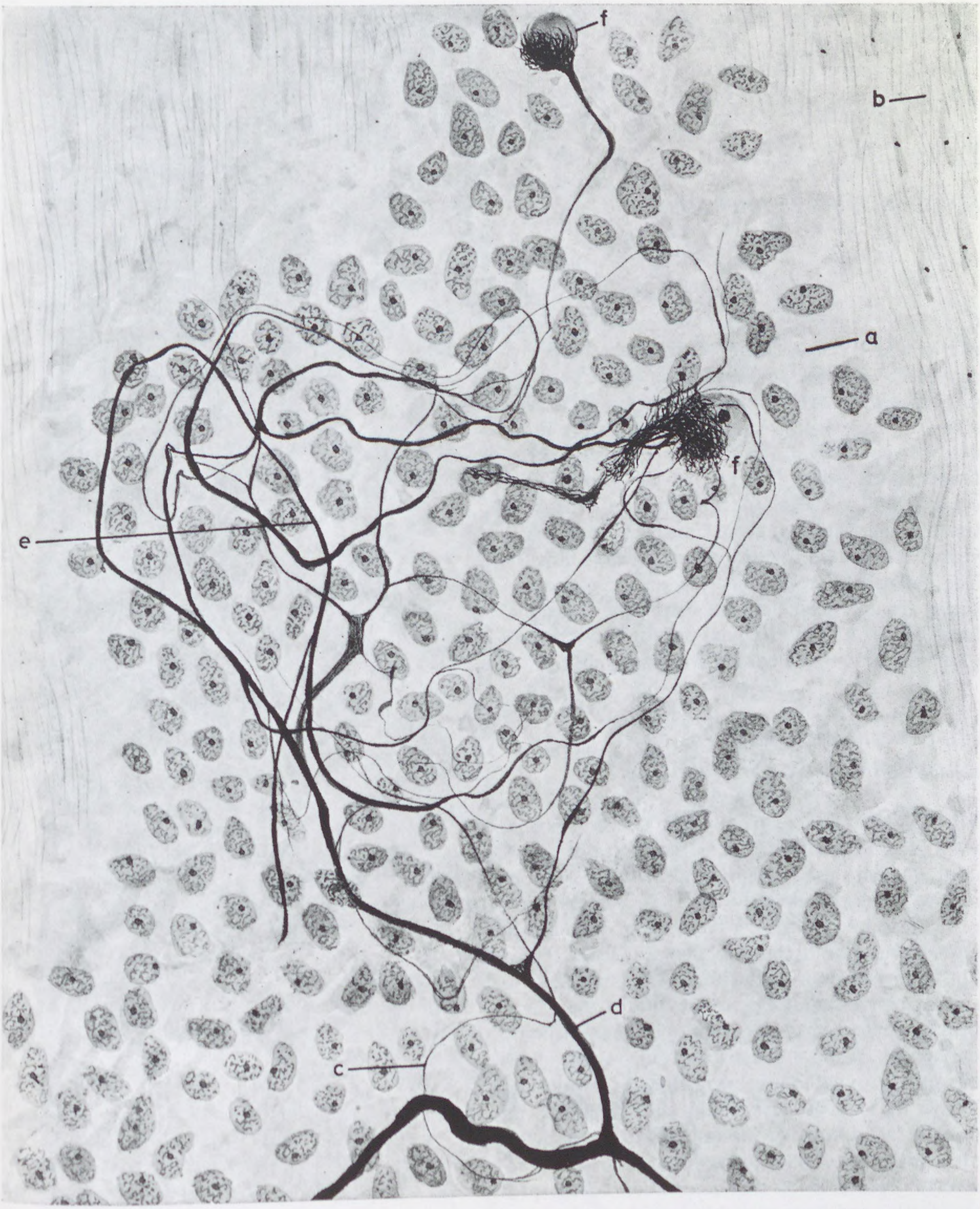
f
b
a
f
e
d
c

Plate 59

Herring gull *(Larus argentatus)* proventriculus

Ábrahám's silver impregnation

Connective tissue (a), containing the nuclei of connective tissue cells (b) and round argentophil nucleoli. The connective tissue layer is flanked by smooth muscle cells (c), with elongated nuclei and spherical nucleoli (d). A thick nerve fibre (e), probably of vagal origin, can be seen in the connective tissue lamella (bottom). Its typical ramifications occupy almost the whole area of the connective tissue island. The triangular lamellae (g) are clearly visible at the sites of branching of the nerve fibre (f). The collaterals are meandering in the connective tissue ground substance and constitute occasional loose coils (h). Their terminal portions are thin and disappear among the connective tissue cells (i).

Functional and comparative neurohistological comments

When studying these pictures the question arises: what is the function of these receptors? It is not clear whether they are sensory elements of the connective tissue or belong to the sensory nerve fibres of the smooth muscle. On the basis of localization and structure both considerations can be accepted but it appears more plausible that essentially two end-systems exist in this case. One of them is a pressoreceptor system providing for the sensitivity of the wall of the proventriculus into which pieces of food arrive without being crushed or masticated. This is the possible reason why such receptors can only be found in lower vertebrates but not in mammals with well-developed dentition. They are characteristic features of the innervation of the proventriculus and have probably ceased to exist when the proventriculus disappeared in the course of phylogeny. The other group of the receptors of the proventriculus confined to the smooth muscle layer presumably provides the latter with sensory end-systems.

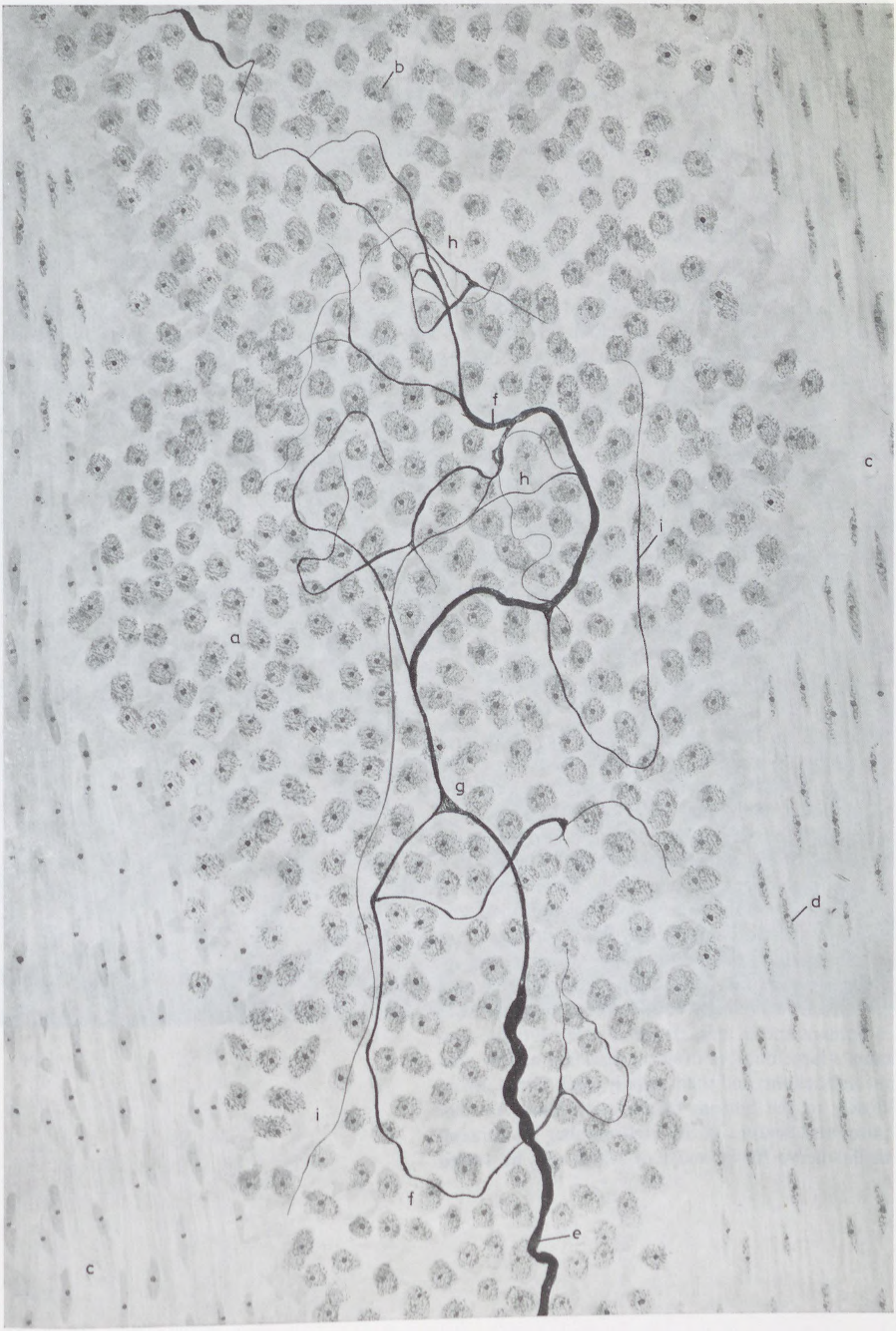
b
h
f
h
i
c
a
g
d
i
f
e
c

Plate 60

Cat *(Felis domestica)* epiglottis

Bielschowsky–Gros–Cauna silver impregnation

Three histological components of the epiglottis can be distinguished here: the epithelium (a), the transversely oriented connective tissue fibres of the tunica propria (b) and a portion of the hyalin cartilage (c, right corner). All three components contain cell nuclei and dense nucleoli. Thick nerve fibres (d) running in the subepithelial connective tissue form a nerve fascicle (e). Some of the intraepithelial fibres (f) originate directly from this fascicle, while other fibres originate from branchings of the thick fibres. A few nerve endings (g) appear on the surface of the epithelium.

Functional and comparative neurohistological comments

Judging from the large number of nerve endings, the epiglottis must be very sensitive. Large nerve trunks run to the laryngeal surface of the epiglottis. Some of their fibres taper off or branch at the border of the epithelium and project into it in large numbers. Some of them pass towards the surface to terminate directly in end-knobs while others run longitudinally in the stratum cylindricum; then they turn upwards to continue towards the surface and terminate there as free endings. Comparative investigations of the receptors in the epiglottis have revealed a surprisingly abundant innervation. Both in humans and in animals the connective tissue contains a large number of nerve fascicles, mainly near the epithelium, and their usually thick fibres adhere closely to the bottom of the epithelium. Another prominent feature is the high number of intraepithelial nerve fibres, most of which can be traced up to the superficial layer of the epithelium. Finally, it is a unique finding that the majority of the intraepithelial fibres end at the surface of the epithelium: the nerve fibres virtually appear to stick out from among the cells of the superficial epithelial layer. Apart from the sensory end-systems the sensitivity of the epiglottis also relies on the numerous gustatory buds found in the epithelium.

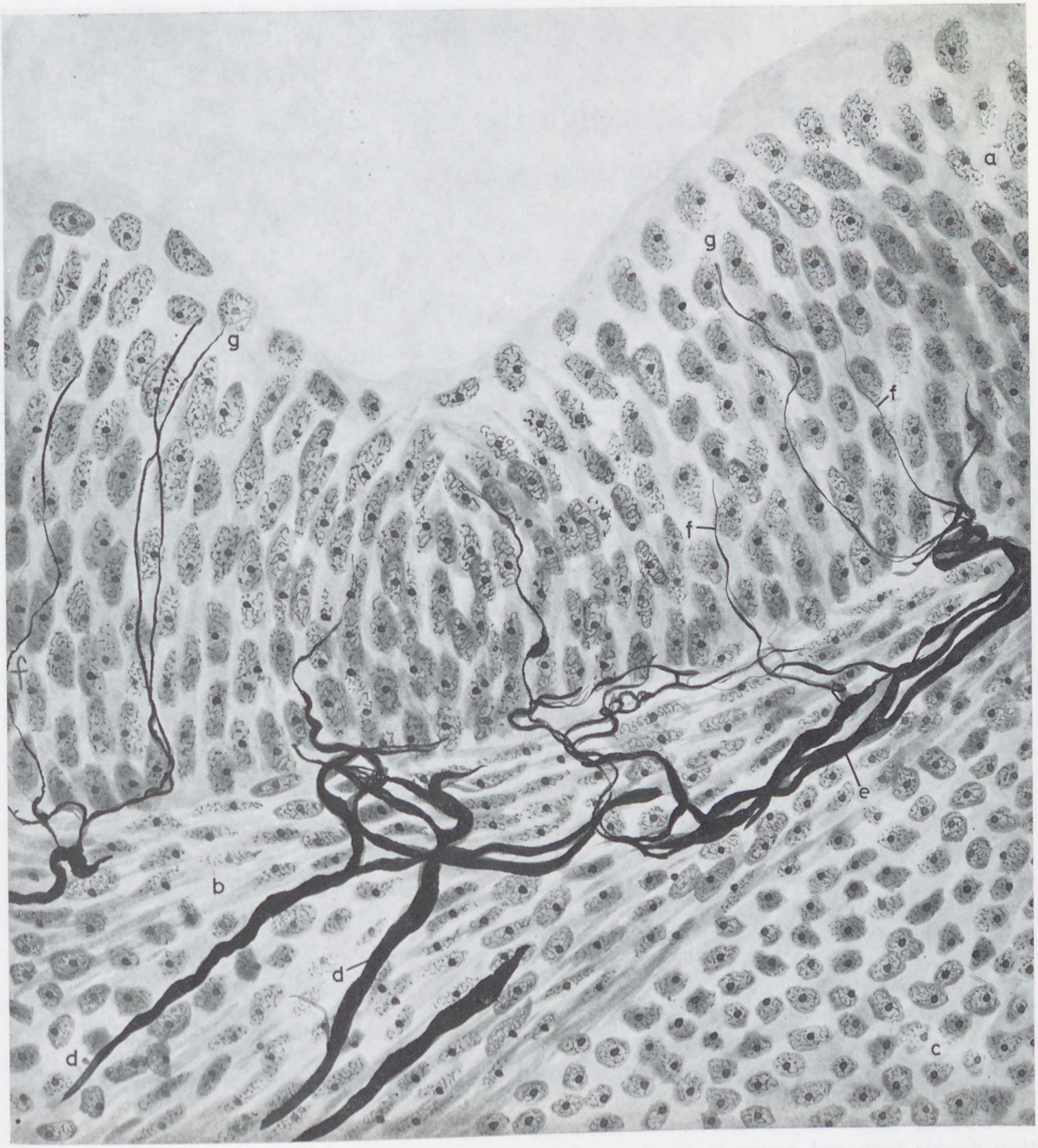
a
g
g
f
f
e
b
d
d
c

Plate 61

Cat *(Felis domestica)* epiglottis

Bielschowsky–Gros–Cauna silver impregnation

Histologically, this picture can be divided into two parts: the epithelium (a) and the tunica propria (b). The latter contains connective tissue fibres running parallel to the surface and peculiarly elongated nuclei of connective tissue cells containing large amounts of chromatin. Thick nerve fibres (c) run in the top layer of the tunica propria, branches (d) of which penetrate the epithelium. Some of these ramify and form loop-like intraepithelial systems (e). The terminal portions of the receptor system consists of free nerve endings between the epithelial cells (f).

Comparative and functional neurohistological comments

It is common in the human epiglottis that some of the intraepithelial fibres (in the lower layers of the epithelium) run a parallel course with the surface indicating extreme sensitivity. Similar innervation is found, among others, in the epidermis and kidney of bony fishes as well as in urinary pathways, walls of the trachea and bronchi, and in the lower layers of the epithelium covering the external genital organs. Recurrent termination is a rare feature of the sensory fibres entering the epithelium from the subepithelial connective tissue and coursing toward the surface, where they bifurcate. The branches then double back and return to the lower layer of the epithelium in parallel with the parent fibre. A similar phenomenon – referred to above – has been found in the skin of the nose of puppies; here, too, the branches double back, but only pass through a few layers of cells. The physiological significance of this undoubtedly peculiar phenomenon can hardly be explained. Large coil systems, the fine fibres of which can only be traced with difficulty in the densely structured terminal fibre system, are common in the human epiglottis at the junction of connective tissue and epithelium. In addition, collaterals with loop-like formations are frequently found in the epithelium. The innervation of the epiglottis, especially its synapses, raise many interesting problems to be solved by electron microscopic investigations.

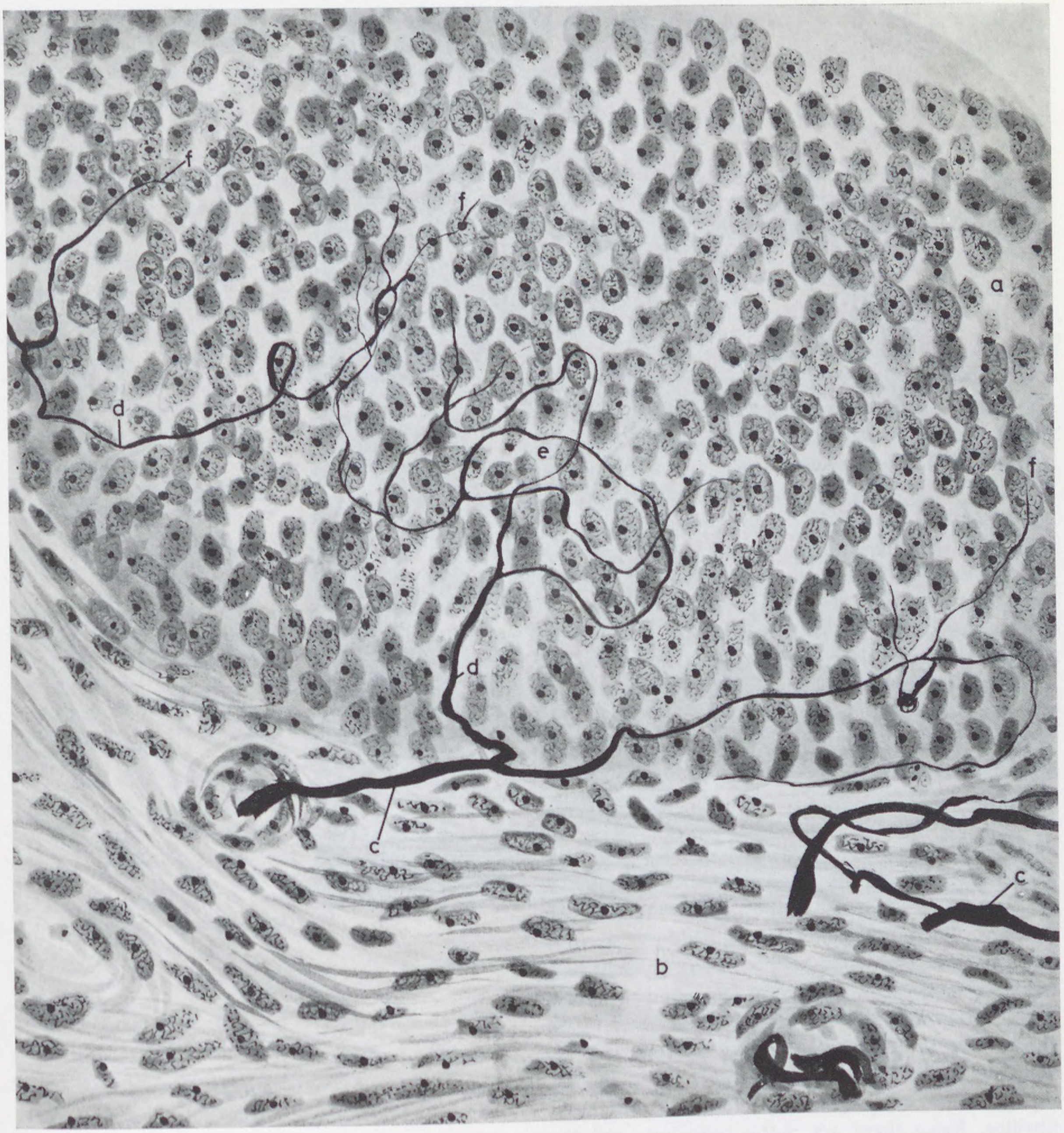
f
f
a
d
e
f
d
c
c
b

Plate 62

Carp *(Cyprinus carpio)* air-bladder

Bielschowsky–Ábrahám silver impregnation

Rich capillary network (b), connective tissue fibres and nuclei of connective tissue cells (c) in the tunica propria (a). A fascicle (d) composed of thin nerve fibres, mostly of sympathetic origin, is crossed by another, similarly structured, fascicle. Fine, wavy fibres (e) innervating the capillaries originate from the sympathetic fascicle. A thick, presumably vagal, nerve fibre (f) runs within one of the sympathetic nerve fascicles. Abandoning the fine fibres, it gives rise to an abundant terminal arborization (g). The finest terminal fibres (h) disappear among the connective tissue cells.

The nerve fibres of the air-bladder originate from the vagus nerve and from the sympathetic chain. Ganglia and well-impregnated thick nerve fibres can be discerned in the fascicles among the fine fibres nnervating smooth muscle cells. The thick fibres seem to belong to the afferent fibre system of the vagus nerve. Usually they leave the fascicle and arborize profusely in the connective tissue. Some of the nerve fibres may leave the fascicle but re-enter it at a distance. Frequently the neurofibrils are well impregnated. They may be lost in some places and reappear in another, enlarged segment of the fibre. The terminal ramifications of the thick nerve fibres show varicose enlargements and terminate in end-lamellae in the vicinity of the parent fibre. The lamellae are either elongated and dense, or round and fibrillar. Since there are many branches, and the terminal ramifications are long, one thick nerve fibre innervates a large area with pressoreceptors. This elaborate receptor system keeps the central nervous system informed about the pressure prevailing inside the air-bladder.

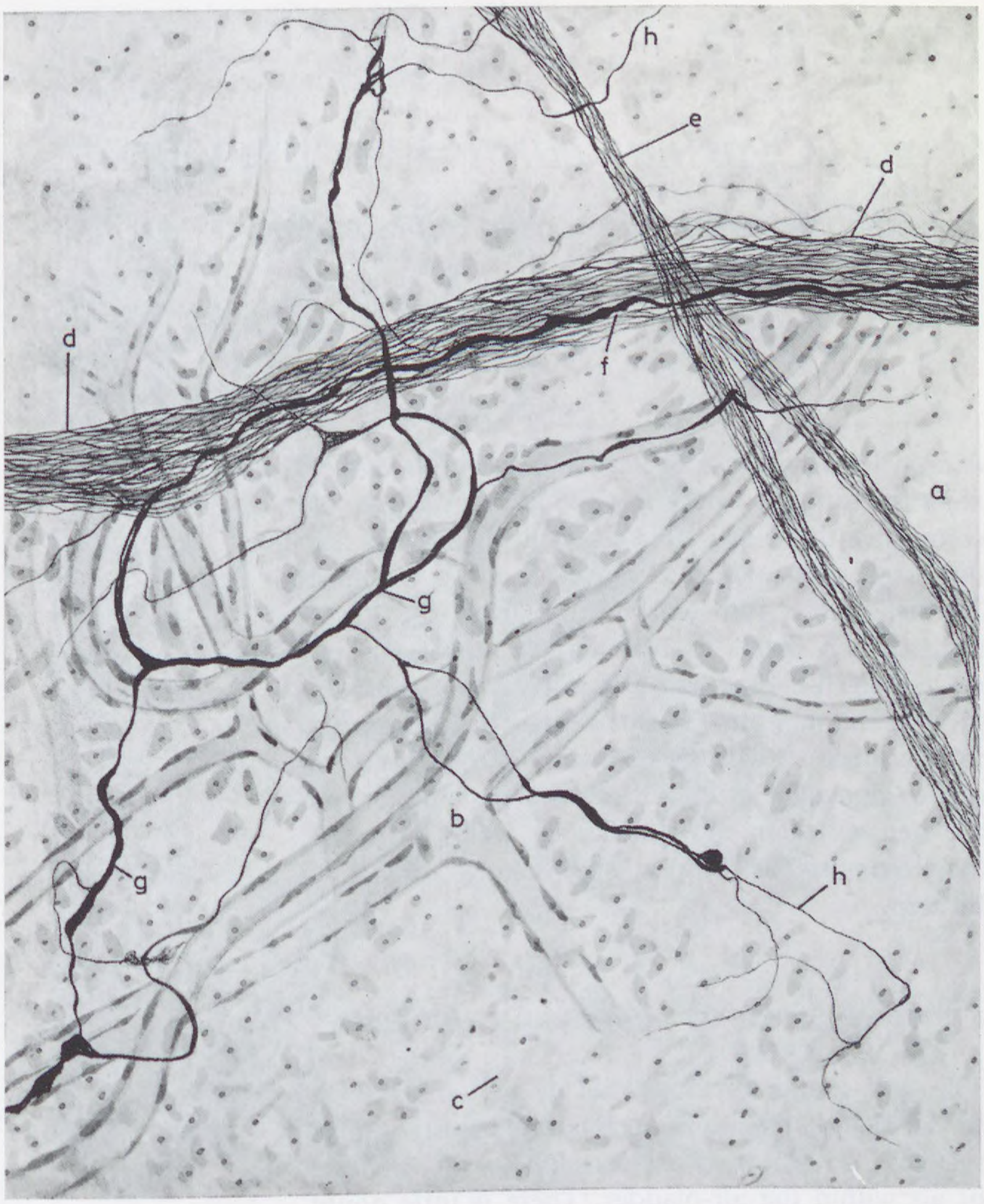
h
e
d
d
f
a
g
b
g
h
c

Plate 63

Carp *(Cyprinus carpio)* air-bladder

Bielschowsky–Ábrahám silver impregnation

A fascicle of sympathetic nerves (c) traverses diagonally the tunica propria (a) containing nuclei (b) of connective tissue cells. The fibres in the fascicle are uniformly thin and are arranged in dense bundles. A thick vagal fibre (d), starting from the lower right corner, forms a characteristic sensory terminal system (e). Fine and coarse segments alternate in the terminal fibres (f). Note the nerve endings (g) in the upper part of the picture. Some of these are dense, elongated or elliptic structures, while others are neurofibrillar end-lamellae in which centrally localized, circular "empty" spaces can occasionally be seen.

Functional neurohistological comments

This and similar pictures indicate that the wall of the air-bladder contains an elaborate pressoreceptor system. The receptors are sensitive to the pressure of air within the air-bladder. There is little doubt that this receptor system plays an important role in monitoring the extent of submersion of the animal in the water. Pressoreceptors in the wall of the air-bladder of fish and in the proventriculus of birds show striking similarities, which is not surprising considering that the air-bladder has developed from a protrusion of the esophagus and has become transformed into an organ producing and housing air secondarily. However, the nerve fibre rings of the proventriculus of birds are absent from the wall of the air-bladder. This fact seems to indicate that the nerve fibre rings represent a phylogenetically higher form of receptors.


g
g
f
g
g
c
e
a
f
b
d

Plate 64

Goldfish *(Carassius carassius)* air-bladder

Bielschowsky–Ábrahám silver impregnation

The picture shows that part of the tunica propria which is in contact with the epithelium. Nuclei (a) of connective tissue cells appear in various forms; some of them have characteristic processes. Some of the nuclei contain more than one nucleolus. A collateral (c) branches off the nerve fibre probably of vagal origin (b), and bifurcates after covering a short distance. In both the principal fibre and its arborization, the neurofibrils (d) are well visible. They are arranged in parallel or plexus-like structures. The terminal arborization of the nerve fibre is composed of end-fibres (e) and end-lamellae (f). The end-fibres are characterized by variable diameter and abundance in neurofibrils. The end-lamellae are large and pleiomorphic, their shape depends on the thickness of the section. They are fitted with ultraterminal fibres (g). Apparently, the sensory terminal and the epithelium of the air-bladder are intimately connected, indicating that the air-bladder possesses special receptor systems which perceive even the smallest change in the pressure of the air. The air-bladder shows considerable differences in the localization, richness and structure of the receptor systems in various species of fresh-water bony (holosteous) fish. Most probably, the differences in the number, ramification, thickness and neurofibrillar arrangement of the vagal fibres and in the shape, size, localization and structure of the end-lamellae are related to ecological conditions of the environment, as well as to the function of the air-bladder.


f
g
g
f
d
e
g
e
d
c
a
b

Plate 65

Cat *(Felis domestica)* heart

Jabonero's silver impregnation

The spherical nuclei (b) of the epithelial cells appear through the connective tissue layer (a) of the ventricular epicardium. A nerve fascicle of nerves (c) passing downwards from the upper left border contains several thin sympathetic fibres and one thick fibre. Another coarse fibre (d), surrounded by a marked myelin sheath (e), leaves the fascicle. The fine collaterals of the thick fibre establish rich terminal arborizations (f) with numerous fine end-rings (g).

Histotechnical comments

The heart of the cat proved to be the most convenient object for the visualization of the epicardial nerve plexus and terminal system. Frozen sections yielded excellent pictures of the nervous elements when using various silver impregnation methods. Nerve plexuses containing a substantial number of fine, smooth sympathetic fibres and individually running coarse myelinated nerve fibres with rich terminal arborizations could be seen in each specimen. By repeated branchings of the parent fibre, fine varicose fibres arise which terminate in loose glomerular systems. The number of glomeruli is very high. In well-stained preparations, the glomeruli give the appearance of bunches of flower spread all over the picture. These sensory nerve endings could be particularly well impregnated if the nerves innervating the epicardium had been cut a few days before this histological procedure. Argentophilia of the terminals obviously increases during the early phase of the Wallerian degeneration.

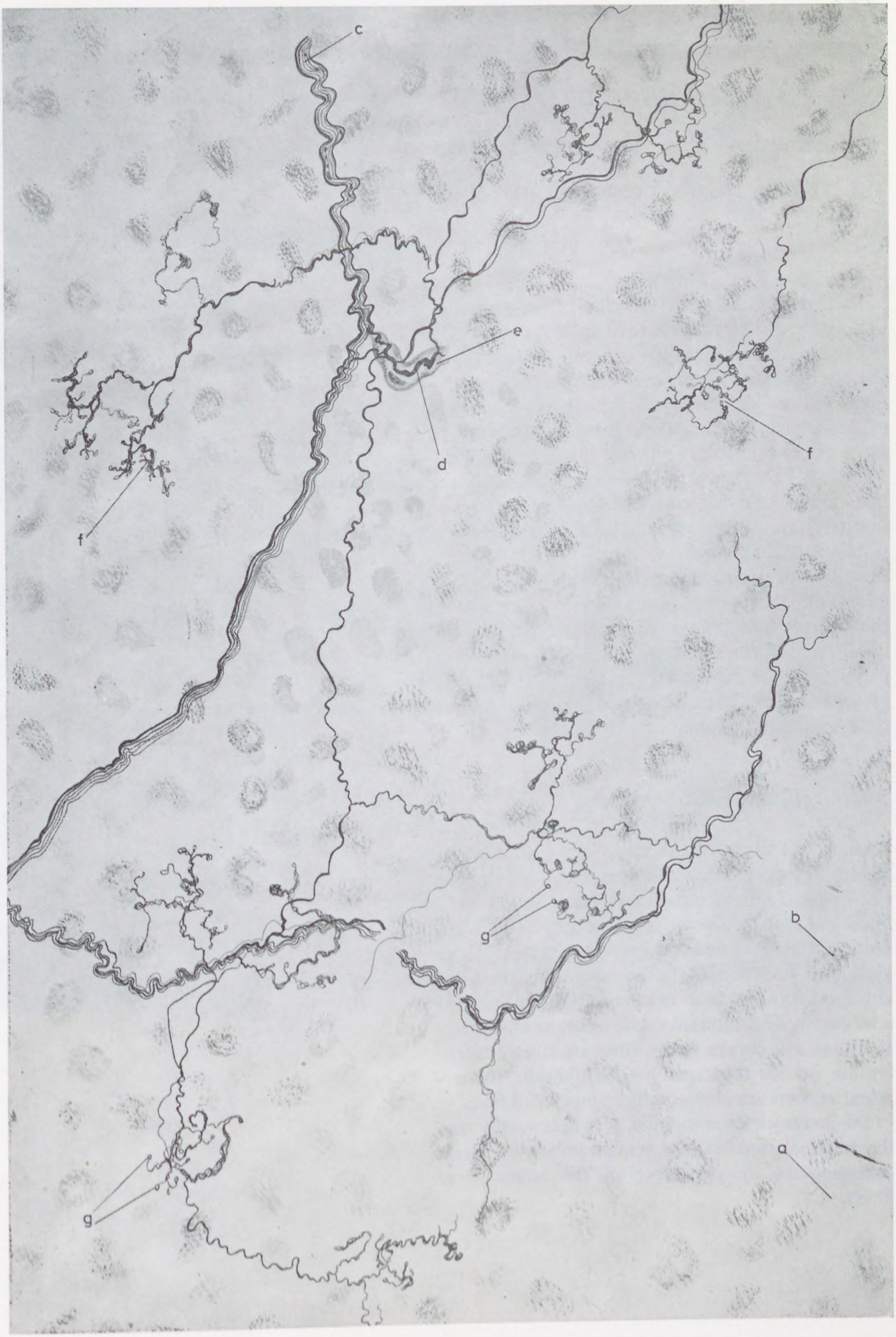
c
e
d
f
f
g
g
b
a

Plate 66

Cat *(Felis domestica)* heart

Bielschowsky–Gros silver impregnation

(Dr. Chabarova's preparation)

Nuclei of connective tissue cells (b), well-impregnated nucleoli and connective tissue fibres of various thickness can be seen in the connective tissue (a) of the epicardium. Two nerve fibres (c) start from the upper left corner. They are covered with thick myelin sheath (d). Here and there, the coarse axon tapers off, while in some other places it becomes strikingly thick (e). This change in thickness is probably related to secondary degeneration (see below). Neurofibrils (f) are clearly seen in the fibres. The thick myelinated fibres gradually taper off and arborize. Simultaneously also the myelin sheath becomes thin and finally disappears. Many end-rings (h) appear in the dense terminal systems (g) either in their original round form or considerably deformed. The majority of the nerve fibres in the epicardium are of vagal origin. Varicosities and neurofibrillar periods can often be found in their course.

Histological comments

The afferent fibres of the vagus nerve are characterized by repeated branchings and terminal systems showing glomerular structures. These can be well impregnated by different silver impregnation techniques; still the terminal structures, however, can be visualized preferentially after vagotomy. The present specimen has been obtained from the heart of a bilaterally vagotomized cat 72 hours after surgery. Incisions and breaks in the fibres are mostly degeneration due to the vagotomy. In addition, the terminal systems are almost fully impregnated because of the increased argentophilia. It is noteworthy that the terminal ramifications remain relatively intact following the disappearance of the larger nerve fibres.

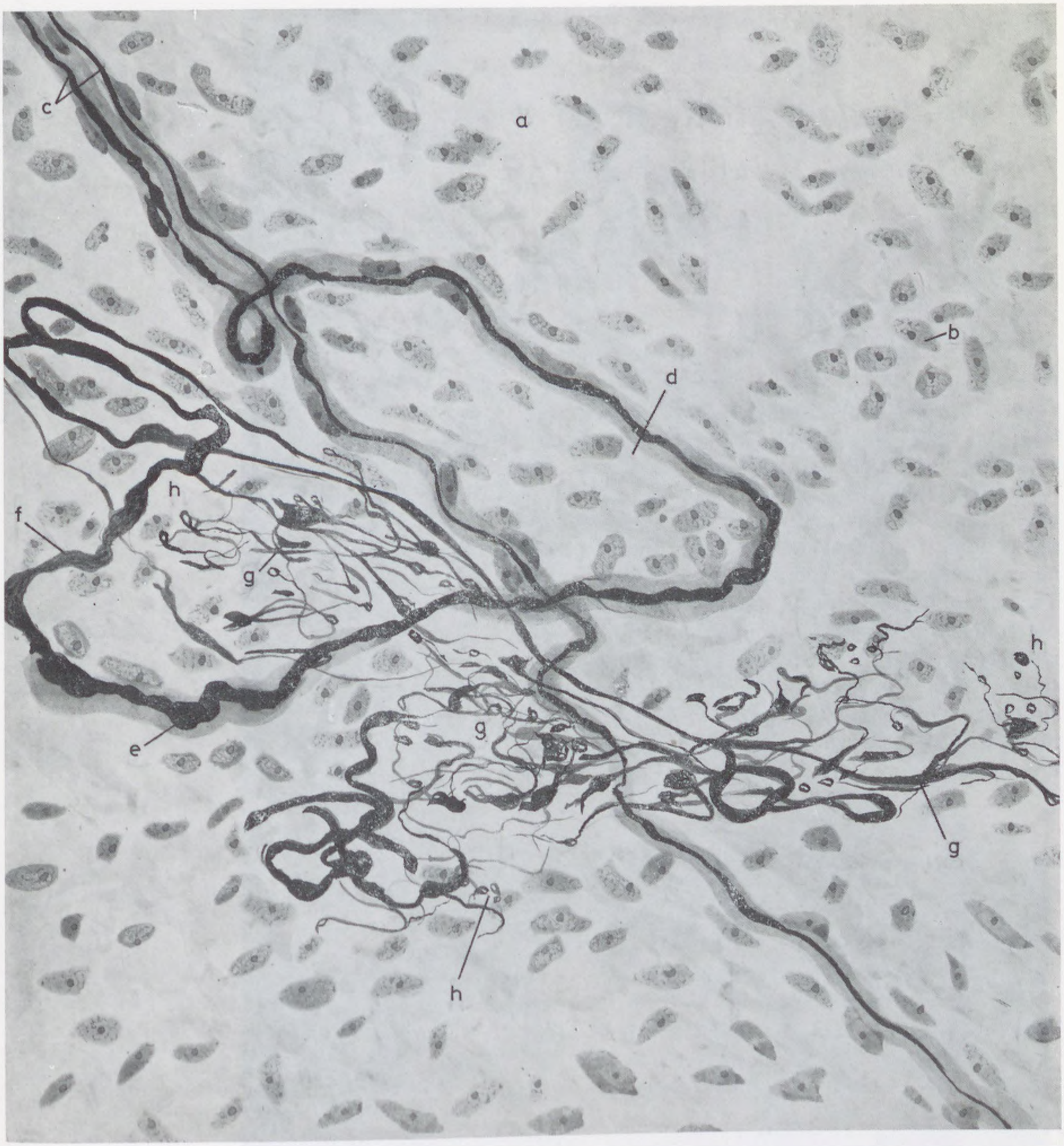
c
a
b
d
h
f
g
h
g
e
g
h

Plate 67

Cat *(Felis domestica)* heart

Photomicrograph. Jabonero's silver impregnation

An elaborate sensory terminal system can be seen in the connective tissue layer of the epicardium. A thick myelinated nerve fibre runs upwards from the lower right corner and disappears in the ground substance of the connective underneath another similarly thick and myelinated nerve fibre. The latter starts at the upper right corner and joins a third thick fibre. (Another interpretation: three thick nerve fibres originate from the same nerve trunk.) The nerve fibres give rise to a conspicuous system of terminal rings to which a complex terminal plexus is attached (centre). The terminal rings differ considerably from one another in size, localization and structure. This photomicrograph was taken from the heart of a cat which underwent bilateral simultaneous vagotomy 168 hours earlier (*see* p. 130).

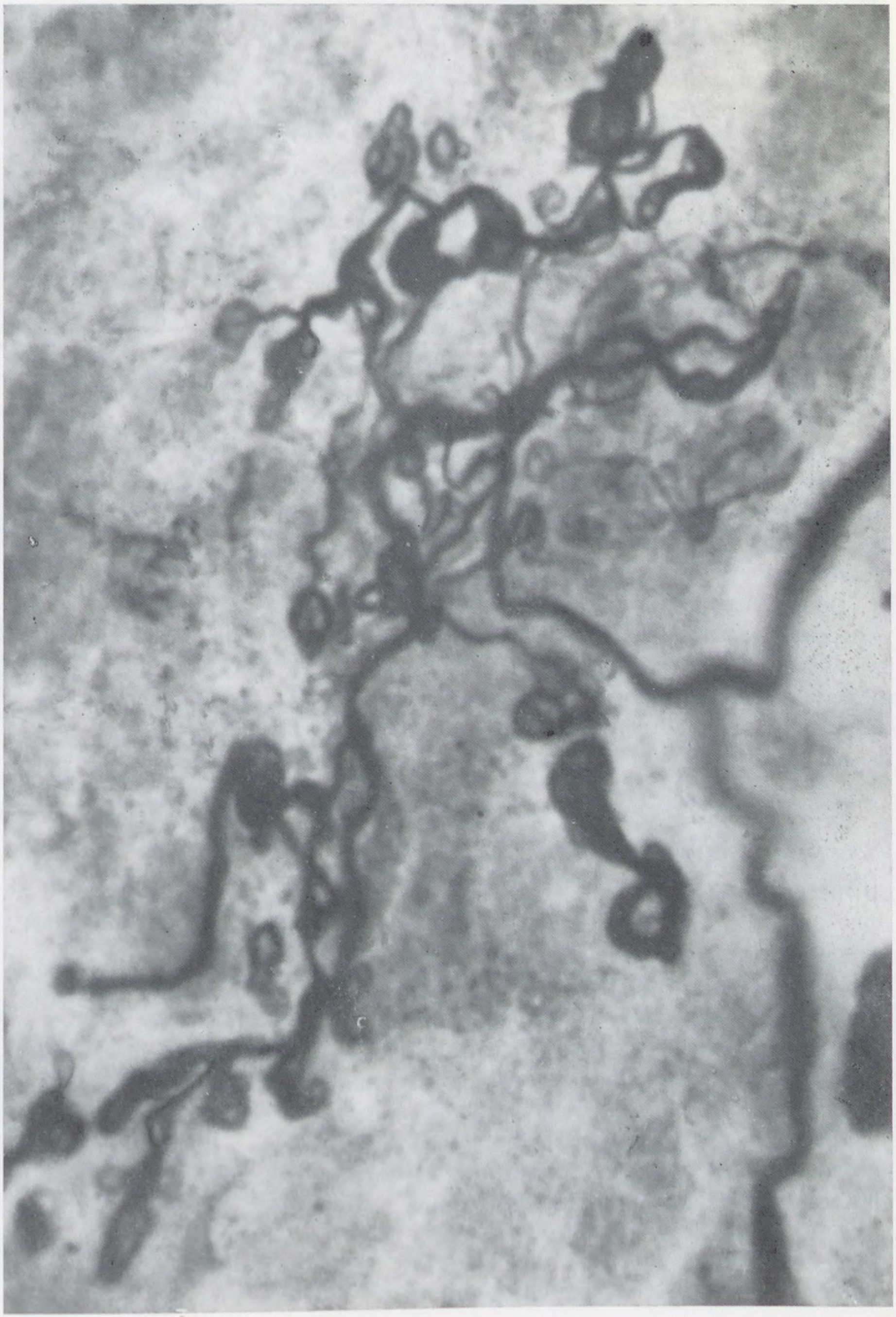

Plate 68

Domestic sheep *(Ovis aries)* heart

Bielschowsky–Ábrahám silver impregnation

Elongated and homogeneously impregnated nuclei of connective tissue cells (b) scattered in the ground substance (a) can be seen in this picture obtained from the epicardium of the right ventricle. Nucleoli remained unstained. A network of coarse nerve fibres (c) appears in the middle portion of the field. Occasional varicosities of considerable size (e) can be found along the fibres. Fine axons (d) with oval varicosities join the plexus of the thick fibres. Fine axons leaving the plexuses terminate in shovel-shaped lamellae (f) among the connective tissue cells and, occasionally, in the immediate vicinity of the nuclei.

Functional neurohistological comments

As seen in the previous plates (and many of our preparations not mentioned in this volume), the nerve plexuses and terminal systems of the epicardium show marked differences in various species. There are also fundamental differences in the innervation of the atria and ventricles, probably reflecting species-specific variations in both the number and sources of nerve fibres innervating the ventricular and atrial myocardium and epicardium.

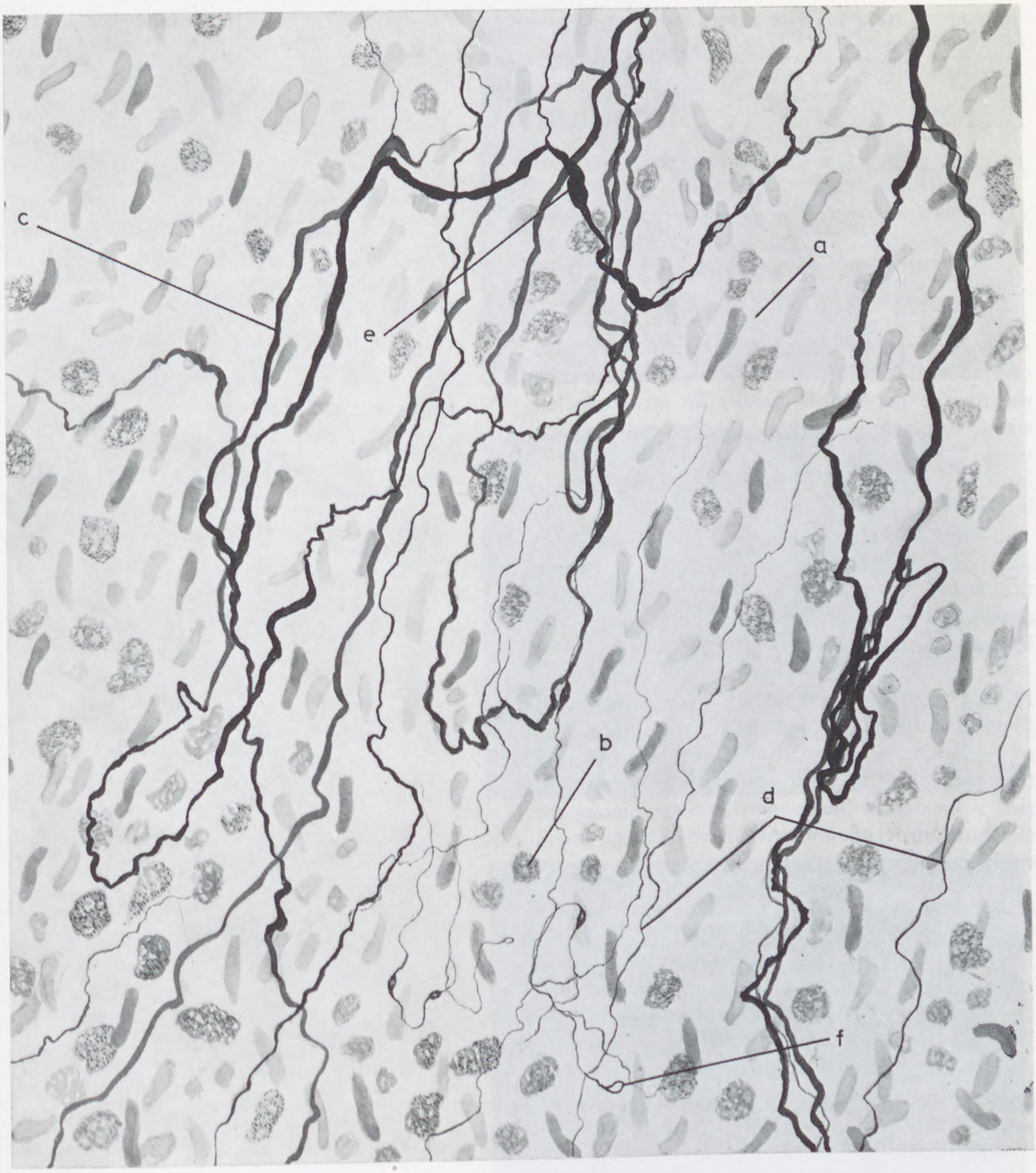
c
e
a
b
d
f

Plate 69

Receptors in the epicardium

Photomicrographs.
Bielschowsky–Gros silver impregnation

1. Cat *(Felis domestica)* epicardium (left) and groups of heart muscle cells (right). Having lost the myelin sheath, the nerve fibre breaks up into branches which terminate in larger or smaller end-ramifications. The terminal swellings are localized mostly in the connective tissue but some of them protrude into the myocardium.

2. Cat *(Felis domestica)* atrial epicardium. Two nerve fibres run from the top of the picture towards the centre. One of them disappears while the other arborizes forming a plexus of fine fibres terminating in ring-like structures.

3. Hog *(Sus scrofa domestica)* atrial epicardium. Fascicles of the muscle cells join the collagenous fibres of the atrial epicardium in the central region of the picture. A plexus of nerve fibres, the variously thickened fibres of which enclose irregular territories, is located in the connective tissue among the elongated nuclei of connective tissue cells and round epithelial cell nuclei.

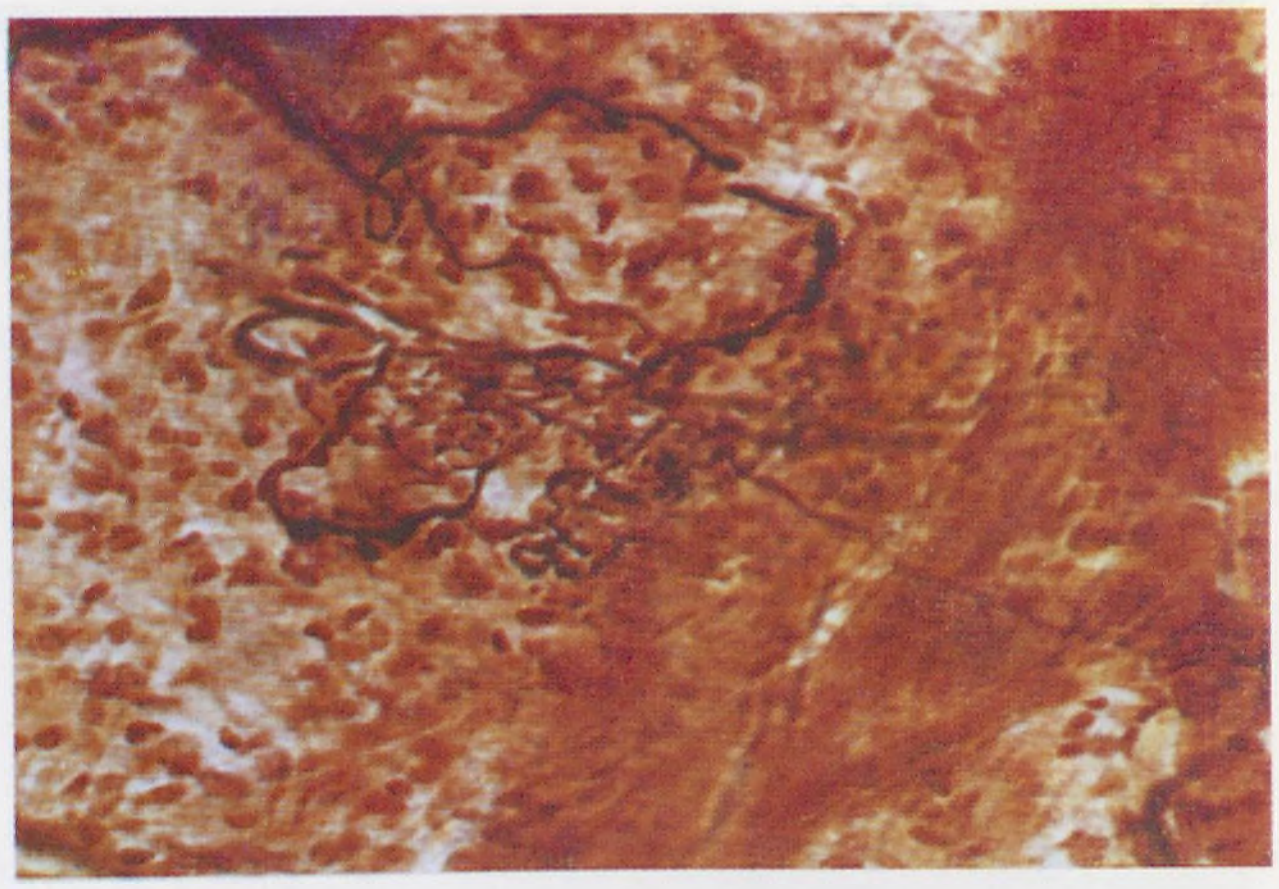

1

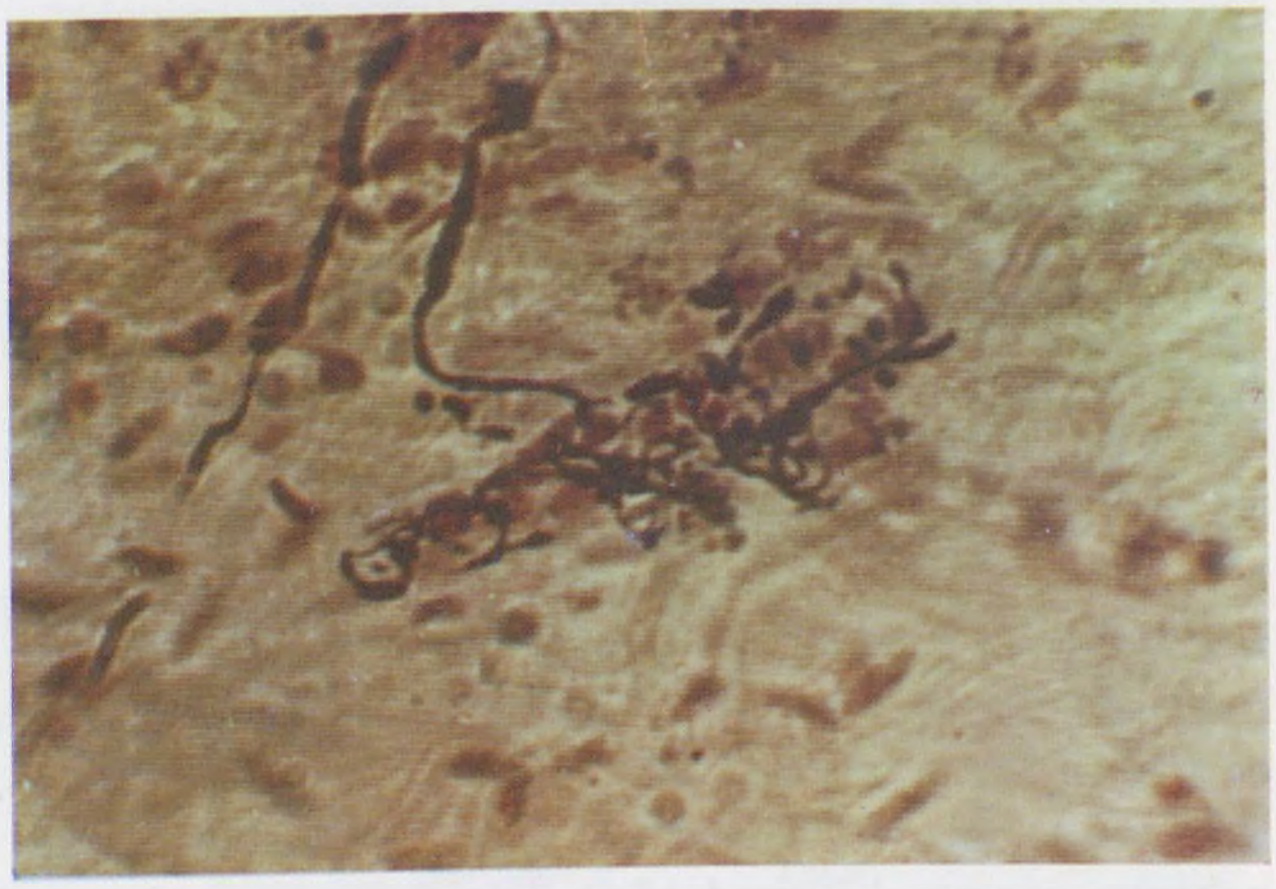

2

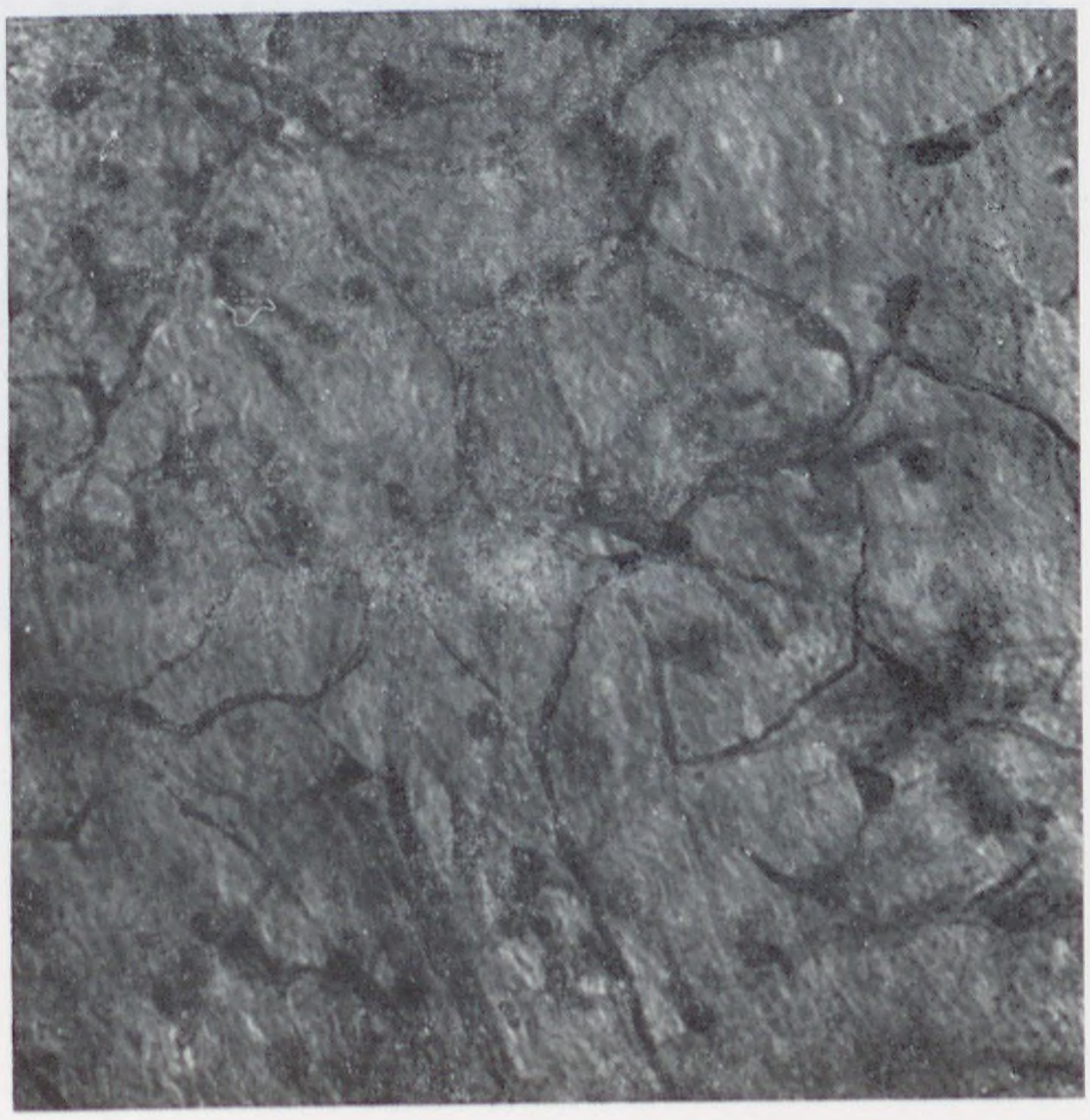

3

Plate 70

Cat *(Felis domestica)* heart

Bielschowsky–Gros silver impregnation

(Dr. Chabarova's preparation)

Part of the superficial layer of the myocardium (a) containing both nuclei and nucleoli (c) of muscle cells, and the epicardium (b) with large polyhedric cell nuclei (d). A thick nerve fibre (e) with typical varicosities (f) starts from the top. The terminal ramifications (g) form elaborate structures (h) containing many terminal rings (i).

Functional neurohistological comments

The myocardium is poor in receptors. Receptor formations suggesting a higher sensitivity can only be revealed in regions adjacent to the epicardium. These formations resemble epicardial receptors both in the course of the fibres and in shape and structure of terminal arborizations (96 hours after bilateral vagotomy, *see* pp. 130 and 134).


b
d
e
h
g
i
i
h
h
a
c
f
d
i
h
d

Plate 71

Cat *(Felis domestica)* heart

Jabonero's silver impregnation

Part of the connective tissue layer (a) can be seen in the atrial septum. A bundle of cardiac muscle cells (d) characterized by striation and muscle cell nuclei (e) can be seen among the connective tissue fibres (b) and the nuclei of connective tissue cells (c). A thick varicose (g) axon (f) originates from the lower right corner. Both branches of the thick fibre show dense terminal arborizations (h) spiralling around the muscle cells. The terminal fibres taper off and bear neurofibrillar end-lamellae (i). This unique sensory structure is probably a pressoreceptor system which perceives changes in the blood pressure on both sides of the septum.

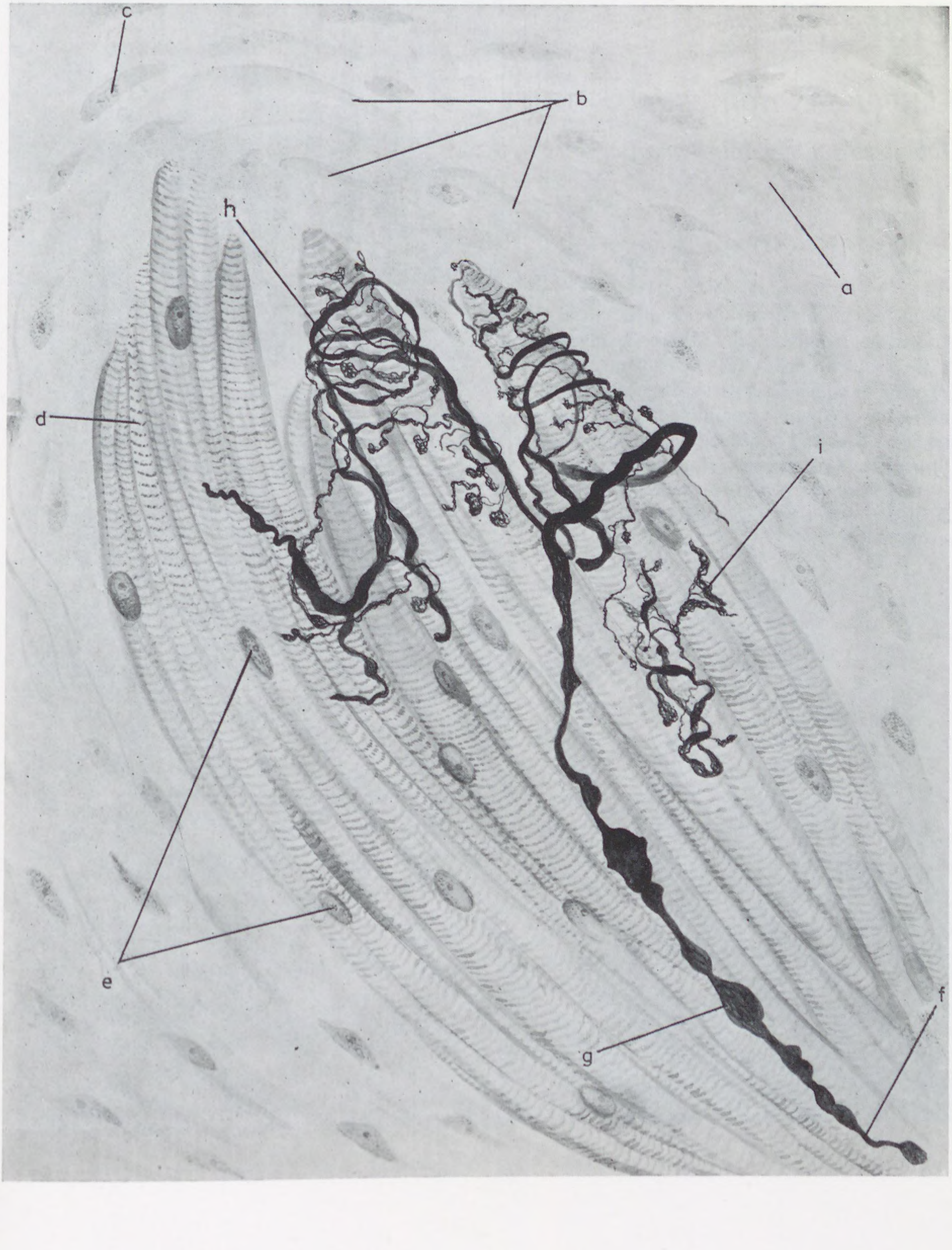
c
b
h
a
d
i
e
g
f

Plate 72

Cat *(Felis domestica)* heart

Jabonero's silver impregnation

Elongated, mostly centrally situated nuclei (b) of striated heart muscle cells (a) in the myocardium of the right atrium. A loose plexus of nerve fibres (c) some of which bear varicosities (d), can be seen on the lower edge of the muscle fascicle. The terminal fibres have end-lamellae (e) in which neurofibrils (f) prevail. This receptor structure might serve as a pressoreceptor system which perceives intracardiac pressure changes during diastole of the atrium.

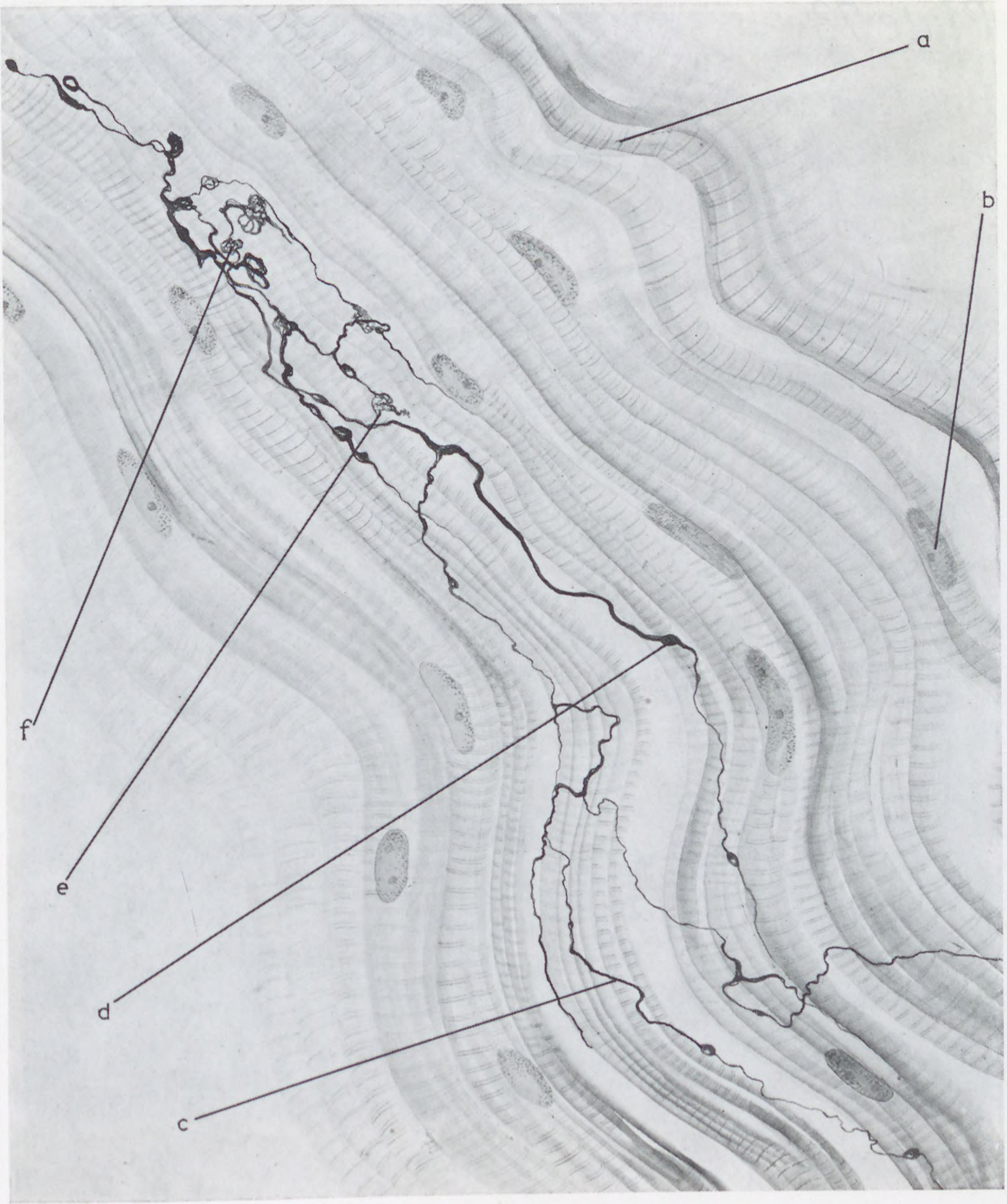
a
b
f
e
d
c

Plate 73

Hog *(Sus scrofa domestica)* heart

Bielschowsky–Ábrahám silver impregnation

Part of the loose connective tissue surrounding the bundle of His. Note connective tissue fibres (a) and nuclei (b) and nucleoli (c) of connective tissue cells. A thick and homogeneously stained varicose nerve fibre (f) surrounded by a plexus of fine fibres (d, e), starts from the upper left corner. Together they form a special and compact fascicle of nerve fibres (g). The sensory end-bulb (h), an enlarged terminal portion of the thick nerve fibre, is found in the lower right corner. It is generally assumed that only the end-bulb is able to perceive the stimuli. Electron microscopic observations have revealed, however, that also the terminal segment of the fibre might be sensitive to stimuli. Consequently, the entire plexus belongs to the pressoreceptor apparatus.

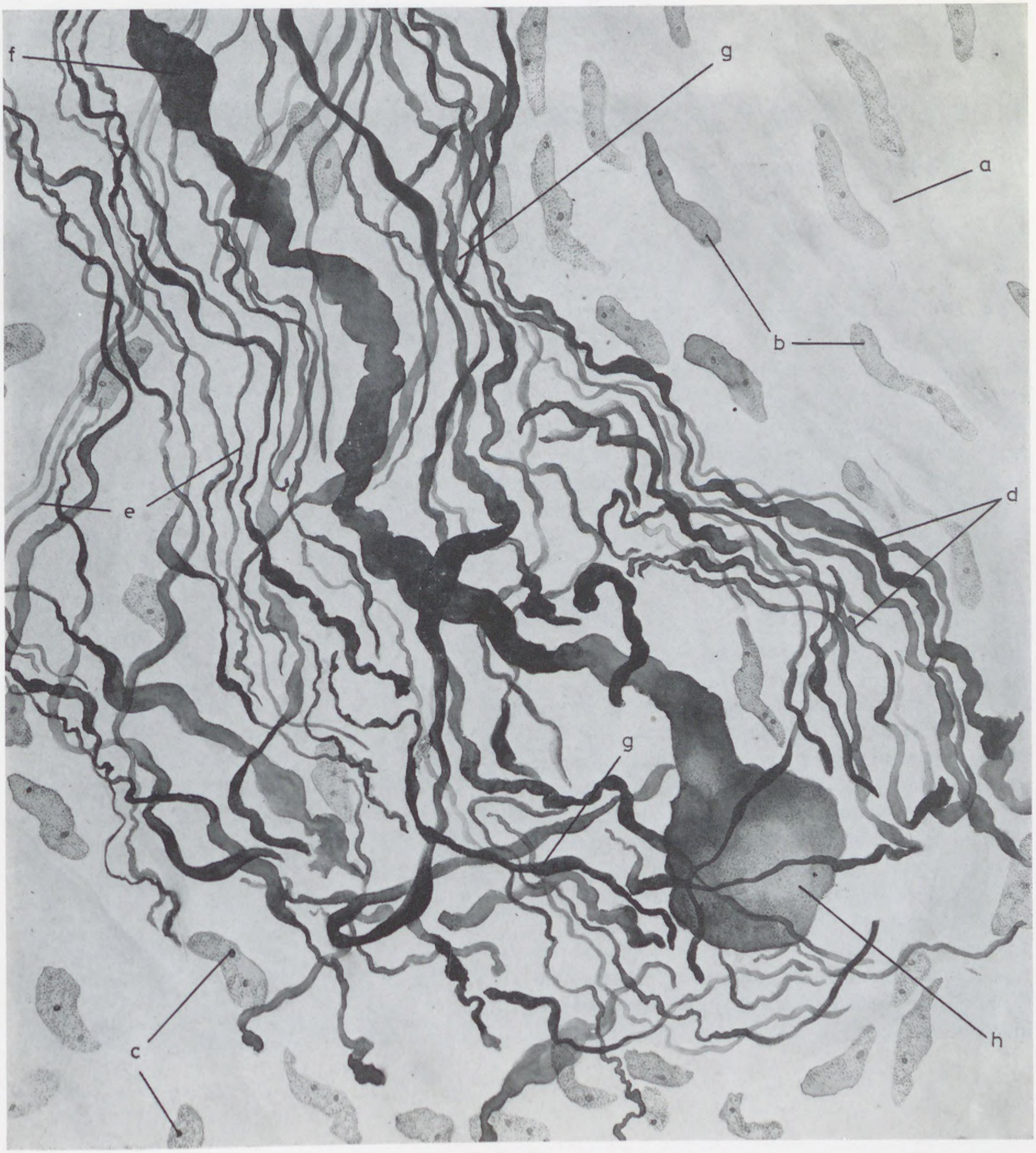
f
g
a
b
b
d
e
e
g
h
c
c

Plate 74

Hog *(Sus scrofa domestica)* heart

Bielschowsky–Ábrahám silver impregnation

Marginal part of the sinus node. A thick fascicle (c) composed of numerous fine nerve fibres traverses the connective tissue (a – nuclei, b – nucleoli). This arrangement is characteristic of sympathetic nerve trunks. The fibres (e) are usually fine and wavy. Coarse fibres (d) occur only occasionally. The latter leave the fascicle and terminate in extensive club-shaped lamellae (f) filled with neurofibrils.

Functional and comparative neurohistological comments

This type of cardiovascular receptor occurs rarely; we have only found it in the heart of the hog. The whole apparatus strongly resembles those observed in the air-bladder of fresh-water bony fish. The analogy can be extended, since receptors and effectors of vagal origin constitute the terminal arborizations of both organs. The functional significance of this type of innervation can, however, be interpreted less easily in the heart. On the basis of its localization and structure, the terminal plexus shown in the picture should be regarded as a sensory system controlling the specialized conducting tissue of the heart.

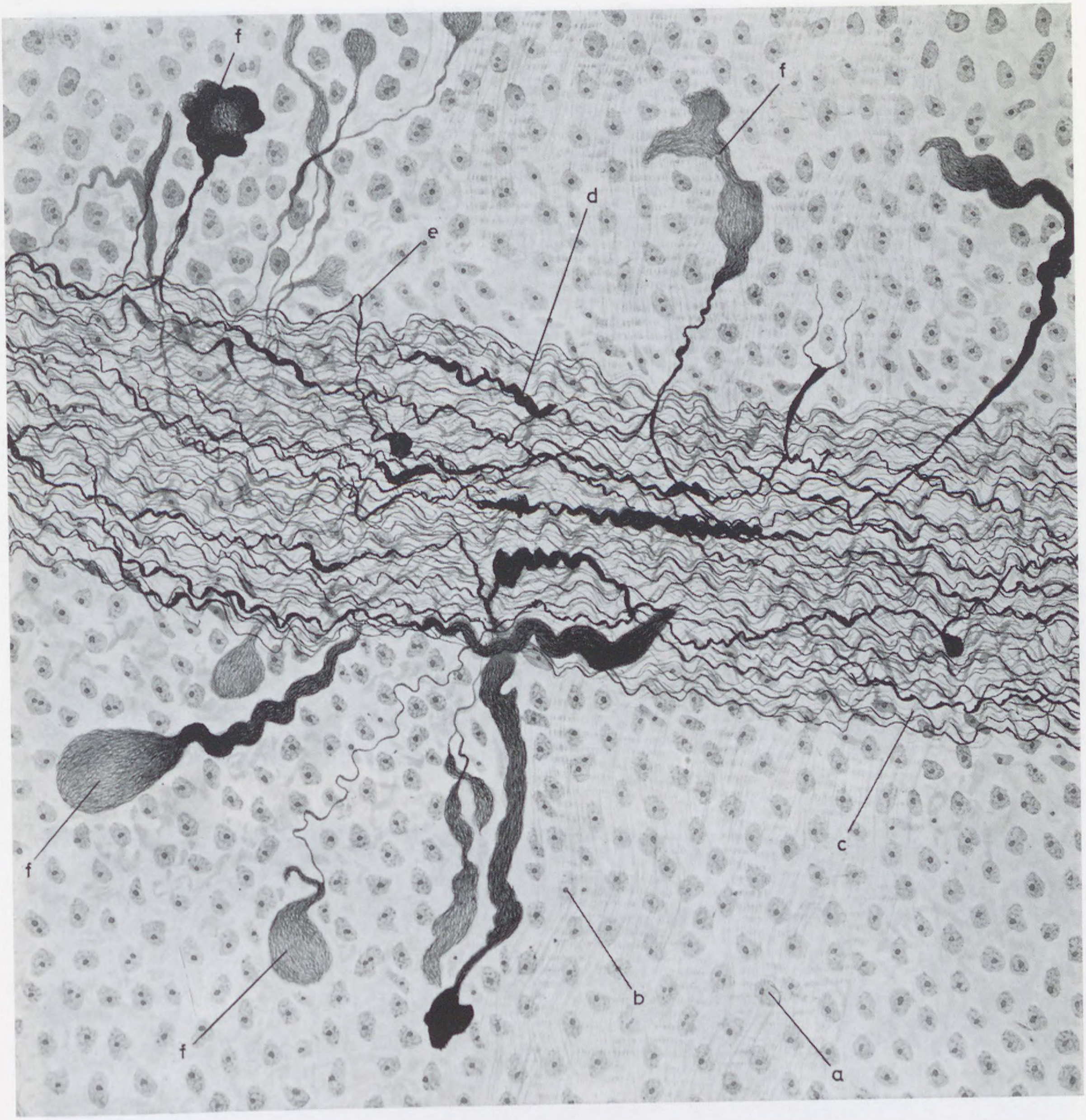
f
f
d
e
f
c
f
b
f
a

Plate 75

Pond tortoise *(Emys orbicularis)* heart

Photomicrographs.
Bielschowsky–Ábrahám silver impregnation

1. Two thick nerve fibres with small varicosities in the connective tissue of the endocardium adjacent to the myocardium. Ring-like nerve endings occur between the two nerve fibres. Some of the endings are contiguous to short segments of nerve fibres. The rings may be regarded as receptors.

2. The same as above with the only difference that also large, round nuclei of endothelial cells are impregnated. Here, too, two nerve fibres traverse the field. In between, various forms of ring-like nerve endings can be seen.

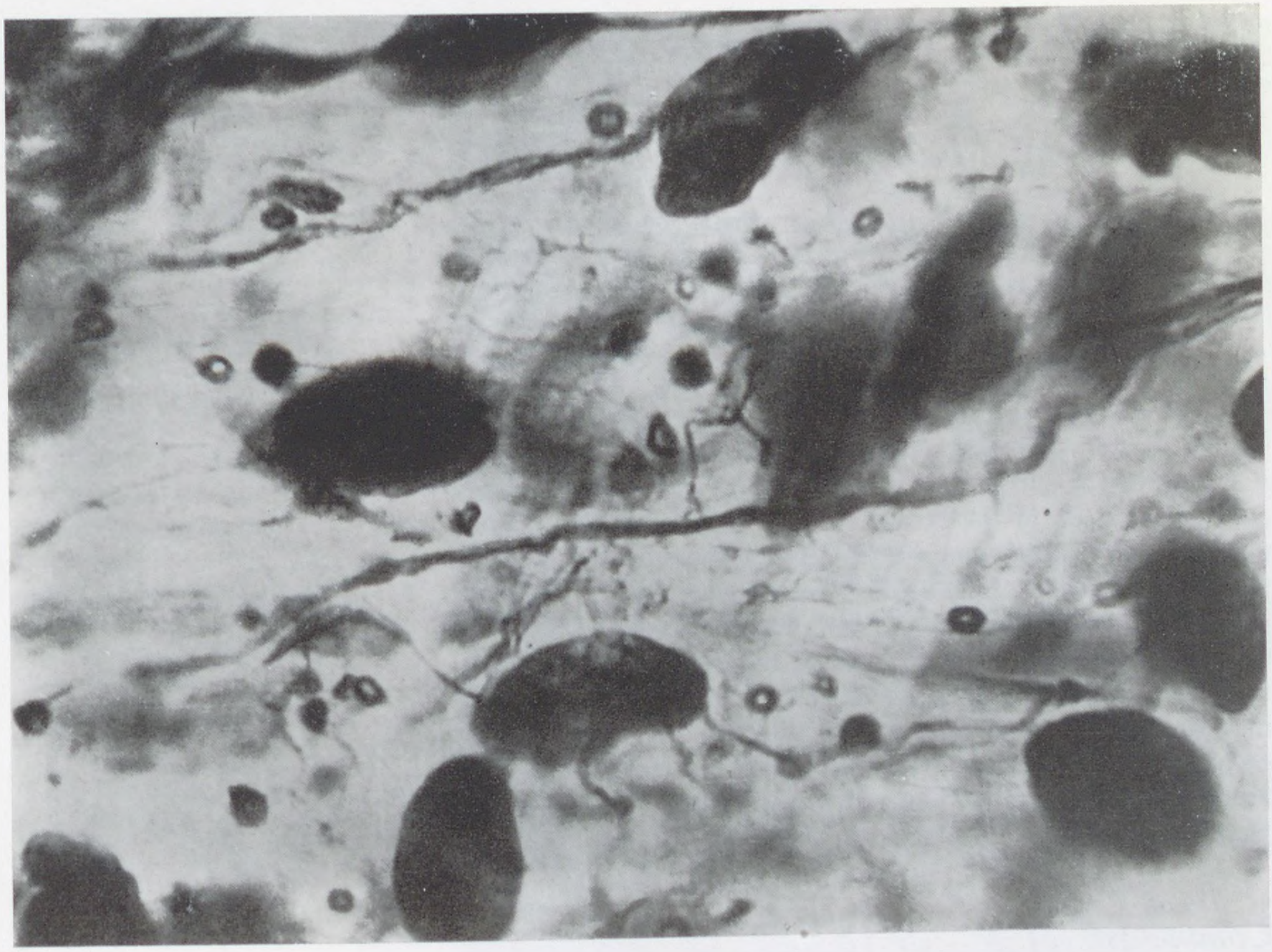

1

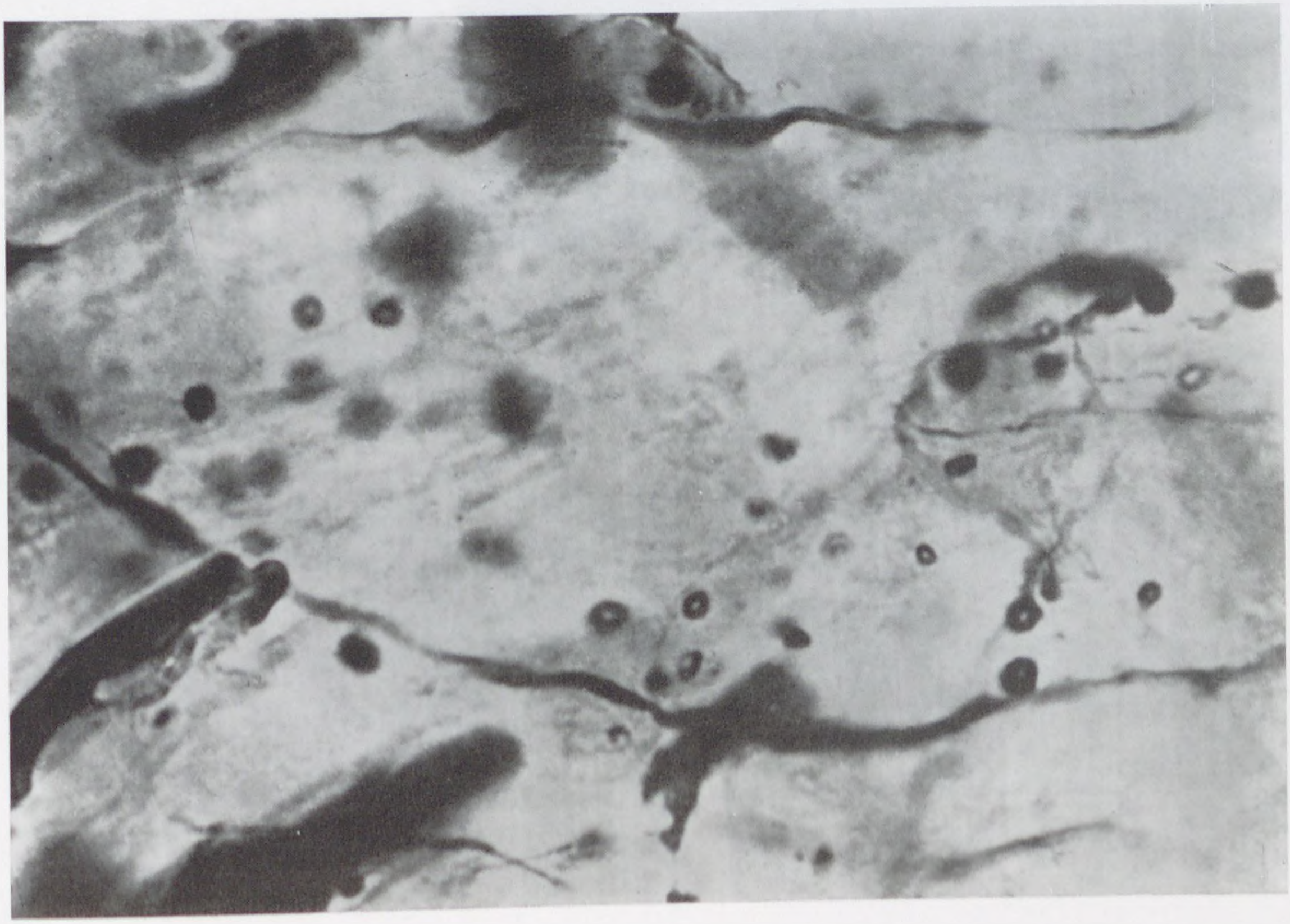

2

Plate 76

Marsh-frog *(Rana ridibunda)* heart

Bielschowsky–Ábrahám silver impregnation

Nuclei of connective tissue cells (a), connective tissue fibres (b) and a thick nerve fibre (c) in the connective tissue of the atrial endocardium. Fine and wavy nerve fibres, some of them just surpassing the resolving power of the light microscope, accompany the thick nerve fibre. Large ring-like nerve endings (d) are located at the end of the fine collaterals of the thick fibre. The ring-like nerve endings which first appear in frogs in phylogeny, develop into a complicated and elaborate receptor system innervating the endocardium and myocardium of mammals.

Comments

The terminal structures shown in this picture are looked upon as receptors because they are localized in a part of the organ devoid of any effector activity. Their functional significance is unknown. Two kinds of function might be envisaged: pressoreception or nociception.

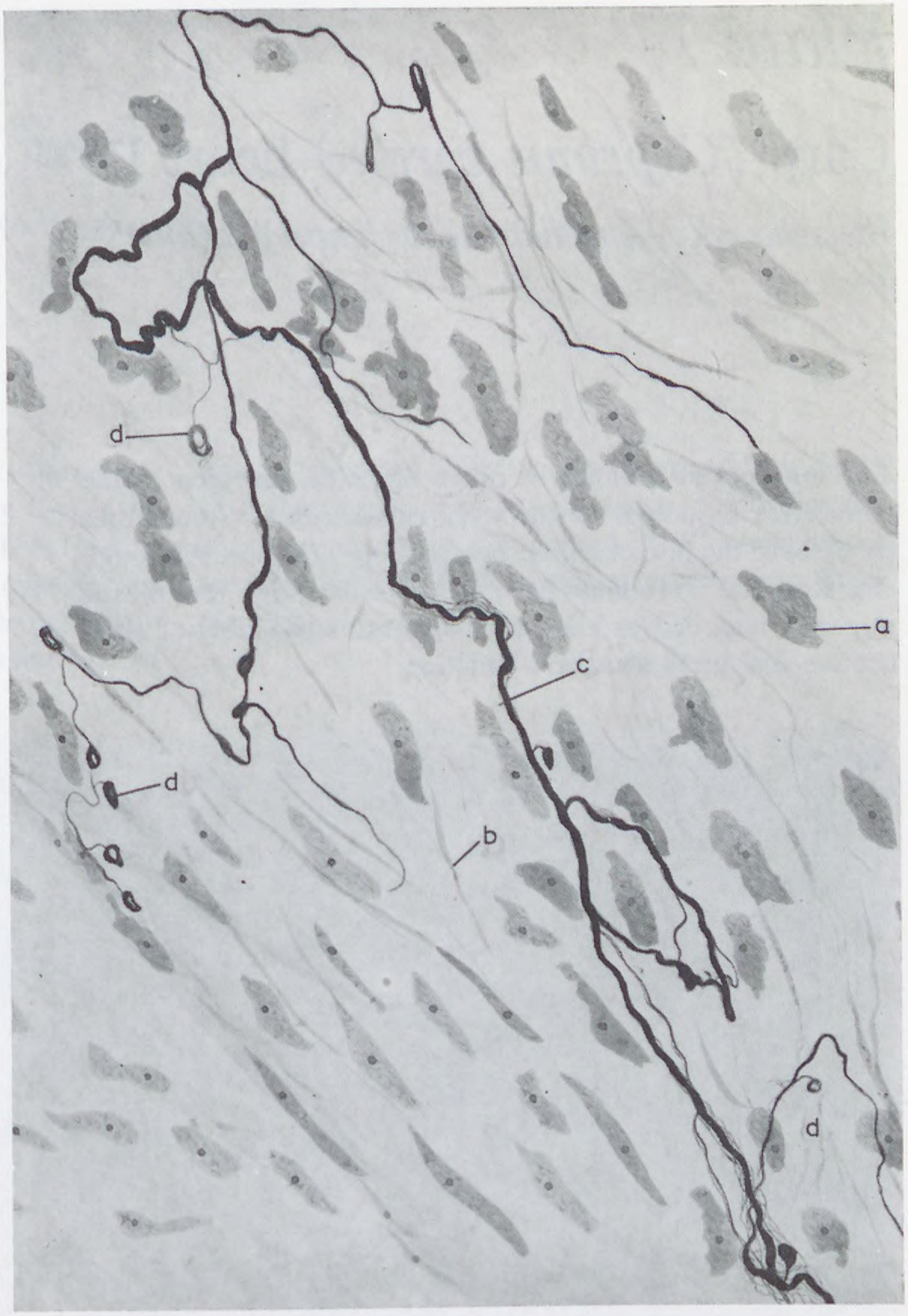
d
d
c
b
a
d

Plate 77

Carp *(Cyprinus carpio)* heart

Bielschowsky–Ábrahám silver impregnation

Two interlocked bundles of nerve fibres (a) are seen in the connective tissue (d) of the atrial endocardium. Some fibres (b, c) leave the fascicles and form a loose network. Although characteristic terminal structures are lacking, the plexus might be regarded as a receptor apparatus probably of nociceptive and pressoreceptive function.

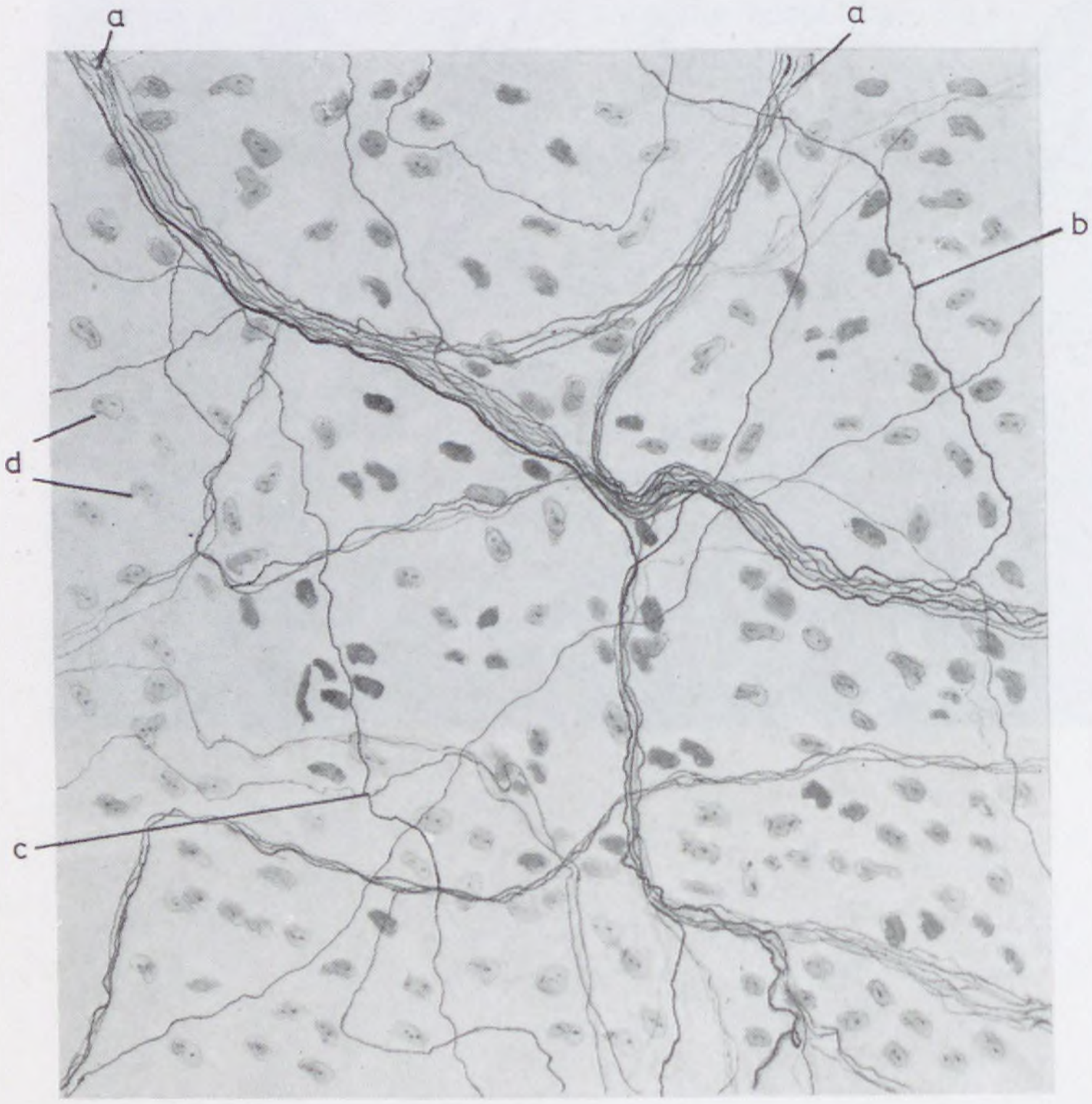

Plate 78

Cat *(Felis domestica)* heart

Bielschowsky–Gros–Cauna silver impregnation

In the endocardium of the right atrium a large terminal glomerulus is seen, surrounded by concentrically arranged rough connective tissue fibres (b) and nuclei of connective tissue cells (c) in a capsule-like form (a). The thick axon (d) shows the characteristic features of depressor fibres. The glomerular system arising from this fibre consists of meandering fibres of uniform thickness bearing large varicosities (e). The central part of the glomerulus (f) contains the terminal ramifications which end in ring-like structures (g).

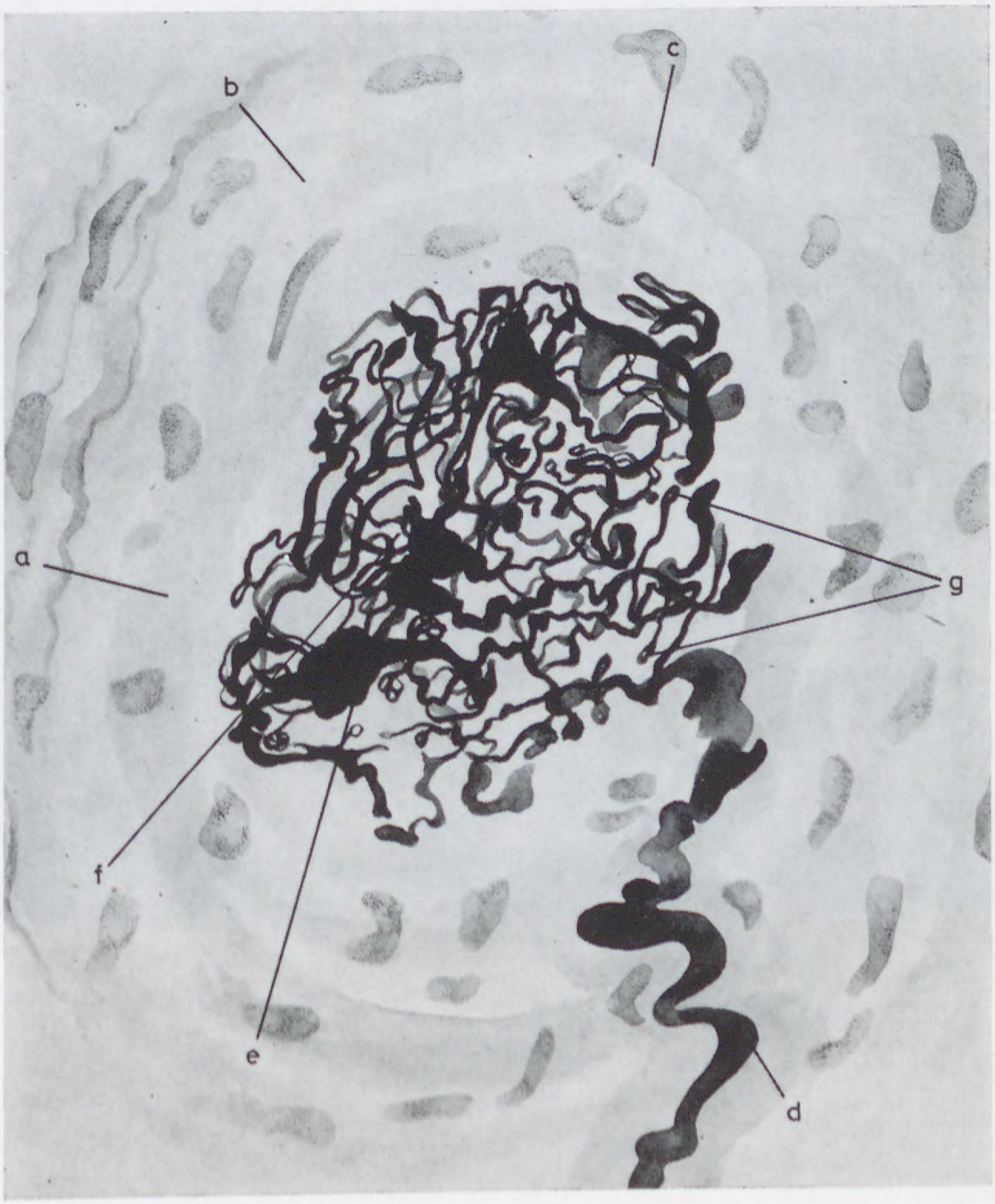

Plate 79

Cat *(Felis domestica)* heart

Bielschowsky–Gros–Cauna silver impregnation

Endocardial connective tissue (a), nuclei of connective tissue cells (b) and fascicles of muscle cells (c) in the endocardium of the right heart. Elongated nuclei (d) characteristic of cardiac muscle cells can also be seen. The thick varicose nerve fibres (e) constitute a special form of depressor fibres in that spiny processes separated from one another by deep incisions, originate from the axon. Grape-like lamellar terminal arborizations (f) of five nerve fibres are shown. Neurofibrils prevail in the lamellae.

Comments

Among the three main layers of the cardiac wall the endocardium is the richest in receptors. It mostly contains free arborizations and loose coil systems of sensory fibres. Both kinds of terminal structures prevail in slides obtained from cats after vagotomy, like this one (72 hours after transection of the right vagus nerve).

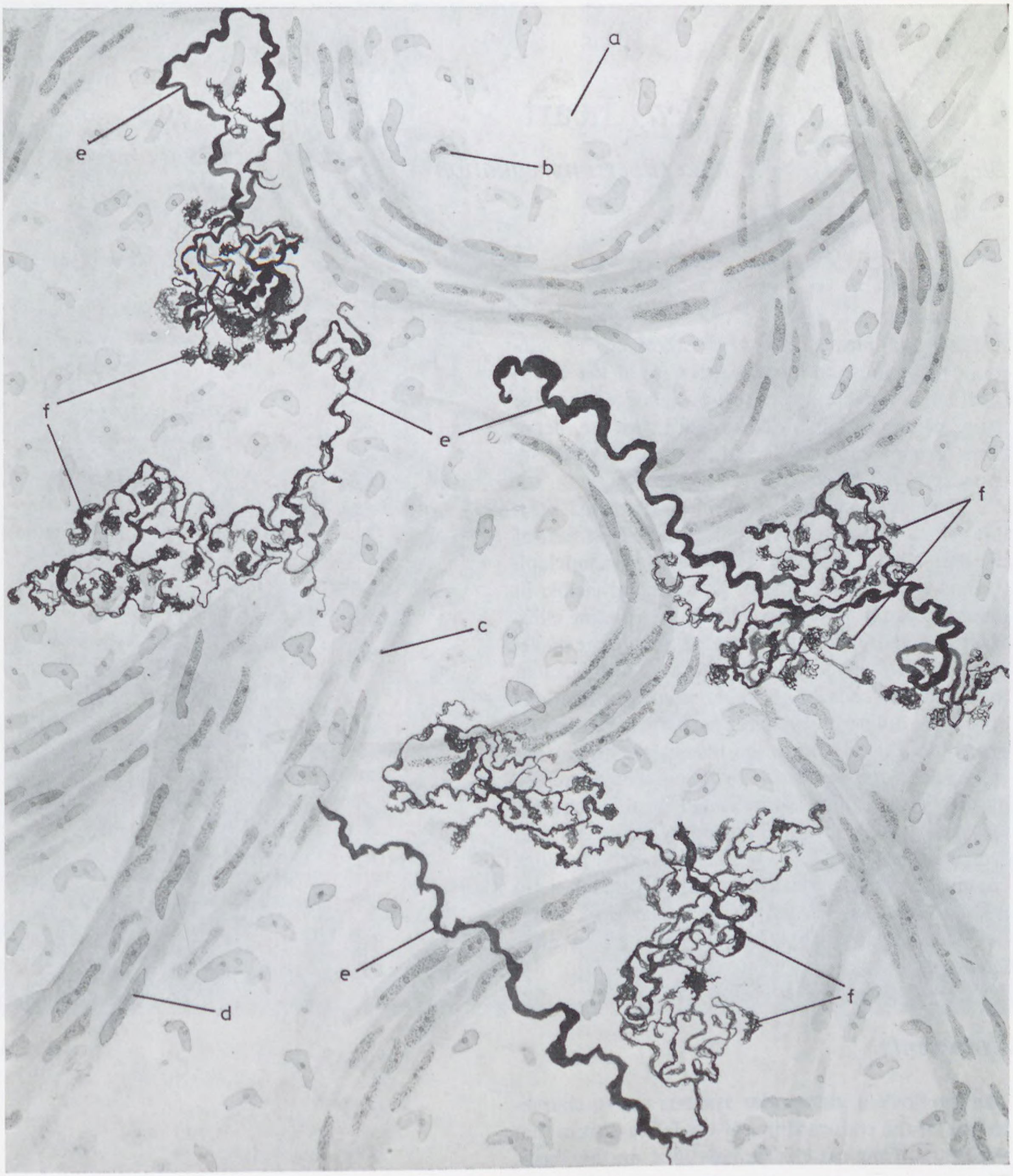
a
b
e
f
e
e
f
c
e
d
f

Plate 80

Cat *(Felis domestica)* heart

Bielschowsky–Gros–Cauna silver impregnation

1. Elaborate plexus of nerve fibres (c, e) surrounded by loose connective tissue (a) in the endocardium of the left atrium (b – nuclei of connective tissue cells). The fine, occasionally varicose, nerve fibres terminate in ring-like structures or in optically dense terminal knobs (d).

2. Two terminal arborizations interlocked by a thick fibre in the endocardium of the left atrium of the cat. Nuclei of connective tissue cells, nucleoli (b) and very fine chromatin granules are visible in the endocardial connective tissue (a). Larger elliptic or polyhedric nuclei are located among the nuclei of connective tissue cells, which are the nuclei of the epithelial cells (c). The terminal arborizations arise from abundant branchings of thick myelinated axons (d). In addition to the myelin sheath (e) nuclei of Schwann's cells are also seen. The depressor nature of these fibres is indicated by their characteristic knot-like thickenings, spiny processes and typical varicosities (f). The terminal arborizations contain glomeruli, plexuses, terminal branches (g) and terminal lamellae (h) rich in neurofibrils. Ring-like structures (i) appear in large numbers after vagotomy.

Comments

The interlocked glomerular systems are so characteristic of the endocardium of the feline atrium that the heart of the cat can be identified on this basis. These receptor systems are present not only in the right atrium, but they can also be frequently found in the endocardium of the left atrium.

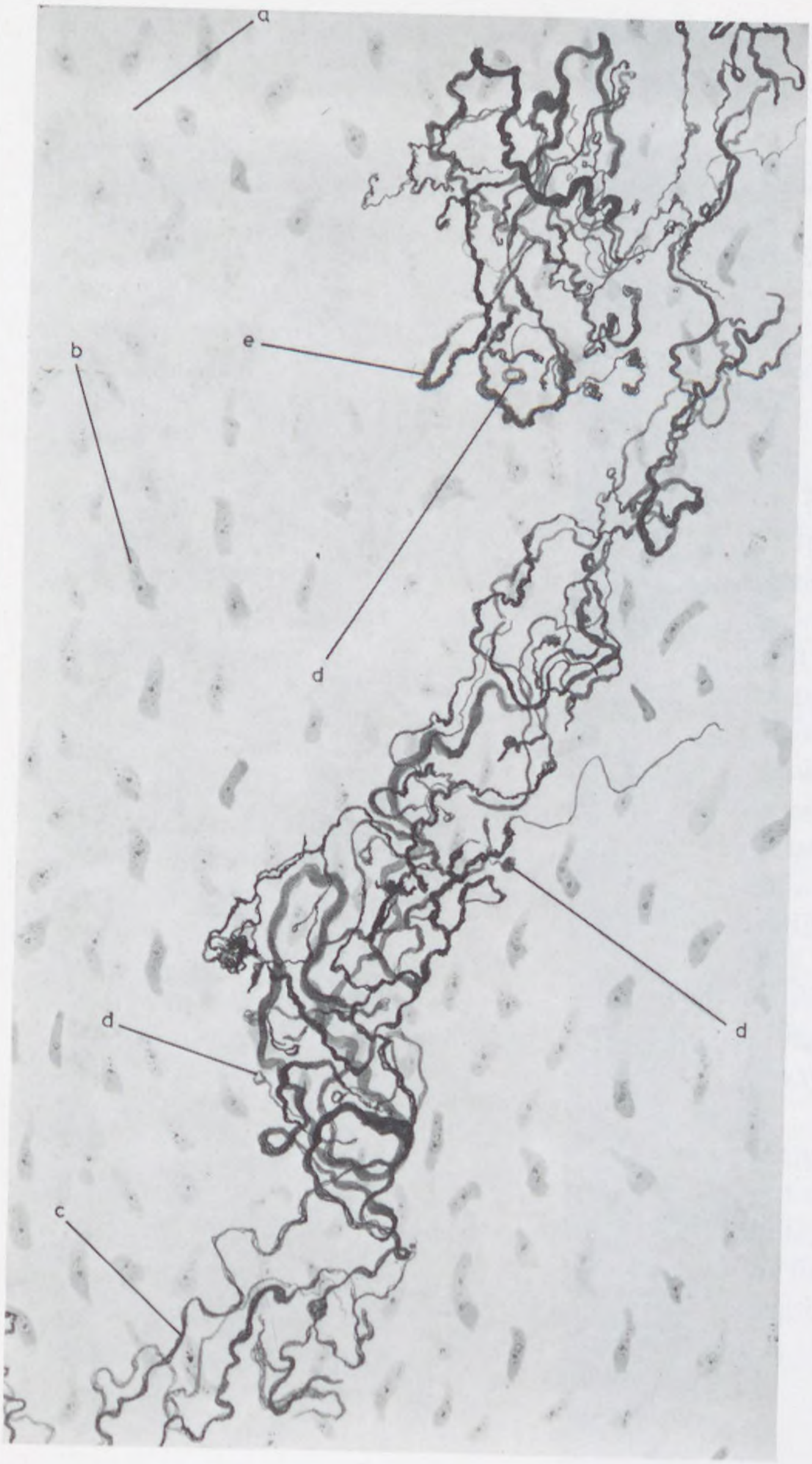

1

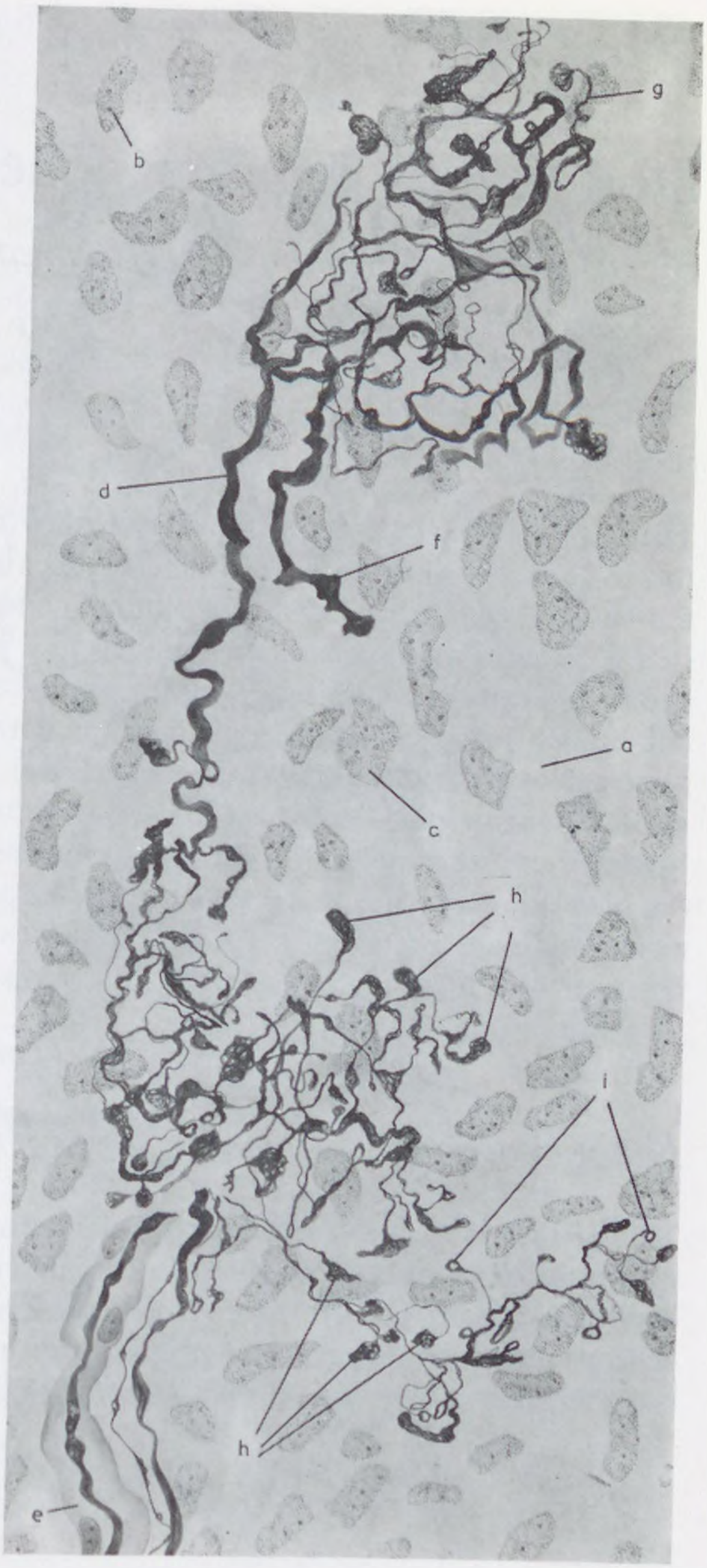

2

Plate 81

Dog *(Canis familiaris)* heart

Bielschowsky–Ábrahám silver impregnation

The terminal system (b) of a thick nerve fibre (a) in the endocardium of the left atrium. In the centre the nerve fibre bifurcates; the right branch ends up in a large neurofibrillar lamella attached to a polyhedric end-lamella. After repeated ramifications the left branch forms an inextricable terminal network attached to the endocardial connective tissue with variously structured end-lamellae. The terminal branches end as lamellar (e) or ring-like expansions (f). Neurofibrils (c) are well visible both in the coarser and the finer branches. Collateral branches and terminal structures are connected to the main fibre by thin portions (d).

Functional neurohistological comments

This picture illustrates the most complicated sensory system of vagal origin, which can be found in the wall of the heart. The presence of these complicated sensory structures suggest that the sensory unit in the vagus nerve have specialized sensory functions.


f
e
b
c
f
e
a
d
b
e

Plate 82

Cattle *(Bos taurus)* heart

Bielschowsky–Ábrahám silver impregnation

Nuclei of connective tissue cells (b) scattered in the connective tissue layer (a) of the endocardium of the right atrium. Also the myocardium can be seen on the right. A thick sensory nerve fibre (f) gives rise to a large and elaborate terminal system. The main axon shows varicosities (e, c); the myelin sheath is uneven (d). The first and higher order branches (f, g) including the terminal ramification (h) are clearly visible. The terminal branches end in neurofibrillar end-lamellae (i).

Comments

This picture illustrates the delicate structure of the terminal arborization of a sensory nerve fibre. While in invertebrates and lower vertebrates the sensory fibres have only a few or no terminal branches, in higher mammals they have a high number of collaterals and terminal structures which are necessary for their complicated function.

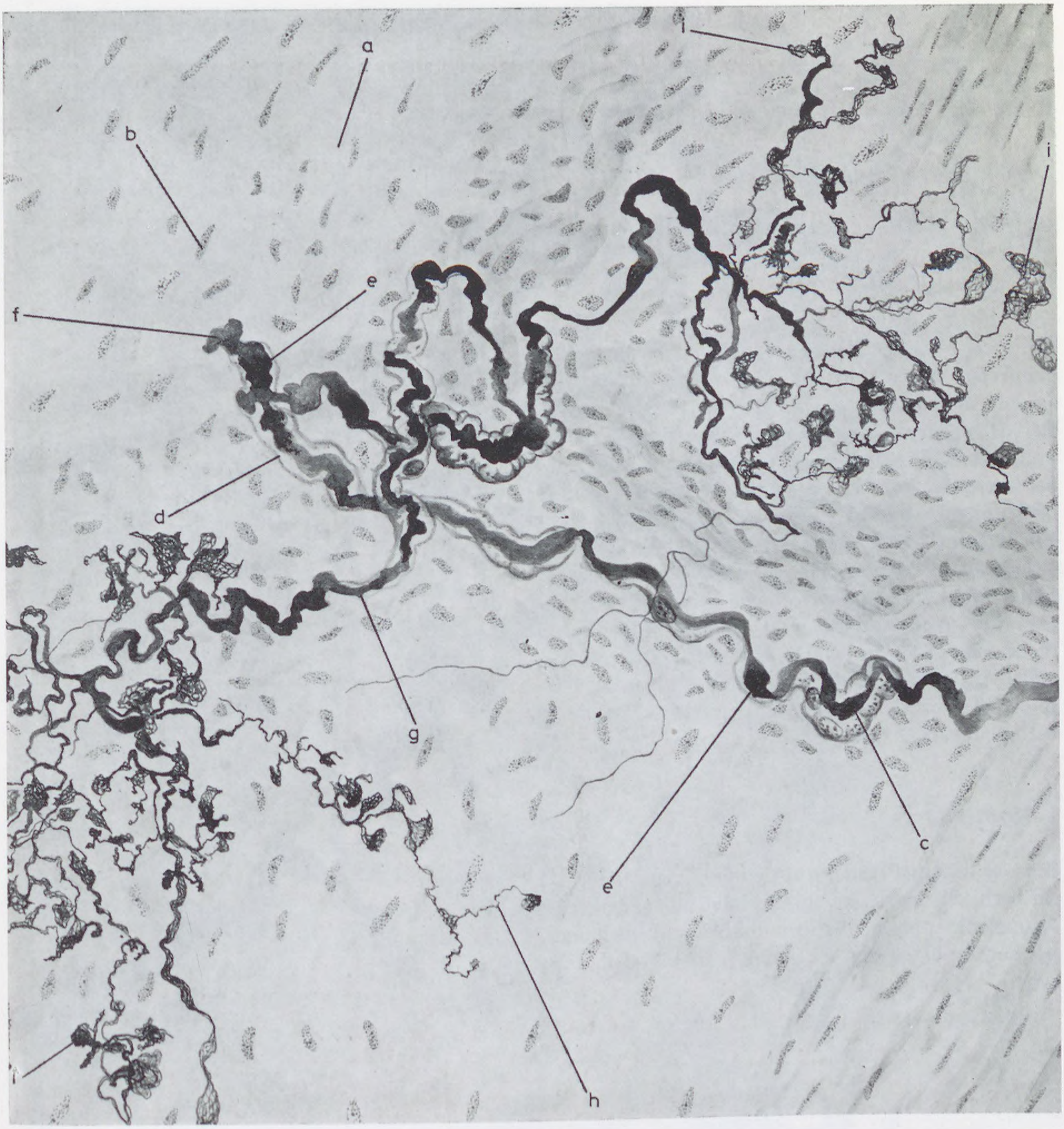
i
a
b
i
e
f
d
g
e
c
h
i

Plate 83

Cattle *(Bos taurus)* heart

Bielschowsky–Ábrahám silver impregnation

Connective tissue (a), irregular and pale nuclei of connective tissue cells (b), and a thin fascicle of smooth muscle cells (c) with narrow, elongated nuclei (d) in the endocardium of the left atrium. A thick nerve fibre (e) showing all the typical features of baroreceptor fibres enters at the lower left margin of the picture, the axon (e) is highly varicose. Myelin sheath (f), neurilemma and Schwann's cell nuclei (g) surround the varicous axon. A system of terminal branches arising from the thick nerve fibre and the lamellae of terminal arborization add to the sensitivity of the wall of the heart. The end-lamellae (j) and especially their enlarged portions, the so-called intercalated lamellae (i) are densely packed with neurofibrils (h).

Comments

Sensory terminal systems of the bovine atrial endocardium can easily be impregnated. The nervous system may play a role in monitoring atrial blood pressure and register the amount of blood in the atria.

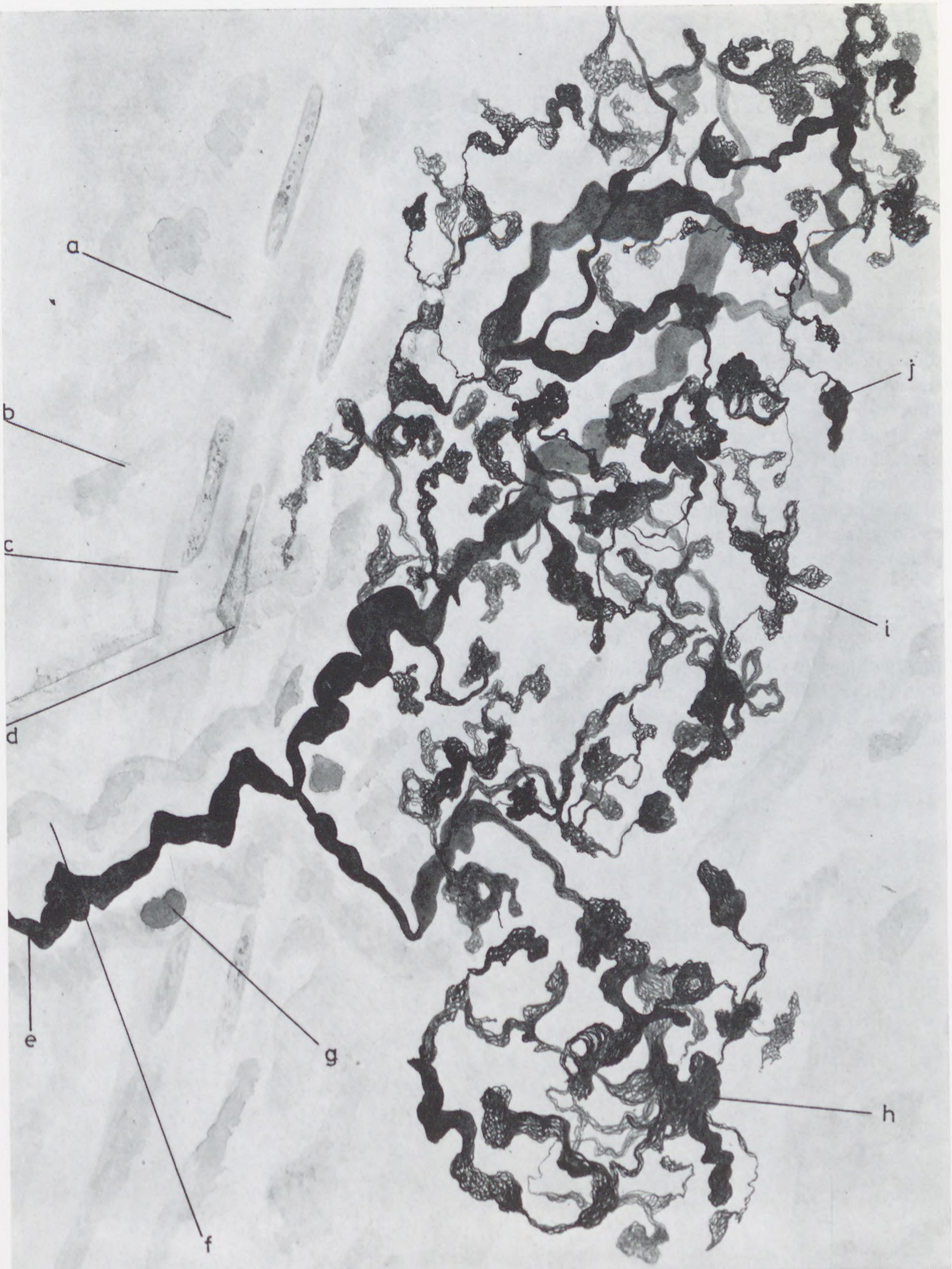
a
b
c
d
e
f
g
h
i
j

Plate 84

Cattle *(Bos taurus)* heart

Bielschowsky–Ábrahám silver impregnation

A peculiar and abundant terminal ramification system of a nerve fibre in the right atrial endocardium. In the loose connective tissue, wavy connective tissue fascicles are dimly seen. A thick nerve fibre (a) entering at the lower left corner runs upwards and bears a large varicosity (b) filled with neurofibrils (c). Enlarged intercalated lamellae (d) can frequently be found along the course of the fibres. The terminal ramifications bear numerous end-lamellae hiding the ground tissue almost completely.

Comments

Innervation of the bovine endocardium is similar to that of the buffalo and the goat. The differences, however, are so evident that the species can be distinguished without difficulty.

c
b
d
a

Plate 85

Cattle *(Bos taurus)* heart

Bielschowsky–Ábrahám silver impregnation

Nuclei (a) and nucleoli (b) of connective tissue cells can be seen in the endocardium of the left atrium. Some smooth muscle cells (c) are on the right side of the picture. The polyhedric or spherical nuclei (d) among the connective tissue and smooth muscle elements belong to epithelial cells. A thick nerve fibre (e) starting from the lower left corner breaks up into two branches (f). The thicker left branch shows the typical features of depressor fibres. It gives rise to collaterals and terminal fibres (h) bearing end-lamellae (i). The end-lamellae varying in shape and size are filled with neurofibrils (j).

Comments

This organization somewhat differs from other sensory systems described in the bovine atrial endocardium previously. Even so, it is considered typical for the heart of the cattle.

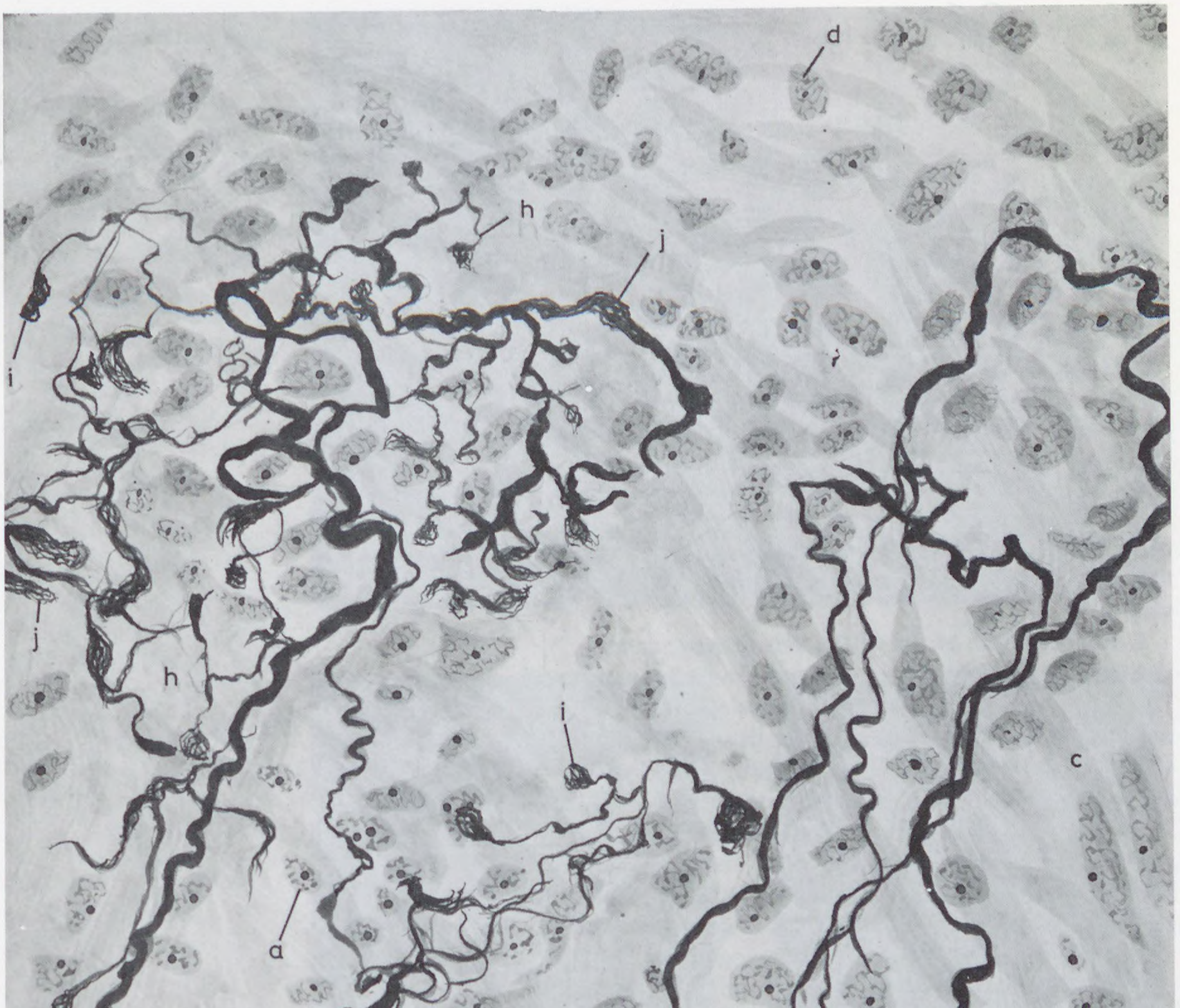
d
h
j
i
j
h
i
c
a
f
i
b
d
f
e
a

Plate 86

Receptor systems in the endocardium

Coloured photomicrographs

1. Atrial endocardium of the cattle *(Bos taurus)* impregnated according to Bielschowsky and Ábrahám. A loose glomerular system formed by the terminal ramification of a thick depressor fibre can be seen among the connective tissue fascicles, nuclei of connective tissue cells and capillaries. Fine terminal fibres and densely impregnated end-lamellae are well visible.

2. Endocardium of the cattle *(Bos taurus)*; silver impregnation according to Jabonero's technique. Dimly outlined connective tissue fascicles and variously shaped nuclei of connective tissue cells, as well as endothelial nuclei can be seen. Two thick and wavy nerve fibres appear on the right side. Above them a nerve fibre approaches the terminal ramification of another thick fibre. The terminal fibres form a very fine and extensive lamellar end-system with polyhedral or triangular lamellae.

3. Right atrial endocardium of the dog *(Canis familiaris)*; Bielschowsky–Gros silver impregnation method. On the left, endocardium with numerous elastic fibres. A thick nerve fibre passes through the connective tissue and ramifies in the endocardium close to the lumen. Its wavy course is a characteristic feature of sensory fibres. Terminal branches of the axon form a loose glomerulus.

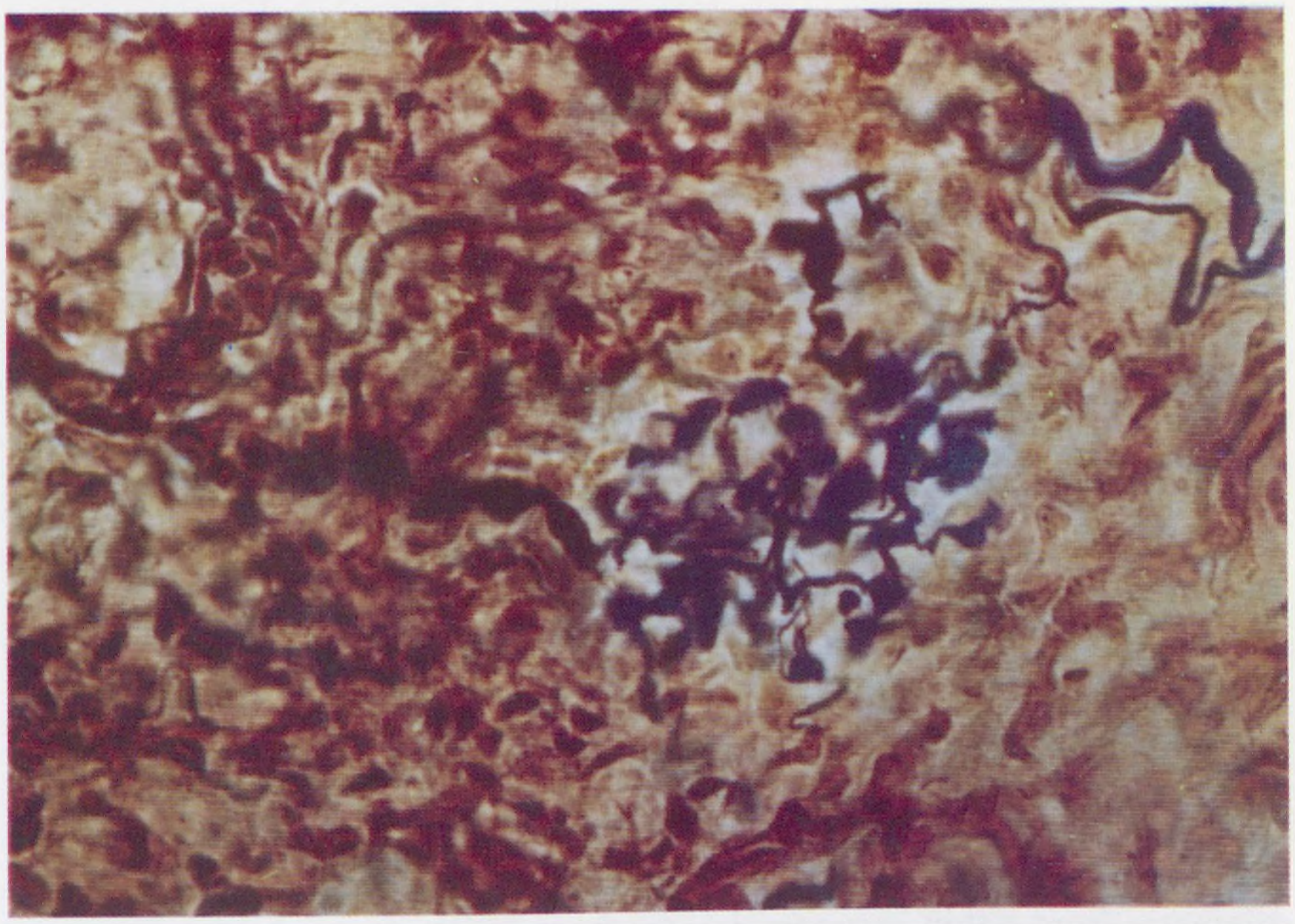

1

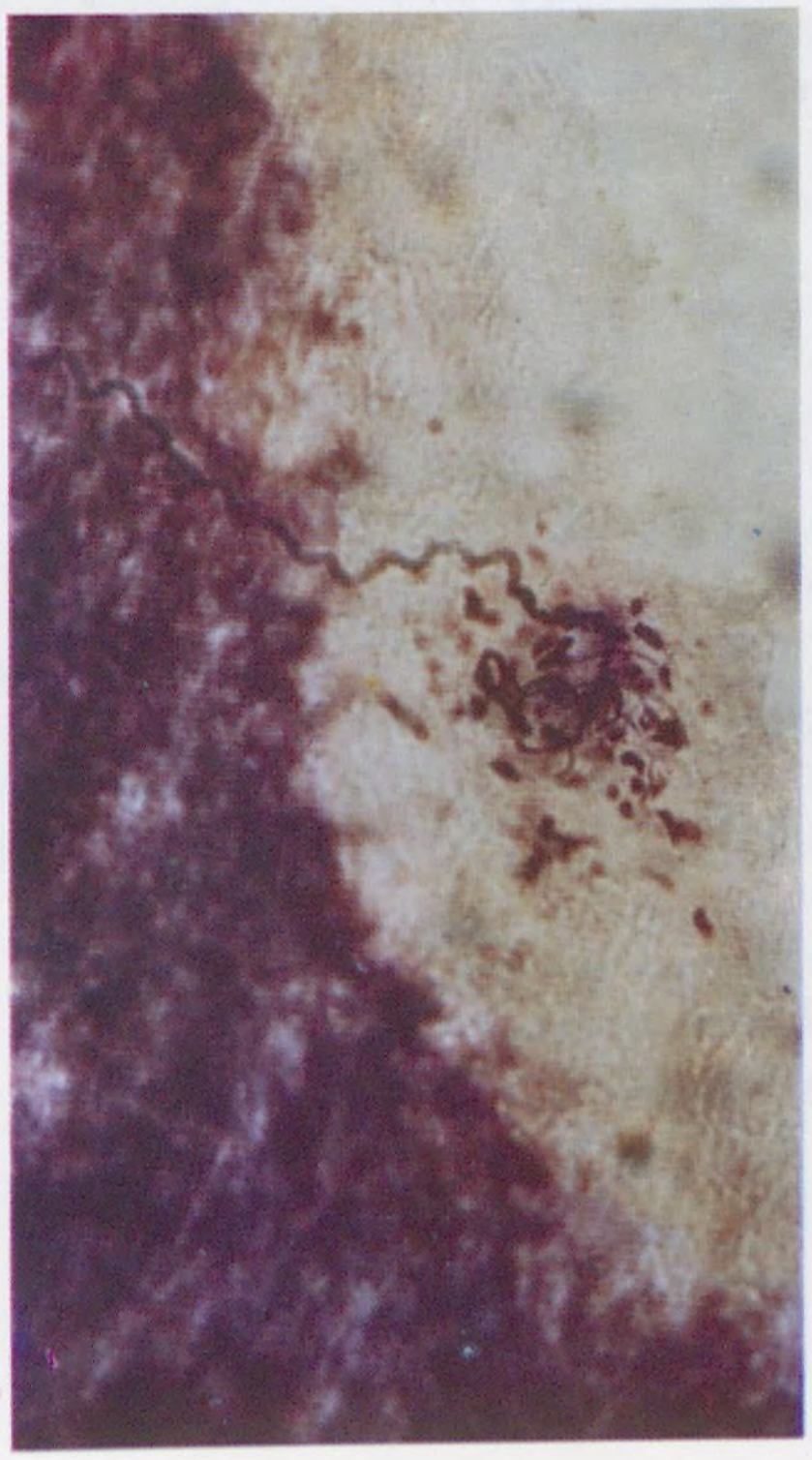

3

2

Plate 87

Human greater cardial vein

Bielschowsky–Gros–Cauna silver impregnation

An extensive terminal system of nerve fibres can be seen in the adventitia of the greater cardial vein among the lightly coloured fascicles (e) and nuclei (f) of connective tissue (g – nucleoli). The large number of neurofibrillar end-lamellae and the intercalated lamellae suggest that a special sensory system has been impregnated. The sensory system originates from a thin nerve fascicle (a) from which fibres with cavernous varicosities (b) and knotty thickenings arise. Lamellae varying in size and filled with neurofibrils (c) leave the thinner nerve fibres. Some of the lamellae are dense and round (d), while others are irregular in shape.

Neurohistological comments

It occurs rarely that all elements of a sensory system are successfully impregnated. One can never extrapolate the missing parts, when only a fraction of the system is visible. The system presented above, however, is a complete receptor formation. Its occurrence in the wall of a vein suggests that the coronary arteries are not the only vessels whose walls are supplied with receptors. In fact, receptors in the walls of the veins are even more complicated than those found in the walls of the coronary arteries.


a
b
b
c
d
e
d
d
c
g
f
d

Plate 88

Human greater cardial vein

Bielschowsky–Gros–Cauna silver impregnation

Thick connective tissue fascicles (b) crossing one another in the loose connective tissue (a) of the adventitia surround apparently empty spaces. The loose connective tissue accomodates a large receptor field containing myelinated fibres. The myelin sheath (c) surrounding thicker nerve fibres varies in thickness. It occasionally tapers off or is even absent in some places. Fragments (d) of the axon bordered by myelin sheath can be discerned. All fibres of the system originate essentially from one axon (e). This principal fibre breaks up gradually into several branches (f), some of which are dense while the others are more or less loosely structured (g). These loose portions continue in polyhedral lamellae (j) which proceed as fine terminal fibres to the end-lamellae (i) (h – neurofibrils).


a
b
d
h
g
f
j
j
e
i
i
c

Plate 89

Dog *(Canis familiaris)* superior vena cava

Bielschowsky–Ábrahám silver impregnation

This picture illustrates the site of transition between intima and endocardium. A nerve fascicle (c) composed of smooth and wavy fibres runs in the connective tissue (a, b – nuclei of connective tissue cells). All the typical features of the baroreceptor fibre are clearly shown by the curved axon (d) which runs alongside the fascicle: thick and large varicosities (e) and thin interconnecting segments (f). This nerve fibre joins a system composed of dense terminal ramifications (g) whose end-fibres (h) continue in large end-lamellae (i). In many lamellae the neurofibrils (j) are clearly seen.

Functional neurohistological comments

The endocardium has a rich innervation especially at the site of the inflow of the large veins. This observation indicates that not only the ultimate portion of the veins but also the entire wall of the right atrium is rich in receptors.

h
g
b
a
h
h
i
g
f
e
g
j
d
h
j
j
c
i

Plate 90

Domestic fowl *(Gallus domesticus)* aortic arch

Bielschowsky–Gros silver impregnation

Baroreceptors of the aortic arch. Collagenous fibres of the loose connective tissue are arranged in fascicle-like formations (a); among them, nuclei of connective tissue cells (b) can be seen. Fragments of smooth muscle tissue (c) also appear. The depressor nerve fibres (d) bear large varicosities (e) and intercalated lamellae (f) connecting the end-lamellae with the nerve fibres. The end-lamellae (g) vary both in form and structure. As a rule, they are well impregnated and contain neurofibrils.

Functional and neurohistological comments

This receptor should not be identified with the well-known receptors of common vascular reflexes (simple terminal ramifications). The special receptor apparatuses demonstrated here are confined to certain vessels and intensify the sensitivity of their wall. Typical receptors of this kind (baroreceptors, pressoreceptors) first appear in birds. Here, as shown in the picture, thick nerve fibres appear and terminate in large neurofibrillar lamellae along the boundary between the media and adventitia of the aortic arch. The end-lamellae vary in number and size.

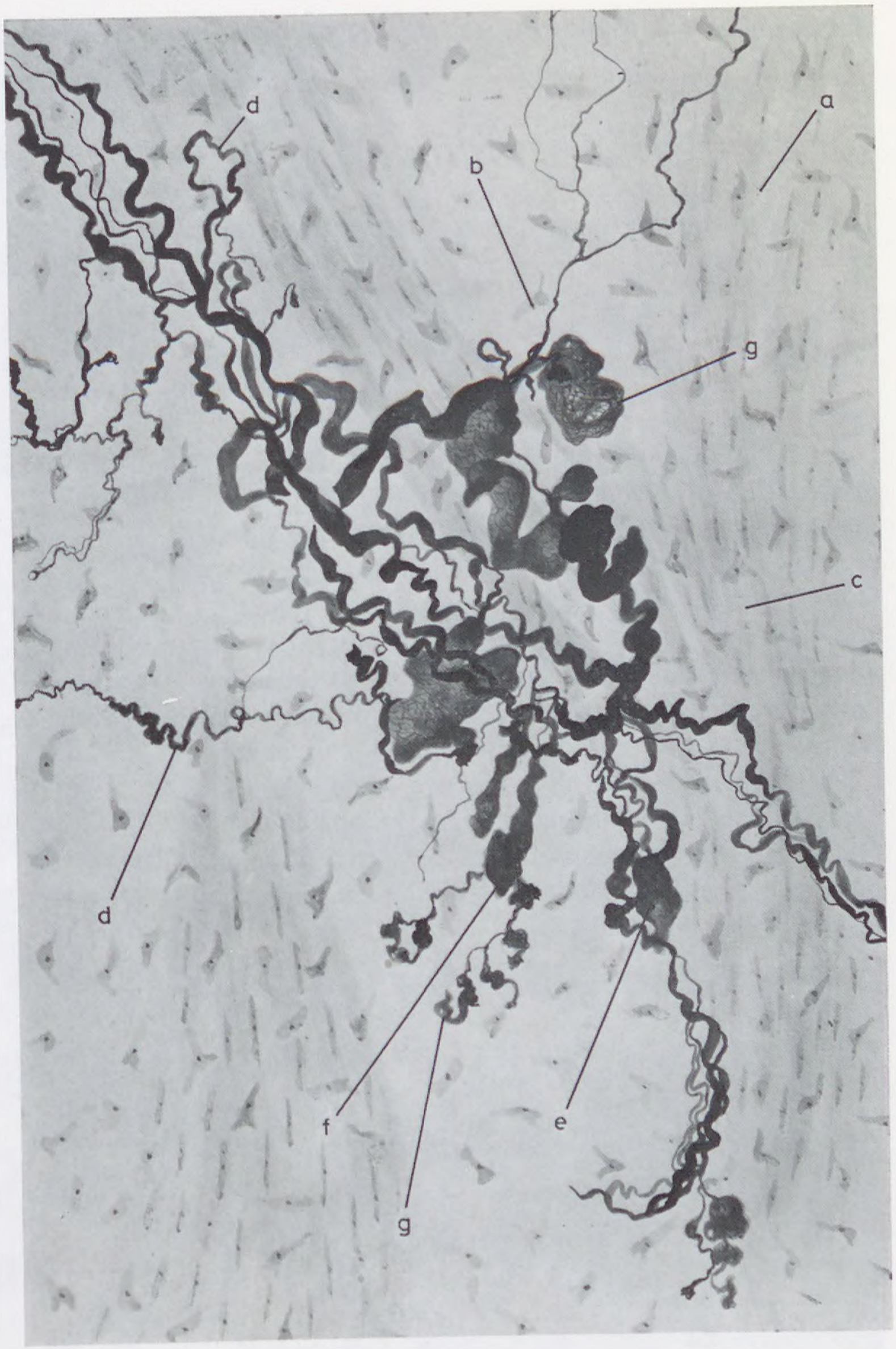
d
b
a
g
c
d
f
e
g

Plate 91

Dog *(Canis familiaris)* aortic arch

Bielschowsky–Gros–Cauna silver impregnation

Part of the adventitia of the aortic arch. Terminal ramification of a single depressor fibre with neurofibrillar end-lamellae. Within the thick nerve fibre (a), the neurofibrils can also be discerned. The collaterals (b) send off tapering terminal fibres (c), equipped with variously shaped neurofibrillar end-lamellae (f). Intercalated lamellae are also present. Note the ring-like terminal structures (e) varying both in the thickness of their wall and the diameter of their lumen. Nuclei of connective tissue cells (g) are visible all over the picture. In the aortic arch of the dog the depressor fibres completely fill the depressor area. Their terminal ramifications appear in bouquet-like formations.

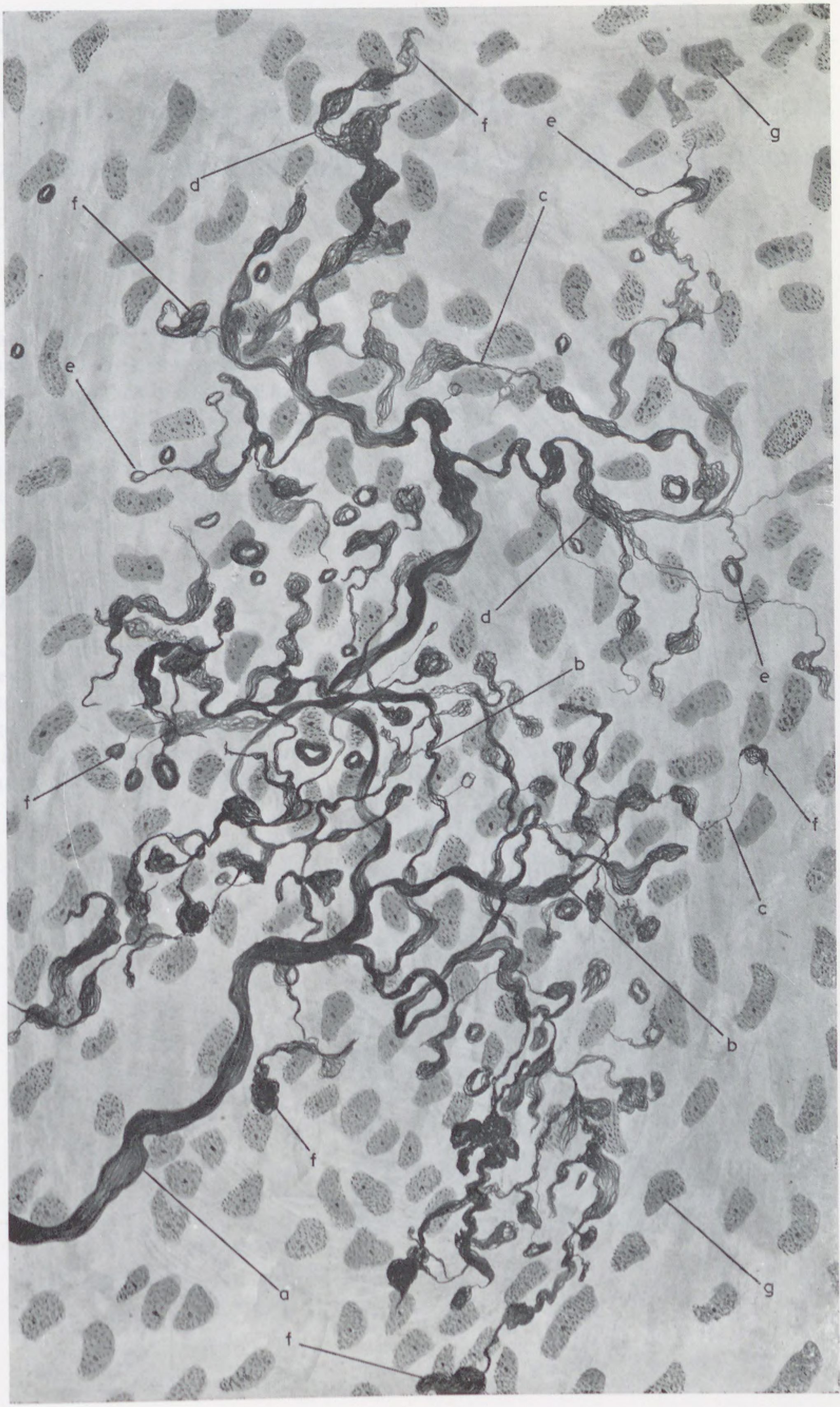
f
e
g
d
f
c
e
d
e
b
f
f
c
b
f
a
g
f

Plate 92

Hog *(Sus scrofa domestica)* aortic arch

Photomicrograph. Bielschowsky–Gros silver impregnation

Two interconnected receptor end-systems, both located in the adventitia composed of dense connective tissue (a). A thick myelinated nerve fibre (b) having varicosities (c) breaks up into several wavy terminal branches. These latter terminate in round or slightly elongated end-lamellae (d).

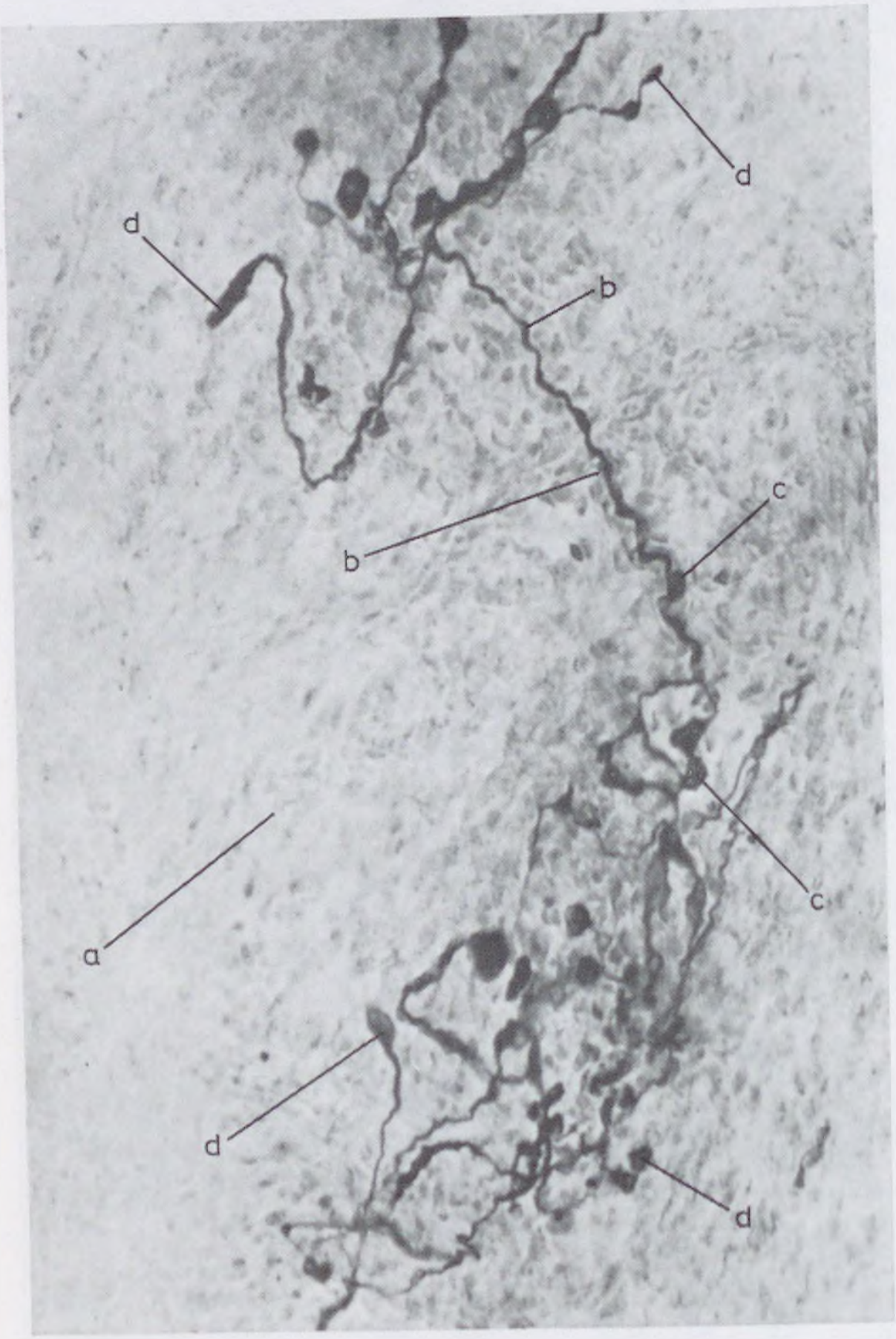

Plate 93

Hog *(Sus scrofa domestica)* aortic arch

Photomicrograph. Bielschowsky–Gros silver impregnation

Two thick myelinated depressor fibres (a), supplied with abundant dense varicosities, arranged like the pearls in a necklace. The frequently occurring axonal indentations are characteristic signs of depressor nerve fibres. Fine wavy and varicose collaterals (b) originate from the branches of the thick fibres. The collaterals terminate in round, homogeneous end-lamellae (c) varying in shape.

Neurohistological comments

Wavy course, varicosities and spherical end-lamellae are specific features of the nerve fibres constituting the aortic baroreceptor system in the hog. It has to be emphasized that slides like this one are rarities. Thousands of sections have to be impregnated until such pressoreceptor apparatuses can be visualized.

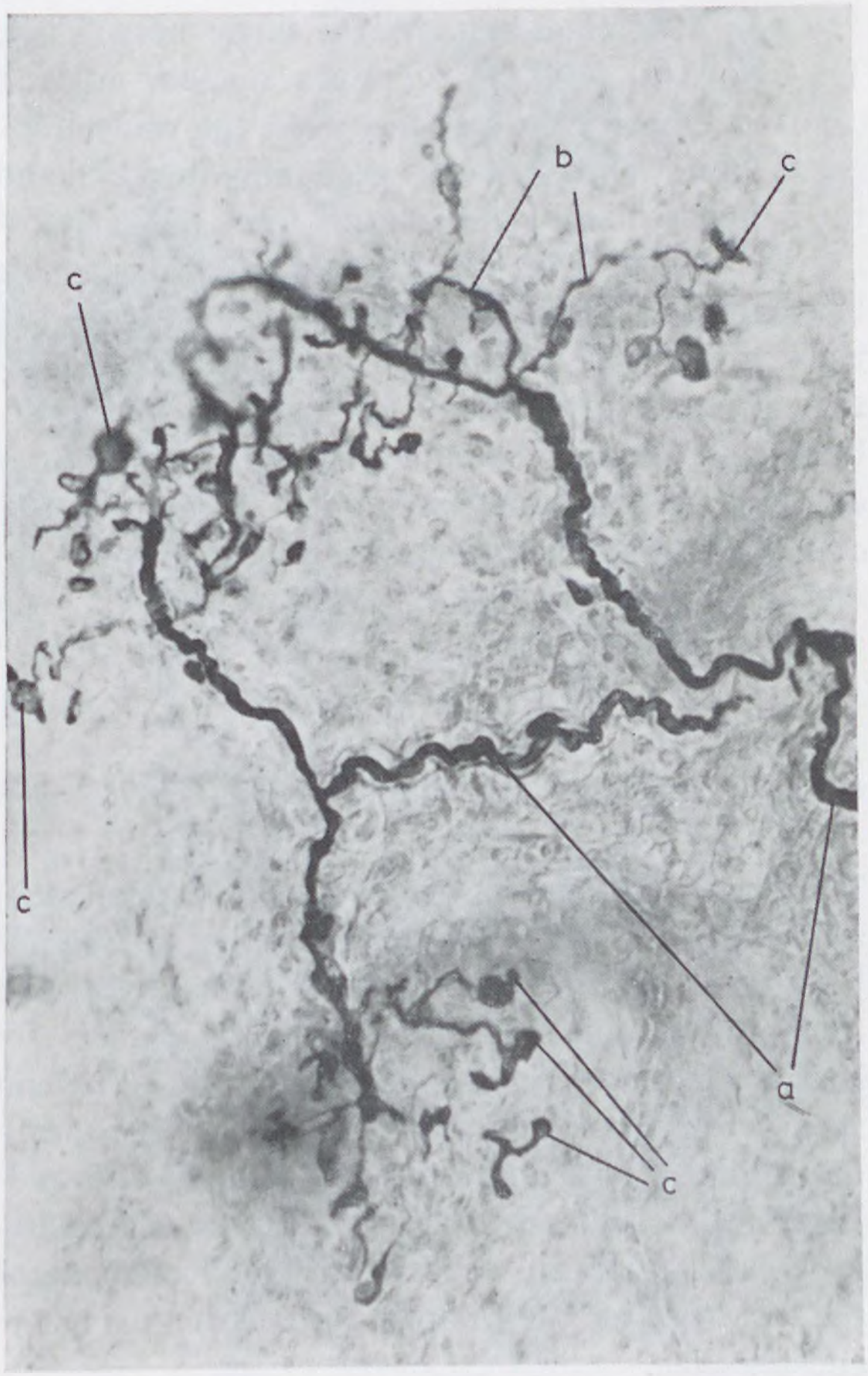

Plate 94

Hog *(Sus scrofa domestica)* aortic arch

Bielschowsky–Gros silver impregnation

The entire terminal system of a single nerve fibre. The axon (a) and the Schwann nucleus (c) can clearly be seen. Thin branches leave the wavy thick nerve fibre. They become gradually thicker; and their fine terminal ramifications form large neurofibrillar end-lamellae (f). The second and ultimate branchings of the parent fibre, though they are unusual, are typical examples of monopodial ramification. Note the myelin sheath (b) along the primary branches. The fine fibres emerging from the latter continue as unmyelinated terminal fibres (d) interconnected by neurofibrillar intercalated lamellae (e) and large end-lamellae (f) some of which form complicated systems.

Functional neurohistotechnical comments

The essential features of the baroreceptor (depressor) system are demonstrated by this picture making optimum use of the capacities of free-hand drawing from microscopic sections. The typical features are as follows: monopodial branchings, thick myelin sheath which can be followed almost to the terminal ramifications, and large intercalated- and end-lamellae, filled with neurofibrils. Electron microscopic investigations are needed for the elucidation of the structure of the synaptic systems involving the end-lamellae.

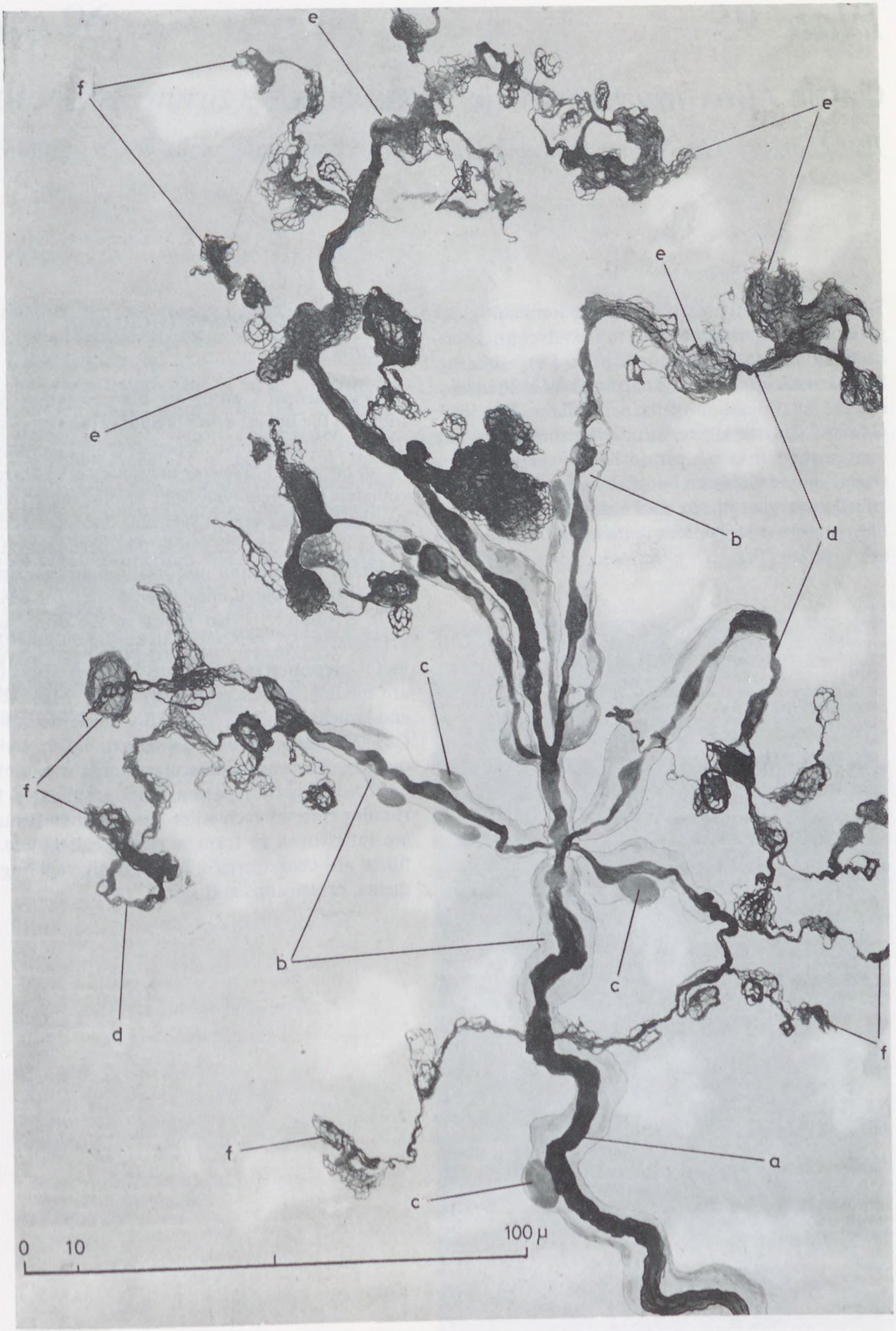
e
f
e
e
e
b
d
e
c
f
d
b
c
f
f
a
c
0
10
100 µ

Plate 95

Cattle *(Bos taurus)* aortic arch

Bielschowsky–Gros silver impregnation

Three thick axons (b) showing predominantly depressor characteristics appear in the adventitial connective tissue (a) of the aortic arch. Large intercalated lamellae (c) form groups mainly in the vicinity of the termination of the nerve fibres. Two large glomerular systems are formed by the axons; the one on the left is complete while of the other one (right) only details can be seen. Neurofibrillar end-lamellae varying in size and shape as well as ring-like endings can be seen within and around the arborizations (d).

Comparative neurohistological comments

A heterogeneous group of baroreceptors can be found in the bovine aorta including parallel systems, dendritic forms and dense terminal formations. *(i) In the parallel systems* the thick nerve fibres surrounded by a relatively thin myelin sheath have a parallel course over considerable distances and only break up into branches near their termination. The branches are fine and uniform in diameter and terminate in elongated end-lamellae. *(ii) The dendritic form* is similar to that found in the dog, but the principal fibres are wavy, the myelin sheath is thin and the terminal ramifications are long. These forms are mainly characterized by large neurofibrillar end-lamellae and by especially thick neurofibrils. *(iii) The dense terminal formations* occur less frequently. They are glomerular ramifications of two or three, slightly tapering, thick myelinated fibres running close to each other. Their terminal branches are interwoven to form a closed end-system. The fibres are characterized by suddenly tapering segments, protrusions and spines.

Plate 96

Cattle *(Bos taurus)* aortic arch

Bielschowsky–Gros silver impregnation

End-formation of a baroreceptor fibre in the outer layer of the adventitia, characterized by wavy connective tissue fascicles (a) and nuclei of connective tissue cells. These latter occur in large numbers in the area of the terminal system and are considered to be characteristic of the baroreceptor system (and of cardiovascular receptors in general). A thick axon (b) with varicosities (c) and suddenly tapering sections, some of which attain considerable lengths, starts at the bottom of the picture. Collaterals (d) first show gradual taperings, then become thicker again, and finally break up into branches terminating in end-lamellae (f) varying both in shape and size, intermingled with similarly structured end-systems of another depressor fibre. The square intercalated lamellae (e) of the wavy terminal fibres are typical features of the end-system.

Functional neurohistological comments

To analyse the possibility of direct connections between nerve fibres and the role of connective tissue cells in sensory function, electron microscopic studies would be necessary. Nevertheless, the abundance of connective tissue nuclei within the receptor fields in the walls of blood vessels and in their immediate vicinity has been clearly demonstrated. This might suggest their role in the complex function of the sensory systems.

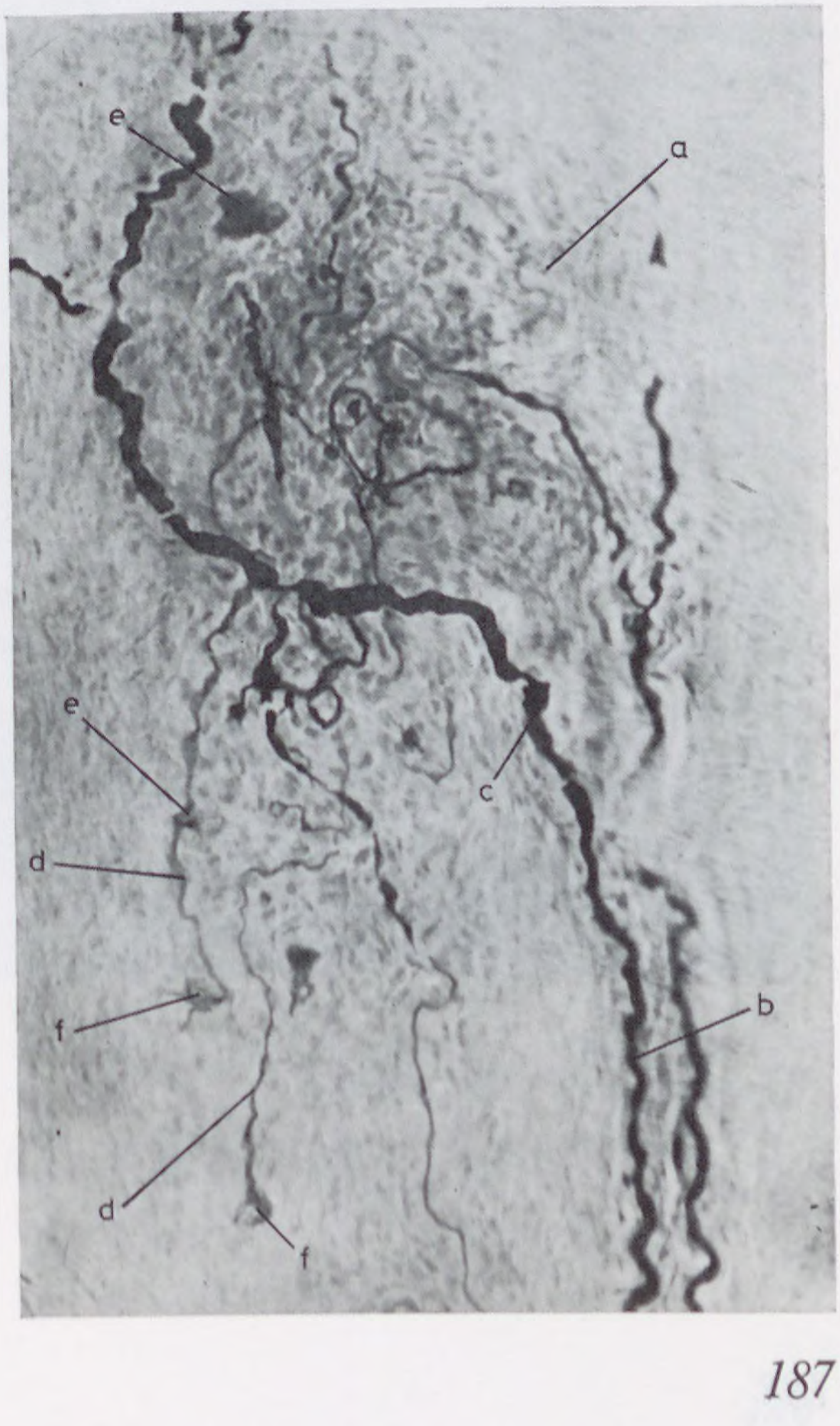

Plate 97

Cattle *(Bos taurus)* aortic arch

Bielschowsky–Gros silver impregnation

A compact field of the nerve end-lamellar system bordered by a capillary loop can be seen in the adventitia of the aortic arch. A baroreceptor fibre (a) traverses the picture; characteristic features are tap-like and spiny protrusions, large and variously shaped varicosities (b) as well as alternating fine and thick segments. The largest part of the picture is occupied by the end-lamellae (c). This large end-system is bordered by the loops of a capillary (d). Note nuclei of endothelial cells in the walls of the blood vessels (f). The entire end-system is located in the outer, loosely structured layer of the adventitia in which, after perfect impregnation, nuclei of connective tissue cells (e) can be seen among the light-coloured connective tissue fibres. Presumably the capillaries surrounding the end-system provide for the oxygen and nutrient requirement of the large receptor apparatus.

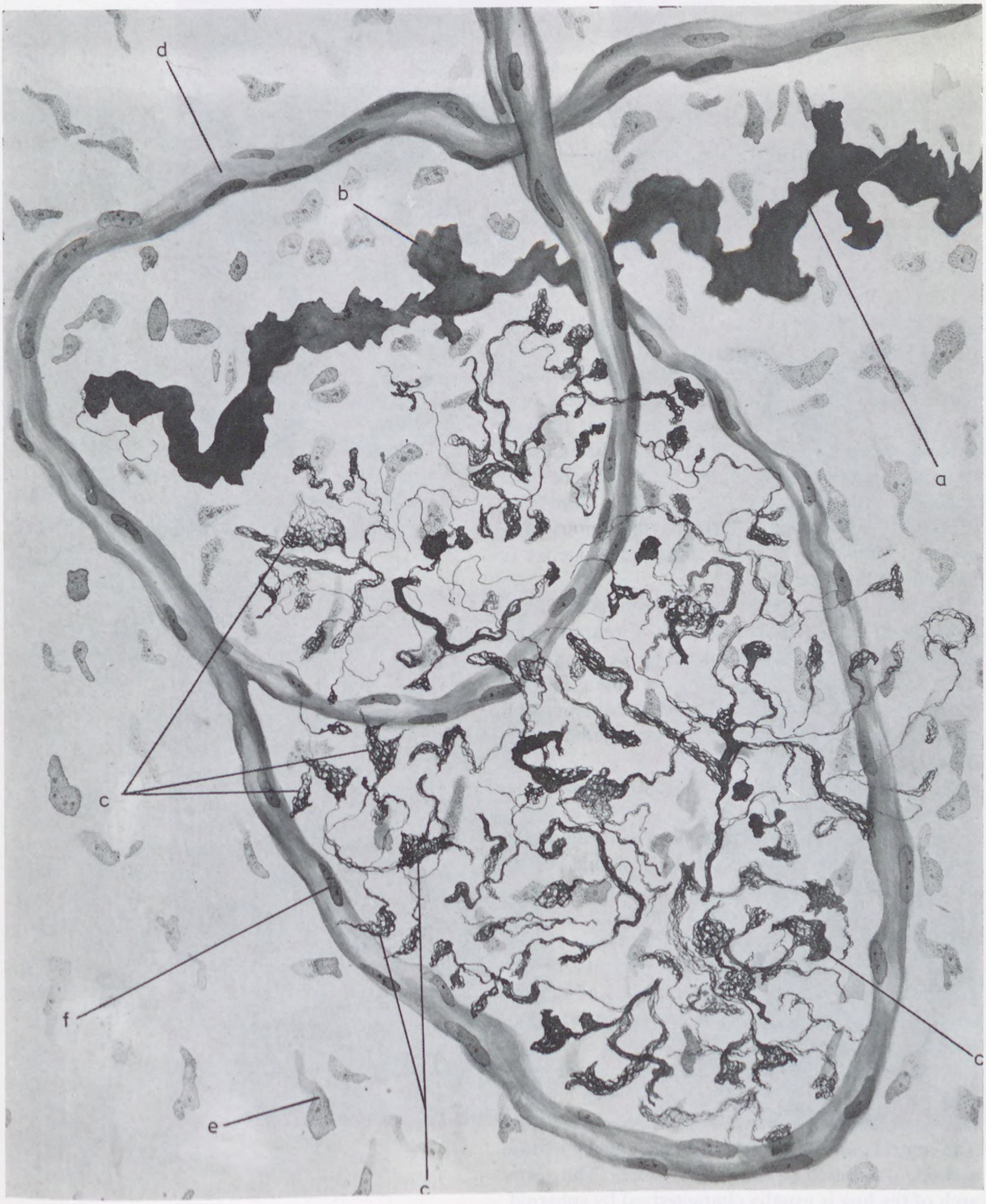
d
b
a
c
f
e
c
c

Plate 98

Baroreceptor terminal systems

Photomicrographs. Bielschowsky–Gros silver impregnation

Baroreceptor systems of similar structure are shown in this plate.

1. Aortic arch of the cattle *(Bos taurus)*. A thick nerve fibre passes among thick connective tissue fascicles and of connective tissue nuclei of the adventitia to break up into three branches after a short tapering segment. Two of the three branches are relatively thin while the third, middle, branch is thicker than the parent fibre. A voluminous end-system terminating in large, dense end-lamellae is formed by this branch.

2. Aortic arch of the hog *(Sus scrofa domestica)*. A terminal system of nerve fibres appears among groups of connective tissue nuclei in the adventitia; both the finer and thicker fibres terminate in end-bulbs. The rather loosely structured terminal system arises from the ramification of myelinated nerve fibres.

3. Aortic arch of the hog *(Sus scrofa domestica)*. A fraction of the media containing muscle cells can be seen, adjacent to the connective tissue lamella of the adventitia on the right side. A terminal system of nerve fibres, essentially a rather loosely structured coil, appears in the spaces between the connective tissue fibres and connective tissue nuclei. Each terminal fibre adheres to elements of the ground tissue by means of end-lamellae of varying size. The fibres of the end-system arise from branches of the thick myelinated axons.

4. Aortic arch of the hog *(Sus scrofa domestica)*. A fraction of the adventitia is shown with connective tissue fibres and nuclei of connective tissue cells. The central part of the picture is occupied by a loose end-coil composed of thick nerve fibres. The aortic arch of the hog is usually characterized by spheroid, as well as elliptical lamellae serving as interconnections within the terminal system.

1

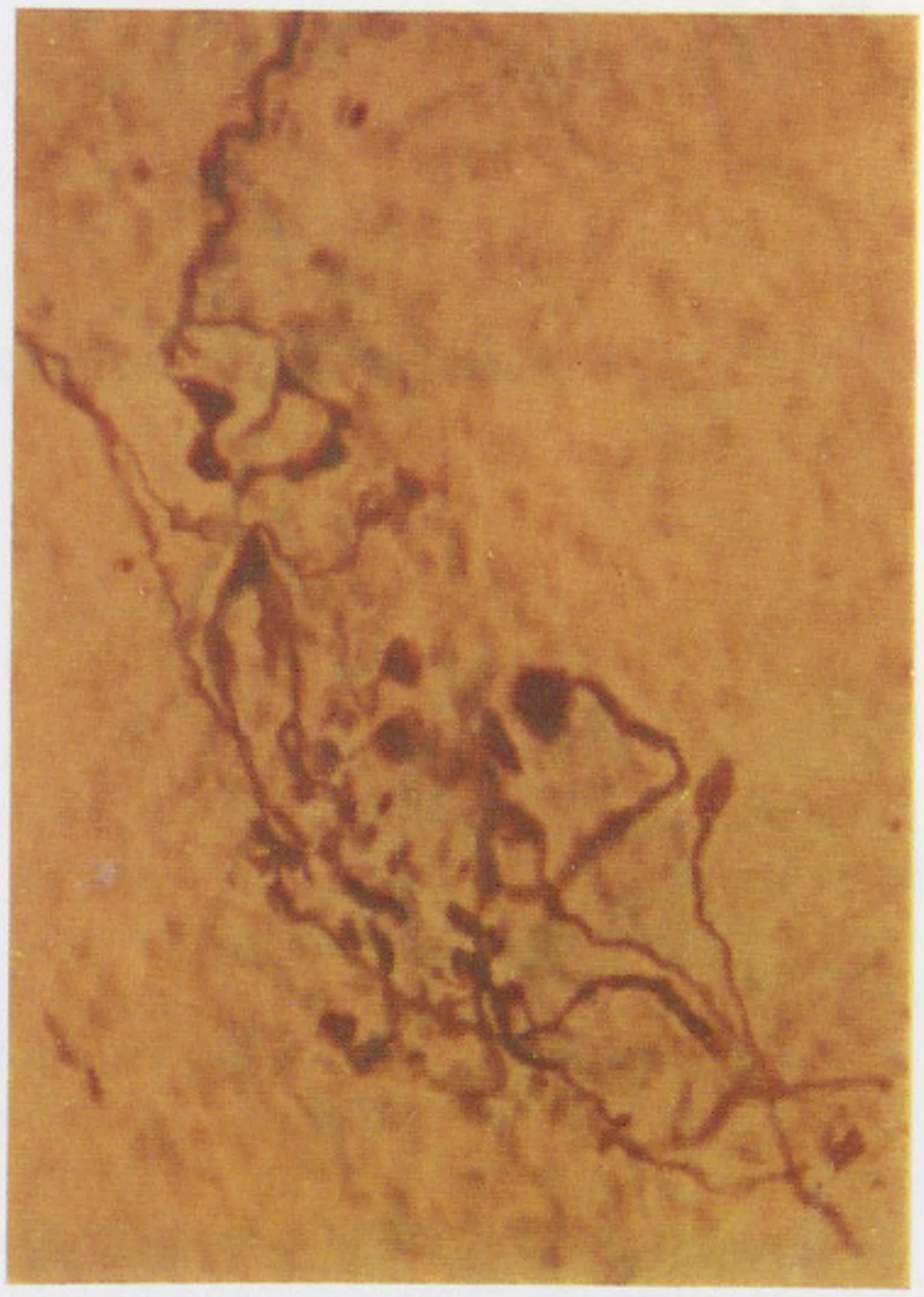

2

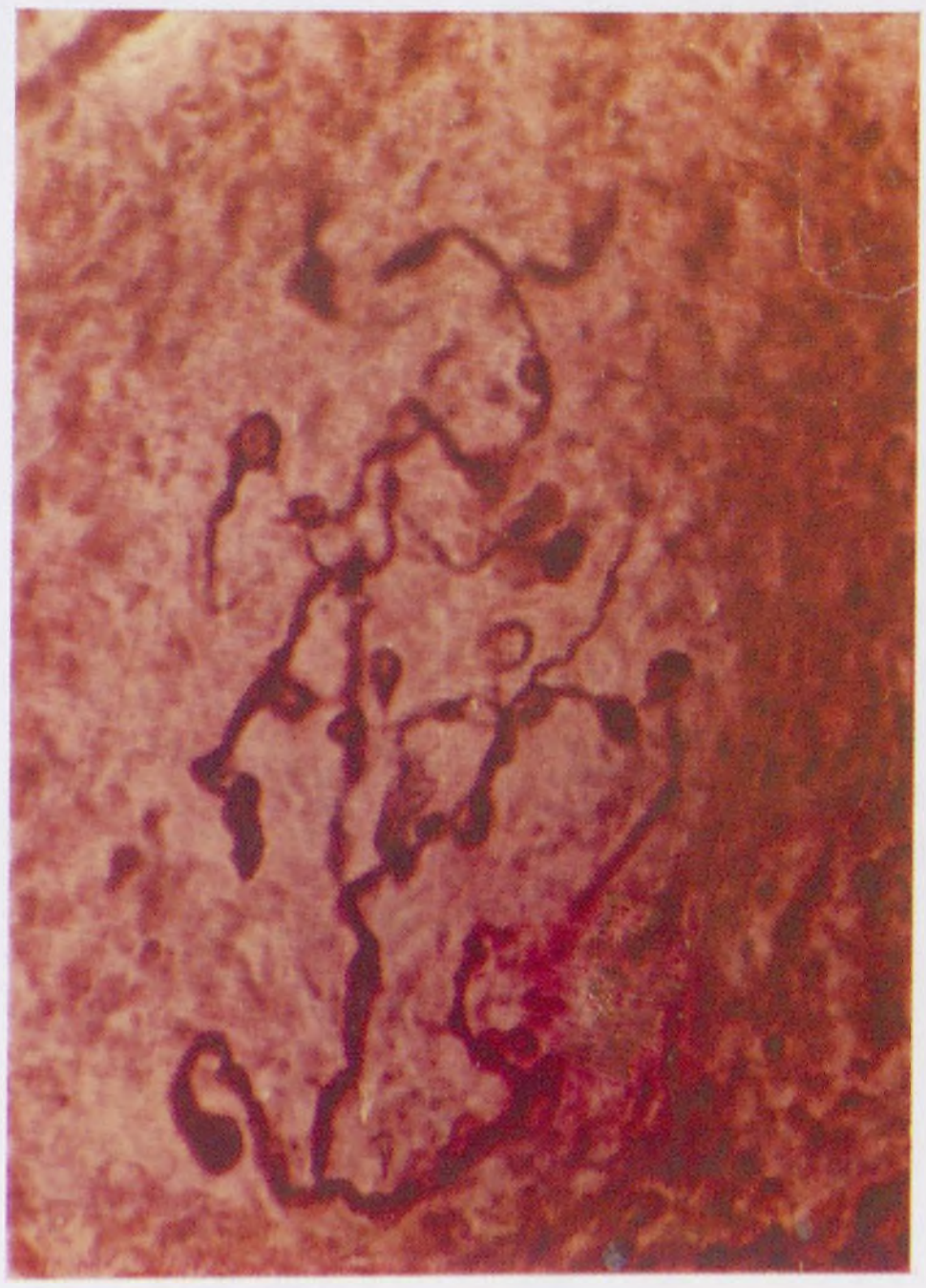

3

4

Plate 99

Human aortic arch

Bielschowsky–Gros silver impregnation

Terminal ramification complete with end-lamellae and intercalated neurofibrillar lamellae of a collateral branch of a thick depressor fibre. A thin side-branch (b) emerges from a varicosity of the thick nerve fibre (a), which follows the course of the parent fibre for a while. Soon it breaks up into two branches which arborize on their own, producing a rich system of fine terminal fibres. Intercalated neurofibrillar lamellae (c) varying in shape and size can be seen along the fibres; the neurofibrils form loose plexuses or appear in a reticular arrangement. The intercalated lamellae continue as large neurofibrillar end-lamellae (d) whose structure, localization and consistency show great variability.

Functional neurohistological comments

This type of depressor receptor belongs to the finest and most sensitive sensory structures of the organism. Monitoring the slightest alterations in pressure, it conducts the relevant impulses to the cerebral cardiovascular centres. The connection between the end-lamellae and the ground tissue is especially remarkable.


d
d
d
b
c
a
d
c

Plate 100

Human aortic arch

Jabonero's silver impregnation

A thick nerve fibre (a) filled with neurofibrils (b) appears in the lower right corner. Note varicosities (c) alongside the larger branches. The entire arborization is furnished by branches and terminals of a single thick fibre. Intercalated lamellae (d) are frequent in segments close to the terminals; neurofibrils are loosely arranged. The terminal branches are of depressor nature and end in large, complicated end-lamellae (e). Ring-like terminal structures occur in large numbers among the end-lamellae. These are attached to the terminal branches by neurofibrillar segments. For technical reasons, the connection between the rings and the nerve fibre cannot always be revealed. The entire system is embedded into loose connective tissue (f) (g — nuclei of connective tissue cells).

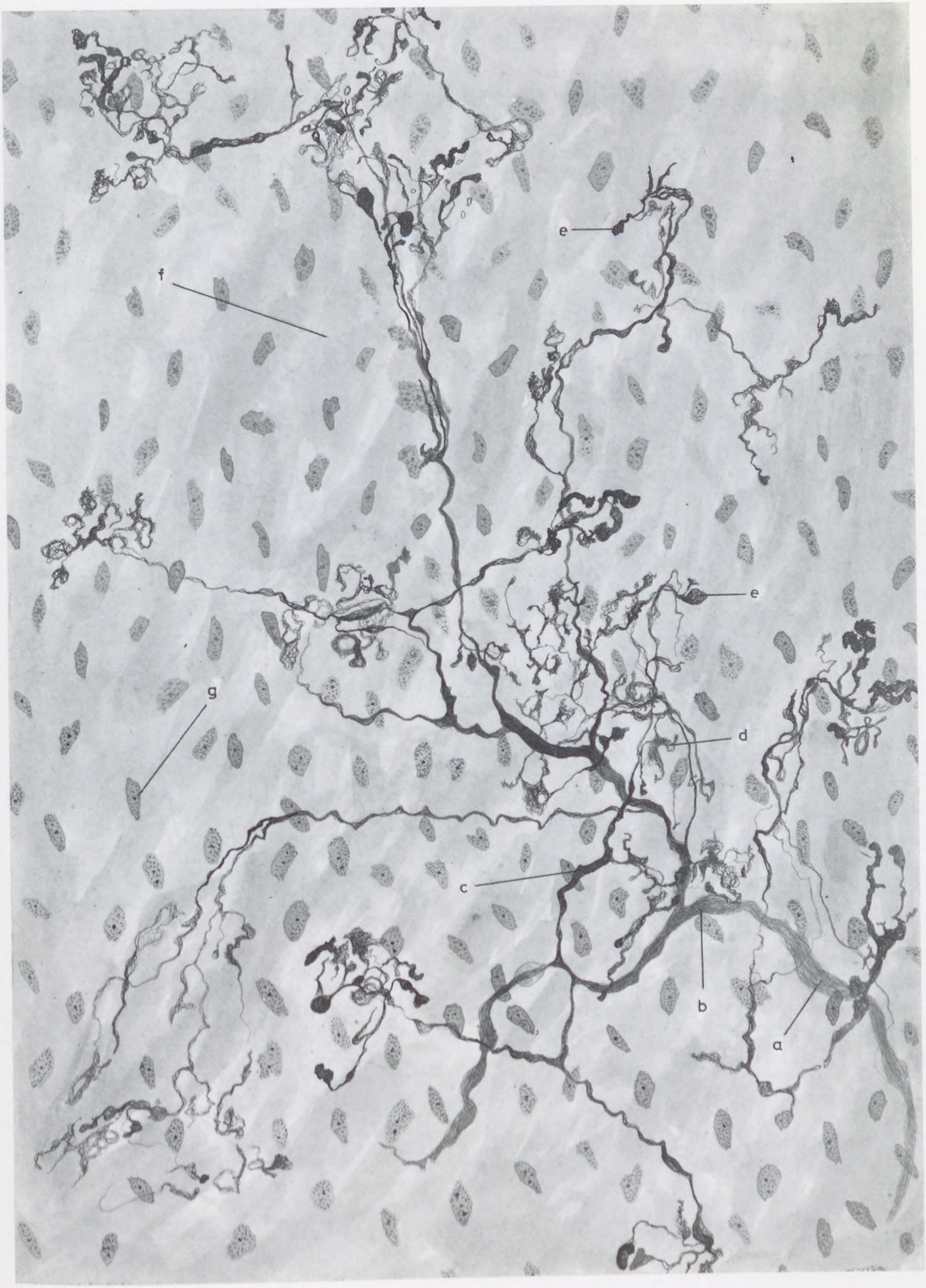
e
f
e
g
d
c
b
a

Plate 101

Human aortic arch

Jabonero's silver impregnation

Terminal arborization of a nerve fibre. Some elements reflect pathological changes due to changes in the wall of the blood vessel. Two thick nerve fibres (a) start from the upper and lower right corners of the picture. Neurofibrils (d) are well visible in both of them, but mainly in the one on the right. A collateral, given off from the fibre on the left, has an abundant terminal ramification system (b) which can hardly be followed until the very ends. Elongated varicosities (e), intercalated lamellae (f) filled with parallel or spirally arranged neurofibrils can frequently be found in the collateral branches. The terminal fibres give rise to very fine terminal ramifications (c) which end in particular end-lamellae (g). Here the neurofibrils are arranged in a reticular array.

Functional neurohistological comments

Such end-lamellae are to be found only in pathologically altered receptors. The shape, arrangement and probably also the functional capacity of the receptors are altered due to advanced age. Numerous terminal structures bear the marks of degeneration such as the thickened axons that taper abruptly, or the large polymorphic nodes that appear occasionally in the course of fibres as well as the round homogeneous nodules arranged in parallel groups and located at the end of the terminal branches.


f
a
e
c
f
d
d
f
c
b
b
g
b
d
g
g
a

Plate 102

Human aortic arch

Bielschowsky–Gros silver impregnation

The terminal phase of nerve fibre degeneration can be seen in the baroreceptor area of the adventitia in a sclerotic aorta. A nerve fascicle (b) composed of thick depressor fibres traverses the loose connective tissue (a). The nerve fibres (c) running within the fascicle seem to have a normal structure although the spines appearing along their course suggest early degenerative processes. Close to the nerve fascicle the remnants of large groups of disintegrated end-lamellae (d) can be observed.

Neurohistopathological comments

In advanced age morphological changes due to arteriosclerosis, like the ones shown in this picture, can often be found both in the aortic arch and in the carotid sinus. It can be assumed that arteriosclerosis gradually destroys the depressor receptor system.

Strangely this fact is not usually taken into consideration in the chronic form of hypertension. It is not known, however, whether the process of degeneration develops peripherally or in the cytoplasm of the nerve cell.

Whatever the pathomechanism, it can be clearly established that small vesicles appear in the terminal fibres in the final stage of degeneration. The end-lamellae undergo atrophy and fragmentation. The ultimate phase of degeneration is the destruction of the end-lamellae. Neurofibrils break up into small fragments which coalesce and form large conglomerates. Finally, the remnants of the terminal fibres and the whole system of end-lamellae merge into large irregular conglomerates. Fragments of the thick nerve fibres located in the vicinity of the conglomerates remain occasionally intact.

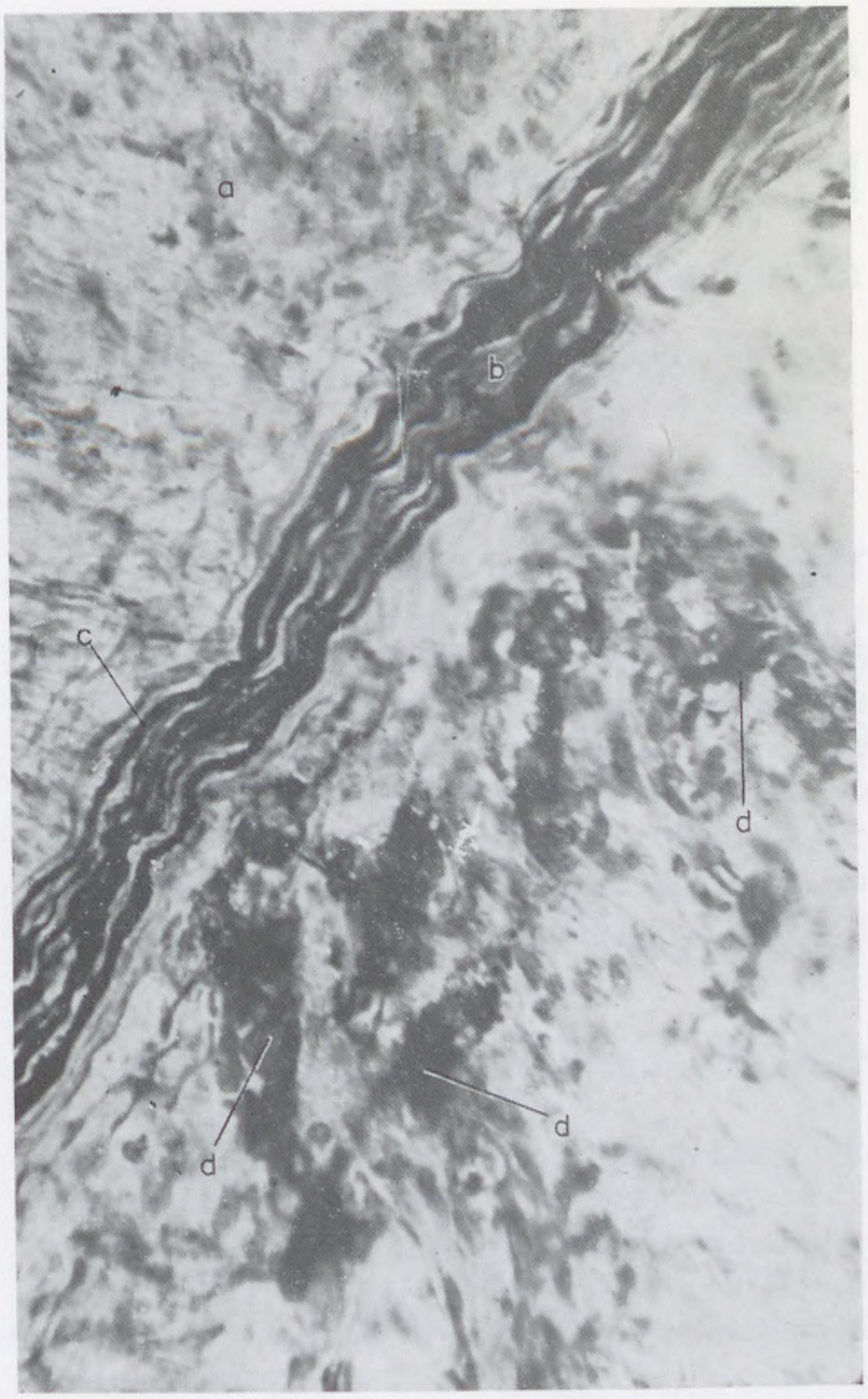
a
b
c
d
d
d
d

Plate 103

Human aortic arch

Bielschowsky–Gros silver impregnation

Thick depressor fibre of vagal origin (a) gives rise to a series of fine branches (b). Note the myelin sheath (c) and the nuclei of Schwann's cells (d). Both the thick myelinated fibre and the unmyelinated collateral branches bear varicosities (e). Neurofibrillar end-lamellae (g) can be found at the end of the fine terminal fibres. The segments of the fibres containing loosely arranged neurofibrils are called neurofibrillar intercalated lamellae (f).

General neurohistological comments

Baro- and pressoreceptors are common in the aortic arch of mammals. Thick myelinated fibres arrive to the convex side of the aortic arch either as separate nerves (nervus aorticus) or as branches of the vagus nerve (ramus aorticus vagi) together with the sympathetic fibres. The joint vagosympathetic nerve constitute large receptor assemblies in the anterior and posterior regions of the aortic arch. Baroreceptors are clearly distinguished from any other receptor formations by the following characteristics: *(i)* The myelinated nerve fibres forming the connecting systems are thick; varicosities, nodes, incisions and spiny protrusions can often be found along the axons. *(ii)* The fibres ramify abundantly; the fine terminal fibres frequently have segments in which neurofibrils are loosely arranged (intercalated lamellae). *(iii)* The vast systems of neurofibrillar end-lamellae in the inner part of the adventitia are a characteristic feature of pressoreceptors. They form a continuous neurofibrillar layer at the boundary between adventitia and media.

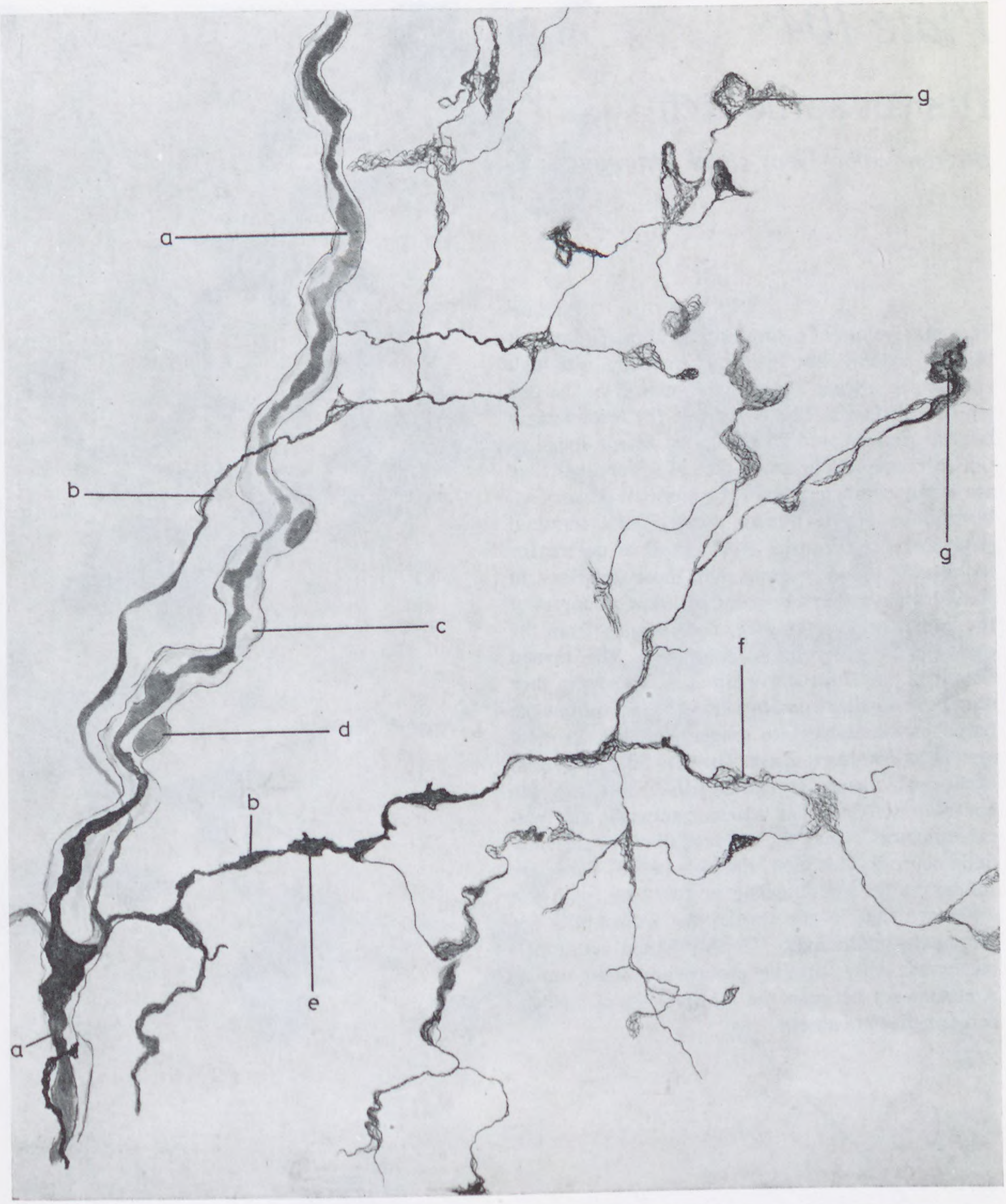
g
a
g
b
c
f
d
b
e
a

Plate 104

Human aortic arch

Bielschowsky–Gros silver impregnation

Terminal system of a single nerve fibre. The parent fibre (a) exhibits homogeneous structure, although neurofibrils appear occasionally, mainly at the origin of collaterals. The collaterals (b) terminate in large neurofibrillar end-lamellae (c). Shape, localization, arrangement and structure of the end-lamellae are highly characteristic of the terminal sensory arborizations of the human aorta. These terminal structures may form a more sensitive device for monitoring blood pressure than those described in similar organs of lower mammals. Baroreceptors of the human aortic arch differ considerably from the corresponding structures in animals. The myelin sheath of the thick nerve fibres is narrower, they send off a smaller number of side-branches, but the branches themselves are longer, and the terminal systems are more extensive. The very fine, elongated, occasionally irregular end-lamellae, in which the neurofibrils form a fine reticular network, are typical structures. Along the terminal fibres one usually finds neurofibrillar intercalated lamellae. These are similar to the end-lamellae in structure, with the difference that in the former the neurofibrils are arranged longitudinally. Trefoil-shaped end-lamellae occasionally forming groups are often found. Anastomoses between the terminal fibres and the end-lamellae are absent.

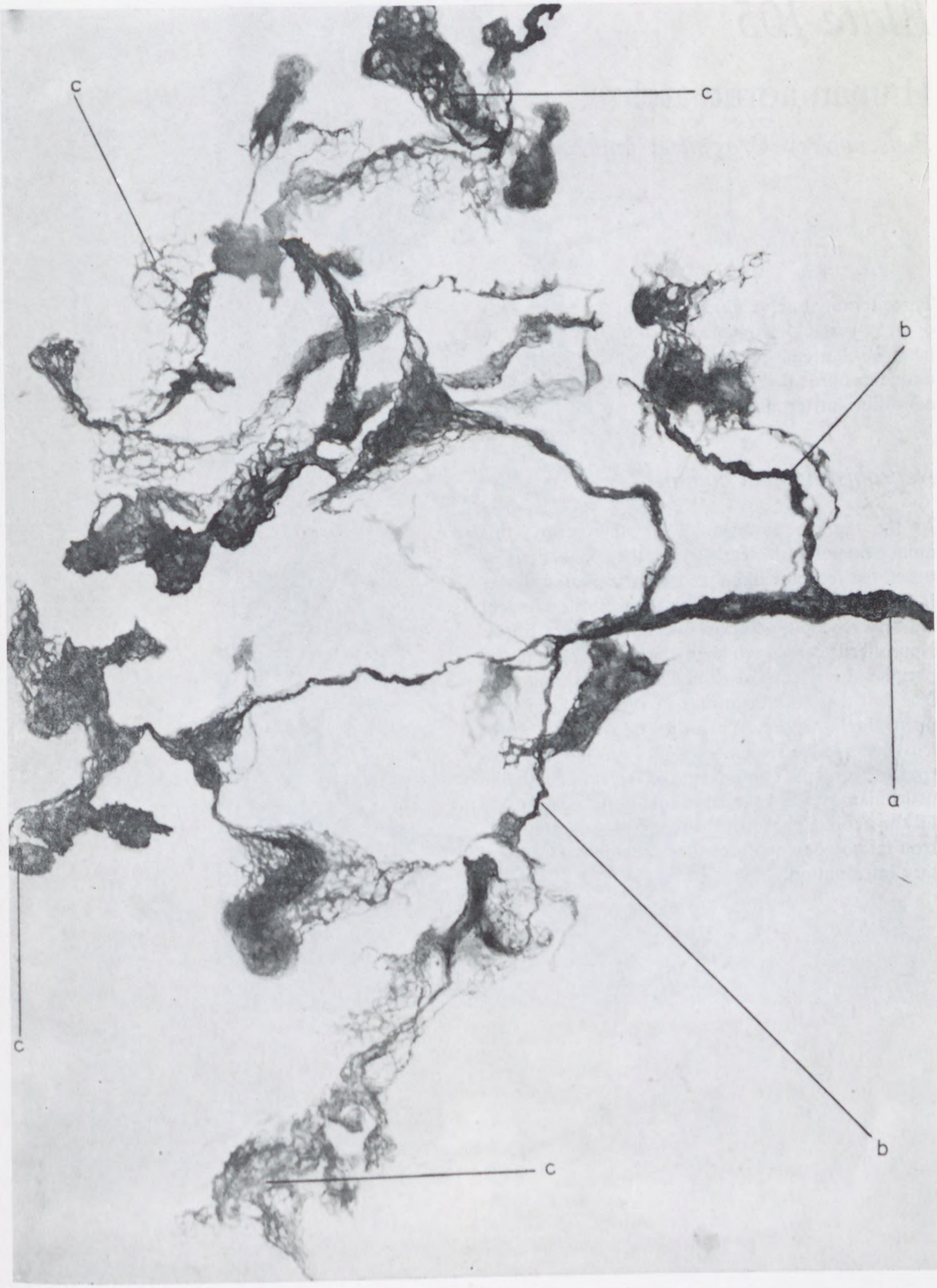
c
c
b
a
b
c
c

Plate 105

Human aortic arch

Bielschowsky–Gros silver impregnation

Three terminal nerve fibres (a) from the aortic arch of a 58-year-old woman. The fibres terminate in neurofibrillar end-lamellae (b) in which the individual neurofibrils (c) divide and form a clearly visible neurofibrillar terminal plexus.

Neurohistological comments

At the highest power of light microscopy, this unique preparation clearly shows the connection between the receptor fibres and the innervated tissue. It also demonstrates that the neurofibrils are real light-microscopic components of the nerve fibres. Neurofibrils can convincingly be shown both in the peripheral and central nervous systems despite the fact that they do not appear in the usual electron microscopic picture. When dealing with this problem it has to be remembered that well-known electron microscopic components of the axoplasm, like neurofilaments and the neurotubuli, do not entirely fill the axon. Consequently, the light- and the electron microscopic pictures may provide complementary information.

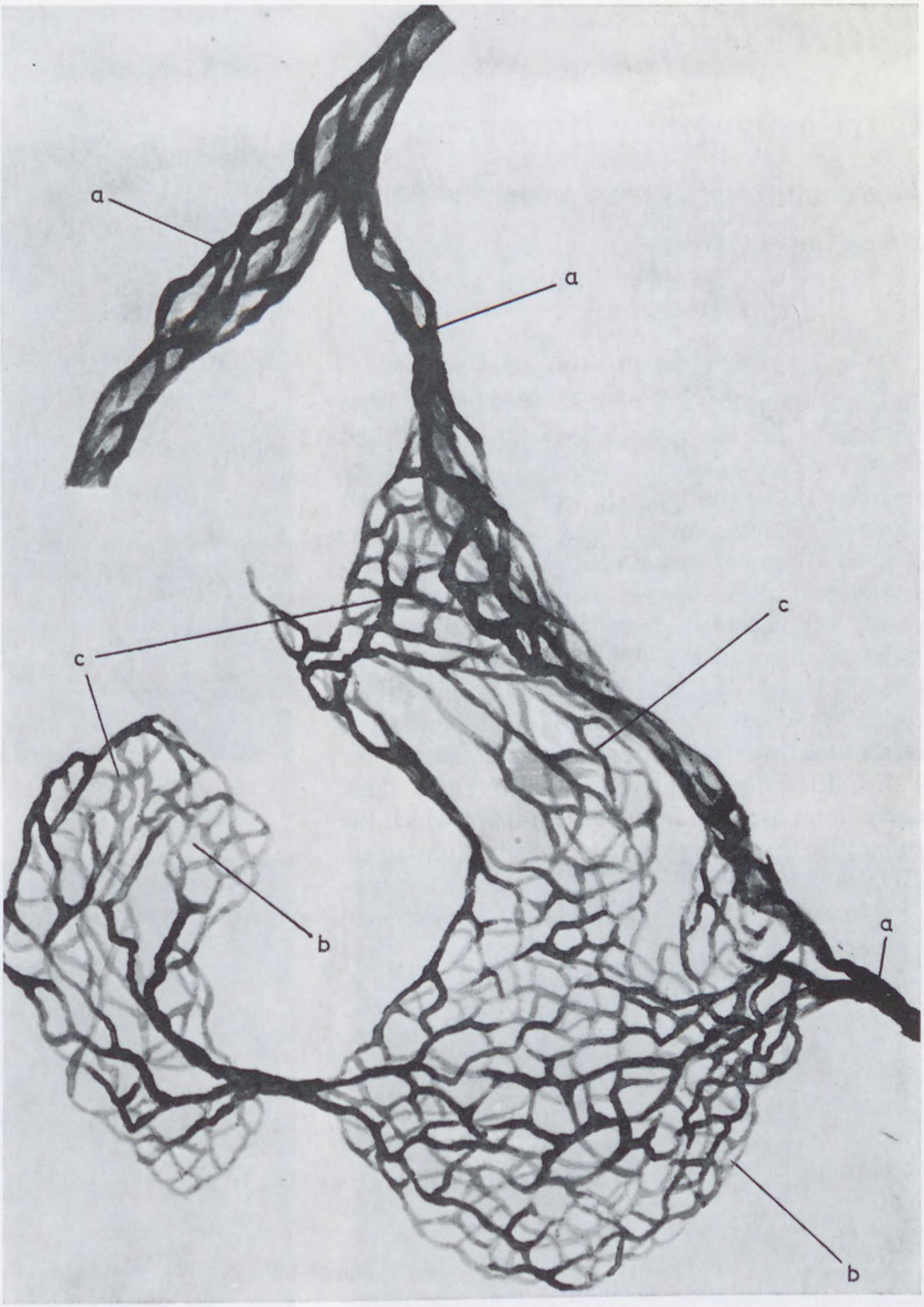
a
a
c
c
c
b
a
b

Plate 106

Cardiovascular baroreceptors

Photomicrographs. Bielschowsky–Gros silver impregnation

1. Human aortic arch with terminal nerve fibre systems in the adventitia. Connective tissue and smooth muscle cells have remained practically unstained. On the other hand, nerve fibres and their terminal ramifications are well impregnated. Myelinated axons start from the upper and lower margins of the picture and run towards the centre. They ramify and form an elongated loose coil system. Enlarged segments and homogeneous lamellae can often be found along the fibres. The terminal fibres end in spherical or polymorphic end-lamellae as seen in the lower right corner of the picture.

2. Cattle *(Bos taurus)* aortic arch. Three thick nerve fibres are seen in the adventitia in which the connective tissue elements have remained unstained. The fibres clearly show the characteristics of baroreceptors. Note the loose coil systems and elongated end-lamellae.

3. Cattle *(Bos taurus)* right atrial endocardium. A thick myelinated nerve fibre of depressor character starts from the upper right corner of the picture and runs among the fascicles of connective tissue. The nuclei of the connective tissue cells remained unstained. Thin terminal nerve fibres are attached to the innervated tissue by means of end-lamellae. The majority of the end-lamellae are dense but some of them seem to have a hole in their centre.

4. Dog *(Canis familiaris)* aortic arch. Thick depressor fibres with numerous collaterals and terminal ramifications can be found in the adventitia. Compact or ring-shaped end-lamellae of various sizes can be observed among the terminal fibres.

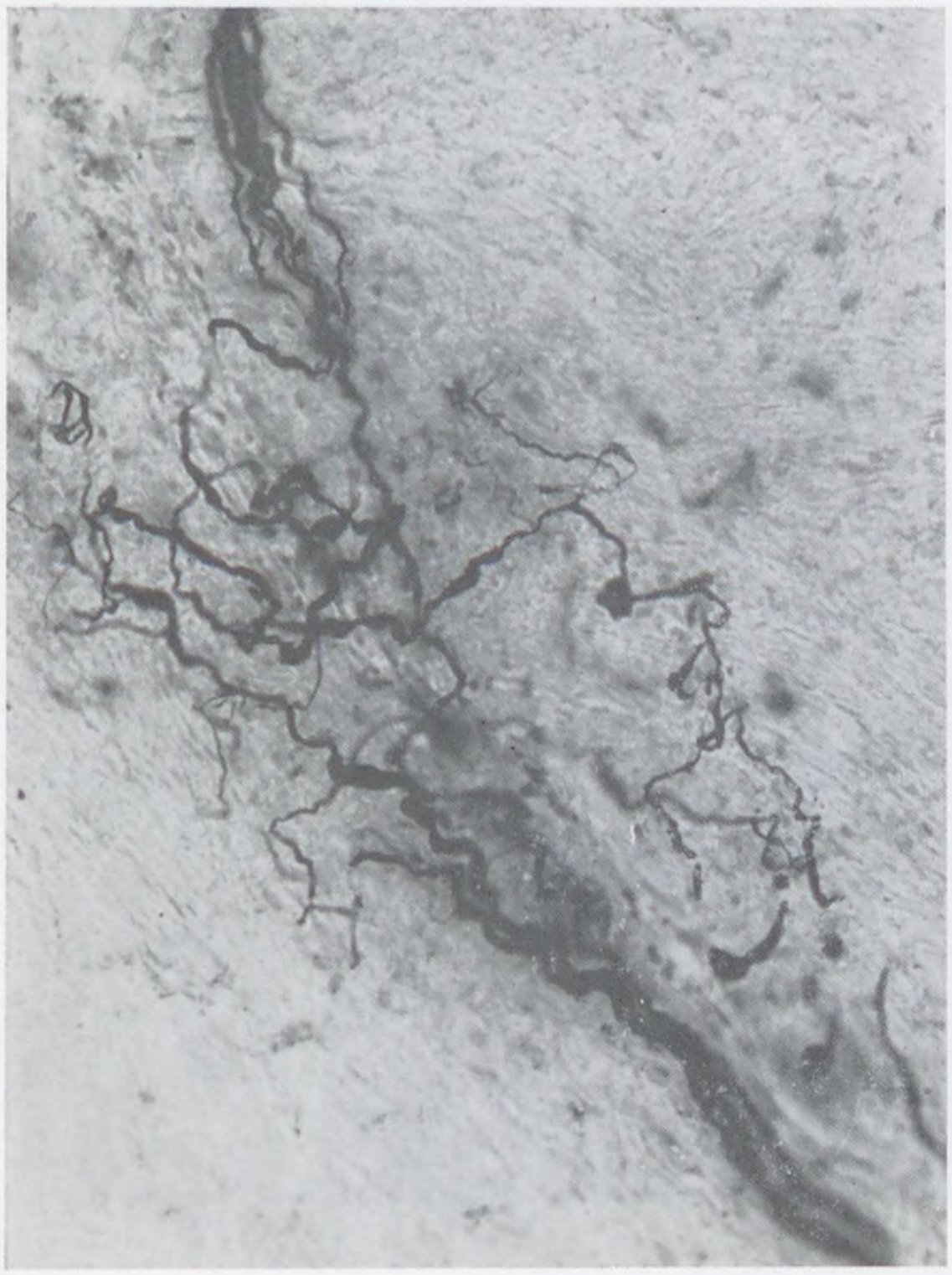

1

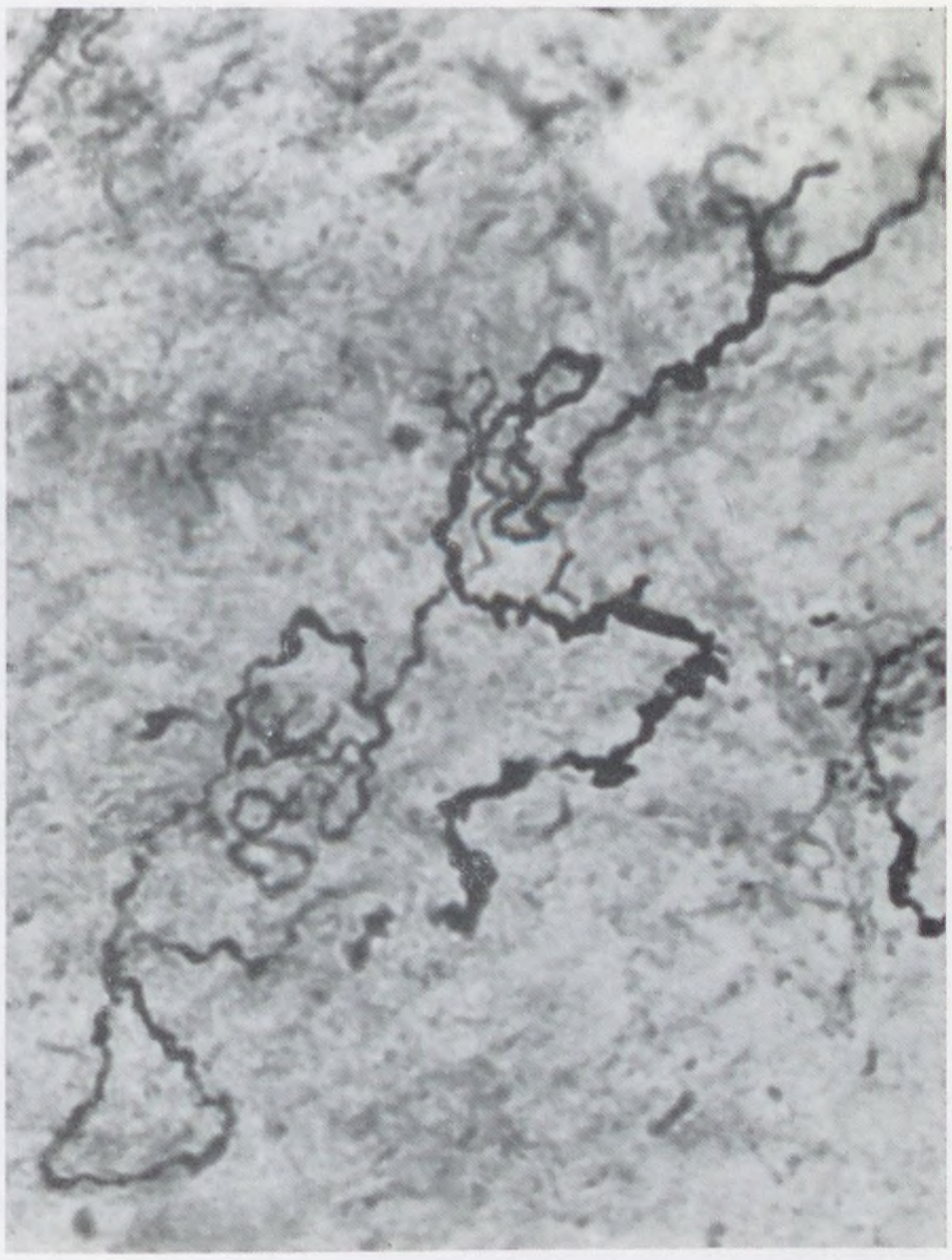

2

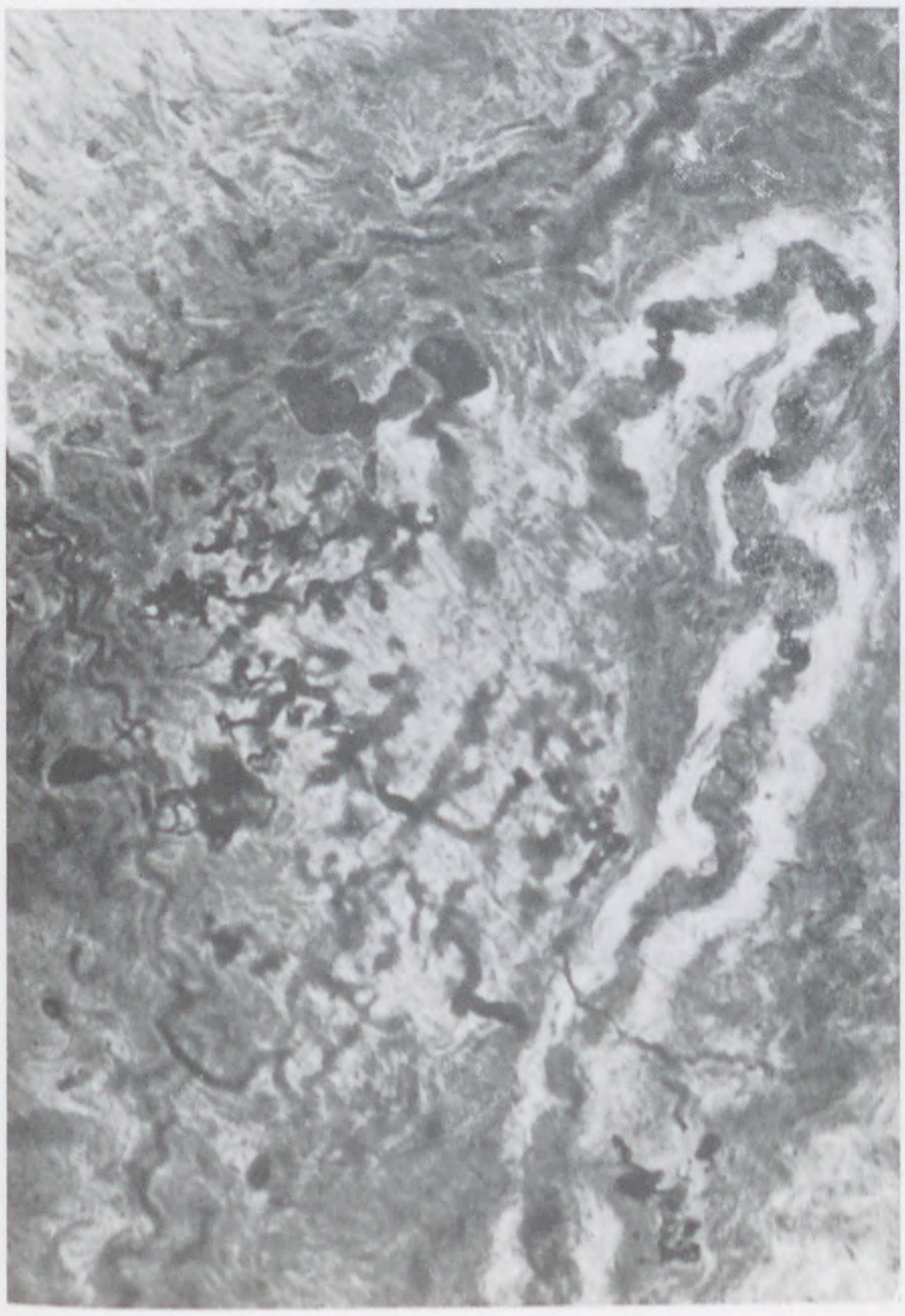

3

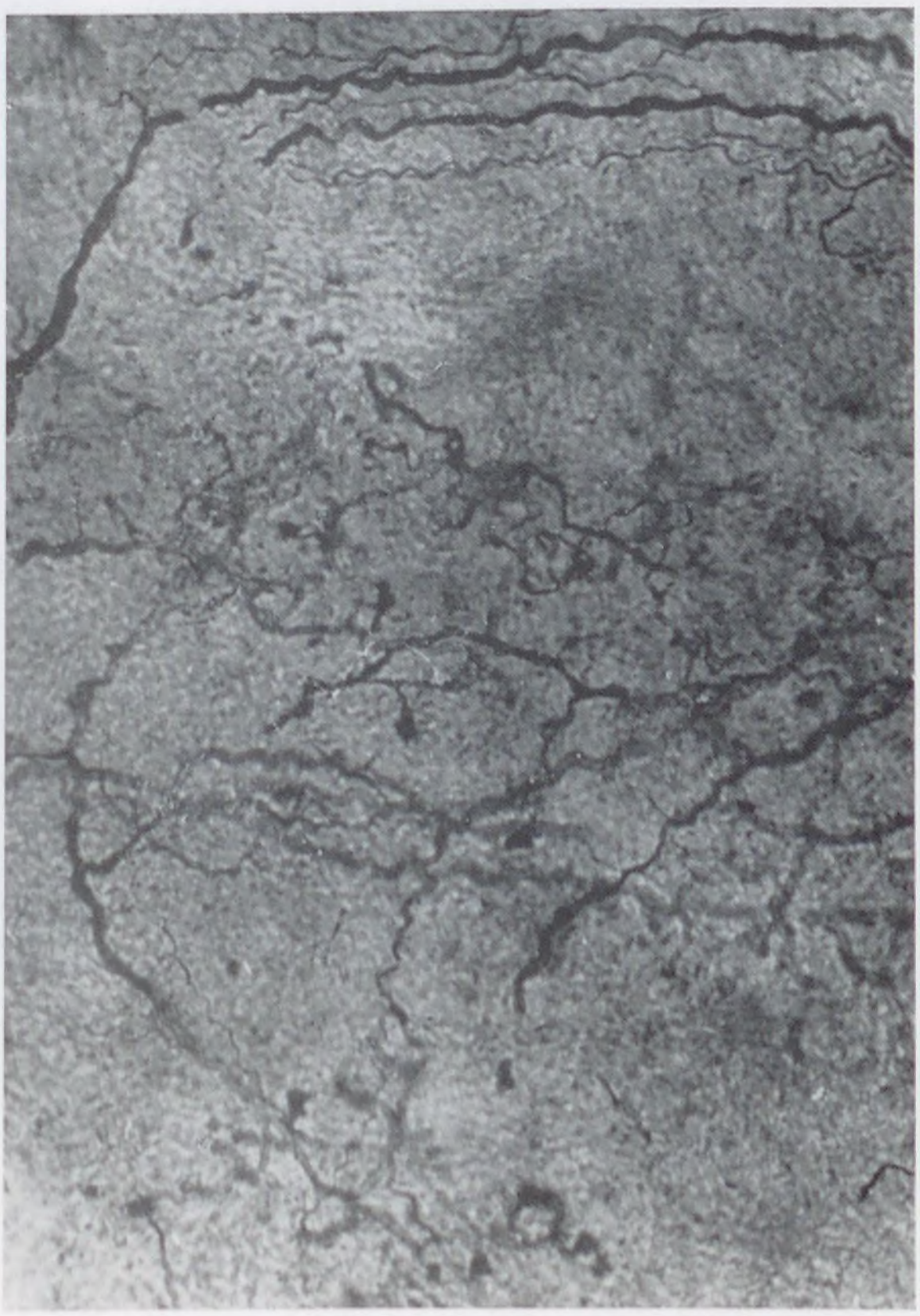

4

Plate 107

Baroreceptor terminal systems of the aortic arch

Coloured photomicrographs.
Bielschowsky–Gros silver impregnation

1. Cattel *(Bos taurus)* aortic arch. An extensive, loose terminal coil system appears among the connective tissue fascicles and nuclei of connective tissue cells. The terminal arborization is made up of several thick depressor fibres terminating in end-lamellae.

2. Human aortic arch. Two longitudinally cut capillaries can be seen among the pale collagenous fibres and connective tissue nuclei. Note the downward coursing thick varicose nerve fibre with thin collaterals terminating in large, trefoil-shaped end-lamellae.

3. Hog *(Sus scrofa domestica)* aortic arch with a depressor terminal nerve fibre system in the adventitia. The depressor terminal fibres ramify and the end-lamellae appear among connective tissue fascicles, nuclei and smooth muscle cells arranged occasionally in groups. The end-lamellae are either elliptical or segmented.

4. Adventitia of the bovine *(Bos taurus)* aortic arch. An abundant terminal nerve fibre system is to be found among the longitudinally arranged connective tissue fascicles and the nuclei of connective tissue cells. The terminal arborization is composed of thick fibres which ramify and form a rich end-coil system. The fine terminal fibres end in large end-lamellae. It is remarkable that the varicosities along the depressor fibres are interconnected by almost invisible axonal segments.

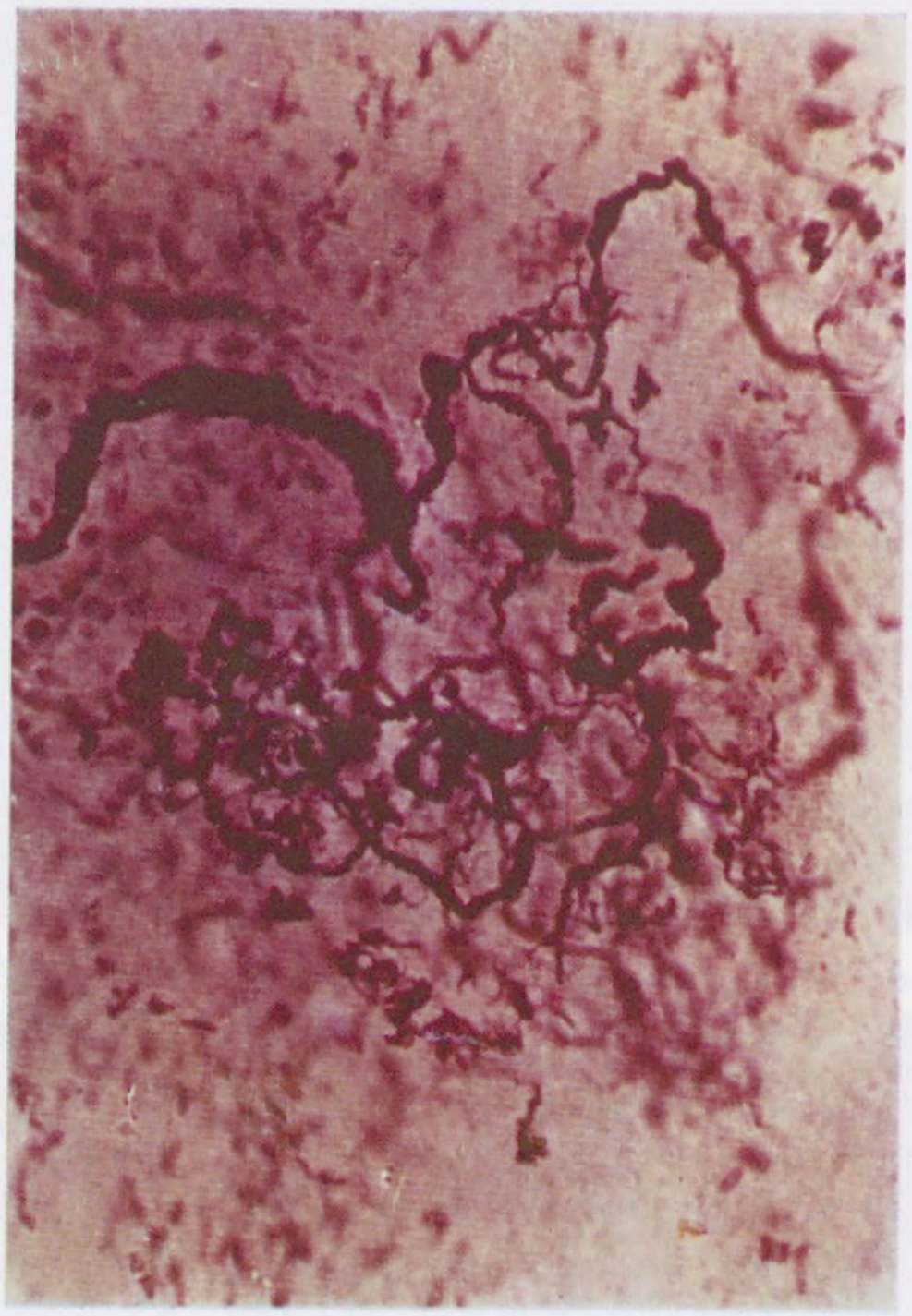
1

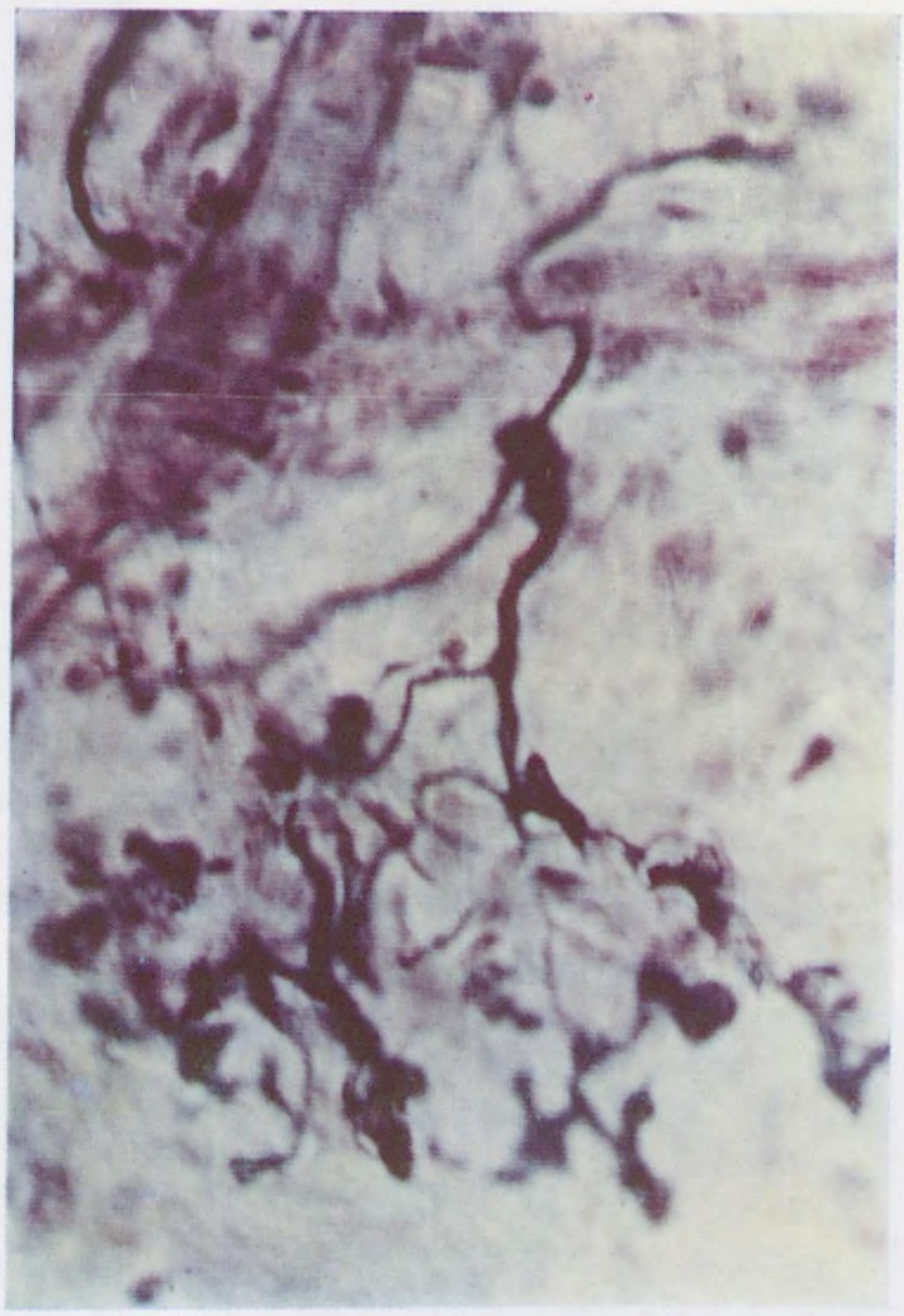
2

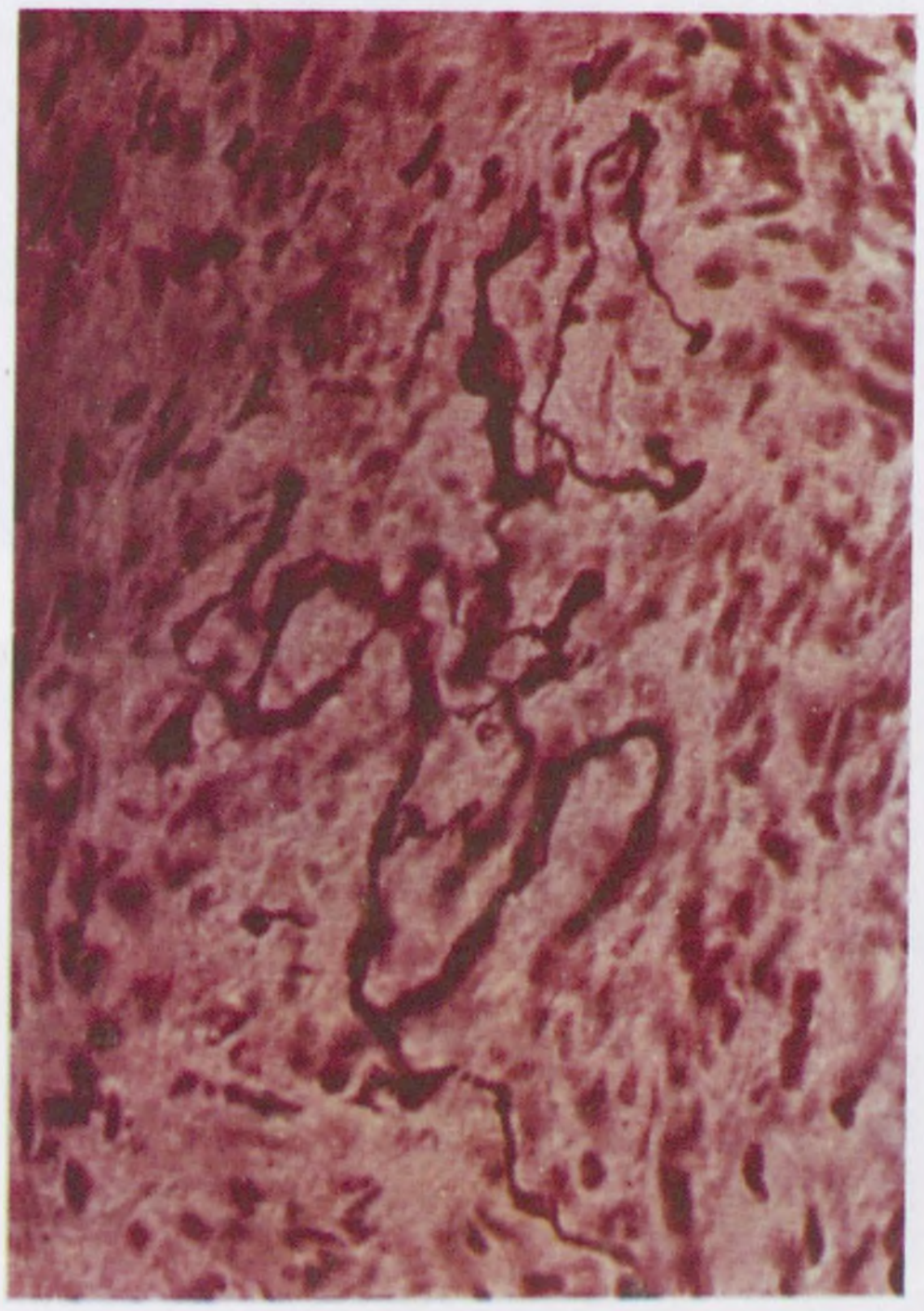
3

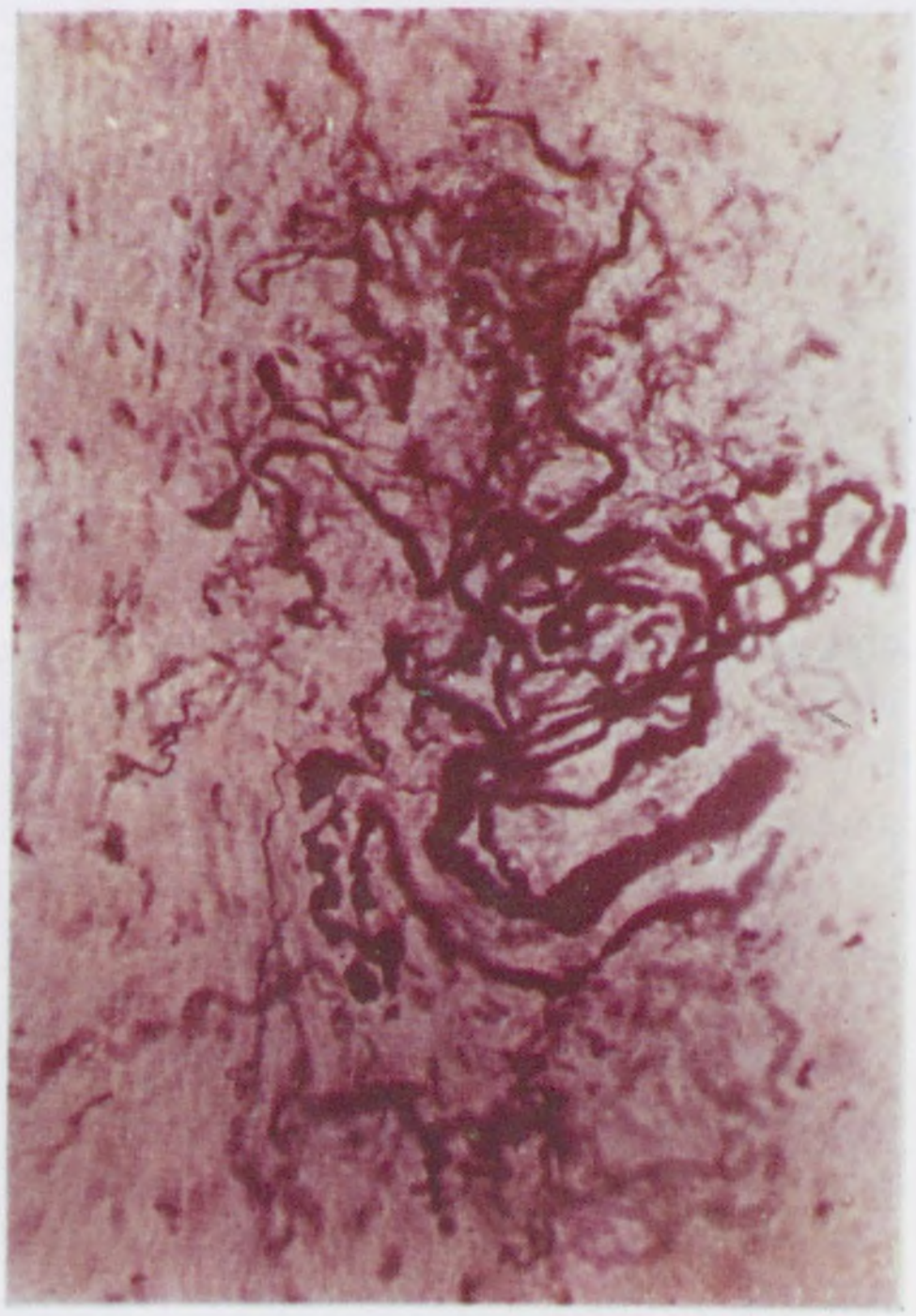
4

Plate 108

Receptors of the aortic arch

Coloured photomicrographs

1. Hog *(Sus scrofa domestica)* aortic arch. Bielschowsky–Gros silver impregnation. Numerous nuclei of connective tissue cells are visible in the inner layer of the densely structured adventitia. Note the groups of connective tissue fascicles (left) and the parallel course of smooth muscle cells (right). A myelinated nerve fibre starts at the upper left corner and arborizes in the middle of the picture. Terminal branches give rise to end-lamellae and end-bulbs. A typical feature of the terminal system is that the terminal branches are thicker than the parent fibre.

2. Hog *(Sus scrofa domestica)* aortic arch. Bielschowsky–Gros silver impregnation. Note connective tissue fibres and nuclei of the adventitial connective tissue cells. A depressor nerve fibre starts from the bottom of the picture and divides into two branches. These, after the characteristic wavy course, extend like an ivy-leaf and terminate at the boundary between adventitia and media.

3. Adventitia of the human aortic arch. Jabonero's silver impregnation. Among the nuclei of the connective tissue cells and connective tissue fascicles a thick depressor fibre bearing a large varicosity runs from left to right and breaks up into two branches. As a result of further repeated branchings, a loose plexus of the nerve fibre is formed with peculiarly structured intercalated neurofibrillar end-bulbs. Bulbous shape of the terminals suggests pathological changes.

4. Dog *(Canis familiaris)* aortic arch. Jabonero's silver impregnation. Arborization of the depressor fibres can be seen in a peculiar nest of the connective tissue. The abundant terminal fibres – wavy, ramifying, thick and unmyelinated – terminate in end-lamellae or ring-like endings.

5. Dog *(Canis familiaris)* aortic arch. Bielschowsky–Gros silver impregnation. The picture shows the wall of the aorta where the branches of the vagus nerve (ramus aorticus n. vagi) join it. The wavy, thick baroreceptor fibres bearing varicosities constitute a loose plexus in the connective tissue of the outer adventitial layer. Note the terminal system of depressor origin in the centre of the picture.

6. Hog *(Sus scrofa domestica)* aortic arch. Bielschowsky–Gros silver impregnation. Two parallel running depressor fibres can be seen in the connective tissue. The one on the left only traverses the picture while the other one, surrounded by an extremely thick myelin sheath, breaks up into branches which terminate in round lamellae. Nuclei of connective tissue cells are interspersed with elements of the terminal system.

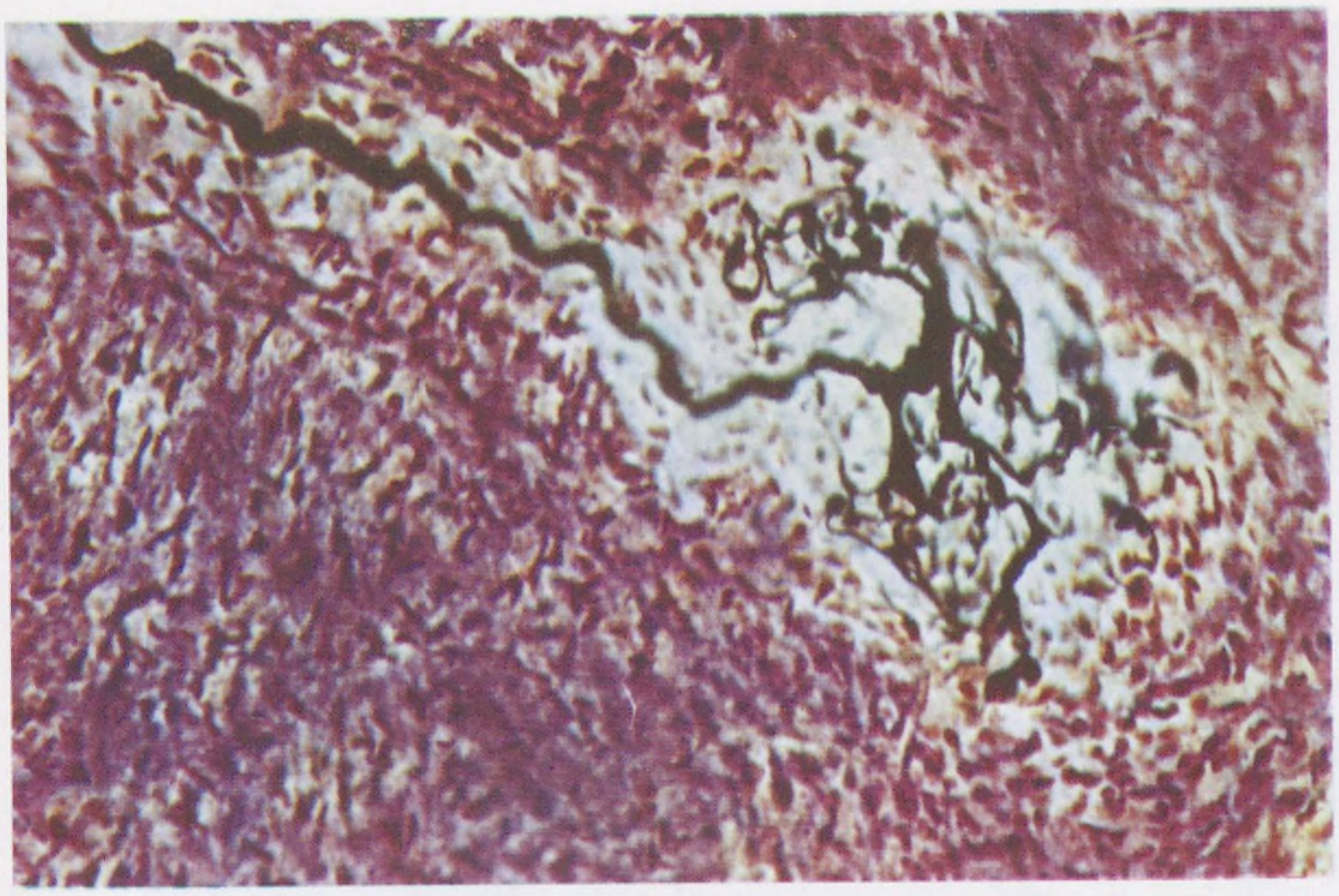

1

2

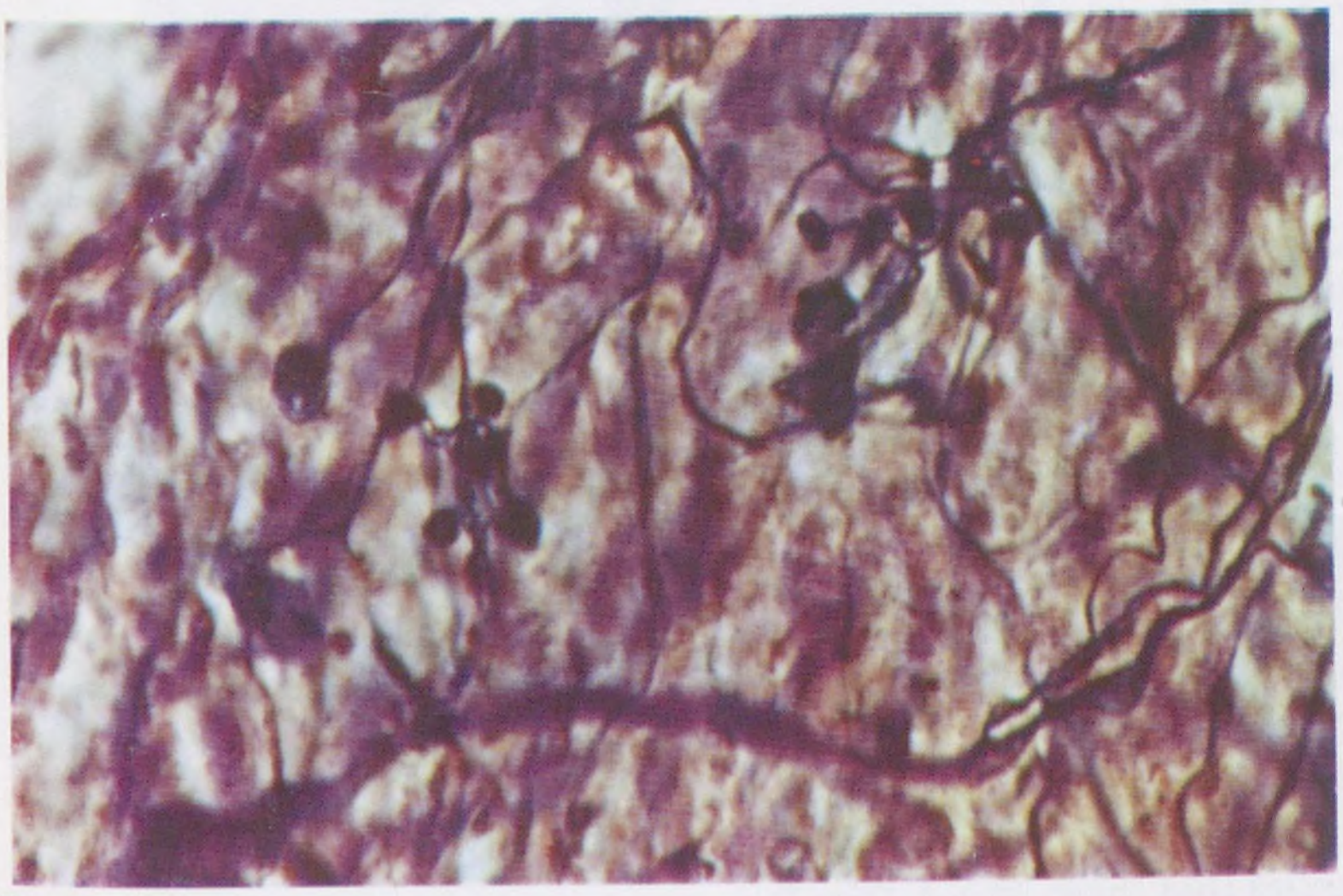

3

4

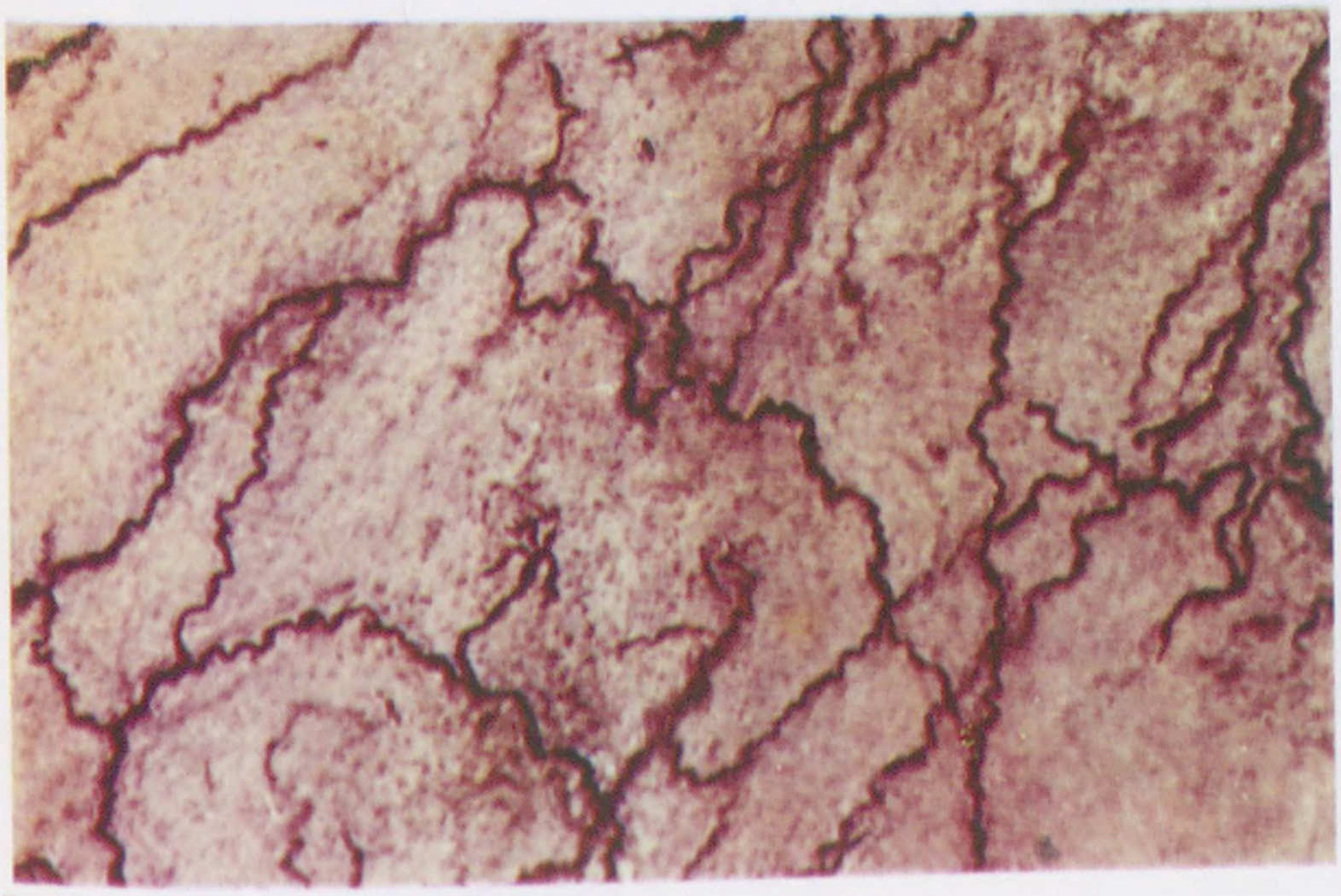

5

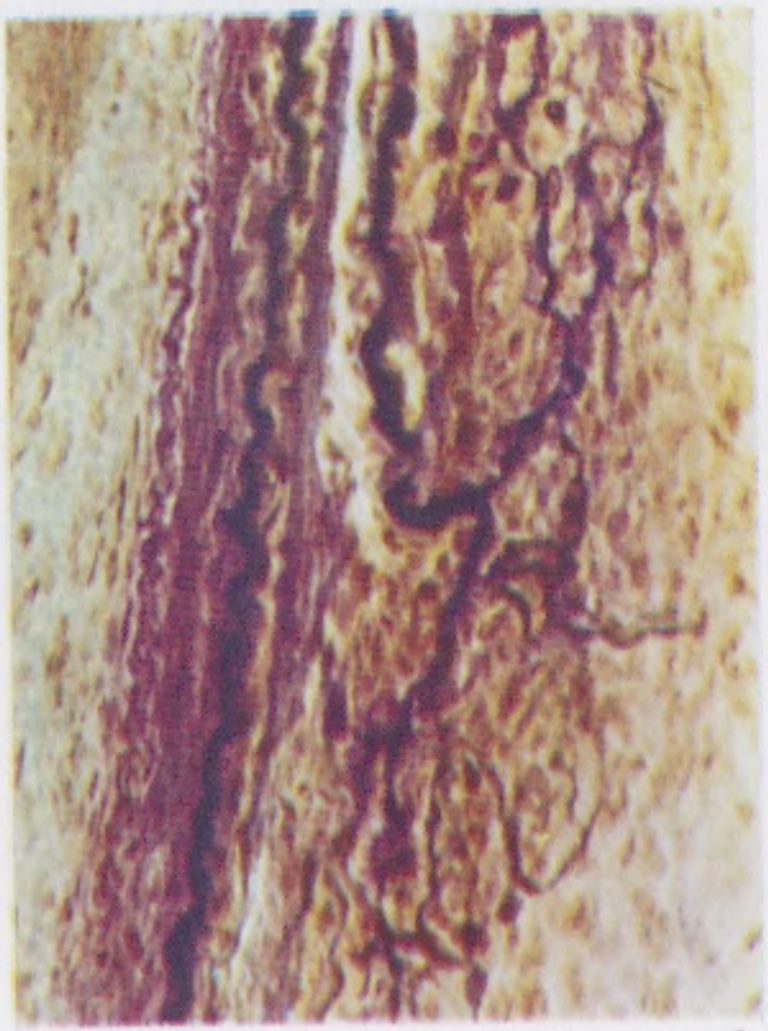

6

Plate 109

Human common carotid artery

Bielschowsky–Gros silver impregnation

The terminal ramification of two myelinated nerve fibres can be seen in this section obtained from the upper segment of the common carotid artery. Due to repeated arborizations of secondary and tertiary branches, the upper fibre (b) has a more abundant terminal system than the lower one (a). Varicosities, enlarged segments of the fibres and the intercalated lamellae (c) varying considerably both in shape and size, characterize the arborization. The size, number and peculiar shape of the intercalated lamellae suggest the presence of early degenerative processes. The fine, meandering axons terminate in neurofibrillar end-lamellae (d). The neurofibrils (e) are clearly visible in the lamellae. The nerve plexuses and the terminal systems are embedded in the adventitial connective tissue comprising fascicles (f) and nuclei of connective tissue cells (g).

This picture proves that baroreceptors occur in the wall of the upper segment of the common carotid artery close to its bifurcation into external and internal carotid arteries, i.e. in the vicinity of the carotid sinus. This finding further implies that these receptors participate in the control of blood pressure. It is noteworthy that large numbers of neurofibrillar end-lamellae can mainly be found in preparations obtained from emaciated individuals.

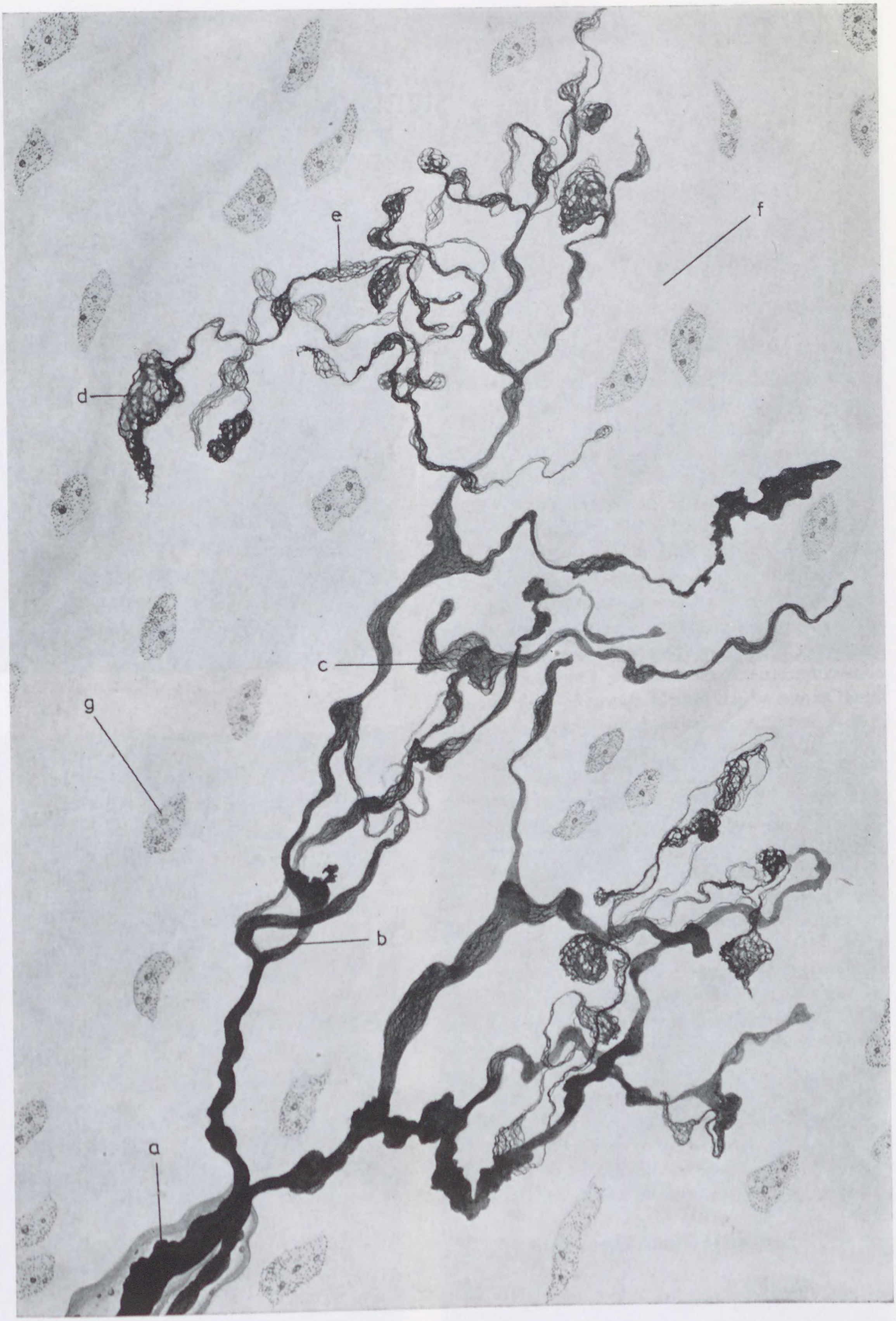
e
f
d
c
g
b
a

Plate 110

Cardiovascular receptor systems

Photomicrographs

1. Right atrium of the feline heart *(Felis domestica).* Jabonero's silver impregnation. Connective tissue fibres and nuclei of the endocardium (top) as well as part of the myocardium can be seen. A large terminal coil enters the picture at the upper right corner. The fine terminal fibres end in small lamellae. This type of cardiovascular receptor can often be found in the endocardium of the right atrium of the feline heart. It is interesting that it invades the myocardium and is surrounded by a large number of connective tissue cells.

2. Fragment of the adventitia of the human aortic arch. Jabonero's silver impregnation. A thick smooth depressor fibre runs upwards and divides repeatedly into finer branches among the collagenous connective tissue fascicles. Fine and long terminal axons, which appear almost in their integrity in this preparation cut in a favourable plane, terminate in large lamellar systems. The frequent occurrence of similar structures in the wall of the aorta suggests that the depressor system belongs to the most sensitive pressoreceptor apparatuses.

3. Adventitia of the hog's *(Sus scrofa domestica)* aortic arch. Bielschowsky–Gros silver impregnation. The baroreceptor (depressor) fibres pass within the loose connective tissue layer. Periodic thickenings characterize the thick nerve fibres. Collateral branches running upwards and downwards emerge from the thick fibre, and form networks of nerve fibres with spheroid varicosities. These terminate in dense or occasionally elongated end-lamellae. Frequent occurrence of varices along the nerve fibres is characteristic of the porcine aortic arch.

4. Adventitia of the canine *(Canis familiaris)* carotid sinus. Bielschowsky–Ábrahám silver impregnation. An extensive plexus of nerve fibres as well as a loose nerve fibre coil (upper left corner) can be seen in this picture. A thick axon, with branches ending in star-shape lamellae leaves the coil.

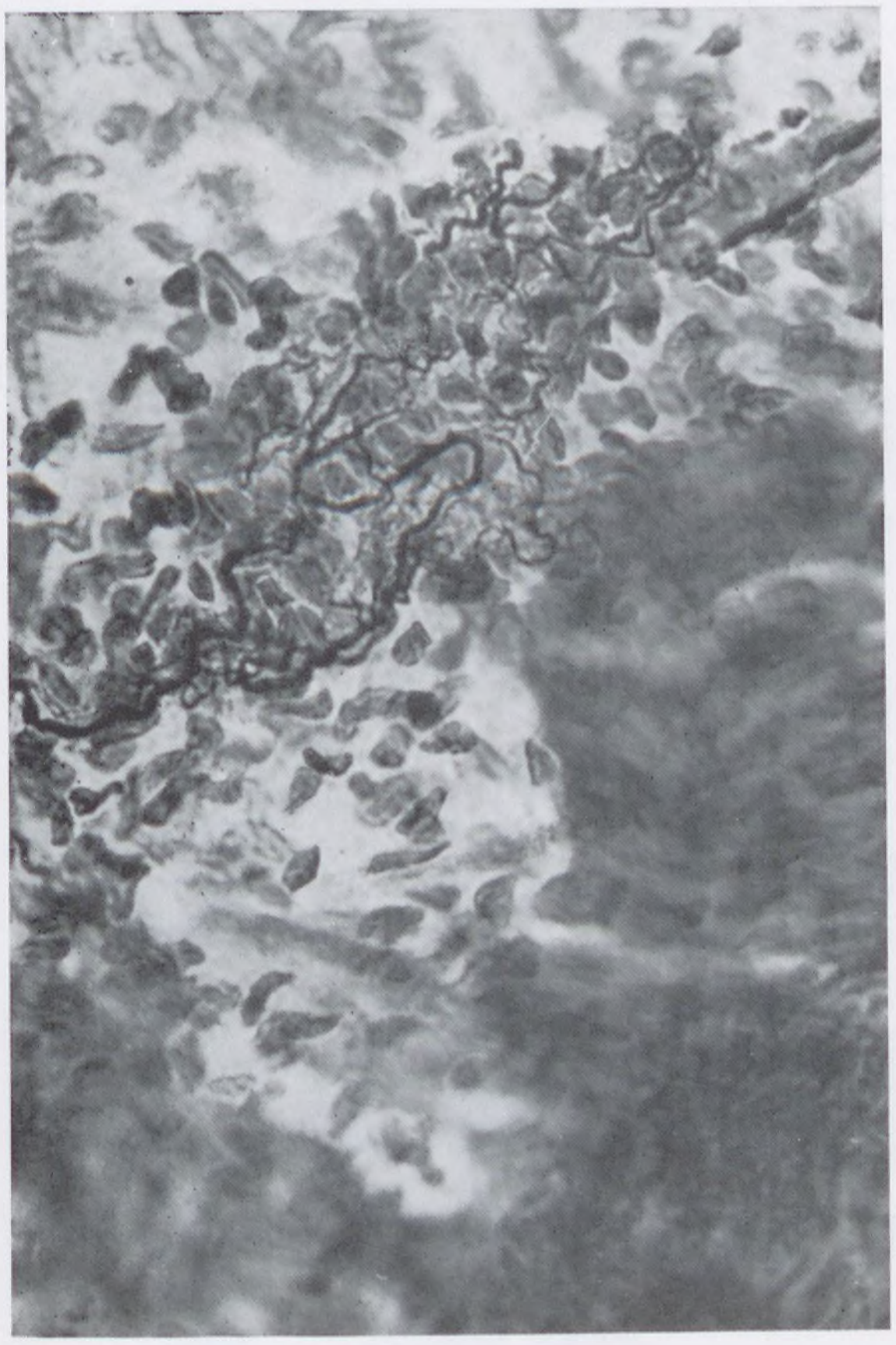
1

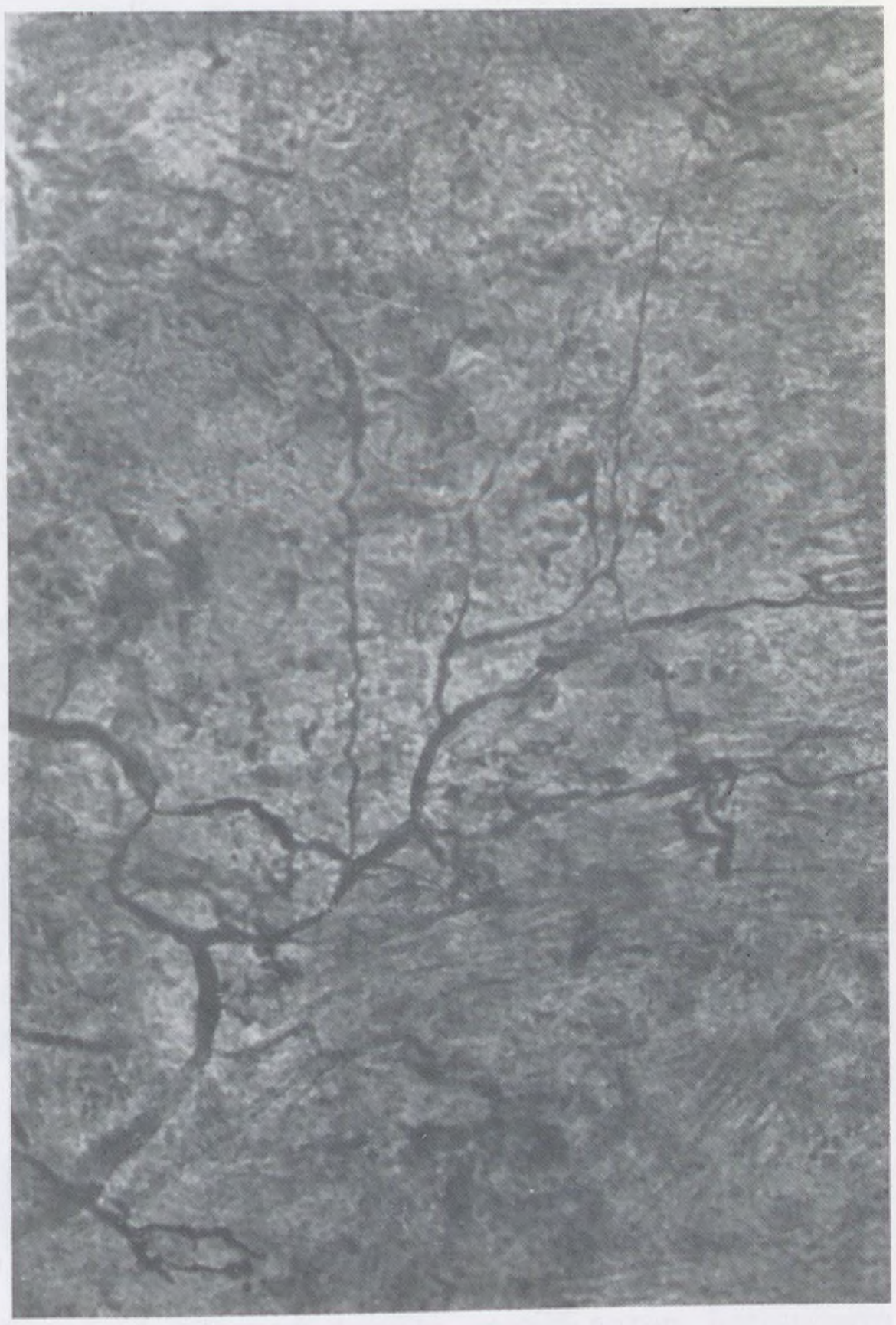
2

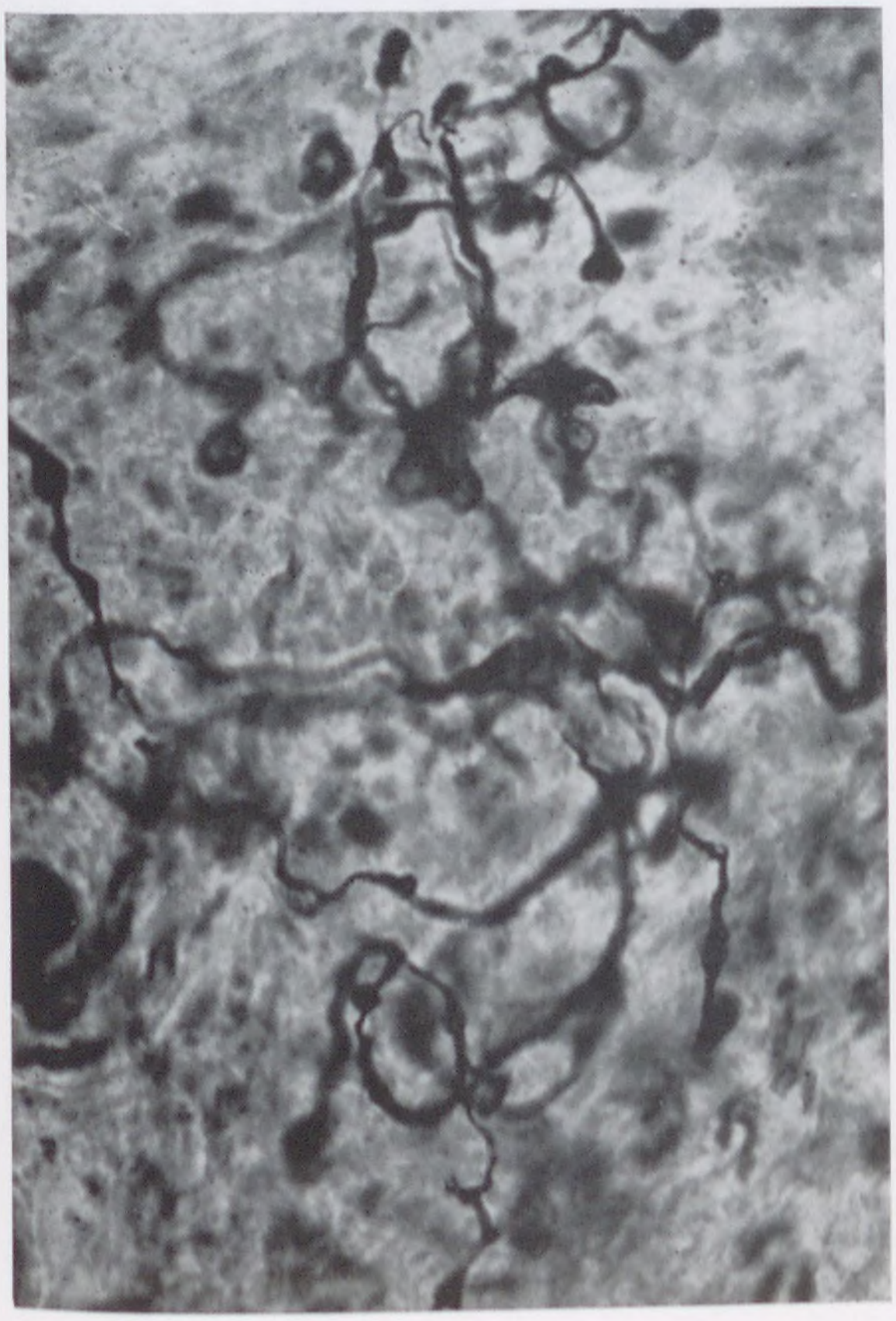
3


4

Plate 111

Dog *(Canis familiaris)* carotid sinus

Bielschowsky–Ábrahám silver impregnation

A thick depressor axon (a) filled with neurofibrils can be seen on the left. Collateral branches (b) emerging from the thick axon have intercalated lamellar systems (d) with loosely arranged neurofibrils (c). Further ramification of the collaterals results in fine nerve fibres which terminate in end-lamellae (e).

Comparative neurohistological comments

Among the domestic animals (dog, hog, cattle and sheep) the dog has been found to have the richest innervation of the carotid sinus. Thick and wavy myelinated nerve fibres almost completely cover every other tissue elements in the carotid sinus. The terminal arborizations are simple, there are only few end-lamellae, but these are large, dense and long. We think that there is a good correlation between the highly mobile way of life of the dog and the development of the arterial baroreceptor systems. This applies to the baroreceptors of both the aortic arch and the carotid sinus, although the fibres of the former system derive from the vagus nerve while those of the latter are of glossopharyngeal origin. On the basis of some especially well-impregnated sections it might be assumed that also vagal fibres participate in the innervation of the carotid sinus, since a few thick fibres with a peculiar branching system terminate in large star-shaped lamellae.

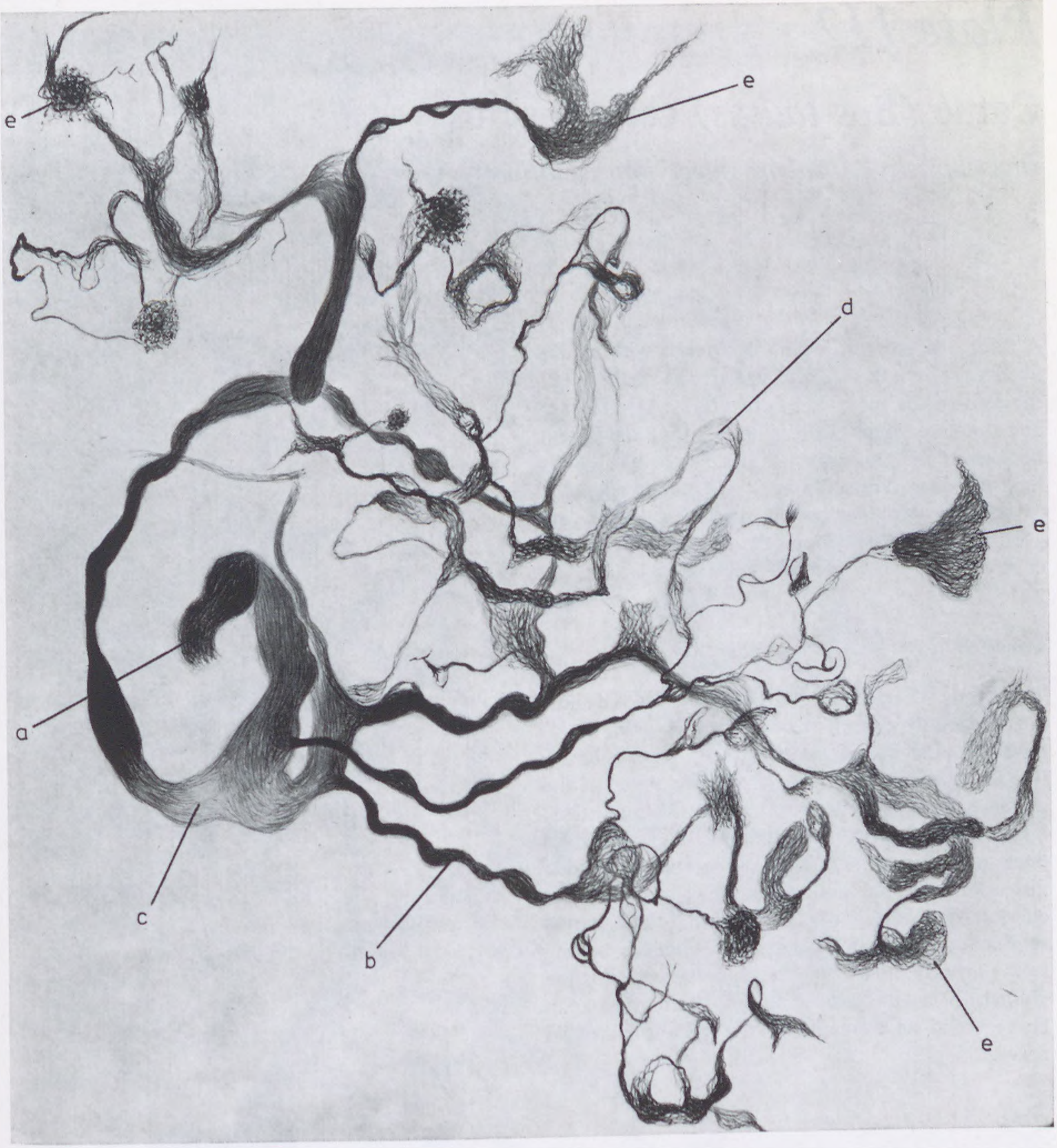
e
e
d
e
a
c
b
e

Plate 112

Cattle *(Bos taurus)* carotid sinus

Bielschowsky–Ábrahám silver impregnation

A thick depressor fibre densely packed with neurofibrils (c) might be followed among the nuclei (b) of the cells of the loose connective tissue (a). Thicker and thinner segments alternate all along the parent fibre and collateral branches (d). At the end of the long terminal ramifications (e) dense, occasionally cavernous end-lamellae (f) are seen. They are grouped like cherries along the thin branches of the cherry tree.

Comments

The terminal nerve fibres of the bovine carotid sinus are characterized by thick baroreceptor fibres, abundant terminal arborizations and frequent alternation of thin and thick segments. Two types of the glomerular end-formations can be distinguished: large, loosely structured glomeruli and elongated dense glomeruli. These latter are composed of thick fibres and of their collaterals which do not bear end-lamellae. It might be assumed that the terminal ramifications containing large end-lamellae belong to the arborization of the vagus nerve, whereas the glomeruli – both the loose and the dense ones – can be regarded as elements of the glossopharyngeal nerve.

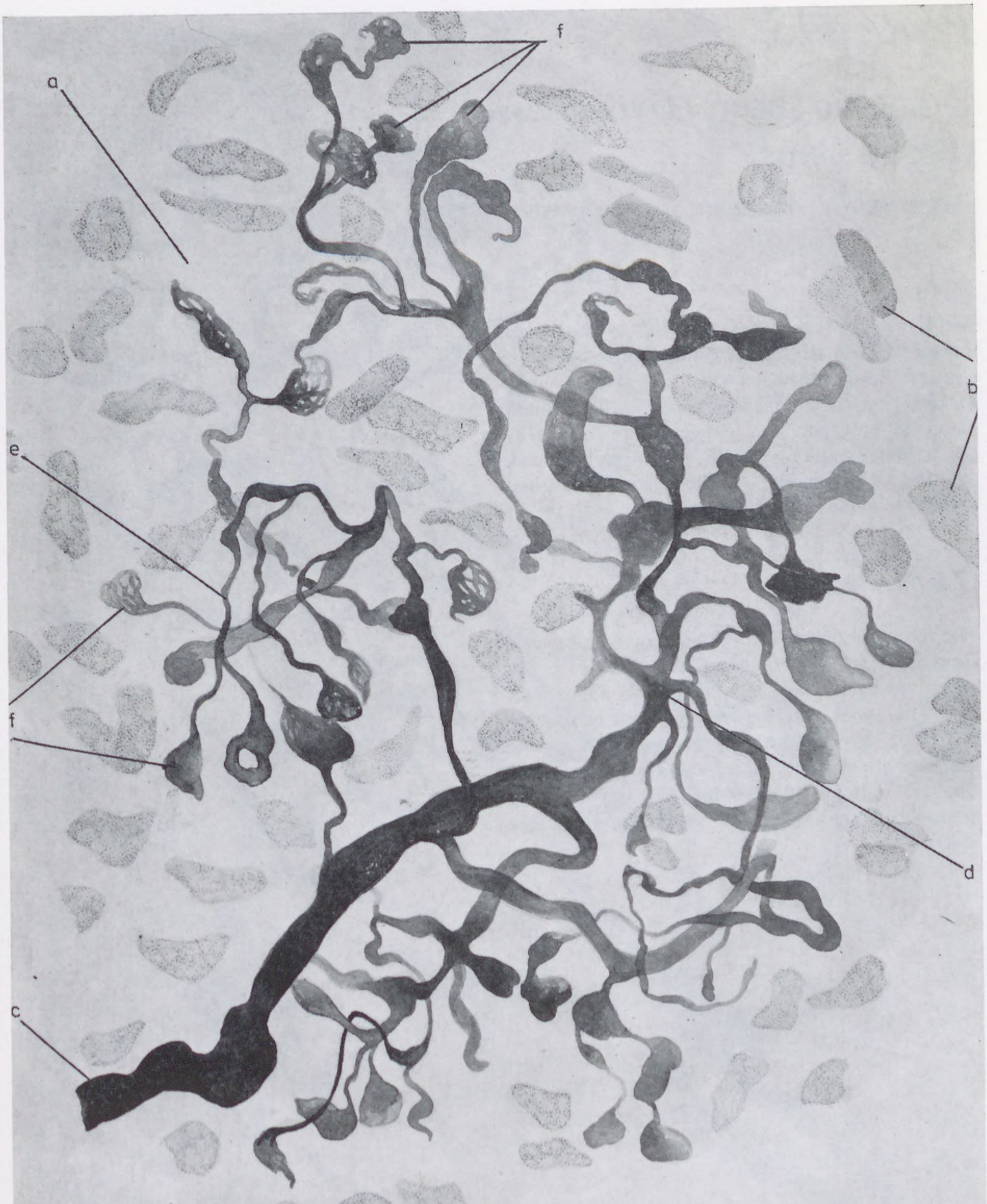
f
a
b
e
f
f
d
c

Plate 113

Domestic sheep *(Ovis aries)* carotid sinus

Bielschowsky–Ábrahám silver impregnation

A thick axon (a) runs and sends off two branches among the pale adventitial connective tissue fascicles and nuclei of the connective tissue cells. Neurofibrils (b) and the intercalated lamellae (c) are found along the branches. Two glomeruli are formed by the terminal branches which end in club-shaped, elliptical, or irregular end-lamellae (d) around within the glomeruli.

Comments

The receptors of the carotid sinus of the domestic sheep are unique as compared with those found in other mammals, although the overall appearance of the neuronal elements resemble that in the dog and cattle. The terminal systems deriving from the branches are arranged in a loose glomerular form. The termination of the terminal fibres in elongated neurofibrillar glomeruli is a special feature of the sheep.


d
d
c
b
a

Plate 114

Receptors in the carotid sinus

Coloured photomicrographs.
Bielschowsky–Gros silver impregnation

1. Adventitia of the canine carotid sinus *(Canis familiaris)* with nuclei of connective tissue cells and loosely arranged, wavy connective tissue fibres. A rich plexus of nerve fibres terminating in large neurofibrillar end-lamellae dominates the picture.

2. Human carotid sinus. Rich terminal ramification of a deformed nerve fibre can be seen in the loose connective tissue of the tunica adventitia (left) and among the smooth muscle fascicles of the tunica media (right). Form and structure of the nervous elements indicate an advanced stage of degeneration.

3. Domestic sheep *(Ovis aries)* carotid sinus. A nerve fascicle surrounded by the smooth muscle cells of the tunica media traverses the connective tissue. It breaks up into individual nerve fibres, the terminal ramifications of which contain numerous triangular neurofibrillar end-lamellae.

4. Human carotid sinus. Two larger nerve fibres can be found in the loose connective tissue. A tapering fine axon runs towards the upper right corner of the picture, then it disappears in the connective tissue. The other, arborizing fibre is a typical depressor nerve; the terminal systems that contain endings resembling ivy leaves show signs of pathological changes.

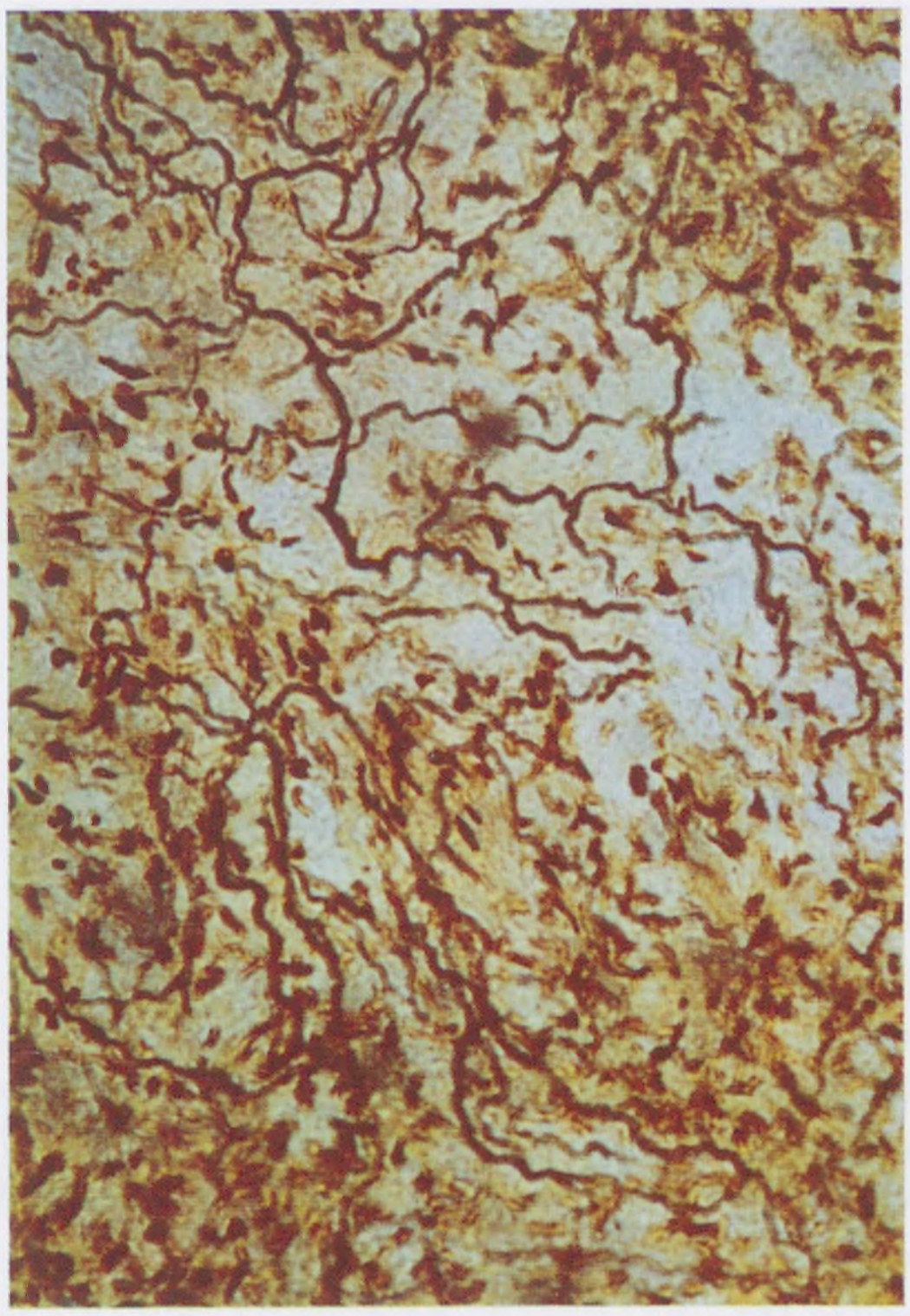

1

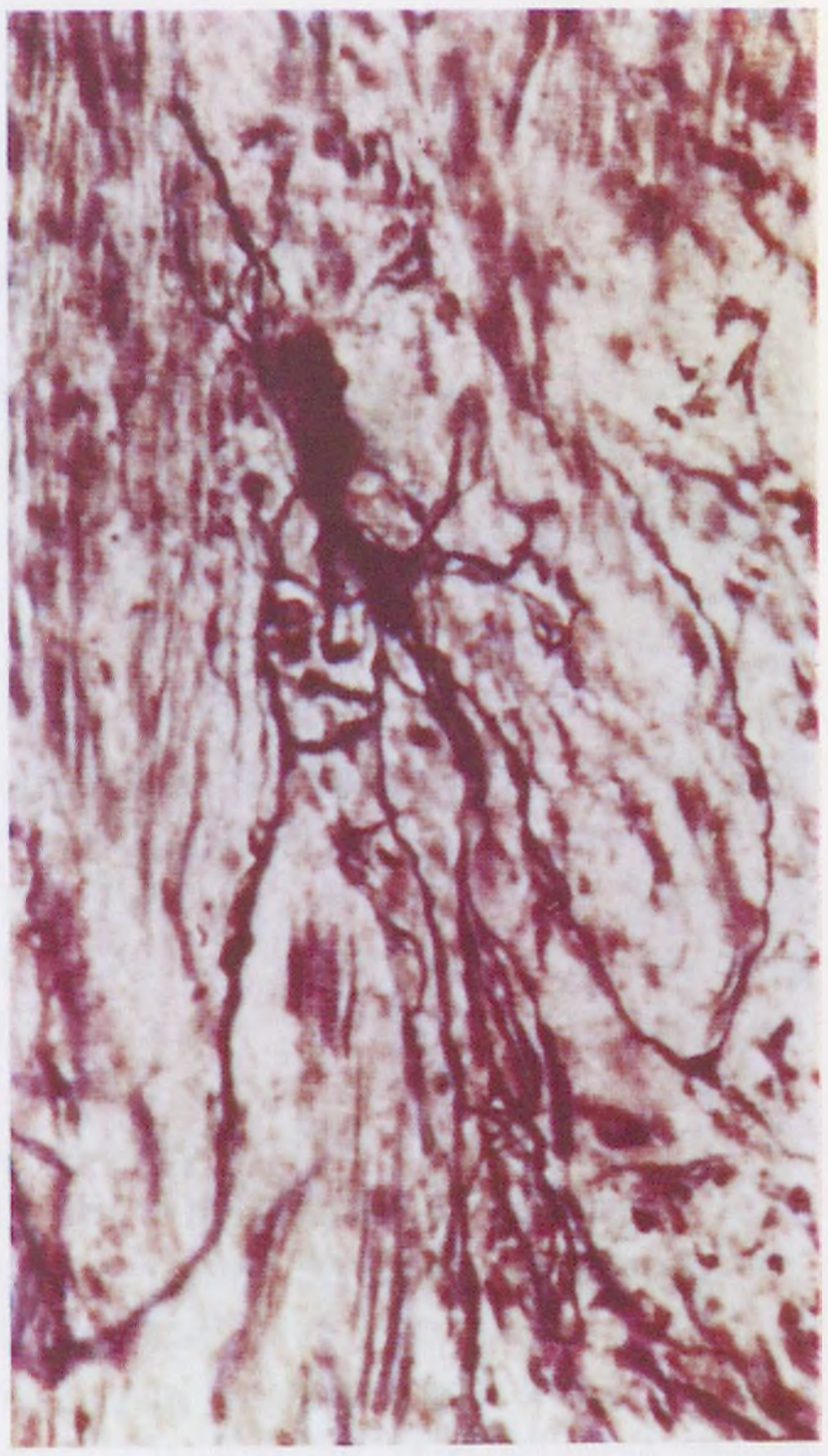

2

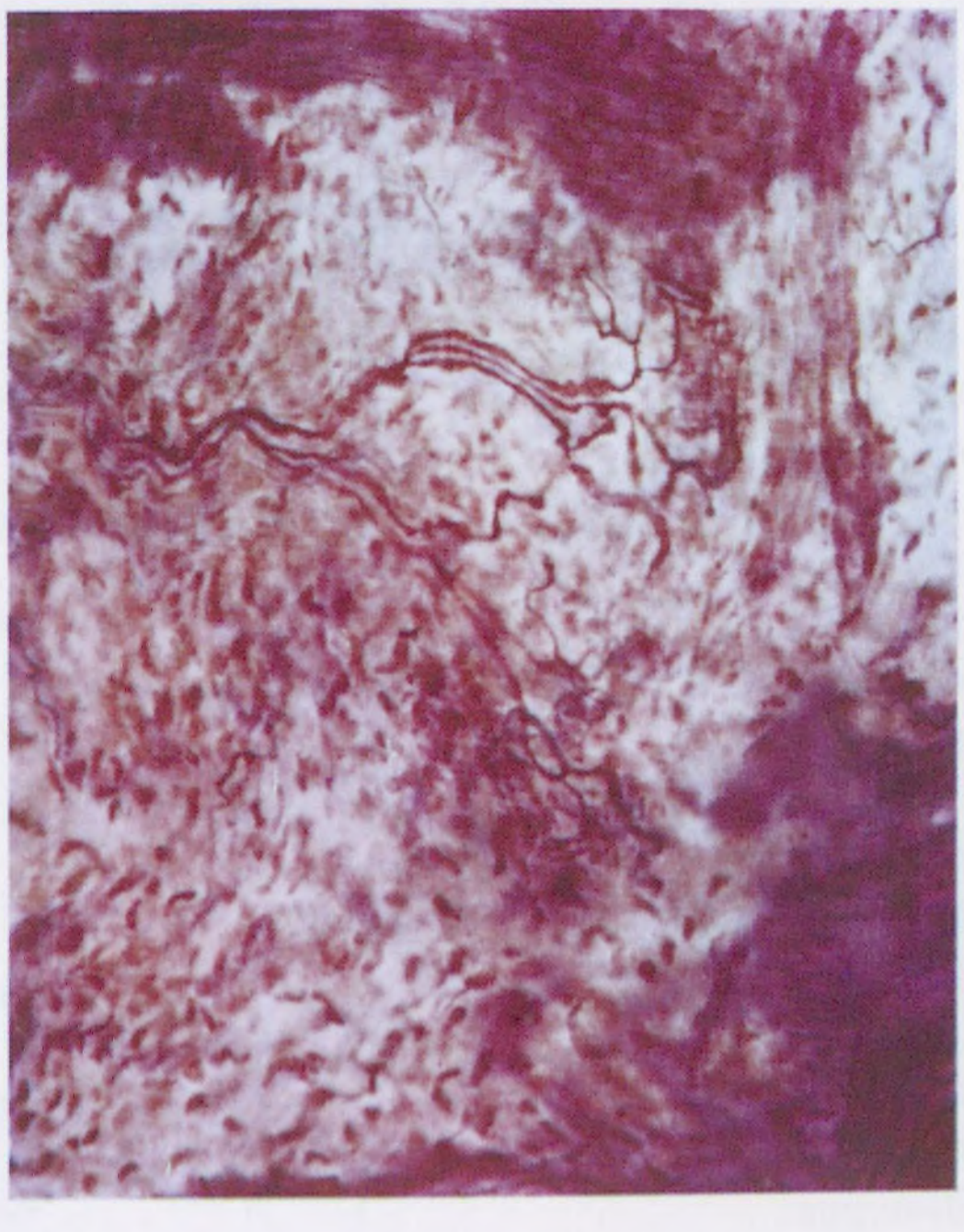

3

4

Plate 115

Human carotid sinus

Bielschowsky–Gros silver impregnation

Terminal system of a rich nerve fascicle in the wall of the human carotid sinus. Such a picture can be obtained only very exceptionally. The nerve fascicle (a) composed of fine and of thick fibres (b) can be seen in the lower left corner. Axons leaving the fascicle arborize repeatedly and form a loose terminal plexus. The branches, gradually tapering off, bear intercalated neurofibrillar lamellae and finally terminate in neurofibrillar end-lamellae. It is a unique finding that all the branches of the thick varicose (e) nerve fibre running upwards on the left side of the fascicle bear neurofibrillar end-lamellae (c). Neurofibrils (d) can be revealed both in the intercalated lamellae and end-lamellae.

Functional and neurohistological comments

The carotid sinus containing similar receptor systems is a bulbous thickening located at the basal part of the internal carotid artery. The general histological structure of the carotid sinus is similar to that of the internal carotid artery. The only difference is that the wall of the carotid sinus is thinner. The baroreceptor terminals, similar in structure to those of the aorta, are arborizations of Hering's sinus nerve, a branch of the glossopharyngeal nerve. The end-systems of the sinus nerve are rich both in animals and in man. In suitably impregnated preparations sectioned parallel to the surface of the blood vessel one sees nothing but nerve fibres and endings. Although the nerve fibres and endings are very similar in structure, quantitative differences exist between individual species.

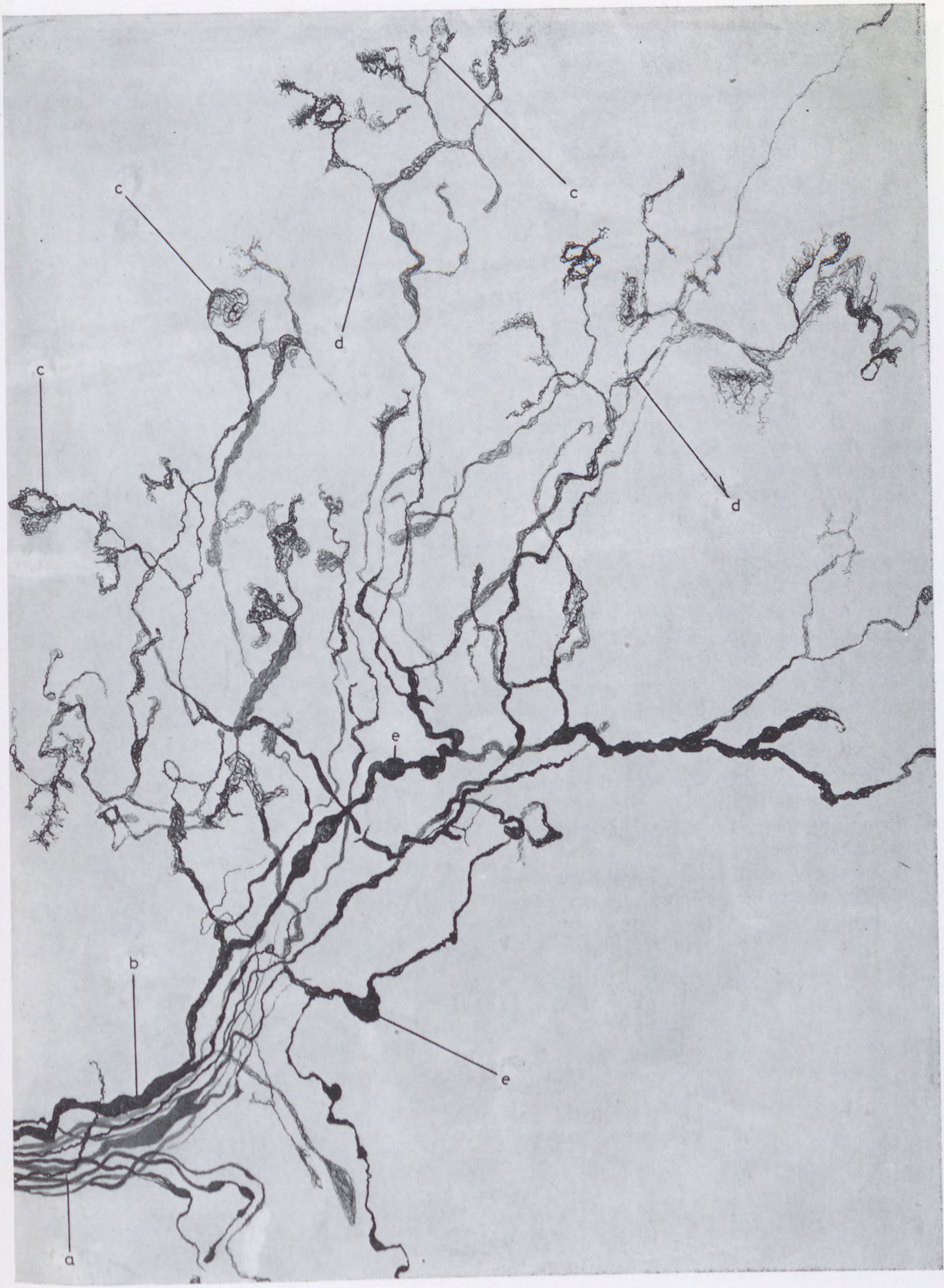
c
c
d
c
d
c
e
b
e
a

Plate 116

Human carotid sinus

Bielschowsky–Gros–Cauna silver impregnation

A bundle of nerve fibres proceeds in the adventitia of the human carotid sinus, among the connective tissue fibres and nuclei of connective tissue cells (f). Thick nerve fibres (a) break up into several collaterals (b); fine terminal fibres (c) end in end-lamellae (e). Neurofibrils can be seen everywhere in the end-lamellae that vary considerably both in size and structure. Intercalated lamellae (d) can be found along both the thick and fine nerve fibres.

General comments

The wall of the human carotid sinus is richly innervated and contains various end-systems. Closer scrutiny will, however, show that they fall into two categories. One of them is a coil-like system, while the other is a dendritic one. The former comprises the terminal branches of two or three myelinated nerve fibres. The curved, interwoven terminal branches bear elongated dense or loose end-lamellae. It should be emphasized that this is only one form of the coil-like terminal systems. The structure shown in this picture belongs to this group.

The structural peculiarities of dendritic systems will be outlined in connection with the next plate.

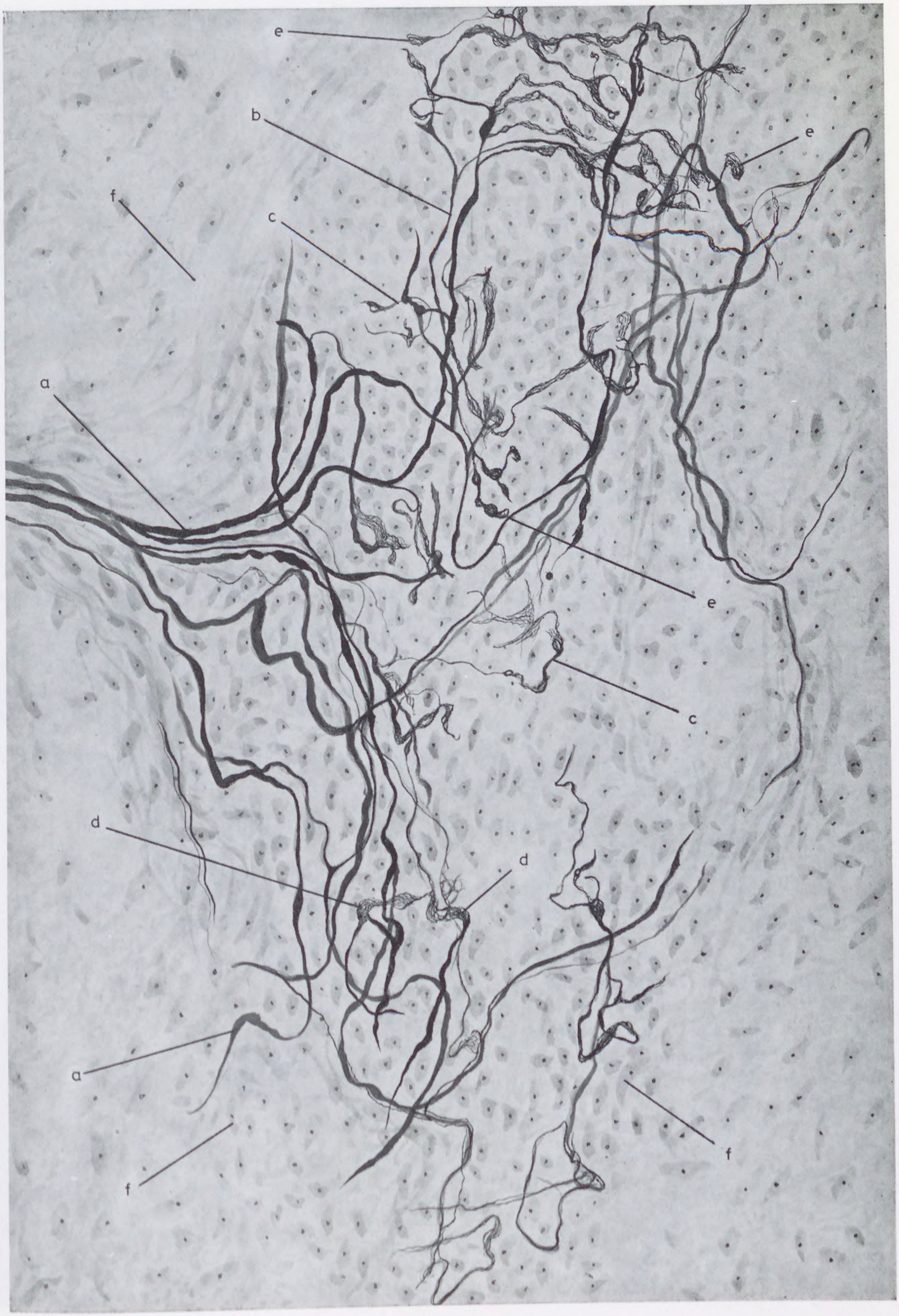
e
b
e
f
c
a
e
c
d
d
a
f
f

Plate 117

Human carotid sinus

Bielschowsky–Gros–Cauna silver impregnation

The entire terminal system of a single nerve fibre can be seen in the adventitia. A characteristic baroreceptor system appears in the connective tissue layer of the blood vessel among the nuclei of the connective tissue cells (f). The thick nerve fibre (a) sends off preterminal fibres (b). Neurofibrils are well visible all along the course of both the parent fibre and its branches. Preterminal branches are almost as thick as the main fibre and give rise to two large terminal systems. Numerous thin terminal fibres (c) end in conspicuously large end-lamellae (d), these are often close to each other without being continuous, however. Neurofibrils are clearly visible in the end-lamellae. Varicosities (e) are frequently found along all the nerve fibres.

General comments

The second type of terminal baroreceptor system found in the wall of the human carotid sinus, i.e. the dendritic terminal structure, is demonstrated in this picture. A single thick myelinated nerve fibre arborizes repeatedly. The resulting preterminal fibres bear neurofibrillar end-lamellae. Thus, two well-defined types of receptors can be distinguished in the wall of the human carotid sinus. It is most likely that the coil-like end-systems originate from the glossopharyngeal nerve while the dendritic ramifications belong to the sensory fibre system of the vagus nerve. This explanation is supported by the occurrence of neurofibrillar end-lamellae which are similar to those found in the baroreceptor terminal fibres of the aortic arch.

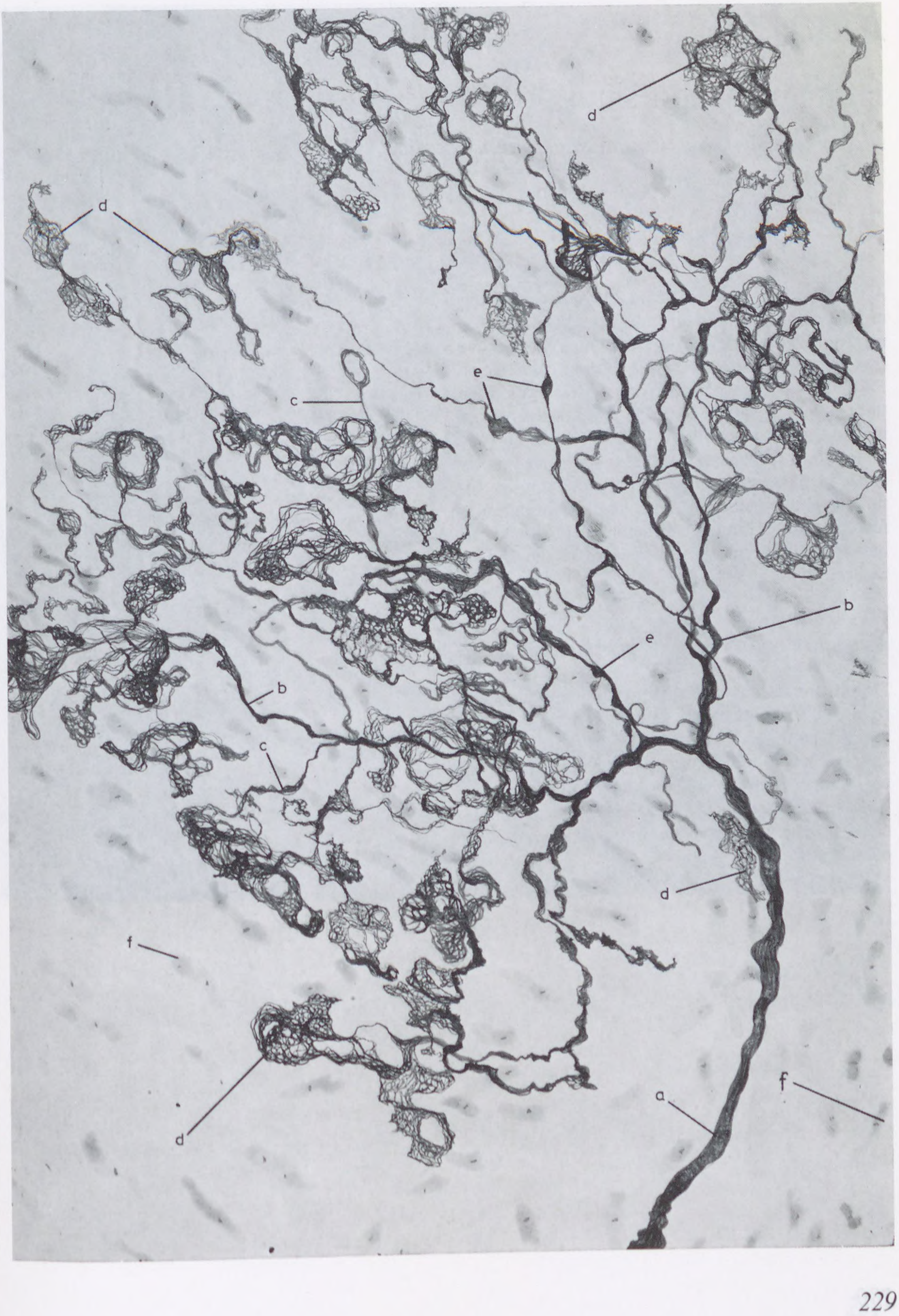
d
d
d
c
e
e
b
e
b
c
d
f
d
a
f

Plate 118

Human carotid sinus

Bielschowsky–Gros–Cauna silver impregnation

A thick fascicle of nerve fibres (c) consisting of numerous smooth depressor fibres is seen among connective tissue nuclei (b) of the inner connective tissue layer (a) in the adventitia of the carotid sinus. Fine fibres (f) run parallel with the fascicles. Two thick fibres (d) leave the fascicle, both of them bearing elongated varicosities (e). The fine smooth terminal fibres (g) become enlarged; these are heavily packed with neurofibrils (h), or terminate in neurofibrillar end-lamellae (i). With the exception of a few compact terminal structures (j), numerous neurofibrils (k) can be seen in most of the end-lamellae.

Neurohistopathological comments

Despite the serious cerebral and vascular alterations found in this patient the depressor fibres have remained more or less intact. Slight morphological changes due to atherosclerosis and chronic hypertension can nevertheless be observed. These alterations represent only the initial phase of a complicated degenerative process occurring in cardiovascular disease.


e
c
d
h
g
h
h
g
i
a
k
f
k
e
i
e
h
b
d
j

Plate 119

Human carotid sinus

Jabonero's silver impregnation

Connective tissue fascicles as well as nuclei (b) and nucleoli (c) of connective tissue cells can be seen in the internal connective tissue lamellae (a) of the adventitia. A large part of the picture is occupied by nerve fibres (d) filled with neurofibrils (i). Smooth, wavy nerve fibres (e), some of them bearing fine varicosities (f), can also be found among the thick fibres. Neurofibrillar intercalated lamellae (g) occur in large numbers in the terminal fibre system. The majority of the nerve end-lamellae are composed of groups of small ring-like terminal structures (j) arranged in clusters.

Neurohistopathological comments

This structure of the end-lamellae can only be found in the carotid sinus of individuals who had died in pulmonary embolism. Compact forms of end-lamellae (h) can fairly frequently be observed in sections obtained from atherosclerotic material.


a
j
b
c
g
d
i
d
g
j
f
j
i
i
e
h
e

Plate 120

Human carotid sinus

Bielschowsky–Gros–Cauna silver impregnation

Terminal system of a degenerating nerve fibre of the human carotid sinus in the loose layer of the adventitia among lightly coloured connective tissue fascicles and elongated nuclei of connective tissue cells (g). The thick nerve fibre filled with neurofibrils (a) courses upwards from the bottom of the picture with alternating fine and enlarged segments (c). In the enlarged segments the neurofibrils have disintegrated (d). Many protrusions (e) and other degenerative formations can be observed. Some end-lamellae (f) of the fine axons (b) originating from the intercalated segments appear to have normal structure, but these are formed by the association of small vesicles.

Neurohistopathological comments

Degeneration, destruction and final disappearance of a depressor axon can be seen in this specimen obtained from the carotid sinus of an individual who had died in pulmonary embolism. A large variety of serious alterations can be encountered in the structure of the baroreceptor terminal systems. According to our investigations, cardiovascular diseases produce degeneration of the baroreceptors, whereas degeneration of these receptors may, in turn, induce cardiovascular disorders.

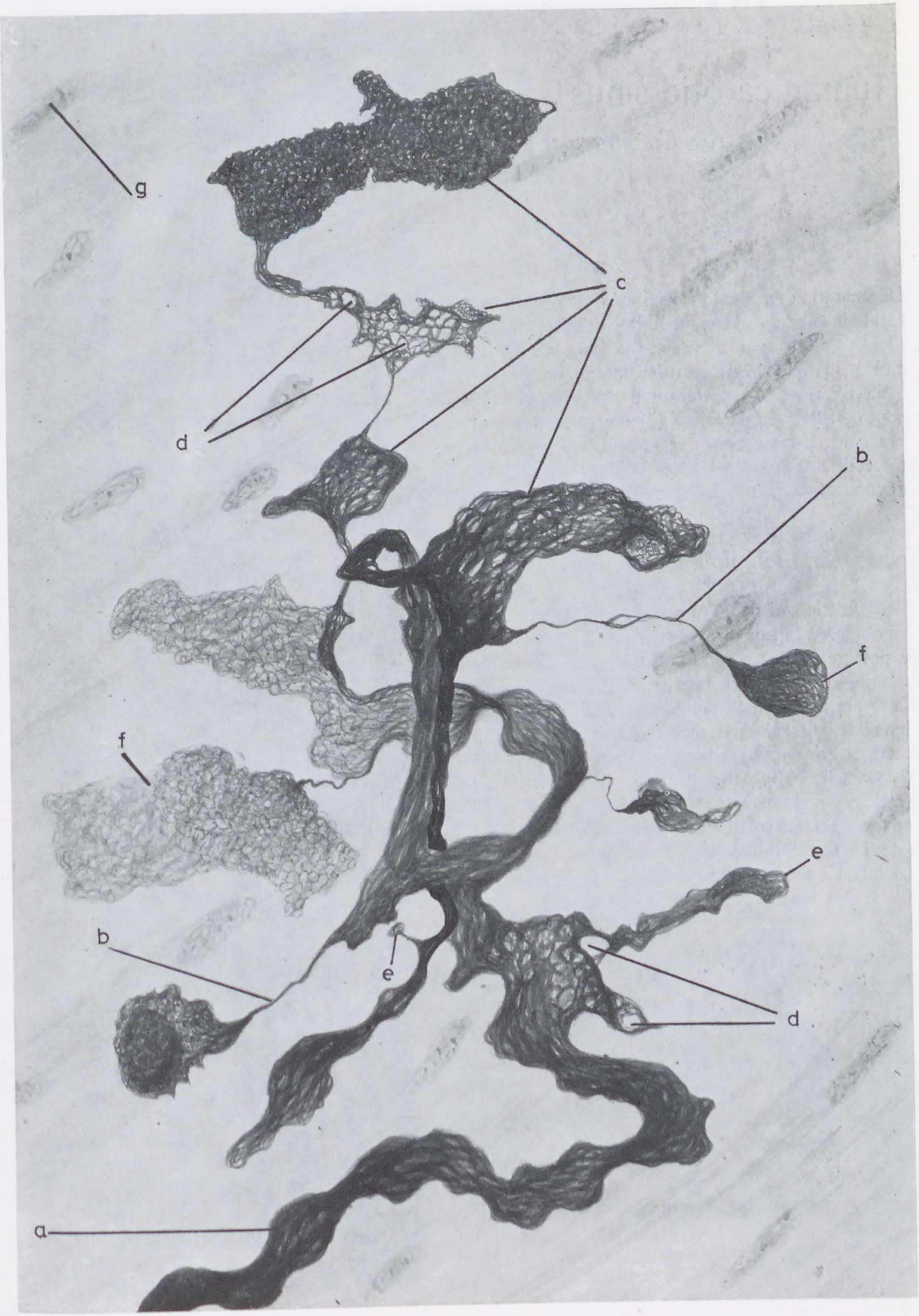
g
c
d
b
f
f
e
b
e
d
a

Plate 121

Human carotid sinus

Bielschowsky–Gros–Cauna silver impregnation

Degenerating terminal nerve fibre system in the carotid sinus of an old man. A thick depressor fibre breaks up into two branches: the main branch (a), and a finer, loosely structured lateral branch (b). Thin terminal and preterminal fibres (c) bearing neurofibrillar end-lamellae (d) emerge from both branches. Homogeneous vesicles (e) are present in the end-lamellae as a sign of degeneration. Nuclei of connective tissue cells (f) are lightly stained.

Neurohistopathological comments

Degeneration of nerve fibres and end-lamellae can be observed in this picture. The initial phase of the disintegration has several morphological signs. The terminal fibres originating from the same parent fibre are arranged in coil-like structures, the end-lamellae are enlarged and the neurofibrils show increased argyrophilia both in the fibres and in the end-lamellae. Subsequently the neurofibrils are thickened and break up into short segments. In more advanced stages small, thick-walled vesicles accumulate in the end-lamellae. These phenomena can usually be seen in advanced age, with sclerosis of the tunica media, as shown in this picture.


e
f
c
c
e
b
c
d
a
b
b
d

Plate 122

Human carotid sinus

Jabonero's silver impregnation

Terminal system of a single degenerating depressor fibre can be seen in the inner lamellae of the adventitia of the carotid sinus. Both the thick nerve fibre (a) and its collaterals (b) arborizing among the elongated nuclei of the connective tissue cells (f) bear baroreceptor features. The large neurofibrillar end-lamellae (d) filled with reticula (e) instead of neurofibrils are continuous with the terminal fibres (c).

Neurohistopathological comments

The process of degeneration is demonstrated in the carotid sinus of an individual who had died in pulmonary embolism. The typical features of advanced degeneration of the baroreceptors are as follows: *(i)* Thickening of the fibres; individual fragments are connected by fine, short segments. *(ii)* Fine side branches emerging from the nerve fibres are relatively long and are attached to elements of the ground tissue by large elongated end-lamellae. *(iii)* Alterations involving the entire terminal system result in the appearance of lamellae consisting of small ring-like structures; the lamellae are densely packed so that they form a kind of a veil. Since these morphological changes were seen to develop as a result of pulmonary embolism, we attribute them to chronic anoxia. That is why all nerve fibres showed identical signs of degeneration, whereas under different pathological conditions intact terminal systems occur side by side with those which have undergone degeneration.

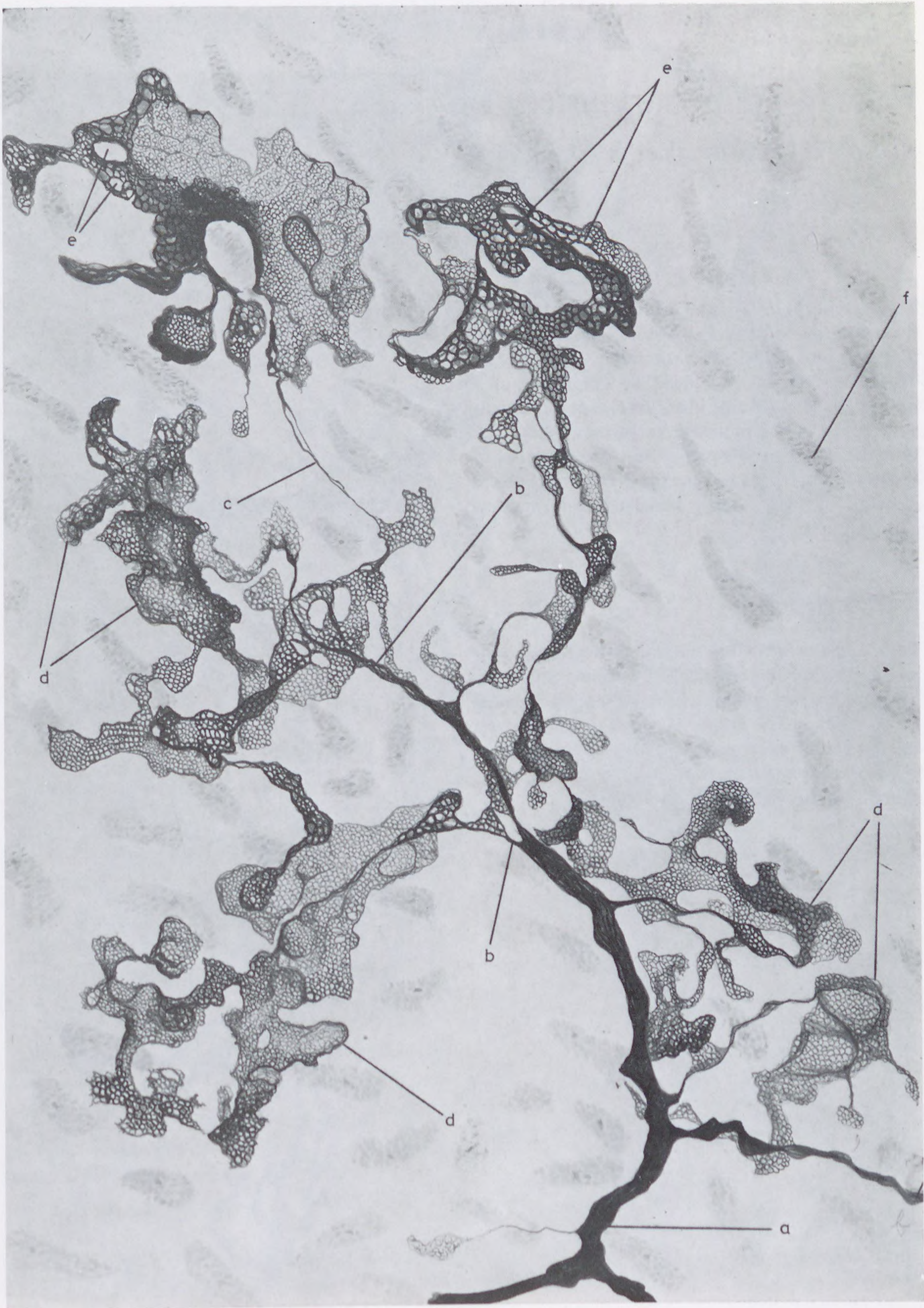
e
e
f
c
b
d
d
b
d
d
a

Plate 123

Human pulmonary artery

Bielschowsky–Gros silver impregnation

Thick nerve fibre (c) filled with neurofibrils (e) in the adventitia among the wavy connective tissue fibres (a) and nuclei of connective tissue cells (b). The thick fibre is surrounded by fine axons of a nerve fascicle (d). Some fibres form a coil-like end-system (g), while others spiral around the thick fibre (d). Terminals emerging from the branches of the thick fibre form an elongated plexus (f) in which, although in small number, lamellar end-formations can be found.

Comments

Baroreceptors located in the wall of the human pulmonary artery have a relatively simple structure. Though receptor apparatuses could not be revealed in the pulmonary artery of other mammals, we think that this failure was due to technical problems: either the impregnation was unsuccessful or an unsuited portion of the artery was studied.

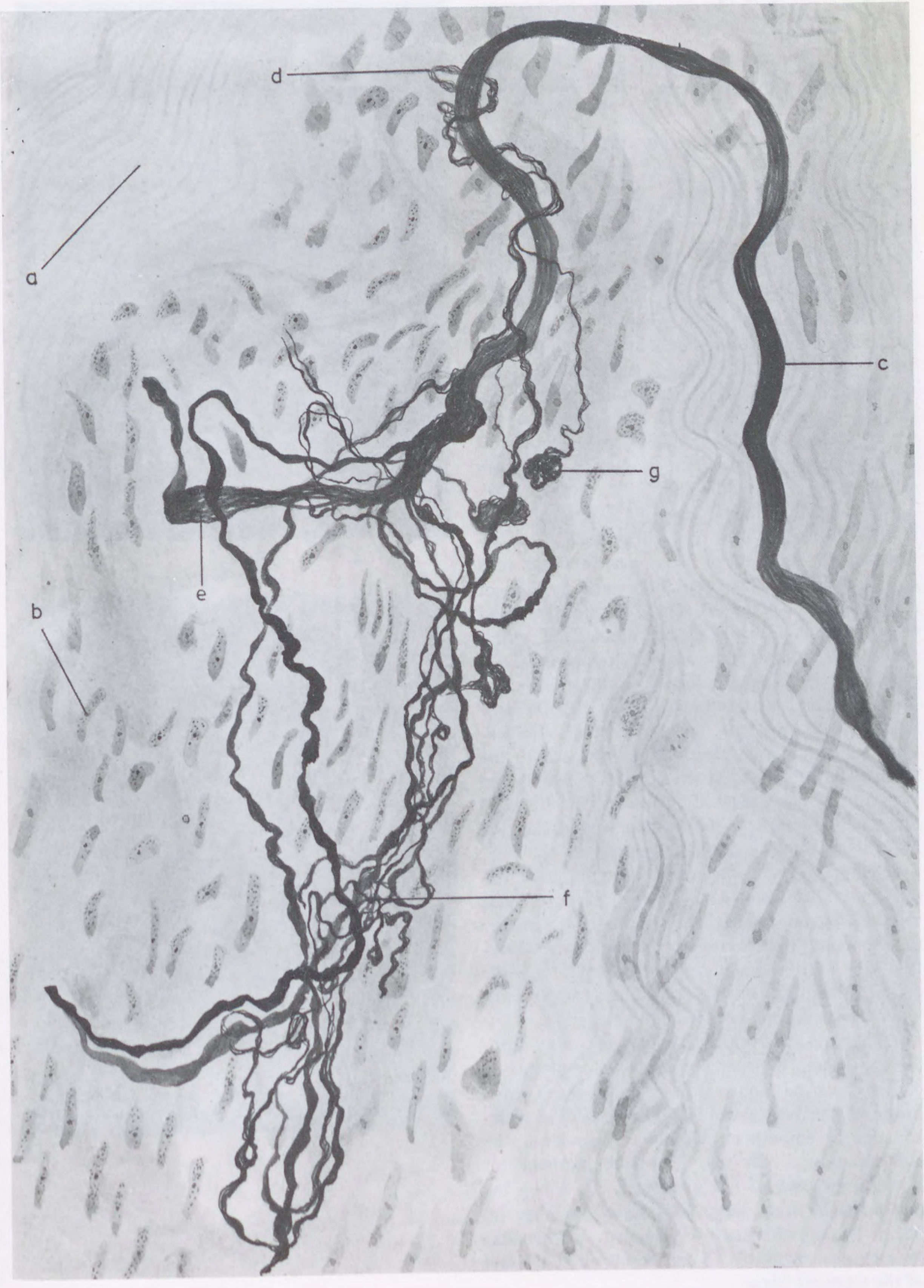
d
a
c
g
e
b
f

Plate 124

Baroreceptors in the subclavian artery

Bielschowsky–Gros silver impregnation

1. Proximal part of the canine *(Canis familiaris)* subclavian artery. The baroreceptor terminals are located in islands of the connective tissue (a) containing nuclei of connective tissue cells (b). Note the smooth muscle tissue (c) containing cells arranged in a row (d). The baroreceptor fibres (e) having varicosities (f) terminate in dense end-lamellae (g). The nerve fibres are characterized by thin segments (h) and small spines.

2. Human subclavian artery. Fascicles of baroreceptor fibres and their terminal systems in the adventitia (a). Note nuclei of connective tissue cells (b), fascicles of collagenous fibres and bundles of smooth muscle fibres (c). Thick baroreceptor and fine sympathetic fibres proceed towards the central part of the picture within the nerve fascicle (d). The baroreceptor fibres as well as their finer branches bear elongated varicosities (f). The baroreceptor fibres branch repeatedly and the terminal ramifications (e) form a rich plexus (g) in which both the terminal portions of the depressor fibres (h), and thin sympathetic fibres (k) can be found. The terminal fibres continue in end-lamellae (i) which, like the intercalated lamellae, contain neurofibrils (j).

3. Human subclavian artery. Voluminous terminal nerve fibre system. Nuclei of connective tissue cells (b) surrounded by bundles of smooth muscle (c, d – smooth muscle cell) can be seen in the adventitia (a). Varicosities (f, i) are present along the course of the thick baroreceptor fibres (e). Note the wavy terminal fibres (g) and end-lamellae (h).

4. Human subclavian artery. Neurofibrillar lamellar end-system of a single baroreceptor fibre. Nuclei (b) of various connective tissue cells are located in the connective tissue lamellae (a) which are surrounded by smooth muscle tissue (c) made up by smooth muscle cells (d). The thick baroreceptor fibre (e) has several fine collaterals (f). Along the fine terminal fibres large intercalated lamellae (g) occur. Round, elongated or falciform end-lamellae (h) rich in neurofibrils (i) can be found at the end of the terminal fibres.

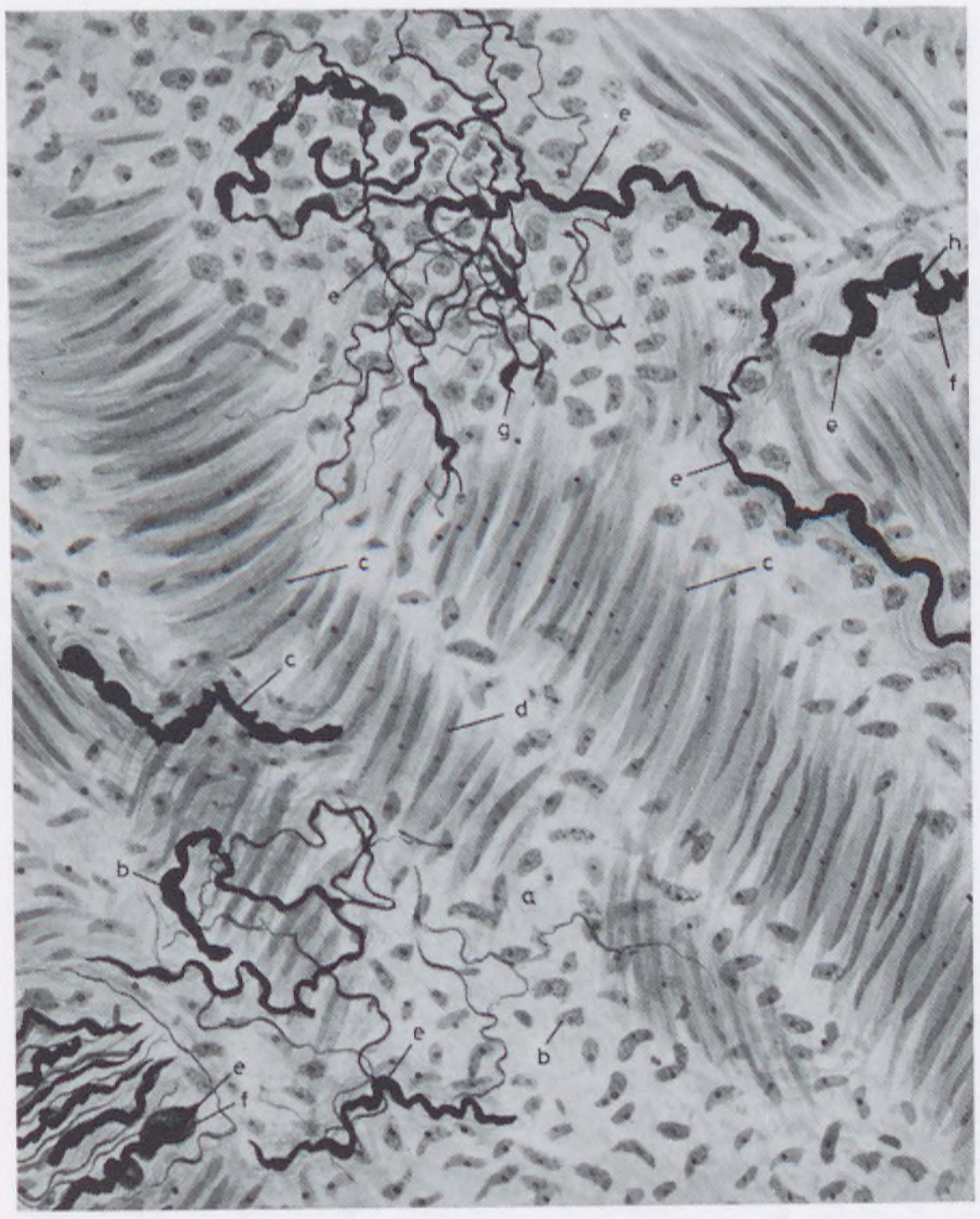
e
e
h
e
f
g
e
c
c
c
d
b
a
b
e
e
f

1

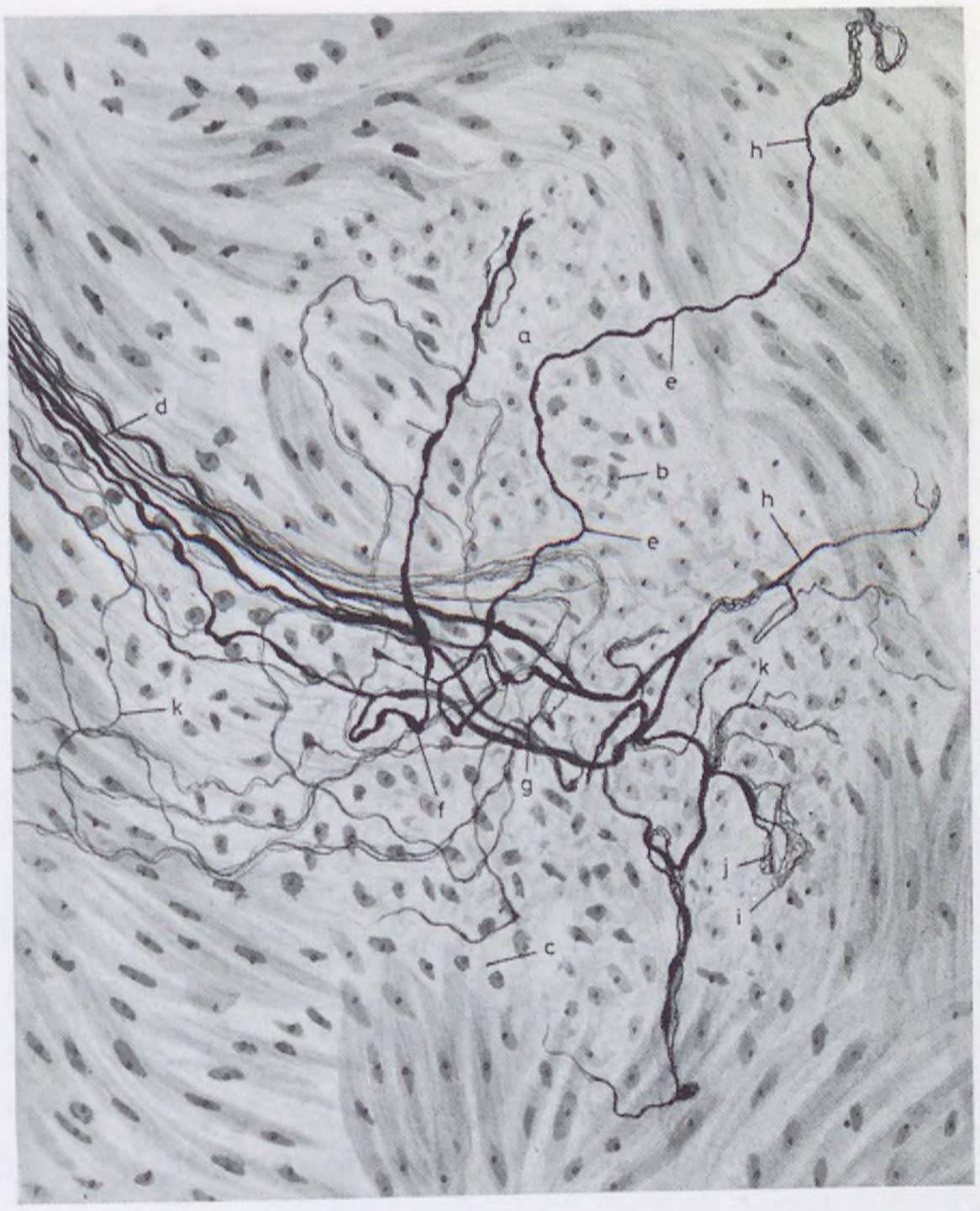
h
a
e
d
b
e
h
k
k
f
g
j
i
c

2

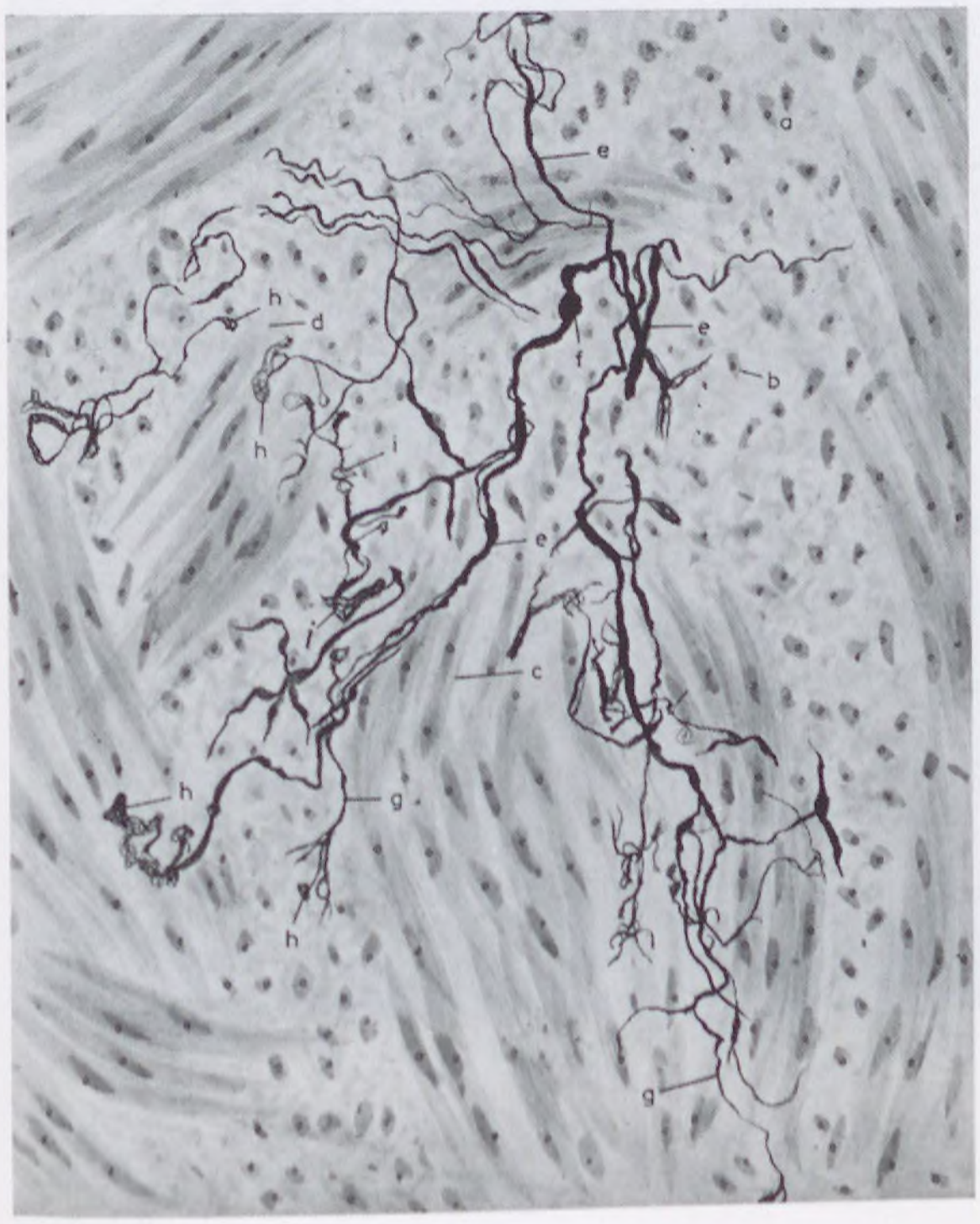
a
e
h
d
e
b
h
i
f
e
c
h
g
h
g

3

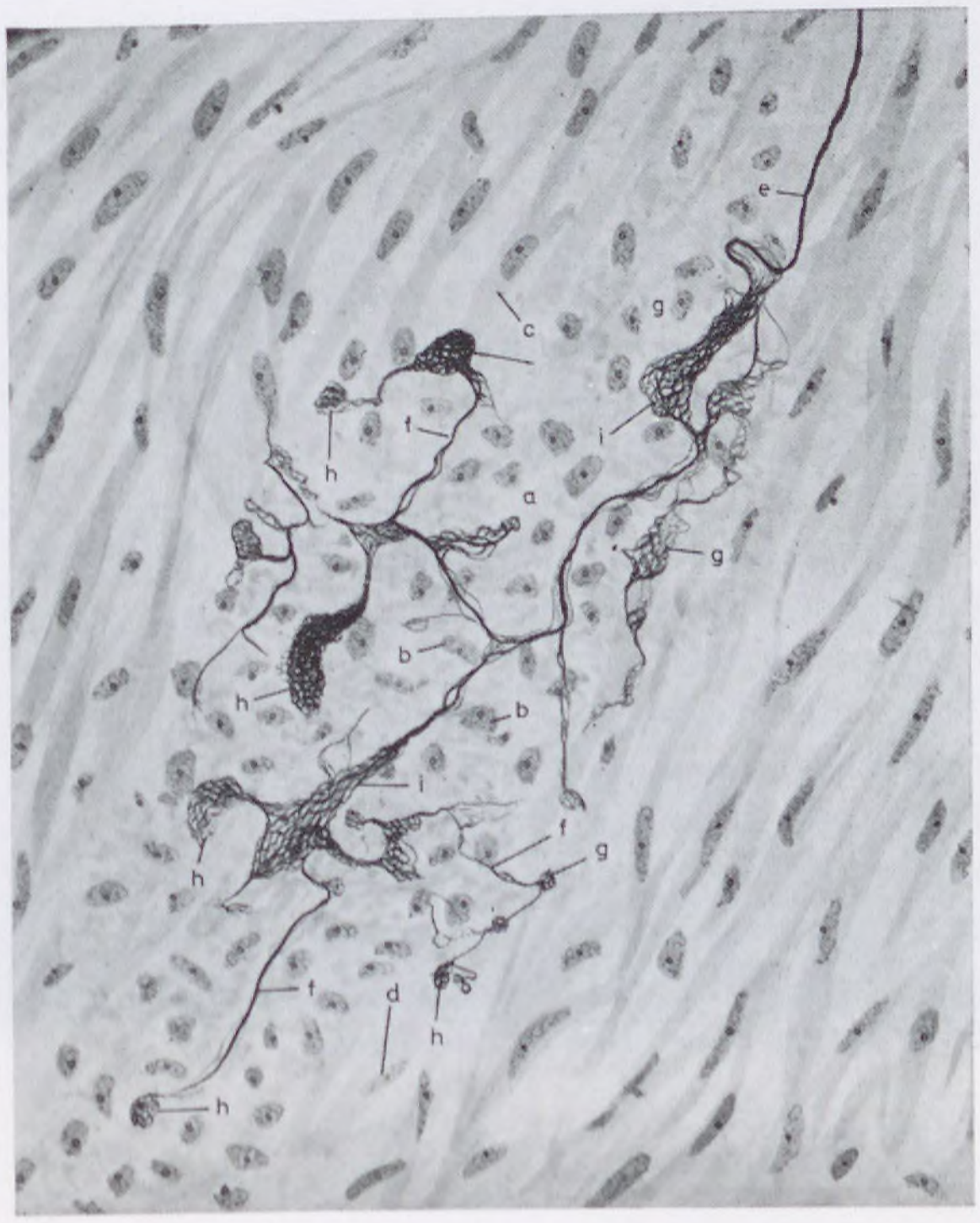
e
c
g
h
f
i
a
g
b
h
b
i
h
f
g
f
d
h
h

4

Plate 125

Pigeon *(Columba domestica)* carotid body

Bielschowsky–Gros–Cauna silver impregnation

A connective tissue capsule (a) surrounds the carotid body. Two cross-sectioned arteries (b) are also visible (lower left). A large part of the picture is filled by the ground substance of the carotid body which is composed mainly of round, closely packed glomus cells (c). Nerve fibres of both the periglandular (e) and intraglomerular plexus (f) originate from the wavy nerve fascicles (d). Most of the nerve fibres (e.g. g) show a wavy course, branch abundantly and their terminal ramifications come into a close contact with the glomus cells.

Neuroanatomical and neurohistological comments

The carotid body of birds lies close to the bifurcation of the common carotid artery, immediately above the ultimobranchial organ. It is a round, dense body consisting of round nests (glomeruli) divided by connective tissue septa. The carotid body is richly innervated. The nerve fibres deriving partly from the glossopharyngeal and partly from the vagus nerve penetrate the body and branch abundantly. The thick nerve fibres are smooth and wavy. The individual branches arborize either within the connective tissue capsule or in the organ and form loose coils within the glomeruli. The nerve fibres do not show depressor characteristics. They taper off and follow a meandering course at the margin of, as well as within, the nests. They terminate in smaller or larger end-bulbs or end-rings.

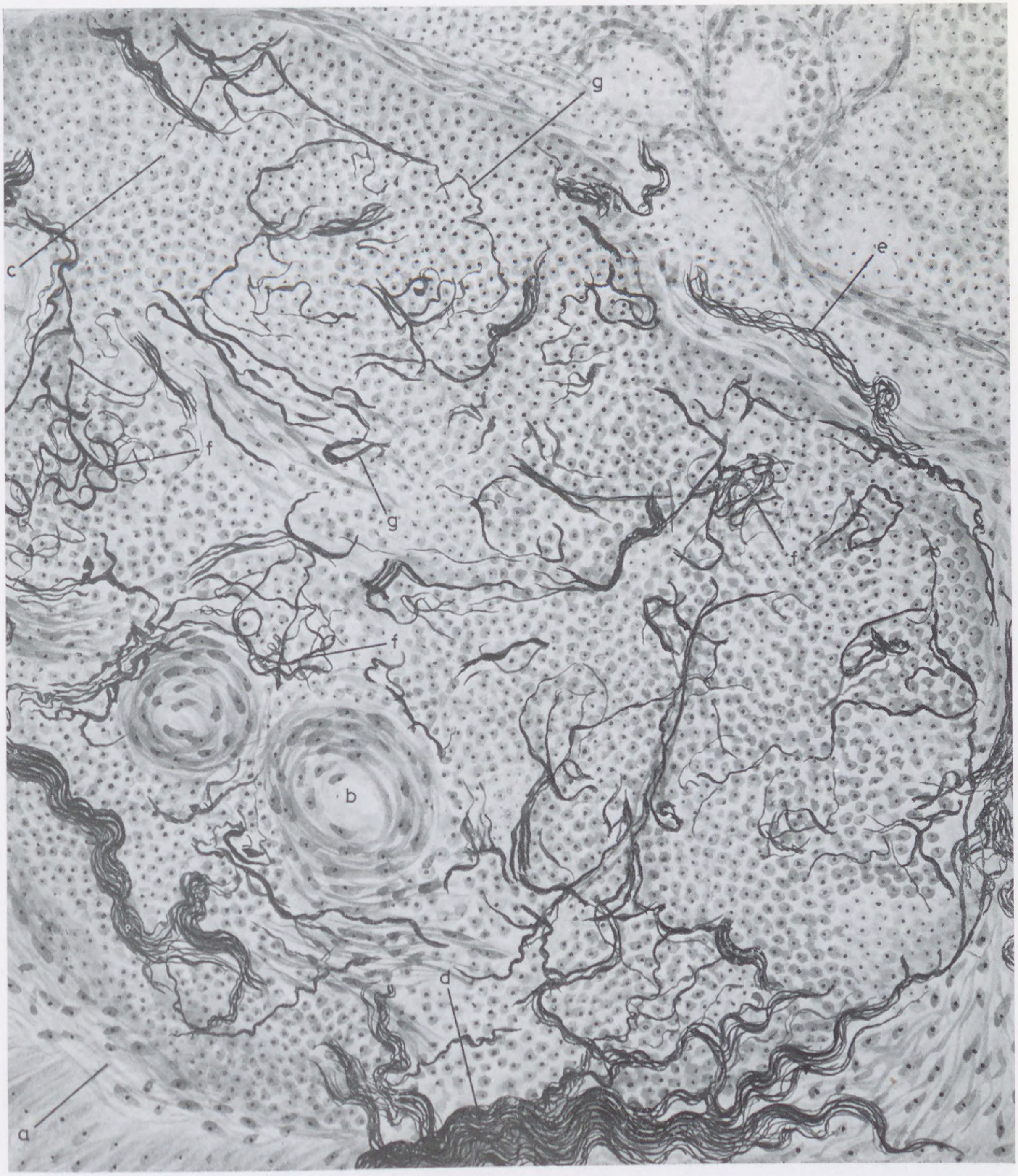
g
c
e
f
g
f
f
b
d
a

Plate 126

Hedgehog *(Erinaceus europaeus)* carotid body

Bielschowsky–Gros–Cauna silver impregnation

Connective tissue fascicles (b), nuclei of connective tissue cells (c) and the cross-section of a smaller artery (d) appear in the connective tissue capsule (a). In the glomeruli (e) the ground substance of the carotid body and the nuclei (f) of the glomus cell can be seen. Note the nerve cells (g), their nuclei (h) and nucleoli (i) both in the lower and upper parts of the picture. Neurofibrils (j) can clearly be discerned within the nerve cells as well as in their processes (k). Thick nerve fibres (m) of chemoreceptor nature occur in the nerve fascicles (l) and also outside them. The thin fibres (n) are of sympathetic origin.

Comparative neurohistological comments

Histological structure of the carotid body of the hedgehog is similar to that of birds. The differences can be summarized as follows: *(i)* The glomus cells are larger, elliptical and have a vacuolated cytoplasm. *(ii)* The connective tissue capsule of the organ is thicker and the connective tissue septa between the nests are denser. *(iii)* Nerve fibres are usually thinner. Innervation of the carotid bodies is very rich. The connective tissue septa contain thick nerve trunks that establish a large plexus. Fibres of various diameter occur in the plexus. The thick fibres belong to the glossopharyngeal and vagus nerves while the thin ones are of sympathetic origin. Small groups of sympathetic and parasympathetic ganglion cells appear in the course of the nerve trunks (horse, hog and rat).

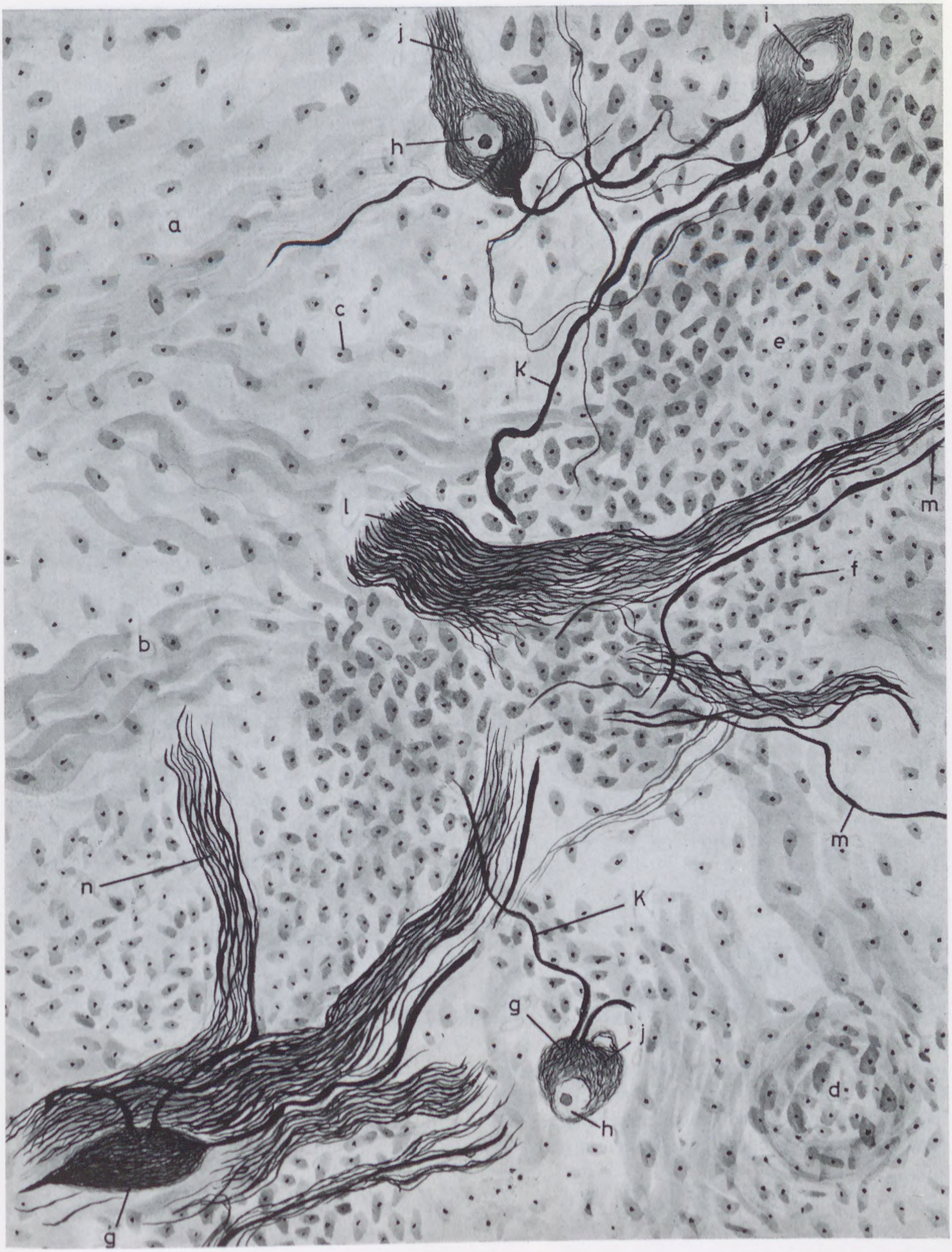
j
i
h
a
c
e
K
l
m
f
b
n
m
K
g
j
d
h
g

Plate 127

Dog *(Canis familiaris)* carotid body

Bielschowsky–Gros–Cauna silver impregnation

Part of the carotid body. Cross- and longitudinal sections of the small arteries (b) can be seen in the connective tissue septa (a) separating the glomeruli. Nerve fibres of various calibre (d), and terminal nerve plexuses (e) are located within the glomeruli (c). In one of the glomeruli also bulb-like endings (f) are present, of which the larger ones have neurofibrillar structure.

Neuroanatomical comments

The majority of the nerve fibres belong to the glossopharyngeal nerve while the rest originate either from the vagus nerve or from the superior cervical sympathetic ganglion. The number of nerve fibres is particularly large in the fast-running animals and in man. These fibres penetrate into the carotid body and form a rich terminal network. The most extensive nerve plexus is located in the capsule (periglandular plexus). It is composed of nerve trunks, and of separate nerve fibres. Ganglia and solitary nerve cells can be found in a considerable number among the nerve fibres. Nerve cells are most numerous in the carotid body of the horse indicating that the superior cervical ganglion plays an important role in the innervation of the carotid body in this animal. Another plexus is situated around the glomeruli (periglomerular plexus). These fibres originate from the periglandular plexus. Axons of the periglomerular plexus enter the glomeruli where they form a terminal plexus (intraglomerular plexus). The fibres of this terminal plexus end among the chemoreceptor cells or upon the cells themselves.

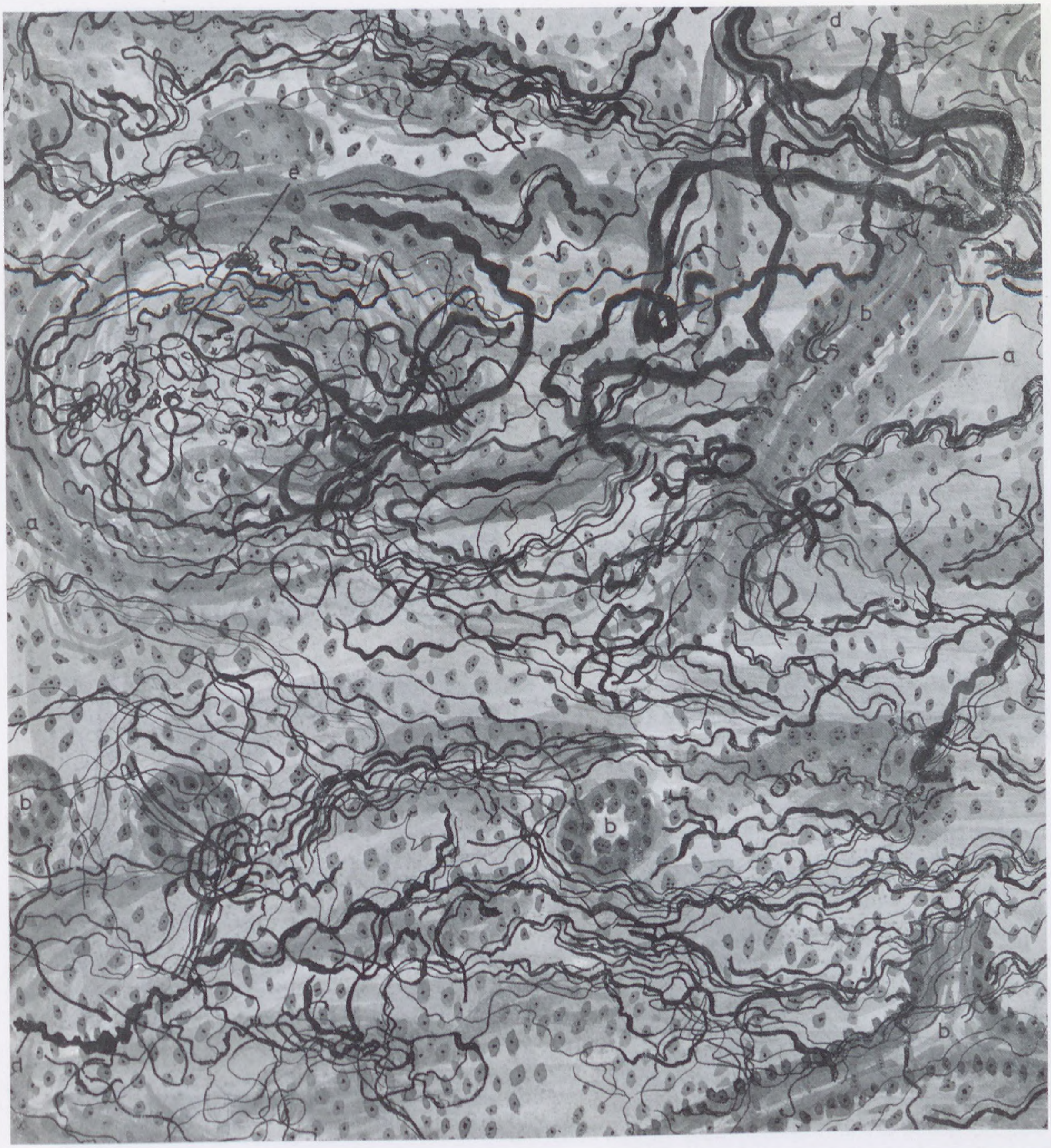
d
e
f
b
a
c
a
b
b
d
b

Plate 128

Receptors in the carotid body

Coloured photomicrographs.
Bielschowsky–Ábrahám silver impregnation

1. Human carotid body. Some of the nerve fibres contained by the periglomerular plexus (top) enter the glomerulus and establish an intraglomerular plexus. The axons have alternating thin and thick segments. A minuscle intraglomerular plexus can be seen in the lower right corner. Nerve fibres traversing the uppermost and lowermost portions of the picture belong to the fibre system of the periglandular plexus.

2. Human carotid body. A group of glomus cells is encircled by the thick fibres of the periglomerular plexus. The nerve fibres leaving the periglomerular fascicle in the lower part of the picture form a loose plexus in the glomerulus. The nerve endings sit on the terminal fibres like cherries on the branch.

3. Human carotid body. The central region of the field is occupied by an elongated glomerulus in which elliptic or spherical nuclei of the glomus cells can be clearly recognized. The fibres of the intraglomerular plexus meandering around the individual glomus cells are well impregnated.

4. Dog *(Canis familiaris)* carotid body. The glomus cells in the round or elliptic glomeruli are arranged in dense groups or, in some places, at a distance from one another. Wavy fibres of the periglomerular plexus can be discerned among the glomeruli. Fine nerve branches penetrate the glomeruli and terminate between the glomus cells.

5. Hedgehog *(Erinaceus europaeus)* carotid body. Part of the connective tissue capsule surrounding the carotid body can be seen in this picture. A nerve fascicle can be seen among the connective tissue fibres and nuclei of connective tissue cells. Two nerve cells can also be discerned in this picture; the lower one emits two processes, while the upper one gives rise to three processes.

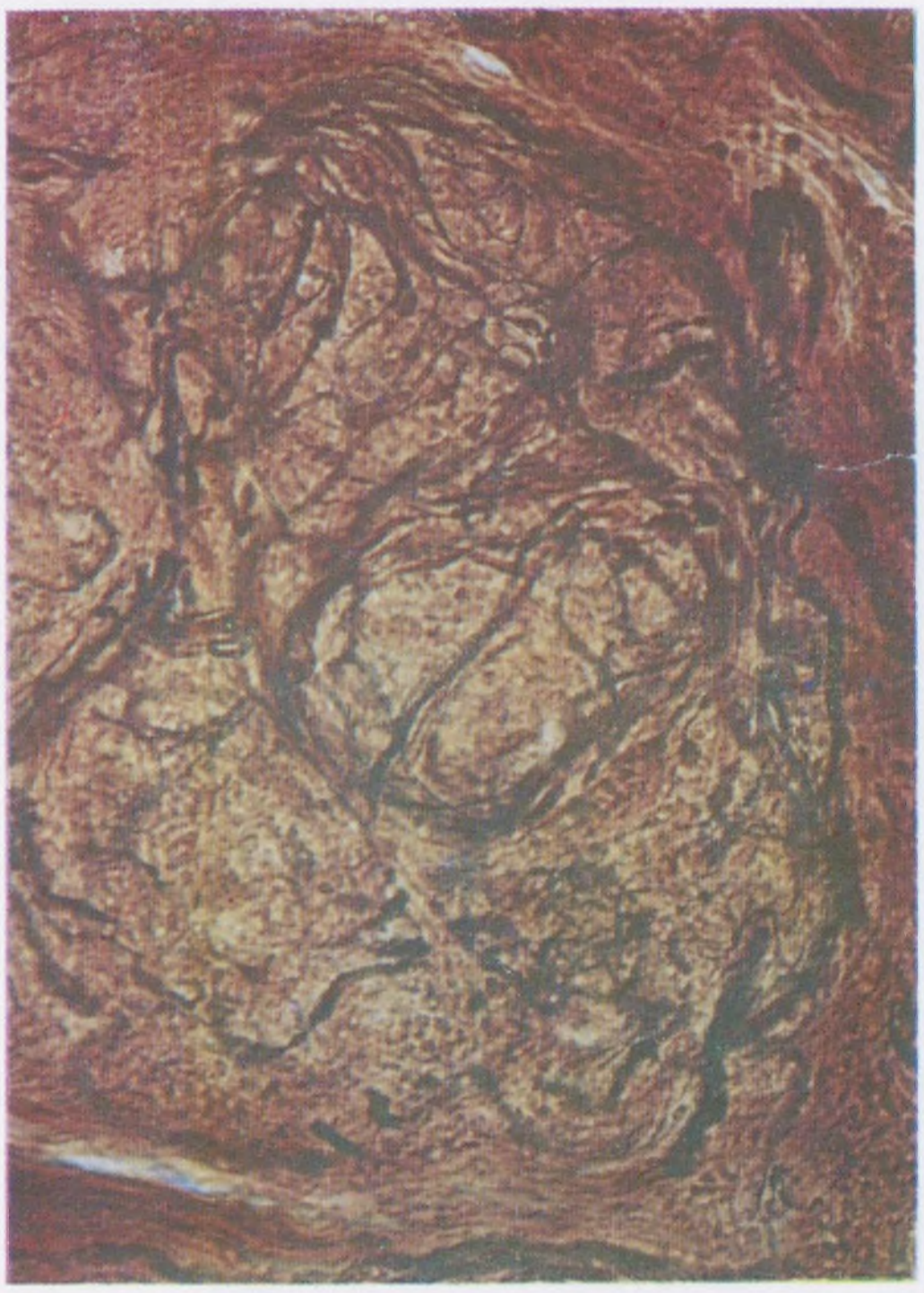
1

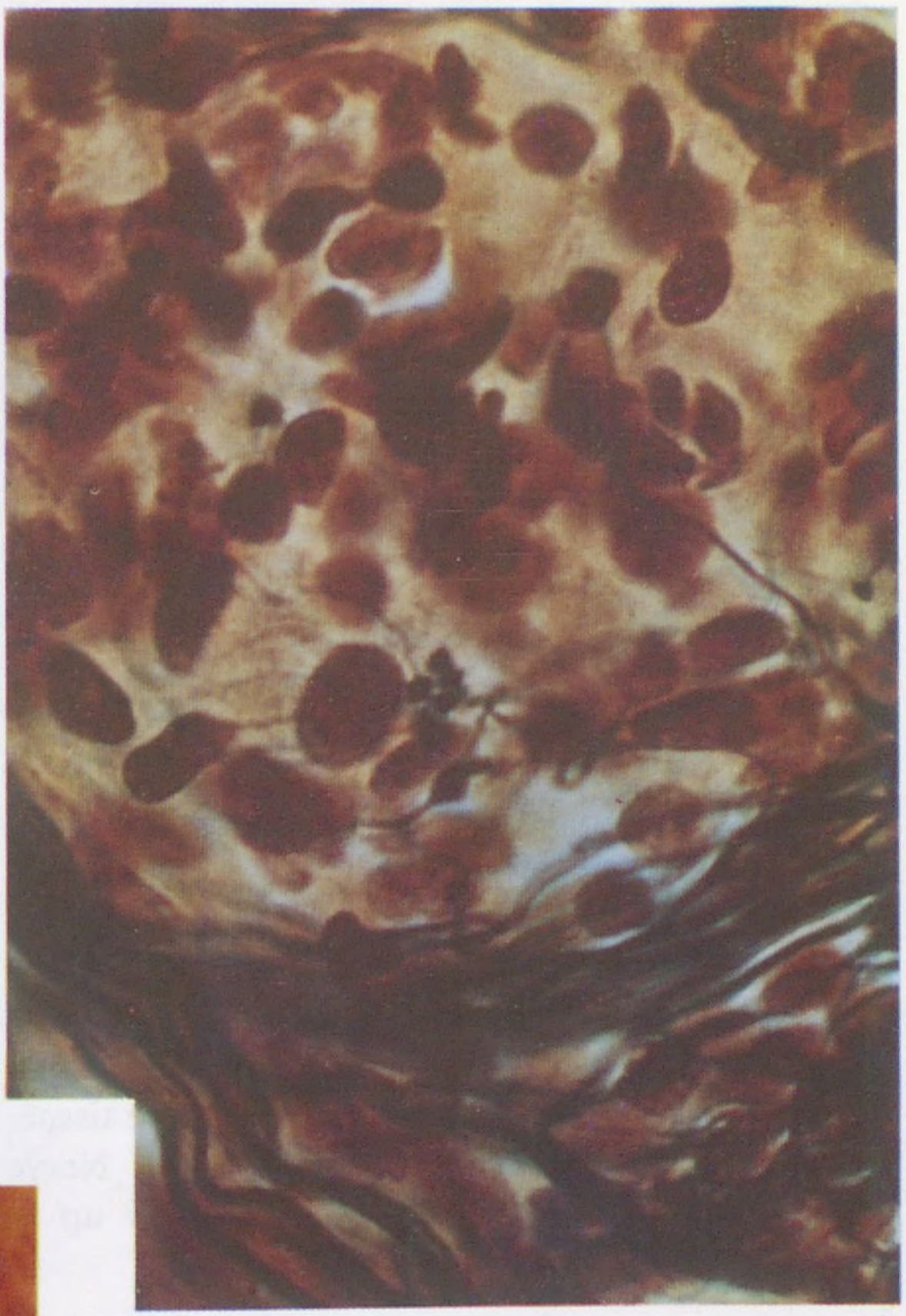
2

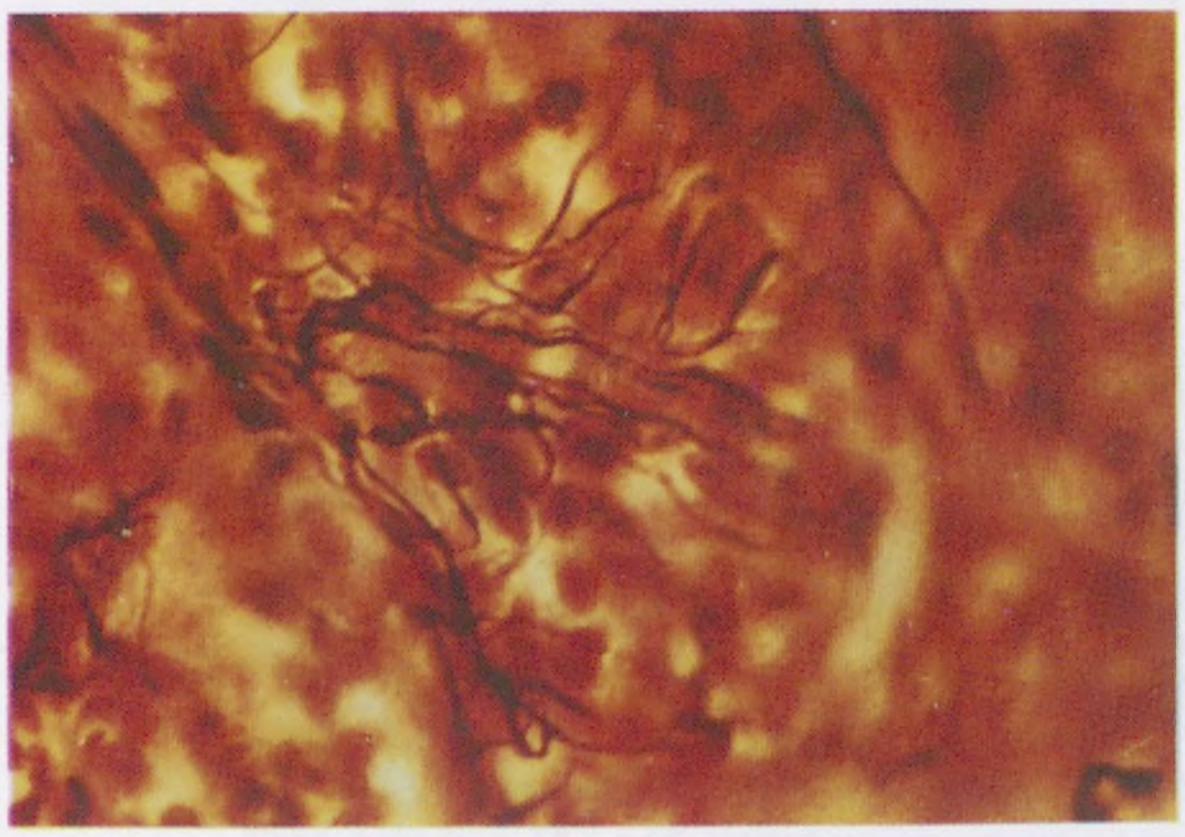
3

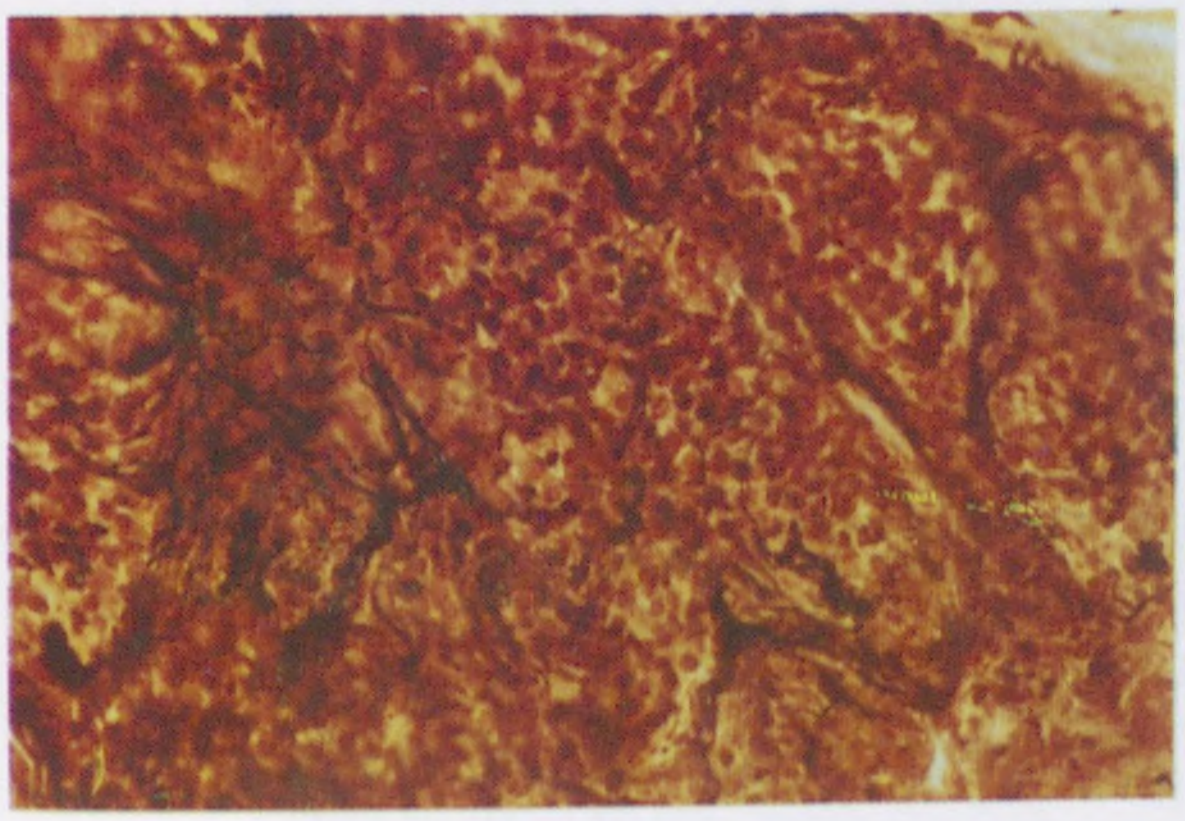
4

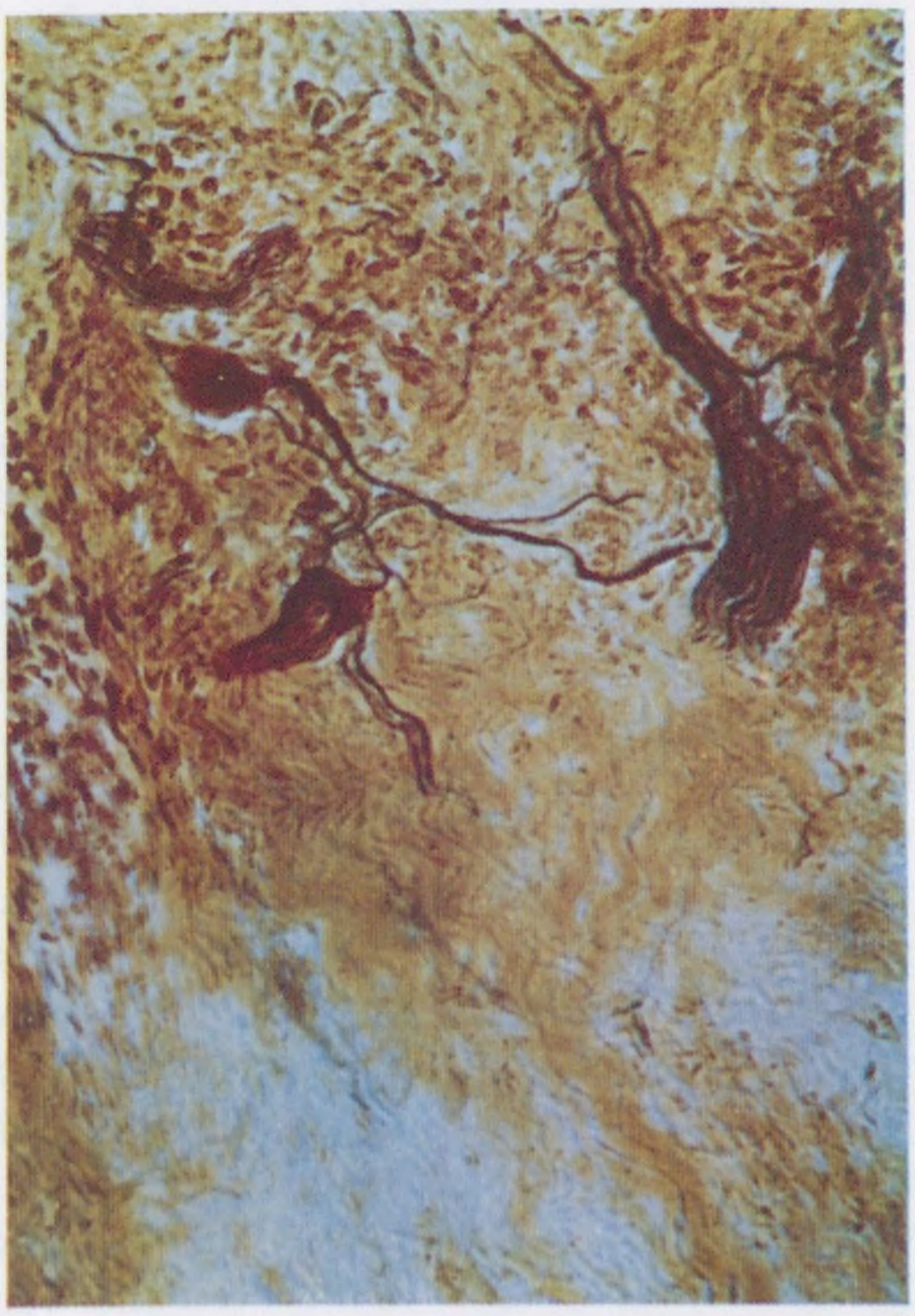
5

Plate 129

Human carotid body

Iron-haematoxylin and eosin staining

1–4. The glomeruli (b) are surrounded by collagenous fibres (a) of the interglomerular connective tissue. Transverse and longitudinal sections of blood vessels containing blood cells can occasionally be seen within the glomeruli. The glomeruli are packed with glomus cells. Two types of glomus cells can be distinguished. Chemoreceptor cells are characterized by dense, concentric nuclei (c); these large round cells appear in the middle of the glomeruli. Elongated smaller cells are visible in the periphery of the glomeruli, near the limiting connective tissue. These cells are probably capsular cells (d). Nerve fibres and terminal structures do not show up in this picture.

Connective tissue and vascular elements

The human carotid body is located medioposteriorly in the bifurcation of the common carotid artery. Its upper portion is attached to the wall of the internal carotid artery. It is encased by a thick connective tissue capsule which penetrates the organ as septa dividing it into smaller glomeruli (interglomerular connective tissue). Delicate connective tissue bundles enter the glomeruli from the septa. The organ is richly vascularized. The blood supply is provided by a small vessel, known as the glomus artery, which usually stems from the bifurcation of the common carotid artery, but may also arise from the external or internal carotid artery. The glomus artery enters the organ through its lower pole; it breaks up into numerous branches which form a rich network in the capsule. Smaller arteries from this network first enter the intraglomerular connective tissue, then the glomeruli where they issue capillaries. Inside the glomeruli the latter are gathered into small veins which join the veins contained by the interglomerular connective tissue. From here the veins are drained into the venous plexus surrounding the carotid body.

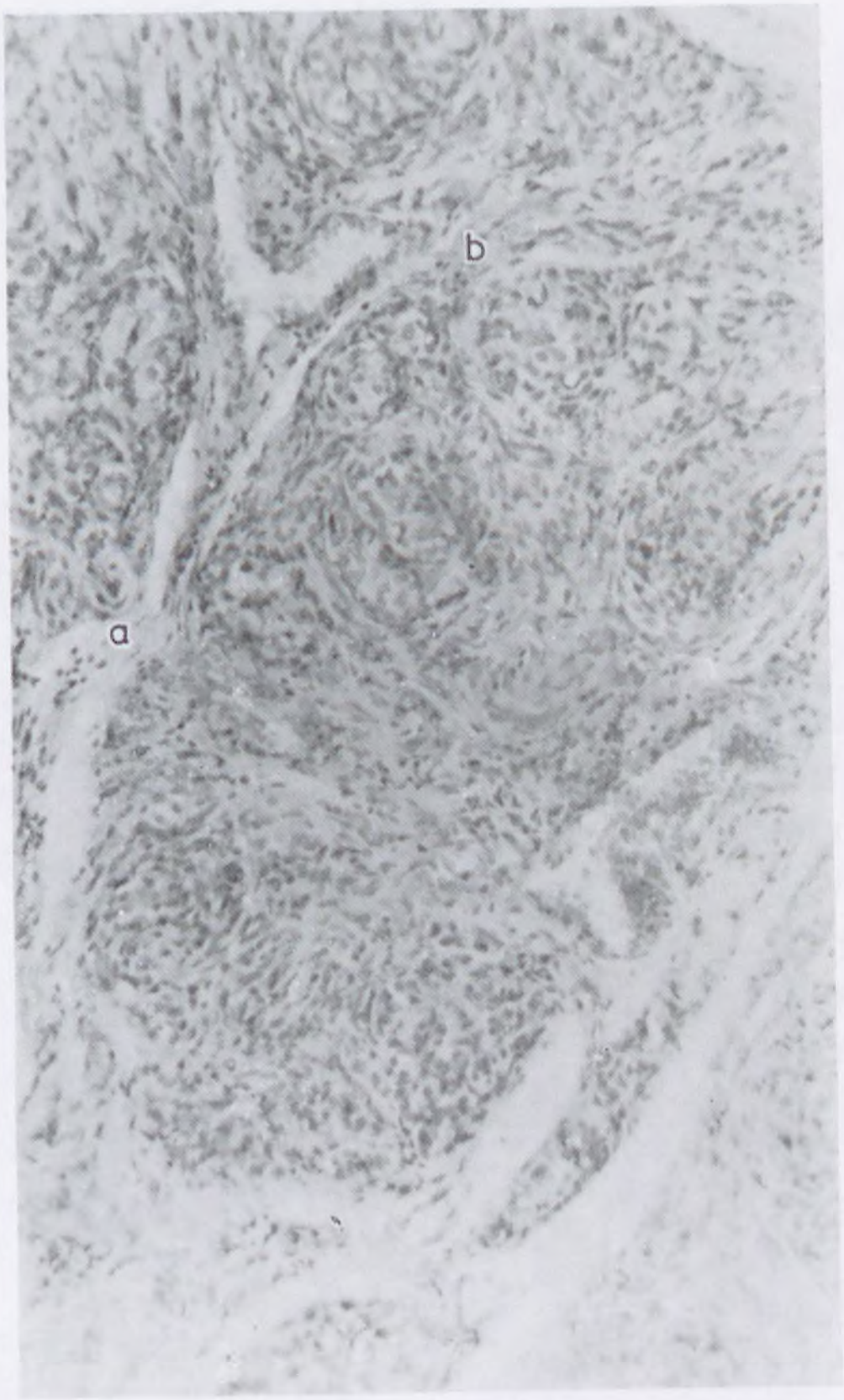

1

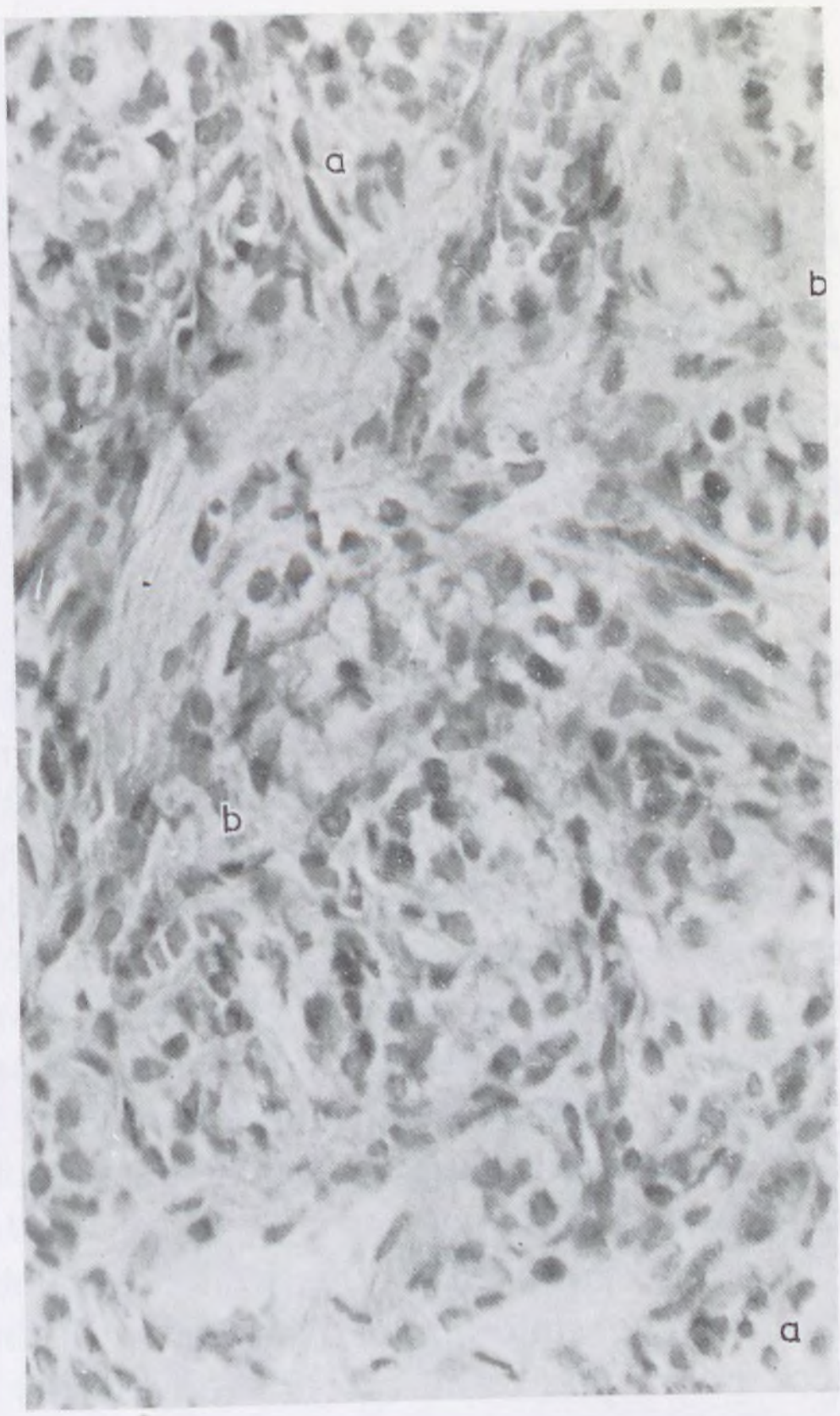

2

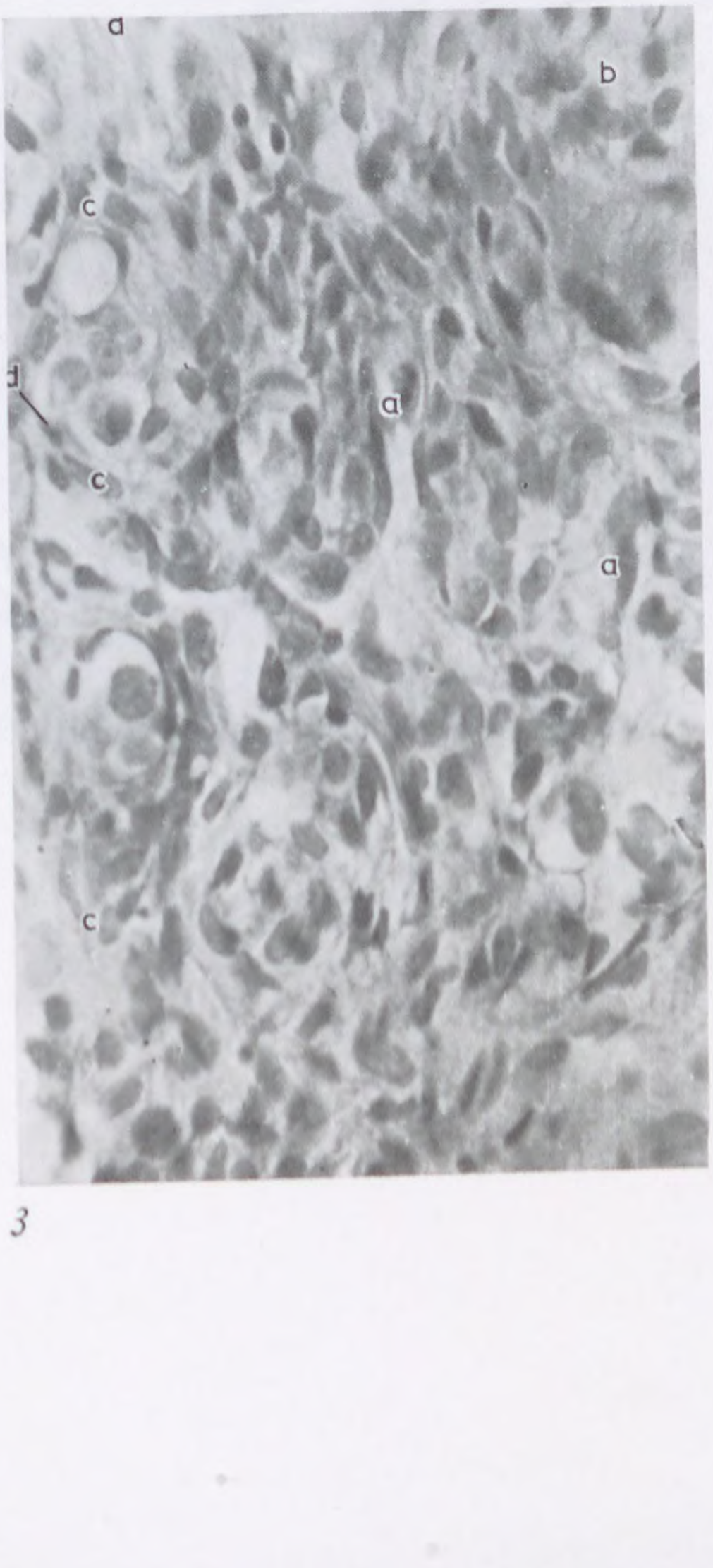

3

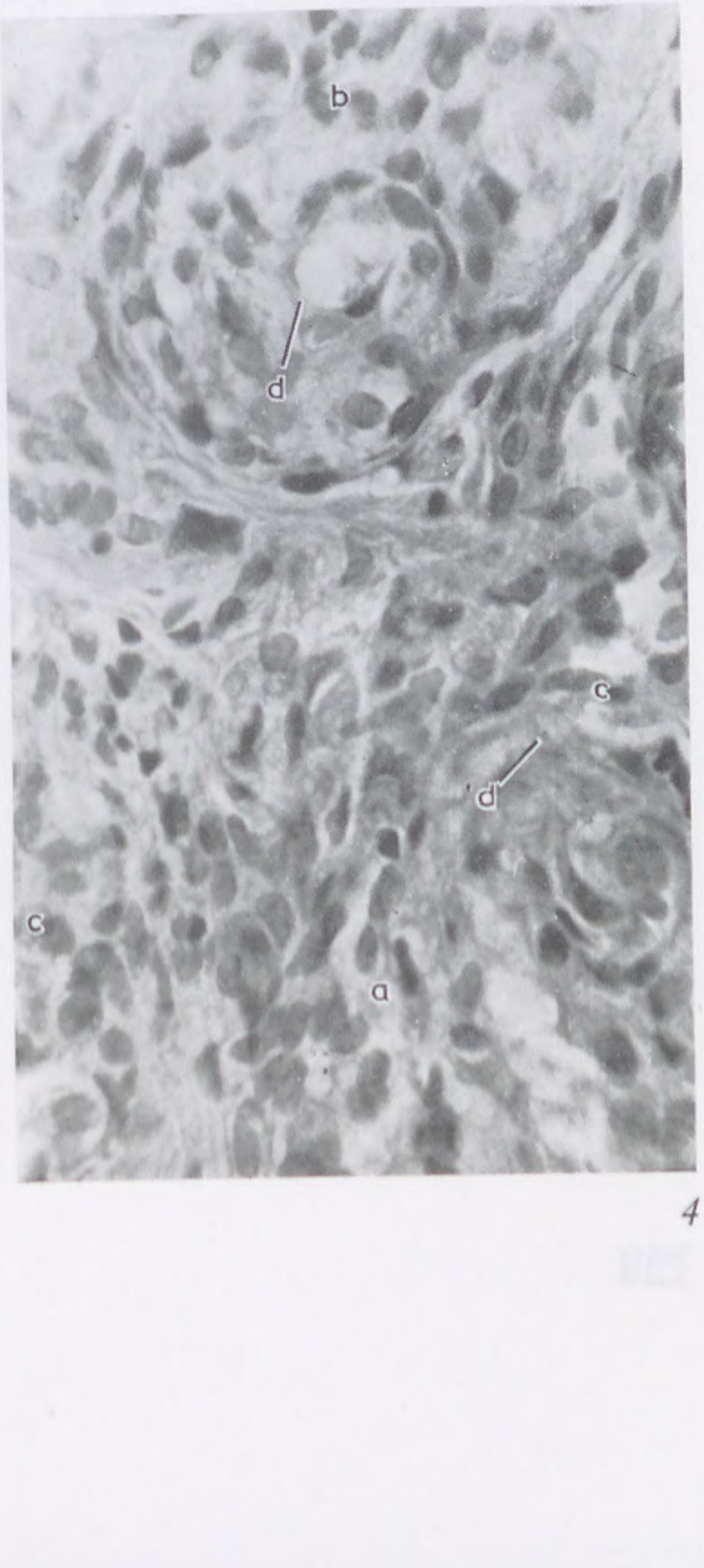

4

Plate 130

Human carotid body

Bielschowsky–Ábrahám silver impregnation
combined with
haematoxylin and eosin staining

Several nuclei of connective tissue cells (a) as well as collagenous fibres (b) are arranged in bundles which accompany the blood vessels (d) and surround the glomeruli (c). Sinusoids (e) appear in the course of the capillaries (d) which are filled with erythrocytes. Note the glomus cells (f) and meandering nerve fibres (g) in the glomeruli. Two wavy nerve fascicles (h) containing both smooth and varicose fibres (i) start from the right edge of the picture. Capillaries, sinusoids and smaller veins of the carotid body become strongly dilated in anoxia. This is substantiated by this section obtained from an individual suffering from respiratory disturbances (cor pulmonale). The carotid body serves for the perception of the gas concentration of blood.


c
a
c
b
f
g
g
d
h
f
i
e
h
b
d
i
a

Plate 131

Human carotid body

Electron micrograph

In addition to the capsular cell in the upper part of the picture, several smaller details can be discerned which are of importance as regards the structure and function of the carotid body. A portion of a chemoreceptor cell (Chc) with cisterns of the endoplasmic reticulum (Er), a group of mitochondria and Golgi's apparatus (G) can be seen in the upper left corner. The narrow cytoplasmic frame, the homogeneous nucleus occasionally bearing indentations and the processes (Pr) surrounding the chemoreceptor cells are typical features of the capsular cells (Cac). Neither the shape nor the structure of capsular cells can be adequately established by light microscopic observations. Electron microscopically, these resemble Schwann's cells which, however, have a more abundant cytoplasm and many processes; also mesaxons give rise to complicated systems. The lumen of a capillary (Lu) bordered by endothelial cells (E) containing mitochondria (M) can also be discerned, which distends sinus-like (Rbc – red blood cell). The endothelial cells vary in shape depending on the blood pressure in the sinus system. The rich capillary network together with the sinuses and endothelial cells may play a specific role in monitoring the gas concentration of blood.

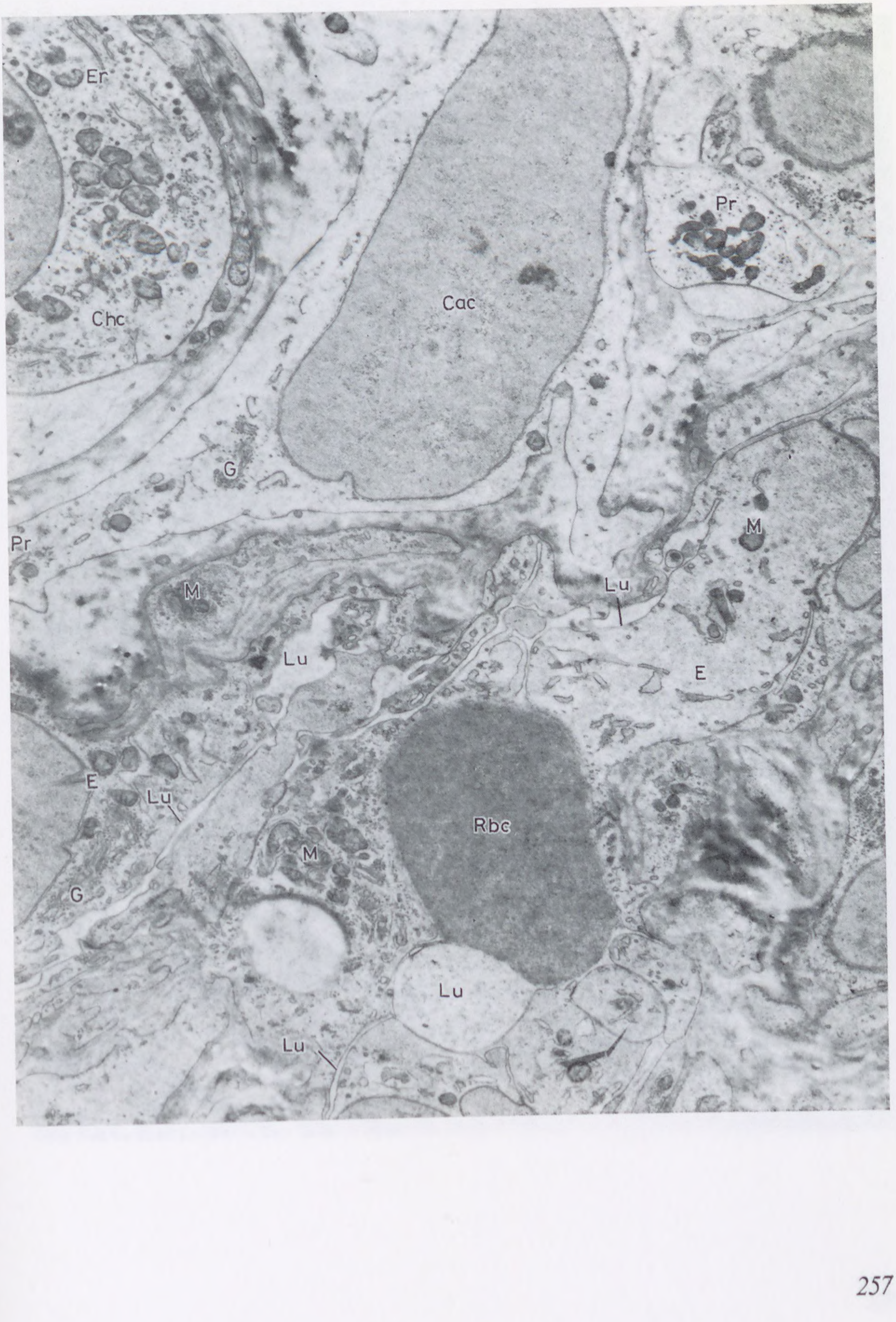
Er
Pr
Cac
Chc
G
Pr
M
M
Lu
Lu
E
E
Lu
Rbc
M
G
Lu
Lu

Plate 132

Human carotid body

Electron micrograph

The lumen (Lu) of a small vein is widened between two endothelial cells like a sinusoid; then it divides into two fine canals which penetrate between the neighbouring endothelial cells (Lup). The lumen of the sinus is surrounded by endothelial cells (E). Numerous vesicles (V) as well as a few mitochondria (M) and lipid droplets (L) can be observed in the cytoplasm (Cyt) of the endothelial cells. The nuclei (N) of the endothelial cells are large, vary in shape, and are surrounded by a relatively sparse cytoplasm. Note the pericytes (Pc) in the upper and lower corners of the picture. Cisterns of endoplasmic reticulum (Er) as well as scarce vesicles (V) can be seen in their cytoplasm. Lamellae of the basement membrane (Bm) between the endothelial cells and the pericytes can also be discerned.

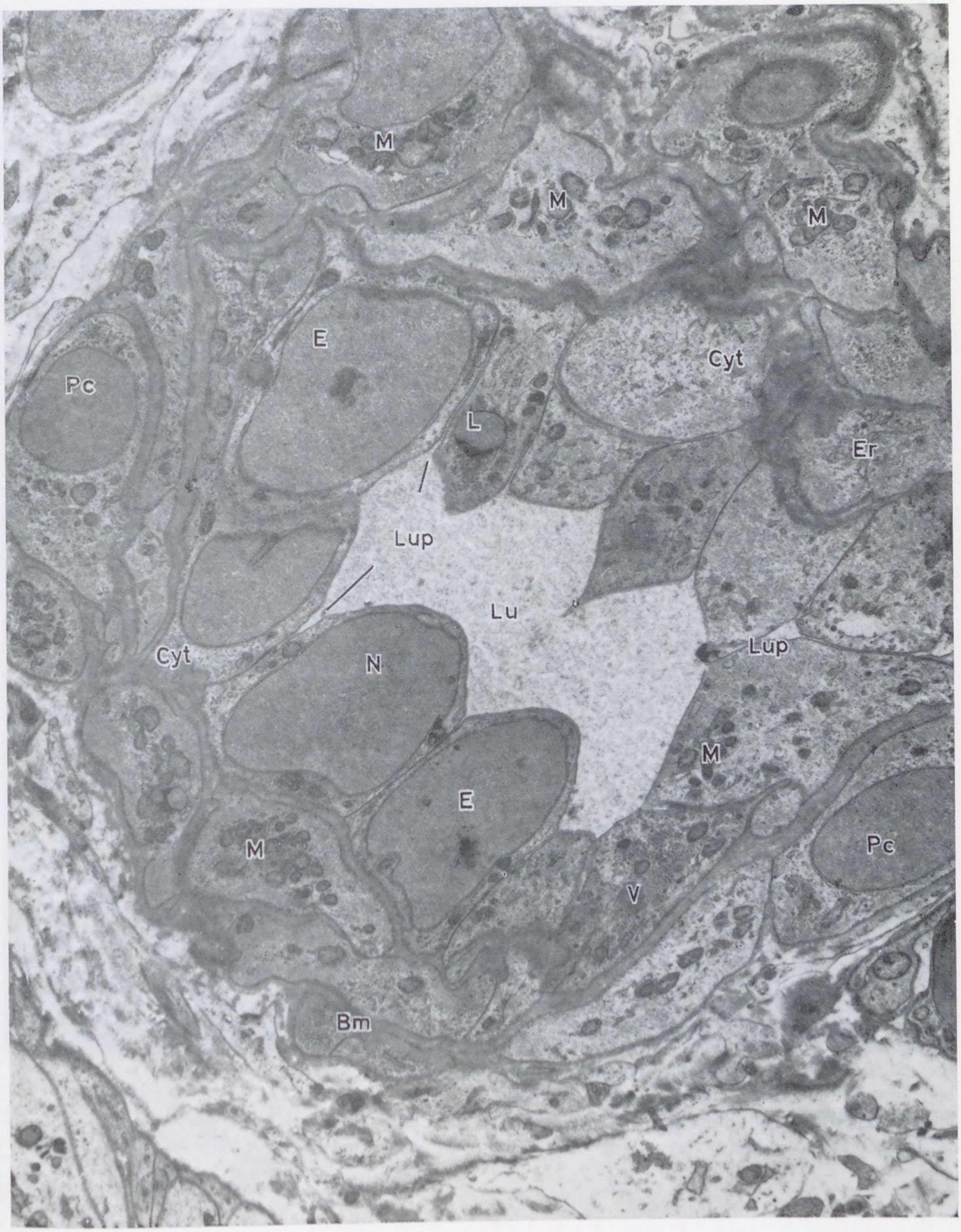
M
M
M
E
Cyt
Pc
L
Er
Lup
Lu
Cyt
N
Lup
M
E
Pc
M
V
Bm

Plate 133

Human carotid body

Jabonero's silver impregnation

Axons of the periglandular plexus (c) bearing numerous varicosities can be seen in the connective tissue bundles (a) and among nuclei of connective tissue cells (b) in the capsule of the carotid body. In the upper right corner, transverse section of a large glomerulus is surrounded by the periglomerular connective tissue and periglomerular plexus (d). This latter consists of varicose fibres of various calibre and contains a few nerve endings (e).

Comparative neurohistological comments

Glomeruli of the human carotid body are abundantly supplied with nerve fibres which form plexuses around the organ (periglandular plexus) as well as around and within the glomeruli (periglomerular and intraglomerular plexus). The term "periglandular plexus" dates back to the time when the carotid body was considered to be a gland (called "intercarotid gland"). This plexus is located in the connective tissue encasing the organ; it is composed mainly of myelinated fibres, but several unmyelinated fibres are also intermingled. In some species (hedgehog, horse and hog) nerve cells, too, occur in this plexus. These unipolar nerve cells seem to belong to the parasympathetic system while the multipolar forms appear to be of sympathetic origin. Nerve cells of parasympathetic origin are present in the hedgehog and rat whereas sympathetic cells can be found in the cattle and horse. The superior cervical ganglion plays an important role in the innervation of the carotid body.

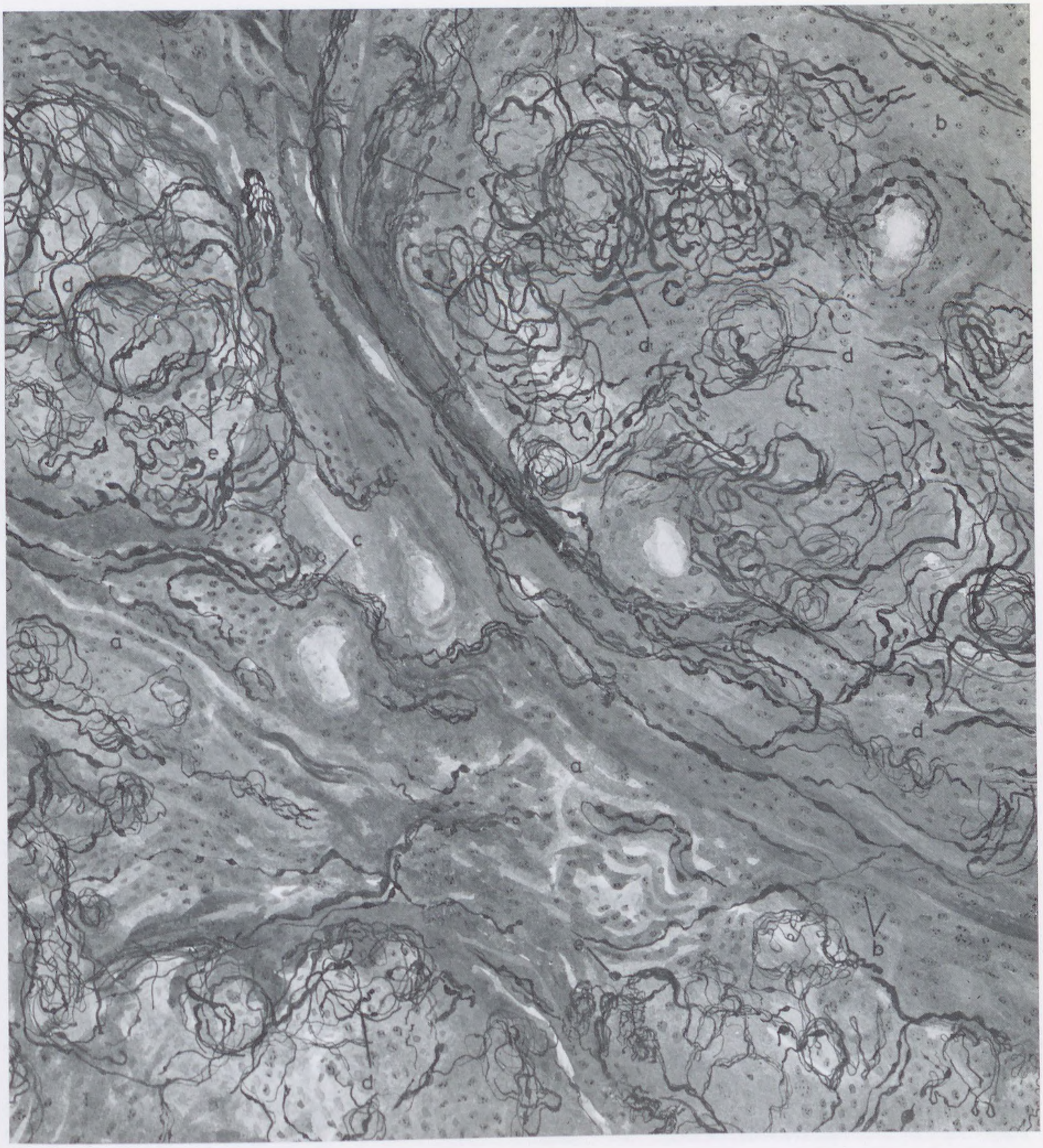
b
c
d
d
d
e
c
a
d
a
e
b
d

Plate 134

Human carotid body

Ábrahám's silver impregnation

Glomeruli (a) surrounded by the axons of the periglomerular plexus. Round nuclei and small centrally situated nucleoli (b) of glomus cells can be seen in the glomeruli. Nerve fascicles (c) composed of wavy fibres (d) and loose networks (e) run along the margins of glomeruli. The network of fibres is particularly rich in the connective tissue septa bordering two or more glomeruli simultaneously. These bundles send off fibres to the intraglomerular plexus which breaks up into fine branches terminating around the glomus cells. Well-impregnated preparations show that each glomus cell receives nerve supply from at least two nerve fibres. The nerve endings are round and dense but also empty and slightly elongated forms can be detected. Numerous contradictory results concerning the nerve endings, their shape, number and localization have been published in the literature. Recently we have been able to demonstrate unequivocally in human bioptic material the existence of nerve endings; their number is high, they are round in form, and terminate among or upon the glomus cells. These findings have been confirmed by electron microscopic examinations. In addition, it has been shown that the nerve fibres enter into a synaptic connection with the glomus cells.

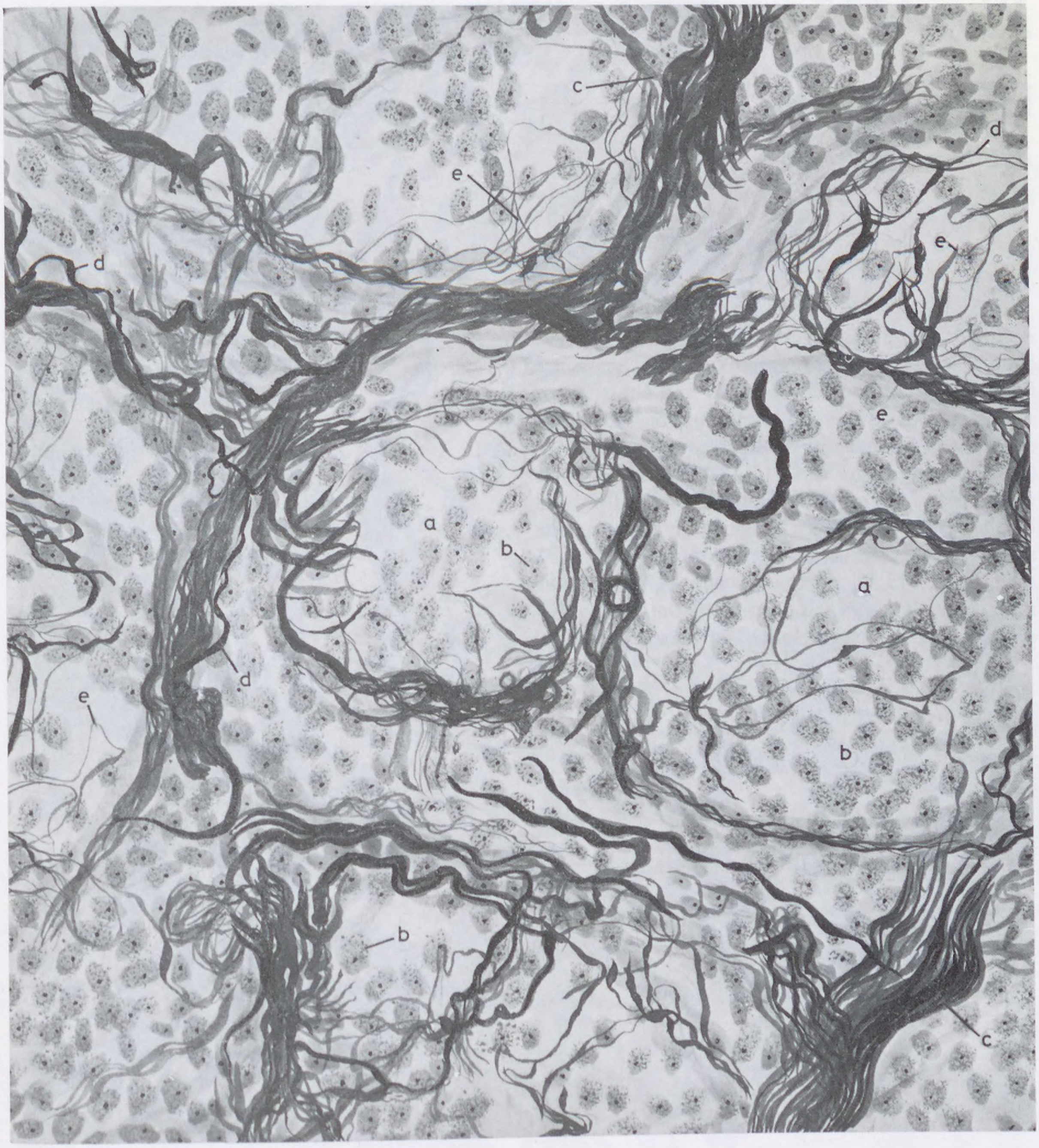
c
d
e
e
d
e
a
b
a
d
e
b
b
c

Plate 135

Human carotid body

Ábrahám's silver impregnation

A single glomerulus (a) containing numerous nerve endings (b – nuclei of glomus cells). Thin nerve fibres (c) varying both in diameter and course form a loose plexus containing numerous ring-like nerve endings (d). Fascicles of thick and wavy nerve fibres (e) containing neurofibrils (f) traverse the left half of the picture. The nerve endings, especially those on the right, are close to the nuclei of glomus cells suggesting that the nerve fibres terminate on the cell membrane. The thick nerve fascicle (g) in the lower right corner is composed of smooth-contoured fibres and belongs to the periglomerular plexus.

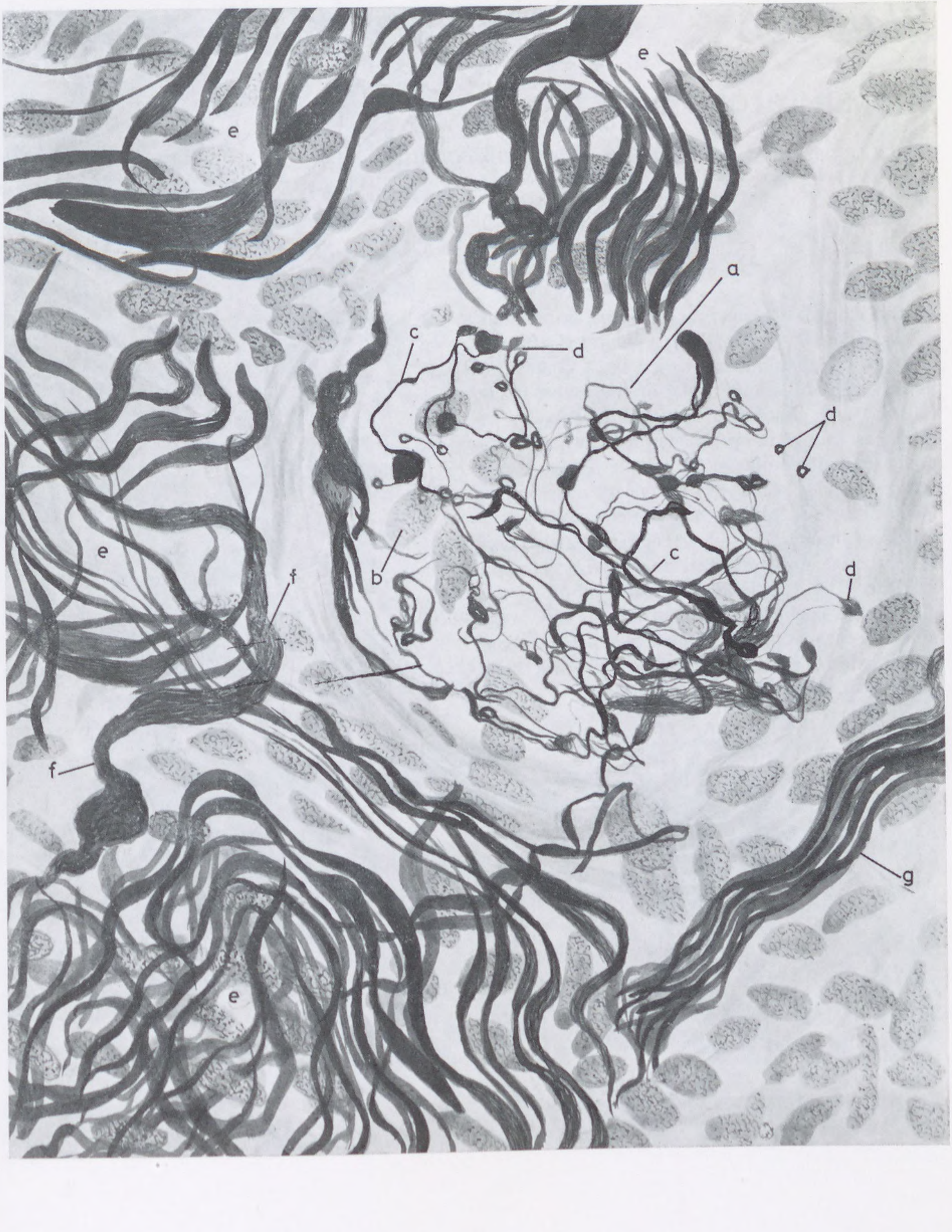
e
e
a
c
d
d
e
c
f
b
d
f
g
e

Plate 136

Human carotid body

Biopsy specimen. Ábrahám's silver impregnation

A large elongated glomerulus and smaller portions of two glomeruli (lower) fill this picture almost entirely. The glomerulus is encased by a connective tissue capsule in which nuclei of connective tissue cells (a) and connective tissue fibres (b) can be seen. Fascicles of the periglomerular plexus (c) approach the glomerulus in the middle. Fibres of the intraglomerular plexus (d) are clearly discernible. Nerve fibres (e) leaving the periglomerular plexus in groups or as single fibres penetrate the glomerulus, arborize and terminate in ring-like terminal structures (f). Termination of nerve fibres in the glomeruli is unequivocal, moreover, it is very probable that each glomus cell has its own nerve ending. Termination of more than one nerve fibre on a single glomus cell cannot be excluded either.

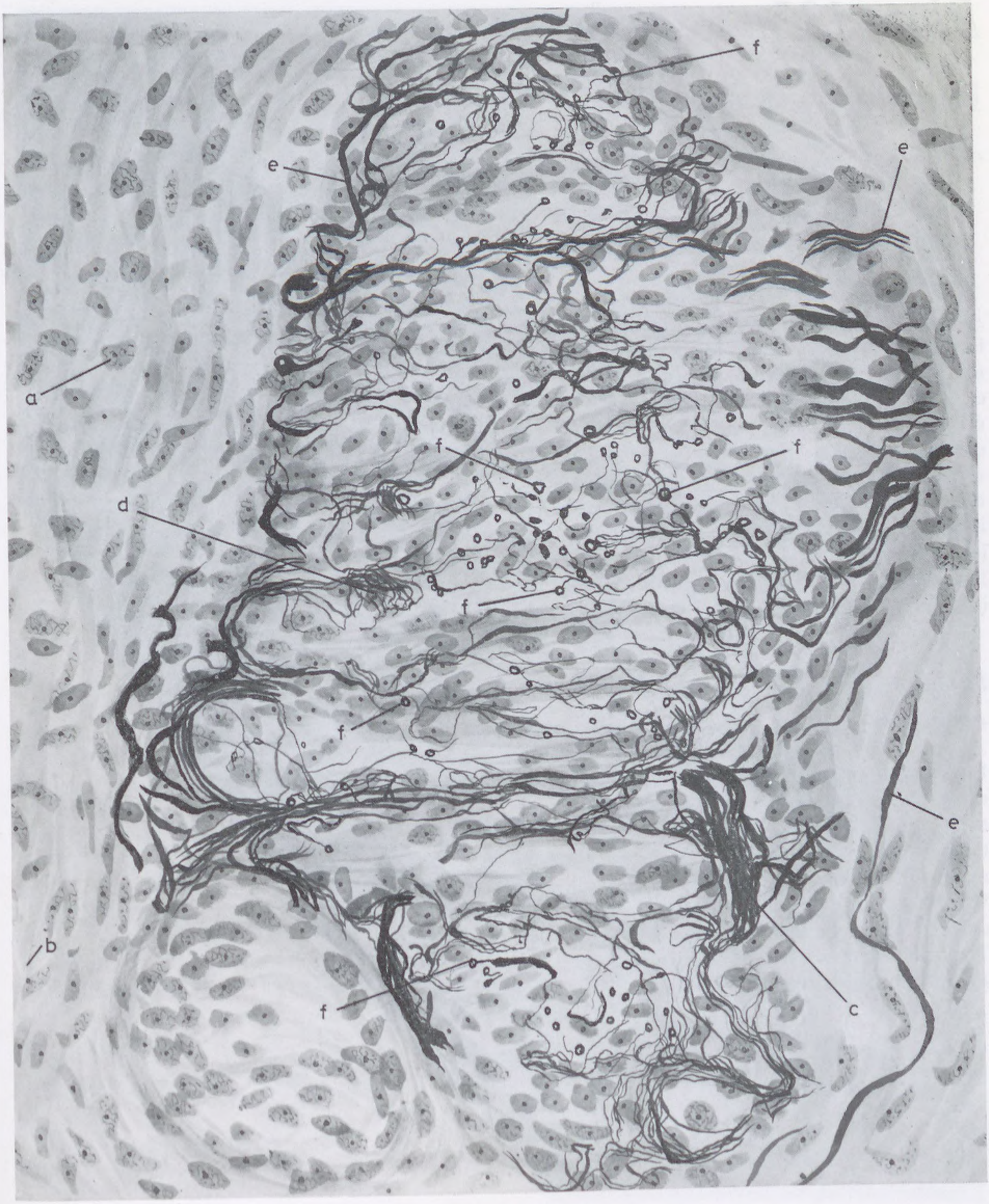
f
e
e
a
f
f
d
f
f
e
b
f
c

Plate 137

Human carotid body

Ábrahám's silver impregnation

A rich pressoreceptor system in the adventitia of a large vein. Note the longitudinal bundles of connective tissue fibres (a), nuclei of connective tissue cells (b) in the adventitia, and elongated smooth muscle cells (c). The endothelium (d) and nuclei of endothelial cells appear in the upper left corner, while a thick depressor fibre (e) passes through the middle of the picture. Intercalated lamellae varying in size and containing parallel running neurofibrils (f) can be seen along the fibre. Fine fibres (g) emerging from the thick ones terminate in end-lamellae (h): a characteristic feature of baroreceptors.

Functional neurohistological comments

Depressor fibres can fairly often be observed in the carotid body indicating that, in addition to chemoreceptor function, it also plays a role in the perception of changes in blood pressure. The system demonstrated above has been found in the wall of a vein, but similar depressor systems, and even circular fibres, are present also in the glomus arteries. The highest number of depressor terminals occur in the carotid body of the cattle.

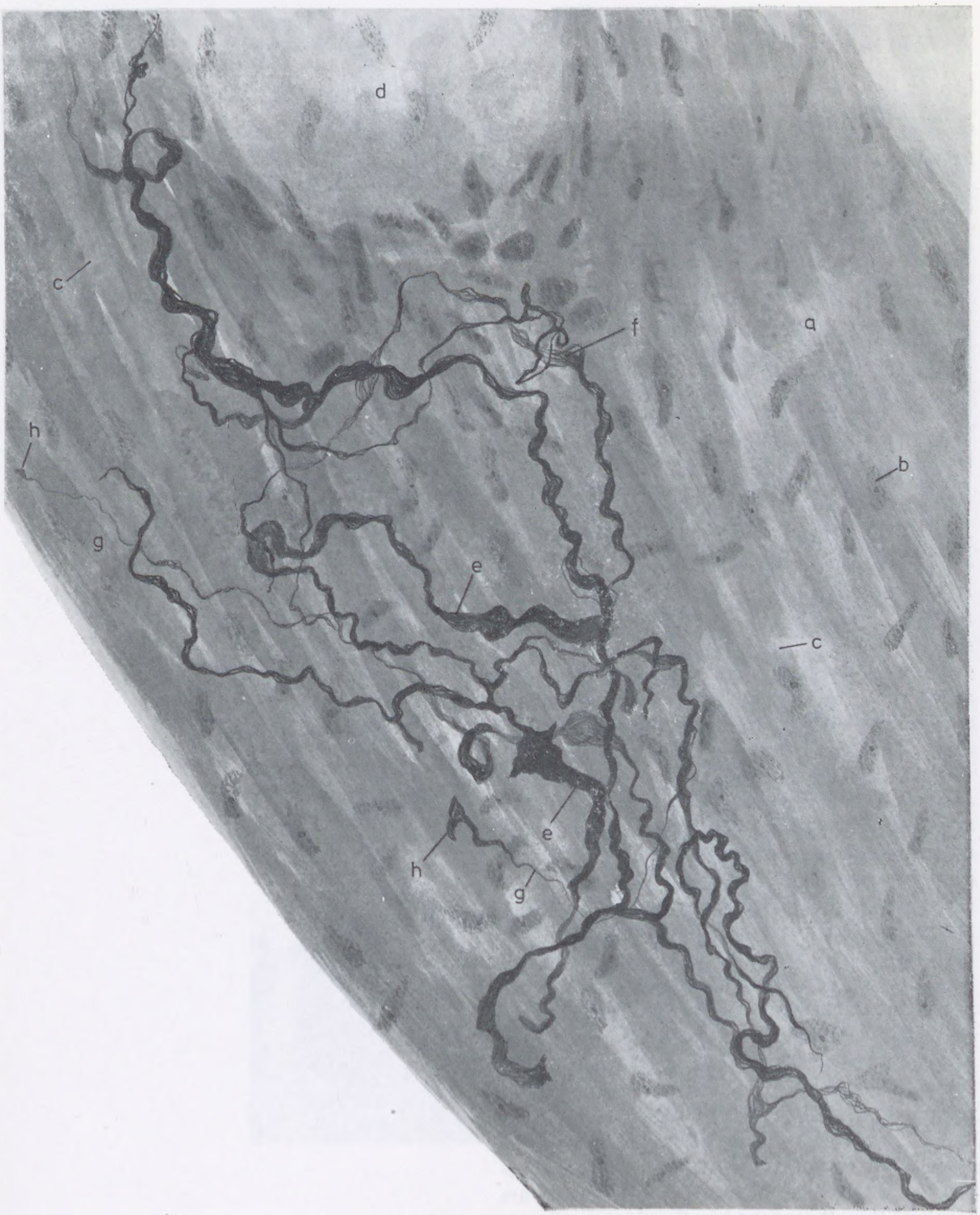
d
c
f
a
h
b
g
e
c
e
h
g

Plate 138

Human carotid body

Electron micrograph

Elongated Schwann's cell (Cm – cell membrane) is surrounded by collagenous fibrils (Cf). Axons (Ax) are attached by means of mesaxons (Ma) formed by the elongation of the cell membrane. Note the cross-sections of neurofilaments (Nf) within the axons.

Comments

As shown by the present picture, mesaxons within the cytoplasm of Schwann's cells may differ considerably. In the simplest form the cross-section of the axon is attached to the cell membrane with a mesaxon. If two or more axons are present, they are linked to the cell membrane by separate mesaxons. This case is illustrated by the above picture where five axons are surrounded by separate mesaxonal membranes. The axons are generally situated at the periphery of the cytoplasm of Schwann's cells. Cross-sections of neurofibrils can clearly be demonstrated in all of them. In other cases the mesaxons traverse through the cell and its processes. Occasionally these systems are so complicated that the course of the individual mesaxons can hardly be followed. These types of systems are often present in the immediate vicinity of chemoreceptor cells. This finding raises the question whether there is any difference between the capsular cells and Schwann's cells. In our opinion these two cell types are the same. Of course it has to be emphasized that the mesaxonal systems in Schwann's cells often assume different forms. In the cells containing complicated mesaxonal systems the mitochondria are narrower than those found in the glomus cells.


Nf
Ax
Cm
Cf
Nf
Ax
Ma
Ma
Cf

Plate 139

Human carotid body

Electron micrograph

Various cells of the carotid body and numerous club-like synapses can be seen in this picture. The term club-like synapse has been coined by us and denotes junctions which are identical with the light-microscopic end-knobs and end-discs. In these junctions the enlarged axon terminals lie in immediate proximity to the glomus cells. Several mitochondria and vesicles can be seen in the presynaptic bag, the synaptic membranes do not show thickenings. Note the chemoreceptor cell (Chc) on the left containing vesicles of different size, the double nuclear membrane (Nm), and the nucleolus (Nu) at right within the nucleus (N). Next to the chemoreceptor cell two capsular cells (Cac) are visible; they are separated by two distinct cell membranes (Cm). Both cells have well-marked processes; one, originating from the upper cell (Pro), is very long and thin and encircles more than half of the chemoreceptor perikaryon. Vesicles and cisterns of Golgi's apparatus (G) and mitochondria (M) as well as a large round lipid droplet (L) can be observed in the cytoplasm of the capsular cells. Round or elongated, club-like axon terminals (Eb) are attached to the cell membrane of the capsular cells, or, occasionally invaginated into the cytoplasm, as seen in the upper capsular cell. The nuclei (N) in both capsule-cells have the same shape as the cells themselves and show constrictions. In the centre of the picture, beneath the lower capsular cell a portion of a Schwann's cell (Sch) can be seen. Axons (A) surrounded by mesaxons (Ma) occur in its cytoplasm. An endothelial cell (E) bordering a thin branch of a sinus (Si) is shown in the upper left corner. The lumen of the sinus is occupied by a red blood cell (Rc). Note another endothelial cell and its characteristic segmented nucleus as well as a portion of a dichotomically branched sinusoid (Si, right). A Schwann's cell (Sch) appears on the extreme right; numerous mesaxons (Ma) and club-like axon terminals (Eb) of various shape are clustered around the cell. A lysosome (Ly) is located within one of the processes of a capsular cell (lower right corner). Lamellae of the basement membrane (Bm) can be recognized in both the right and left upper corners of the picture. Mitochondria (M) and synaptic vesicles (V) can be distinguished in the club-like synapses.

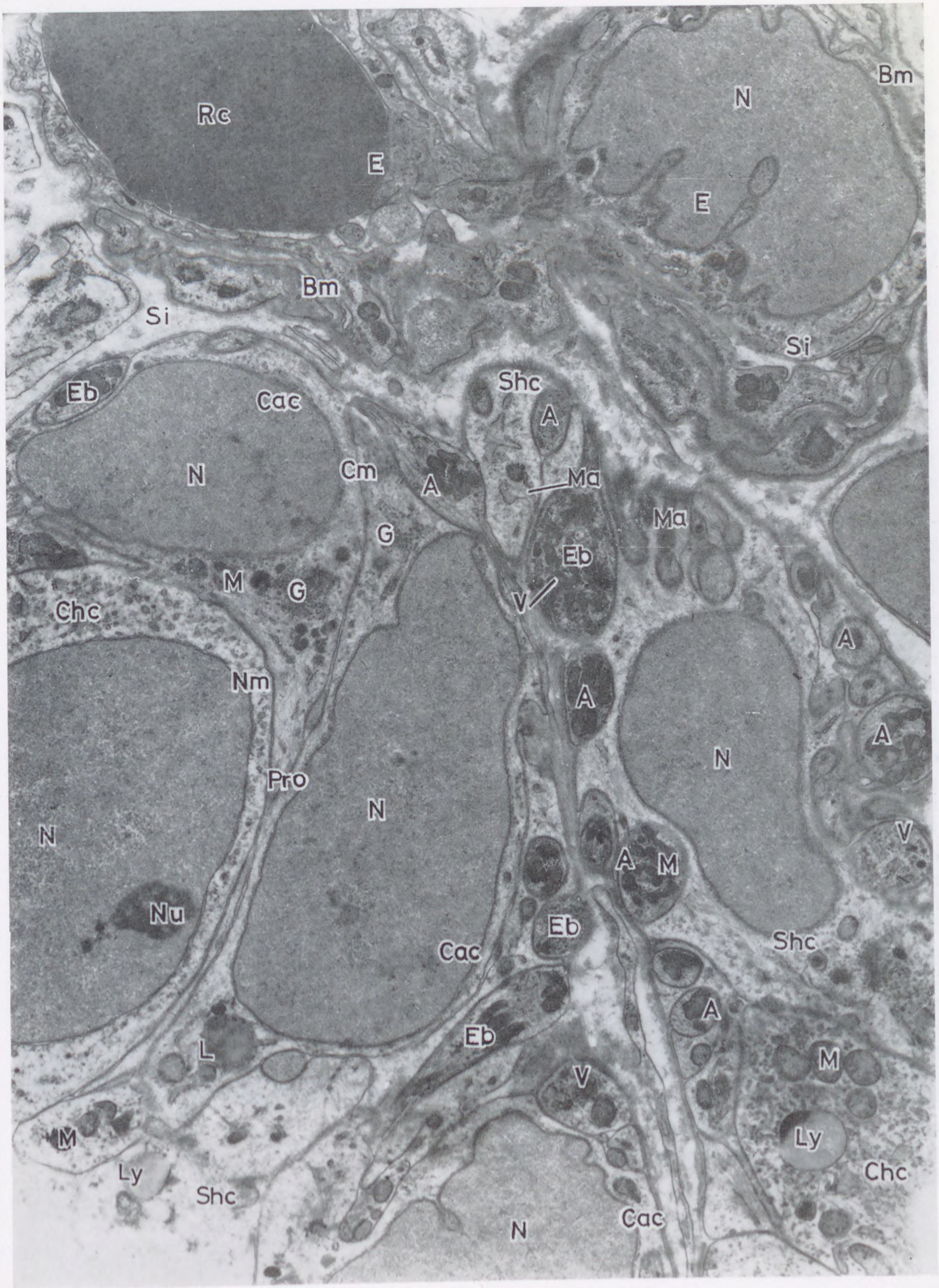
Rc
E
N
Bm
E
Bm
Si
Si
Eb
Cac
Shc
A
N
Cm
A
Ma
Ma
G
Eb
M
G
V
Chc
Nm
A
A
N
A
Pro
N
N
V
A
M
Nu
Eb
Cac
Shc
A
L
Eb
M
V
M
Ly
Ly
Chc
Shc
N
Cac

Plate 140

Carp *(Cyprinus carpio)* kidney

Bielschowsky–Ábrahám silver impregnation

Top: cross-sections of two renal tubuli (a) with nerve fibres (b) in the layer of simple columnar epithelium. Bottom: longitudinally sectioned tubule (c) in which a wavy nerve fibre (d) of changing width runs in the epithelium along its entire length. Epithelial cells (e) and the lumen (f) can be discerned in both the cross- and longitudinally sectioned tubuli.

Functional neurohistological comments

Single nerve fibres and nerve bundles can be found also in the renal parenchyma. Large plexuses emerge from the bundles in the vicinity of blood vessels. The nerve fibres in the epithelium of the tubuli might be regarded as receptors. Only in the carp could nerve fibres be observed in the tubular epithelium of the kidney. This, however, does not mean that they are absent in the kidney of other kinds of fish; the possibility of unsuccessful impregnation cannot be ruled out. The fibres are probably pressoreceptors perceiving changes in pressure caused by the passage of excretum through the tubular lumen. They might play a role in excretion, resorption or in the regulation of the function of the extremely complicated system of endoplasmic reticulum in the epithelial cells. Moreover they might inform the higher nervous centres about the functional state of the epithelial cells. Nerve fibres are present also in other regions of the renal parenchyma, most of them around the blood vessels. Nerves contain vasomotor elements but many of them supply the adventitia, participating in vasomotor reflexes as receptors.

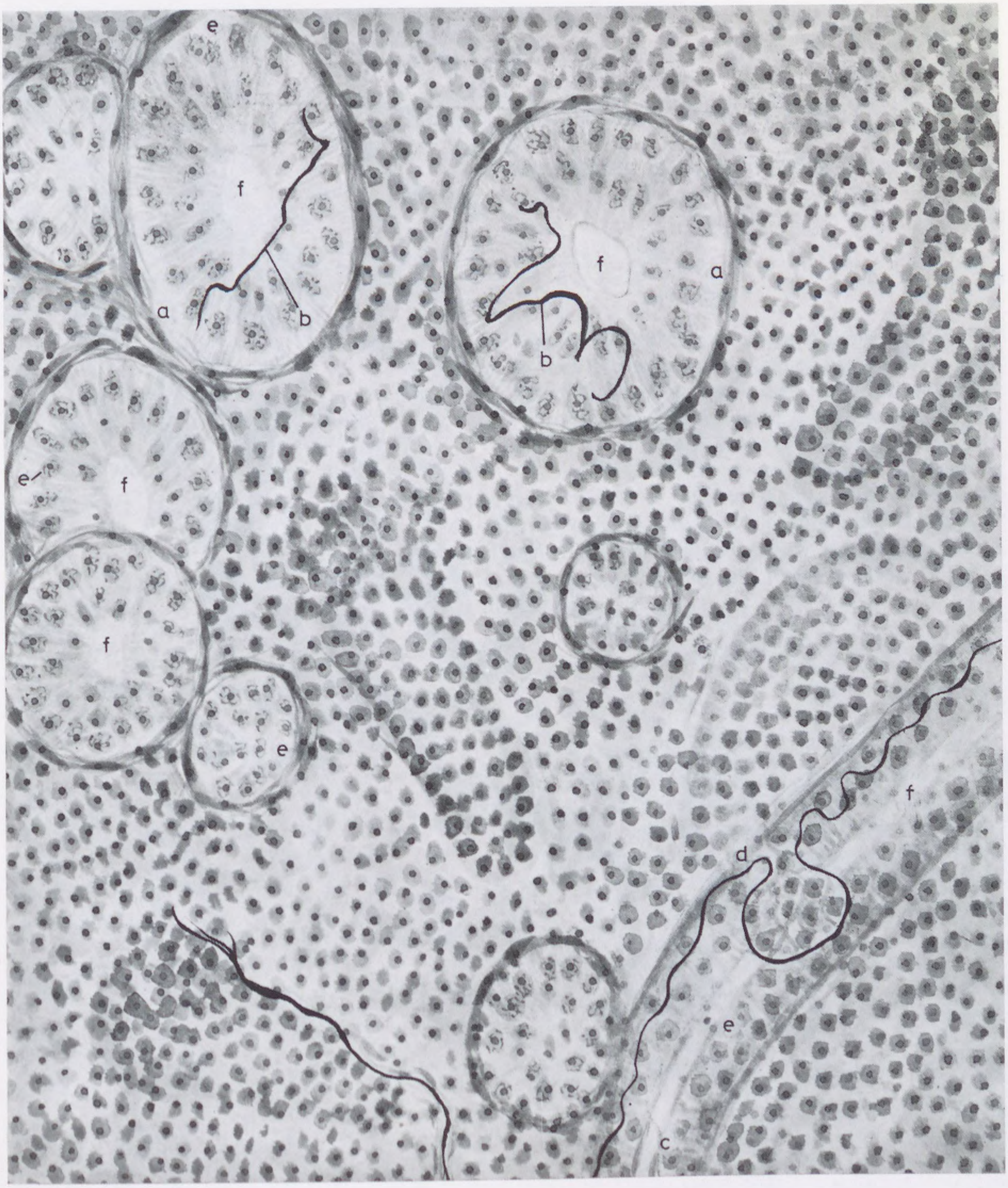
e
f
a
b
f
a
b
e
f
f
e
f
d
e
c

Plate 141

Marsh-frog *(Rana ridibunda)* kidney

Bielschowsky–Ábrahám silver impregnation

This picture shows a small, loosely structured ganglion consisting of round, elongated or polyhedral cells (a) with nuclei and dense nucleoli and cytoplasmic granules (b). A plexus of fine, wavy, smooth-contoured fibres of sympathetic origin (c) passes through the lower half of the picture. Two shovel-shaped nerve endings (e) appear in the middle. Several meandering, smooth-edged nerve fibres (d), which are in close connection with the epithelial cells (f – nuclei of epithelial cells) can be observed.

Functional neurohistological comments

Although the general structure of the nervous elements suggests effector characteristics, the end-rings around the nerve cells might be regarded as receptors. Since such changes occur also among the epithelial cells, we may suppose that their function is analogous with that of the intraepithelial fibres of the carp kidney (*see* Plate 140).


d
b
e
a
f
e
c
b

Plate 142

Desert monitor *(Varanus griseus)* kidney

Bielschowsky–Ábrahám silver impregnation

Left: cross- and longitudinal sections of collecting tubuli (a). A capillary system appears in the middle of the picture; some of the capillaries form large loops (b). Since this section was obtained from the vicinity of the ureteropelvic junction, the nuclei of connective tissue cells (d) fill out the connective tissue (c) between the tubuli. Nerve fascicles (e) start out from the right upper corner which then form a rich plexus. Single fibres as well as groups of fine branches (g) leave the plexus; the individual terminal ramifications (f) penetrate into the tubuli to pass among the epithelial cells.

Functional neurohistological comments

The abundance of the nerve fibres both on the surface and within the walls suggests neural control of the tubuli. The highest number of nerve fibres occur around the blood vessels, but there are many – mainly straight and fine axons – that supply the epithelial cells of the renal tubuli. In our opinion these latter may function as receptors.

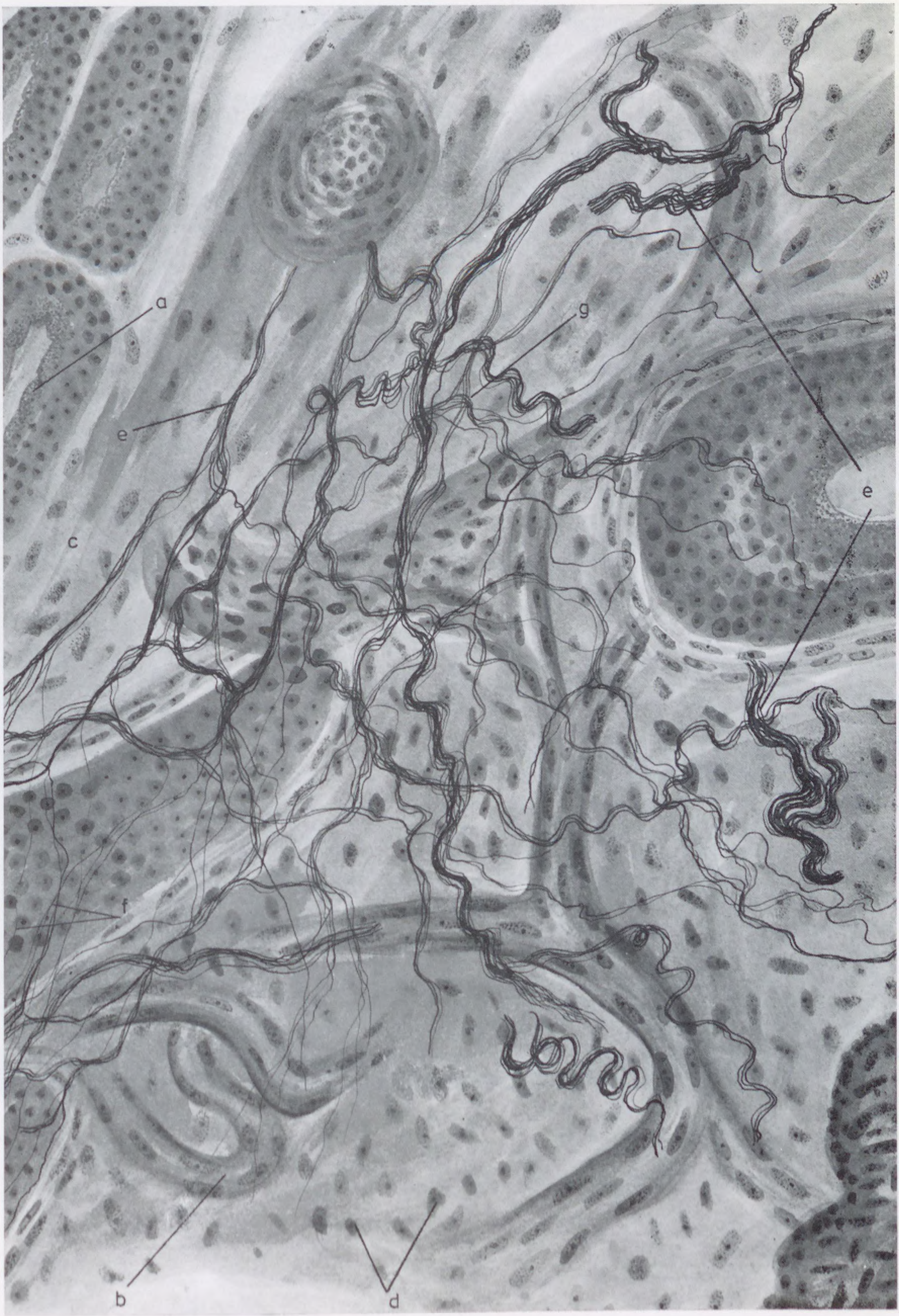
a
g
e
e
c
f
b
d

Plate 143

Desert monitor *(Varanus griseus)* kidney

Bielschowsky–Ábrahám silver impregnation

Nerve fibres in the wall of a longitudinally cut tubule. The tubule lies within a connective tissue lamella (a); the nuclei of the connective tissue cells (b) show up from the background. Due to the tangential section, the epithelial cells (c) constituting the wall of the tubule form a continuous field. A thick nerve fibre (d) filled with neurofibrils runs downwards from the upper right corner. The enlarged lamellar segments (e) resemble the intercalated lamellae of the depressor fibres. The epithelium is interwoven with a rich network of fine, occasionally varicose nerve fibres (f).

Functional neurohistological comments

The thick fibre and the network system probably constitute a receptor apparatus. As shown by this picture, the kidney of reptilia, especially the part of the medullar substance which contains the final portions of the collecting tubuli, is richly innervated. Numerous nerve fibres emerging from the loose plexuses in the connective tissue penetrate the basement membrane of the tubular epithelium. There they break up into branches which surround the tubuli in the form of a loose network. Presumably these are receptors. Terminations and junctional forms of the individual fibres could not be revealed so far.

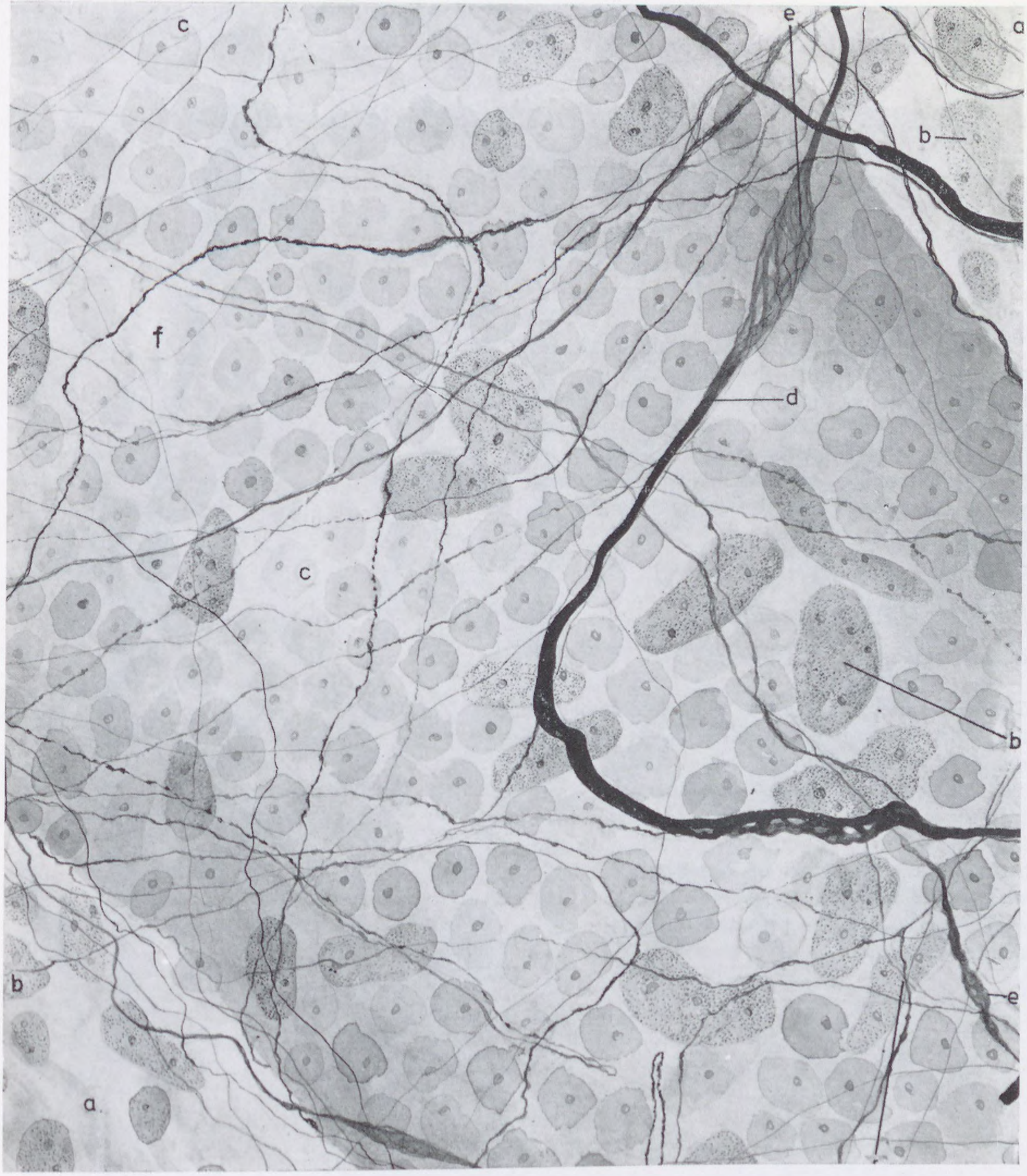
c
e
a
b
f
d
c
b
b
e
a

Plate 144

1. Collared dvoe *(Streptopelia decaocto)* kidney

Bielschowsky–Ábrahám silver impregnation

The blood vessel (b) filled with red blood cells (c) almost completely enfold the renal tubuli (a). The majority of the nerve fascicles (d) innervate blood vessels but the nerve fibres running in a fascicle at the extreme left (e) may be regarded as receptors on the basis of their localization. The single nerve fibres which pass through the epithelial cells (f) are also receptors.

Functional neurohistological comments

The innervation of the kidney of birds is similar to that of reptiles. Along the arterial walls there are rich nerve plexuses. In some places they approach also the tubuli to which they send fibres. No proper receptor structures can, however, be found either in the parenchyma or within the tubular walls. On account of their localization, fine terminal networks which surround some segments of the tubuli and send branches to the epithelium should be considered receptors.


b
a
f
b
c
c
f
e
e
d

Plate 144

2. Human renal artery

Bielschowsky-Gros silver impregnation

Encapsulated end-coil in the adventitia (a). The connective tissue fascicles are clustered around the coil and form a connective tissue capsule (b). After bifurcation a thick myelinated nerve fibre (c) gives rise to a branch (d) that thickens within the connective tissue capsule and forms a characteristic coil (e). Myelin sheath (f) and nuclei (g) of Schwann's cells can be identified along this fibre. Two varicose terminals of the other, thinner, branch (h) also participate in the constitution of the coil.

Functional neurohistological comments

Nerve endings similar to that shown in this picture can be found in the renal artery of other mammals as well. These sensory structures and dendritic terminal ramifications seem to regulate the amount of blood flowing through the kidney.

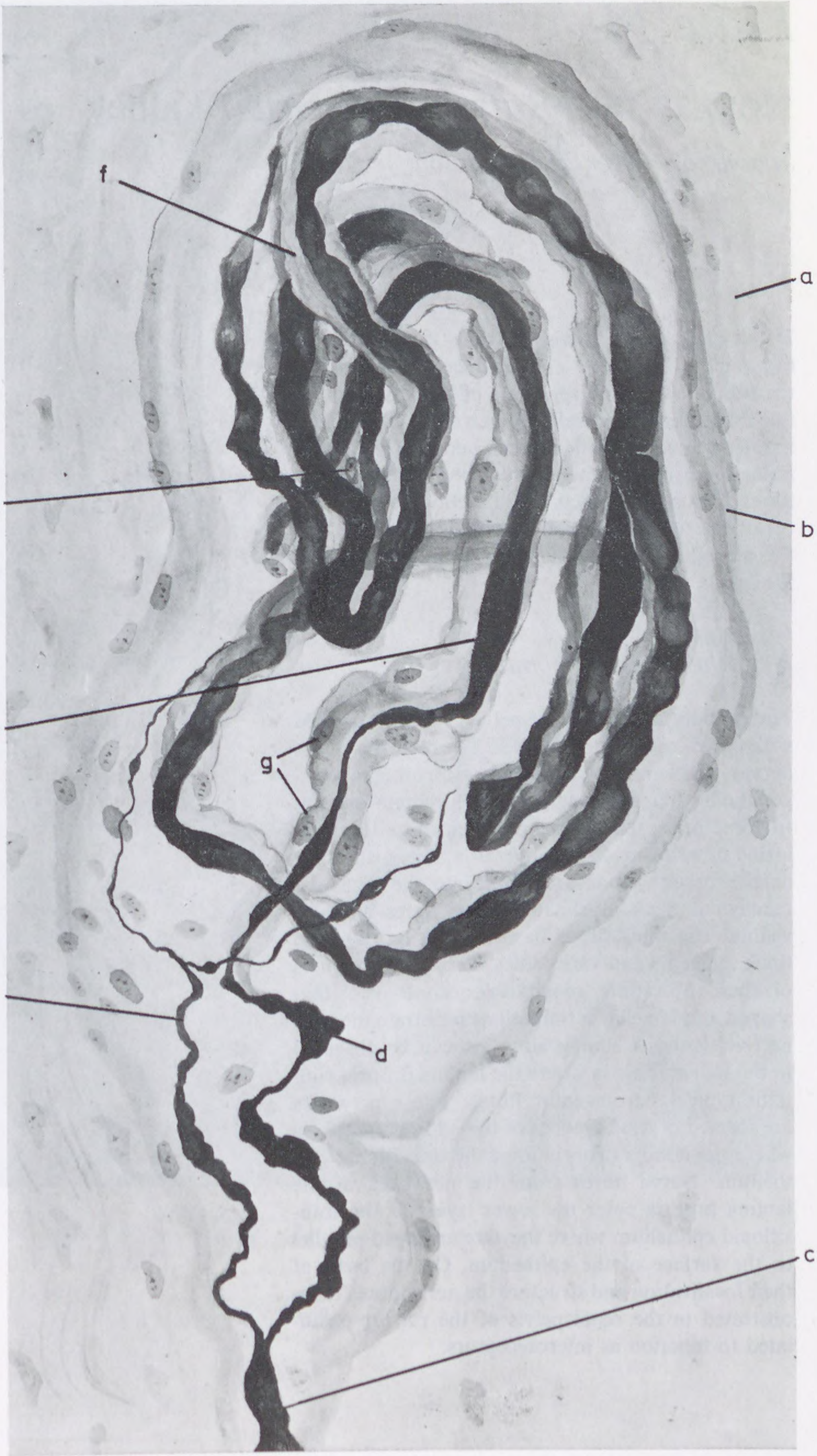
f
a
g
b
e
g
h
d
c

Plate 145

Norway rat *(Rattus norvegicus)* kidney

Jabonero's silver impregnation

Detail of the renal pelvis. Portions of renal tubuli (a), nuclei (b) of the epithelial cells constituting the tubular wall, and segments of blood vessels (c) filled with red blood cells. A nerve fascicle (e) giving rise to several smaller axonal bundles (d) appears in the lower right corner of the picture. Single nerve fibres (f) some of which may function as receptors (g) of the tubular epithelium pass close to the epithelial cells. Some nerve fibres bear large varicosities (h).

Neurohistological comments

The adventitia of the renal pelvis is richly supplied with nerve trunks and plexuses. The majority of the nerves are smooth-contoured sympathetic postganglionic fibres belonging to the efferent system. In some nerve trunks, especially in those localized in the outer layer of the adventitia and in the connective tissue islands projecting into the renal parenchyma, thick myelinated nerve fibres are also visible. The thick fibres have alternating thin and thick segments and varicosities. Terminal structures of these fibres are remarkable: knob-like, ring-shaped and lamellar terminations penetrate the connective tissue. A similar situation can be observed in the tunica mucosa where the lamina propria contains typical baroreceptor fibres. Loose networks are formed of the branches of these fibres especially where the lamina propria joins the transitional epithelium. Nerve fibres from the networks in the lamina propria enter the lower layers of the transitional epithelium where they are arranged parallel to the surface of the epithelium. On the basis of their localization and structure the nerve fibres demonstrated in the renal pelvis of the rat are postulated to function as interoreceptors.

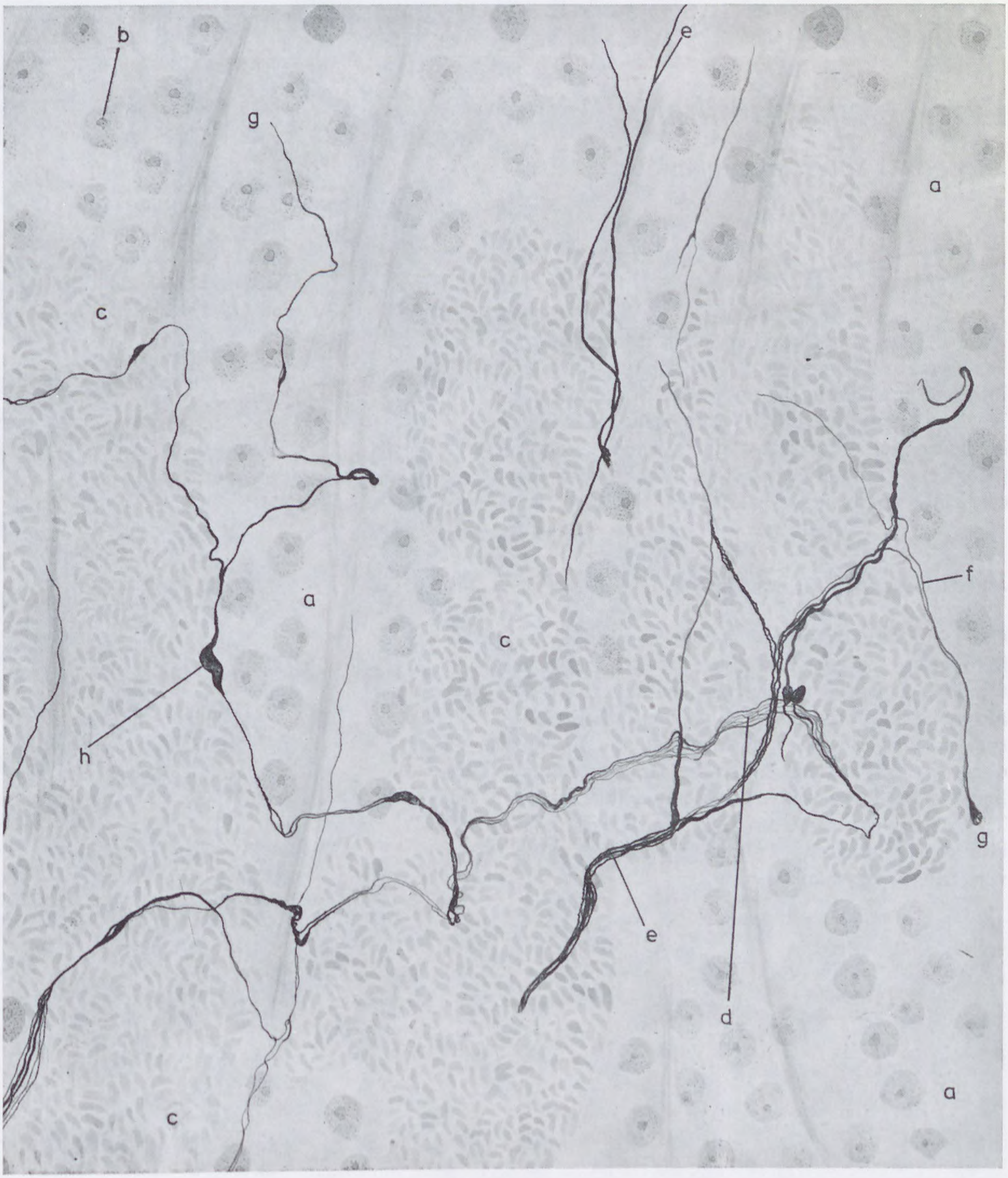
b
g
e
a
c
a
c
h
f
g
e
d
c
a

Plate 146

Dog *(Canis familiaris)* kidney

Jabonero's silver impregnation

A large group of the papillary ducts (b) with blood vessels (a) and nerves (d). The capillary (a) divides into two branches in the upper half of the picture. Nuclei of the epithelial cells (c) are arranged in lines in the wall of the papillary ducts. Single receptor fibres (e) of the nerve fascicle (d) terminate in the epithelium as free nerve endings (f).

Neurohistological comments

Convoluted renal tubuli and smooth-edged autonomic fibres can be revealed in this picture. The nerve terminals with receptor function can be seen in the most clear-cut form along the papillary ducts. Sensory systems are observed especially in rats and dogs, in the area subjacent to the papillary epithelium and in the connective tissue between the tubuli. The subpapillary nerve terminals transmit information to the higher centres about the condition of the whole tubular system.

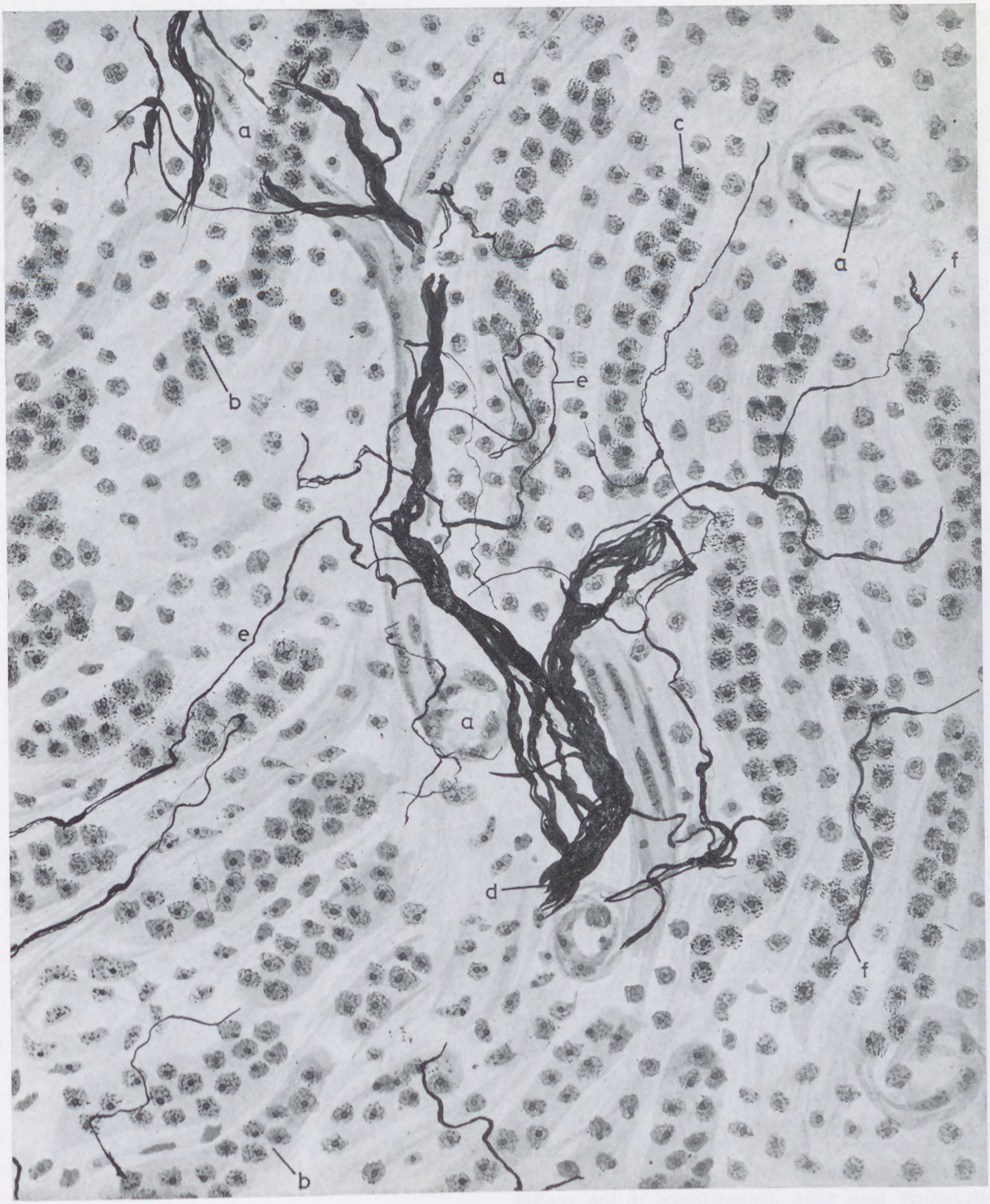
a
a
c
a
f
b
e
e
a
d
f
b

Plate 147

Sandy lizard *(Lacerta agilis)* penis

Bielschowsky–Gros–Cauna silver impregnation

The epidermis (a) of the lizard's penis is made up of a special kind of stratified epithelium; the superficial cells have point-like endings whereby a peculiar spiny layer (b) is formed. Note the spines (c) in the superficial part of the epithelium. The nuclei of the epithelial cells (d) and those of the connective tissue cells (f) can be readily identified. Striated muscle fibres (g) of the retractor muscle lie adjacent to the connective tissue (e). Nuclei of the muscle cells (h) can also be seen. Nerve fibres (i) run both in the connective tissue and in the epithelium (j).

Neurohistological comments

The external genital organs serving race preservation, thus the continuity of the life, are rich in receptors. It would be an interesting task to follow the development of the genital receptor formations from the simple to the more complicated forms. As a young research worker, the present author demonstrated genital receptors and sensual bodies in the penis of different lizards *(Lacerta viridis, Lacerta taurica, Lacerta agilis)* using Lőwit's gold impregnation. However, the conclusions turned out to be incorrect due to shortcomings of the technique. Nevertheless the fact remains that intraepithelial nerve fibres are present in the characteristic spiny epithelium lining the cavernous system of the lizard's penis. Although they do not exhibit peculiarities characterizing receptors related to sexual activity, we think that these structures may develop into genital receptors in the course of phylogeny. This assumption is confirmed by the fact that similar structures have been demonstrated in the genital epithelium of a number of higher species.

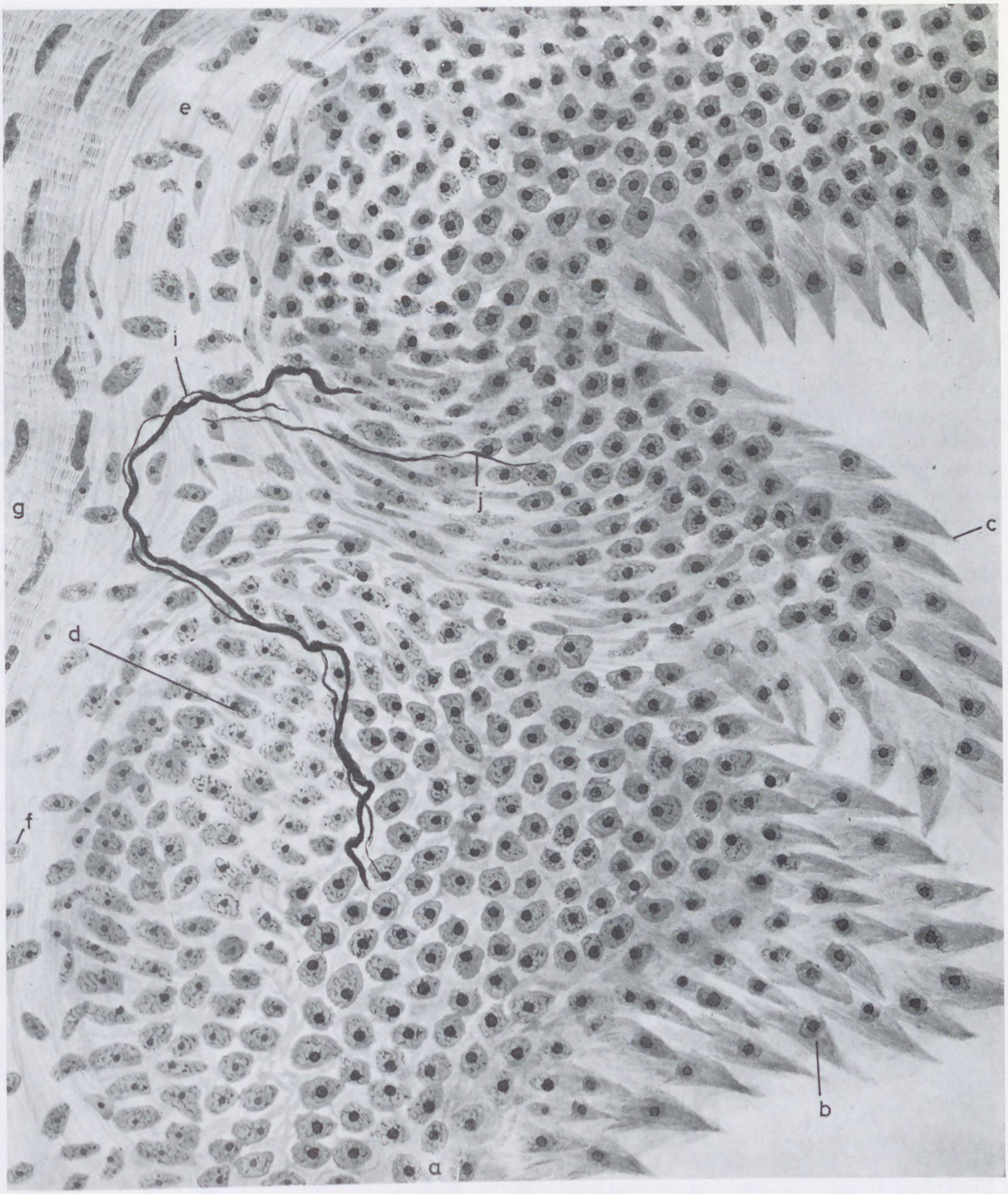
e
h
i
j
c
g
d
f
b
a

Plate 148

Norway rat *(Rattus norvegicus)* penis

Bielschowsky–Ábrahám silver impregnation

Corium (b) underlying the thick and wavy epidermis (a). Horny spines (c) ending in dark points project from the horny layer. Note the cells of the stratum germinativum (d) in the basal layer of the epidermis and the horny lamellae (stratum corneum) on the surface of the epithelium (e). In the corium (left) the connective tissue fibres (f) are arranged in wavy fascicles among the epithelial pegs (g – nuclei of connective tissue cells). Thick and wavy nerve fibres with varicosities form a bundle (h) which passes through the middle of the picture. The nerve bundle breaks up into two branches (i), one of which remains within the connective tissue while the other is directed to the epithelium. One of the connective tissue papillae (right) contains a nerve fibre coil (j) surrounded by a capsule of connective issue. Ramifying intraepithelial nerve fibres (k) esablish fine free terminals among the epithelial cells.


d
g
f
i
k
e
i
j
c
b
h
a

Plate 149

Cat *(Felis domestica)* penis

Jabonero's silver impregnation

1. Connective tissue fibres (c) arranged in fascicles and nuclei of connective tissue cells (d) can be seen in the corium (b) subjacent to the epidermis (a). Note the nuclei of epithelial cells (e) in the epidermis. Outlines of connective tissue fascicles (f) appear in the epithelium due to the unusual thickness of the section. A thick bundle of nerve fibres (g) runs in the corium. The individual nerve fibres (h) pass towards the epithelium where they give rise to several branches. Numerous meandering nerve fibres emerge from the ramifications; they constitute a loose network at the corio-epidermic border. Vertical branches leaving the network run upwards in the epithelium and terminate as free nerve endings (k) in the superficial layers.

2. A cross-sectioned horny spine (a) appears in the middle. Connective tissue fascicles (c) of the corium (b) surround the base of the spine. Round nuclei of connective tissue cells (d) are clustered in an unusual form. The nuclei (e) of the lower epidermal layers can be seen at the base of the spine. A nerve bundle (f) rich in fibres runs vertically on the left. Fine single nerve fibres (g) penetrate the epithelial layers of the base of the spine. Since the sensitivity of the spines is multiplied by the nerve fibres, the spines are regarded as genital corpuscles.

General neurohistological comments

Numerous nerve fibres are to be found in the penis of the cat while the typical terminal nerve fibre coils are almost completely absent. The well-developed spines found in the epithelial areas are covered with a thick horny cap. The nerve fibres encircle the epithelium at the base of the spines and form a loose plexus. The Pacinian corpuscles in the corpus cavernosum are smaller than the usual size.

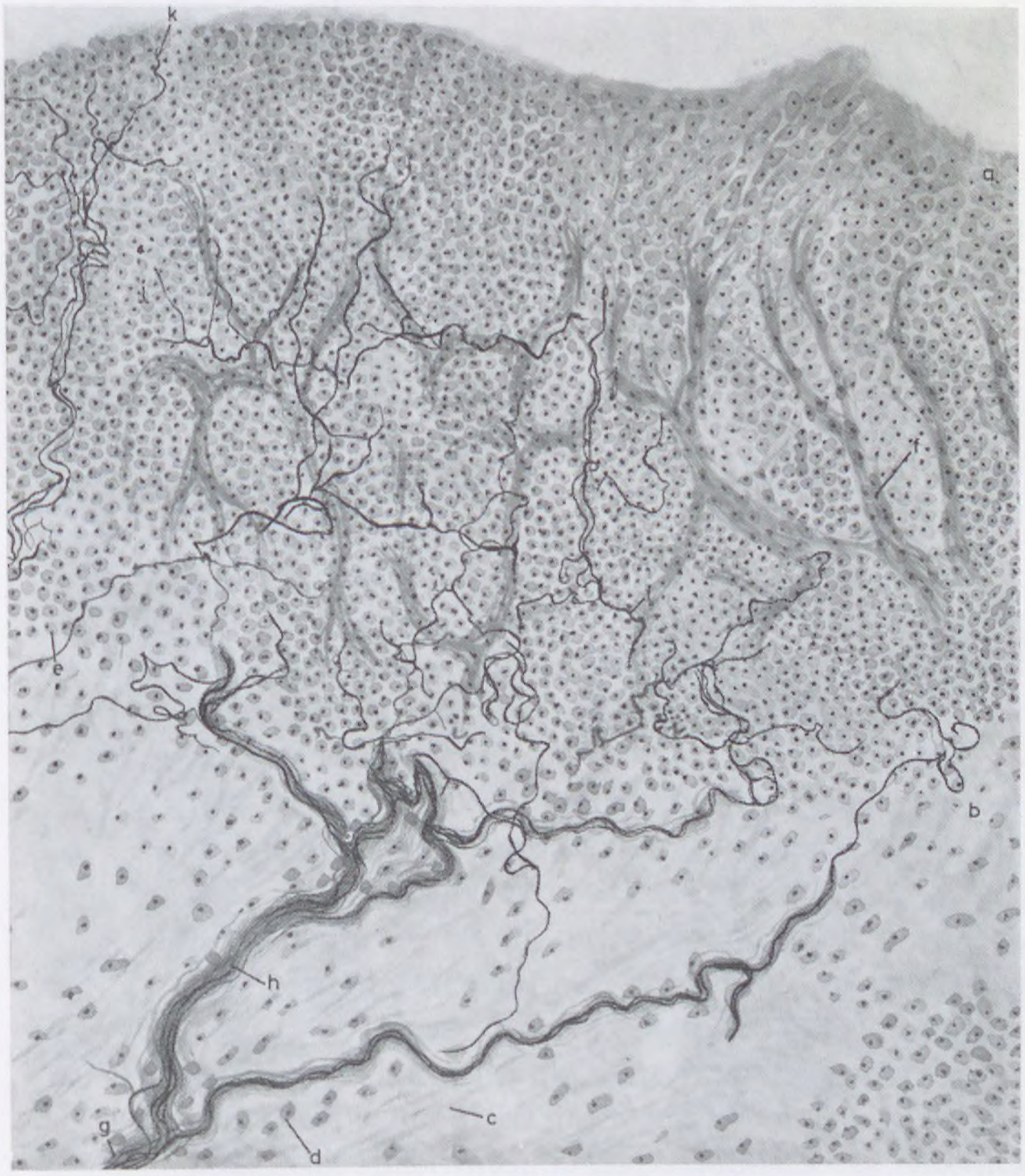

1

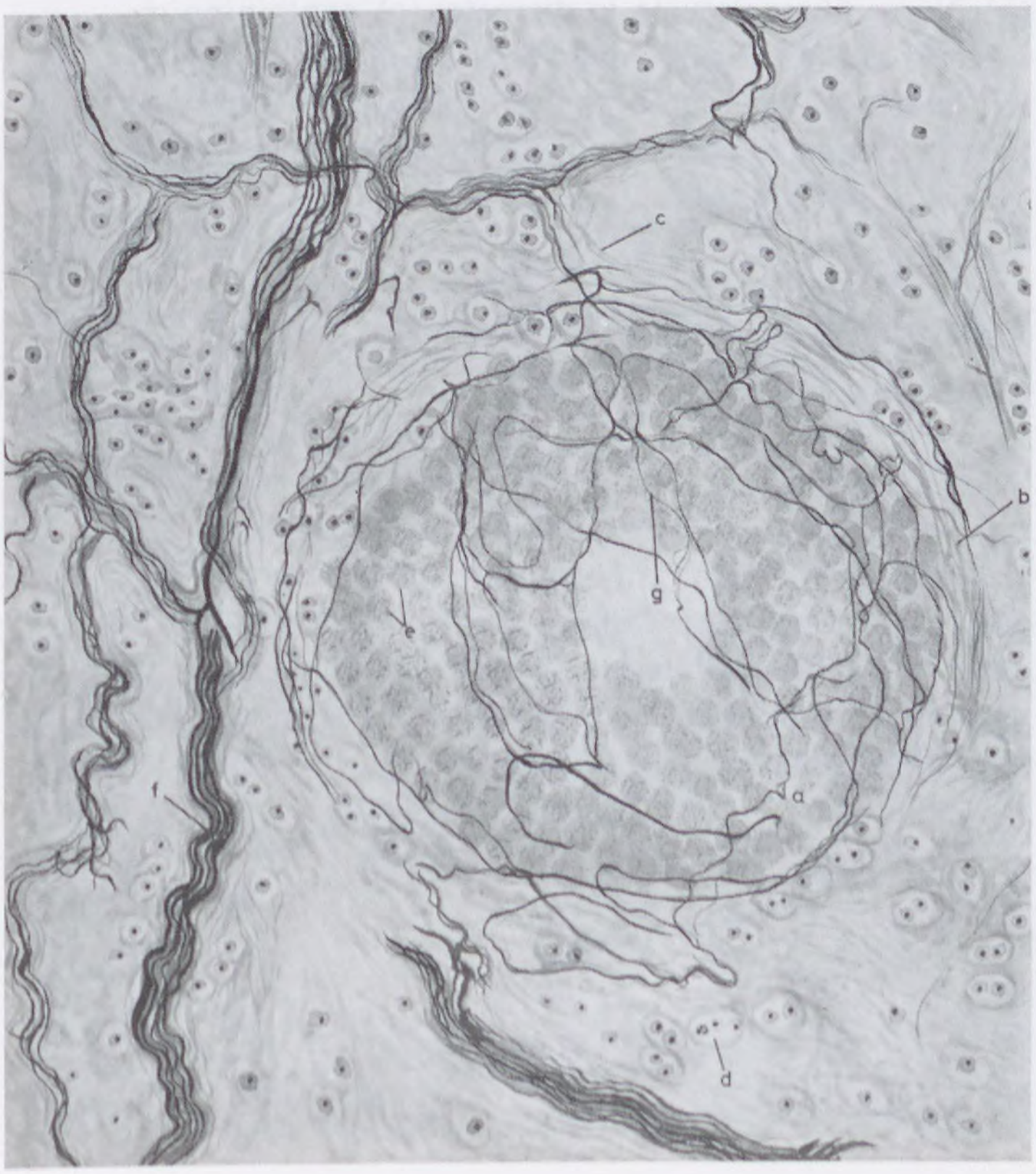

2

Plate 150

Hog *(Sus scrofa domestica)* penis

Bielschowsky–Ábrahám silver impregnation

1. On the left a genital body is seen supplied with a nerve fibre, while the nerve fibres supplying the three genital bodies on the right are not apparent. The wavy collagenous fibres (a) form a capsule of connective tissue (b) around the glomeruli. The nerve fibre entering the genital body is surrounded by myelin sheath (c). Occasionally neurofibrils (e) can be discerned in the axon (d). The genital bodies comprise glomeruli of nerve fibres (f), which have kept their myelin sheath. On the extreme right epithelial cells (g) of the penis can be seen.

2. Fine terminal system of a genital body. The nerve coil is located within the connective tissue capsule (a) composed of concentrically arranged collagenous fascicles and of connective tissue nuclei (b). Nerve fibres varying in diameter (c), containing neurofibrils (d) and elongated varicosities (e) form the terminal coil. Fine branches of the fibres terminate in elongated end-lamellae (f) filled with a loose plexus of neurofibrils.

Comparative neurohistological comments

The receptor system of the hog's penis differs from that of the rat. The typical features can be summarized as follows: in the connective tissue ground substance there are many large, round, encapsulated nerve coils of meandering myelinated fibres with empty spaces between them. A thick, wavy, myelinated fibre runs to each of the coils.

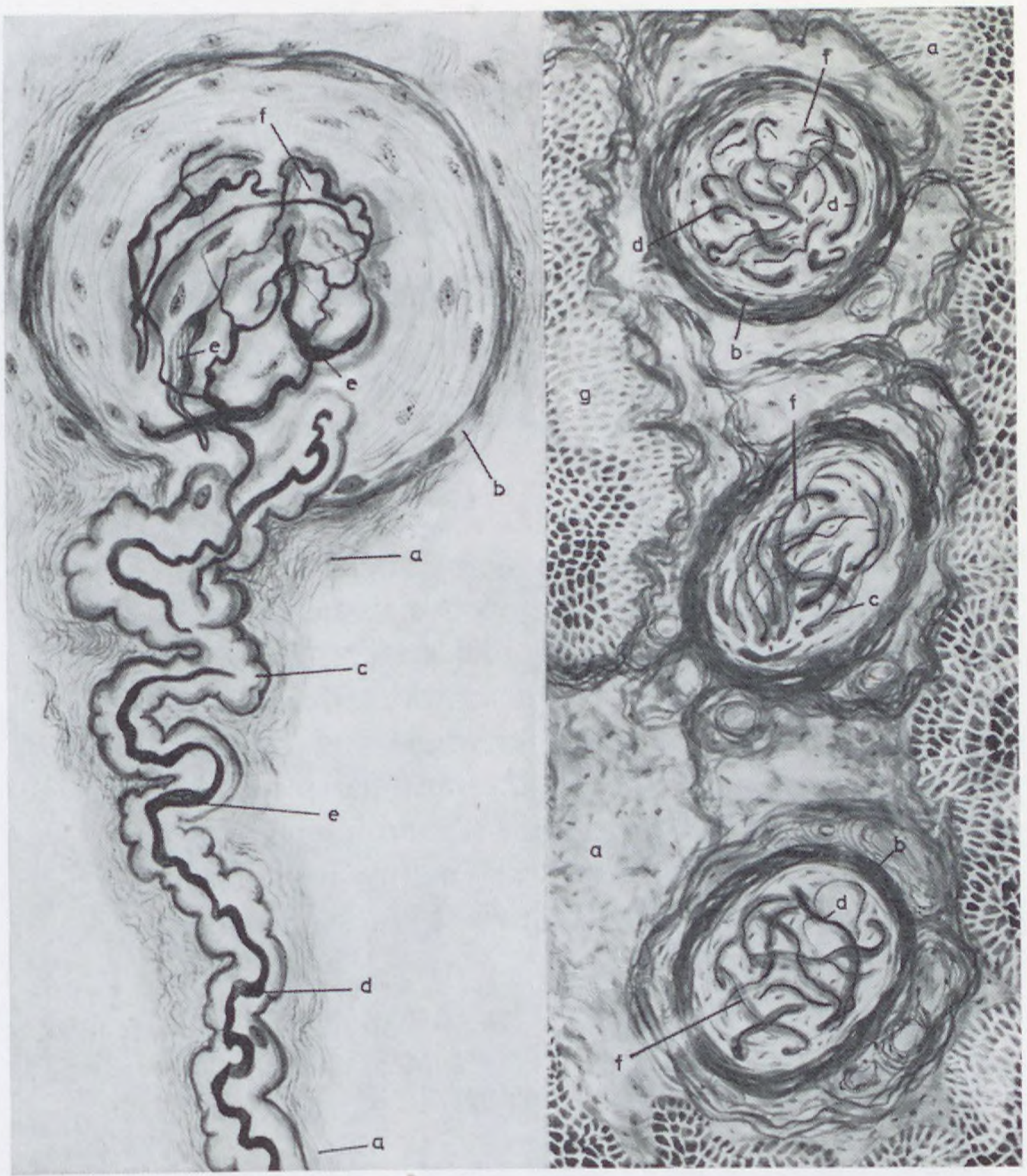

1

2

Plate 151

Cattle *(Bos taurus)* penis

Bielschowsky–Ábrahám silver impregnation

Loose connective tissue (a) containing nuclei of connective tissue cells (b) and connective tissue fibres organized in concentric or parallel systems (c). A thick nerve fibre (d) with characteristic varicosities (e) runs vertically. Peculiarly enlarged and much thinner segments alternate in the terminal section of the fibre. Note the neurofibrils (f) and intercalated lamellae in the side-branches. The fine terminal fibres (g) end either as small knobs (h) or as neurofibrillar end-lamellae (i).

Comparative neurohistological comments

A striking similarity has been observed between the nerve endings in the bovine and porcine penis. In both species loose encapsulated coils of myelinated fibres can be seen. The axon is fine and the capsule is stratified; the capsules are, as a rule, supplied by a single thick nerve fibre. The special receptor formations can be considered characteristic of the species. Essentially they are axonal ramifications which terminate in large, fine lamellae.


d
h
i
i
g
c
f
a
g
e
b
d
f
c

Plate 152

Goat *(Capra ibex)* penis

Bielschowsky–Ábrahám silver impregnation

Blood vessels, nerve plexuses and encapsulated terminal coil-systems in the corium of the penis. Pale connective tissue fascicles passing in various directions, branching capillaries as well as precapillary arteries (b) can be seen in the connective tissue (a). Most of the coil-systems are elongated and elliptic in shape, surrounded by a lamellated connective tissue capsule (c). One or two thick myelinated nerve fibres (d, e) run to each nerve ending. The nerve fibres, after having lost their myelin sheath, enter the capsule and ramify forming loose coils (f) in which a thinner branch spirals around the fibre which runs along the axis of the end-organ.

Comparative neurohistological comments

The genital bodies found in the goat's penis are rather peculiar. They are large, have a particular shape, contain thick myelinated fibres, the terminal ramifications of which are surrounded by a lamellar capsule. These genital bodies are much larger than those found in either the hog or in the cattle, and also their number is extremely high.

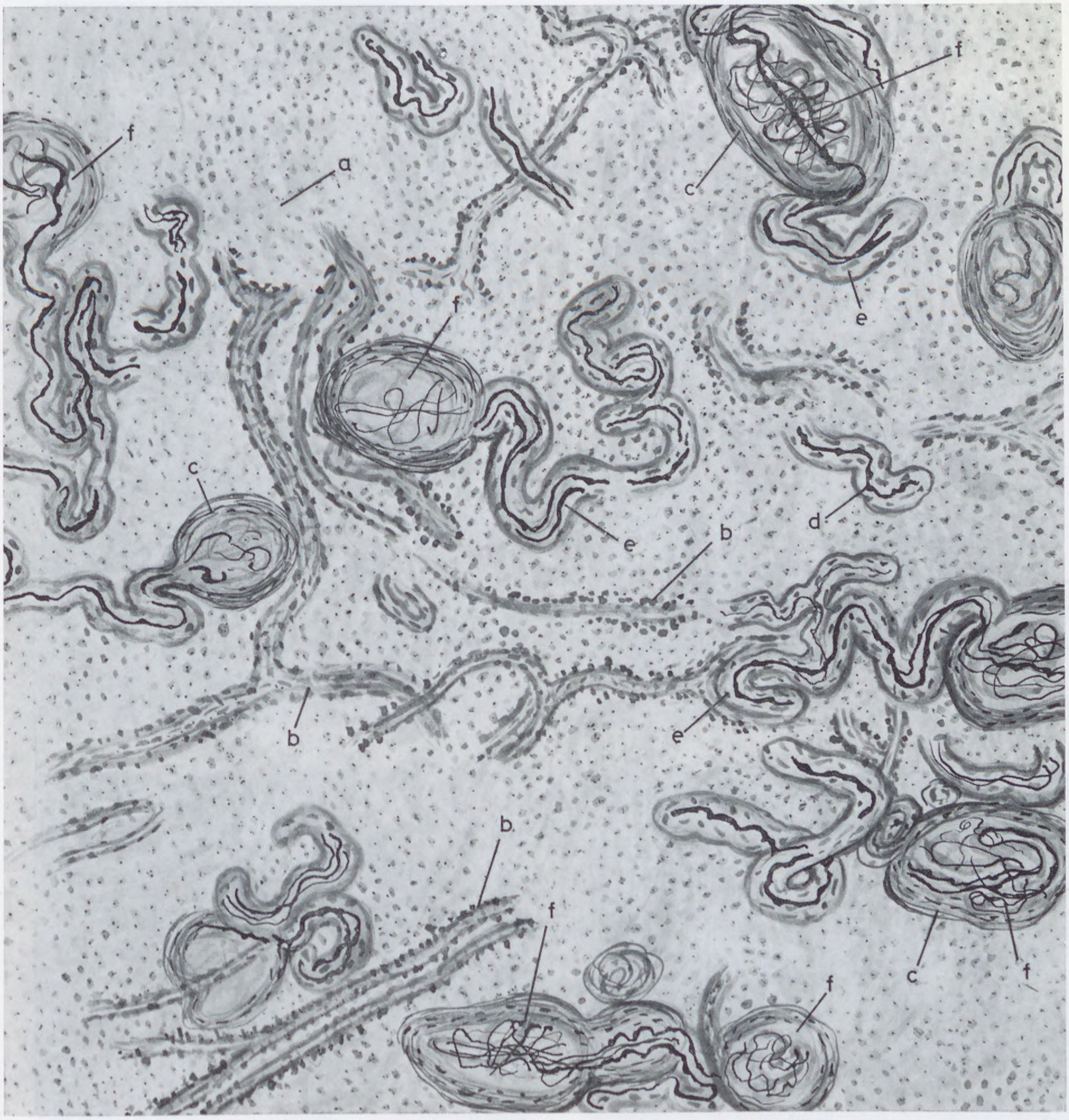
f
f
a
c
e
f
c
e
b
d
b
e
b
f
f
c
f

Plate 153

Goat *(Capra ibex)* penis

Photomicrographs. Bielschowsky–Ábrahám silver impregnation

Each of the four genital bodies shown in these pictures is surrounded by a connective tissue capsule. The capsule, which is relatively thick, is composed of concentric collagenous fascicles in which also the connective tissue cells are concentrically arranged. The pale connective tissue fascicles and the nuclei of connective tissue cells are well discernible. Having entered the genital body a single thick myelinated nerve fibre can be seen to ramify in the connective tissue of the capsule. Nuclei of connective tissue cells appear in groups around the ramifications.

Comments

The nerve fibre protruding into the genital bodies at one pole is a typical structural feature. The fibre loses the myelin sheath and ramifies *(1)*. The fine end-fibres terminate in homogeneous lamellae, which can only be observed in thin sections. The terminal ramifications form a network corresponding to the shape of the genital body *(2, 3* and *4)*. Picture *4* in which all components of the end-structure can be seen, is especially valuable from the point of view of the functional interpretation of morphological characteristics.

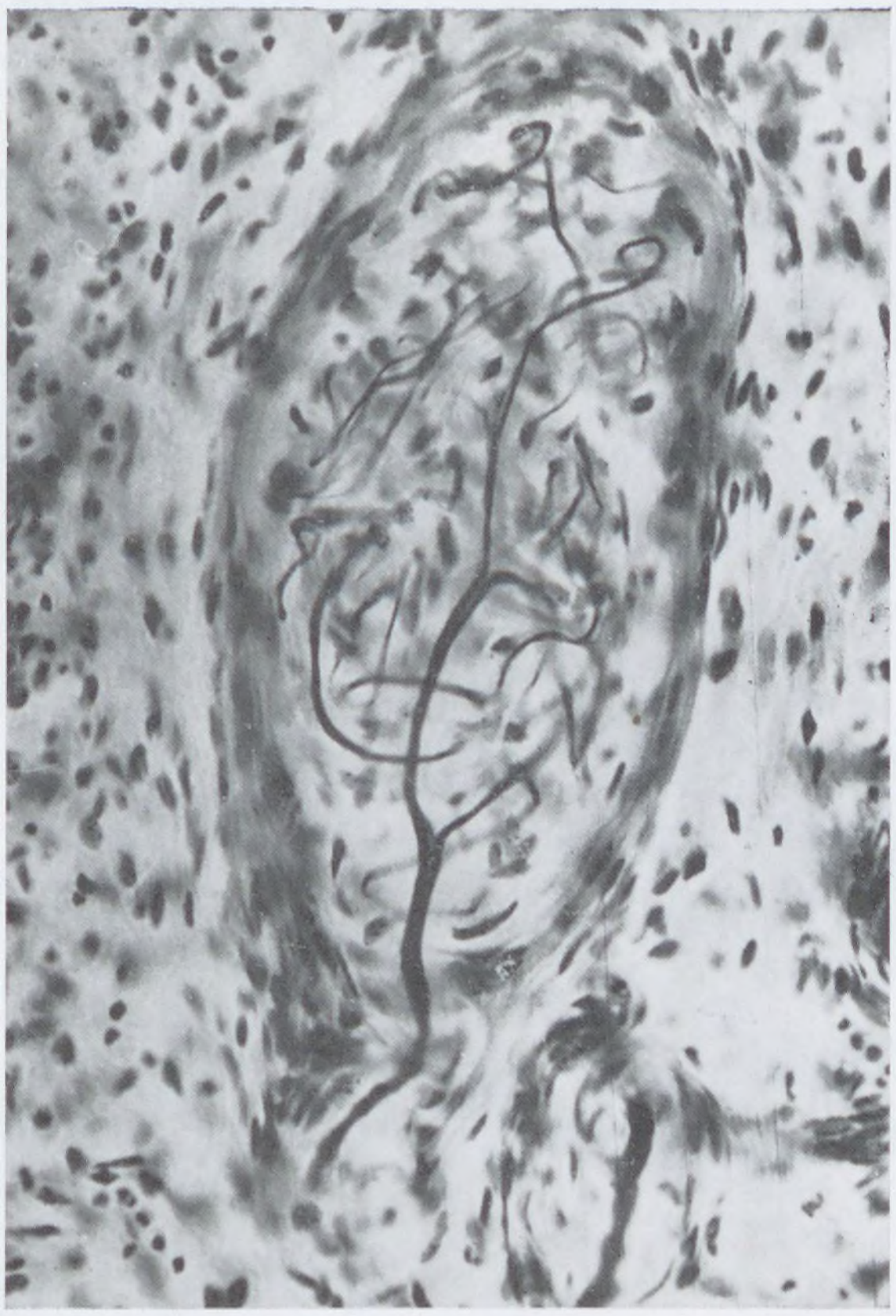

1

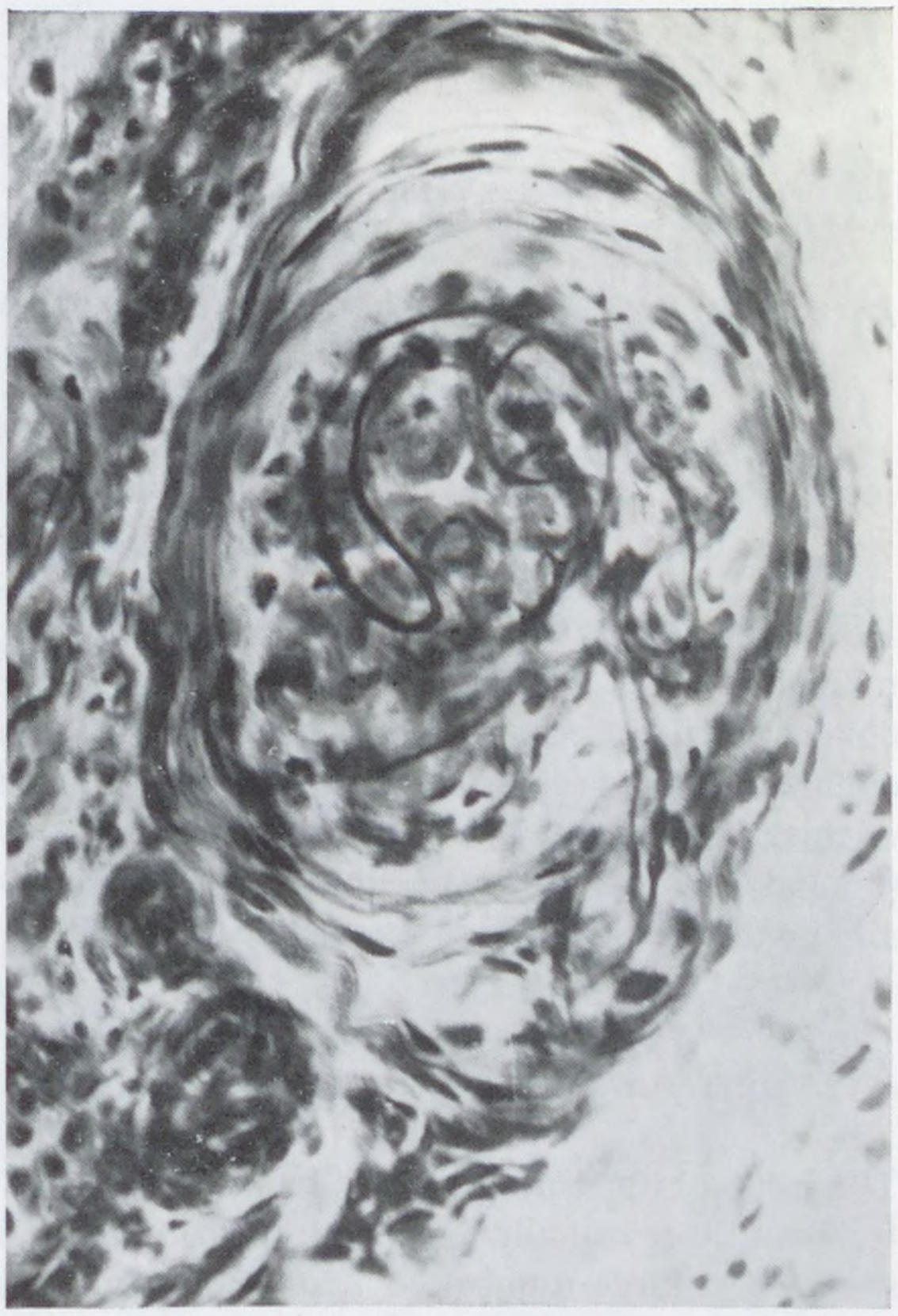

2

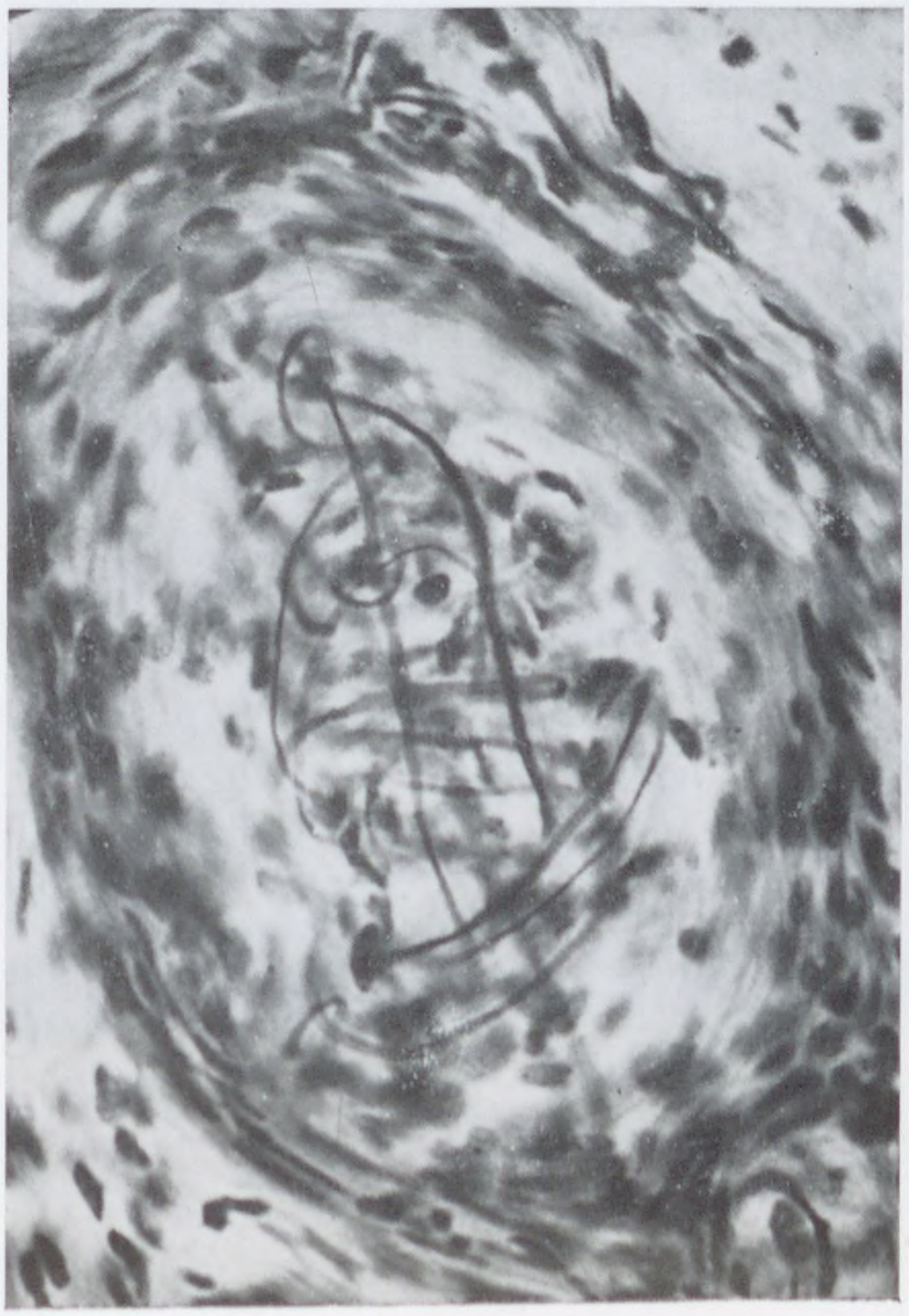

3

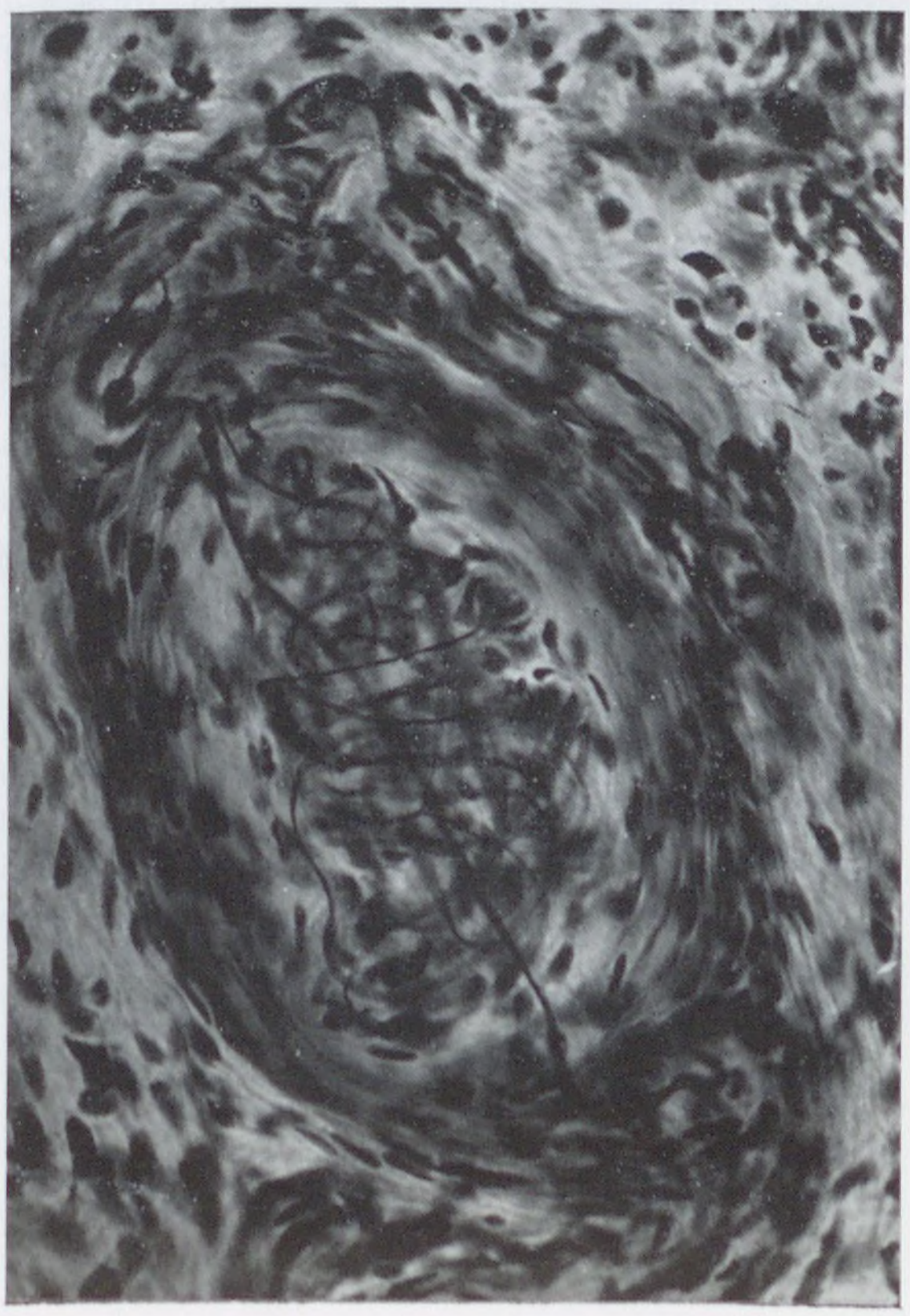

4

Plate 154

Human prepuce

Bielschowsky–Gros silver impregnation

Rows of epithelial cells (a) indicate the longitudinally cut ridges of the skin. Polyhedral nuclei of connective tissue cells (c) are scattered in the corial connective tissue (b). A nerve fascicle (d) composed of thick nerve fibres continues in a coil (e) of thick (f) and fine (g) terminal fibres, which arborize among the round nuclei of connective tissue cells (h).

Neurohistological comments

The receptor apparatuses of the human prepuce differ from those of animals in both their number and shape. The large number of nerve fibres and end-formations proves that the prepuce is the most sensitive and reflectorically the most important among the genital areas. An extremely high number of coil systems can be demonstrated in well-impregnated sections. There are two kinds of end-formations, namely the non-encapsulated, free coils and Krause's corpuscles. The former has again two types, a round, densely woven one, and an irregular, loose form. Both forms occur in the subepithelial connective tissue.

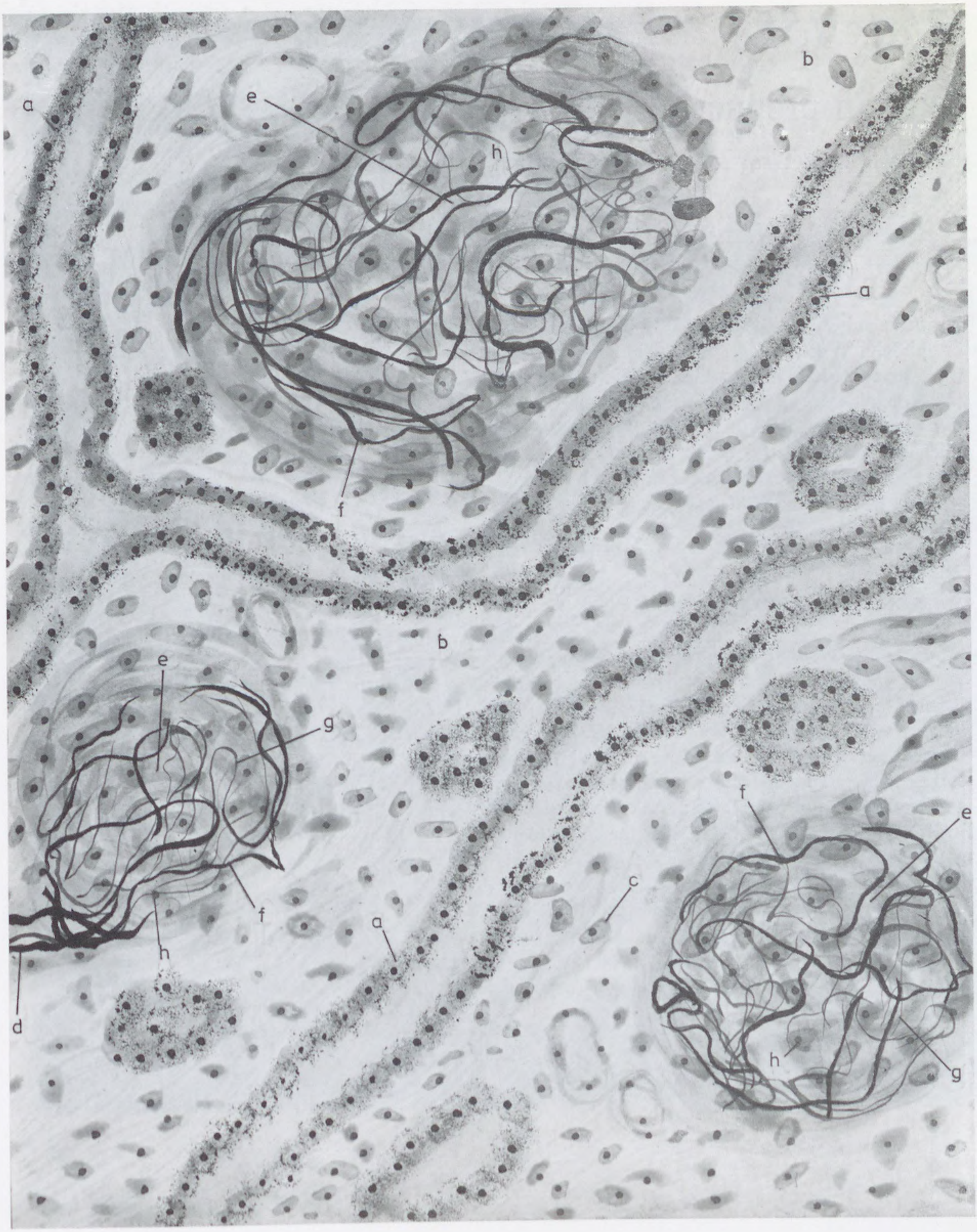
b
e
a
h
a
f
b
e
g
f
e
c
f
a
h
d
h
g

Plate 155

Human prepuce

Bielschowsky–Gros silver impregnation

Krause's end-bulb (e) bordered by longitudinal rows of epithelial cells (a) and connective tissue fascicles (b). The epithelial cells contain nuclei and nucleoli (c). Note also the nuclei and nucleoli (d) of connective tissue cells. A thick nerve fibre (f) covered by a thick myelin sheath (g) enters the end-bulb at its lower left pole. The nerve fibre forms a rich terminal plexus (coil) (h) in which many tactile cells (i) are visible.

Neurohistological comments

Some of the coil-like encapsulated nerve endings in the prepucial area are similar in structure to Krause's end-bulbs. Having lost its myelin sheath, the sensory myelinated nerve fibre ramifies. The branches form a network filling the area enclosed by the capsule. Characteristic features of these highly variable end-bulbs are as follows: the capsule enfolding the coil system is relatively thin; the coil is elongated; the terminal plexus is loosely structured. The number of Krause's corpuscles in the prepuce is lower than that of the non-encapsulated coils.

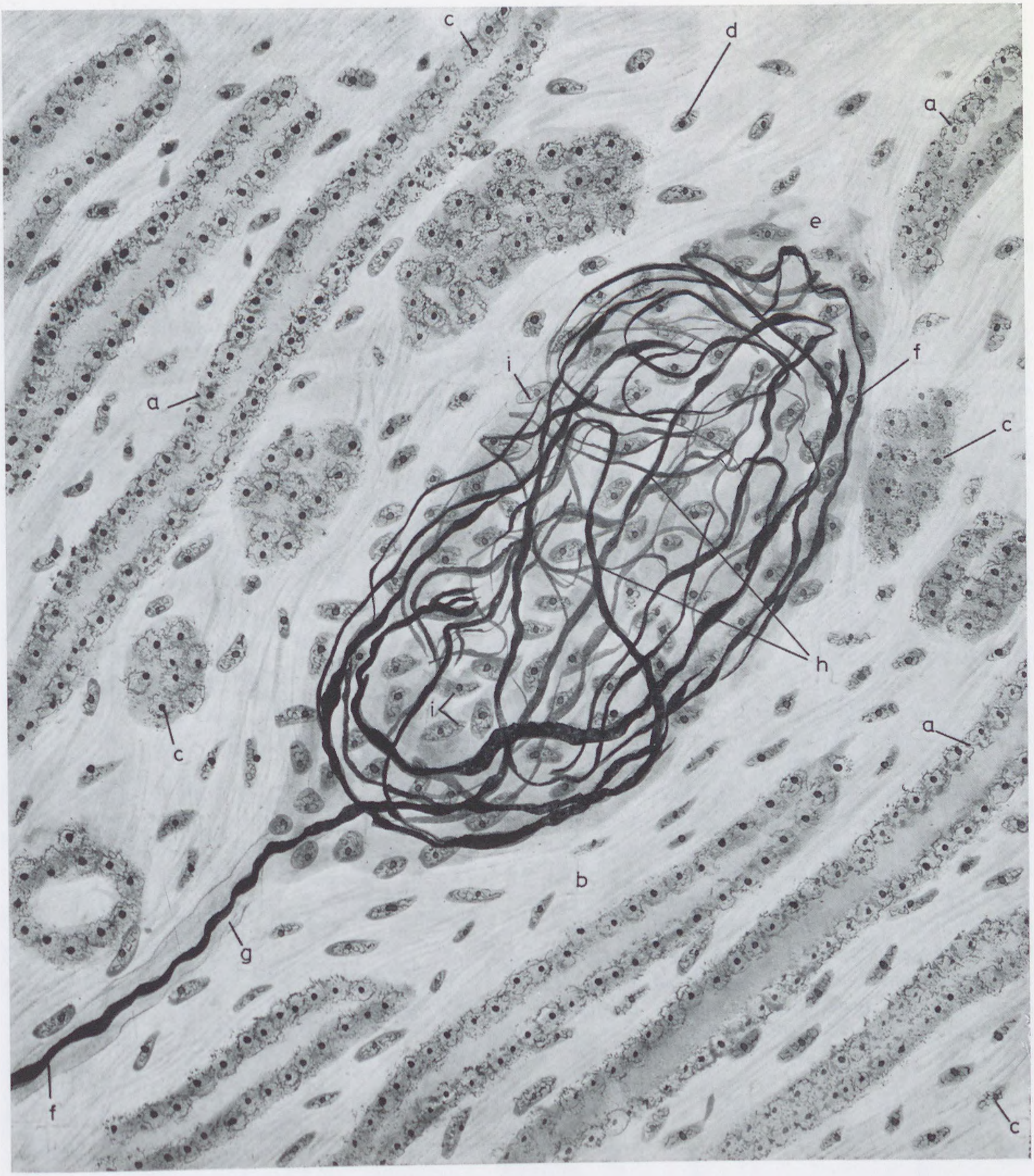
c
d
a
e
f
i
a
c
h
i
c
a
b
g
f
c

Plate 156

Human glans penis

Bielschowsky–Gros silver impregnation

Corial connective tissue (b) lying beneath the epithelium (a); the nuclei of both the epithelial (c) and connective tissue cells (d) vary widely in size and shape. A sensory end-bulb (e) innervated by a thick, wavy nerve fibre (f) can be seen in the middle. The nerve fibre forms a loose network or coil (g) in the end-bulb. The terminal fibres are intermingled with nuclei (h) of tactile cells. The coil is surrounded by a capsule (i) of concentric fascicles of the corial connective tissue.

Neurohistological comments

Much less genital corpuscles are present in the subepithelial layer of the glans penis than in the prepuce. Some of them are encapsulated nerve coils while the others are free endings. They are mostly elliptic or pleiomorphic. The nerve coils in the corial papillae adhere closely to the lower layer of the epithelium. The termination of nerve fibres can only rarely be traced inside the thin capsule. Occasionally the individual coils are interlaced with ultraterminal fibres. The coils of the corpus cavernosum are larger, denser, and more elongated. Loose terminal network systems supplying the epithelium can frequently be found in the vicinity of the end-bulbs.

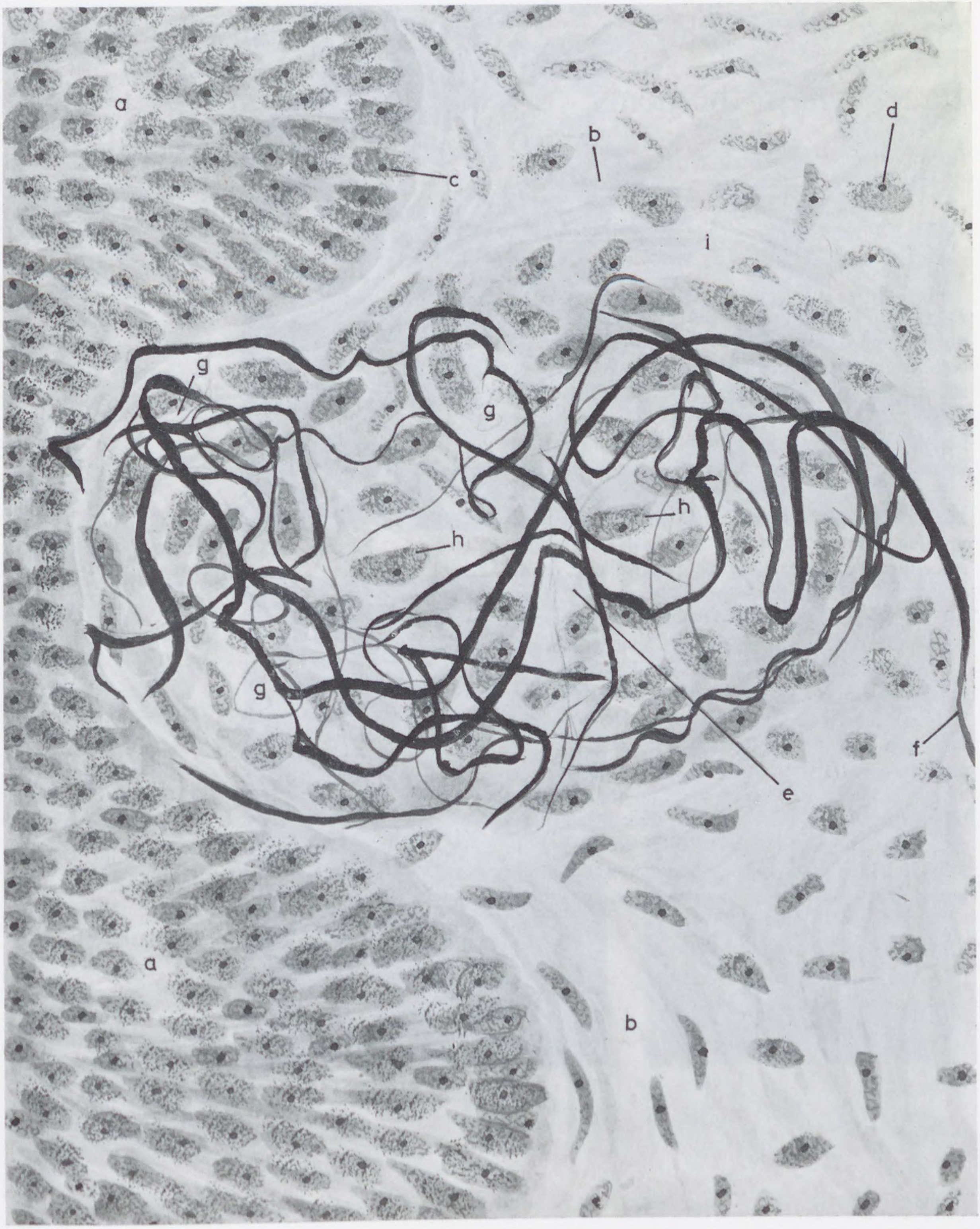
a
b
c
d
i
g
g
h
h
g
e
f
a
b

Plate 157

Receptors in the penis

Photomicrographs

1. Human prepuce. Bielschowsky–Gros silver impregnation. A fairly large non-encapsulated end-coil system can be seen in the corial connective tissue among the epithelial ridges. The thick nerve fibre coursing downwards gives rise to branches forming a rich network in the corial papilla containing numerous nuclei of connective tissue cells.

2. Glans penis of the hog *(Sus scrofa domestica).* Jabonero's silver impregnation. A few meandering myelinated nerve fibres pass among the wavy fibres of connective tissue. Note the encapsulated genital corpuscle in the centre. Fine unmyelinated fibres form a complicated terminal coil system in the loose connective tissue substance of the inner bulb.

3. Cat *(Felis domestica)* penis. Jabonero's silver impregnation. Cross-section of an epithelial spine of the penis. The spine is a purely epidermal structure, equipped with some corial connective tissue only in its base. The sensory system of the spine is a terminal plexus of nerve fibres in the epithelial layers. Myelinated nerve fibres projecting into the spine can be seen on both sides of the nerve coil. After having lost their myelin sheath the fibres break up into branches giving rise to the coil system.

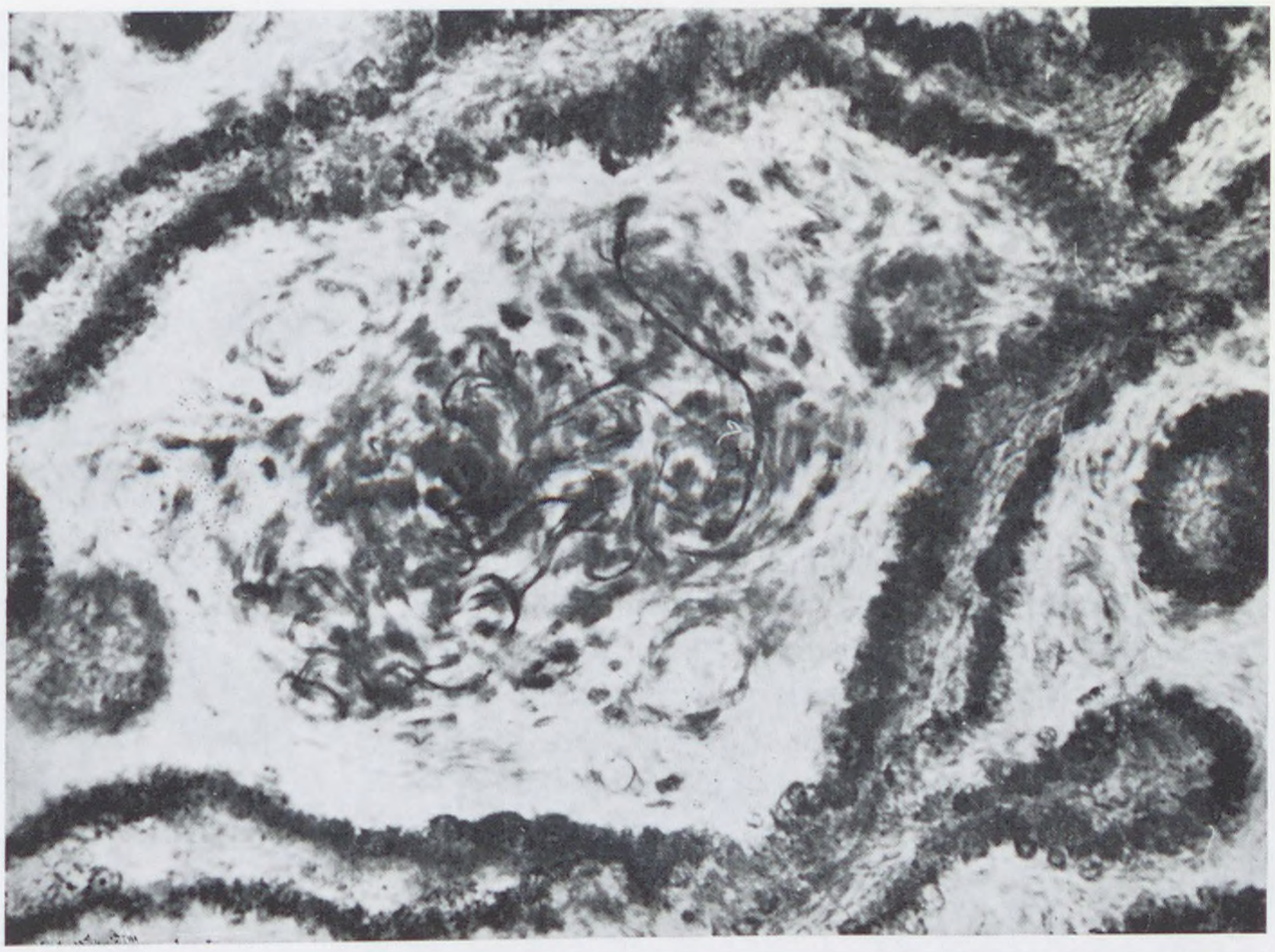

1

2

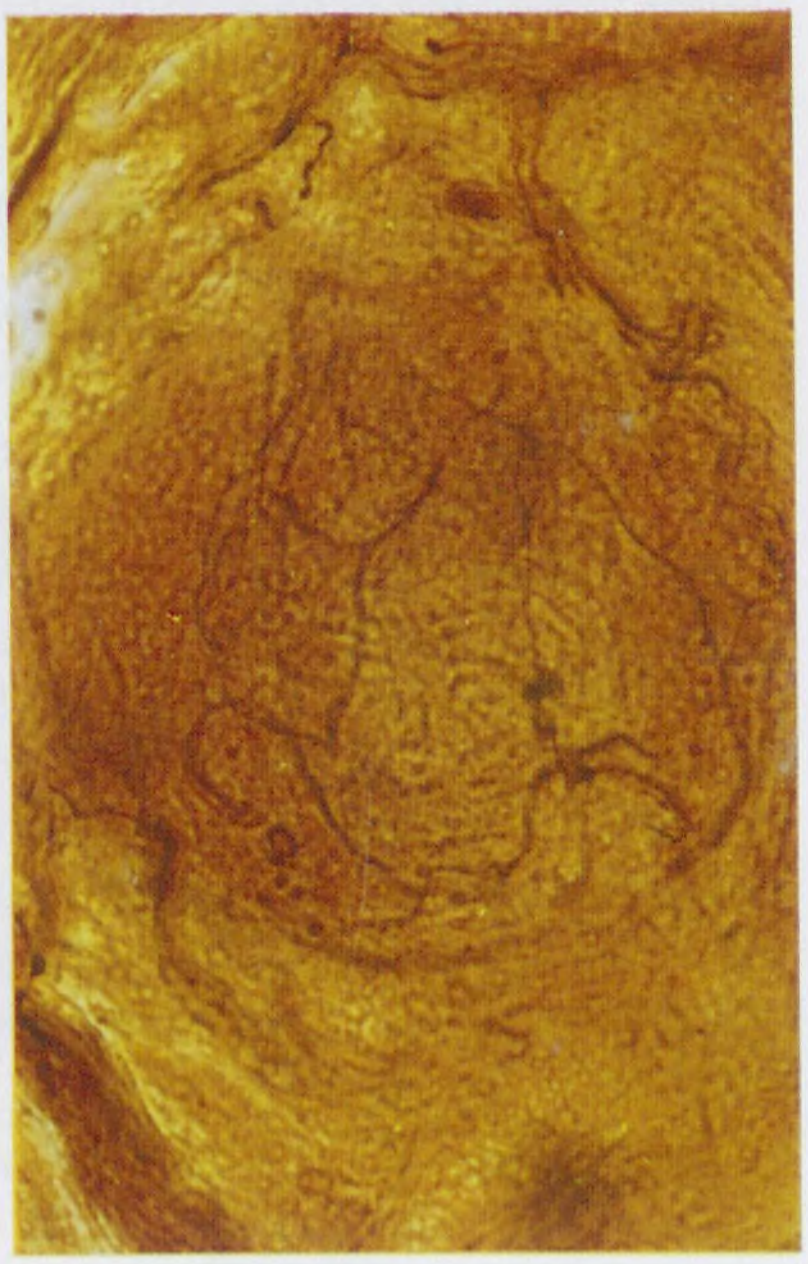

3

Plate 158

Human clitoris

Bielschowsky–Gros silver impregnation

A sensory terminal arborization can be found in the connective tissue (a) of the clitoris. Within the connective tissue, nuclei (b) and bundles of connective tissue fibres can be discerned. A well-impregnated axon (c) surrounded by a thick myelin sheath (d) as well as by a Schwann's sheath (e) enters the picture on the extreme left. The myelin sheath can be traced to the end-system. In the middle of the picture a loose coil (f) of terminal nerve fibres is present. Typical end-structures cannot be seen. The connective tissue cells presumably playing an important role in transduction are clustered in the region of the end-coil.

Neurohistological comments

The clitoris is extremely rich in receptors but they differ from those found in the penis. In the clitoris, in both humans and animals, "dendritic" systems, dense round coils and encapsulated nerve terminals can be distinguished. It is a specific feature of the human clitoris that the terminal coil systems are attached to one another. In animals the sensory end-systems are simpler and fewer, and are interlinked by intraepithelial nerve fibres. The presence of a phylogenetically higher apparatus in humans is a sign of more complicated reflex functions.

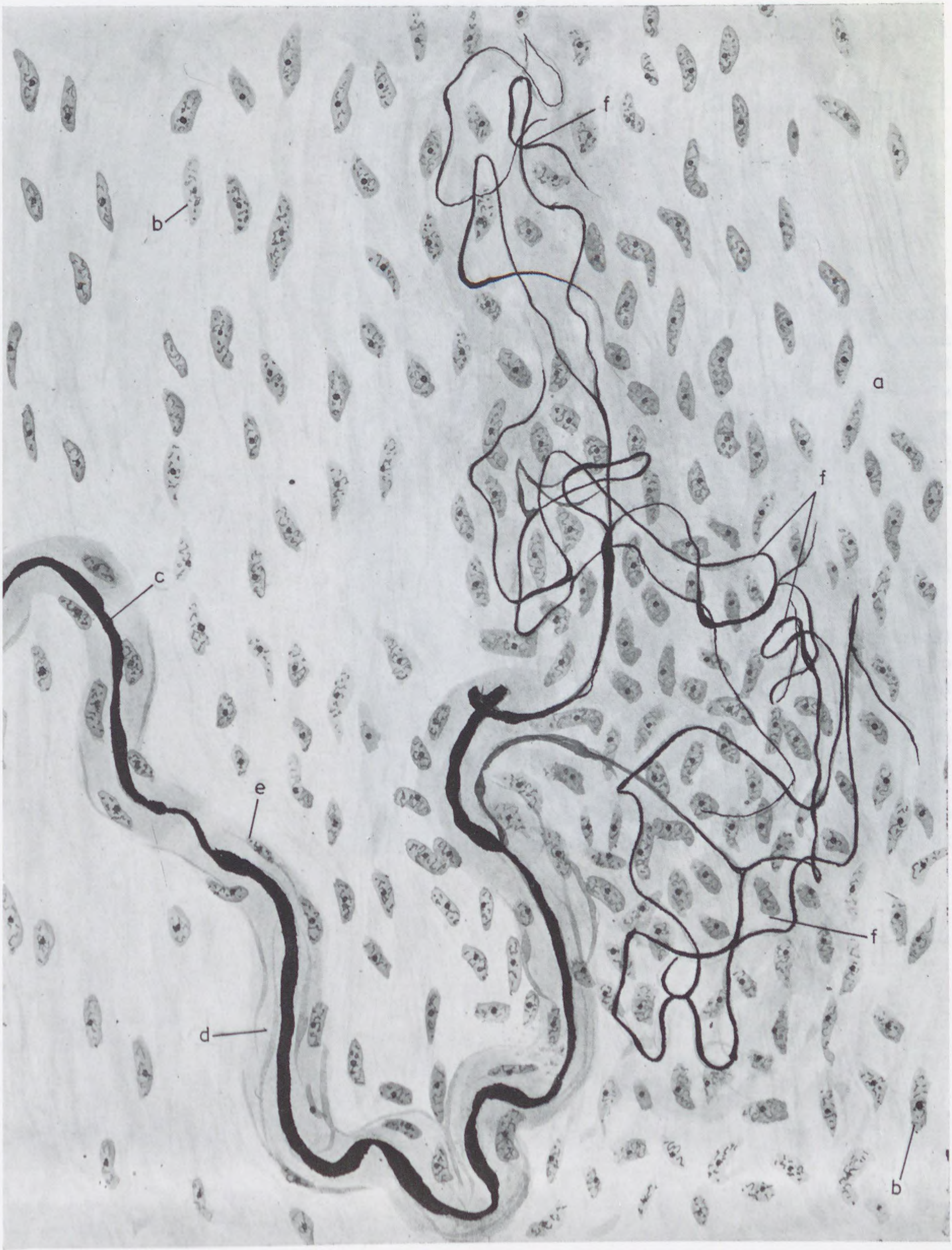
f
b
a
f
c
e
f
d
b

Plate 159

Human clitoris

Bielschowsky–Gros silver impregnation

Loosely structured end-coil. Tactile cells appear among the meandering nerve fibres (a) varying in thickness. The nuclei of the tactile cells are elongated or occasionally polyhedral; their centrally located round nucleoli are dense (b). The thick nerve fibres (c) show incisions and varicosities. The central part of the coil is composed of fine fibres (d), the terminal structures remained unimpregnated.

Neurohistological comments

Such elliptical and laminated types of coils, in which thick and fine fibres are interwoven, are frequently encountered in the subepithelial tissue of the clitoris. It cannot be judged whether the fine fibres, which occasionally constitute independent coils among the thick fibres, are in fact branches of the thick fibre or belong to another axon. The number of the nuclei of connective tissue cells is much smaller in these systems than in the formations described so far.


a
c
b
d
d
a
d
b
c

Plate 160

Human clitoris

Bielschowsky–Gros silver impregnation

1. Sensory system composed of several smaller terminal coils is enclosed by a connective tissue capsule consisting of loose, concentric connective tissue fibres (a), and nuclei of connective tissue cells (b). Three terminal coil systems (c) appear inside the capsule. They are composed of meandering nerve fibres (d), some of which retain their original thickness, whereas others taper off gradually while issuing fine end-fibres which remain in the centre of the coils. Nuclei (e) of tactile cells can be also seen in the coils.

2. Two terminal coil systems are located in the superior part of the connective tissue. Connective tissue (a) with bundles of connective tissue fibres and elongated nuclei (b) of connective tissue cells can be seen around the terminal sensory structure. Very thick, partly myelinated, nerve fibres (c) run to the terminal sensory organs. Thinner nerve fibres deriving from the branchings of the thick ones form coils (d) in which nuclei (e) of sensory cells are arranged concentrically.

1

2

Plate 161

Human clitoris

Bielschowsky–Gros silver impregnation

This picture shows two probably functionally related terminal coil systems. The nuclei of the tactile cells (a) are assembled in groups; fine nerve fibres (b) and coil systems (c) appear in the spaces among them. Neurofibrils (d) as well as a few end-lamellae (e) can be seen. The two loose coils are terminal arborizations of three thick nerve fibres (f). Two of them are extremely thick, and bear indentations as well as large varicosities. Thicker and thinner segments alternate within these fibres. The third fibre is finer, but its arborization is similar to that of the thick fibres.


c
a
d
a
f
e
b
b
d
c

Plate 162

Human clitoris

Bielschowsky–Gros silver impregnation

A very complicated terminal body (g) is present in a corial papilla of the clitoris. Note the connective tissue fascicles and the nuclei of connective tissue cells (b) in the corial connective tissue (a). Thick nerve fibres (c) having neurofibrils (e) and large varicosities (d) traverse the picture vertically. Nuclei of tactile cells (f) appear in groups in the area of the terminal system. Some segments of the terminal system enter the adjacent connective tissue.

Neurohistological comments

Dendritic terminal systems located near the epithelium and enclosed by connective tissue capsules, occur frequently in the human clitoris. They are composed of numerous thick nerve fibres which double back from the epithelium. The thick fibres often contain loose neurofibrillar segments. The nuclei of connective tissue cells are elongated, whereas nucleoli are large and spherical. Localization of the end-bodies in the connective tissue papillae where they are covered only by a very thin epithelial layer, suggests a significant functional role.


g
c
e
f
e
d
d
a
b
c
c

Plate 163

Human clitoris

Bielschowsky–Gros silver impregnation

Connective tissue (a) with fascicles and nuclei of connective tissue cells (b). A thick nerve fibre (c) coursing upwards from the left lower corner of the picture gives rise to four richly arborizing coil systems (d). The coils are interconnected by short segments (e) of the nerve fibre. Numerous nuclei of tactile cells (f) are visible in the coil systems.

Comments

The classical maxim "structura obscura, morbi obscuriores, functiones obscurissimae" also fits the nervous system. The structural details bear witness both to a high degree of sensitivity of, and the large area innervated by, a single sensory fibre.

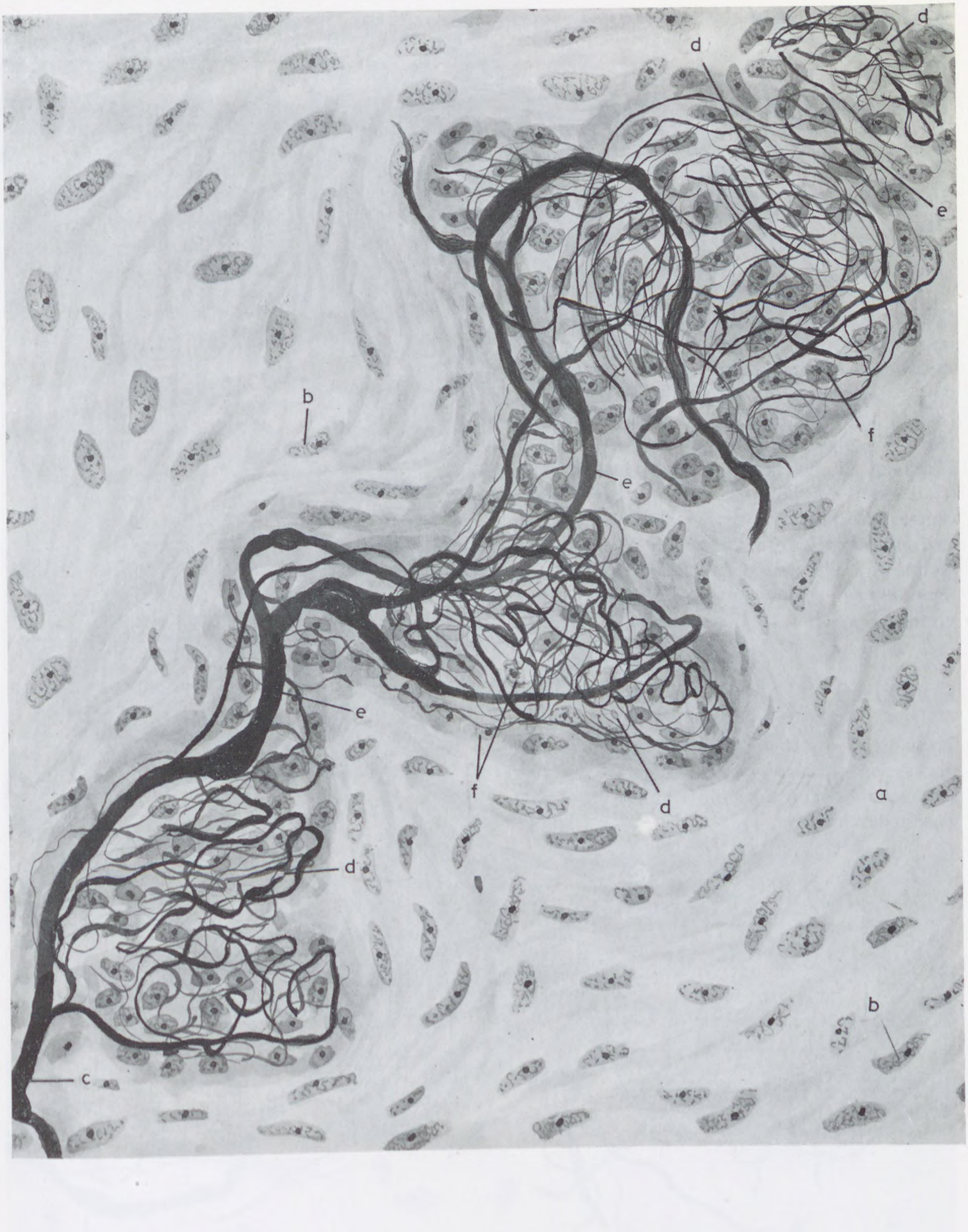
d
d
e
b
f
e
e
f
d
a
d
b
c

Plate 164

Human clitoris

Bielschowsky–Gros silver impregnation

Sensory coil system in the upper part of the corial connective tissue (a) containing elongated nuclei (b) of connective tissue cells, as well as bundles of thin collagenous fibres (c). Groups of nuclei of tactile cells (d) appear within the terminal nerve fibre systems. An upward coursing thick nerve fibre (e) forms an elliptic, non-encapsulated terminal coil (f). There is another arborization system (g) in the centre consisting of several smaller portions, while two smaller coils are found in the lower part of the picture (h). The thick nerve fibre passing between these latter indicates that these, too, belong to the upper coil systems.

Comments

These are the most complicated dendritic arborization systems occurring in the human body, representing, at the same time, the highest stage of phylogenetic development.

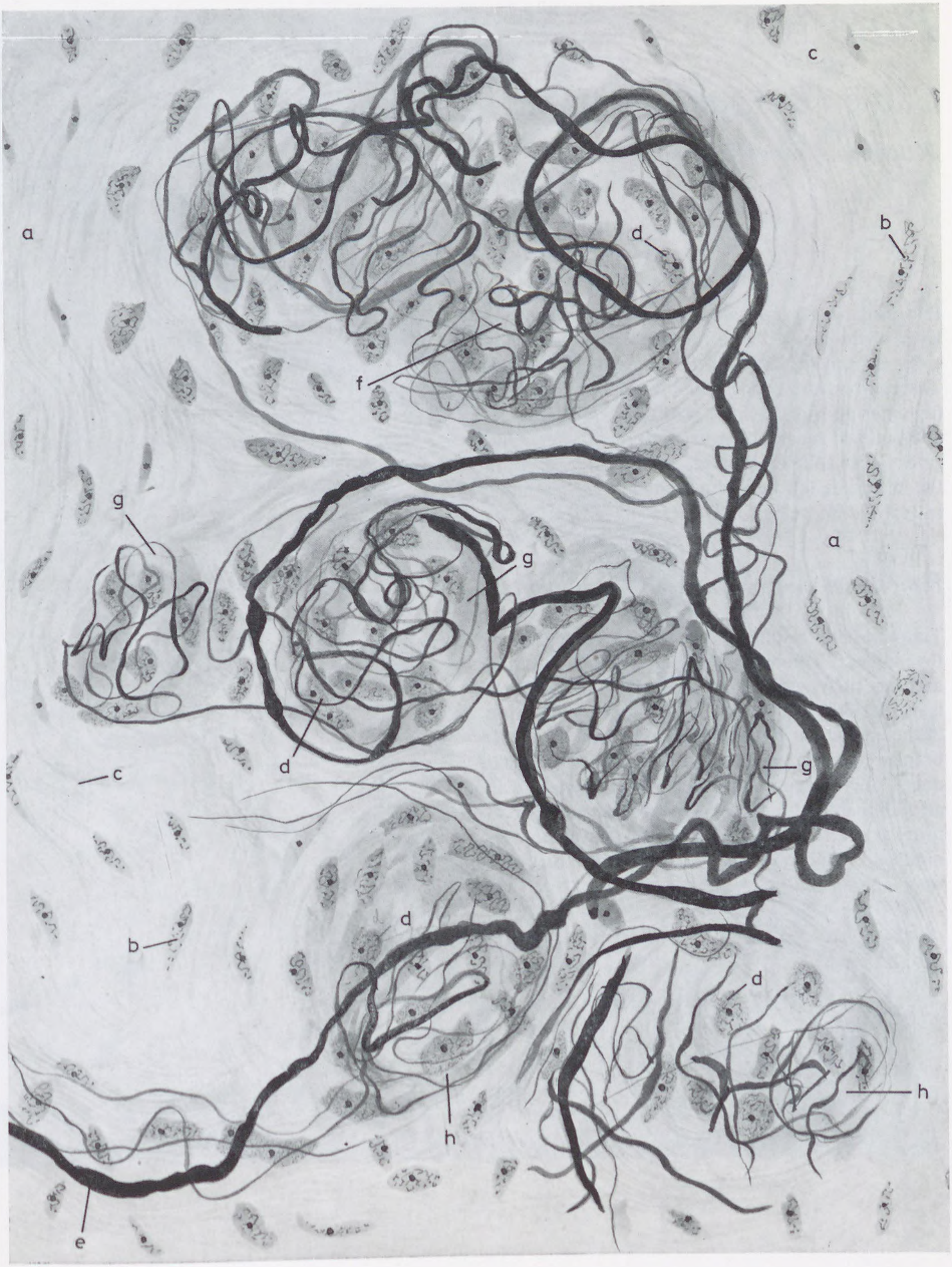
c
a
b
d
f
g
a
g
g
d
c
b
d
d
h
h
e

Plate 165

Cattle *(Bos taurus)* nipple

Jabonero's silver impregnation

Encapsulated Krause's end-bulb in the lower corial layer of the nipple. Note the connective tissue fascicles (b) and nuclei (c) in the connective tissue (a). The end-body is a long, narrow, encapsulated coil (d) differing slightly in its structure from Krause's end-bulbs in general. The nerve fibre (f) of the bulb gives rise to collaterals (g) all along its course within the inner core (e). Individual branches (h) terminate in typical end-bulbs (i).

Functional neurohistological comments

This end-body belongs to the epithelial receptors of the nipple; functionally it is connected with lactation and especially with the ejection of milk. The latter is regulated by a reflex arc with its sensory terminals in the epithelium of the nipple and motor terminals in the smooth muscle fascicles surrounding the milk-ducts. Such receptor apparatuses can be found in all mammals, although their number, site and structure vary in the individual species. As a rule, their number is higher in small mammals as compared with large ones.

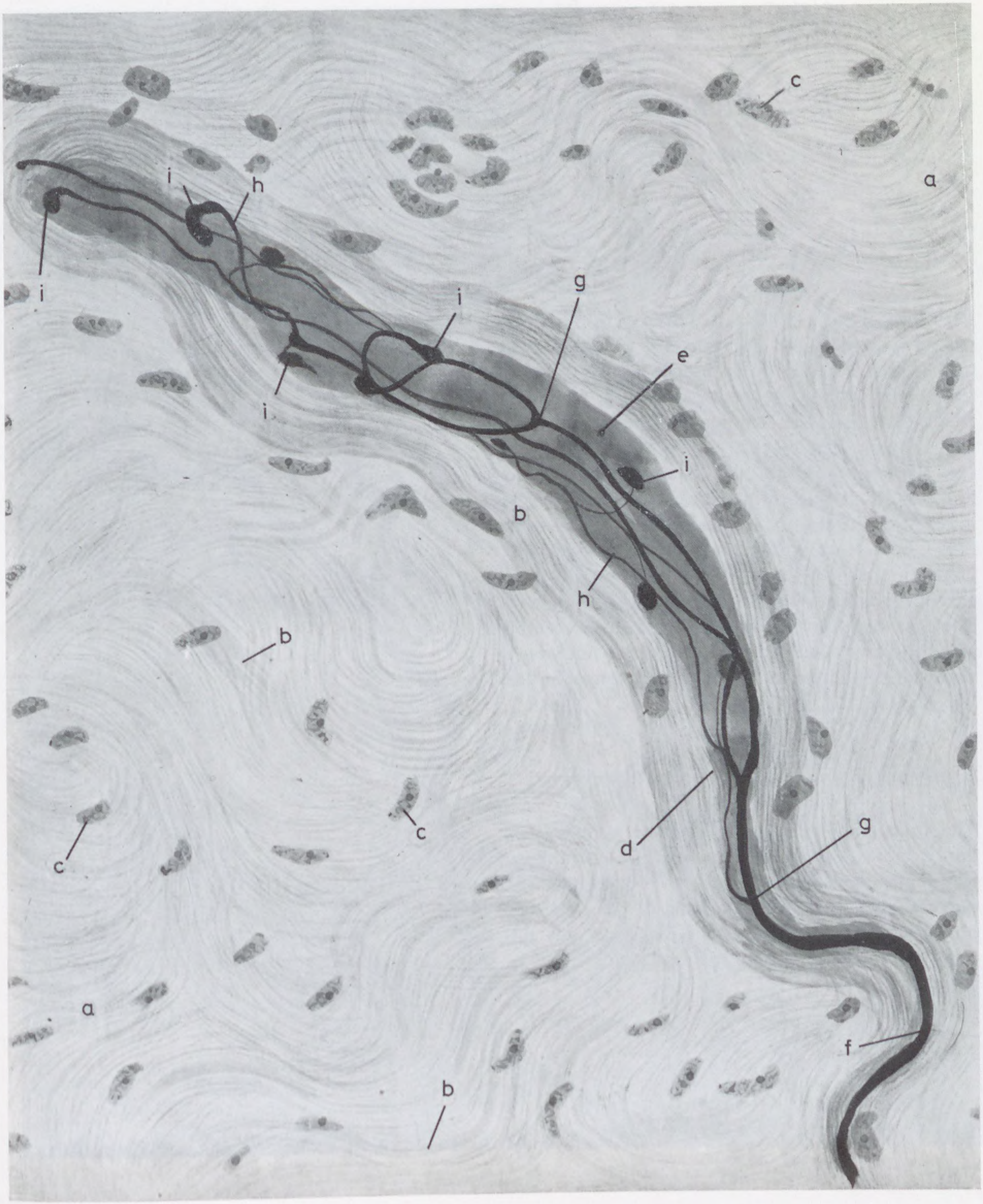
c
a
i
h
i
i
g
e
i
i
b
h
b
a
d
g
c
c
f
a
b

Plate 166

Cat *(Felis domestica)* stellate ganglion

Bielschowsky–Ábrahám silver impregnation

Perikarya of nerve cells (a) are present in the loose connective tissue (e). A vertically running thick nerve fibre divides into two branches; one of them (b) breaks up into several meandering branches which then disappear among the elements of connective tissue. The other branch (c) bearing numerous varicosities gives rise to a number of fine fibres which terminate in long lamellae. The thick nerve fibre seems to be a sensory fibre of the vagus nerve. Several such fibres pass through the stellate ganglion of the cat; they form a large receptor system in the connective tissue capsule of the ganglion. The fact that they belong to an extensive receptor system is substantiated mainly by the fine wavy fibres which terminate in elongated neurofibrillar lamellae (d).

Functional neurohistological comments

The functional significance of these systems can hardly be assessed on the basis of their morphological appearance. Some authors consider these nerve endings to be the receptors of the ganglion, but it is also possible that they innervate only the relatively thick connective tissue capsule.

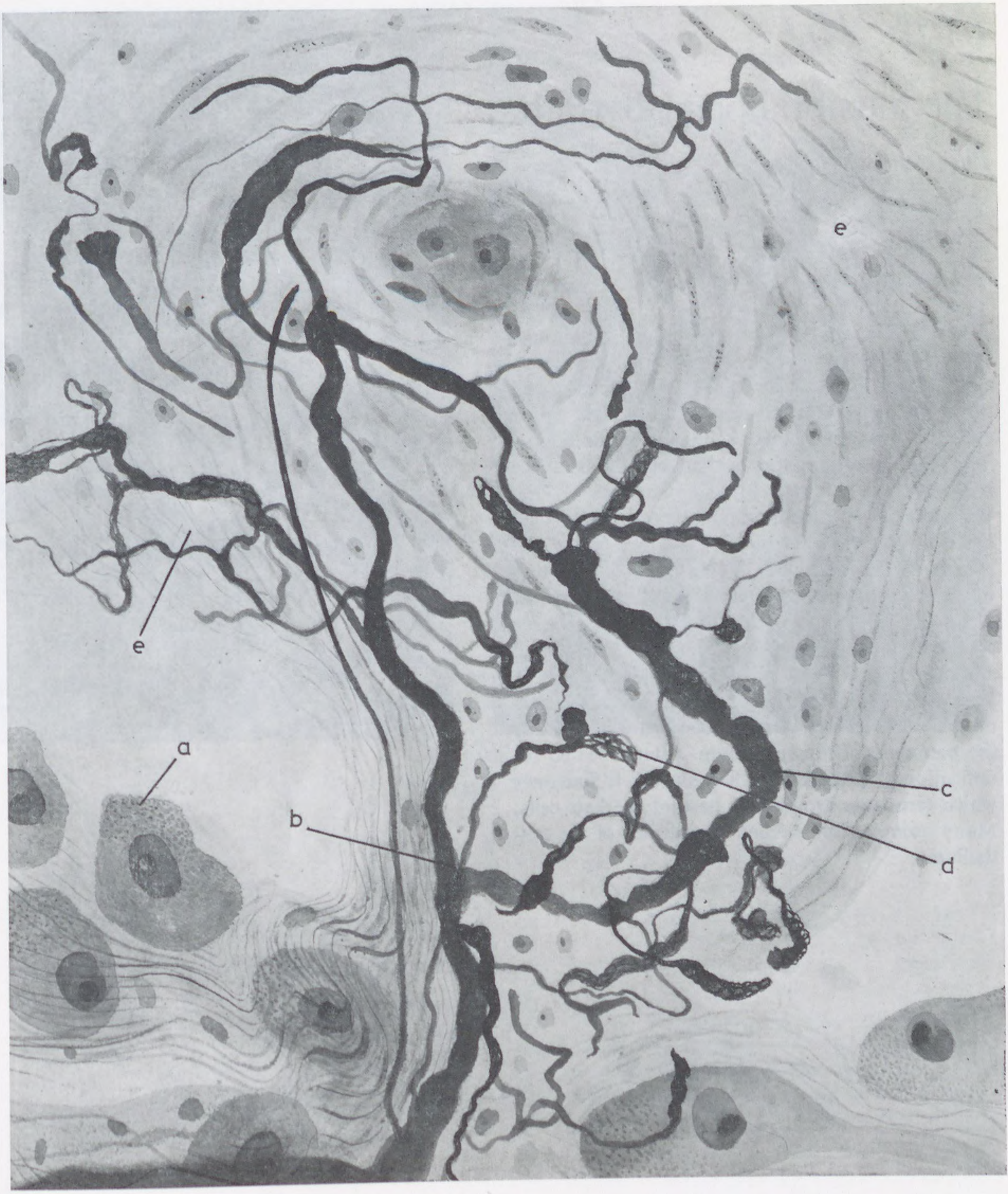

e
e
a
b
c
d

Plate 167

The membranous labyrinth

Photomicrographs

1. Membranous labyrinth (labyrinthus membranaceus) of the carp *(Cyprinus carpio)*, part of the saccule. Hair cells and the nuclei of other cells constituting the epithelium can be seen in the right upper corner. A rich nerve plexus lies under the epithelium; the fibres terminate in small end-knobs at the bottom of the hair cells.

2. Portion of a crista ampullaris (crista acustica) in the carp *(Cyprinus carpio)*. The lower part of the picture shows the longitudinal section of the shaft of the crista, while the epithelial cap is seen in cross-section in the upper field. The chondroid tissue constituting the outer part of the labyrinthine wall and thick nerve fibres passing towards the epithelium of the sensula are present in the shaft. The vestibular nerve fibres increase in thickness towards the boundary of the epithelium. After repeated ramifications, the thick branches give rise to fine ones which terminate around the base of the hair cells. Many terminal fibres reach the surface of the epithelium.

1

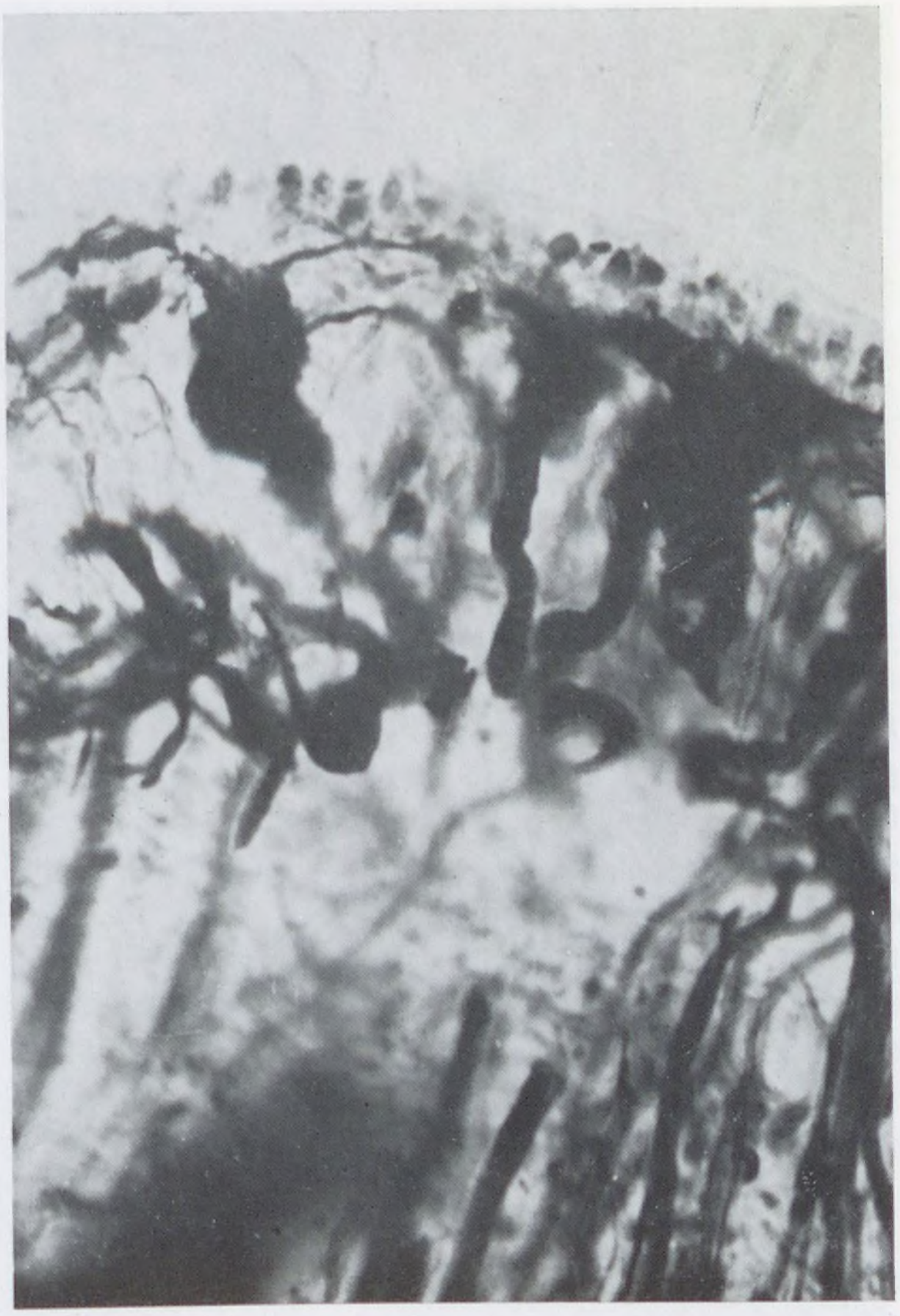

2

Plate 168

Carp *(Cyprinus carpio)* otoliths

Photograph of otoliths removed from the membranous labyrinth. The otoliths ("auditory stones") lie over the auditory fields, one stone over each auditory field. Three types of otoliths can be distinguished in ganoid (Ganoidea) and bony fishes (Teleostei), these are: lagenoliths (asteriscus), sacculoliths (sagitta) and the utriculoliths (lapillus). In the carp the crescent-shaped asteriscus (a) is the longest of the three stones; it has jagged edges and lies over the sensory area of the lagena. The smaller convexo-concave lapillus (b) lies over the macula utriculi. The sagitta (c) which is the smallest of the three, is a three-sided prism and lies over the macula sacculi.

Comparative and functional anatomical comments

The shape of the otoliths is characteristic of the individual species. Sacculoliths might also be used for age determination in some fishes (e.g. the plaice, *Pleuronectes platessa*). When transilluminated, bright and dark layers are seen to alternate in the sagitta corresponding to phases of annual growth. The bright rings are deposited in spring and early summer while the dark one in late summer and in autumn. Like other sea-fishes, this animal, too, stops growing in winter. If the otolith is thick, the growth-rings can be identified only after polishing. Otoliths are of major paleontological significance since they are preserved after the death of the fish and thus furnish important data about extinct species. (In the Middle Ages mysterious healing power had been attributed to otoliths. They were sold by apothecaries as *lapides percarum*—"Peter's stones", so called because of a key-shaped pattern had been thought to be distinguishable on their surface.) Cuvier has postulated an analogy between the three stones and the three auditory ossicles of mammals. The structure and function of the otoliths is still unclear; also their relation to the macula has remained a problem. The otoliths rest on the surface of the neuroepithelium containing the terminations of the auditory nerve fibres. They are in close contact with the superficial nerve fibres transmitting information to the higher centres about changes in the position of the endolymph, thus about the position of the head in space. To sum up, the otoliths play an important role in the function of the receptor apparatus involved in the perception of body posture.


a
a
b
a
b
a
b
b
b
b
a
c
c
b
a

Plate 169

Carp *(Cyprinus carpio)* crista ampullaris

Bielschowsky–Gros silver impregnation

Thick nerve fibres (a) filled occasionally with neurofibrils can be seen in the tangential section of the crista ampullaris. At the boundary of the epithelium the nerve fibres enlarge considerably (b) and divide into many branches. Sometimes the ground tissue (e) may disappear entirely under the mass of nerve fibres and terminal arborizations. Fibres leaving the network have fine meandering end-branches (c) with free nerve endings (d) among the epithelial cells (e).

Neurohistological comments

The crista ampullaris protrudes from the ampullary wall into the lumen. The simple cuboidal epithelium of the ampulla continues on the shaft of the crista; in some cases one side of the shaft is covered with columnar epithelium while the other side with cuboidal epithelium. The ground substance of the crista, a column-like continuation of the lamina propria of the labyrinth, is a homogeneous chondroid substance readily stained with basic aniline dyes. Cristae are covered with a thick layer of stratified sensory epithelium, the sensula. Fine pointed hairs protrude from the hair cells on top of the epithelium. The hairs merge and enter the slim gelatinous cupula. The interwoven gelatinous filaments of the cupula project into the ampullar lumen. Hair cells are long, rounded at their base, with a large nucleus. The epithelium consists mostly of small elongated cells with round nuclei. These narrow supporting cells are attached to the lamina propria. They generally lie below the hair cells, but some may reach the surface among the hair cells. The crista ampullaris is supplied by the nervus ampullaris passing in the lamina propria of the shaft of the crista. The diameter of the fibres increases five- to sixfold under the sensory neuroepithelium. Numerous branches emerge from the enlarged fibre portions; this part of the crista may thus be regarded as true nervous tissue. Nerve fibres entering the epithelium proceed towards the surface and get into contact with the hair cells. Some of them penetrate deeply into the epithelium and terminate on its free surface.

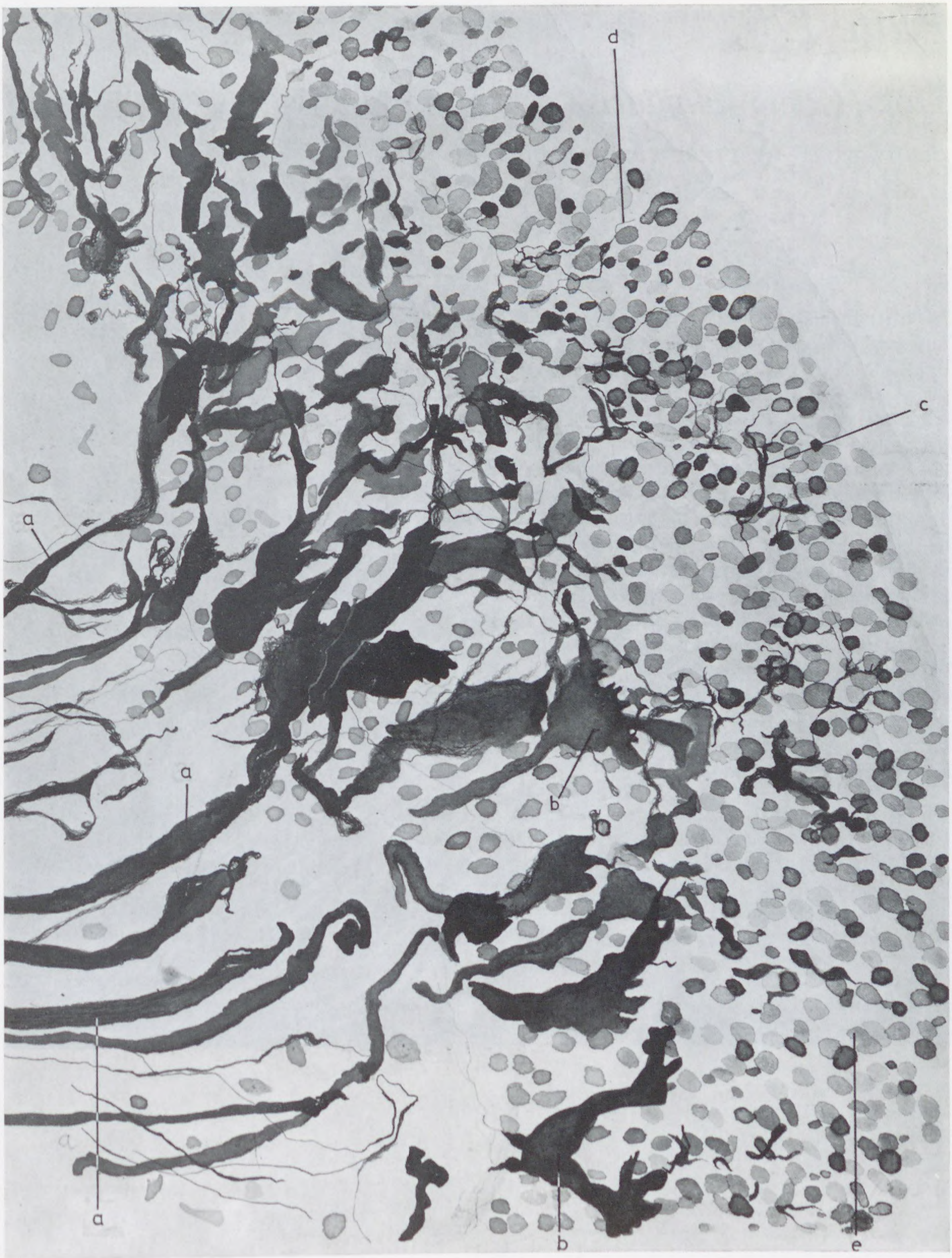
d
c
a
a
b
a
b
e

Plate 170

Dog *(Canis familiaris)* crista ampullaris

Bielschowsky–Gros silver impregnation

Neuro-epithelium (a) which seems to be stratified in this tangential section may be seen above on the right side. Note nuclei and nucleoli (b) of the epithelial cells. Under the epithelium, loose connective tissue (c) appears with round nuclei (d). Cells of the individual tissue elements cannot be perfectly distinguished in such thick preparations obtained after decalcination. On the other hand, the nerve fibres are well impregnated. A large nerve bundle (e) proceeds towards the upper right corner of the picture; the smooth nerve fibres assume a plexus-like appearance near the neuroepithelium. Individual fibres suddenly taper off, then become thick again (f) and form a loose network beneath the epithelium. Nerve fibres varying in calibre leave this subepithelial network and terminate freely among the epithelial cells. Nerve fibres running parallel to the surface of the epithelium (g) originate from the subepithelial network, too.

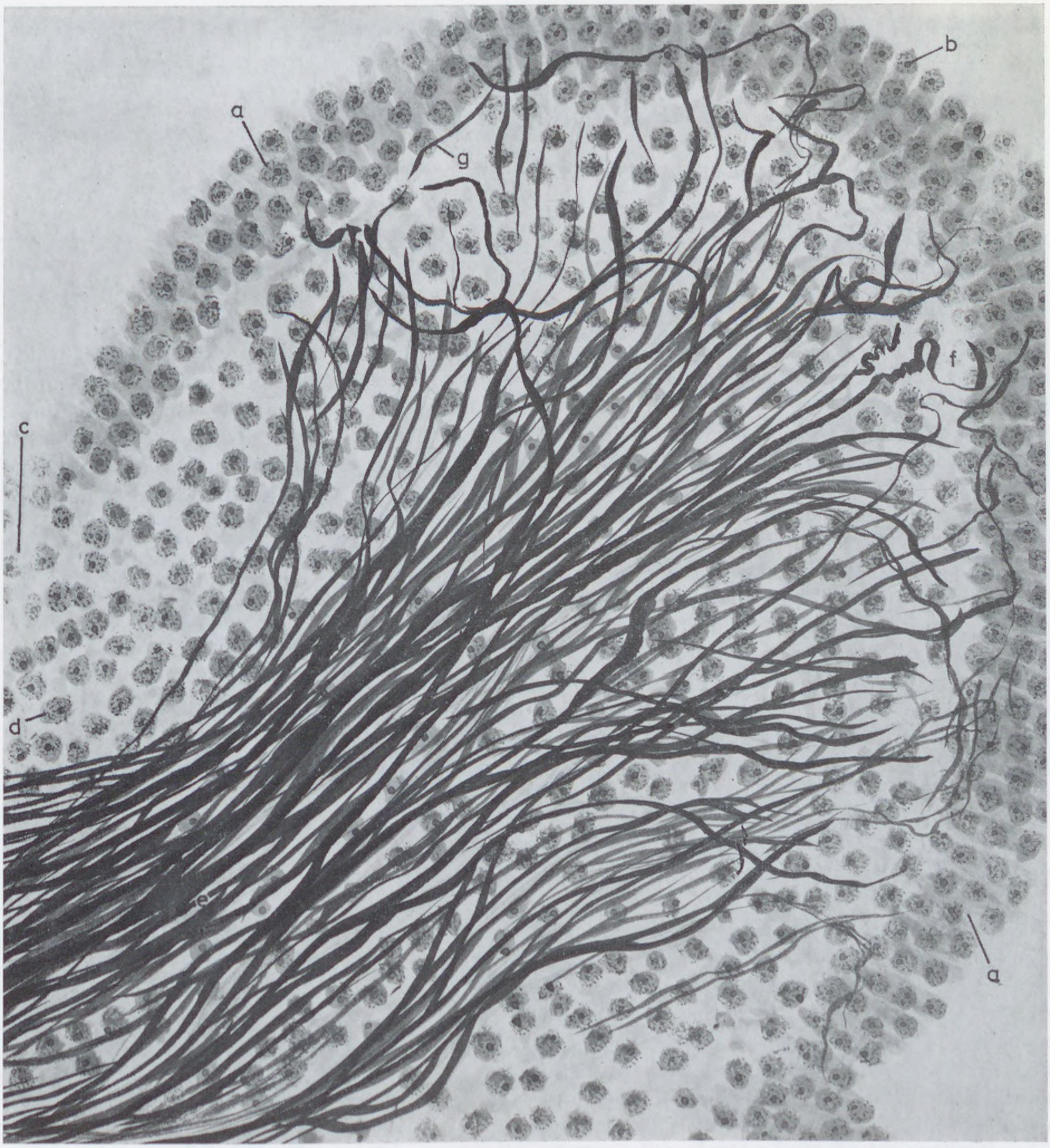
b
a
g
f
c
d
e
a

Plate 171

Carp *(Cyprinus carpio)* macula utriculi

Bielschowsky–Gros silver impregnation

Part of the macula utriculi together with the supplying nerve bundles. The neuro-epithelium (a) appears to be stratified due to tangential sectioning. Connective tissue (b) is visible under the epithelium. Nuclei of the epithelial cells (d) are round, while those of the connective tissue cells (c) are elongated; their longitudinal axis usually lies parallel to the surface of the epithelium. The nerve bundles (e) reach the macula utriculi through the clefts of the lamina propria. Nerve fibres are thick (f) and bear occasional varicosities (g). Characteristically enlarged portions of the nerve fibres (h) exceed even those of the crista ampullaris both in size and abundance of ramification. The branches (i) emerging from the enlarged sections form a network under the neuroepithelium; some fibres terminate freely among the epithelial cells.

General neurohistological comments

The macula utriculi, which emerges from the bottom of the recessus utriculi, is a large field of specialized epithelium, corresponding to the epithelial cap of the crista ampullaris. Hair cells are situated along its free surface. A layer of elongated supporting cells is located underneath, with nuclei arranged at different heights. At the edge of the macula utriculi, the neuroepithelium yields for a simple columnar epithelium, which changes to the cuboidal epithelium lining the cavity of the utricle. Both types of epithelium rest on the lamina propria of the utricle. The structure of the lamina propria is similar to that of the ampullar regions, but it contains capillaries. It is perforated by a number of spherical or ovoid foramina, through which the bundles of the auditory nerve enter the macula. The utricle is innervated by the nervus utricularis, a branch of the anterior ramus passing along the wall of the utricle. Beneath the lamina propria, the nervus utricularis breaks up into several branches which, entering the epithelium of the macula through the foramina, are thickened and constitute a profuse network. Some fibres which leave the network terminate free among the cells of the neuroepithelium.


c
j
b
g
f
f
e
h
c
d
g
b
i
a
h

Plate 172

Compound eye

Colour photomicrograph

Part of the compound eye of the snouted grasshopper *(Acrida hungarica)*. The cornea appears in the upper part of the picture, underneath the individual simple eyes are connected with the optic ganglion by nerve fibres. The centre of the ganglion is occupied by axons while the nerve cells are located peripherally.

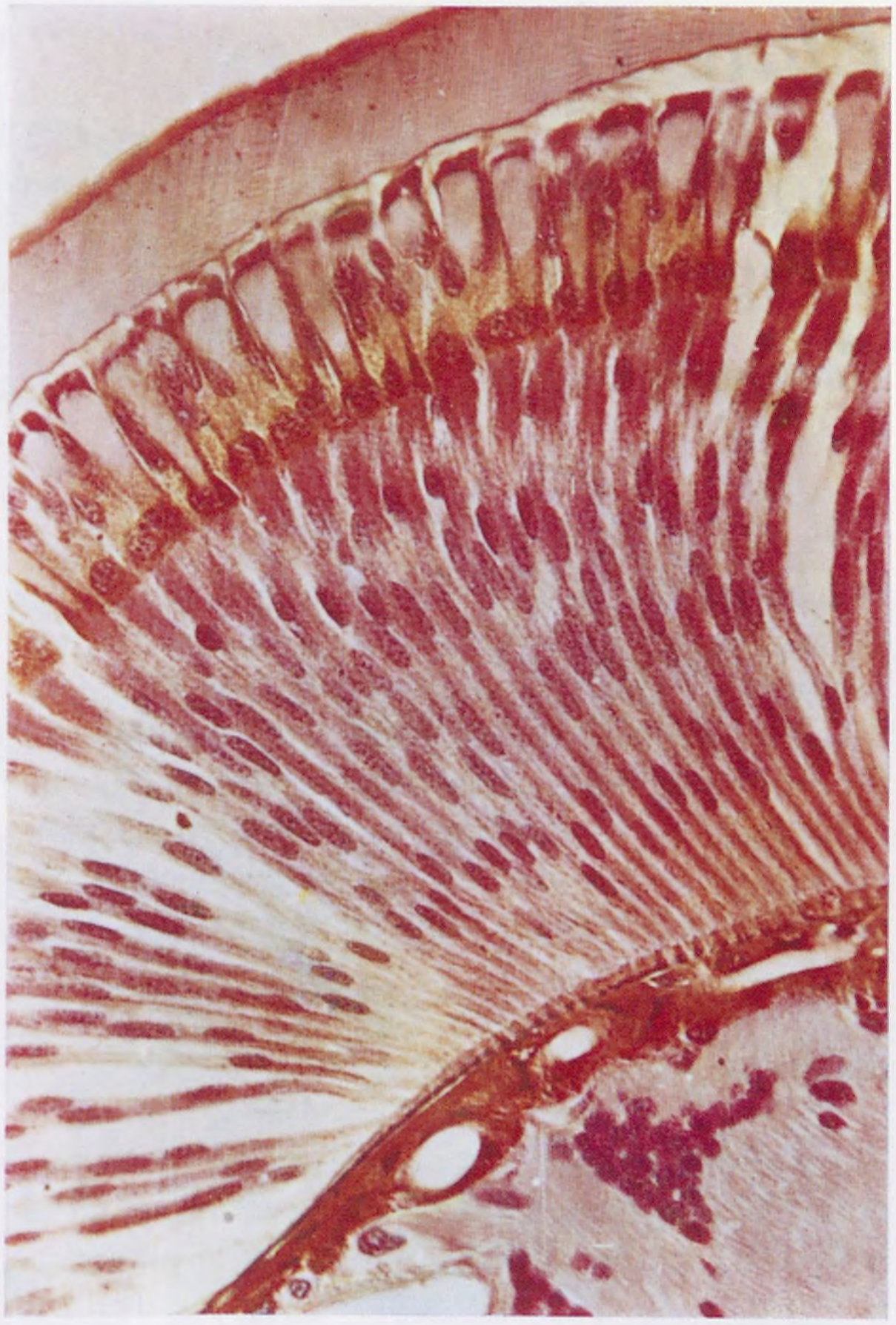

Plate 173

Snouted grasshopper *(Acrida hungarica)* compound eye

Haematoxylin-eosin staining

Compound eye and optic ganglion. Adjacent to the cornea (a) the hypodermis (b) is seen (right). The simple eyes are arranged side by side; they consist of a crystalline corpuscle (c), a pigment cell (d), the retina (e) and the basement membrane (f). The optic ganglion is a solid round body on the left. Nerve cells (g) form groups on the periphery while the nerve fibres run towards the centre (h).

Neurohistological comments

The compound eyes are composed of numerous, optically isolated simple eyes (ommatidium). The number of the simple eyes is variable: in one compound eye there are 12,400 simple eyes in the death's-head hawk-moth *(Acherontia)*, 10,000 in the plasse libellula *(Aeschna)*, 4,500 in the butterfly painted lady *(Vanessa cardui)*, 4,000 in the bumble-bee and 2,000 in the large green grasshopper *(Locusta viridissima)*. Compound eyes may be atypical or typical. Those in which the simple eyes are loosely arranged with their characteristic features well discernible are called atypical compound eyes. In the typical lateral compound eye the globular simple eyes are in close contact with one another, and their surface blends with the surrounding cuticle. Proximally the eyeball is bordered by the basement membrane, equipped with foramina for the nerve fibres (fenestrated membrane). The elements of the individual eyes are as follows: cuticular cornea, four crystalline cells, retinula composed of optic cells, together with the rhabdom, the optic isolator and the pigment covering. The cornea is a stratified biconvex, occasionally planoconvex lens which bulges forward from the integrated cornea in front of each ommatidium. The four crystalline cells form a pointed coniform structure with a basis on the inner surface of the cornea. Depending on the structure of the crystalline cells, aconic, euconic and pseudoconic eyes can be distinguished. The crystalline cells of the *aconic* eye have no crystalline body; both the cells and their nuclei are large, the cytoplasm is homogeneous or contains droplets of intracellular fluid (vitrella). The crystalline cells of the *euconic* eye produce a crystalline cone of four segments; the base of the cone faces the cornea. In *pseudoconic* eyes the crystalline cells produce an extracellular mucous cone (pseudoconus) which forms a deposit on the cornea. The retinula is composed of eight optic cells, which show a rosette-like arrangement in cross-section; the centrally situated rhabdoms extend over the whole length of the retinula. The pigment serving for isolation is produced partly by the optic cells and partly by the pigment cells of the iris (covering the ommatidium from outside) and the retina. The pigment cells of the retina are located on the basement membrane and surround the basal part of the retinula.

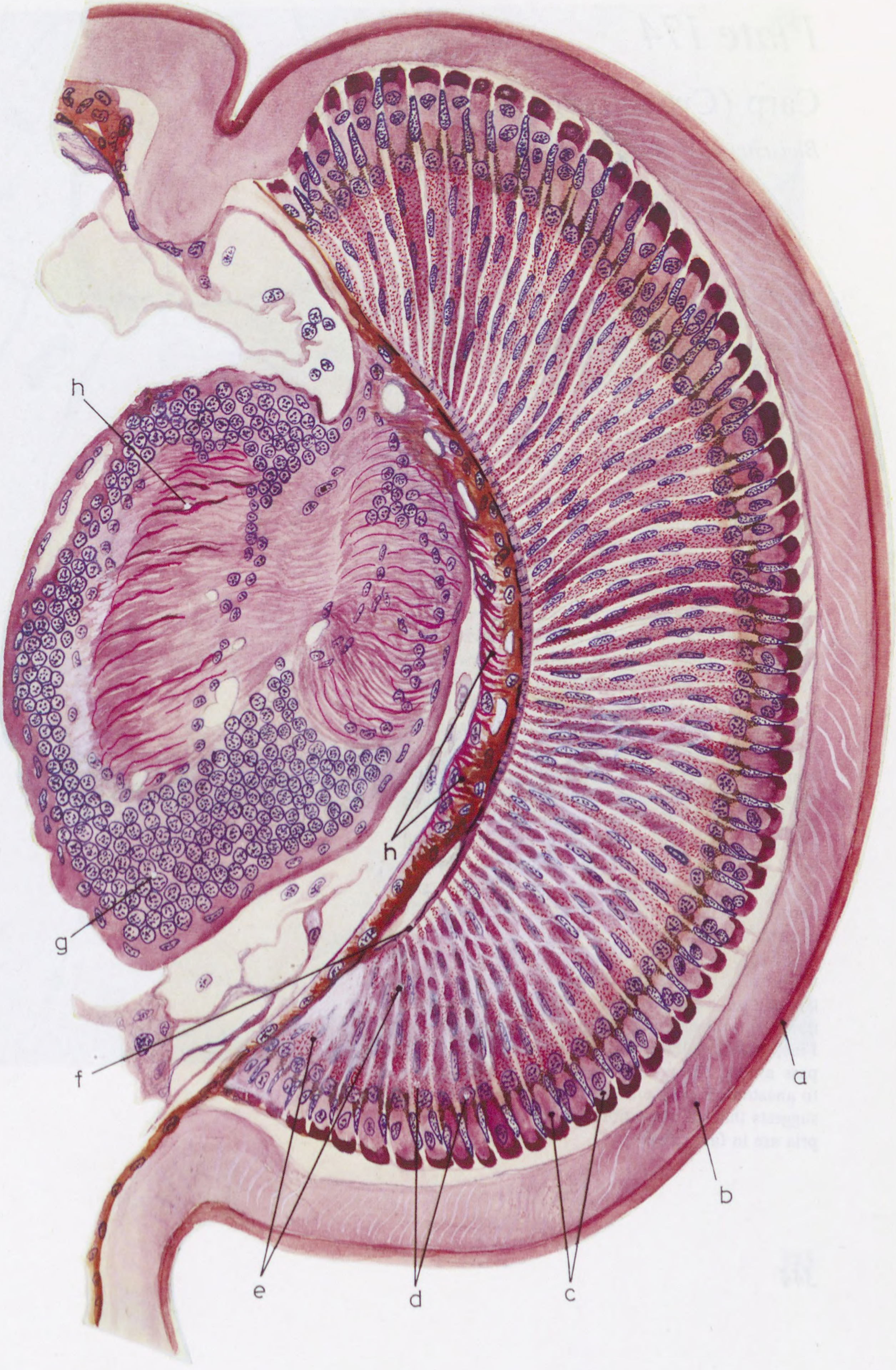
h
h
g
f
a
b
e
d
c

Plate 174

Carp *(Cyprinus carpio)* cornea

Bielschowsky–Ábrahám silver impregnation

Thick nerve fibres (a) in the substantia propria of the cornea bear varicosities (d) and some enlarged segments packed with neurofibrils (c). Parallel to the network of the thick fibres another loose network (b) composed of fine fibres can be seen. Some terminal fibres of this latter system run close to the characteristic large connective tissue cells (e), called "corneal corpuscles" of the substantia propria.

General histological comments

The cornea is thick peripherally but becomes thinner towards the convex central part. The substantia propria is composed of parallel lamellae of connective tissue intermingled with the above-mentioned connective tissue cells (corneal corpuscles). In bony fishes the outer epithelium of the cornea consists of 6 to 8 rows of cells, the two outermost rows containing flattened cells. Between the anterior epithelium and the lamina propria Bowman's membrane becomes thinner peripherally and is continuous with the basement membrane of the conjuctiva. There is *no* Descemet's membrane in the eye of the carp, since the substantia propria is bordered by a single layer of flattened epithelium towards the anterior chamber. Bundles of nerve fibres, arriving to the cornea from the sclera, proceed radially towards the centre to form a network. The fibres spread out distally to constitute a loose network at the boundary between the outer epithelial coat and the substantia propria. The connection of the nerve fibres with the epithelium will be discussed later on. Fine, occasionally strongly varicose, nerve fibres pass among the corneal corpuscles which appear to anastomose with one another. Their localization suggests that all nerve fibres of the substantia propria are in fact receptors.

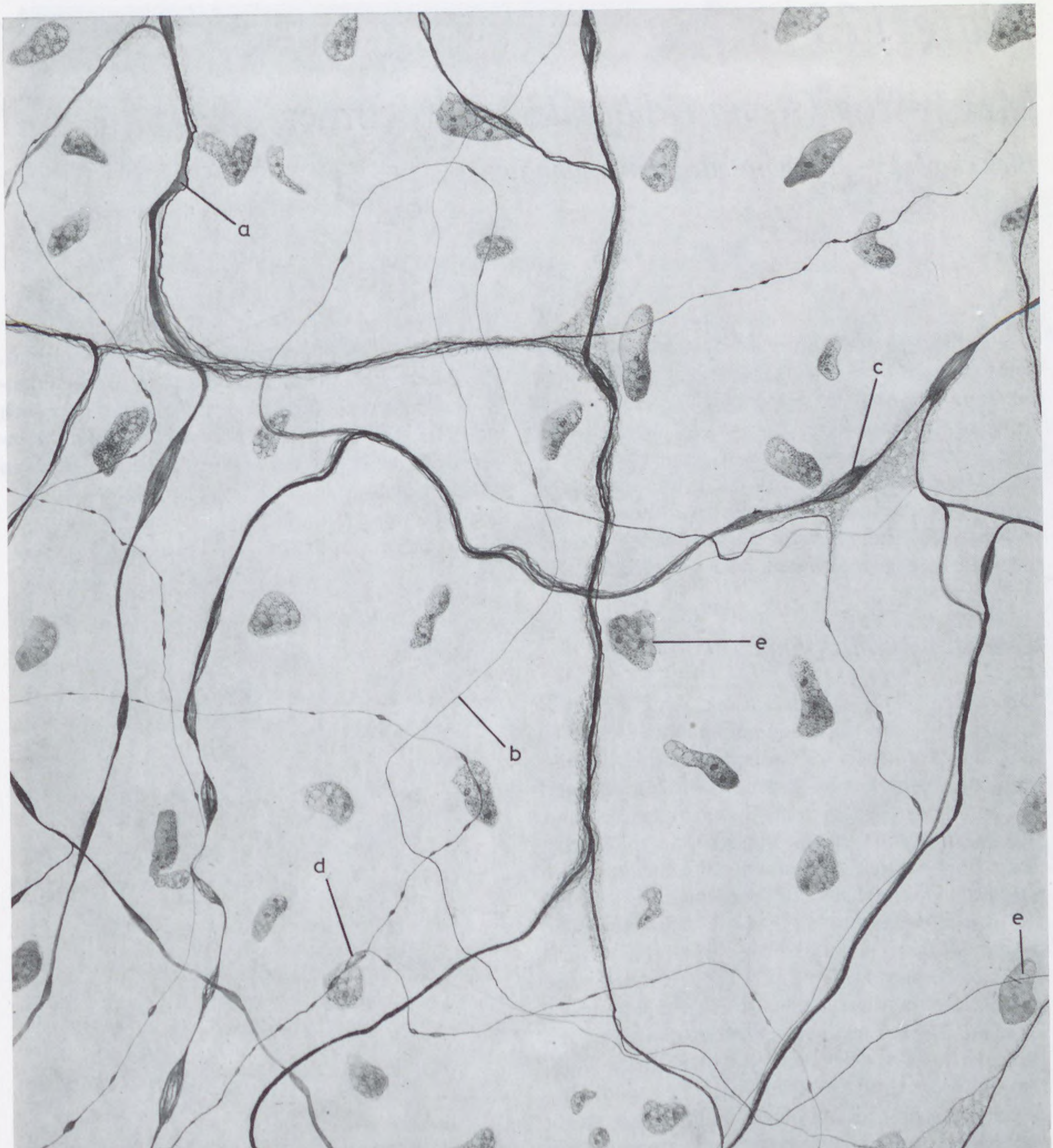
a
c
e
b
d
e

Plate 175

Marsh-frog (*Rana ridibunda* Laur) cornea

Bielschowsky–Ábrahám silver impregnation

A few thick (a) and numerous fine, varicose nerve fibres (b) constitute this characteristic plexus. Each collateral (c) originates perpendicularly from a varicosity of the main fibre. The straight, parallel running fibres of the plexus show a geometrical structure. The terminal fibres (d) end in the immediate vicinity of the corneal corpuscles (e). Numerous fine processes (f) originate from the cells of the cornea; they can be easily confused with nerve fibres.

General neurohistological comments

The cornea of the frog is convex. Anteriorly it is covered by a stratified squamous epithelium. The basal layer consists of cuboidal epithelial cells, while more superficially flattened cells can be found in 1 to 3 layers. There is no Bowman's membrane. The substantia propria is thicker than the epithelium; it is composed of about 20 lamellae which are parallel to the surface of the cornea. The lamellae are formed of connective tissue fascicles connected by an adhesive material. The substantia propria seems to be homogeneous. Corneal corpuscles and polynuclear migratory cells are located among the lamellae. The corneal corpuscles are elongated and their short, thick processes have blunt ends. Anastomoses between the cells can rarely be found. Descemet's membrane is a 2 μm thick, homogeneous or fibrillar structure; it does not contain any cells. It is limited by simple flattened epithelium towards the anterior chamber. The pentagonal or hexagonal epithelial cells are extremely flat, less than 1 μm in width. Nerve fibres arrive from the sclera and form a plexus near the outer epithelium. The fibres of the plexus vary in calibre. The thick fibres are generally varicose and continue in fine arborizations. The fine branches form frequent loops or rectangular bends. Occasionally the terminal fibres approach the fibrocytes but no direct connection could be revealed. Some of the nerve fibres penetrate between the epithelial cells.

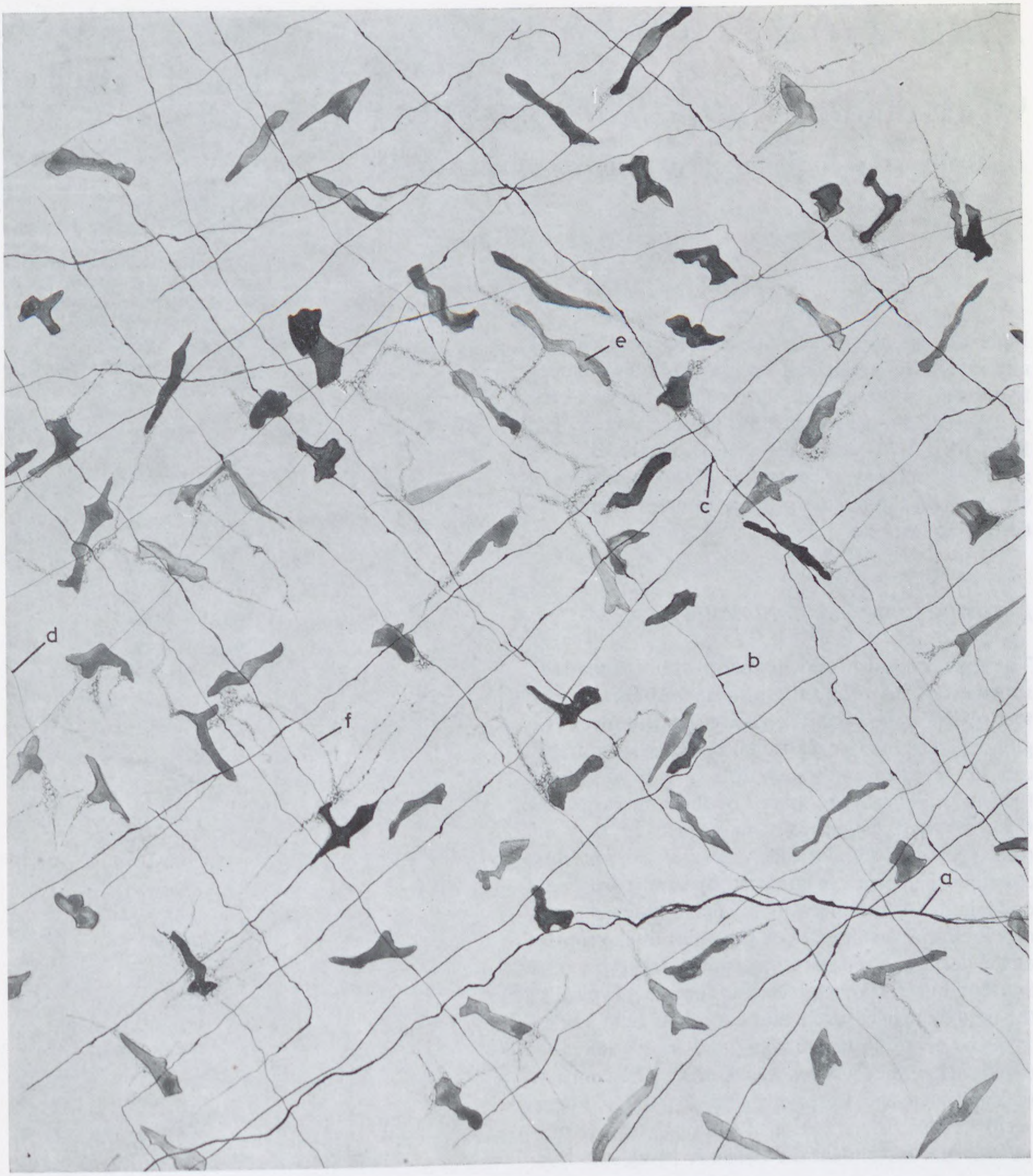
e
c
d
b
f
a

Plate 176

Grass snake *(Natrix natrix)* cornea

Bielschowsky–Ábrahám silver impregnation

Fine varicose nerve fibres (a), corneal corpuscles (d) and bundles of collagenous fibres (g) in the connective tissue substance of the cornea. Nerve fibres emit several branches (b). Some peculiarly fine nerve fibres (c) pass towards the corneal corpuscles (e – nuclei of corneal corpuscles). Fine channels are visible (f) in the lamina propria among the connective tissue fascicles.

Neurohistological comments

The convex cornea is thicker peripherally. The main substance is the substantia propria corneae. Descemet's membrane is hardly visible in the convex region whereas the fine elastic fibres of the membrane can be revealed on the periphery with resorcin-fuchsin staining. The outer epithelium varies in thickness and is generally composed of two or three rows of cuboidal cells. Towards the anterior chamber the cornea is bordered by simple flattened epithelium. A rich network of nerve fibres is present in the anterior part of the substantia propria of the cornea. Axons of various thickness cross one another but no anastomosis is formed. Typically the nerve fibres leave the nerve trunk at right angle. The fine nerve fibres are wavy and bear numerous ovoid, sometimes hollow, varicosities. The connection between the fibrocytes and the nerve fibres needs further investigations. Although the terminations are not known for the time being, the fine nerve plexuses in the cornea might be regarded as receptors.

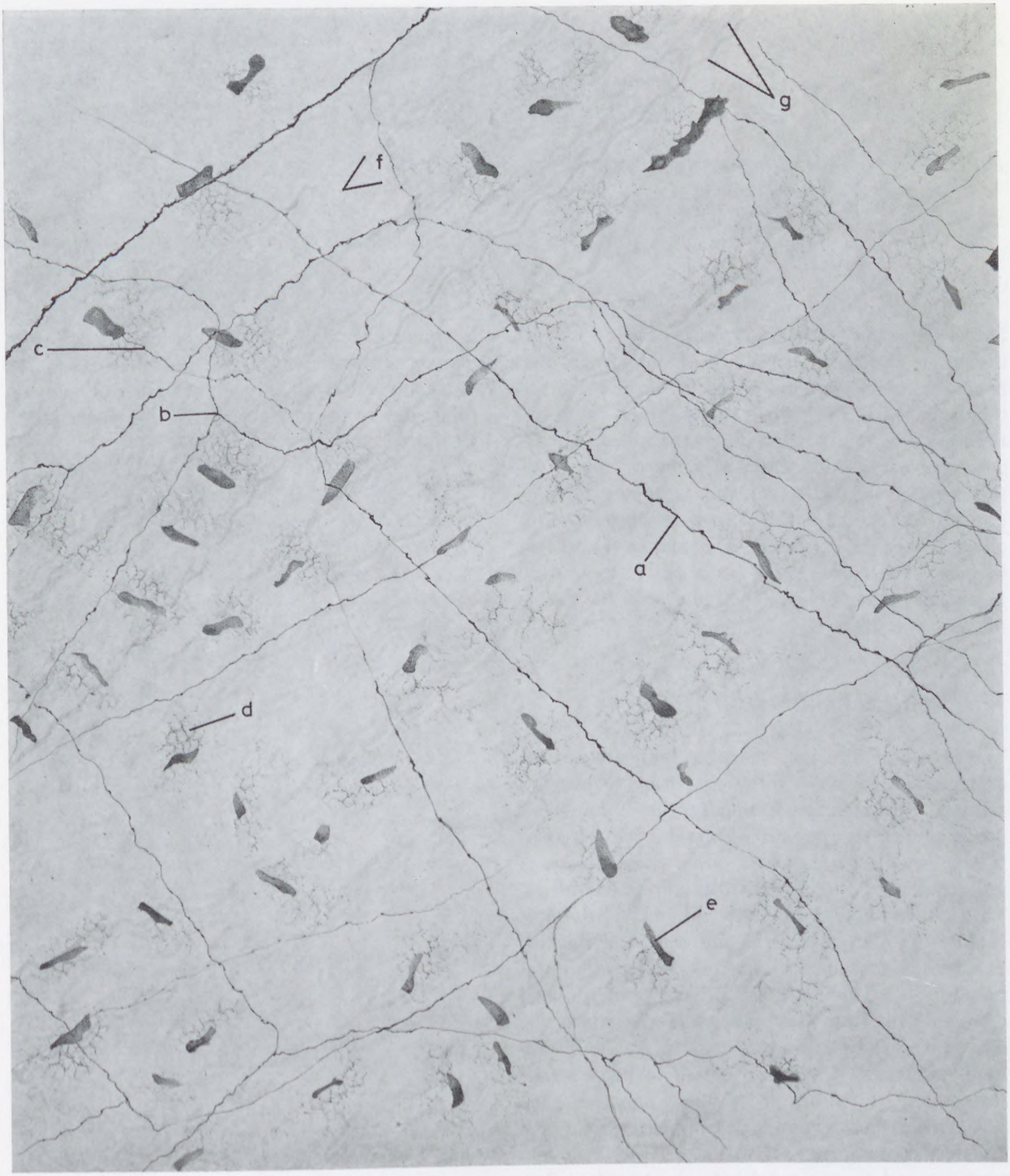
g
f
c
b
a
d
e

Plate 177

Domestic goose *(Anser domesticus)* cornea

Bielschowsky–Ábrahám silver impregnation

Nerve fibres and corneal corpuscles can be seen in the connective tissue substance of the cornea. Repeatedly branching nerve fibres (a) form a characteristic network. Triangular thickenings (b) mark the points of ramification along the fibres. Apparently the nerve fibres enter also the cytoplasm of the corneal corpuscles (c) and terminate in end-knobs (d). The characteristic corneal corpuscles (e) give rise to a great number of processes (f) passing in every direction. These processes have a wide base, taper gradually off, and blend with the plexus of the nerve fibres.

Histological comments

The cornea of birds is convex but there are considerable species-specific variations in its convexity, size and thickness. Undoubtedly, these differences are related to the animals' way of life as well as to the environment. There are birds whose cornea is quite flat, while it is markedly convex in others. The cornea is 5 to 6 mm in diameter, thinnest around the midpoint of the convexity and thickest around the margins. Its *outer epithelium* is composed of 4 to 5 cell layers. The basal layer contansi cuboidal cells covered with rows of columnar cells. The cells of the other layers are flat. At the border of the sclera the epithelium blends with the stratified columnar epithelium of the conjuctiva. The *substantia propria* is composed of connective tissue lamellae running parallel to the surface. The corneal corpuscles are located between these lamellae. Descement's membrane is thin; it stains with resorcin-fuchsin. The inner epithelium is simple, its cells are flat and protrude into the anterior chamber. Nerve fibres of the cornea derive from the long and short ciliary nerves. Bundles of nerve fibres leaving the sclera enter the substantia propria and form regular quadrangular systems in the connective tissue. Fine ramifications of these systems surround the connective tissue cells and seem to perforate them or terminate inside the cells. However, the "intracellular" termination is very probably only an artifact due to the restricted resolving power of the light microscope.


c
e
f
e
a
b
e
d

Plate 178

Domestic fowl *(Gallus domesticus)* cornea

Bielschowsky–Ábrahám silver impregnation

Small portion of the connective tissue of the cornea demonstrating close contacts between the nerve fibres and the corneal corpuscles. Several branches (b) originate from a long meandering nerve fibre (a). Characteristic triangular lamellae filled with neurofibrils can be seen at the branching sites. Some of the terminal segments bear end-bulbs (c) which are in close contact (d) with the corneal corpuscles even if they do not penetrate the cytoplasm. Note two corneal corpuscles (e) with typical large polyhedral nuclei (f) and many branching processes (g) in close contact with the fine nerve fibres.

Neurohistological comments

The richness of the nerve supply of the substantia propria is surprising. The number of nerve fibres is so high that they might be mistaken for processes of the corneal corpuscles running parallel with the collagenous fibres of the lamellae in the substantia propria. At higher power, however, the differences between these extremely fine nerve fibres and the anastomosing processes of the fibrocytes are clearly seen. Occasionally the nerve fibres break up into branches which leave the main axon at a right angle. Network systems are formed in the substantia propria by repeated branchings. The terminal fibres are attached either to the body of the fibrocytes or to their processes. As a result, axons are associated with two or more connective tissue cells or cellular processes.

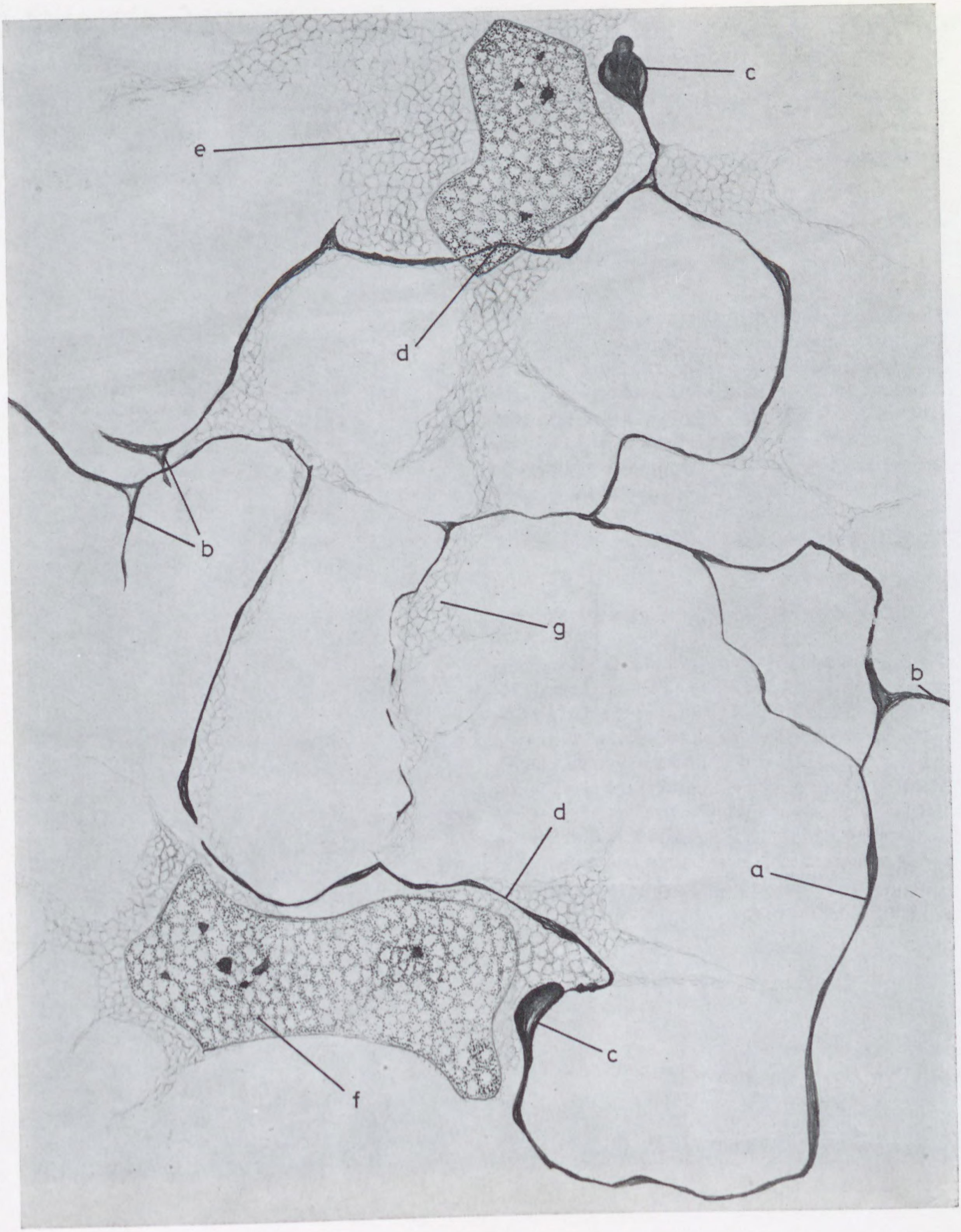
c
e
d
b
g
b
d
a
c
f

Plate 179

Domestic fowl *(Gallus domesticus)* cornea

Bielschowsky–Ábrahám silver impregnation

Corneal corpuscles and a network of nerves deriving from a single nerve fibre are shown in the connective tissue of the cornea. The nerve fibre (a) emerging from the main trunk emits branches (b), collaterals (c) and fine terminal fibres (d). Here and there, the nerve fibre (e) seems to pass inside the corneal corpuscle (f), occasionally very close to the nucleus (g). The nerve fibres terminate in bulky end-knobs, some of which are attached to the fine terminal processes of the neighbouring fibrocytes.

General neurohistological comments

The interpretation of functional connections between corneal corpuscles and nerve fibres is a controversial issue. Some authors claim that the nerve fibres terminate inside the cytoplasm of the fibrocytes, while others have failed to find an intimate contact between the corneal corpuscles and the nerve fibres. Recent electron microscopic investigations of the mammalian cornea have suggested that the nerve bundles in the lamina propria are intermittently in direct contact with the cytoplasmic membrane of the corneal corpuscles.

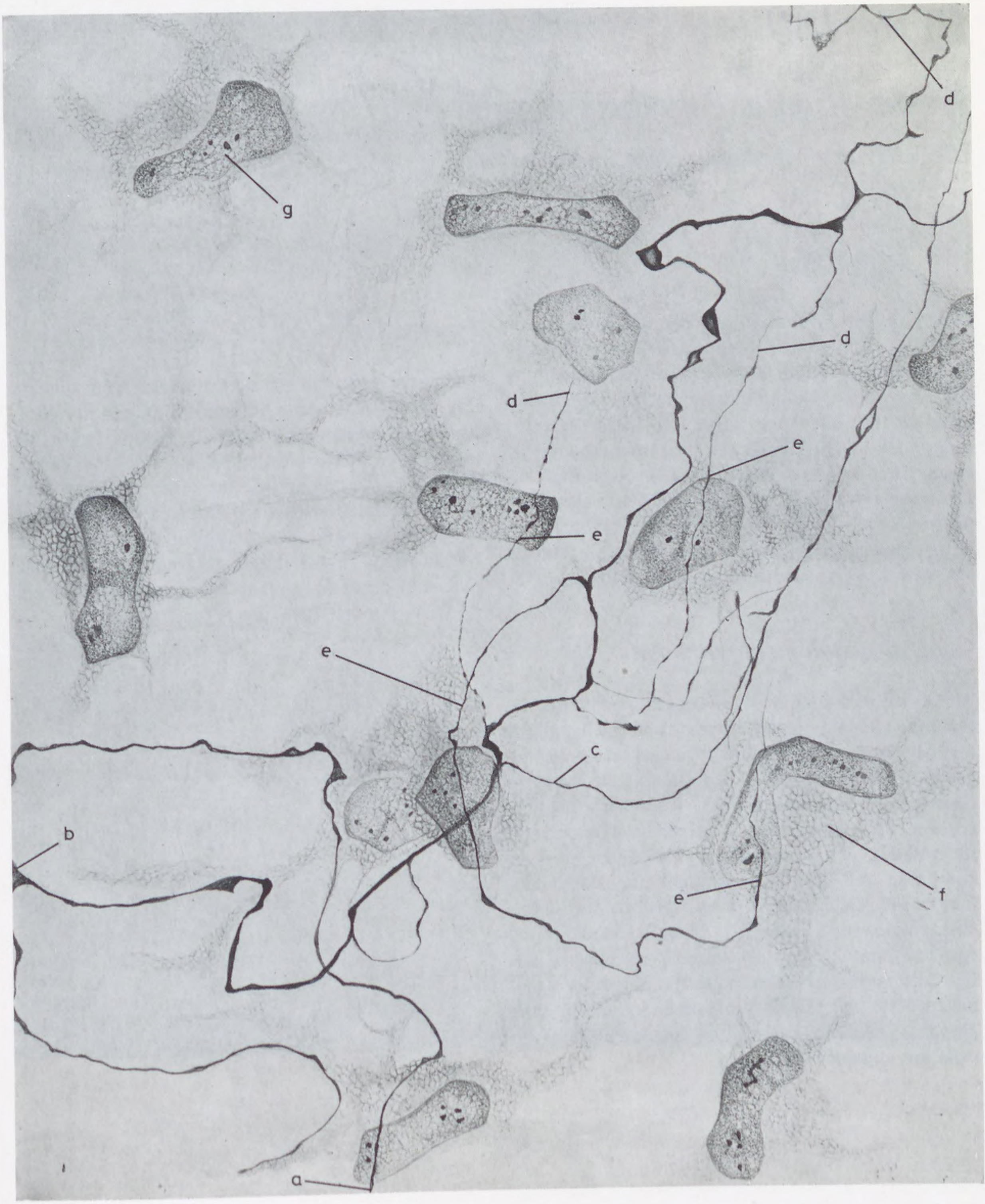
d
g
d
d
e
e
e
b
c
f
e
a

Plate 180

Horse *(Equus caballus)* cornea

Bielschowsky–Ábrahám silver impregnation

Plexus of nerve fibres in the connective tissue of the cornea and corneal corpuscles. The thick fibres (a) running in bundles show frequent branchings (b). As a rule, collaterals originate from triangular lamellae, but they also leave the main fibre (c) monopodially. The branches bear numerous varicosities and elliptic thickenings (d). Note the corneal corpuscles (e) with vacuolated cytoplasm. The nuclei (f) vary in shape and size. Cytoplasmic processes (g) arise from a wide basis; anastomoses (h) are conspicuous at light-microscopic pictures.

General histological comments

The cornea of mammals is convex and varies in thickness: it is thinner at the centre and thicker along the periphery. The corneal layers are as follows: *(i)* outer epithelium, *(ii)* lamina elastica anterior (Bowman's membrane), *(iii)* substantia propria corneae, *(iv)* lamina elastica posterior (Descemet's membrane), *(v)* endothelium. The outer layer is composed of stratified epithelium; Bowman's membrane is a thin layer of collagenous fibrils; the substantia propria consists of collagenous fibres showing birefringance; Descemet's membrane is a light, homogeneous membrane staining with resorcin-fuchsin. Angular cells of the endothelium have elongated nuclei; intercellular spaces among the cells are conspicuous.

Innervation

The nerve supply of the cornea comes from the ciliary plexus. The nerve fibres form an annular plexus in the sclera. The trunks emerging from this plexus give anastomosing branches to the nerves passing to the conjuctiva; then they enter the cornea as radial branches arranged in several layers starting from the inner margin of the cornea. The ramifications in the different layers form a dense plexus of nerve fibres. The varicose terminal fibres establish contact with the corneal corpuscles.

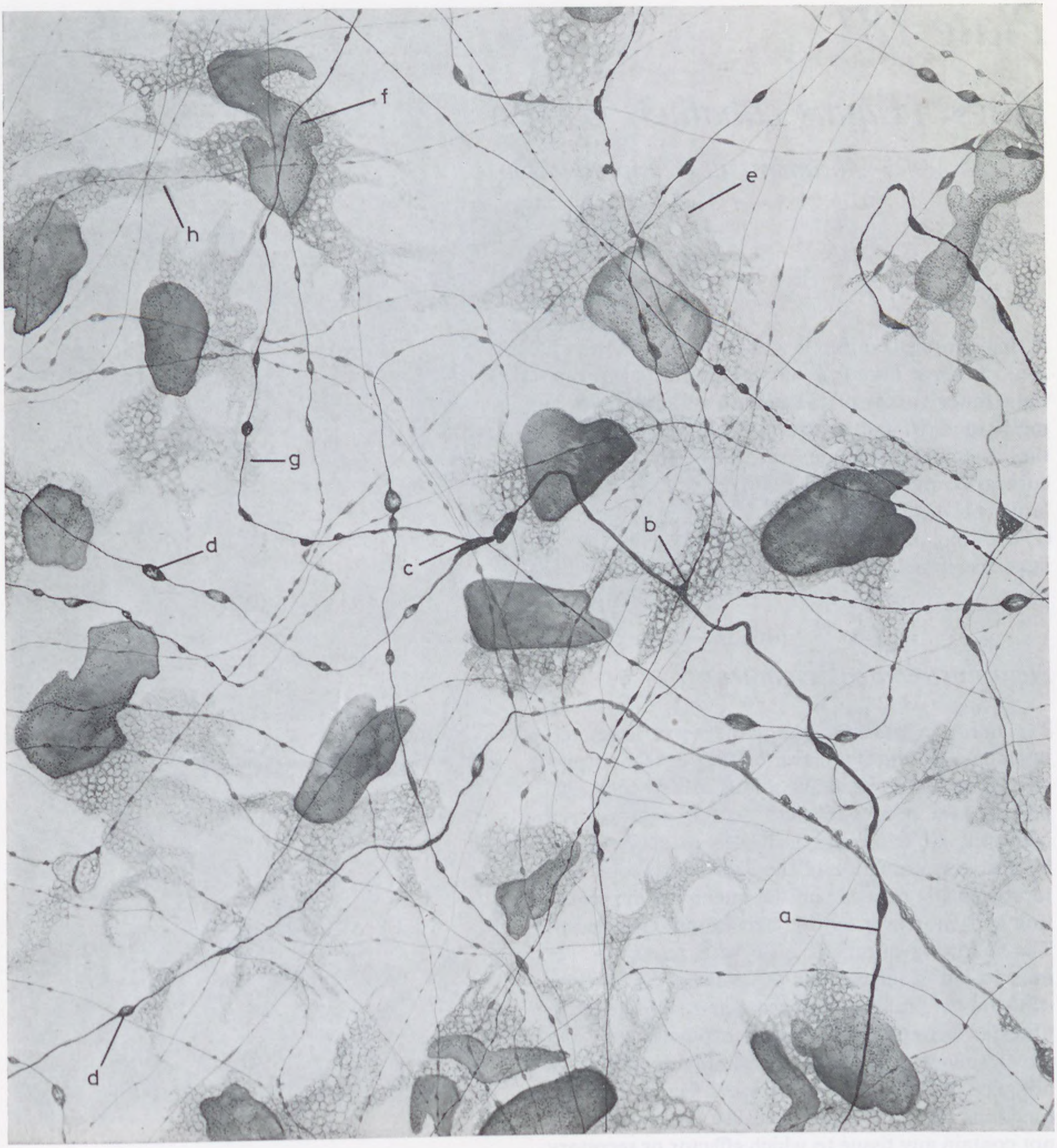
f
e
h
g
d
b
c
a
d

Plate 181

Horse *(Equus caballus)* cornea

Bielschowsky–Ábrahám silver impregnation

A single corneal corpuscle with its nervous network. A thick nerve fibre (a) coursing upwards from the right lower corner of the picture emits a descending branch (b) and two terminal fibres (c). One of these seems to terminate (d) within a process of the corneal corpuscle (e). The corneal corpuscle has a large, polyhedral, eccentric, homogeneous nucleus (f) and long processes (g). The cytoplasm is vacuolated also in the processes and contains dark aggregates.

Neurohistological comments

The question whether or not the nerve fibres terminate within the cytoplasm of the corneal corpuscles, has been repeatedly raised. More than 300 papers have been published on this controversial issue but no consensus has been reached mainly because the evaluation of the light-microscopic pictures strongly depends on the quality of impregnation and, moreover, on the bias of the investigator. The following questions arise with respect to the innervation of the cornea: *(i)* What is the function of the nerve fibres of the cornea? *(ii)* Do the nerve fibres in fact enter the corneal corpuscles? *(iii)* Do they terminate in the cytoplasm? *Ad (i):* The nerve fibres of the cornea have a sensory function. Other functions can be excluded because the cornea does not contain any tissue to which effector or secretory function could be assigned. The network supplies with receptors both the substantia propria and the outer epithelium and innervates the corneal corpuscles which might be regarded as sensory cells on the basis of their close contact with the nerve fibres. *Ad (ii):* It is a fairly sound proposition that in birds and mammals the nerve fibres do in fact penetrate the corneal corpuscles. *Ad (iii):* Having entered, they either terminate inside the cells or pass on in the anastomosing processes.


e
f
g
d
c
b
c
a
c

Plate 182

Horse *(Equus caballus)* cornea

Bielschowsky–Ábrahám silver impregnation

A single fibrocyte of the cornea (corneal corpuscle) surrounded by nerve fibres and terminals. A nerve fibre (a) passes through the fibrocyte, recurves, and traverses the cytoplasm once more. A short lateral branch terminates in a peculiar end-formation (c_1) on a process of the fibrocyte. The nerve fibre, bearing varicose thickenings (b), seems to protrude into one of the processes of the corneal corpuscle in which it divides into two short branches (c_2). The branches terminate inside the cytoplasm without an end-formation. The cytoplasm of the corneal corpuscle (d) is vacuolated; the nucleus (e) is irregular and eccentric. Cell processes (f) emerge with a wide basis, are rather long, and branch abundantly.

Neurohistological comments

Light-microscopic pictures suggest that the nerve fibres project into and terminate within corneal corpuscles. In view of their close connection with the nerve fibres, the corneal corpuscles have been considered neuron-like cells. Since, as far as we know, the cornea is the only site where nerve fibres terminate on connective tissue cells, it might be assumed that the corneal corpuscles differ from other fibrocytes. They should not be regarded as neuron-like cells either, but rather as secondary sensory cells in contact with nerve fibres. Thus they probably play a role in the regulation of the vasomotor activity of loop-like vessels constricted or dilated reflectorically under the influence of nervous impulses thus maintaining the water balance of the substantia propria.

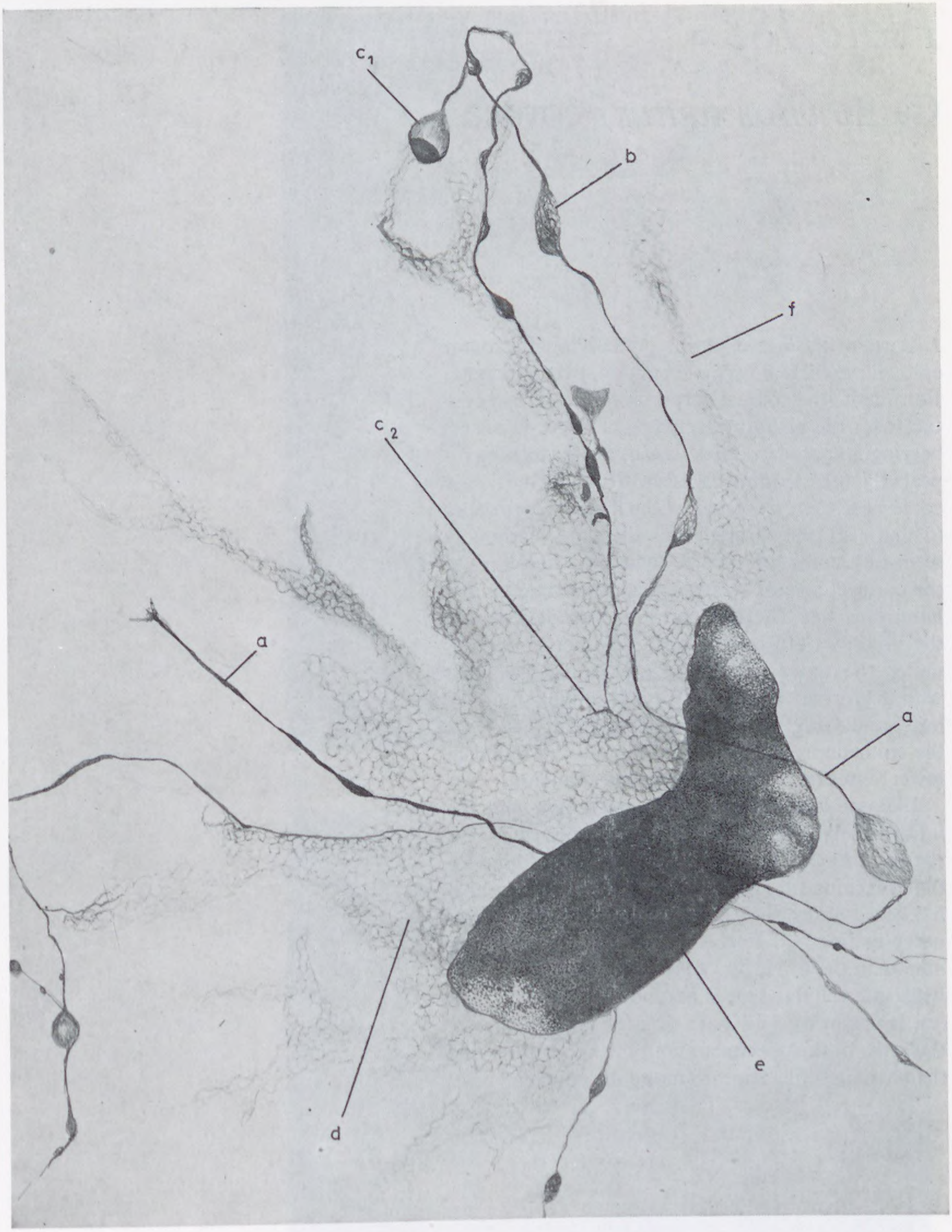
c1
b
f
c2
a
a
e
d

Plate 183

Cattle *(Bos taurus)* cornea

1. Part of the nerve plexus underlying the outer epithelium (Bielschowsky–Ábrahám silver impregnation). Note the corneal corpuscles which are in contact with the elaborate network of nerve fibres (a) bearing numerous varicosities (b) and branching repeatedly (c). A number of nerve fibres not only come near the cytoplasm of the corneal corpuscles (d) but also pass through the cells and occasionally seem to terminate (?) inside them. The nuclei (e) of the corneal corpuscles are irregular, elongated, and homogeneous. The cytoplasm is vacuolated, and the processes are rather short. The nerve plexuses under the outer epithelium are in close contact with the former; these are especially abundant in the horse and cattle. Some of the fibres do, in fact, enter the epithelium. Such plexuses can also be found in lower vertebrates, but they are less abundant.

2. Basal layer of the outer epithelium and the intraepithelial nerve plexus (Jabonero's silver impregnation). Note the thick varicose nerve fibres (a), the branching sites (b) and the plexus of intraepithelial nerve fibres (c). This layer contains only a few nerve endings (d) since the majority of axons terminate in the top layer of the epithelium. There are wide intercellular spaces among the epithelial cells (e). Irregular nuclei (f) are situated in the centre of the cells. In this specimen, both the nerve fibres and their terminations appear among the epithelial cells.

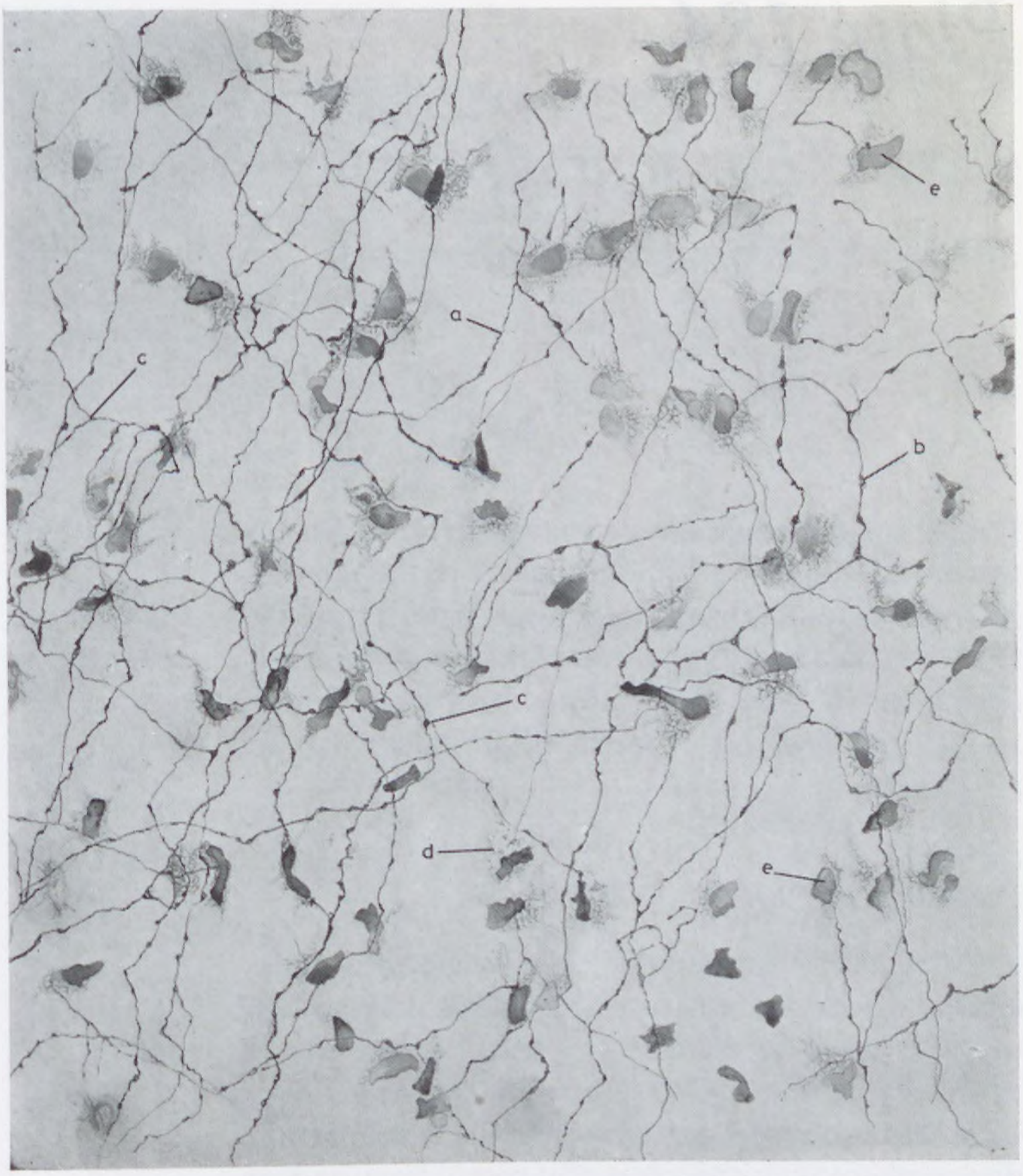

1

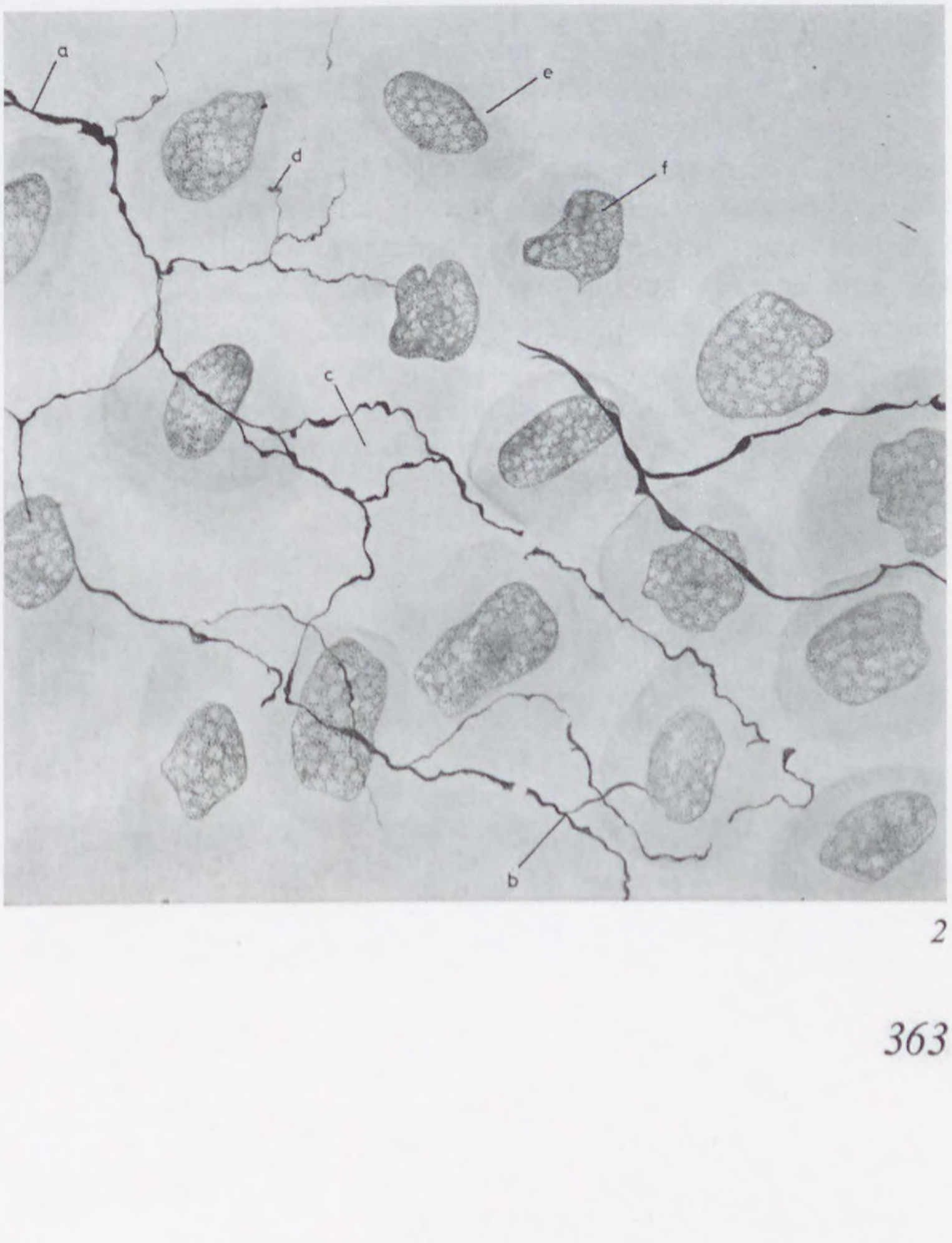

2

Plate 184

Cattle *(Bos taurus)* cornea

Jabonero's silver impregnation

Portion of the external corneal epithelium. An upward coursing nerve fibre (a) passes in the intercellular clefts and, approaching the surface, terminates freely in an end-knob (b). The diameter of the meandering nerve fibre varies along its course. Large, round epithelial cells (c) with elliptic nuclei (d) are also visible.

Neurohistological comments

The debates on intraepithelial nerve fibres were focussed around two questions: *(i)* what is the course of such nerve fibres, and *(ii)* where is the site of their termination? Silver-impregnated preparations have failed to furnish an answer to the first question, due partly to their thickness and partly because they have not been made in series. Also, different sites of termination have been proposed, depending on the technique used. Electron microscopic investigations of the cornea have finally revealed that in the basal layer the nerve fibres are invaginated into epithelial cells in deep grooves. The nerve fibres protruding into the epithelium also proceed in the intercellular grooves of the epithelial cells. Intraepithelial nerve fibres reach the surface of the cornea and the majority terminate in the layer of squamous cells. The number, course and localization of intraepithelial fibres show extreme variations in different vertebrates; they are most numerous in the human cornea.

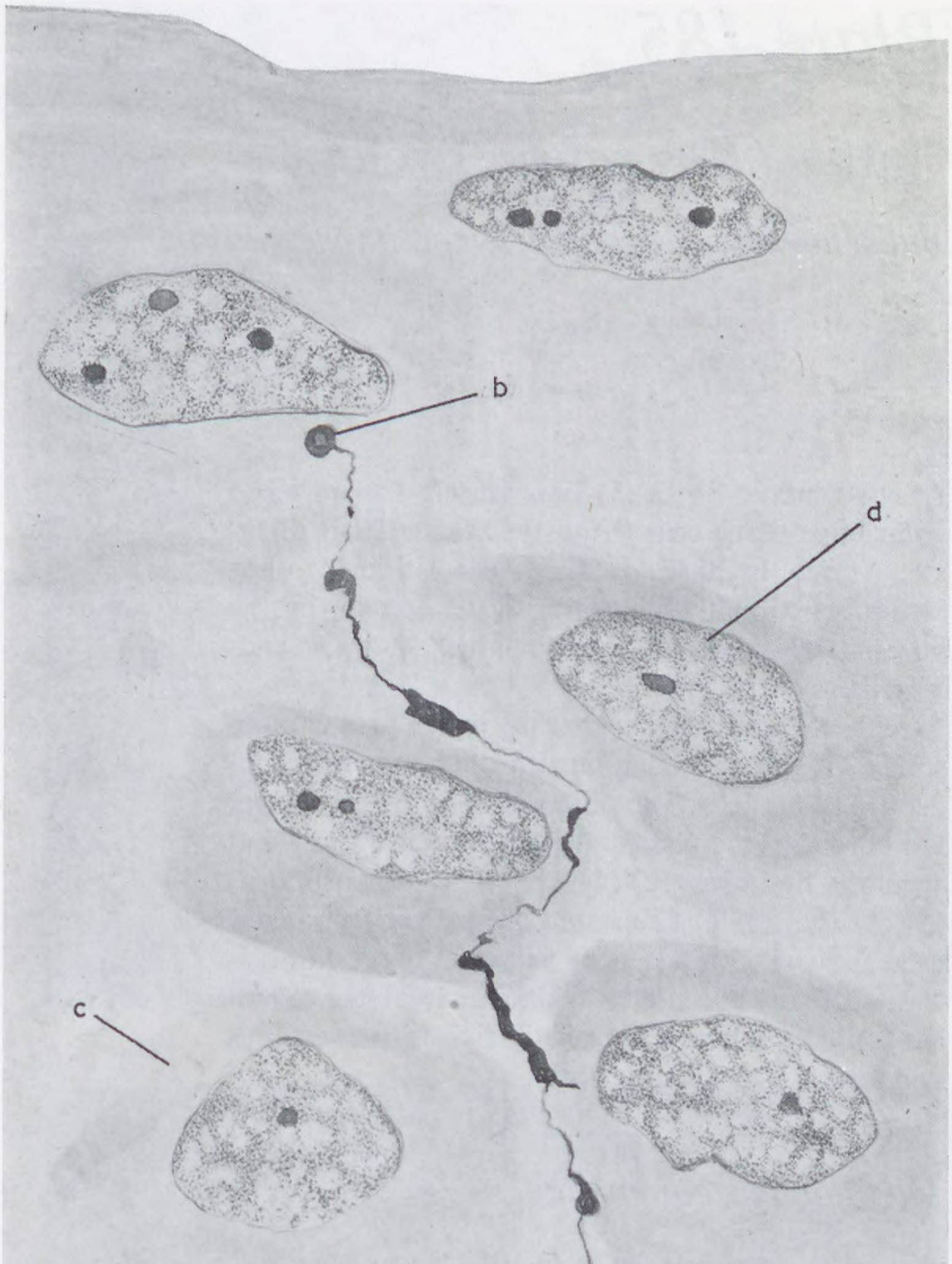
b
d
c
a

Plate 185

Cattle *(Bos taurus)* sclera

Bielschowsky–Ábrahám silver impregnation

1. Thick nerve fibres (a) pass among the nuclei of connective tissue cells (b) of the sclera. Their diameter varies because of the varicosities (c) they bear; occasionally neurofibrils (d) appear in the fibres (f) (e – intercalated lamellae, g – end-lamellae).

2. Rich terminal nerve plexus in the ground substance of the sclera among the nuclei (e) of connective tissue cells. The thick nerve fibre in the lower left corner of the picture divides into two wavy and varicose branches (b) which contain neurofibrils (d). As the result of repeated branchings (a), a delicate network composed of very fine nerve fibres is formed. Note the neurofibrillar intercalated lamellae (c). The sclera is especially rich in nerve fibres and nerve endings anteriorly.

Histological comments

The mammalian sclera is a thick membrane, bluish-white in colour. Its main constituents are collagenous connective tissue fascicles arranged in meridional, but also in equatorial direction. Elongated connective tissue cells appear among the fascicles. Nerve plexuses consisting of thick and fine fibres alternate in the outer and central layers of the sclera. The thick fibres ramify and the branches terminate in polyhedral end-lamellae of ring-like structures.

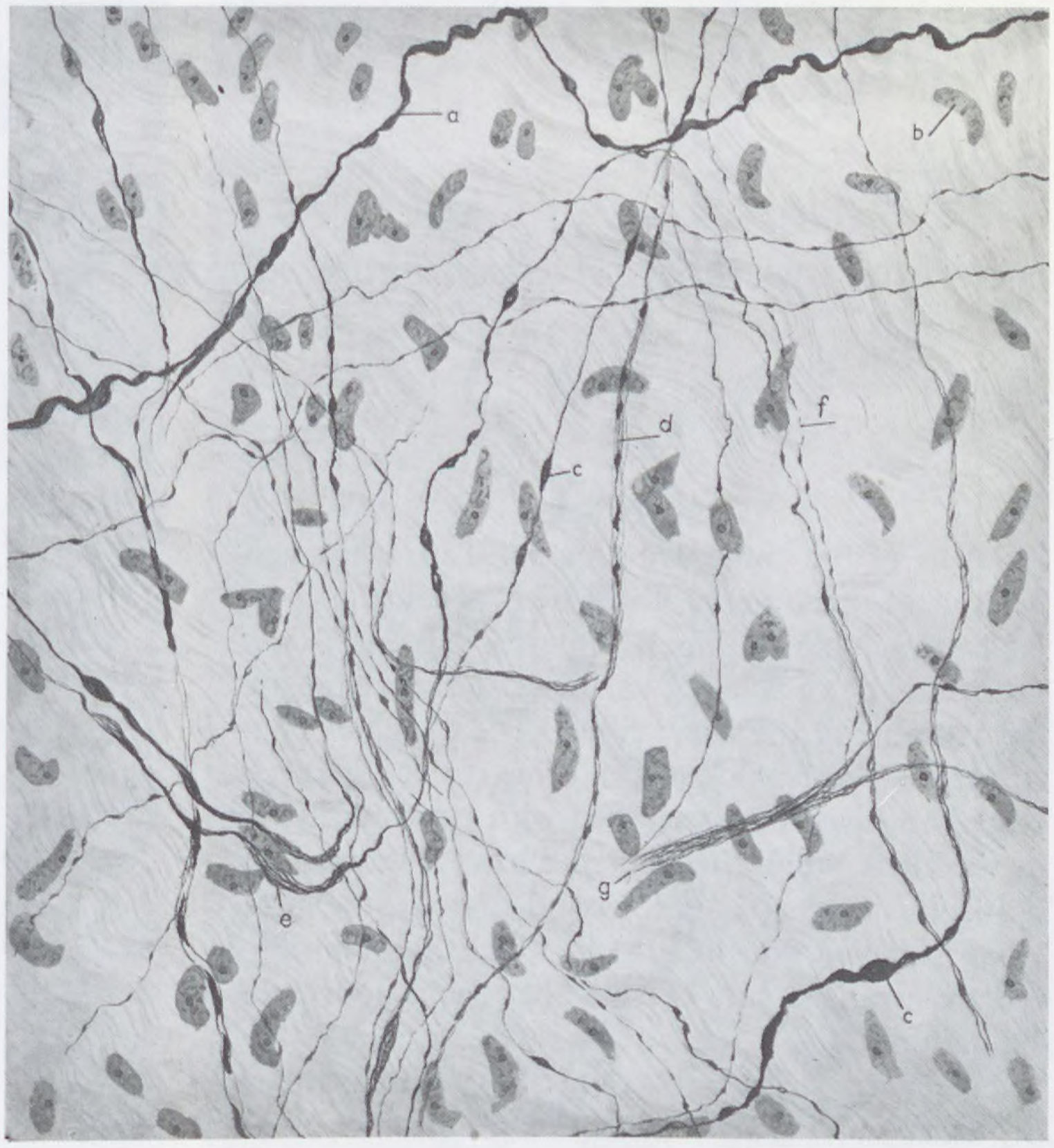

1

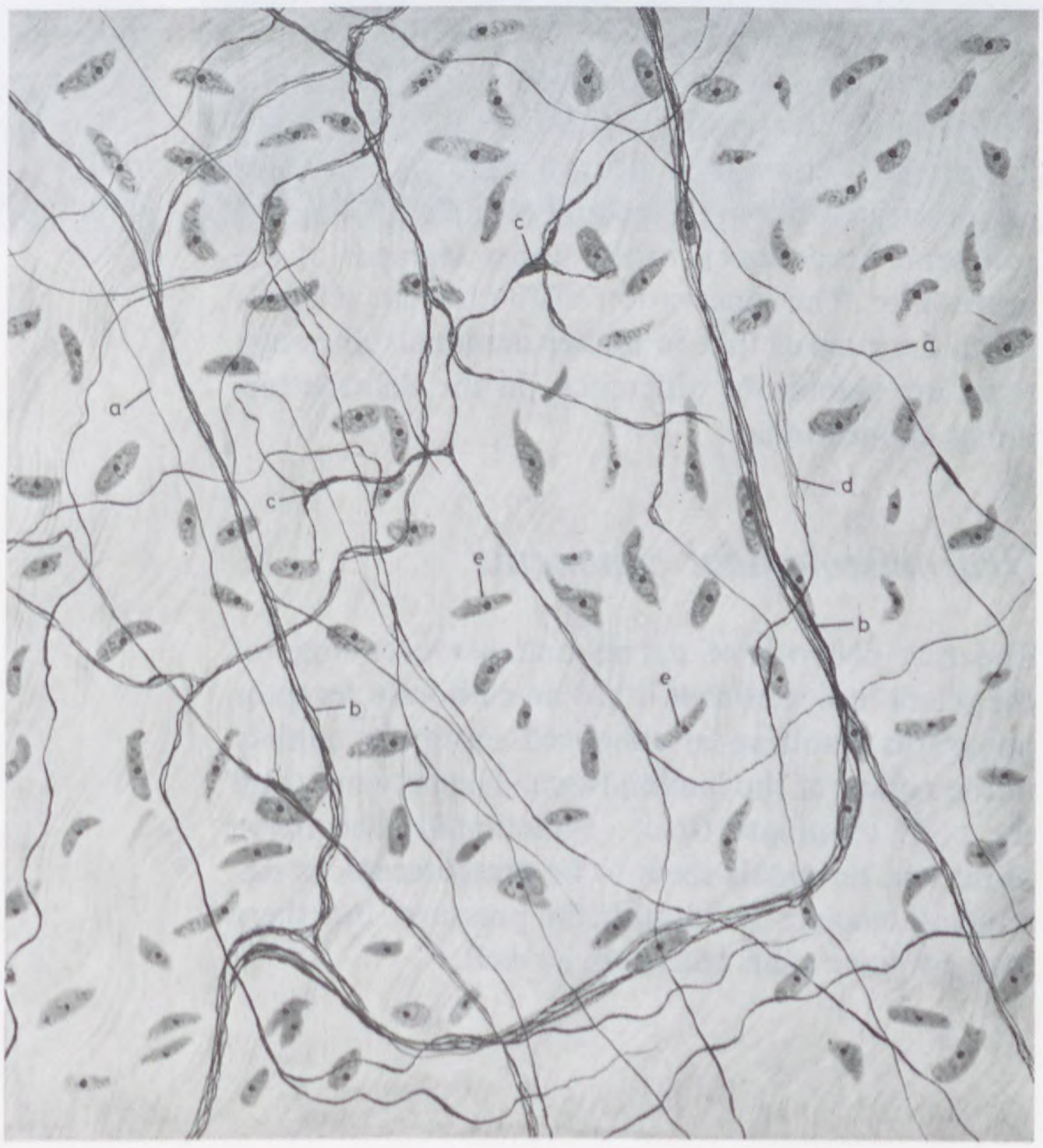

2

Plate 186

Sclera

Bielschowsky–Ábrahám silver impregnation

1. Sclera of the cattle *(Bos taurus)*. Terminal ramification of some nerve fibres with peculiar end-lamellae resembling Chinese lanterns. Nuclei of connective tissue cells (a) of various size and shape are located among the nerve fibres. The plexus is constituted by both thick (b) and fine (c) nerve fibres. Note the varicosities (d) filled with neurofibrils (e) in the thick fibres. The nerve fibres (g) leaving the branching points (f) are long and smooth; the large lantern-shaped lamellae (h) in which the neurofibrils are arranged side by side are conspicuous end-formations.

2. Human sclera. A thick bundle (c) of myelinated (d) nerve fibres passes among the connective tissue fascicles (a) and nuclei of connective tissue cells (b). Some axons bear enlargements and incisions characteristic of depressor fibres, and also varicosities (f). Fine terminal fibres (h) originate from the bundle vertically (e); these are equipped with round terminal discs (i) containing neurofibrils (g). The discs vary considerably in shape and structure. Note the collateral branches (j) in the upper segment of the nerve fibre. The innervation of the human sclera is much the same as that in higher mammals although there are significant differences in the delicate terminal connections.

Neurohistological comments

The rich network of nerves and nerve endings of the sclera indicates that it has an elaborate receptor apparatus resulting in enhanced sensitivity mainly in the region of the lamina fusca. The networks and the coils terminate freely. Functionally the nerve fibres and terminals seem to be pressoreceptors signalizing changes in intraocular pressure, but there may be some pain receptors as well.

1

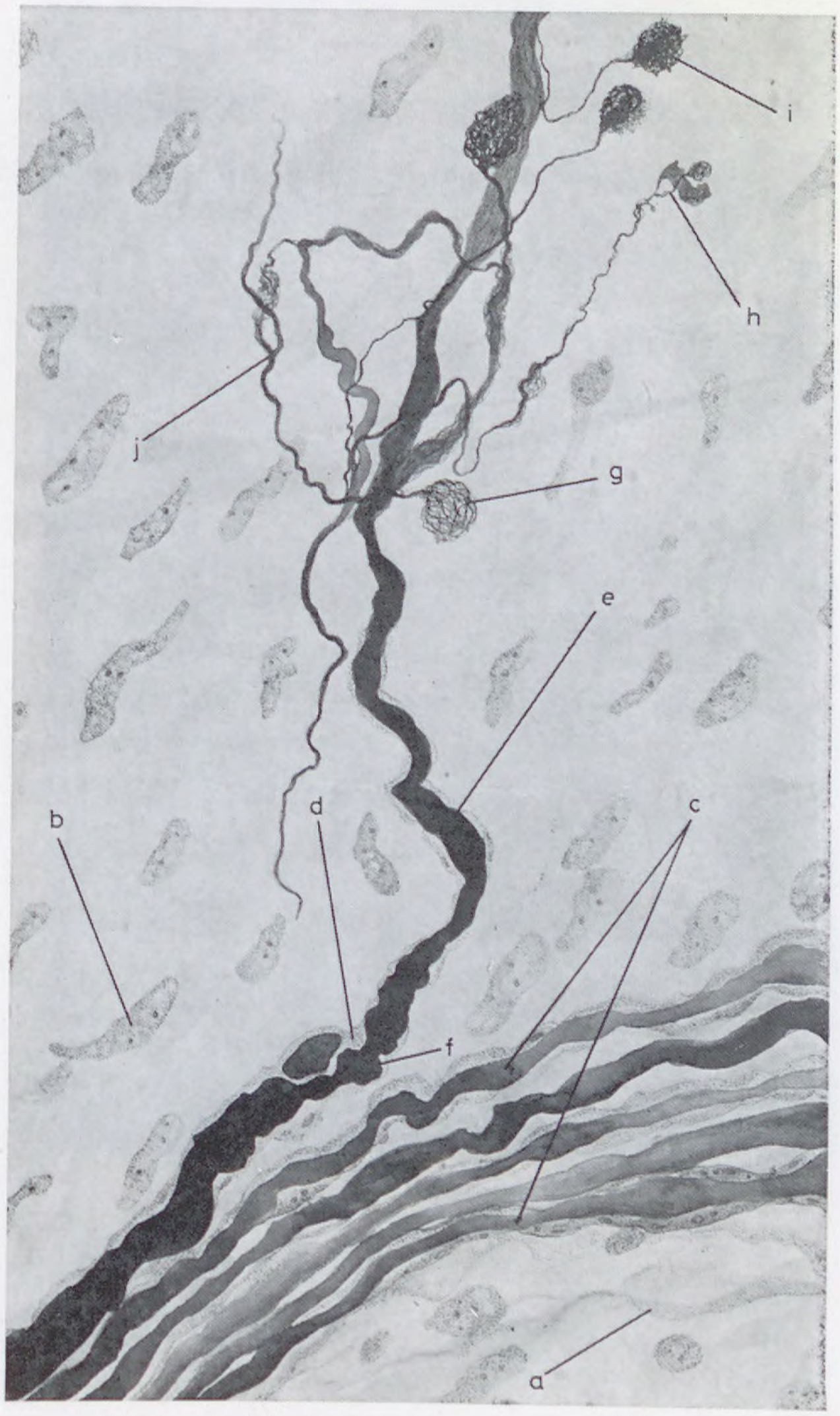

2

Plate 187

Innervation of the sclera

Photomicrograph

Sclera of the cattle *(Bos taurus)*. A large fascicle of parallel nerve fibres terminating in small end-lamellae appears in the middle of the picture. Bundles of collagenous fibres, nuclei of connective tissue cells and large multipolar chromatophores are to be discerned around the nerve fascicle. The thick nerve fibres within the fascicle are the receptors of the sclera.

Plate 188

Marsh-frog *(Rana ridibunda)* retina

Golgi's silver impregnation

A portion of the retina is shown in this picture. Under the layer of rods and cones (a) there is the outer nuclear layer (stratum granulosum externum, b), followed by the outer plexiform layer (stratum plexiforme externum, c). The wide inner nuclear layer (stratum granulosum internum, d) and the inner plexiform layer (stratum plexiforme internum, e) are located underneath. A bipolar cell (f) is present in the inner nuclear layer; its axon (g) arborizes in the inner plexiform layer. Dendrites (h) and nerve endings (j) are located in the outer plexiform layer. In the inner plexiform layer the axon of the bipolar cell (g) enters into synaptic connection (i) with the dendrite of a large ganglion cell (l). The layer of ganglion cells (stratum gangliosum, k) lies beneath the inner plexiform layer. Dendrites of the ganglion cells (m) arborize in the ganglion layer.

General neurohistological comments

The retina of the frog consists of the following layers, starting from the choroid inwards: *(i)* The *pigment layer* consists of a simple cuboidal epithelium, resting on the hyaloid membrane of the choroid. The proximal part of the cells, containing the nucleus, is pigmentless, while the needle-like pigment granules appear distally. The cytoplasm contains yellow, spherical lipid droplets and sausage-shaped myeloid corpuscles. *(ii) The rods* are long and thin while the *cones* are thick and short. *(iii) The external limiting membrane* appears on histological pictures as a distinct line. *(iv) The outer nuclear layer* contains the nuclei of the rods and cones in two rows. The rods and cones are the distal processes of the receptor cells. Proximally both cells have widened processes. The end of the rods is the spherule, and that of the cones is called the pedicelle. *(v) The outer plexiform layer* consists of nerve fibres of various origin. The spherules and pedicelles project into this layer and enter into synaptic connection with the dendrites of the bipolar cells. *(vi) The inner nuclear layer* contains four types of cells. The horizontal cells are located at the boundary of the outer plexiform layer and their long processes run parallel to the surface of the retina. The bipolar cells represent the second group of cells. Their dendrites are connected to the rods and cones in the outer plexiform layer while their axons synapse with the ganglion cells in the inner plexiform layer. Müller's long and narrow glial cells are the third cell type of the inner nuclear layer. Their cone-shaped terminals constitute the external limiting membrane while their proximal processes reach to the internal limiting membrane. The amacrin cells are the fourth cell type. They are located closest to the inner plexiform layer and have only one process each, which breaks up into branches at different levels. *(vii)* In *the inner plexiform layer* the axons of the bipolar cells enter into synaptic contact with dendrites of the ganglion cells. *(viii) The ganglion cell layer* consists of a single row of multipolar nerve cells. Their dendrites synapse with the axons of the bipolar cells, while their axons protrude into the next layer. *(ix)* The *layer of nerve fibres* is composed of the axons of the ganglion cells; these axons fuse in the optic nerve. *(x)* The innermost layer is the *internal limiting membrane* constituted by the widened processes of Müller's cells.

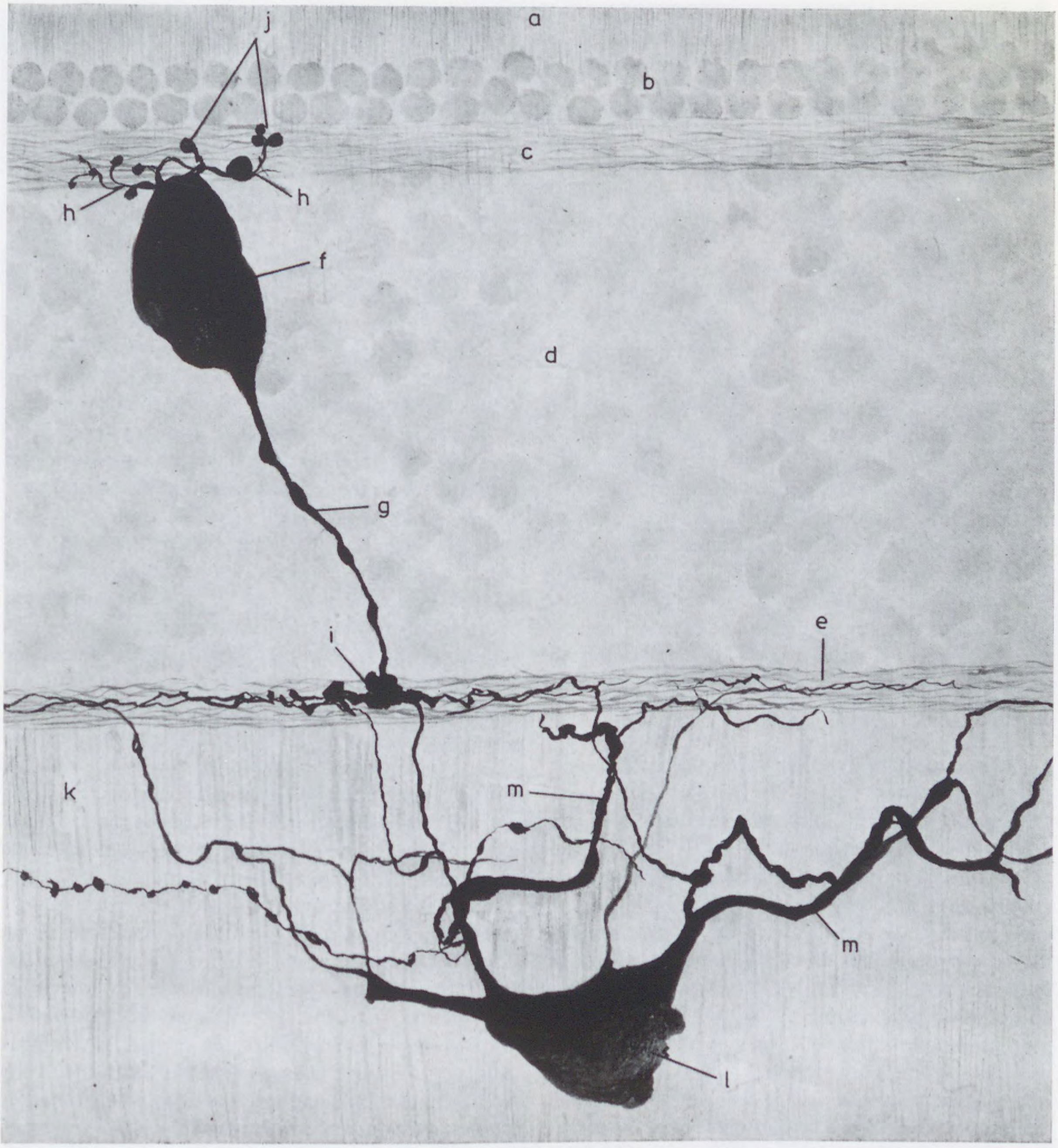
a
j
b
c
h
h
f
d
g
e
i
k
m
m
l

Plate 189

Common buzzard *(Buteo buteo)* retina

Golgi's silver impregnation

In the lower right corner of the picture the layer of rods and cones (a) and, above them, the outer nuclear layer (b) can be seen. Also the outer plexiform layer (c), inner nuclear layer (d), inner plexiform layer (e) and the ganglion cell layer (f) are depicted. Müller's fibres (g) take their origin from the outer nuclear layer as well as from the external limiting membrane while their arborization system (h) may be seen in the inner plexiform layer, the ganglion cell layer and in the layer of nerve fibres. The latter (i) is located over the supporting system in the upper left corner. A small part of the vitreous body (j) is to be seen above the retina.

General neurohistological comments

The retina of birds has the same structure as that of vertebrates.

(i) Pigment layer. *(ii)* Sensory epithelium (neuroepithelium) containing the rods and cones. The rods vary in length, generally between 40 and 45 μm; their inner portion is thin and slim while the outer part is cylindrical and thick. The cones are shorter and contain lipid droplets. *(iii)* The external limiting membrane is thin but distinct. *(iv)* The nuclei of rods and cones are arranged in 2 to 3 rows in the outer nuclear layer. Each photoreceptor cell emits a thin axon which projects into the next layer. *(v)* The outer plexiform layer consists of these thin fibres. The spherules of rods and the pedicelles of cones terminate here. *(vi)* The cellular elements of the inner nuclear layer are the horizontal cells, bipolar cells, amacrin cells and Müller's cells. The horizontal cells lie at the boundary between the plexiform layer and the inner nuclear layer. Their dendrites end upon the spherules and pedicelles in telodendritic form. The bipolar cells are arranged in at least five layers. Their proximal processes synapse with the spherules and pedicelles while the distal processes synapse with both the ganglion cells and amacrin cells in the inner plexiform layer. The amacrin cells are concentrated in the proximal part of the layer. One or several processes originate from their pyriform perikarya and form numerous sublayers in the inner plexiform layer. The inner nuclear layer contains also the nuclei of Müller's cells which span the entire thickness of the retina from the external to the internal limiting membrane. Their thin perikarya traverse the outer nuclear layer, outer plexiform layer and inner nuclear layer to break up into numerous branches in the proximal part of the inner plexiform layer. The branches then advance in the retina and terminate in slightly thickened end-knobs constituting the external limiting membrane. *(vii)* The thin inner plexiform layer is composed of nerve fibres. *(viii)* Most of the ganglion cell layer contains a single row of multipolar nerve cells, but the cells may be arranged in 3 to 4 rows in the region of the central fovea. Dendrites of the nerve cells synapse with both the axons of the bipolar cells and the processes of the amacrin cells in the inner plexiform layer. *(ix)* The layer of nerve fibres consists of unmyelinated axons which form the optic nerve and terminate in the cerebral optic centre. *(x)* The thin internal limiting membrane is formed by the end-knobs of Müller's cells arranged side by side.

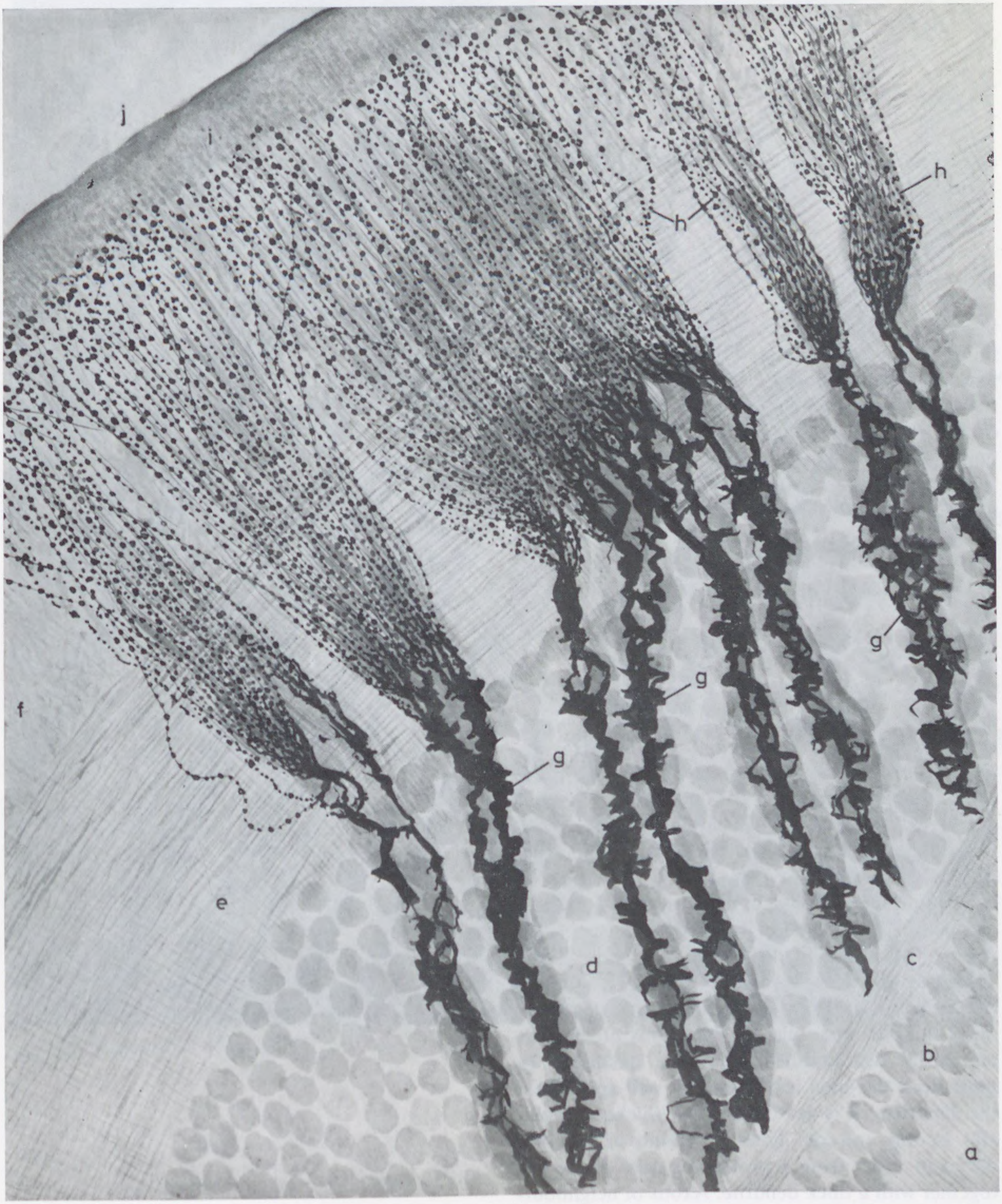
j
i
h
h
g
g
g
g
f
e
d
c
b
a

Plate 190

Horse *(Equus caballus)* retina

Bielschowsky–Ábrahám silver impregnation

Details of the ganglion cell layer and layer of nerve fibres. The multipolar nerve cells (a) contain neurofibrils (b); some dendrites (c) may be seen to leave the cells. The axons (d) of the ganglion cells ascend diagonally. Between the nerve cells and the nerve bundles there is a loose plexus of nerve fibres (e). Elongated varicosities (f) are frequent along the fine fibres constituting the plexus. The round nuclei (g) belong to nerve cells that have remained unimpregnated.

General neurohistological comments

The nerve cells in the retina of the cattle and horse are very large and their network of dendrites is very rich. The perikarya are large and polyhedral depending mainly on the number and shape of the processes. The cytoplasm is homogeneous without any special features. The tigroid bodies are relatively large and can be stained with toluidine blue or gallocyanine. The wavy neurofibrils varying in calibre produce distinct network systems. A great number of small, round mitochondria appear in the cytoplasm mainly in the vicinity of the nucleus. The relatively large, globular nucleus is situated eccentrically. The nuclear membrane is conspicuously thick in some places. The axons of the cells are easily distinguished from the dendrites. In most cases the axon leaves the cell well apart from the dendrites; it is narrow first but thickens gradually. In dogs and cats, however, mainly in old ones, the axon arises from a protruding part of the cell together with a thick dendrite. Axons of neighbouring cells assemble in groups and enter the layer of nerve fibres in fascicles. The dendrites originate from a wide base and establish extremely abundant ramification systems.

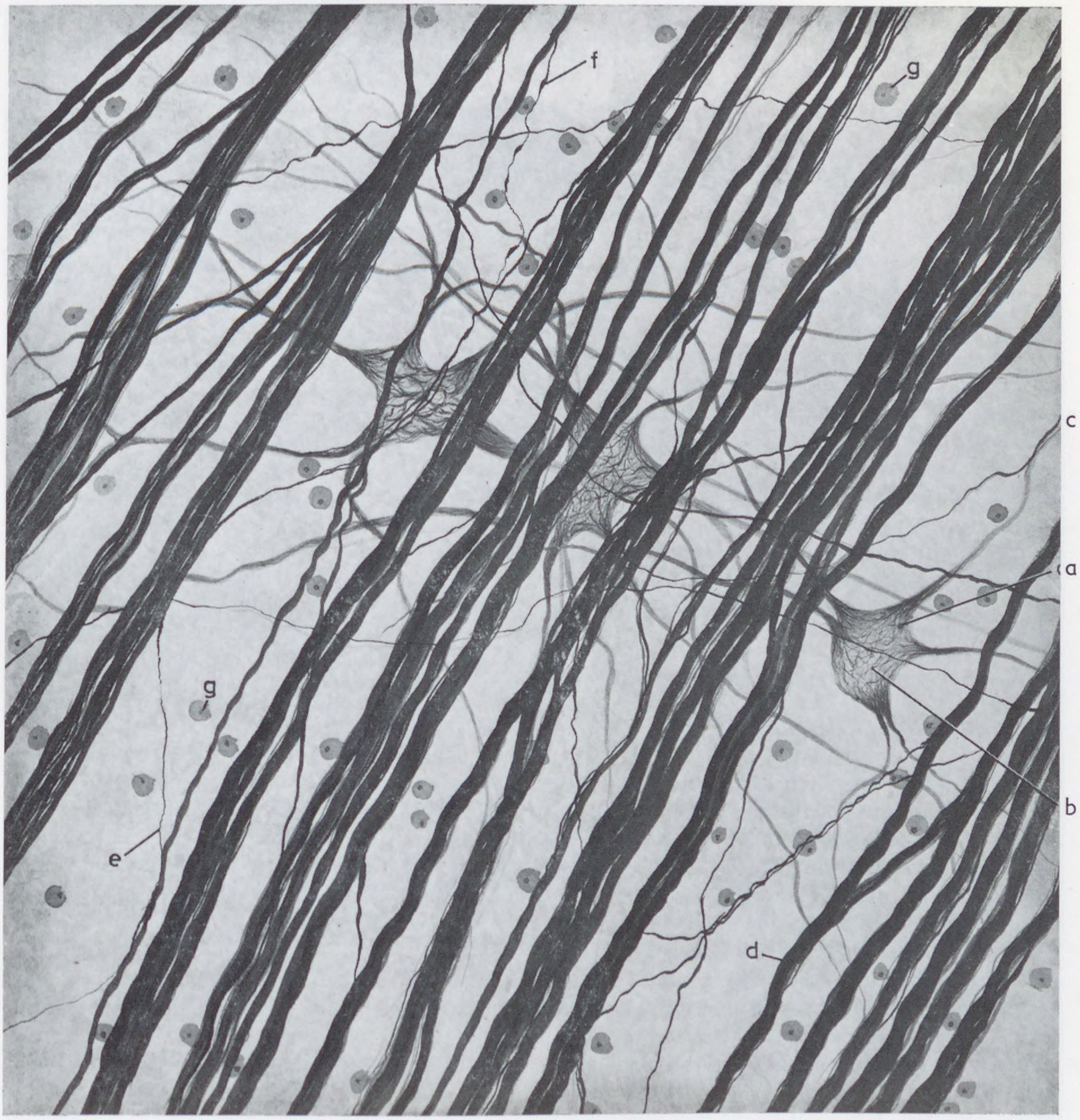
f
g
c
a
g
b
e
d

Plate 191

Cattle *(Bos taurus)* retina

Bielschowsky–Ábrahám silver impregnation

Part of the ganglion layer. Two nerve cells (a) can be seen in the right and left corners. The round nuclei (b) are situated eccentrically; neurofibrils (c) and dendrites (d) can also be discerned. Dendrites leave the perikarya in large numbers and radiate in many directions. The dendritic branches bear varicosities (e), while the thin terminal branches are equipped with round end-bulbs (f). Neurofibrils (c) appear periodically in one of the thick nerve fibres (g). The thin fibres (h) bear series of elongated varicosities (i).

Neurohistological comments

Dendrites which vary both in calibre and in their ramification systems emerge mainly from the larger nerve cells; as many as 20 to 30 dendrites or even more may originate from a single cell. Their initial segment is thick and they usually contain neurofibrils. Immediately after leaving the perikaryon, the dendrites bifurcate; one of the branches is often much thicker than the other. The branches proceed in a narrow flat layer. In well-stained preparations the dendritic arborizations can be seen to end in relatively large bulbs establishing synaptic connection with the axons of bipolar cells.

e
h
e
g
f
e
f
c
i
d
f
c
a
a
b
c
d

Plate 192

Cattle *(Bos taurus)* retina

Bielschowsky–Ábrahám silver impregnation

Part of the ganglion cell layer with large nerve cells (a), their nuclei (b) and neurofibrils (c) in the cytoplasm. Dendrites emerge from the nerve cells and proceed in different directions. Fine dendritic branches disappear among the nuclei of nerve cells which remain unimpregnated. In the upper right corner and at the bottom of the picture there are nerve cells (d) the processes of which are not impregnated. Their structure is similar to that of the large nerve cells; however, according to some authors, differences in size may indicate differences in function. The vertically running thick nerve fibres (e) bear a large number of varicosities (f). There are numerous fine processes (g) which belong to the arborization system of the dendrites.

Comments on the problem of the "nodulous fibres"

Some authors have described characteristic varicose nerve fibres in the ganglion cell layer called "nodulous fibres". We, too, have seen these fibres and have identified them as elements of the retinal plexiform layer. This fact should be stressed because the cells of origin of the "nodulous fibres" have not been found either in the retina or in the optic nerve. According to our investigations these fibres are axons of the large multipolar nerve cells of the ganglion cell layer; thus, there is no reason to use a special term for their designation. Many "nodulous fibres" can be revealed in some retinas, whereas they are completely absent from other preparations. In a great number of our preparations obtained from bovine retina the characteristic "nodulous fibres" are visible in large numbers. On the other hand, no "nodulous fibres" have been found in the majority of retinas obtained from other animals. The "noduli" are in fact varicosities which are characteristic elements of both the central and peripheral axons.

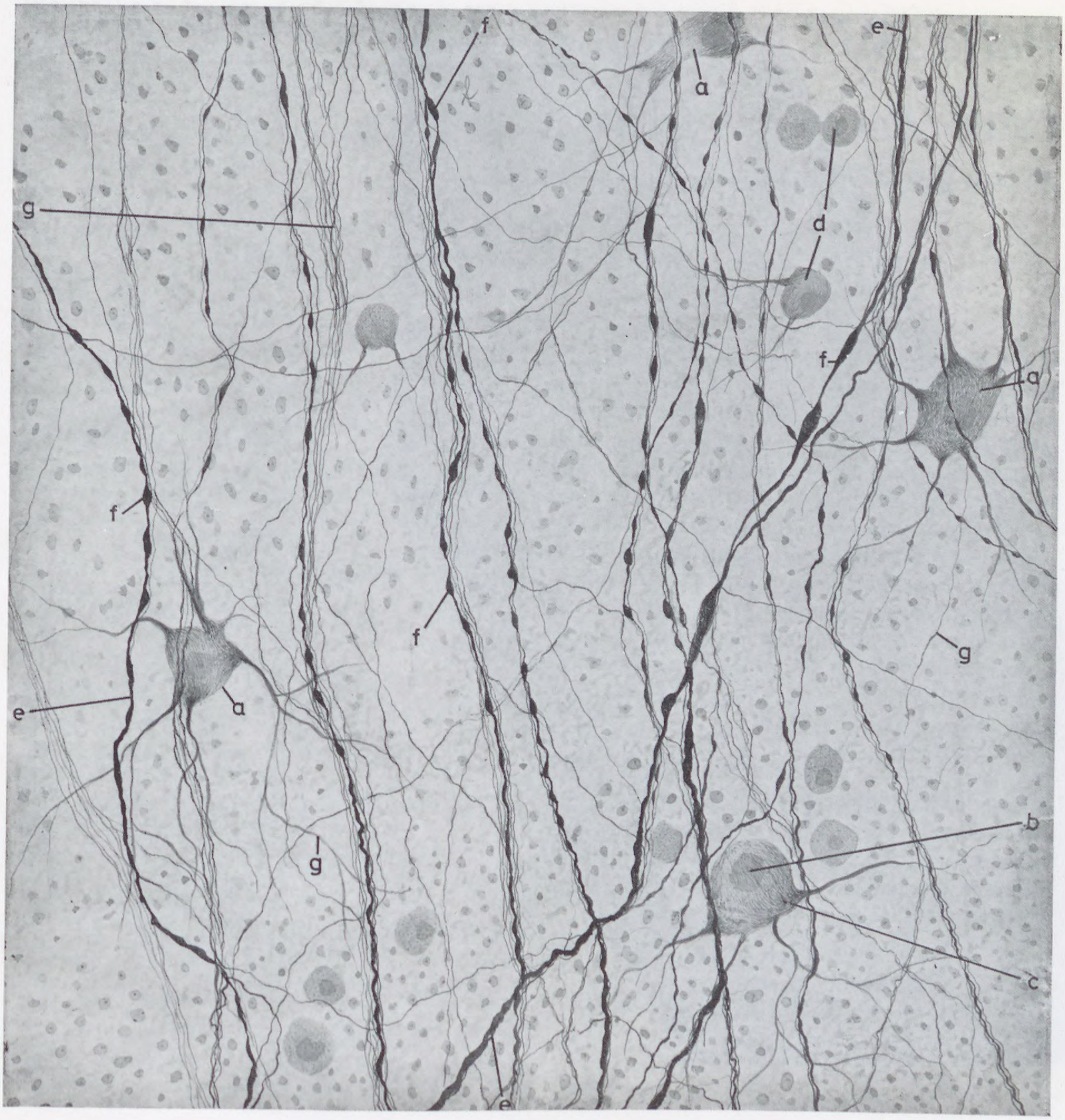
f
a
e
d
g
d
f
a
f
f
g
e
a
g
b
c
e

Plate 193

Cattle *(Bos taurus)* retina

Bielschowsky–Ábrahám silver impregnation

A system of sensory nerve endings in the wall of a terminal branch of the ophthalmic artery. In the ground tissue, i.e. the external lamella (a) of the adventitia, concentrically arranged wavy connective tissue fibres (b) are present in large numbers (mainly on the extreme right and left). The nerve fibres (d) varying in thickness form coil-like networks (e) among the nuclei of connective tissue cells (c). A thick depressor fibre emerges from the network on top to ascend and terminate in an elliptic end-lamella in which well-impregnated neurofibrils (f) form a network.

Comments

On the basis of its localization and structure, this system should be regarded as the pressoreceptor apparatus of the retinal blood vessels. It can only rarely be encountered in histological preparations which may be due to its staining properties.

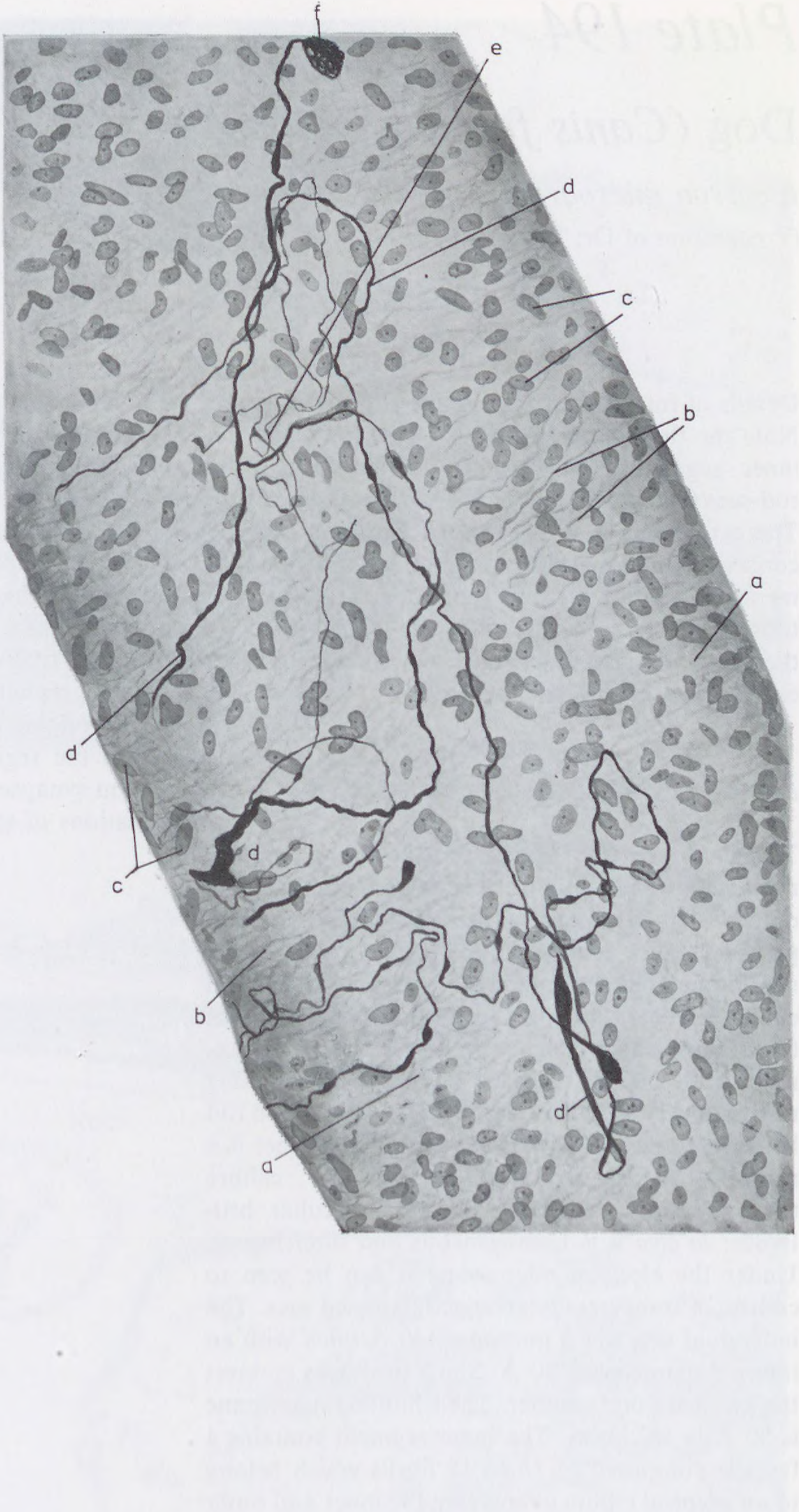
f
e
d
c
c
b
b
a
d
c
d
b
a
d

Plate 194

Dog *(Canis familiaris)* retina

Electron micrograph
(Preparation of Dr. Radnót)

Details of four rods from a retina exposed to light. Note the three outer segments (Ros) (left) and the inner segments (Ris) (right). In the former the rod-sacs (Rs) are limited by the sac membrane (Sm). The cytolemma (Cm), the centriolum (C), and the connecting cilium (Rcc) containing the ciliar filaments (cf) can be identified on the right. Wide cisterns of the endoplasmic reticulum (Er) and, above them, an elongated, cristate mitochondrium (M) can be seen in the inner segment.

Neurohistological comments

The photoreceptors, i.e. the rods and cones, are the most important cellular elements of the retina. The outer (scleral) portion of the rod cell, i.e. the rod proper, is to be found between the external limiting membrane and the pigment layer. Its peripheral end invaginates among the fimbriate processes of the pigmented epithelial cells, while the inner (vitreal) part, having crossed the external limiting membrane, runs to the outer nuclear layer. Each rod has an outer and an inner segment. The former is a smooth-surfaced cylinder, uniform in calibre throughout. Its substance shows a peculiar brilliance; *in vivo* it is homogeneous and birefringent. Under the electron microscope it can be seen to consist of transversally arranged flattened sacs. The individual sacs are 2 μm long, 140 Å thick with an internal diameter of 80 Å. Short processes connect the sacs with one another. Their limiting membrane is 30 Å in thickness. The inner segment contains a fascicle composed of 16 to 18 fibrils which belong to an atypical cilium connecting the inner and outer segments. The basal body of the cilium and a lipid droplet are contained by the peripheral part of the inner segment. Proximally the inner segment contains the myoid. The lipid droplet probably serves as a refracting medium while the myoid, which is filled with mitochondria, maintains contractility. The inner segment of the rod continues in the perikaryon, containing the elongated nucleus. The cytoplasm is thin; it contains a few cisterns of the endoplasmic reticulum, a poor Golgi apparatus, and few mitochondria. The central fibre has a thickened, bulb-shaped terminal part, the spherule. From the outer plexiform layer nerve fibres protrude into the invaginations of the spherule. Synaptic ribbons overlie these invaginations. The nerve fibres entering the spherule (4 to 5 in number) are arborizing dendrites of the bipolar cells. Synapses in the region of the invaginations are called ribbon synapses; the ribbons are located in the terminations of the receptors.

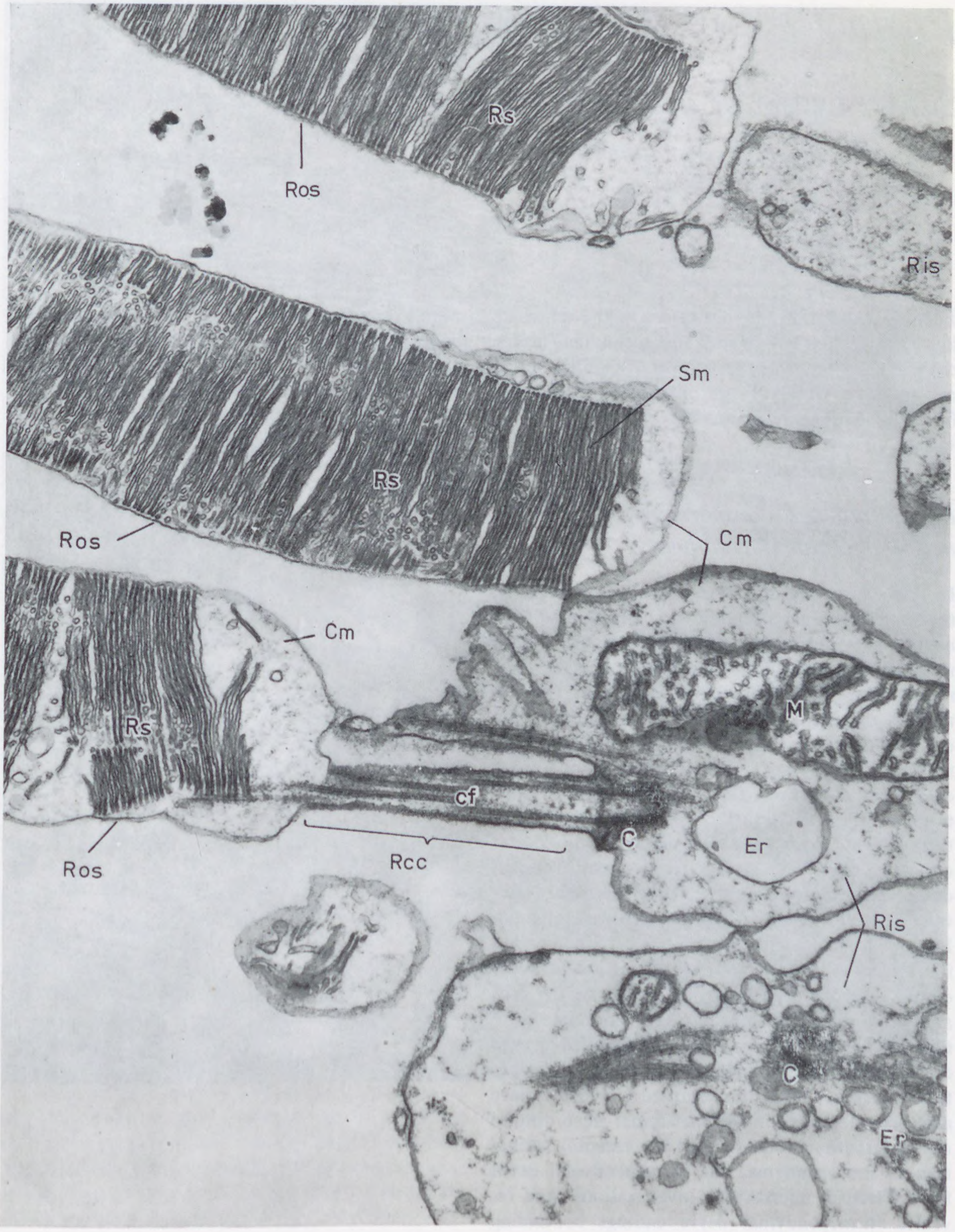
Rs
Ros
Ris
Sm
Rs
Ros
Cm
Cm
M
Rs
cf
Ros
C
Er
Rcc
Ris
C
Er

Plate 195

Sandy lizard *(Lacerta agilis)* ependyma

Ábrahám's silver impregnation

Ependymal cells (b) line both sides of the ventriculus mesencephali (a). Under the ependymal layers there are the inner plexiform layer (c) and the inner nuclear layer (d). Note the intraependymal nerve fibres (e) and nerve endings (f) close to the free surface.

Functional and comparative neurohistological comments

In this species the ependyma covering the wall of the ventriculus mesencephali is richly supplied with nerve fibres similar to those appearing in large numbers in the subependymal areas. These latter run parallel to the wall of the ventricle. A large number of nerve fibres enter the ependyma; some of them course parallel to the lumen while others run perpendicularly. The former contact numerous ependymal cells along their course while the latter terminate close to the surface. There is no doubt that these fibres, which have been described in several other species as well, are the receptors of the ependyma. They most probably inform the higher centres about the pressure of the cerebrospinal fluid. Intraependymal nerve cells have been demonstrated in different animals. Some authors regard the ependymal cells phylogenetically analogous to the rods and cones of the retina. It has been maintained that the cells of the rods and cones are epithelial cells containing intraepithelial nerve fibres. Complicated terminal nerve formations regarded as receptors have also been described in the ependyma. According to our observations there is only one receptor formation in the ependyma: the intraependymal nerve fibre. Electron microscopic investigations have revealed intraependymal nerve endings containing conventional and dense-core vesicles. The former can be identified as synaptic vesicles and the latter probably contain catecholamines. Special nerve cells, whose processes pass through the ependyma, assume a bulb-like form, and terminate freely on the surface. Such cells have been found in the wall of the fourth ventricle and in the central canal of rabbits. The bulbs are loaded with mitochondria. The nerve cell located hypependymally may be regarded as a neurosecretory cell. It can be assumed that the secretory products synthesized in the perikaryon accumulate in the bulbs and are released gradually into the cerebrospinal fluid.

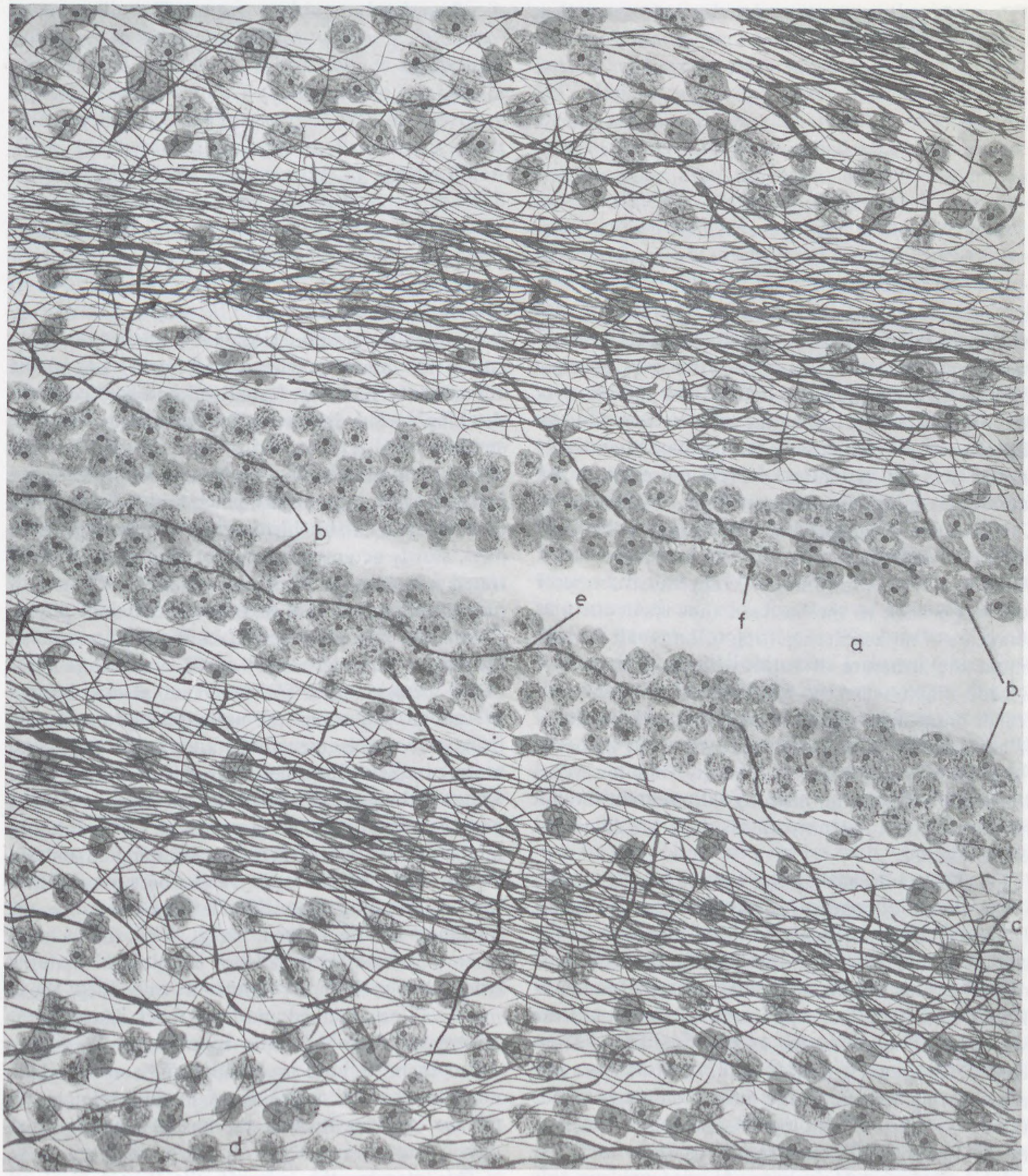
b
e
f
a
b
c
d

Epilogue

It is more than fifty years now that I have been investigating the structure of the nervous system. Even as an undergraduate I found the nervous system – almost neglected in the courses that time at the university – particularly fascinating. My interest in the nervous system was even more increased later when I became lecturer at the Institute of Comparative Anatomy and Histology at the University of Budapest. But just to be able to start studying this extraordinarily complex structure, I had to go back to the basics. I thus spent the first ten years of my research getting to know all I could about the structure of various kinds of tissues. A decade might seem too long; but if one wants to feel at home in comparative anatomy and histology, if he wants to be at all familiar with that immense "regnum animale", he will hardly find ten years too much to spend on histological research, though he devotes to it not only all his days, but also most of his nights.

I was fortunate during this time to be the instructor in charge of conducting the histology practicals. I devised these practicals so that, over a given period, I would have the opportunity to study each of the various organs in a great variety of animals. I thus had plenty of opportunity to compare the structure of these organs as they are found from the Coelenterata right up to man. It was, I must say, a pioneering venture of the most absolute kind, for there was then no histological research to speak of at the Institute of Comparative Anatomy and Histology, Budapest University. As students, we only acquired a rudimentary knowledge of the various types of cells and of the basic tissues. There was neither the requisite equipment nor the necessary experience for the more sophisticated studies. To try to master histology under these conditions was a challenge indeed!

To start with, I fixed and embedded all the available organs of a variety of invertebrates and vertebrates, preparing and staining sections for the students as required. It was when I walked around to see how they were doing that I selected the specimens that fitted in with what I myself was working on at the moment. I analysed and studied these checking in the literature for whatever was new to me.

The method proved a success. The students enjoyed the histology experiments, and I, having studied all the available histological literature of those days, slowly acquired a series of slides which illustrated not only the development and perfection of individual organs, but also the processes of phylogenesis. As regards the animals, the picture seemed satisfactory enough; but I could not help asking: "Quo usque tandem?" There had always been a process of evolution; the animal kingdom started from the simple structures and grew more and more complex. But where was the beginning – and where is the end? If there was development in the past, it must still be going on today and will go on in the future, for there is no stopping in nature. Where, then, is life heading, and where man? There was no stopping now – I had to get to know the histology of the human body. With the help of some physician friends, I got histological material from all the human organs; I embedded them, made sections, stained and fixed them. Through the systematic study of these specimens – my friends called them "school preparations" – and the assiduous study of all the Hungarian and foreign books on the subject, I came to master human histology.

This step-by-step, comparative histological research, then, gave me a picture of the world of histology as it was then known; but it was a picture that was lacking the most essential element – the engine that kept it going, that gave it its direction and rationale: the nervous system. Yet it was this that I wanted most of all to understand in all its manifestations.

The very attempt to do so was frought with grave obstacles; not in the whole Institute was there to be found a single preparation showing a single neuron or nerve fibre. There was nothing to be done for it, but to set to work and go through the painful process of trial and error. I had neither equipment, nor a colleague whom I could turn to for help in working out the methodology. I was on my own. Then, good fortune brought an Estonian scientist to the Institute. He was investigating species differences in the black rat and the Norway rat through comparing their genital organs. At this stage, he wanted to understand the development and connections of the nervous system. Now there were two of us working. We tried everything recommended in all the available – mainly Hungarian – books, but after a year, we had got next to nowhere. I decided to try another tack – to go abroad to study the methods of neurohistology there. I decided on a trip to Germany, hoping there to meet two outstanding scientists: Franz Maurer, Professor of Comparative Anatomy at the University of Jena; and Rudolf Krause, Professor of Anatomy at the University of Berlin.

I went to find Maurer in the hope that I might see the slide from which he had drawn the picture in his book "*Die Epidermis und ihre Abkömmlinge*", showing a nerve fibre connected to the "macula tactus" cells in the skin of the frog. I wanted to ask him about the technique he had used to stain the section. Accordingly, after visiting the Zoological Institute of the University of Jena, the Phyletisches Museum, and the Haeckel Museum, I went to Maurer in the Anatomical Institute and asked him to show me the preparation drawn in his book. I remember his answer to this day: "Ich habe es leider schon nicht mehr". This slide no longer existed and I had to leave the Institute of Anatomy empty-handed, although I had been received most cordially by Maurer, and had been showed everything there was to see.

There is something else about Maurer – more precisely, Maurer and Haeckel – that is worth mentioning. Perhaps it is nothing very extraordinary, but it always comes to my mind whenever I wonder about the sense of life, its origin, present and future. When I visited the Haeckel Museum set up in Haeckel's cottage at the edge of town in the so-called *Kartoffel-feld*, on Haeckel's large desk, cordoned off, I saw Haeckel's beautiful drawings, the pencils and paints he used, and the fine magnifying glasses he used in drawing his brilliant *Die Kunstformen der Natur*. I also saw there the black broad-rimmed hat he liked to wear, called *Schöpfungsgeschichte Hut* at that time. The history of this designation is that, when Haeckel's *Welträtsel*, describing his theory of the origin of life, was published, a Japanese hatmaker became so enthusiastic over the book that he sent Haeckel a whole case full of hats. What I'm coming to, however, is this: on Haekkel's desk, I saw a big, heavy book entitled: *Das Gehirn von Ernest Haeckel*. Haeckel, who was on friendly terms with Maurer, had asked him to analyse his brain after his death. Maurer was all the more inclined to grant this request as it was generally known that Haeckel was a man of genius. Maurer therefore investigated the brain with particular care and interest, both anatomically and histologically. Maurer's book contained the pictures of Haeckel's brain, and the conclusion that morphologically, the brain showed no trace at all of creative genius. In the final analysis, Haeckel's brain was like that of any other very old man: it was an atrophic, sclerotic and contracted brain, showing no anomaly or special feature at all. There was nothing either in the nerve cells or in the nerve fibres to indicate creative genius.

After studying everything in Jena that I thought worthwhile and necessary, I left for Berlin in order to examine there, too, the state of research in the field of neurohistology. I did this because I knew Krause as a good histologist. I thought him just the man to investigate the nervous system, for he had great experience in using the appropriate methods. Krause gave me a friendly reception, but he lost no time letting me know that, unfortunately, he could show me nothing, having already packed for his holidays. In any case, he said, the season was not suitable for staining nerves with vital methylene blue; I should come another time, if possible, next April. I thanked him for seeing me and for the good advice, and started for home having decided never to return again. There was nothing left for me to do, but to experiment laboriously and to wait patiently. And my professor had already given me a task: to find the genital bodies in the phallus of lizards, for this may be very useful for understanding the ways of phylogeny.

I worked on the subject for about a year. When I began working, my professor had said: "Solve this problem, and you will at once become a well-known histologist". Delighted at the prophecy, I set to work with great diligence. But when, after a year, I reported that I had achieved nothing, and could observe no nerve fibres whatsoever in any of my preparations, he only retorted: "How could you expect to solve this problem? I have worked on it for three years with no result at all". It was a back-handed compliment if ever there was one! And from my boss, to boot! It was, perhaps, one of the greatest slaps in the face that I ever got from life.

But it was late July, and in the first days of August I went home to county Csik, where bubbling brooks and the sight of the wind in the pines eased the disappointment and disillusionment that had almost worn me down.

On returning from the country, I again surveyed my preparations and – to my astonishment – found what I had been looking for. The nerve fibres, as well as the nerve terminals, were there. With the enthusiasm of a beginner, I looked through all my preparations, only to find that, as a result of the gold impregnation I had made, the nerve fibres and nerve terminals were clearly visible in the epithelium. When I was certain of success, I reported my findings to the professor and submitted my preparations. Though he was no specialist in this field, he was supportive, and suggested I report my findings in a paper he would recommend for publication in *Természettudományi Értesítő* (Communications in Natural Sciences), a journal of the Hungarian Academy of Sciences. This I did, and to my no small pleasure, the results of my first neurohistological investigations appeared in print. As most beginners, I was inspired by the printed words to redouble my efforts. The procedure I had worked out proved inadequate in several respects, but it was very suitable, for instance, for visualizing the motor endplates in the blindworm *(Anguis fragilis)*. This, of course, was no great novelty, but it whetted my interest in the histology of the nervous system. I turned to investigate the nervous system of a worm *(Opisthodiscus diplodiscoides)*, as part of the Institute's work project. Subjecting the animal to almost all the known forms of vital methylene blue staining and to Golgi's rapid impregnating procedure I finally revealed both its central and peripheral nervous systems.

It was the success of the investigations carried out with methylene blue which drew my attention to the shrimps *(Gammarus roeseli, Niphargus puteanus)*. I was interested primarily in their exteroceptors for the staining of which I had worked out a successful procedure. By that time, my results were being published in different journals at home and abroad; then something happened through which I became thoroughly familiar with the peculiarities of the methods of silver impregnation. An old bear had to be killed at the Budapest Zoo; some acquaintances helped me get small pieces of the bear's skin and tongue. These I fixed in formalin. I would have needed a freezing microtome, to make sections, but I had none. At last I found out that there was one at the University Department of Dermatology, with which I made my sections. In fact, I had to go begging not only for instruments, but for usable chemicals, too. Finally, I succeeded in making an impregnation according to the Bielschowsky–Gros method. The nerve fibres and nerve terminals became visible both in the skin and the tongue. My conviction of the novelty and importance of the work I had started was reinforced by something the Head of the Department of Dermatology said to me: "I have been heading this Department for 25 years, and all this time I could never display a Meissner corpuscle because there was nobody to make such a preparation."

Later, I became interested in the intestinal tract. I tried to show its neural connections and mainly its synapses in leeches. I was all the more drawn to these investigations as my predecessor, István Apáthy, had taken much trouble with the intestinal nervous system of these animals. Having worked out a procedure using gold salts, he was the first to stain the intestinal nervous system of a kind of leech *(Pontobdella muricata)*, thereby presenting evidence to support the theory of continuity as opposed to the neuron theory (contiguity). Since experiments using silver impregnation on different leeches yielded no support for a strong stand against the continuity theory, which I was convinced was wrong, I began to investigate the intestinal tract of Gastropoda *(Helix pomatia, Arion empricorum)*, using various forms of Bielschowsky's procedure. I succeeded in proving that Apáthy's interpretation of the pictures he got of the intestinal tract of *Pontobdella muricata* was wrong. He had thought that the thin neurofibrils in the nerve fibres supplying the muscular layers of the intestines pass from one nerve cell to the next one without interruption. He thus thought that the main elements of the nervous system were the neurofibrils interconnecting the nerve cells into a continuous nervous system. I myself had never found evidence of this; in fact, in the impregnated preparations deriving from the intermuscular layers of the intestinal tract of the snail *(Helix pomatia)* I did not see any nerve fibrils passing through the nerve cells. I attributed Apáthy's theories then (as I do now) to the fact that he took for "neurofibrils" the bundles of nerve fibres running above or below the nerve cells, but which may appear to pass through the very body of the cells. The serial sections made of my most perfectly impregnated preparations disproved these appearances completely. I thus became a neuronist, trusting the results of my own investigations, and defending this standpoint for thirty years against those who, following Apáthy, maintained the theory of continuity.

That I became and remained a neuronist was due not only to my findings on the nerve cells of the intestinal tract. Interested as I was in the entire nervous system, my approach was always comparative, with a view to the gradual perfection of each system. From the beginning I was preoccupied with the thought of how the nervous system – the forerunners of which can be seen in the form of neuronemata in some higher unicellular animals, e.g. the Ciliata – had evolved in the course of phylogeny, how it became more and more perfect, a unique complex structure eventually giving rise to consciousness, which governs the world, kindles light in darkness, links Earth with her sister planets, and dares assault the sky.

I thus continued my investigations of the nervous system of the intestinal tract on various invertebrates, on fish, on Amphibia, on birds, on mammals, and finally on man. The neurohistological pictures obtained here, contained a great number of ganglia and led me to examine the autonomic nervous system. I looked for synapses in the autonomic ganglia and in the smooth muscle tissue of almost all multicellular animals. Getting a clear picture of the structure of both the paravertebral ganglia and the intramural plexuses proved an exciting job indeed. But most exciting and most laborious was the job of finding the connection between smooth muscle tissue and autonomic nerve fibres. Practically everyone dealing with this question during the past forty years has maintained that here the neuron theory is not valid: the nerve fibres innervating the smooth muscle cells were thought to have no visible terminals or at most only an extremely fine network *("Terminalretikulum")* that did not merit the name "terminal". In all the world practically I alone disputed this conception, simply because I had never seen a terminal reticulum either in my own preparations or in those studied in different Institutes abroad. Besides, I regarded it a necessary organizing principle that a process growing out of a nerve cell terminate somewhere.

I must confess that I myself had seen synapses of the autonomic nerve fibres but very rarely, and even then, the number of terminal enlargements found was very small for the size of the area investigated. Nevertheless, I held fast to my opinion. That I was right to do so has been definitely confirmed by electron microscopy. These investigations have shown that nerve fibres synapse with the smooth muscle cells in the same way as they do with other tissues. Unfortunately, however, I myself had the equipment to see this for myself only some time after others had confirmed my earlier results with the use of the electron microscope.

It was the problems that arose in the course of my investigating the peripheral part of the autonomous nervous system that led me to study the adrenal gland. The adrenal is close to the autonomic nervous system both structurally and evolutionally. I thoroughly examined the innervation of the medullary substance of the adrenal gland in all the vertebrate classes. I established, mainly by studying different birds and mammals, that the nerve plexuses, richly infiltrating the medullary substance of the adrenal gland of reptiles and birds in particular, are connected to the cells of the adrenal in the form of end-bulbs. I found evidence of this not only using the light microscope, but more recently, in the course of investigating the adrenal gland of the green toad (*Bufo viridis* Laur) with the electron microscope, I saw that the nerve fibres reach the cytoplasmic membrane of the cells in the form of typical synapses, in the way generally characteristic of axosomatical synapses.

In investigating the autonomic nervous system, I did not overlook nerve cells either. Starting with leeches *(Hirudo medicinalis)* I investigated each single nerve cell and nerve-cell association in the region of the intestinal tract. I studied the connections between cells, between nerve cells and the nerve fibres terminating in the vicinity of the cells, as well as the connection between the processes of the nerve cells and the adjacent or remote tissue elements. I investigated the ciliary ganglion in all the vertebrate classes, with particular regard to synaptic connections. I also investigated the paravertebral ganglia in all the vertebrate classes, as well as the celiac ganglion, the superior mesenteric ganglion, and the inferior mesenteric ganglion in mammals. I established that some of the preganglionic fibres entering the autonomous ganglia terminate on the body of nerve cells in the form of end-rings, while other nerve fibres surround basket-like the body of nerve cells.

In the course of investigating the structure of the autonomic nervous system and the forms of its connections, I got to the blood vessels. During the past 20 to 25 years, I have studied the nerve connections of the adventitia, and have investigated the forms of terminal connections of the nerve fibres in the smooth muscle cells of the media, I wanted to get both overall and detailed pictures of the connections between smooth muscle cells and nerves that were convincing. Besides the nerve plexuses in the adventitia, the afferent elements of normal vascular reflexes, I was particularly interested in the special and extremely complicated sensory terminals present in large numbers in a few sectors of some blood vessels. These terminals are known as baroreceptors or pressoreceptors. They are sensitive to sudden increases in blood pressure, and it is their function to reduce it reflectorically and generally. I also spent much time on the peculiar chemoreceptors similarly located in the wall of blood vessels. It is known that these respond to changes in the oxygen and carbon dioxide content of the blood.

The comparative neurohistological study of the vascular system led me to the systematic, comparative investigation of the heart, the central organ of circulation.

My students and I began the systematic investigation of the various layers of the heart in fishes, in frogs, reptiles, birds, mammals, and finally in man. These investigations lasted for many years. I reported on our results in several publications, then I summarized them in a monograph *(Die mikroskopische Innervation des Herzens und der Blutgefässe von Vertebraten*, published by Akadémiai Kiadó, Publishing House of the Hungarian Academy of Sciences, in 1964). In 1969 a second, enlarged English edition was published jointly by Akadémiai Kiadó, Budapest and Pergamon Press, Oxford, with the title: *The Microscopic Innervation of the Heart and Blood Vessels in Vertebrates Including Man.*

Since I was interested in the nervous system as a whole, my attention was bound finally to concentrate on the central nervous system. Guided by my fundamental conception, I endeavoured to analyse the differences in the structure, modifications and connections of the neurons in various animal groups. With this in mind, I investigated the nervous system of Turbellaria *(Dendrocoelum lacteum, Planaria alpina)*, annelids *(Lumbricus terrestris, Hirudo medicinalis)*, insects *(Dytiscus marginalis, Hydrophilus piceus, Gryllus campestris, Gryllotalpa gryllotalpa, Acrida hungarica, Diestreammena marmota)*, molluscs *(Helix pomatia, Aplysia california, Anodonta cygnea)*. In addition to these, of course, I also looked at some vertebrates. We examined some parts of the brain of bony fishes such as the carp *(Cyprinus carpio)* and the goldfish *(Carassius carassius)*. We investigated the entire brain of various frogs *(Rana ridibunda, Rana esculenta)*, tortoises *(Emys orbicularis)*, lizards *(Lacerta taurica, Lacerta agilis)*, snakes *(Natrix natrix)*, birds *(Gallus domesticus, Anser domesticus)*, some mammals *(Talpa europaea, Cavia cobaya, Rattus rattus, Canis familiaris, Sus scrofa domestica, Bos taurus)*, and man. In these investigations, what we were mainly interested in, was the problem of synapses, and phylogeny. As for the synapses, in invertebrates (insects and molluscs) we found several forms of synapses that differed essentially from those held to be fundamental to the transfer of impulses in vertebrates. On the other hand, in vertebrates the synaptic characteristics proved on the whole to be uniform. As for our phylogenetic findings, we became convinced that every nerve cell is essentially of the same form, whether in the brain of a flatworm or in any layer of any brain section of a highly developed mammal. The shape of the cell, the structure of the cytoplasm, the form of the nucleus, the cytoplasmic organelles are the same everywhere, and they are even similar in their size, form and location. Phylogeny, however, reveals the road to perfection. The connections of the nerve cells with the external world, the development and perfection of the dendrites, the increasing complexity of the ramifications and of the terminal systems lead up to man, where the most complicated and most refined forms of the dendritic terminal system can be found which are quite unique in their situation and structure.

In order to see the morphological bases of nerve-cell activity more clearly, for the past ten years I have been following neurosecretion with some attention. I must admit that for many years I took a negative stand on neurosecretion. I could not imagine that a cell which is structurally a nerve cell could at the same time be a glandular cell. To find out the facts, I asked some acquaintances dealing with neurosecretion for some preparations. These sections, originating from mammalian brains, I carefully investigated but I was unable to find any sure sign of neurosecretion. Later, I discovered that the true site of neurosecretion is the brain of insects. I turned to look at beetles, primarily to the European predacious diving beetle *(Dytiscus marginalis)* and the water scavenger beetle *(Hydrophilus piceius)*; here, I found definite proof of the existence of neurosecretion. In the forebrain of insects, thus in the forebrain of *Dytiscus marginalis*, too, right and left of the midline, there is a cell group consisting of 15 to 20 unipolar large-sized cells, the rounded cell bodies of which produce great amounts of neurosecretion that can be stained well. I also found that the secretion is transported from the brain through pathways crossing in the middle region of the brain, and is stored in the corpus cardiacum and corpus allatum, from where, through the intervening haemolymph, it spreads in the body. From my own preparations, I have been convinced that in the diencephalon of vertebrates, too, there are some cell groups (paraventricular and supraoptic nuclei) which produce neurosecretory granules. I have succeeded in tracing the structure and activity of the paraventricular nucleus in the brain of the carp, and the structure and connections of the supraoptic nucleus in the diencephalon of horseshoe-bats *(Rhinolophus ferrum-equinum)*. At present, I am involved in the comparative investigation of the nervous system using the electron microscope, with special reference to the cerebral cortex of Sauropsidae, and to the receptors of the cardiovascular system, the sense organs, and the common integument.

Now, as I run my eyes over the huge map of the nervous system, with more than 55 years of research behind me, I should like to emphasize two facts. One is that the neuron is perfectly the same in form and structure in the central nervous system of the lowest worm and in that of man. The only difference there is, is indicative of development and perfection: the increasing complexity of axons and dendrites, and the growing regional and structural refinement of the terminal systems. These are marks that, as we advance in phylogeny, show the upward path of transformation and development. The other fact is that the morphological bases of nerve conduction are the same everywhere. This process is connected with synaptic vesicles and neurosecretory granules. It is these that carry out the immense and complex job generally spoken of as the "function" of the nervous system.

I should have liked to publish everything expounded in this book in a larger monograph, much more systematically and in greater detail. Since, however, much of my activity has been devoted to the investigation of the structure of receptors, I have summarized this problem in this book, hoping thereby to cast light on the paths of development and phylogenesis as well.

In conclusion, I should like to say something on the question of whether biology gives one who has devoted his life to studying it a Weltanschauung indicative of the direction to be followed. Beyond doubt, it does. The interpretation it offers, however, is far from satisfactory, as it leaves the beginning and the end unaccounted for, and can respond to the question "why" only with another "why". Yet, if there is in this biological approach anything of comfort, it is the thought of oneness and of eternity. Matter is one and so is energy, and both are eternal, changing only in form. The laws of nature are one; they apply to living and non-living alike. There is no "cause", only "*causes*". These are unknown, and if one or another is discovered, it is only to set us looking for its own causes: "*Malo me Galathea petit lasciva puella, fugit ad salices et se cupit antevideri*". Truth flees before us like Galathea, the perfidious girl throwing apples in Virgil's *Eclogue*, and escapes us like the horizon receding from the weary wanderer.

Bibliography

Ábrahám, A.: A gyíktüdő idegvégződései (Nerve terminals of the lizard lung). *Magy. Tud. Akad. Math. Term. Tud. Ért.* **44,** 2–16 (1927).

— Az *Opisthodiscus diplodiscoides nigrivasis* Méhelyi idegrendszere (Das Nervensystem von *Opisthodiscus nigrivasis* Méhelyi). *Studia Zool.* **11,** 136–157 (1929).

Ábrahám, A. and Wolsky, A.: Über die Nerven und Nervenendigungen der Antennen einiger Landisopoden. *Zool. Anz.* **84,** 316–323 (1929).

Ábrahám, A. and Wolsky, A.: Die Geruchsorgane der Landisopoden. *Zschr. Morphol. Ökol. Tiere* **17,** 441–463 (1930).

Ábrahám, A.: Neue sensible Endorgane in der Zunge des braunen Bären. *Z. Zellforsch.* **11,** 609–614 (1930).

— Az archeo- és neolacerták combmirigyeiről (Über die Schenkeldrüsen der Archeo- und Neolacerten). *Studia Zool.* **1,** 204–252 (1930).

— Die Nervenendorgane der Hundeschnauze. Atti dell XI. Congresso Internazionale di Zoologia. *Arch. Zool. Ital.* **16,** 717–731 (1930).

— Über das sensible Nervensystem der Amphipoden. *Zool. Anz.* **92,** 273–282 (1930).

— Über die Innervierung des Verdauungstraktes einiger Knochenfische. *Magy. Biol. Kutató Int. I. Oszt. munkái.* 1933, pp. 6–12.

— *Újabb adatok az elefántormány idegvégszerveinek ismeretéhez* (Neuere Beiträge zur Kenntnis der Nervenendorgane der Schnauze von *Elephas indicus*). A Szt. István Akad. Ért. 14, Budapest, 1934.

— Beiträge zur Kenntnis der Innervation des Vogeldarmes. *Z. Zellforsch.* **23,** 737–745 (1936).

— Über die Innervation der Gaumenschleimhaut. *Extrait des Comptes Rendus du XII^e^ Congrès International de Zoologie, Lisbonne,* 1935. Lisboa, 1936, pp. 375–391.

— Über die mikroskopische Innervation der Gaumenschleimhaut der Frösche. *Z. Zellforsch.* **27,** 745–753 (1938).

— Die Innervation des Darmkanals der Gastropoden. *Z. Zellforsch.* **30,** 273–296 (1940).

— Gibt es Nervennetze? *Z. Zellforsch.* **30,** 321–322 (1940).

— Die Sinusgegend des menschlichen Herzens und ihr Nervensystem. *Z. Zellforsch.* **31,** 146–155 (1940).

— Az emberi glomus caroticum idegrendszere (Über das Nervensystem des Glomus caroticum bei Menschen). *Acta zool. Univ. Szeged* **1,** 1–50 (1942).

— Az ember nyelvének érző idegvégszervei (Sensory nerve terminal organs of the human tongue). *Állattani Közl.* **40,** 15–22 (1943).

— Idegvégtestek az arteria renalis falában (Nerve terminal bodies in the wall of the renal artery). *Állattani Közl.* **40,** 242–252 (1943).

— Beiträge zur Kenntnis der sensiblen Endorgane der Sinusreflexe von Hering. *Z. Zellforsch.* **34,** 208–229 (1949).

— Receptors in the wall of the blood vessels. *Acta biol. Acad. Sci. hung.* **1,** 157–175 (1949).

— The endings of the nervus acusticus in the labyrinth of the carp. *Z. Zellforsch.* **35,** 396–424 (1951).

— Further investigations on the structure and the endings of the nervus depressor in man. *Acta biol. Acad. Sci. hung.* **1,** 165–178 (1951).

— The comparative histology of the stellate ganglion. *Acta biol. Acad. Sci. hung.* **2,** 311–354 (1951).

— Az aortaideg szerkezete és végződésformái a kutya arteriás törzseiben (Structure and terminal forms of the aortic nerve in the arterial trunks of the dog). *Annal. Biol. Univ. Hung. Pars Szegediensis* **1,** 325–340 (1952).

— Studies on the location and structure of the receptors of Goltz's clasping-reflex. *Acta biol. Acad. Sci. hung.* **3,** 365 – 377 (1952).

Ábrahám, A. and Stammer, A.: Pressoreceptoren in der Wand der Schwimmblase. *Annal. Biol. Univ. Hung. Pars Szegediensis* **2,** 345–360 (1952).

Ábrahám, A.: Die Innervation der Blutgefässe. *Acta biol. Acad. Sci. hung.* **4,** 69–160 (1953).

— Blood pressure and peripheral nervous system. *Acta biol. Acad. Sci. hung.* **4,** 307–365 (1954).

— Microscopic innervation of the cornea with reference to the neural connections of the fibrocytes. *Acta biol. Acad. Sci. hung.* **6,** 31–76 (1955).

— Über die Stelle und Struktur der Rezeptoren im Aortenbogen des Rindes. *Acta biol. Univ. Szeged* **1,** 125–159 (1955).

Ábrahám, A. and Sin, L.: Microscopic innervation of fixed vascular grafts. *Acta morph. Acad. Sci. hung.* **5,** 103–112 (1955).

Ábrahám, A.: Über die Probleme in der Histologie des vegetativen Nervensystems. *Acta biol. Univ. Szeged* **2,** 111–135 (1956).

— Über die Struktur und die Endigungen der Aorticusfasern im Aortenbogen des Menschen mit Berücksichtigung der Cholinesterase-Aktivität der Pressoreceptoren. *Z. mikr.-anat. Forsch.* **62,** 194–228 (1956).

— Die mikroskopische Innervation des Vogelherzens. *Acta biol. Univ. Szeged* **3,** 247–273 (1957).

Ábrahám, A. and Erdélyi, L.: Über die Struktur und die Innervation des Reizleitungssystems im Herzen der Säugetiere. *Acta biol. Univ. Szeged* **3,** 275–308 (1957).

Ábrahám, A. and Minker, E.: Innervation of the lamellibranch muscle. *Nature (Lond.)* **180,** 925–926 (1957).

Ábrahám, A. and Minker, E.: Über die Innervation des Darmkanals des medizinischen Blutegels (*Hirudo medicinalis*). *Z. Zellforsch.* **47**, 307–311 (1958).

Ábrahám, A: Die mikroskopische Innervation der Niere des *Varanus griseus* Daud. *Z. mikr.-anat. Forsch.* **64**, 296–320 (1958).

— Beiträge zur Kenntnis der Interoreceptoren im Bereiche des cardiovaskulären Systems. *Acta biol. Univ. Szeged* **4**, 179–202 (1958).

Ábrahám, A.: Zur Frage der interneuronalen Synapsen in den vegetativen Ganglien. *Z. mikr.-anat. Forsch.* **65**, 574–581 (1959).

Ábrahám, A. and Erdélyi, L.: Localization of acetylcholinesterase in the cardiac conducting system of Ungulata. *Acta morph. Acad. Sci. hung.* **8**, 403–414 (1959).

Ábrahám, A. and Horváth, I.: Über die mikroskopische Innervation des Herzens von Süsswasserknochenfische. *Z. mikr.-anat. Forsch.* **65**, 1–20 (1959).

Ábrahám, A. and Minker, E.: Experimentell-morphologische Untersuchungen über die Innervation der Schliessmuskeln von Süsswassermuscheln. *Z. Zellforsch.* **49**, 638–654 (1959).

Ábrahám, A. and Minker, E.: The role of ganglions in the motility of bivalve shells. *Acta biol. Acad. Sci. hung.* **9**, 219–227 (1959).

Ábrahám, A. and Stammer, A.: Experimentell-morphologische Untersuchungen über die Innervation der Augenmuskeln von Fröschen. *Z. mikr.-anat. Forsch.* **65**, 582–594 (1959).

Ábrahám, A. and Stammer, A.: Untersuchungen über die Struktur, die mikroskopische Innervation und die Cholinesteraseaktivität der Nebenniere von Vögeln. *Acta biol. Univ. Szeged* **5**, 85—95 (1959).

Ábrahám, A.: Morphologische Grundlagen der nervalen Nierenregulation. In: *Nierenfunktion und Nervensystem.* VEB Verlag Volk und Gesundheit, Berlin, 1960, pp. 3–38.

— Zur Kenntnis der Struktur der Netzhaut, mit besonderer Berücksichtigung der Ganglienzellenschicht. *Z. Zellforsch.* **52**, 529–548 (1960).

— A szív beidegződése (Innervation of the heart). *Magy. Tud. Akad. Biol. Orv. Tud. Oszt. Közl.* **12**, 207–244 (1961).

— Die mikroskopische Innervation des Herzens der Amphibien. *Acta biol. Univ. Szeged* **7**, 45–64 (1961).

— Struktur und Endigungsformen der Fasern des Nervus aorticus im Aortenbogen des Schweines. *Z. mikr.-anat. Forsch.* **67**, 409–426 (1961).

— Die mikroskopische Innervation des Herzens der Reptilien. *Acta biol. Univ. Szeged* **7**, 95—107 (1961).

— Considerations about the structure and function of the baroreceptors in the arterial trunks of mammals. *Symposium Theriologicum, Brno*, 1960. Praha, 1962, pp. 21–26.

— Die Nervenversorgung der Kranzgefässe des Herzens. *Arch. int. Pharmacodyn.* **139**, 17–27 (1962).

Ábrahám, A.: Die intramurale Innervation des Vogelherzens. *Z. mikr.-anat. Forsch.* **69**, 195–216 (1962).

— Über die Struktur der Ganglien des Säugetierherzens. *Acta biol. Univ. Szeged* **8**, 121–134 (1963).

— The structure of the interneuronal synapses in the visceral ganglion of Aplysia. *Acta Anat.* (*Basel*) **54**, 260–264 (1963).

— Receptoren in der Sklera. *Anat. Anz.* **113**, 317–331 (1963).

— *Die mikroskopische Innervation des Herzens und der Blutgefässe von Vertebraten.* Akadémiai Kiadó, Budapest, 1964.

— Über Lage und Struktur der Synapsen im Herzen der Sumpfschildkröte (*Emys orbicularis*). *Acta biol. Univ. Szeged* **10**, 79–86 (1964).

— Die Struktur der Synapsen im Ganglion viscerale von *Aplysia californica*. *Z. mikr.-anat. Forsch.* **73**, 45–59 (1965).

— The structure of the synapses in the heart of the European pond turtle (*Emys orbicularis*). *Symp. Biol. Hung.* **5**, 69–83 (1965).

— Endokrine Systeme im Gehirn des Schwimmkäfers (*Dytiscus marginalis*). *Acta biol. Univ. Szeged* **11**, 245–255 (1965).

Ábrahám, A.: Silberverfahren zur Impregnation der Elemente des Nervensystems. *Z. wiss. Mikr.* **67**, 183–189 (1966).

— The influence of environmental factors on the neurosecretory activity of the water beetle (*Dytiscus marginalis*). *Rev. Roum. Biol. Ser. Zool.* **2**, 25–33 (1966).

— Neurosecretory activity in the brain of the water beetle (*Dytiscus marginalis*). *Acta Anat.* (*Basel*) **65**, 435–466 (1966).

— Phylogenesis of the nerve cell. In: R. Hassler and H. Stephan (eds): *Evolution of the Phylogenesis and Ontogenesis of the Forebrain.* Georg Thieme Verlag, Stuttgart, 1966, pp. 259–270.

— Nerve supply of the adrenal gland. *Acad. Sci. Bulg. V. Symposium Histologicum Internationale.* Sofia, 1966, pp. 289–304.

Ábrahám, A. and Stammer, A.: Über die Struktur und die Innervierung der Augenmuskeln der Vögel unter Berücksichtigung des Ganglion ciliare. *Acta biol. Univ. Szeged* **12**, 87–118 (1966).

Ábrahám, A.: Die Struktur der Gehirnzentren des Gelbrandkäfers (*Dytiscus marginalis* L.) *Z. mikr.-anat. Forsch.* **76**, 436–465 (1967).

Ábrahám, A.: The structure of baroreceptors in pathological conditions in man. In: *Baroreceptors and Hypertension. Proc. Int. Symp. Dayton, Ohio*, 1965. Pergamon Press, Oxford–New York, 1967, pp. 273–291.

— Electron microscope examinations on the brain of water beetle (*Dytiscus marginalis*). *Acta biol. Univ. Szeged* **13**, 46–62 (1967).

— Species characteristics in the structure of the nervous system in the carotid body. In: R. W. Torrance (ed.): *Arterial Chemoreceptors.* Oxford, 1968, pp. 57–63.

— Specielle Synapsen im Mittelhirn des Karpfens (*Cyprinus carpio*). *Acta Anat.* (*Basel*) **70**, 124–135 (1968).

— *Microscopic Innervation of the Heart and Blood Vessels in Vertebrates Including Man.* Akadémiai Kiadó, Budapest, and Pergamon Press, London, 1968.

— Electron microscopic investigations on the human carotid body (Preliminary communication). *Z. mikr.-anat. Forsch.* **79**, 309–315 (1968).

— Electron microscopic observations on the medial neurosecretory cells in the brain of the water beetle (*Dytiscus marginalis*). *Z. mikr.-anat. Forsch.* **80**, 469–484 (1969).

— Elektronenmikroskopische Untersuchungen an menschlichen Karotiskörpern. *Z. mikr.-anat. Forsch.* **81**, 413–453 (1970).

Ábrahám, A.: Recherches ultrastructurales sur les terminaisons nerveuses du « Corpuscule carotidien » humain.

54^e Congrès, Sofia, 30 mars–3 avril, 1969. *Bull. Assoc. Anat.* **146,** 393–400. (1970).

— Ultrastructural investigations on human carotid bodies. *Acta biol. Univ. Szeged* **16,** 97–112 (1971).

— Electron microscopic observations on the adrenal gland of the green toad (*Bufo viridis* Laur). *Acta biol. Univ. Szeged* **18,** 223–240 (1972).

— Die Transformation der Mitochondrien der Lipidzellen in der Nebenniere des Wechselkröte (*Bufo viridis*). *Z. mikr.-anat. Forsch.* **86,** 39–49 (1972).

— Ultrastructure investigations on the cerebral cortex of the sand-lizard (*Lacerta agilis*). *Acta biol. Univ. Szeged,* **19,** 99–116 (1973).

Ábrahám, A., Tury, G. and Halász, N.: On the nature of cell divisions adjacent to electrolytic lesion in the brain of the marsh frog. *Z. mikr.-anat. Forsch.* **87,** 65–84 (1973).

Ábrahám, A.: Structure of synapses in the supraoesophageal ganglion of the water beetle (*Dytiscus marginalis*). *Z. mikr.-anat. Forsch.* **90,** 226–238 (1976).

— Ultrastructurelle Untersuchungen an der Wachshaut von Enten unter besonderer Berücksichtigung der Grandryschen und Herbstschen Körper. *Z. mikr.-anat. Forsch.* **92,** 81–118 (1978).

Ábrahám, A.: A receptorok helye és szerkezete a sündisznó (*Erinaceus europaeus*) orrabőrében fény- és elektronmikroszkóp alatt (The place and structure of the receptors in the nasal skin of the hedgehog (*Erinaceus europaeus*) under the light- and electron microscope). *Állattani Közlemények* **67,** 21–43 (1980).

A. ÁBRAHÁM

ICONOGRAPHY OF SENSORY NERVE ENDINGS