ANATOMICAL DICTIONARY

WITH NOMECLATURES AND EXPLANATORY NOTES

by

TIBOR DONĀTH



AKADÉMIAI KIADÓ,
BUDAPEST

ANATOMICAL DICTIONARY

WITH NOMENCLATURES AND EXPLANATORY NOTES

by T. DONÁTH

The English version of this dictionary, following the highly successful Hungarian, German and Russian versions, has been meant to satisfy the wide demands for books setting out the medical and anatomical nomenclatures with explanations of their terms.

The first section consists of a comparative survey of the Basle, Jena and Paris nomenclatures grouped according to the various organs. The PNA includes the modifications and completions ratified by the Seventh and Eighth International Congresses of Anatomists held respectively at New York in 1960 and at Wiesbaden in 1965.

In the second section 2500 basic words complete with grammatical and etymological explanations are listed in alphabetical order. Biographical information on 500 anatomists is added, whose names have been linked to the eponymic terms used. An alphabetical index embracing all three nomenclatures helps orientation. The book is an indispensable compendium for academic, research and practical workers alike.

AKADÉMIAI KIADÓ
Publishing House of the Hungarian Academy of Sciences
BUDAPEST

ANATOMICAL DICTIONARY

with Nomenclatures and Explanatory Notes

ANATOMICAL DICTIONARY

with Nomenclatures and Explanatory Notes

by

TIBOR DONÁTH, M. D.
Professor of Anatomy
Budapest University School of Medicine

English Edition Edited by
G. N. C. CRAWFORD
Department of Human Anatomy, Oxford University

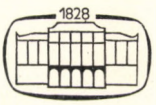

AKADÉMIAI KIADÓ, BUDAPEST 1969

© AKADÉMIAI KIADÓ, BUDAPEST 1969

PRINTED IN HUNGARY

CONTENTS

Foreword	6
Preface to the English edition	7
Preface to the Hungarian edition	8
The anatomical nomenclature	10
Comparison of the nomenclatures of Basle, Jena and Paris	15
Nomina Anatomica	17
Partes corporis humani	37
Osteologia	43
Syndesmologia	81
Myologia	99
Splanchnologia	125
Angiologia	175
Neurologia	217
Organa sensuum	277
Regiones corporis	303
Additional PNA terms	309
Explanatory dictionary	317
List of authors with biographical data	509
Index	537

FOREWORD

THE Anatomical Dictionary of Tibor Donáth has during the eight years of its existence proved a most valuable aid both in the learning and teaching of anatomy in this country. The German translation printed only one year after the original edition met favourable acknowledgement in anatomical circles of Central Europe. A thoroughly revised edition in Russian appeared in 1964.

The particular need for such a book is easily explained by two circumstances: modern requirements of streamlined secondary school teaching as well as of medical studies, have in the last decades considerably reduced the knowledge of the classical languages on one hand and the time available for the anatomist to dwell on details of anatomical terms and their synonyms on the other. The quick change of continental anatomy from the Basle Nomina Anatomica (1895) to the Jena (1935) and finally to the Paris Nomina Anatomica (1955) as well as its further revisions in New York (1960) and Wiesbaden (1965) at times when other branches of medical literature have not even caught up with the first, is a constant source of difficulties and ambiguities if not of severe misunderstandings.

Students of, as well as those teaching, anatomy will find Doctor Donáth's book an excellent aid whenever the necessity arises for linguistic or historical explanation of any anatomical term, whether this be one of the internationally accepted nomenclature, or some older expression connected with an author's name.

J. SZENTÁGOTHAI

Member of the Hungarian Academy of Sciences
Professor of Anatomy, Budapest

PREFACE TO THE ENGLISH EDITION

SINCE its original publication in Hungarian in 1958, the Anatomical Dictionary has appeared both in German and Russian. The wide demand for books setting out the medical and anatomical nomenclatures with explanations of their terms has now stimulated an English edition.

In about A.D. 100 a Greek physician, Rufus of Ephesus, wrote thus on anatomical terms: „What do you learn first in playing the guitar? To touch and name every string. What do you master first in learning a language? To know and name every letter." And in the 16th century, Isaac Joubert in his *Interpretatio dictionum anatomicarum* stated: „Each science has its own language which should be taught and explained to the beginner; otherwise he will not be able to pursue its study."

With these thoughts in mind we present our book to the English reader.

The present revised English edition has been completed by an index embracing all three nomenclatures so that the situation of anatomical terms in the section where they are grouped according to the various systems can be quickly determined. It also incorporates those changes of the Paris Nomina Anatomica, which on the suggestion of the International Anatomical Nomenclature Committee were ratified by the Seventh International Anatomical Congress at New York in 1960 and by the Eight at Wiesbaden in 1965.

I wish to express my deep gratitude to Dr. G. N. C. Crawford, University Lecturer at the Department of Human Anatomy, Oxford, for his careful work in preparing the English edition of this book and in expanding the explanatory part. Limitations of space, as in previous editions, prevented the inclusion of the name of every structure in the latter section; representative ones and those which might cause difficulties to the student were therefore chosen. It is to be hoped that the choice will not seem too arbitrary.

I am much indebted to Mrs. Martha Karwinski for the translation, and to my colleague Mrs. Éva Szaszovsky for her valuable help in the preparation of the manuscript. Sincere thanks are also due to the Pergamon Press and the Publishing House of the Hungarian Academy of Sciences for the excellent format of the book.

Budapest

T. DONÁTH

PREFACE TO THE HUNGARIAN EDITION

MANY medical terms derive from the nomenclature of anatomy and their incorrect use is frequently encountered both in medical practice and in the literature. This is partly due to the fact that although the Paris Nomina Anatomica was accepted internationally in 1955, anatomical terms from the three different nomenclatures are, in fact, still used at the present time. Thus those in recent works may be hardly intelligible to the physician of the older school, while medical students may be equally confused by the earlier books.

The author has dealt before with the explanation of anatomical terms (Donáth–Palkovics: *Explanation of Anatomical Terms*, 1952, 1955, Hung.). Subsequent events have led to a book of a different type, and this anatomical dictionary is intended to help surmount the difficulties due to three concurrent nomenclatures, thus assisting in the study of the countless textbooks and atlases based on the Basle, Jena or Paris nomenclatures pending international use of the latter. Itt aims primarily at facilitating university teaching but it should also be useful in both general practice and in the medico-scientific field.

In the university course the learning of several thousand Latin terms presents great difficulty to the medical student who often does not understand their meaning, and is unable to perceive the logical construction of the term, its grammatical formation, or the possibilities of derivations from the basic word (e.g. abducere, nervus abducens, musculus abductor, to abduct, etc.). Explanation and definition simplifies their memorization since experience shows that words may be kept firmly in mind only if one understands their sense. The analysis of the words also encourages correct usage.

The first section of the book therefore presents the anatomical nomenclature grouped according to the various systems. Thus the student can easily survey the terms relevant to the region or organ which he is studying. Moreover, mastery of the anatomy of an organ implies knowledge of its terms and their meaning and such a survey also helps the revising student to recall the anatomy of the different parts. The Basle, Jena and Paris nomenclatures are listed side-by-side to facilitate and encourage replacement of the old by the current terminology.

The second section, based originally on the Basle nomenclature, contains the basic words occurring in anatomy in alphabetical order. Their genitive case, gender and etymology are indicated, as well as adjectives derived from them, and their meaning.

Subsequently a short explanation is given of the anatomical terms related to the basic words.

The third section contains in alphabetical order very brief biographical data concerning those famous anatomists whose names have been linked to a term in the nomenclature.

Many thanks are due to Dr. I. Lengyel for his valuable work in assembling data and to Mrs. Maria Deák for help in its presentation.

T. DONÁTH

Budapest

THE ANATOMICAL NOMENCLATURE

A specialized terminology has evolved for the interchange of scientific knowledge and ideas and their transmission to future generations. Medicine, perhaps the oldest of sciences, has had its own since antiquity and it was in the epoch of Hellenism, when there was systematic study of the human body, especially by Herophilos and Erasistratos of the Alexandrian school in the third century B.C., that the nomenclature of anatomy first attained a high level. Ever since it has evolved and developed.

At the time of Galen, Greek words were used exclusively. The anatomists of the Middle Ages employed Latin expressions as well and moreover adopted some Arabic and old Greek names, often in an unrecognizably distorted form, and innumerable synonyms caused much confusion. Vesalius was the first who tried to impose order. He rejected the Arabic and mediaeval Latin terms and translated the Greek so as to have all in classical Latin. Some of the translations, however, appeared forced (e.g. sclera = dura oculi tunica; musculus deltoideus = musculus brachium moventium secundum) and then a return was made to the original Greek.

Since Vesalius, numerous attempts were made to create a unified nomenclature, but the prestige of their authors was insufficient to enable them to enforce their views, and it was not until 1880 that Hyrtl's claim for reform eventually resulted in the compilation of the Basle Nomina Anatomica (BNA, 1895), which put an end to anarchy. A structure, hitherto known perhaps under several names, was assigned one, and in the case of a term linked to the names of several authorities (e.g. valvula ileocaecalis Bauhini, seu Tulpii, seu Fallopii) the eponyms were either discarded or that one retained whose author had the best claims to priority. Simplicity and brevity were decisive in the choice of terms. A large proportion of the tens of thousands of names surviving from previous centuries were rejected as synonyms, the remainder comprising about 4,500 of the original total.

Forty years later fundamental changes had been accomplished by the Association of German Anatomists when in 1936 Stieve presented the so-called Jena Nomenclature (JNA, 1935). For example, the JNA introduced a number of entirely new terms for the nervous systems and to denote directions (e.g. ventralis instead of anterior, and cranialis instead of superior). Throughout stress was laid upon philological exactness. Today it is realized that the JNA was not in fact generally practicable. Neither the theoreticians nor the clinicians being satisfied with it, they reverted to the BN Aand it was not generally used in the Anglo-Saxon and Soviet literature. The expressions of the JNA are too

long and ponderous and often unreasonable (e.g. mesostenium instead of mesenterium). However, as the JNA was accepted for some new textbooks, especially those deriving from the German school, the intermingling of the two nomenclatures caused much trouble. Those accustomed to older books could not find their way in the new ones and medical students especially faced serious difficulties. In order to eliminate this dualism the International Anatomical Nomenclature Committee (I.A.N.C.), which was set up in Oxford during the 5th International Congress of Anatomy in 1950 and consisted of 22 members, compiled a new nomenclature. This was accepted in Paris in 1955 by the 6th International Congress of Anatomists and was known as the Paris Nomina Anatomica (PNA).

The PNA is based on the BNA. It includes about 5,640 terms, of which 4,286 (76%) remained unchanged from the BNA, while 886 (15·6%) of the latter were modified. About 268 (4·9%) were adopted from the JNA, and more than 200 (3·5%) entirely new ones added. Thus there was a total of about 1,354 (24%) changes. Whereas in the JNA etymological exactness was the main aim, in the PNA simple, short and memorable terms were sought. All the eponyms of macroscopic anatomy were omitted.

On the suggestion of the I.A.N.C. further modifications of the Nomina Anatomica were introduced at the 7th International Congress of Anatomy at New York in 1960. 104 terms were changed and 119 added, and there were relatively minor alterations such as changes of position (58) and spelling (89), removal of diphthongs (80) and

Comparative table of the most important terms of direction

BNA	JNA			PNA
	Head	Trunk	Extremities	
superior	superior maxillaris	cranialis	proximalis	superior
inferior	inferior mandibularis	caudalis	distalis	inferior
anterior	anterior frontalis rostralis	ventralis	volaris: upper extremity ventralis: lower extremity	anterior
posterior	posterior occipitalis	dorsalis	dorsalis	posterior
medialis	medialis nasalis	medialis	ulnaris: upper extremity tibialis: lower extremity	medialis
lateralis	lateralis temporalis	lateralis	radialis: upper extremity fibularis: lower extremity	lateralis

inconsistencies (23), and grammatical corrections (20). Nearly 500 changes appears a considerable number, but these actually affected less than 10% of the total nomenclature and less than half were of much significance. Certain general changes included, in addition to the removal of diphthongs, the removal of hyphens between vowels in the middle of words. Words such as margo and paries were to be masculine (they had been either masc. or fem. before), and words such as calyces were to be spelt calices. Grammatical errors such as genu for genus were corrected. There were also additions in the form of general terms and, especially noteworthy, new terms for pulmonary vessels based on Boyden's classification. Other minor changes included, for example, the omission of "comitantes" from some venous terms and A. appendicis vermiformis became A. appendicularis, and humor aqueus, humor aquosus. In short there was a general tidying up of the Nomina Anatomica, which resulted in a second edition in 1961.

Finally the International Congress of Anatomy at Wiesbaden in 1965 accepted improvements introduced by the I.A.N.C. which incorporated suggestions put to them in the previous five years. The I.A.N.C. stressed that no changes were made for merely pedantic reasons or unless they were desired by the majority. They continued to adhere to the policy that terms should always be in Latin, and be as short, simple and informative as possible; that alternatives should be avoided and eponyms discarded; that related structures (e.g. arteries, veins, nerves) have similar names and differentiating adjectives be opposites (e.g. major, minor). Alterations to well-established terms were avoided. Over half of the 1,000 modifications were additions to the general terms and a few accidental omissions (e.g. Junctura lumbosacralis) were repaired. A very small number of incorrect terms (e.g. M. sphincter vesicae) and some further inconsistencies, and spelling and grammatical errors were deleted or remedied. More important was the decision to include names for the segments of the liver and kidney (and consequently to adjust the names of their vessels) and to add a number of dental terms. The nomenclature of the thalamic nuclei was also modified. All these changes were incorporated in the 3rd edition of the Nomina Anatomica, which was published in 1966 and is now the definitive nomenclature.

The I.A.N.C. is continuing its functions, but the very thorough work outlined above has resulted in a nomenclature which should prove generally acceptable and only require occasional and minor modification.

BIBLIOGRAPHY

ABDERHALDEN, R.: Medizinische Terminologie, Basel, Benno Schwabe, 1948.

BREZINA, E.: Medizinisches Wörterbuch, Wien, Urban u. Schwarzenberg, 1948.

CHAUNCEY EYCLESHYMER, A.: Anatomical Names (especially the BNA), New York, William Wood and Co., 1917.

DOBSON, J.: Anatomical Eponyms. London, E. and S. Livingstone, 1962, 2nd edition.

DONÁTH, T. and PALKOVICS, I.: Explanation of Anatomical Terms (Hung.), Budapest, Egészségügyi Kiadó, 1952.
DORLAND's Illustrated Medical Dictionary, Philadelphia and London, W. B. Saunders Co., 1961.
GUTTMANN's Medizinische Terminologie, edited by Dr. H. Volkmann, Wien, Urban u. Schwarzenberg, 1939, 29th edition.
HIS, W.: Die anatomische Nomenklatur, Leipzig, Veit u. Co., 1895.
HYRTL, J.: Onomatologia anatomica. Geschichte und Kritik der anatomischen Sprache der Gegenwart, Wien, 1880.
KOPSCH, FR. and KNESE, H.: Nomina Anatomica, Stuttgart, G. Thieme, 1957, 5th edition.
KRÜGER, G.: Der anatomische Wortschatz, Leipzig, Hirzel, 1950.
MITCHELL, G. A. G.: Report by the Hon. Secretary to the Plenary Session of the VII. International Anatomical Congress, New York, April, 1960.
Nomina Anatomica, Amsterdam, Excerpta Medica Foundation, 1961, 2nd edition.
Nomina Anatomica, Amsterdam, Excerpta Medica Foundation, 1966, 3rd edition.
PETROVICS, L. and SZABÓ, Z.: Hungarian Sense of Anatomical Terms (Hung.), Budapest, R. Novák and Co., 1936.
STEDMAN's Medical Dictionary, Baltimore, Williams and Wilkins, 1966, 21st edition.
STIEVE, H.: Nomina Anatomica, Jena, G. Fischer, 1936.
WOERDEMAN, M. W.: Nomina anatomica parisiensia (1955) et BNA (1895), Utrecht Ossthoek, 1957.
ZETKIN, M. and SCHALDACH, H.: Wörterbuch der Medizin, Berlin, VEB. Volk u. Gesundheit, 1956.

ABBREVIATIONS

anat.:	in the anatomical sense
BNA:	Basle Nomina Anatomica
f.:	femininum (feminine gender)
Gr.:	Greek
JNA:	Jena Nomina Anatomica
clin.:	in the clinical sense
s.:	see
L.:	Latin
m.:	masculinum (masculine gender)
n.:	neutrum (neuter gender)
plur.:	plural
PNA:	Paris Nomina Anatomica
prep.:	preposition
seu, sive:	or
sing.:	singular
syn.:	synonym
var.:	variation

ANATOMICAL ABBREVIATIONS

a.:	arteria
aa.:	arteriae
art.:	articulatio
can.:	canalis
dext.:	dexter
ggl.:	ganglion
ggll.:	ganglia
gl.:	glandula
gll.:	glandulae
lgl.:	lymphoglandula
lgll.:	lymphoglandulae
lig.:	ligamentum
ligg.:	ligamenta
m.:	musculus
mm.:	musculi
n.:	nervus
nn.:	nervi
plex.:	plexus
proc.:	processus
r.:	ramus
rr.:	rami
rostr.:	rostralis
sin.:	sinister
v.:	vena
vv.:	venae

NOMINA ANATOMICA OF BASLE (BNA) 1895
NOMINA ANATOMICA OF JENA (JNA) 1935
AND
NOMINA ANATOMICA OF PARIS (PNA) 1955

A COMPARATIVE SYNOPSIS WITH TERMS GROUPED ACCORDING TO SYSTEMS AND ORGANS

Between brackets: anatomical variations, official alternatives and explanatory terms.
The index at the end of the book gives the pages on which the terms appear in the following section.

° The headings marked with a circle are not in the official nomenclature but help explain the grouping of the succeeding terms.

+ The terms of the cerebral pathways, marked with a cross in the BNA list, were not included in the official BNA of 1895.

* Modifications accepted at the International Anatomical Congress at New York in 1960.

** Modifications accepted at the International Anatomical Congress at Wiesbaden in 1965.

*** For further terms relating to those marked with three asterisks in the PNA list see pages 310–315.

NOMINA ANATOMICA

Nomina anatomica	*Nomina anatomica*	*Nomina anatomica emendata*
TERMINI SITUM ET DIRECTIONEM PARTIUM CORPORIS INDICANTES		
TERMINI GENERALES	TERMINI GENERALES	.....
Verticalis	.....	Verticalis
Horizontalis	.....	Horizontalis
Medianus	Medianus	Medianus
.....	.....	Coronalis*
Sagittalis	Sagittalis	Sagittalis
Frontalis	Frontalis	Frontalis
Transversalis	Transversalis	Transversalis
Medialis	Medialis	Medialis
Intermedius	Intermedius	Intermedius
Lateralis	Lateralis	Lateralis
Anterior	Anterior	Anterior
Medius	Medius	Medius
Posterior	Posterior	Posterior
Ventralis	Ventralis	Ventralis
Dorsalis	Dorsalis	Dorsalis
Internus	Internus	Internus
Externus	Externus	Externus
Dexter	Dexter	Dexter
Sinister	Sinister	Sinister
Longitudinalis	Longitudinalis	Longitudinalis
Transversus	Transversus	Transversus
Cranialis	Cranialis	Cranialis
Rostralis	Rostralis	.....
Caudalis	Caudalis	Caudalis
Superior	Superior	Superior
Inferior	Inferior	Inferior
Superficialis (sublimis) ..	Superficialis	Superficialis
Profundus	Profundus	Profundus

BNA	JNA	PNA
TERMINI AD EXTREMITATES SPECTANTES	TERMINI AD EXTREMITATES SPECTANTES	TERMINI AD MEMBRA SPECTANTES
Proximalis	Proximalis	Proximalis
Distalis	Distalis	Distalis
Radialis	Radialis	Radialis
Ulnaris	Ulnaris	Ulnaris
Tibialis	Tibialis	Tibialis
Fibularis	Fibularis	Fibularis
	Volaris	Palmaris
	Plantaris	Plantaris
	Dorsalis	
	TERMINI GENERALES	
		Abdomen**
		Abducens**
		Abductor**
		Aberrans**
Accessorius		Accessorius**
Acinus	Acinus	Acinus
		Acutus**
		Adductor**
		Adeps, adipis**
		Adhesio**
Aditus	Aditus	Aditus
		Adminiculum**
		Adventicius**
		Afferens**
		Affixus**
		Agger**
Ala	Ala, alaris	Ala
		Albicans**
		Albugineus**
		Albus**
		Alimentarius**
Alveolus	Alveolus, alveolaris	Alveolus
		Alveus**
		Ambiguus**
Ampulla	Ampulla, ampullaris	Ampulla
		Amygdala**
		Anastomosis**

BNA	JNA	PNA
.....	.....	Anatomia, anatomica**
.....	.....	Ancon, anconis**
Angulus	Angulus, angularis	Angulus
Ansa	Ansa	Ansa
.....	.....	Anserinus**
Antrum	Antrum	Antrum
.....	Anulus, anularis	Anulus
.....	Anus, analis	Anus**
.....	.....	Aorta**
Apertura	Apertura	Apertura
Apex	Apex	Apex
.....	.....	Aponeurosis**
.....	.....	Apophysis**
.....	Apparatus	Apparatus**
Appendix	Appendix, Appendiculari	Appendix
.....	.....	Aqueductus**
.....	.....	Aquosus**
.....	.....	Arachne**
.....	.....	Arbor**
.....	.....	Arcuatus**
Arcus	Arcus, arciformis, arcuatus, arcuarius	Arcus
Area	Area, areolaris	Area
.....	.....	Areola**
.....	.....	Arrector**
.....	.....	Arteria
.....	.....	Arteriola**
.....	Articulus, articularis	Articulatio
.....	.....	Arytena**
.....	.....	Ascendens**
.....	.....	Asper**
.....	.....	Associus**
.....	.....	Atavus**
.....	.....	Atrium**
.....	.....	Auditus**
.....	.....	Auricula**
.....	.....	Auris**
.....	.....	Autonomicus**
.....	.....	Axilla**
.....	.....	Axis*
.....	.....	Azygos**
.....	.....	Basilicus**

BNA	JNA	PNA
Basis	Basis	Basis
		Biceps**
		Bicornis**
		Bifidus**
		Bifurcus**
Brachium	Brachium, brachialis	Brachium
		Branchia**
		Brevis**
		Bronchiolus**
		Bronchus**
	Bucca, buccalis	Bucca**
		Buccina**
	Bulbus	Bulbus**
		Bulla**
		Bursa
		Calcaneum**
		Calcar, calcaris**
		Caliculus**
		Calix**
		Callosus**
		Calvaria**
		Calx, calcis**
		Camera**
Canaliculus	Canaliculus	Canaliculus
Canalis	Canalis	Canalis
		Cancellus**
		Capillaris**
		Capillus**
		Capitalis**
		Capitatus**
Capitulum	Capitulum	Capitulum
Capsula	Capsula, capsularis	Capsula
Caput	Caput, capitalis	Caput
		Cardia**
		Cardiacus**
		Carina**
		Carneus**
		Carpus**
Cartilagos	Cartilago, cartilagineus	Cartilago, cartilaginis**
Caruncula	Caruncula	Caruncula
Cauda	Cauda, caudalis, caudatus	Cauda
Caverna	Caverna, cavernosus	Caverna**

BNA	JNA	PNA
.....	Cavitas	.....
Cavum	Cavum	Cavum
.....	.....	Cavus**
.....	.....	Cecus**
.....	.....	Celiacus**
.....	.....	Cella**
Cellula	.....	Cellula
.....	.....	Centralis**
.....	.....	Centrum**
.....	.....	Cephalicus**
.....	Cerebellum, cerebellaris ..	Cerebellum**
.....	Cerebrum, cerebralis	Cerebrum**
.....	.....	Ceruleus**
.....	Cervix, cervicalis	Cervix*
.....	.....	Chiasma*
.....	.....	Chorda**
.....	.....	Choroidea**
.....	.....	Chroma**
.....	.....	Chylus**
.....	.....	Cilium**
.....	.....	Cinereus**
.....	.....	Cingulum**
Circulus	Circulus, circularis	Circulus
.....	.....	Circumferentia**
.....	.....	Circumflexus**
Cisterna	Cisterna	Cisterna
.....	.....	Claustrum**
.....	.....	Clavicula**
.....	.....	Clinoideus**
.....	.....	Clitoris**
.....	.....	Clivus**
.....	.....	Clunis**
.....	.....	Coccyx**
.....	.....	Cochlea**
.....	.....	Collateralis**
.....	Colliculus	Colliculus**
Collum	Collum	Collum
.....	.....	Colon**
Columna	Columna	Columna
.....	.....	Comes, comitis**
Commissura	Commissura, commisuralis	Commissura
.....	.....	Communis**

BNA	JNA	PNA
.....	.....	Compactus**
.....	.....	Compressor**
.....	.....	Concha**
.....	Condylus, condylicus ...	Condylus**
.....	.....	Conexus**
.....	.....	Confluens**
.....	.....	Congenitus**
.....	.....	Conjugatio**
.....	.....	Conjunctivus**
.....	.....	Constrictor**
.....	Conus, conicus	Conus**
.....	.....	Convexus**
.....	.....	Convolutus**
.....	.....	Corium**
.....	.....	Cornea**
.....	Corniculum, corniculatus .	Corniculatus**
Cornu	Cornu	Cornu
Corona	Corona, coronarius	Corona
Corpus	Corpus	Corpus
Corpusculum	Corpusculum	Corpusculum
.....	.....	Corrugator**
.....	Cortex, corticalis	Cortex, corticis**
.....	.....	Costa**
.....	.....	Cotyla**
.....	.....	Coxa**
.....	Cranium, cranialis	Cranium**
.....	.....	Crassus**
.....	.....	Crena**
.....	Cribrum, cribriformis, cribratus	Cribriformis**
.....	.....	Cribrosus**
.....	.....	Cricoideus**
Crista	Crista	Crista
.....	.....	Cruciatus**
Crus	Crus, cruralis	Crus, cruris**
.....	.....	Cubitum**
.....	.....	Culmen, culminis**
.....	.....	Cumulus**
.....	.....	Cuneus**
.....	.....	Cupula**
.....	.....	Curvatura**
.....	.....	Cuspis, cuspidis**

BNA	JNA	PNA
.....	.....	Cuticula**
.....	.....	Cutis, cutis**
.....	.....	Deciduus**
.....	.....	Declive, declivis**
Decussatio	Decussatio	Decussatio
.....	.....	Deferens**
.....	.....	Delta**
.....	.....	Dens, dentis**
.....	.....	Densus**
.....	.....	Denticulatus**
.....	.....	Dentinum**
.....	.....	Depressor**
.....	.....	Dermis**
.....	.....	Descendens**
.....	.....	Detrusor**
.....	.....	Diaphragma**
.....	.....	Diaphysis**
.....	.....	Diastema**
.....	.....	Diencephalon**
.....	.....	Digastricus**
.....	.....	Digitalis**
.....	.....	Digitus**
.....	.....	Dilator**
.....	.....	Diplois**
.....	.....	Discus*
.....	.....	Diverticulum**
Dorsum	Dorsum, dorsalis	Dorsum
Ductulus	Ductulus	Ductulus
Ductus	Ductus	Ductus
.....	.....	Duodeni**
.....	.....	Durus**
.....	.....	Efferens**
.....	.....	Ejaculatorius**
.....	.....	Elasticus**
.....	.....	Ellipsoideus**
.....	.....	Embryo**
Eminentia	Eminentia	Eminentia
.....	.....	Emissarius**
.....	.....	Encephalon**
Endothelium	.....	Endothelium
.....	.....	Entericus**
.....	.....	Ependyma**

BNA	JNA	PNA
.....	.....	Epicondylus**
.....	.....	Epidermis**
.....	.....	Epididymis**
.....	.....	Epigastrium**
.....	.....	Epiphysis**
Epithelium	.....	Epithelium
.....	.....	Equator*
.....	.....	Equinus**
.....	.....	Erector**
.....	.....	Esophagus**
.....	.....	Excavatio*
.....	.....	Extensor**
Extremitas	Extremitas	Extremitas
Facies	Facies, facialis	Facies
.....	Falx, falciformis	Falx, falcis**
Fascia	.....	Fascia
Fasciculus	Fasciculus, fascicularis ...	Fasciculus
.....	.....	Fauces**
.....	.....	Fenestra**
.....	.....	Fetus**
Fibra	Fibra, fibrosus	Fibra
Fibrocartilago	.....	Fibrocartilago
.....	.....	Filamentum**
Filum	Filum	Filum
.....	.....	Fimbria**
Fissura	Fissura	Fissura
.....	.....	Flavus**
.....	.....	Flexor**
Flexura	Flexura	Flexura
Folium	Folium, foliatus	Folium
Folliculus	Folliculus	Folliculus
.....	.....	Fonticulus**
Foramen	Foramen, foraminosus ...	Foramen
.....	.....	Forceps, forcipis**
Formatio	Formatio	Formatio, formationis**
Fornix	Fornix, fornicatus	Fornix, fornicis**
Fossa	Fossa	Fossa
Fossula	Fossula	Fossula
Fovea	Fovea	Fovea
Foveola	Foveola, foveolaris	Foveola
Frenulum	Frenulum	Frenulum
.....	.....	Frons, frontis**

BNA	JNA	PNA
.....	Funda, fundiformis	.....
Fundus	Fundus	Fundus
Funiculus	Funiculus, funicularis	Funiculus
.....	.....	Fuscus**
.....	.....	Fusiformis**
.....	.....	Galea**
.....	.....	Gallus**
.....	.....	Ganglion*
.....	.....	Gaster**
.....	.....	Gelatinosus**
.....	.....	Genesis**
Geniculum	Geniculum, geniculatus ..	Geniculum
.....	.....	Genitalis**
Genu	Genu, genitivus: genus ..	Genu
.....	.....	Germen, germinis**
.....	.....	Germinativus**
.....	.....	Gingiva**
.....	.....	Ginglymus**
Glandula	Glandula, glandularis	Glandula
.....	.....	Glans, glandis**
.....	.....	Globus**
Glomerulus	Glomerulum	Glomerulus
Glomus	Glomus, glomiformis ...	Glomus, glomeris**
.....	.....	Gluteus**
.....	.....	Gomphosis**
.....	.....	Gracilis**
.....	.....	Granulatio**
.....	.....	Griseus**
.....	.....	Gyrus
.....	.....	Hallux, hallucis**
.....	.....	Hamatus**
.....	.....	Hamulus**
.....	.....	Haustrum**
.....	.....	Helix, helicis**
.....	.....	Hemispherium**
.....	.....	Hepar, hepatis**
.....	.....	Hiatus**
Hilus	Hilus	Hilus
.....	.....	Hippocampus**
.....	.....	Homo, hominis**
Humor	Humor	Humor
.....	.....	Hyalinus**

BNA	JNA	PNA
.....	.....	Hybrida**
.....	.....	Hymen, hymenis**
.....	.....	Hyoideus**
.....	.....	Hypogastrium**
.....	.....	Hypoglossus**
.....	.....	Ileum**
.....	.....	Ilia, ilium**
.....	.....	Iliacus**
.....	.....	Impar**
Impressio	Impressio	Impressio, impressionis**
.....	.....	Imus**
Incisura	Incisura	Incisura
.....	.....	Incisus**
.....	.....	Index, indicis**
Infundibulum	Infundibulum	Infundibulum
.....	.....	Inguen, inguinis**
.....	.....	Insula**
.....	.....	Integumentum**
.....	.....	Intercalatus**
.....	.....	Intersectio**
.....	.....	Interstitium**
Intestinum	Intestinum, intestinalis ...	Intestinum**
.....	.....	Intima**
.....	.....	Introitus**
.....	.....	Intumescentia**
.....	.....	Iris, iridis**
.....	.....	Ischiadicus**
.....	.....	Ischium**
Isthmus	Isthmus, isthmicus	Isthmus
.....	.....	Jejunum**
.....	.....	Jugulum**
.....	.....	Jugum**
Junctura	Junctura	Junctura**
Labium	Labium, labialis	Labium
.....	.....	Labrum**
.....	.....	Labyrinthus**
.....	.....	Lac, lactis**
.....	.....	Lacerus**
.....	.....	Lacertus**
.....	.....	Lacrima**
Lacuna	Lacuna, lacunaris	Lacuna
Lamina	Lamina	Lamina

BNA	JNA	PNA
.....	.....	Lanugo**
.....	.....	Laryngeus**
.....	.....	Latissimus**
Latus	Latus, lateralis	Latus
.....	.....	Lemniscus
.....	.....	Lens, lentis**
.....	.....	Levator**
.....	.....	Liber**
.....	.....	Lien, lienis**
Ligamentum	Ligamentum, ligamentosus	Ligamentum
Limbus	Limbus, limbicus	Limbus
Limen	Limen	Limen, liminis**
.....	.....	Limitaneus**
Linea	Linea	Linea
.....	.....	Lingua**
.....	.....	Lingula**
Liquor	Liquor	Liquor
Lobulus	Lobulus	Lobulus
Lobus	Lobus, lobaris	Lobus
.....	.....	Locus**
.....	.....	Longissimus**
.....	.....	Longus**
.....	.....	Lucidus**
.....	.....	Lumbricus**
.....	.....	Lumbus**
.....	.....	Lunatus**
.....	.....	Lunula**
.....	.....	Luteus**
.....	.....	Lympha**
.....	.....	Lymphaticus**
Macula	Macula	Macula
.....	.....	Magnus**
.....	.....	Major**
.....	.....	Mala**
.....	.....	Malleolus**
.....	.....	Malleus**
.....	Mamilla, mamillaris	Mamilla**
.....	.....	Mamma**
.....	.....	Mandibula**
.....	.....	Manubrium**
.....	.....	Manus**
Margo	Margo, marginalis	Margo, marginis**

BNA	JNA	PNA
Massa	Massa	Massa
		Masticatus**
		Mastoideus**
		Mater, matris**
		Matrix, matricis**
		Maximus**
Meatus	Meatus	Meatus
		Medianum**
		Mediastinum**
Medulla	Medulla, medullaris	Medulla
		Melania**
Membrana	Membrana, membranaceus	Membrana
Membrum	Membrum	Membrum
		Meninx, meningis**
		Meniscus**
		Mentum**
		Mesothelium
		Metacarpus**
		Metaphysis**
		Metatarsus**
		Minimus**
		Minor**
		Mitra**
		Modiolus**
		Mola**
		Molecularis**
		Mollis**
		Mons, montis**
		Monticulus**
		Motor**
		Mucosus**
Mucus	Mucus, mucosus	Mucus**
		Multifidus**
Musculus	Musculus, muscularis	Musculus
		Naris**
		Nasus**
		Nates**
		Natus**
		Navicula**
		Nephritis**
Nervus		Nervus
		Neuras**

BNA	JNA	PNA
.....	.....	Niger**
Nodulus	Nodulus	Nodulus
.....	Nodus, nodosus	Nodus
.....	.....	Nomen, nominis**
.....	.....	Norma**
.....	Nucha, nuchalis	Nucha**
.....	.....	Nucleolus**
Nucleus	Nucleus, nuclearis	Nucleus
.....	.....	Nutricius**
.....	.....	Obliquus**
.....	.....	Obturator**
.....	Occiput, occipitalis	Occiput, occipitis**
.....	.....	Occultus**
.....	.....	Octavus**
.....	.....	Oculus**
.....	.....	Olfactus**
.....	.....	Oliva**
.....	.....	Omentum**
.....	.....	Omphalos**
.....	.....	Operculum**
.....	.....	Ophthalmicus**
.....	.....	Ora**
.....	.....	Orbicularis**
.....	.....	Orbiculus**
.....	Orbita, orbitalis	Orbita**
Organon	Organon	Organum
Orificium	Orificium	Orificium**
.....	.....	Origo, originis**
Os (oris)	Os, gen.: oris, oralis ...	Os, oris
Os (ossis)	Os gen.: ossis, osseus ...	Os, ossis
.....	.....	Ossiculum**
Ostium	Ostium	Ostium
.....	.....	Oticus**
.....	.....	Ovarius**
.....	.....	Ovum**
.....	Palatum, palatinus	Palatum**
.....	.....	Pallidus**
.....	.....	Pallium**
.....	.....	Palma**
.....	.....	Palmaris**
.....	.....	Palpebra**
.....	.....	Pampiniformis**

BNA	JNA	PNA
.....	.....	Paniculus**
Papilla	Papilla, papillaris	Papilla
.....	.....	Papyraceus**
.....	.....	Paraganglion**
.....	.....	Parasympathicus**
Parenchyma	.....	Parenchyma
Paries	Paries, parietalis	Paries, parietis
.....	.....	Parotis, parotidis**
.....	Pars	Pars, partis**
.....	.....	Parvus**
.....	.....	Pecten, pectinis**
.....	.....	Pectus, pectoris**
.....	.....	Pedalis**
.....	.....	Pedunculus (pediculus)**
.....	.....	Pellis**
.....	.....	Pellucidus**
.....	Pelvis, pelvinus	Pelvis
.....	.....	Perforatus**
Perichondrium	Perichondrium	Perichondrium
.....	.....	Perineon**
Periosteum	Periosteum	Periosteum
.....	.....	Peripheria**
.....	.....	Peritoneum**
.....	.....	Permanens, permanentis**
.....	.....	Perpendicularis**
.....	.....	Peroneus**
.....	.....	Pes, pedis**
.....	.....	Petra**
.....	.....	Petrosus**
.....	.....	Phalanx, phalangis**
.....	.....	Phallus**
.....	.....	Pharynx, pharyngis**
.....	.....	Philtrum**
.....	.....	Pigmentum**
.....	.....	Pilus**
.....	.....	Pinea**
.....	.....	Pinna**
.....	.....	Piriformis**
.....	.....	Pisiformis**
.....	.....	Pituita**
.....	.....	Pius**
.....	.....	Plantaris**

BNA	JNA	PNA
.....	.....	Planus**
.....	.....	Pleura**
Plexus	Plexus	Plexus
Plica	Plica	Plica
.....	.....	Pneumaticus**
.....	.....	Pollex, pollicis**
Polus	.....	Polus
.....	.....	Pons, pontis**
.....	.....	Poples, poplitis**
Porta	Porta	Porta**
.....	Portio	Portio, portionis**
.....	Porus	Porus
.....	.....	Primus**
.....	.....	Princeps, principis**
.....	.....	Prisma, prismatis**
Processus	Processus	Processus
.....	.....	Projectio, projectionis**
Prominentia	Prominentia	Prominens, prominentis**
.....	.....	Promontorium**
.....	.....	Pronator**
.....	.....	Propior**
.....	.....	Pterygoma, pterygomatis**
.....	.....	Pubes**
.....	.....	Pudendus**
.....	.....	Pulmo, pulmonis**
.....	.....	Pulpa**
.....	.....	Pulposus**
Punctum	.....	Punctum
.....	.....	Pupilla**
.....	.....	Pupillaris**
.....	.....	Pylorus**
.....	.....	Pyramis, pyramidis**
.....	.....	Quadrangulum**
.....	.....	Quadratus**
.....	.....	Quadriceps, quadricipitis**
.....	.....	Racemosus**
.....	.....	Racemus**
.....	.....	Radiatio, radiationis**
Radix	Radix, radicularis	Radix, radicis**
Ramulus	Ramulus	.....
Ramus	Ramus	Ramus

BNA	JNA	PNA
Raphe	Raphe	Raphe
Recessus	Recessus	Recessus
		Rectus**
		Recurrens, recurrentis**
		Reflexus**
Regio	Regio	Regio
		Renalis**
		Respiratio, respirationis**
Rete	Rete, reticularis	Rete
		Reticulum**
	Retinaculum	Retinaculum
		Retroflexus**
		Retrogressus**
		Rhomboides**
Rima	Rima	Rima
	Rostrum, rostralis	Rostrum**
		Rotundus**
		Ruber**
Rudimentum	Rudimentum	Rudimentum
		Ruga**
		Sacculus**
	Saccus, sacciformis	Saccus
	Sacrum, sacralis	Sacrum**
		Saliva**
		Sanguis, sanguinis**
		Scala**
		Scalenus**
		Scapha**
		Scapus**
		Sceletus**
		Sclera**
		Scrotum**
		Sebaceus**
		Sebum**
		Secretum**
		Sectio, sectionis**
		Segmentum**
		Sella**
		Semen, seminis**
		Sensorium**
		Sensus**
Septulum	Septulum	Septulum

BNA	JNA	PNA
Septum	Septum, septalis	Septum
		Serotinus**
		Serratus**
		Serum**
		Sesamoides**
		Sigmoideus**
		Simplex, simplicis**
		Singularis**
Sinus	Sinus	Sinus
		Solitarius**
		Solum
Spatium	Spatium	Spatium
		Sperma, spermatis**
		Spermaticus**
		Sphenoidalis**
		Sphericus**
		Spheroides**
Spina	Spina, spinalis	Spina
		Splanchnicus**
		Splenium**
		Spondylus**
		Spongiosus**
		Spurius**
		Squama**
		Squamosus**
		Status**
		Stella**
		Stellatus**
		Stoma, stomatis**
		Stomachus**
Stratum	Stratum	Stratum
Stria	Stria, striatus	Stria
		Striatus**
Stroma	Stroma	Stroma, stromatis**
		Stylus**
Substantia	Substantia	Substantia
Succus	Succus	Succus
		Sudor, sudoris**
Sulcus	Sulcus	Sulcus
		Supinus**
		Sura**
		Suspensus**

BNA	JNA	PNA
.....	.....	Sustentaculum**
.....	.....	Sutura**
.....	.....	Sympathicus**
.....	.....	Symphysis**
.....	.....	Synchondrosis**
.....	Synovia, synovialis	Synovia
.....	.....	Systema, systematis**
.....	.....	Tactus**
.....	.....	Tactilis**
.....	.....	Tectorius**
.....	.....	Tectum**
Taenia	Taenia, taeniatus	Tenia*
Tegmen	Tegmen, tegmentalis	Tegmen, tegminis**
.....	.....	Tegmentum**
Tela	Tela	Tela
Tela conjunctiva	.....	.....**
Tela elastica	.....	.....**
.....	Tendo, tendineus	Tendo
.....	.....	Tensor**
.....	.....	Tentorium**
.....	.....	Tenuis**
.....	.....	Teres, teretis**
.....	.....	Terminalis**
.....	.....	Terminatio**
.....	.....	Theca**
.....	Thorax, thoracicus	Thorax, thoracis**
.....	.....	Tonsilla**
Torus	Torus	Torus
Trabecula	Trabecula	Trabecula
Tractus	Tractus	Tractus
Trigonum	Trigonum, trigonalis	Trigonum
.....	.....	Triticeus**
Trochlea	Trochlea, trochlearis	Trochlea
Truncus	Truncus	Truncus
.....	Tuba, tubalis	Tuba
Tuber	Tuber, tuberalis	Tuber, tuberis**
Tuberculum	Tuberculum, tubercularis .	Tuberculum
.....	Tuberositas	Tuberositsa**
Tubulus	Tubulus	Tubulus
.....	Tubus	Tubus**
Tunica	Tunica	Tunica
Tunica propria	.....	.... **

BNA	JNA	PNA
.....	.....	Tympanum**
Umbo	Umbo	Umbo**
.....	.....	Umbilicus**
.....	.....	Uncinatus**
.....	.....	Uncus**
.....	.....	Unguis**
.....	.....	Urina**
.....	.....	Uterus**
.....	.....	Utriculus**
Uvula	Uvula	Uvula
Vagina	Vagina, vaginalis	Vagina
.....	.....	Vagus**
Vallecula	Vallecula	Vallecula
Vallum	Vallum, vallatus	Vallum**
.....	.....	Valva
Valvula	Valvula, valvularis	Valvula
Vas	Vas	Vas
.....	.....	Vascularis**
.....	.....	Vastus**
Velum	Velum	Velum
.....	.....	Vellus, velleris**
.....	.....	Vena
.....	Venter, ventralis	Venter, ventris**
.....	.....	Ventriculus**
.....	.....	Venula**
.....	.....	Vermis**
.....	.....	Vertebra**
Vertex	Vertex, vide: Vortex	Vertex, verticis**
.....	.....	Verus**
Vesica	Vesica, vesicalis	Vesica
.....	.....	Vesicalis**
Vesicula	Vesicula, vesiculosus	Vesicula
Vestibulum	Vestibulum, vestibularis .	Vestibulum
.....	.....	Vestibularis**
.....	.....	Vestigium
Villus	Villus	Villus
.....	.....	Vinculum**
Viscus (viscera)	Viscera, visceralis	Viscus, visceris**
.....	.....	Visus**
.....	.....	Vita**
.....	.....	Vitellus**
.....	.....	Vitreus**

BNA	JNA	PNA
.....	.....	Vocalis**
.....	.....	Vola**
Vortex	Vortex, vorticosus	Vortex, vorticis**
.....	.....	Vorticosus**
.....	.....	Vulva**
.....	.....	Xiphoideus**
Zona	Zona, zonalis	Zona
.....	.....	Zonula**
.....	.....	Zygomaticus**

PARTES CORPORIS HUMANI

Caput	Caput	Caput
Collum	Collum	Collum
Truncus	Truncus	Truncus
Extremitates	Extremitates	Membra
CAPUT	CAPUT	CAPUT
CRANIUM	CRANIUM	CRANIUM
Vertex	Vertex (Vortex)	Vertex
Sinciput		Sinciput
Frons	Frons	Frons
Occiput	Occiput	Occiput
Tempora	Tempora	Tempora
Auris		Auris
Auricula	Auricula	Auricula
FACIES	FACIES	FACIES
Oculus	*Oculus*	*Oculus*
Supercilium	Supercilium	Supercilium
Palpebra superior	Palpebra superior	Palpebra superior
Palpebra inferior	Palpebra inferior	Palpebra inferior
Rima palpebrarum	Rima palpebrarum	Rima palpebrarum
Bulbus oculi	Bulbus oculi	Bulbus oculi
Sulcus infrapalpebralis	Sulcus palpebromalaris	Sulcus infrapalpebralis
Nasus	*Nasus*	*Nasus*
Dorsum nasi	Dorsum nasi	Dorsum nasi
Apex nasi	Apex nasi	Apex nasi
Ala nasi	Ala nasi	Ala nasi

BNA	JNA	PNA
Os	*Os*	*Os***
Sulcus nasolabialis	Sulcus nasolabialis	Sulcus nasolabialis
Labium superius	Labium maxillare	Labium superius
Philtrum	Philtrum	Philtrum*
Labium inferius	Labium mandibulare	Labium inferius
Rima oris	Rima oris	Rima oris
Cavum oris	Cavum oris	Cavum oris
Lingua	Lingua	Lingua
Fauces	Fauces	Fauces
Bucca (Mala)	Bucca	Bucca (Mala)
Mentum	Mentum	Mentum
Sulcus mentolabialis	Sulcus mentolabialis	Sulcus mentolabialis
COLLUM	COLLUM	COLLUM
Cervix	Cervix	Cervix
	Nucha	Nucha
Larynx	Larynx	Larynx
Prominentia laryngea	Prominentia laryngica	Prominentia laryngea
Pharynx	Pharynx	Pharynx
Trachea	Trachea	Trachea
Oesophagus	Oesophagus	Esophagus*
TRUNCUS	TRUNCUS	TRUNCUS
Dorsum	*Dorsum*	*Dorsum*
Columna vertebralis	Columna vertebralis	Columna vertebralis
Canalis spinalis		
Canalis vertebralis	Canalis vertebralis	Canalis vertebralis
Thorax	*Thorax*	*Thorax*
Cavum thoracis	Cavum thoracis	Cavum thoracis
Pectus	Pectus	Pectus
Mamma	Mamma	Mamma
Papilla mammae	Papilla mammae	Papilla mammae
Abdomen	*Abdomen*	*Abdomen*
Cavum abdominis	Cavum abdominis	Cavum abdominis
Scrobiculus cordis		Fossa epigastrica

BNA	JNA	PNA
Linea semilunaris (Spigeli)	.....	Linea semilunaris
Umbilicus	Umbilicus	Umbilicus
Latus	Latus	Latus
Lumbus	Lumbus	Lumbus
Inguen	Inguen	Inguen
Pelvis	*Pelvis*	*Pelvis*
Cavum pelvis	Cavum pelvis	Cavum pelvis
Mons pubis	Mons pubis	Mons pubis
Coxa	Coxa	Coxa
Nates (Clunes)	Nates = Clunes	Nates (Clunes)
Anus	Anus	Anus
Crena ani	Crena ani	Crena ani
Perineum	Perineum	Regio perinealis*
		Regio analis
		Regio urogenitalis
EXTREMITATES	EXTREMITATES	MEMBRA
EXTREMITAS SUPERIOR	EXTREMITAS THORACICA	MEMBRUM SUPERIUS
Axilla	Axilla	Axilla
Plica axillaris anterior .	Plica axillaris ventralis .	Plica axillaris anterior .
Plica axillaris posterior .	Plica axillaris dorsalis . .	Plica axillaris posterior .
Acromion	Acromion	Acromion
Brachium	Brachium	Brachium
Facies anterior	Facies volaris	Facies anterior
Facies posterior	Facies dorsalis	Facies posterior
Facies lateralis	Facies radialis	Facies lateralis
Facies medialis	Facies ulnaris	Facies medialis
Sulcus bicipitalis lateralis	Sulcus bicipitalis radialis	Sulcus bicipitalis lat.
Sulcus bicipitalis medialis	Sulcus bicipitalis ulnaris	Sulcus bicipitalis med.
Cubitus	Cubitus	Cubitus
Antibrachium	Antebrachium	Antebrachium
Facies dorsalis	Facies dorsalis	Facies posterior
Facies ulnaris	.....	.....
Facies volaris	Facies volaris	Facies anterior
Margo radialis	Margo radialis	Margo lat. (radialis)
Margo ulnaris	Margo ulnaris	Margo med. (ulnaris)
Manus	Manus	Manus
Carpus	Carpus	Carpus
Metacarpus	Metacarpus	Metacarpus

BNA	JNA	PNA
Dorsum manus	Dorsum manus	Dorsum manus
Vola manus (Palma) ..	Vola manus (Palma) ..	Palma manus
Thenar	Thenar	Thenar
Hypothenar	Hypothenar	Hypothenar
Digiti manus	Digiti manus	Digiti manus
Pollex (Digitus I.)	Pollex (Digitus manus primus)	Pollex (Digitus I.)
Index (Digitus II.)	Index (Digitus manus secundus)	Index (Digitus II.)
Digitus medius (Digitus III.)	Digitus medius (Digitus manus tertius)	Digitus medius (Digitus III.)
Digitus annularis (Digitus IV.)	Digitus anularis (Digitus manus quartus)	Digitus anularis (Digitus IV.)
Digitus minimus (Digitus V.)	Digitus minimus (Digitus manus quintus)	Digitus minimus (Digitus V.)
Facies dorsales	Facies dorsales	Facies dorsales
Facies volares	Facies volares	Facies palmares
Margines radiales	Margines radiales	Facies laterales (radiales)
Margines ulnares	Margines ulnares	Facies mediales (ulnares)
EXTREMITAS INFERIOR	EXTREMITAS PELVINA	MEMBRUM INFERIUS
Sulcus glutaeus	Sulcus glutaeus	Sulcus gluteus*
Femur	Os femoris = Femur ...	Femur
Facies anterior	Facies anterior	Facies anterior
Facies posterior	Facies posterior	Facies posterior
Facies lateralis	Facies fibularis	Facies lateralis
Facies medialis	Facies tibialis	Facies medialis
Genu	Genu	Genu
Poples	Poples	Poples
Patella	Patella	Patella
Crus	Crus	Crus
Facies anterior	Facies anterior	Facies anterior
Facies posterior	Facies posterior	Facies posterior
.....	.....	Facies lateralis (fibularis)

BNA	JNA	PNA
.....	.....	Facies medialis (tibialis)
Sura	Sura	Sura
Malleolus lateralis	Malleolus fibularis	Malleolus lateralis
Malleolus medialis	Malleolus tibialis	Malleolus medialis
Pes	Pes	Pes
.....	.....	Arcus pedis longitudinalis*
		Pars medialis
		Pars lateralis
.....	.....	Arcus pedis transversalis*
Tarsus	Tarsus	Tarsus
Metatarsus	Metatarsus	Metatarsus
Dorsum pedis	Dorsum pedis	Dorsum pedis
.....	Planta pedis	Planta
Margo pedis lateralis ..	Margo pedis fibularis .	Margo lateralis (fibularis)
Margo pedis medialis .	Margo pedis tibialis ...	Margo medialis (tibialis)
Calx	Calx	Calx
Digiti pedis	Digiti pedis	Digiti pedis
Hallux (Digitus I.)	Hallux (Digitus pedis primus)	Hallux (Digitus I.)
Digiti II–IV.	Digitus pedis secundus (tertius, quartus)	Digiti II–IV.
Digitus minimus (Digitus V.)	Digitus pedis minimus (Digitus pedis quintus) ...	Digitus minimus (Digitus V.)
Facies dorsales	Facies dorsales	Facies dorsales
Facies plantares	Facies plantares	Facies plantares
Margines laterales	Margines fibulares	Facies laterales*
Margines mediales	Margines tibiales	Facies mediales*

OSTEOLOGIA

Osteologia	*Osteologia*	*Osteologia*
Os longum	Os longum	Os longum
Os breve	Os breve	Os breve
Os planum	Os planum	Os planum
Os pneumaticum	Os pneumaticum	Os pneumaticum
Epiphysis	Epiphysis	Epiphysis
Diaphysis	Diaphysis	Diaphysis
Synchondrosis epiphyseos	Synchondrosis epiphyseos	Cartilago epiphysialis Linea epiphysialis
.....	Synostosis	Synostosis
Apophysis	.....	Apophysis
Facies articularis	Facies articularis	Facies articularis
Substantia compacta	Substantia compacta	Substantia compacta
Substantia corticalis	Cortex	Substantia corticalis
Substantia spongiosa	Substantia spongiosa	Substantia spongiosa
Cavum medullare	Cavum medullare	Cavum medullare
Medulla ossium	Medulla ossium	.....
Medulla ossium flava ...	Medulla ossium flava ...	Medulla ossium flava
Medulla ossium rubra ...	Medulla ossium rubra ...	Medulla ossium rubra
.....	Medulla ossium gelatinosa	.....
Foramen nutricium	Foramen nutricium	Foramen nutricium
Canalis nutricius	Canalis nutricius	Canalis nutricius
.....	Periosteum	.....
.....	Endosteum	.....

BNA	JNA	PNA
OSSA EXTREMITATIS SUPERIORIS	OSSA EXTREMITATIS THORACICAE	OSSA MEMBRI SUPERIORIS
CINGULUM EXTREMITATIS SUPERIORIS	*OSSA CINGULI EXTREMITATUM THORACICARUM*	*CINGULUM MEMBRI SUPERIORIS*
SCAPULA	SCAPULA	SCAPULA
Facies costalis	Facies costalis	Facies costalis
Fossa subscapularis ...	.....	Fossa subscapularis
Lineae musculares ..	Lineae musculares ..	.....
Facies dorsalis	Facies dorsalis	Facies dorsalis
Spina scapulae	Spina scapulae	Spina scapulae
Fossa supraspinata	Fossa supra spinam ...	Fossa supraspinata
Fossa infraspinata	Fossa infra spinam ...	Fossa infraspinata
Acromion	Acromion	Acromion
Facies articularis acromii	Facies articularis acromii	Facies articularis acromii
.....	.....	Angulus acromialis
Processus coracoideus ...	Processus coracoides	Processus coracoideus
Margo superior	Margo cranialis	Margo superior
Incisura scapulae	Incisura scapulae	Incisura scapulae
Margo vertebralis	Margo vertebralis	Margo medialis
Margo axillaris	Margo axillaris	Margo lateralis
Angulus medialis	Angulus cranialis	Angulus superior
Angulus lateralis	Angulus articularis	Angulus lateralis
Angulus inferior	Angulus caudalis	Angulus inferior
Cavitas glenoidalis	Fossa articularis	Cavitas glenoidalis
Tuberositas supraglenoidalis	Tuberositas supraarticularis	Tuberculum supraglenoidale
Tuberositas infraglenoidalis	Tuberositas infraarticularis	Tuberculum infraglenoidale
Collum scapulae	Collum scapulae	Collum scapulae
CLAVICULA	CLAVICULA	CLAVICULA
Extremitas sternalis	Extremitas sternalis	Extremitas sternalis

BNA	JNA	PNA
Facies articularis sternalis	Facies articularis sternalis	Facies articularis sternalis
Tuberositas costalis ...	Tuberositas costalis ...	Impressio lig. costoclavicularis
Foramen nutricium ...	Foramen nutricium ...	Vide: Osteologia
Extremitas acromialis	Extremitas acromialis	Extremitas acromialis
Facies articularis acromialis	Facies articularis acromialis	Facies articularis acromialis
Tuberositas coracoidea .	Tuberositas coracoidea	{Tuberculum conoideum {Linea trapezoidea
SKELETON EXTREMITATIS SUPERIORIS LIBERAE	*OSSA EXTREMITATIS THORACICAE LIBERAE*	*SKELETON MEMBRI SUPERIORIS LIBERI*
HUMERUS	OS BRACHII = HUMERUS	HUMERUS
Epiphysis proximalis°		
Caput humeri	Caput humeri	Caput humeri
Collum anatomicum ...	Collum anatomicum ...	Collum anatomicum
Tuberculum majus	Tuberculum majus	Tuberculum majus
Crista tuberculi majoris	Crista tuberculi majoris	Crista tuberculi majoris
Tuberculum minus	Tuberculum minus	Tuberculum minus
Crista tuberculi minoris	Crista tuberculi minoris	Crista tuberculi minoris
Sulcus intertubercularis	Sulcus intertubercularis	Sulcus intertubercularis
Collum chirurgicum ..	Collum chirurgicum ..	Collum chirurgicum
Corpus humeri	Corpus humeri	Corpus humeri
Facies anterior medialis	.....	Facies anterior medialis
Facies anterior lateralis	.....	Facies anterior lateralis
Facies posterior	.....	Facies posterior
Margo medialis	Margo ulnaris	Margo medialis
Margo lateralis	Margo radialis	Margo lateralis

BNA	JNA	PNA
Tuberositas deltoidea ..	Tuberositas deltoidea ..	Tuberositas deltoidea
Sulcus nervi radialis ...	Sulcus nervi radialis ...	Sulcus nervi radialis
Foramen nutricium ...	Foramen nutricium ...	Vide: Osteologia
Epiphysis distalis°		
Epicondylus lateralis ..	Epicondylus radialis ...	Epicondylus lateralis
Epicondylus medialis ..	Epicondylus ulnaris ...	Epicondylus medialis
Sulcus nervi ulnaris .	Sulcus nervi ulnaris .	Sulcus nervi ulnaris
(Processus supracondyloideus)	Processus supracondylicus	(Processus supracondylaris)
.....	Condylus humeri	Condylus humeri
Capitulum humeri	Capitulum humeri	Capitulum humeri
Trochlea humeri	Trochlea humeri	Trochlea humeri
Fossa radialis	Fossa radialis	Fossa radialis
Fossa coronoidea	Fossa coronoidea	Fossa coronoidea
Fossa olecrani	Fossa olecrani	Fossa olecrani
.....	OSSA ANTEBRACHII	.....
RADIUS	RADIUS	RADIUS
Epiphysis proximalis°		
Capitulum radii	Capitulum radii	Caput radii
Fovea capituli radii ..	Fovea capituli radii	.....
Circumferentia articularis	Circumferentia articularis	Circumferentia articularis
Collum radii	Collum radii	Collum radii
Corpus radii	Corpus radii	Corpus radii
Tuberositas radii	Tuberculum radii	Tuberositas radii
Crista interossea	Crista interossea	Margo interosseus*
Facies dorsalis	Facies dorsalis	Facies posterior
Facies volaris	Facies volaris	Facies anterior
Facies lateralis	Facies radialis	Facies lateralis
.....	Tuberositas pronatoria	.....
Margo dorsalis	Margo dorsalis	Margo posterior
Margo volaris	Margo volaris	Margo anterior
Foramen nutricium ...	Foramen nutricium ...	Vide: Osteologia
Epiphysis distalis°		
Facies articularis carpea	Facies articularis carpica	Facies articularis carpea
Incisura ulnaris	Incisura ulnaris	Incisura ulnaris
Processus styloideus ..	Processus styloides	Processus styloideus

BNA	JNA	PNA
ULNA	ULNA	ULNA
Epiphysis proximalis°		
Olecranon	Olecranon	Olecranon
Processus coronoideus	Processus coronoides	Processus coronoideus
Tuberositas ulnae	Tuberositas ulnae	Tuberositas ulnae
Incisura semilunaris	Incisura semilunaris	Incisura trochlearis
Incisura radialis	Incisura radialis	Incisura radialis
Crista m. supinatoris	Crista supinatoria	Crista m. supinatoris
Corpus ulnae	Corpus ulnae	Corpus ulnae
Crista interossea	Crista interossea	Margo interosseus*
Margo dorsalis	Margo dorsalis	Margo posterior
Margo volaris	Margo volaris	Margo anterior
Facies dorsalis	Facies dorsalis	Facies posterior
Facies volaris	Facies volaris	Facies anterior
Facies medialis	Facies ulnaris	Facies medialis
Epiphysis distalis°		
Capitulum ulnae	Capitulum ulnae	Caput ulnae
Circumferentia articularis	Circumferentia articularis	Circumferentia articularis
Processus styloideus	Processus styloides	Processus styloideus
CARPUS	CARPUS	CARPUS
OSSA CARPI	OSSA CARPI	OSSA CARPI
	Ossa carpi distalia	
	Ossa carpi proximalia	
Os naviculare manus	Os naviculare manus	Os scaphoideum
Tuberculum ossis navicularis	Tuberculum ossis navicularis	Tuberculum ossis scaphoidei
Os lunatum	Os lunatum	Os lunatum
Os triquetrum	Os triquetrum	Os triquetrum
Os pisiforme	Os pisiforme	Os pisiforme
Os multangulum majus	Os multangulum majus	Os trapezium
Tuberculum ossis multanguli majoris	Tuberculum ossis multanguli majoris	Tuberculum ossis trapezii
Os multangulum minus	Os multangulum minus	Os trapezoideum

BNA	JNA	PNA
Os capitatum	Os capitatum	Os capitatum
.....	Caput ossis capitati ..	.....
Os hamatum	Os hamatum	Os hamatum
Hamulus ossis hamati	Hamulus ossis hamati	Hamulus ossis hamati
Eminentia carpi radialis .	Eminentia carpi radialis .	.....
Eminentia carpi ulnaris ..	Eminentia carpi ulnaris ..	.....
Sulcus carpi	Sulcus carpi	Sulcus carpi
(Os centrale)	var. Os centrale carpi ...	(Os centrale)
.....	Ossa accessoria carpi	.....
METACARPUS	METACARPUS	METACARPUS
.....	OSSA METACARPI	.....
Ossa metacarpalia I–V.	Os metacarpi primum (secundum, tertium, quartum, quintum)	Ossa metacarpalia I–V.
Basis	Basis	Basis
Corpus	Corpus	Corpus
Capitulum	Capitulum	Caput
Os metacarpale III.	.....	Os metacarpale III.
Processus styloideus ..	Processus styloides ossis metacarpi tertii	Processus styloideus
PHALANGES DIGITORUM MANUS	OSSA DIGITORUM MANUS	OSSA DIGITORUM MANUS
Phalanx prima	Phalanx proximalis	Phalanx proximalis
Phalanx secunda	Phalanx media	Phalanx media
Phalanx tertia	Phalanx distalis	Phalanx distalis
Basis phalangis	Basis phalangis	Basis phalangis
Corpus phalangis	Corpus phalangis	Corpus phalangis
Trochlea phalangis ...	Trochlea phalangis ...	Caput phalangis
Tuberositas unguicularis	Tuberositas unguicularis	Tuberositas phalangis distalis
Ossa sesamoidea	Ossa sesamoidea	Ossa sesamoidea
DIGITI MANUS	DIGITI MANUS	DIGITI MANUS
Digitus annularis (Digitus IV.)	Digitus anularis (Digitus manus quartus)	Digitus anularis (Digitus IV.)

BNA	JNA	PNA
Digitus medius (Digitus III.)	Digitus medius (Digitus manus tertius)	Digitus medius (Digitus III.)
Digitus minimus (Digitus V.)	Digitus minimus (Digitus manus quintus)	Digitus minimus (Digitus V.)
Pollex (Digitus I.)	Pollex (Digitus manus primus)	Pollex (Digitus I.)
Index (Digitus II.)	Index (Digitus manus secundus)	Index (Digitus II.)
Margines radiales	Margines radiales	Facies laterales (radiales)
Margines ulnares	Margines ulnares	Facies mediales (ulnares)
OSSA EXTREMITATIS INFERIORIS	OSSA EXTREMITATIS PELVINAE	OSSA MEMBRI INFERIORIS
CINGULUM EXTREMITATIS INFERIORIS	*OSSA CINGULI EXTREMITATUM PELVINARUM*	*CINGULUM MEMBRI INFERIORIS*
OS COXAE	OS COXAE	OS COXAE
Foramen obturatum	Foramen obturatum	Foramen obturatum
Acetabulum	Acetabulum	Acetabulum
Incisura acetabuli	Incisura acetabuli	Incisura acetabuli
Facies lunata	Facies lunata	Facies lunata
Fossa acetabuli	Fossa acetabuli	Fossa acetabuli
OS ILIUM	OS ILIUM	OS ILIUM
Corpus ossis ilium	Corpus ossis ilium	Corpus ossis ilii
Ala ossis ilium	Ala ossis ilium	Ala ossis ilii
Crista iliaca	Crista ilica	Crista iliaca
Labium externum ..	Labium externum ..	Labium externum
Linea intermedia	Linea intermedia	Linea intermedia
Labium internum ...	Labium internum ...	Labium internum
Spina iliaca ant. sup. .	Spina ilica ventralis ...	Spina iliaca ant. sup.
Spina iliaca ant. inf. ..	Tuberculum ilicum ...	Spina iliaca ant. inf.
Spina iliaca post. sup.	Spina ilica dorsalis cranialis	Spina iliaca post. sup.
Spina iliaca post. inf. .	Spina ilica dorsalis caudalis	Spina iliaca post. inf.

BNA	JNA	PNA
.....	.....	Facies glutea
Linea glutaea ant.	Linea glutaea cranialis .	Linea glutea ant.
Linea glutaea post. ...	Linea glutaea dorsalis ..	Linea glutea post.
Linea glutaea inf.	Linea glutaea supra-acetabularis	Linea glutea inf.
Fossa iliaca	Fossa iliaca	Fossa iliaca
Linea arcuata	Linea arcuata	Linea arcuata
Sulci paraglenoidales ..	Sulcus juxtaauricularis .	.....
.....	.....	Facies sacropelvina
Facies auricularis ...	Facies auricularis ...	Facies auricularis
Tuberositas iliaca ...	Tuberositas ilica	Tuberositas iliaca
OS ISCHII	OS ISCHII	OS ISCHII
Corpus ossis ischii	Corpus ossis ischii	Corpus ossis ischii
Spina ischiadica	Spina ossis ischii	Spina ischiadica
Incisura ischiadica major	Incisura ischiadica major	Incisura ischiadica major
Incisura ischiadica minor	Incisura ischiadica minor	Incisura ischiadica minor
.....	Ramus ossis ischii	.....
Ramus superior ossis ischii	Pars acetabularis (rami ossis ischii)	.....
Ramus inferior ossis ischii	Pars pubica (rami ossis ischii)	Ramus ossis ischii
Tuber ischiadicum	Tuber ossis ischii	Tuber ischiadicum
OS PUBIS	OS PUBIS	OS PUBIS
.....	.....	Crista pubica*
Corpus ossis pubis	Corpus ossis pubis	Corpus ossis pubis
Eminentia iliopectinea .	Eminentia iliopectinea .	Eminentia iliopubica*
.....	Ramus ossis pubis	.....
Ramus superior ossis pubis	Pars acetabularis (rami ossis pubis)	Ramus superior ossis pubis
Pecten ossis pubis	Pecten ossis pubis	Pecten ossis pubis
Crista obturatoria	Crista obturatoria	Crista obturatoria
Tuberculum pubicum	Tuberculum pubicum	Tuberculum pubicum
Sulcus obturatorius ...	Sulcus obturatorius ...	Sulcus obturatorius

BNA	JNA	PNA
Tuberculum obturatorium ant.	Tuberculum obturatorium pubicum	Tuberculum obturatorium ant.
(Tuberculum obturatorium post.)	Tuberculum obturatorium ischiadicum ...	(Tuberculum obturatorium post.)
Ramus inferior ossis pubis	Pars symphysica (rami ossis pubis)	Ramus inferior ossis pubis
.....	Crista phallica	.....
Facies symphyseos	Facies symphyseos	Facies symphysialis
PELVIS	PELVIS	PELVIS
Arcus pubis	Arcus pubis	Arcus pubis
Angulus pubis	Angulus pubis	Angulus subpubicus
Pelvis major	Pelvis major	Pelvis major
Pelvis minor	Pelvis minor	Pelvis minor
Linea terminalis	Linea terminalis	Linea terminalis
Pars sacralis	Pars sacralis	.....
Pars iliaca	Pars iliaca	.....
Pars pubica	Pars pubica	.....
Apertura pelvis (minoris) sup.	Aditus pelvis	Apertura pelvis sup.*
Apertura pelvis (minoris) inf.	Exitus pelvis	Apertura pelvis inferior*
Axis pelvis	Axis pelvis	Axis pelvis
Conjugata	{ Diameter mediana .... } { Conjugata vera ..... }	Conjugata
Diameter transversa	Diameter transversa	Diameter transversa
.....	Diameter diagonalis	.....
Diameter obliqua	Diameter obliqua	Diameter obliqua
Inclinatio pelvis	.....	Inclinatio pelvis
SKELETON EXTREMITATIS INFERIORIS LIBERAE	*OSSA EXTREMITATIS PELVINAE LIBERAE*	*SKELETON MEMBRI INFERIORIS LIBERI*
FEMUR	OS FEMORIS = FEMUR	FEMUR
Epiphysis proximalis°		
Caput femoris	Caput femoris	Caput femoris
Fovea capitis femoris	Fovea capitis femoris	Fovea capitis femoris

BNA	JNA	PNA
Collum femoris	Collum femoris	Collum femoris
Trochanter major	Trochanter major	Trochanter major
Trochanter minor	Trochanter minor	Trochanter minor
Fossa trochanterica ...	Fossa trochanterica ...	Fossa trochanterica
Linea intertrochanterica	Linea intertrochanterica	Linea intertrochanterica
Crista intertrochanterica	Crista intertrochanterica	Crista intertrochanterica
Corpus femoris	Corpus femoris	Corpus femoris
Linea aspera	Crista femoris	Linea aspera
Labium mediale	Labium tibiale	Labium mediale
Labium laterale	Labium fibulare	Labium laterale
(Trochanter tertius) ...	var. Trochanter tertius	(Trochanter tertius)
Tuberositas glutaea ...	Tuberositas glutaea ...	Tuberositas glutea
Linea pectinea	Linea pectinea	Linea pectinea
.....	.....	Tuberculum adductorium
Epiphysis distalis°		
Epicondylus medialis ..	Epicondylus tibialis ...	Epicondylus medialis
Epicondylus lateralis ..	Epicondylus fibularis ..	Epicondylus lateralis
Condylus medialis	Condylus tibialis	Condylus medialis
Condylus lateralis	Condylus fibularis	Condylus lateralis
.....	Sulcus popliteus	.....
Fossa intercondyloidea.	Fossa intercondylica ...	Fossa intercondylaris
Linea intercondyloidea.	Linea intercondylica ...	Linea intercondylaris
Planum popliteum	Planum popliteum	Facies poplitea
Facies patellaris	Facies patellaris	Facies patellaris
.....	OSSA CRURIS	.....
TIBIA	TIBIA	TIBIA
Epiphysis proximalis°		
Condylus medialis	Condylus tibialis	Condylus medialis
Condylus lateralis	Condylus fibularis	Condylus lateralis
.....	Tuberositas tractus iliotibialis	.....
Facies articularis sup. .	Facies articulares proximales	Facies articularis sup.
Eminentia intercondyloidea	Eminentia intercondylica	Eminentia intercondylaris

BNA	JNA	PNA
Tuberculum intercondyloideum med. ..	Tuberculum intercondylicum tibiale	Tuberculum intercondylare med.
Tuberculum intercondyloideum lat. ...	Tuberculum intercondylicum fibulare ..	Tuberculum intercondylare lat.
Fossa intercondyloidea ant.	Fossa intercondylica ant.	Area intercondylaris ant.
Fossa intercondyloidea post.	Fossa intercondylica post.	Area intercondylaris post.
.....	Facies articularis fibularis tibiae	Facies art. fibularis
Margo infraglenoidalis .	.....	.....
Corpus tibiae	Corpus tibiae	Corpus tibiae
Tuberositas tibiae	Tuberositas tibiae	Tuberositas tibiae
Facies medialis	Facies tibialis	Facies medialis
Facies posterior	Facies posterior	Facies posterior
Facies lateralis	Facies fibularis	Facies lateralis
Margo medialis	Margo tibialis	Margo medialis
Crista anterior	Crista anterior	Margo anterior
Crista interossea	Crista interossea	Margo interosseus*
Linea poplitea	Linea poplitea	Linea m. solei
Epiphysis distalis°		
Malleolus medialis	Malleolus tibiae	Malleolus medialis
Sulcus malleolaris ...	Sulcus malleoli tibiae	Sulcus malleolaris
Incisura fibularis	Incisura fibularis	Incisura fibularis
Facies articularis inf. ..	Facies articularis distalis	Facies articularis inf.
Facies articularis malleolaris	Facies articularis malleoli	Facies art. malleoli*
FIBULA	FIBULA	FIBULA
Capitulum fibulae	Capitulum fibulae	Caput fibulae
Apex capituli fibulae ..	Apex capituli fibulae ..	Apex capitis fibulae

BNA	JNA	PNA
Facies articularis capituli	Facies articularis capituli	Facies articularis capitis fibulae
Corpus fibulae	Corpus fibulae	Corpus fibulae
Crista interossea	Crista interossea	Margo interosseus*
Crista anterior	Crista anterior	Margo anterior
Crista lateralis	Crista fibularis	Margo posterior
Crista medialis	Crista tibialis	Crista medialis
Facies medialis	Facies tibialis	Facies medialis
Facies lateralis	Facies fibularis	Facies lateralis
Facies posterior	Facies posterior	Facies posterior
Malleolus lateralis	Malleolus fibulae	Malleolus lateralis
Facies articularis malleolaris	Facies art. malleoli ...	Facies articularis malleoli*
.....	Fossa malleoli fibulae .	Fossa malleoli lateralis . .
.....	Sulcus malleoli fibulae	.....
PATELLA	PATELLA	PATELLA
Basis patellae	Basis patellae	Basis patellae
Apex patellae	Apex patellae	Apex patellae
Facies articularis	Facies articularis	Facies articularis
.....	.....	Facies anterior
TARSUS	TARSUS	TARSUS
OSSA TARSI	OSSA TARSI	OSSA TARSI
.....	Ossa tarsi proximalia	.....
.....	Ossa tarsi distalia	.....
.....	Ossa tarsi accessoria	.....
TALUS	TALUS	TALUS
Caput tali	Caput tali	Caput tali
Facies articularis navicularis	Facies articularis navicularis	Facies articularis navicularis
Collum tali	Collum tali	Collum tali
Corpus tali	Corpus tali	Corpus tali

BNA	JNA	PNA
Trochlea tali	Trochlea tali	Trochlea tali
Facies malleolaris... med.....	Facies malleolaris tibialis	Facies malleolaris... med.
Facies malleolaris lat.	Facies malleolaris fibularis	Facies malleolaris lat.
Facies superior	Facies proximalis ...	Facies superior
.....	Facies articularis pro ligamento calcaneonaviculari	.....
Sulcus tali	Sulcus tali	Sulcus tali
Processus lateralis tali ..	Processus fibularis tali ...	Processus lateralis tali
.....	Facies articularis calcanearis distalis bipartita ...	.....
Facies articularis calcanea post.....	Facies articularis calcanearis proximalis	Facies articularis calcanea post.
Facies articularis calcanea media	Facies articularis calcanearis media	Facies articularis calcanea media
Sulcus m. flexoris hallucis longi	Sulcus tendinis musculi flexoris hallucis longi ..	Sulcus tendinis m. flexoris hallucis longi
Facies articularis calcanea ant.	Facies articularis calcanearis distalis	Facies articularis calcanea ant.
Processus posterior tali	Processus proximalis tali	Processus posterior tali
.....	Tuberculum fibulare (processus proximalis tali)	Tuberculum laterale
.....	Tuberculum tibiale (processus proximalis tali)	Tuberculum mediale
(Os trigonum)	.....	(Os trigonum)
CALCANEUS	CALCANEUS	CALCANEUS (OS CALCIS)*
Tuber calcanei	Tuber calcanei	Tuber calcanei

BNA	JNA	PNA
Processus med. tuberis calcanei	Tuberculum tibiale tuberis calcanei	Processus med. tuberis calcanei
Processus lat. tuberis calcanei	Tuberculum fibulare tuberis calcanei	Processus lat. tuberis calcanei
Corpus calcanei	Corpus calcanei	.....
Sustentaculum tali	Sustentaculum tali	Sustentaculum tali*
Sulcus m. flexoris hallucis longi	Sulcus tendinis m. flexoris hallucis longi	Sulcus tendinis m. flexoris hallucis longi
Sulcus calcanei	Sulcus calcanei	Sulcus calcanei
Sinus tarsi	Sinus tarsi	Sinus tarsi
Facies articularis ant. .	Facies articularis talaris distalis	Facies articularis talaris ant.
Facies articularis media	Facies articularis talaris media	Facies articularis talaris media
Facies articularis post.	Facies articularis talaris proximalis	Facies articularis talaris post.
Sulcus m. peronaei (longi)	Sulcus tendinis musculi fibularis longi	Sulcus tendinis m. peronei (fibularis) longi**
(Processus trochlearis)	var. Processus trochlearis	Trochlea peronealis (fibularis)
Facies articularis cuboidea	Facies articularis cuboidea	Facies art. cuboidea
.....	var. Facies articularis talaris distalis bipartita	.....
OS NAVICULARE PEDIS	OS NAVICULARE PEDIS	OS NAVICULARE
Tuberositas ossis navicularis	Tuberositas ossis navicularis	Tuberositas ossis navicularis

BNA	JNA	PNA
OS CUNEIFORME PRIMUM OS CUNEIFORME SECUNDUM OS CUNEIFORME TERTIUM	OS CUNEIFORME PRIMUM OS CUNEIFORME SECUNDUM OS CUNEIFORME TERTIUM	OS CUNEIFORME MEDIALE OS CUNEIFORME INTERMEDIUM OS CUNEIFORME LATERALE
OS CUBOIDEUM	OS CUBOIDES	OS CUBOIDEUM
Sulcus m. peronaei (longi)	Sulcus tendinis m. fibularis longi	Sulcus tendinis m. peronei longi*
Tuberositas ossis cuboidei	Tuberositas ossis cuboidis	Tuberositas ossis cuboidei
METATARSUS	METATARSUS	METATARSUS
.....	OSSA METATARSI	.....
Ossa metatarsalia I–V. .	Os metatarseum primum (secundum, tertium, quartum, quintum)	Ossa metatarsalia I–V.
Basis	Basis	Basis
.....	Facies articularis	.....
Corpus	Corpus	Corpus
Capitulum	Capitulum	Caput
Tuberositas ossis metatarsalis I.	Tuberositas ossis metatarsi primi	Tuberositas ossis metatarsalis I.
Tuberositas ossis metatarsalis V.	Tuberositas ossis metatarsi quinti	Tuberositas ossis metatarsalis V.
PHALANGES DIGITORUM PEDIS	OSSA DIGITORUM PEDIS	OSSA DIGITORUM PEDIS
Phalanx prima	Phalanx proximalis	Phalanx proximalis
Phalanx secunda	Phalanx media	Phalanx media
Phalanx tertia	Phalanx distalis	Phalanx distalis
Tuberositas unguicularis	Tuberositas unguicularis	Tuberositas phalangis distalis
Basis phalangis	Basis phalangis	Basis phalangis
.....	Facies articularis	.....
Corpus phalangis	Corpus phalangis	Corpus phalangis
Trochlea phalangis	Trochlea phalangis	Caput phalangis
Ossa sesamoidea	Ossa sesamoidea	Ossa sesamoidea

BNA	JNA	PNA
DIGITI PEDIS	DIGITI PEDIS	DIGITI PEDIS
Digiti II–IV. (pedis)	Digitus pedis secundus (tertius, quartus)	Digiti II–IV.
Digitus minimus (Digitus V.)	Digitus pedis minimus (Digitus pedis quintus) . .	Digitus minimus (Digitus V.)
Hallux (Digitus I.)	Hallux (Digitus pedis primus)	Hallux (Digitus I.)
Margines laterales	Margines fibulares	Margines laterales
Margines mediales	Margines tibiales	Margines mediales
OSSA TRUNCI°	OSSA TRUNCI°	OSSA TRUNCI°
COLUMNA VERTEBRALIS	*COLUMNA VERTEBRALIS*	*COLUMNA VERTEBRALIS*
VERTEBRAE	VERTEBRAE°	VERTEBRAE°
Corpus vertebrae	Corpus vertebrae	Corpus vertebrae
.....	Facies caudalis	.....
.....	Facies cranialis	.....
Arcus vertebrae	Arcus vertebrae	Arcus vertebrae*
.....	.....	Lamina arcus vertebrae
Radix arcus vertebrae	Radix arcus vertebrae . .	Pediculus arcus vertebrae
Incisura vertebralis superior	Incisura vertebrae cranialis	Incisura vertebralis superior
Incisura vertebralis inferior	Incisura vertebrae caudalis	Incisura vertebralis inferior
Foramen vertebrale	Foramen vertebrae	Foramen vertebrale
Canalis vertebralis	Canalis vertebralis	Canalis vertebralis
Processus articulares superiores	Processus articularis cranialis	Processus articularis sup. (zygapophysis)**
Facies articulares superiores	Facies articularis cranialis	.....

BNA	JNA	PNA
Processus articulares inferiores	Processus articularis caudalis	Processus articularis inf. (zygapophysis)**
Facies articulares inferiores	Facies articularis caudalis	.....
Processus transversus	Processus transversus vertebrae thoracicae	Processus transversus
Processus spinosus	Processus spinalis	Processus spinosus
Foramen intervertebrale .	Foramen intervertebrale .	Foramen intervertebrale
Vertebrae cervicales	Vertebrae vervicales	Vertebrae cervicales
.....	Processus costotransversarius vertebrae cervicalis	.....
Foramen transversarium	Foramen costotransversarium vertebrae cervicalis	Foramen transversarium
Sulcus nervi spinalis ..	Sulcus n. spinalis	Sulcus nervi spinalis
Tuberculum anterius ..	Tuberculum ventrale vertebrae cervicalis	Tuberculum anterius (vertebrarum cervicalium)
Tuberculum posterius .	Tuberculum dorsale vertebrae cervicalis	Tuberculum posterius (vertebrarum cervicalium)
Tuberculum caroticum (vertebrae cervicalis VI.)	Tuberculum caroticum vertebrae cervicalis VI.	Tuberculum caroticum (vertebrae cervicalis VI.)*
Vertebra prominens ...	Vertebra prominens ...	Vertebra prominens
Vertebrae thoracales	Vertebrae thoracicae	Vertebrae thoracicae
Fovea costalis sup.	Fovea costalis cranialis	Fovea costalis sup.
Fovea costalis inf.	Fovea costalis caudalis	Fovea costalis inf.
Fovea costalis transversalis	Facies costalis processus transversi vertebrae thoracicae	Fovea costalis transversalis

BNA	JNA	PNA
Vertebrae lumbales	Vertebrae lumbales	Vertebrae lumbales
Processus costarius	Processus costarius vertebrae lumbalis	Processus costarius
Processus accessorius .	Processus accessorius .	Processus accessorius (vertebrarum lumbalium)*
Processus mamillaris ..	Processus mamillaris ..	Processus mamillaris
Vertebrae sacrales	Vertebrae sacrales	Vertebrae sacrales
Vertebrae coccygeae	Vertebrae caudales = coccygicae	Vertebrae coccygeae
ATLAS	ATLAS	ATLAS
Arcus anterior	Arcus ventralis	Arcus anterior
Tuberculum anterius ..	Tuberculum ventrale ..	Tuberculum anterius
Fovea dentis	Facies articularis dentalis	Fovea dentis
Arcus posterior	Arcus dorsalis	Arcus posterior
Tuberculum posterius .	Tuberculum dorsale ...	Tuberculum posterius
Sulcus arteriae vertebralis	Sulcus a. vertebralis ...	Sulcus a. vertebralis
Massa lateralis	Massa lateralis	Massa lateralis
Foveae articulares superiores	Fovea articularis cranialis	Fovea articularis superior
Facies articulares inferiores	Facies articulares caudales	Fovea articularis inferior
EPISTROPHEUS	EPISTROPHEUS	AXIS
Dens	Dens	Dens
.....	Apex dentis	.....
Facies articularis ant. .	Facies articularis ventralis	Facies articularis ant.
Facies articularis post.	Facies articularis dors.	Facies articularis post.
.....	Facies articularis lat. .	.....
OS SACRUM	OS SACRUM	OS SACRUM
Basis ossis sacri	Facies terminalis cranialis	Basis ossis sacri
Processus articularis sup.	Processus articularis cranialis	Processus articularis sup.

BNA	JNA	PNA
Promontorium	Promontorium	Promontorium
Apex ossis sacri	Apex ossis sacri	Apex ossis sacri
Pars lateralis	Pars lateralis	Pars lateralis
Facies auricularis	Facies auricularis	Facies auricularis
Tuberositas sacralis ...	Tuberositas sacralis ...	Tuberositas sacralis
Foramina intervertebralia	Foramina intervertebralia	Foramina intervertebralia
Facies pelvina	Facies pelvina	Facies pelvina
Foramina sacralia anteriora	Foramina sacralia pelvina	Foramina sacralia pelvina
Lineae transversae	Lineae transversae	Lineae transversae
Facies dorsalis	Facies dorsalis	Facies dorsalis
Foramina sacralia posteriora	Foramina sacralia dorsalia	Foramina sacralia dorsalia
Crista sacralis media	Crista sacralis media	Crista sacralis mediana
Cristae sacrales laterales	Crista sacralis lat.	Crista sacralis lateralis
Cristae sacrales articulares	Crista sacralis articularis	Crista sacralis intermedia
Cornua sacralia	Cornu ossis sacri	Cornu sacrale
Canalis sacralis	Canalis sacralis	Canalis sacralis
Hiatus sacralis	Hiatus canalis sacralis ...	Hiatus sacralis
.....	Facies terminalis caudalis	.....
OS COCCYGIS	OS COCCYGIS	OS COCCYGIS
Cornua coccygea	Cornua ossis coccygis ...	Cornu coccygeum
.....	Facies terminalis sacralis	.....
THORAX	*THORAX*	*THORAX*
COSTAE	COSTAE	COSTAE
Costae verae	Costae sternales	Costae verae
Costae spuriae	Costae arcuariae	Costae spuriae
.....	Costae arcuariae affixae .	.....
.....	Costae arcuariae fluctuantes	.....

BNA	JNA	PNA
Os costale	Os costale	Os costale
Cartilago costalis	Cartilago costalis	Cartilago costalis
Capitulum costae	Capitulum costae	Caput costae
Facies articularis capituli costae	Facies articulares capituli costae	Facies articularis capitis costae
Crista capituli	Crista capituli	Crista capitis costae
Collum costae	Collum costae	Collum costae
Crista colli costae ...	Crista colli costae ...	Crista colli costae
Corpus costae	Corpus costae	Corpus costae
Tuberculum costae	Tuberculum costae ...	Tuberculum costae
Facies articularis tuberculi costae	Facies articularis tuberculi costae	Facies articularis tuberculi costae
Angulus costae	Angulus costae	Angulus costae
Tuberculum scaleni (Lisfranci)	Tuberculum musculi scaleni	Tuberculum m. scaleni anterioris
Sulcus subclaviae	Sulcus arteriae subclaviae	Sulcus a. subclaviae
.....	.....	Sulcus v. subclaviae*
Tuberositas costae II. ...	Tuberositas costae secundae	Tuberositas m. serrati anterioris
Sulcus costae	Sulcus costae	Sulcus costae
STERNUM	STERNUM	STERNUM
Manubrium sterni	Manubrium sterni	Manubrium sterni
Incisura clavicularis ...	Incisura clavicularis ...	Incisura clavicularis
Incisura jugularis	Incisura jugularis	Incisura jugularis
Angulus sterni	Angulus sterni	Angulus sterni
Synchondrosis sternalis ..	Symphysis sterni	Vide: Juncturae thoracis**
Corpus sterni	Corpus sterni	Corpus sterni
Incisurae costales	Incisurae costales	Incisurae costales
Planum sternale	Planum sternale	.....
Processus xiphoideus	Processus ensiformis	Processus xiphoideus
(Ossa suprasternalia)	(Ossa suprasternalia)	(Ossa suprasternalia)
CAVUM THORACIS	CAVUM THORACIS	CAVUM THORACIS
Apertura thoracis sup. ..	Apertura thoracis cranialis	Apertura thoracis superior

BNA	JNA	PNA
Apertura thoracis inferior	Apertura thoracis caudalis	Apertura thoracis inf.
Arcus costarum	Arcus costarum	Arcus costalis
Spatia intercostalia	Spatia intercostalia	Spatium intercostale
Angulus infrasternalis ...	Angulus arcuum costarum	Angulus infrasternalis
Sulcus pulmonalis	.....	Sulcus pulmonalis
OSSA CRANII	OSSA CRANII	OSSA CRANII
CRANIUM CEREBRALE	.....	.....
OS OCCIPITALE	OS OCCIPITALE	OS OCCIPITALE
Foramen occipitale magnum	Foramen occipitale magnum	Foramen magnum
Os basilare	.....	.....
Pars basilaris	Pars basialis	Pars basilaris
Clivus	.....	vide: Cranium
Sulcus petrosus inf. ...	Sulcus petrosus	Sulcus sinus petrosi inferioris
Tuberculum pharyngeum	Tuberculum pharyngicum	Tuberculum pharyngeum
Pars lateralis	Pars lateralis	Pars lateralis
Incisura jugularis	Incisura jugularis	Incisura jugularis
Processus intrajugularis	Processus intrajugularis	Proc. intrajugularis
Processus jugularis	Processus jugularis	Processus jugularis
Condylus occipitalis ..	Condylus occipitalis ..	Condylus occipitalis
Canalis condyloideus ..	Canalis condylicus	Canalis condylaris
Canalis hypoglossi	Canalis nervi hypoglossi	Canalis hypoglossi
Tuberculum jugulare ..	Tuberculum jugulare ..	Tuberculum jugulare
Fossa condyloidea	Fossa condylica	Fossa condylaris
Squama occipitalis	Squama occipitalis	Squama occipitalis
Planum occipitale	Planum occipitale	.....
Planum nuchale	Planum nuchale	.....
Protuberantia occipitalis ext.	Protuberantia occipitalis ext.	Protuberantia occipitalis ext. Inion*

BNA	JNA	PNA
(Torus occipitalis)	.....	.....
Crista occipitalis ext. ..	Crista occipitalis ext. ..	(Crista occipitalis ext.)
.....	.....	(var. Crista occipitalis int.)
Linea nuchae suprema	Linea nuchalis supraterminalis	Linea nuchae suprema
Linea nuchae superior .	Linea nuchalis terminalis	Linea nuchae superior
Linea nuchae inferior .	Linea plani nuchalis ..	Linea nuchae inferior
Eminentia cruciata	.....	Eminentia cruciformis
Protuberantia occipitalis int.	Protuberantia occipitalis int.	Protuberantia occipitalis int.
.....	Fossa occipitalis cerebellaris	.....
.....	Fossa occipitalis cerebralis	.....
Sulcus sagittalis	Sulcus sagittalis	Sulcus sinus sagittalis superioris
Sulcus transversus	Sulcus transversus	Sulcus sinus transversi
.....	Sulcus sigmoides	Sulcus sinus sigmoidei
(Processus paramastoideus)	(Processus paramastoideus)	(Proc. paramastoideus)
Margo mastoideus	Margo mastoideus	Margo mastoideus
Margo lambdoideus	Margo lambdoideus	Margo lambdoideus
(Os interparietale)	var. Os interparietale	(Os interparietale)
OS SPHENOIDALE	OS SPHENOIDES	OS SPHENOIDALE
Corpus	Corpus	Corpus
Clivus	Clivus	.....*
.....	Planum sphenoideum ..	.....
Sinus sphenoidalis	Sinus sphenoideus	Sinus sphenoidalis
Conchae sphenoidales	Concha ossis sphenoidis	Concha sphenoidalis
Septum sinuum sphenoidalium	Septum sinuum sphenoideorum	Septum sinuum sphenoidalium

BNA	JNA	PNA
Apertura sinus sphenoidalis	Apertura sinus sphenoidei	Apertura sinus sphenoidalis
Sella turcica	Sella turcica	Sella turcica
Dorsum sellae	Dorsum sellae	Dorsum sellae
Tuberculum sellae ...	Tuberculum sellae ...	Tuberculum sellae
Fossa hypophyseos ..	Fossa hypophyseos ..	Fossa hypophysialis*
Processus clinoideus posterior	Processus dorsi sellae	Processus clinoideus posterior
Processus clinoideus medius	Processus sellae medius	(Processus clinoideus medius)*
Sulcus caroticus	Sulcus caroticus	Sulcus caroticus
Lingula sphenoidalis .	Lingula sphenoidea .	Lingula sphenoidalis
Crista sphenoidalis ...	Crista sphenoidea	Crista sphenoidalis
Rostrum sphenoidale .	Rostrum sphenoideum	Rostrum sphenoidale
Ala parva	Ala parva	Ala minor
.....	Margo frontalis	.....
.....	Limbus sphenoideus ...	.....
Sulcus chiasmatis	Sulcus fasciculi optici . .	Sulcus chiasmatis*
Foramen opticum	Canalis fasciculi optici .	Canalis opticus
Processus clinoideus anterior	Processus alae parvae . .	Processus clinoideus anterior
Fissura orbitalis superior	Fissura orbitalis cerebralis	Fissura orbitalis superior
Ala magna	Ala magna	Ala major
Facies cerebralis	Facies cerebralis	Facies cerebralis
Impressiones digitatae	Impressiones gyrorum	Vide: Cranium
		Jugum sphenoidale*
		.....
Juga cerebralia	Juga cerebralia	Foramen rotundum
Foramen rotundum .	Canalis rotundus	Foramen ovale
Foramen ovale	Foramen ovale	Foramen spinosum
Foramen spinosum ..	Foramen spinae	Facies maxillaris*
Facies sphenomaxillaris	Facies sphenomaxillaris	Facies temporalis
Facies temporalis	Facies temporalis	Crista infratemporalis
Crista infratemporalis	Crista infratemporalis	

BNA	JNA	PNA
.....	Facies infratemporalis .	.....
Facies orbitalis	Facies orbitalis	Facies orbitalis
Angulus parietalis	Angulus parietalis	Margo parietalis
Margo squamosus	Margo squamalis	Margo squamosus
Margo frontalis	Margo frontalis	Margo frontalis
Margo zygomaticus ...	Margo zygomaticus ...	Margo zygomaticus
Spina angularis	Spina ossis sphenoidis .	Spina ossis sphenoidalis
Processus pterygoideus ..	Processus pterygoides	Processus pterygoideus
Lamina lateralis processus pterygoidei	Lamina lateralis processus pterygoidis	Lamina lateralis processus pterygoidei
Lamina medialis processus pterygoidei	Lamina medialis processus pterygoidis	Lamina medialis processus pterygoidei
Hamulus pterygoideus	Hamulus pterygoideus	Hamulus pterygoideus
Sulcus hamuli pterygoidei	Sulcus hamuli pterygoidei	Sulcus hamuli pterygoidei
Fissura pterygoidea ...	Incisura pterygoidea ...	Incisura pterygoidea*
Fossa scaphoidea	Fossa scaphoides	Fossa scaphoidea
Processus vaginalis ...	Processus vaginalis ...	Processus vaginalis
Canalis pharyngeus ...	Canalis pharyngicus ..	Sulcus palatovaginalis*
Canalis basipharyngeus.	Canalis basipharyngicus	Sulcus vomerovaginalis*
Fossa pterygoidea	Fossa pterygoidea	Fossa pterygoidea
Canalis pterygoideus (Vidii)	Canalis pterygoideus ..	Canalis pterygoideus
Sulcus tubae auditivae	Sulcus tubae pharyngotympanicae	Sulcus tubae auditivae
Sulcus pterygopalatinus	Sulcus pterygopalatinus	..... *
Processus pterygospinosus (Civinini)	(Processus pterygospinalis)	Processus pterygospinosus
OS TEMPORALE	OS TEMPORALE	OS TEMPORALE
.....	Pars squamalis	.....
Squama temporalis	Squama temporalis	Pars squamosa
Facies temporalis	Facies temporalis	Facies temporalis

BNA	JNA	PNA
Sulcus arteriae temporalis mediae	Sulcus a. temporalis mediae	Sulcus a. temporalis mediae
Facies cerebralis	Facies cerebralis	Facies cerebralis
Processus zygomaticus .	Processus zygomaticus .	Processus zygomaticus
Fossa mandibularis ...	Fossa mandibularis ...	Fossa mandibularis
Facies articularis	Facies articularis	Facies articularis
.....	Processus retroarticularis	.....
Tuberculum articulare .	Tuberculum articulare	Tuberculum articulare
Margo parietalis	Margo parietalis	Margo parietalis
Incisura parietalis	Incisura parietalis	Incisura parietalis
Margo sphenoidalis ...	Margo sphenoideus ...	Margo sphenoidalis
.....	Linea temporalis	.....
.....	Linea temporalis fascialis	.....
Pars petrosa (pyramis) ..	Pars petromastoidea	Pars petrosa
.....	Pyramis	.....
Apex pyramidis	Apex pyramidis	Apex partis petrosae
Facies anterior pyramidis	Facies cerebralis (anterior interna) pyramidis	Facies anterior partis petrosae
Impressio trigemini ..	Impressio trigemini ..	Impressio trigemini
.....	Apertura interna canalis carotici	.....
Sulcus n. petrosi superficialis majoris .	Sulcus n. petrosi superficialis majoris .	Sulcus n. petrosi majoris
.....	Canaliculus n. petrosi superficialis minoris	.....
Sulcus n. petrosi superficialis minoris .	Sulcus n. petrosi superficialis minoris .	Sulcus n. petrosi minoris
Apertura superior canaliculi tympanici .	Apertura interna canaliculi nervi petrosi superficialis minoris	.....

BNA	JNA	PNA
Eminentia arcuata ..	Eminentia arcuata ..	Eminentia arcuata
Tegmen tympani	Tegmen tympani	Tegmen tympani
Canalis facialis (Falloppii)	Canalis nervi facialis	Canalis facialis*
Hiatus canalis facialis	Hiatus canalis nervi facialis	Hiatus canalis n. petrosi majoris*
Geniculum canalis facialis	Geniculum canalis nervi facialis	Geniculum canalis facialis*
.....	.....	Hiatus canalis n. petrosi minoris*
Angulus superior pyramidis	Crista pyramidis	Margo superior partis petrosae
Angulus anterior pyramidis	.....	.....
Angulus posterior pyramidis	.....	Margo posterior partis petrosae
Sulcus petrosus inferior	Sulcus petrosus	Sulcus sinus petrosi inferioris
Sulcus petrosus superior	Sulcus cristae pyramidis	Sulcus sinus petrosi superioris
Facies posterior pyramidis	Facies cerebellaris (posterior interna) pyramidis	Facies posterior partis petrosae
Porus acusticus internus	Porus acusticus internus	Porus acusticus internus
Meatus acusticus internus	Meatus acusticus internus	Meatus acusticus internus
Fossa subarcuata ...	Fossa subarcuata ...	Fossa subarcuata
.....	Hiatus subarcuatus ..	.....
Aquaeductus vestibuli	Canaliculus vestibuli	Aqueductus vestibuli*

BNA	JNA	PNA
Apertura ext. aquaeductus vestibuli ..	Apertura interna canaliculi vestibuli ..	Apertura ext. aqueductus vestibuli*
.....	.....	Sulcus sinus sigmoidei
Facies inferior pyramidis	Facies basialis pyramidis	Facies inferior partis petrosae
Incisura jugularis	Incisura jugularis	Incisura jugularis
Processus intrajugularis.	Processus intrajugularis	Processus intrajugularis.
Fossa jugularis	Fossa jugularis	Fossa jugularis
Canaliculus mastoideus.	Canaliculus mastoideus.	Canaliculus mastoideus.
Sulcus canaliculi mastoidei	Sulcus canaliculi mastoidei	.....
.....	Pars hyoidea	.....
Processus styloideus ..	Processus styloides	Processus styloideus
Vagina processus styloidei	Vagina (Semivagina) processus styloidis ..	Vagina processus styloidei
Foramen stylomastoideum	Foramen stylomastoideum	Foramen stylomastoideum
Fossula petrosa	Fossula petrosa	Fossula petrosa
Canaliculus tympanicus	Canaliculus tympanicus	Canaliculus tympanicus
	Apertura externa canalis carotici	.....
Apertura inf. canaliculi tympanici	Apertura ext. canaliculi tympanici	.....
Apertura sup. canaliculi tympanici	Apertura int. canaliculi nervi petrosi superficialis minoris	.....
Canaliculus cochleae ..	Canaliculus cochleae ..	Canaliculus cochleae
Apertura ext. canaliculi cochleae	Apertura ext. canaliculi cochleae	Apertura ext. canaliculi cochleae
Canalis caroticus	Canalis caroticus	Canalis caroticus

BNA	JNA	PNA
Canaliculi caroticotympanici	Canaliculi caroticotympanici	Canaliculi caroticotympanici
Canalis musculotubarius	Canalis musculotubalis.	Canalis musculotubarius
Semicanalis m. tensoris tympani	Semicanalis musculi tensoris tympani	Semicanalis m. tensoris tympani
Semicanalis tubae auditivae	Semicanalis tubae pharyngotympanicae ...	Semicanalis tubae auditivae
Septum canalis musculotubarii	Septum canalis musculotubalis	Septum canalis musculotubarii
Canaliculus chordae tympani	Canaliculus chordae tympani	Canaliculus chordae tympani*
Fissura petrotympanica (Glaseri)	Fissura petrotympanica.	Fissura petrotympanica.
Fissura petrosquamosa	Fissura petrosquamalis.	Fissura petrosquamosa.
	Facies tympanica pyramidis	.....
Pars tympanica	Pars tympanica	Pars tympanica
Annulus tympanicus ...	Anulus tympanicus	Anulus tympanicus
.....	Sulcus anuli tympanici	.....
Spina tympanica minor	Spina tympanica minor	Spina tympanica minor
Spina tympanica major	Spina tympanica major	Spina tympanica major
.....	Crista tegmentalis	.....
.....	Crista tympanica	.....
Meatus acusticus externus	Meatus acusticus externus	Meatus acusticus externus
Sulcus tympanicus	Sulcus tympanicus	Sulcus tympanicus
.....	.....	Incisura tympanica**

BNA	JNA	PNA
Porus acusticus externus	Porus acusticus externus osseus	Porus acusticus externus
(Spina supra meatum)	Spina supra meatum	(Spina supra meatum)
Fissura tympanomastoidea	Fissura tympanomastoidea	Fissura tympanomastoidea
		Fissura tympanosquamosa
Pars mastoidea	Pars petromastoidea (mastoidea + petrosa)	
Margo occipitalis	Margo occipitalis	Margo occipitalis
Processus mastoideus	Processus mastoides	Processus mastoideus
Incisura mastoidea	Incisura mastoidea	Incisura mastoidea
Sulcus arteriae occipitalis	Sulcus arteriae occipitalis	Sulcus arteriae occipitalis
Sulcus sigmoideus	Sulcus sigmoides	
Foramen mastoideum	Foramen mastoideum	Foramen mastoideum
Cavum tympani (Vide: Organum auditus)	Cavum tympani	Cavum tympani. Vide: Organum vestibulocochleare*
OS PARIETALE	OS PARIETALE	OS PARIETALE
Facies parietalis	Facies parietalis	Facies externa
Tuber parietale	Tuber parietale	Tuber parietale
Linea temporalis sup.	Linea temporalis fascialis	Linea temporalis sup.
Linea temporalis inf.	Linea temporalis	Linea temporalis inf.
Facies cerebralis	Facies cerebralis	Facies interna
	Sulci arteriarum	
Sulcus transversus	Sulcus transversus	Sulcus sinus sigmoidei
Sulcus sagittalis	Sulcus sagittalis	Sulcus sinus sagittalis superioris*
(Foveolae granulares Pacchioni)	Foveolae granulares	Foveolae granulares
Foramen parietale	Foramen parietale	Foramen parietale
Margo occipitalis	Margo occipitalis	Margo occipitalis
Margo squamosus	Margo squamalis	Margo squamosus

BNA	JNA	PNA
Margo frontalis	Margo frontalis	Margo frontalis
Margo sagittalis	Margo sagittalis	Margo sagittalis
Angulus frontalis	Angulus frontalis	Angulus frontalis
Angulus occipitalis	Angulus occipitalis	Angulus occipitalis
Angulus sphenoidalis ...	Angulus sphenoideus	Angulus sphenoidalis
Angulus mastoideus	Angulus mastoideus	Angulus mastoideus
OS FRONTALE	OS FRONTALE	OS FRONTALE
Squama frontalis	Squama frontalis	Squama frontalis
Facies frontalis	Facies frontalis	Facies externa
Margo supraorbitalis	Margo aditus	Margo supraorbitalis .....
Incisura frontalis	Margo orbitalis	
	Incisura frontalis medialis	Incisura sive Foramen frontale*
Foramen supraorbitale	Incisura frontalis lat.	Foramen sive Incisura supraorbitalis*
Processus zygomaticus	Processus zygomaticus	Proc. zygomaticus
Linea temporalis	Linea temporalis	Linea temporalis
Facies temporalis ...	Facies temporalis ...	Facies temporalis
Arcus superciliaris ..	Arcus superciliaris ..	Arcus superciliaris
Glabella	Glabella	Glabella
Tuber frontale	Tuber frontale	Tuber frontale
Facies cerebralis	Facies cerebralis	Facies interna
Crista frontalis	Crista frontalis	Crista frontalis
Sulcus sagittalis	Sulcus sagittalis	Sulcus sinus sagittalis superioris
Foramen caecum ...	Foramen caecum ...	Foramen cecum*
Margo parietalis	Margo parietalis	Margo parietalis
.....	Margo sphenoideus .	.....
Pars orbitalis	Pars orbitalis	Pars orbitalis
Incisura ethmoidalis ...	Incisura ethmoidea	Incisura ethmoidalis
.....	Margo sphenoides ..	.....
Facies orbitalis	Facies orbitalis	Facies orbitalis
Fovea trochlearis ...	Foveola trochlearis ..	Fovea trochlearis
(Spina trochlearis) ..	var. Spina trochlearis	(Spina trochlearis)
Fossa glandulae lacrimalis	Fossa glandulae lacrimalis	Fossa gl. lacrimalis
.....	Foveolae ethmoideae	.....

BNA	JNA	PNA
Foramen ethmoidale ant.	Canalis orbitocranialis	Foramen ethmoidale ant.
Foramen ethmoidale post.	Canalis orbitoethmoideus	Foramen ethmoidale post.
Pars nasalis	Pars nasalis	Pars nasalis
Margo nasalis	Margo nasalis	Margo nasalis
Spina frontalis	Spina nasalis ossis frontalis	Spina nasalis
Sinus frontalis	Sinus frontalis	Sinus frontalis
Septum sinuum frontalium	Septum sinuum frontalium	Septum sinuum frontalium
.....	Apertura sinus frontalis	Apertura sinus frontalis
(Sutura frontalis)	(Sutura frontalis)	(Sutura frontalis) (Sutura metopica)*
OS ETHMOIDALE	OS ETHMOIDES	OS ETHMOIDALE
Lamina cribrosa	Lamina cribriformis	Lamina cribrosa
Crista galli	Crista galli	Crista galli
Processus alaris	Processus alaris	Ala cristae galli
Lamina perpendicularis .	Lamina mediana	Lamina perpendicularis
Labyrinthus ethmoidalis .	Labyrinthus ossis ethmoidis	Labyrinthus ethmoidalis
Cellulae ethmoidales ..	Sinus ethmoidei (anteriores, posteriores)	Cellulae ethmoidales
Infundibulum ethmoidale	Infundibulum ethmoideum	Infundibulum ethmoidale
Hiatus semilunaris ..	Hiatus semilunaris ..	Hiatus semilunaris
Bulla ethmoidalis	Bulla ethmoidea	Bulla ethmoidalis
Lamina papyracea	Lamina orbitalis	Lamina orbitalis
Foramina ethmoidalia .	Foramina ethmoidea ..	Foramina ethmoidalia
(Concha nasalis suprema)	(Concha nasalis suprema)	(Concha nasalis suprema)
Concha nasalis superior . .	Concha nasalis superior .	Concha nasalis superior
Concha nasalis media ...	Concha nasalis media ...	Concha nasalis media
Processus uncinatus	Processus uncinatus	Processus uncinatus

BNA	JNA	PNA
CONCHA NASALIS INF.	CONCHA NASALIS INF.	CONCHA NASALIS INF.
Processus lacrimalis	Processus lacrimalis	Processus lacrimalis
Processus maxillaris	Processus maxillaris	Processus maxillaris
Processus ethmoidalis ...	Processus ethmoideus	Processus ethmoidalis
OS LACRIMALE	OS LACRIMALE	OS LACRIMALE
Crista lacrimalis post. ...	Crista lacrimalis post. ...	Crista lacrimalis post.
Hamulus lacrimalis	Hamulus lacrimalis	Hamulus lacrimalis
Sulcus lacrimalis	Sulcus lacrimalis	Sulcus lacrimalis
Fossa sacci lacrimalis ...	Fossa sacci lacrimalis ...	.....**
OS NASALE	OS NASALE	OS NASALE
Foramina nasalia	Foramina nasalia	.....
Sulcus ethmoidalis	Sulcus ethmoideus	Sulcus ethmoidalis
VOMER	VOMER	VOMER
Ala vomeris	Ala vomeris	Ala vomeris
OSSA FACIEI	*OSSA FACIEI°*	*OSSA FACIEI*
MAXILLA	MAXILLA	MAXILLA
Corpus maxillae	Corpus maxillae	Corpus maxillae
Facies anterior	Facies anterior	Facies anterior
Margo infraorbitalis .	Margo aditus	Margo infraorbitalis*
Foramen infraorbitale	Foramen infraorbitale	Foramen infraorbitale*
Sutura infraorbitalis .	Sutura infraorbitalis .	Sutura infraorbitalis*
Fossa canina	Fossa canina	Fossa canina
(Fossa praenasalis) .	var. Fossa praenasalis	.....
Incisura nasalis	Incisura nasalis	Incisura nasalis
.....	Crista infrazygomatica	.....
Facies infratemporalis .	Facies infratemporalis .	Facies infratemporalis
Tuber maxillare	Tuber maxillae	Tuber maxillae
Foramina alveolaria .	Foramina alveolaria .	Foramina alveolaria
Canales alveolares ..	Canales alveolares ..	Canales alveolares
Facies orbitalis	Facies orbitalis	Facies orbitalis
.....	Margo orbitalis	.....
Planum orbitale	.....	.....
Sulcus infraorbitalis .	Sulcus infraorbitalis .	Sulcus infraorbitalis*
Canalis infraorbitalis	Canalis infraorbitalis	Canalis infraorbitalis*
Facies nasalis	Facies nasalis	Facies nasalis

BNA	JNA	PNA
Hiatus maxillaris	Hiatus sinus maxillaris	Hiatus maxillaris
Sulcus lacrimalis ...	Sulcus lacrimalis ...	Sulcus lacrimalis
Canalis nasolacrimalis	Canalis nasolacrimalis	Canalis nasolacrimalis
Crista conchalis	Crista conchalis	Crista conchalis
Processus maxillae°		
Processus frontalis	Processus frontalis	Processus frontalis
Margo lacrimalis	Margo lacrimalis	Margo lacrimalis
Incisura lacrimalis ..	Incisura lacrimalis ..	Incisura lacrimalis
Crista lacrimalis ant.	Crista lacrimalis ant.	Crista lacrimalis ant.
Crista ethmoidalis ...	Crista ethmoidea	Crista ethmoidalis
Processus zygomaticus .	Processus zygomaticus .	Processus zygomaticus
Processus alveolaris ...	Processus alveolaris ...	Processus alveolaris
Alveoli dentales	Alveoli dentales	Alveoli dentales
Septa interalveolaria .	Septa interalveolaria .	Septa interalveolaria
.....	Septa intraalveolaria	Septa interradicularia
Limbus alveolaris ...	Margo alveolaris	Arcus alveolaris
Juga alveolaria	Juga alveolaria	Juga alveolaria
Processus palatinus	Processus palatinus	Processus palatinus
Crista nasalis	Crista nasalis	Crista nasalis
Spina nasalis ant. ...	Spina nasalis ant. ...	Spina nasalis ant.
Sulci palatini	Sulci palatini	Sulci palatini
.....	.....	Sulcus palatinus major*
Spinae palatinae	.....	Spinae palatinae
Os incisivum	Os incisivum	Os incisivum
Sutura incisiva	(Sutura incisiva)	Sutura incisiva
Canalis incisivus	Canalis incisivus	Canalis incisivus(vide : Cranium, palatum osseum)
Foramen incisivum ..	Foramen incisivum ..	Foramen incisivum (vide: Cranium, palatum osseum)
Sinus maxillaris	Sinus maxillaris	Sinus maxillaris
OS PALATINUM	OS PALATINUM	OS PALATINUM
Pars perpendicularis	Lamina maxillaris	Lamina perpendicularis
Facies maxillaris	Facies maxillaris	Facies maxillaris
Sulcus pterygopalatinus	Sulcus pterygopalatinus	Sulcus palatinus major*

BNA	JNA	PNA
Facies nasalis	Facies nasalis	Facies nasalis
Crista ethmoidalis ...	Crista ethmoidea	Crista ethmoidalis
Crista conchalis	Crista conchalis	Crista conchalis
Processus orbitalis	Processus orbitalis	Processus orbitalis
Processus sphenoidalis .	Processus sphenoideus	Processus sphenoidalis
Incisura sphenopalatina	Incisura pterygopalatina	Incisura sphenopalatina
Pars horizontalis	Lamina palatina	Lamina horizontalis
Facies nasalis	Facies nasalis	Facies nasalis
Crista nasalis	Crista nasalis	Crista nasalis
Facies palatina	Facies palatina	Facies palatina
Spina nasalis post. ...	Spina nasalis post. ...	Spina nasalis post.**
Foramen palatinum majus	Foramen palatinum majus	Foramen palatinum majus
Foramina palatina minora	Foramina palatina minora	Foramina palatina minora
Canales palatini	Canales palatini	Canales palatini minores*
.....	.....	Crista palatina
Processus pyramidalis ...	Processus pyramidalis ...	Processus pyramidalis
OS ZYGOMATICUM	OS ZYGOMATICUM	OS ZYGOMATICUM
Facies malaris	Facies malaris	Facies lateralis*
Facies temporalis	Facies temporalis	Facies temporalis
Facies orbitalis	Facies orbitalis	Facies orbitalis
.....	Processus maxillaris	.....
Processus temporalis	Processus temporalis	Processus temporalis
Processus frontosphenoidalis	Processus frontosphenoideus	Processus frontalis
(Processus marginalis) ...	.....	(Tuberculum marginale)
Foramen zygomaticoorbitale	Foramen zygomaticoorbitale	Foramen zygomaticoorbitale
Foramen zygomaticofaciale	Foramen zygomaticofaciale	Foramen zygomaticofaciale

BNA	JNA	PNA
Foramen zygomaticotemporale	Foramen zygomaticotemporale	Foramen zygomaticotemporale
MANDIBULA	MANDIBULA	MANDIBULA
Corpus mandibulae	Corpus mandibulae	Corpus mandibulae
Basis mandibulae	.....	Basis mandibulae
Protuberantia mentalis	Protuberantia mentalis	Protuberantia mentalis
Tuberculum mentale	Tuberculum mentale	Tuberculum mentale .....
Spina mentalis	Trigonum mentale ..	Spina mentalis
.....	Spinae mandibulae .	.....
.....	Spina m. genioglossi	.....
Foramen mentale ...	Spina m. geniohyoidei	Foramen mentale
Linea obliqua	Foramen mentale ...	Linea obliqua
Fossa digastrica	Linea obliqua	Fossa digastrica
Fovea sublingualis ..	Fossa musculi biventeris	Fovea sublingualis
Linea mylohyoidea .	.....	Linea mylohyoidea
Sulcus mylohyoideus (Fovea submaxillaris)	Linea mylohyoidea ..	Sulcus mylohyoideus
Juga alveolaria	Sulcus mylohyoideus	Fovea submandibularis
Pars alveolaris	Juga alveolaria	Juga alveolaria
Limbus alveolaris ...	Pars alveolaris	Pars alveolaris
Alveoli dentales	Margo alveolaris	Arcus alveolaris
Septa interalveolaria .	Alveoli dentales	Alveoli dentales
.....	Septa interalveolaria .	Septa interalveolaria
.....	Septa intraalveolaria	Septa interradicularia
Ramus mandibulae	Trigonum retromolare	.....
Angulus mandibulae ..	Ramus mandibulae	Ramus mandibulae
(Tuberositas masseterica)	Angulus mandibulae ..	Angulus mandibulae
(Tuberositas pterygoidea)	Tuberositates massetericae	(Tuberositas masseterica)
	Tuberositas pterygoidea	(Tuberositas pterygoidea)

BNA	JNA	PNA
(Crista buccinatoria) ..	.....	.....
Incisura mandibulae ...	Incisura mandibulae ...	Incisura mandibulae*
Processus condyloideus	Processus articularis ...	Processus condylaris
Capitulum (proc. condyl.) mandibulae	Capitulum mandibulae .	Caput mandibulae
Collum (proc. condyl.) mandibulae	Collum mandibulae ...	Collum mandibulae
Fovea pterygoidea (proc. condyloidei)	Fovea pterygoidea processus articularis ...	Fovea pterygoidea
Processus coronoideus	Processus muscularis ..	Processus coronoideus
Foramen mandibulare .	Foramen mandibulae ..	Foramen mandibulae
Lingula mandibulae ...	Lingula mandibulae ...	Lingula mandibulae
Canalis mandibulae ...	Canalis mandibulae ...	Canalis mandibulae
OS HYOIDEUM	OS HYOIDES	OS HYOIDEUM
Corpus	Corpus ossis hyoidis	Corpus
Cornu minus	Cornu minus	Cornu minus
Cornu majus	Cornu majus	Cornu majus
CRANIUM	*CRANIUM*	*CRANIUM*
Calvaria	Calvaria	Calvaria
Pericranium	Pericranium	Pericranium
Lamina externa	Lamina externa	Lamina externa
Diploë	Diploë	Diploë
Canales diploici (Brescheti)	Canales diploici	Canales diploici
Lamina interna	Lamina interna	Lamina interna
Facies	Facies	.....
Cranium cerebrale	.....	.....
Cranium viscerale	.....	.....
Vertex	Vertex (Vortex)	Vertex
Frons	Frons	Frons
Occiput	Occiput	Occiput
.....	.....	Tempora*
.....	Basis cranii	.....
Basis cranii externa	Facies externa (baseos cranii)	Basis cranii externa
Basis cranii interna	Facies interna (baseos cranii)	Basis cranii interna
Fossa cranii anterior ..	Fossa cranii frontalis ..	Fossa cranii anterior

BNA	JNA	PNA
Fossa cranii media	Fossa cranii media	Fossa cranii media
.....	Pars sellaris (fossae cranii mediae)	.....
.....	Partes temporales (fossae cranii mediae) ..	.....
Fossa cranii posterior .	Fossa cranii occipitalis	Fossa cranii posterior
.....	.....	Clivus*
Juga cerebralia	Juga cerebralia	.....
Impressiones digitatae .	Impressiones gyrorum .	Impressiones digitatae
Sulci venosi	Sulci venarum	Sulci venosi
Sulci arteriosi	Sulci arteriarum	Sulci arteriosi
(Foveolae granulares [Pacchioni])	Foveolae granulares ..	Foveolae granulares
(Ossa suturarum)	var. Ossa suturarum ..	(Ossa suturarum)
Planum temporale	Planum temporale	.....
Fossa temporalis	Fossa temporalis	Fossa temporalis
.....	.....	Fissura pterygomaxillaris*
Arcus zygomaticus	Arcus zygomaticus	Arcus zygomaticus
Fossa infratemporalis	Fossa infratemporalis	Fossa infratemporalis
Fossa pterygopalatina ...	Fossa pterygopalatina ...	Fossa pterygopalatina
Canalis pterygopalatinus	Canalis pterygopalatinus	Canalis palatinus major
Foramen sphenopalatinum	Foramen pterygopalatinum	.....
Foramen jugulare	Foramen jugulare	Foramen jugulare
Fissura sphenopetrosa ...	Fissura sphenopetrosa ...	Fissura sphenopetrosa
Fissura sphenooccipitalis .	Fissura sphenooccipitalis	.....*
Fissura petrooccipitalis ..	Fissura petrooccipitalis ..	Fissura petrooccipitalis
Foramen lacerum	Foramen lacerum	Foramen lacerum
Fibrocartilago basalis	Fibrocartilago basialis ...	.....
CAVUM NASI	CAVUM NASI	CAVUM NASI
.....	Cavum nasi ossei	.....
Apertura piriformis ...	Apertura piriformis ...	Apertura piriformis
Septum nasi osseum ..	Septum nasi osseum ..	Septum nasi osseum
Meatus nasi superior ..	Meatus nasi superior ..	Meatus nasi superior
Meatus nasi medius ...	Meatus nasi medius ...	Meatus nasi medius
Meatus nasi inferior ..	Meatus nasi inferior ..	Meatus nasi inferior
Meatus nasi communis	Meatus nasi communis	.....
Meatus nasopharyngeus	Meatus nasopharyngicus	Meatus nasopharyngeus
.....	.....	Foramen sphenopalatinum*

BNA	JNA	PNA
Choanae	Choana	Choanae
Recessus sphenoethmoidalis	Recessus sphenoethmoideus	Recessus sphenoethmoidalis*
PALATUM DURUM	PALATUM OSSEUM	PALATUM OSSEUM
.....	.....	Fossa incisiva
Canalis incisivus	Canalis incisivus	Canalis incisivus
Foramen incisivum	Foramen incisivum	Foramina incisiva*
(Torus palatinus)	(Torus palatinus)	(Torus palatinus)
.....	.....	Canalis palatovaginalis*
.....	.....	Canalis vomerovaginalis*
ORBITA	ORBITA	ORBITA
Paries superior	Paries superior	Paries superior
Paries inferior	Paries inferior	Paries inferior
Paries medialis	Paries nasalis	Paries medialis
Paries lateralis	Paries temporalis	Paris lateralis
Fissura orbitalis superior	Fissura orbitalis cerebralis	Fissura orbitalis superior
Fissura orbitalis inf.	Fissura orbitalis sphenomaxillaris	Fissura orbitalis inferior
Margo supraorbitalis	Margo aditus	Margo supraorbitalis
Margo infraorbitalis	Margo aditus	Margo infraorbitalis*
Aditus orbitae	Aditus orbitae	Aditus orbitae
.....	Pars frontalis (marginis aditus orbitae)	.....
.....	Pars maxillaris (marginis aditus orbitae)	.....
.....	Pars zygomatica (marginis aditus orbitae)	.....

SYNDESMOLOGIA

Syndesmologia	*Juncturae ossium*	*Syndesmologia*
Junctura ossium.....	Juncturae ossium	Articulationes (Juncturae ossium)*
Synarthrosis	Synarthrosis	Junctura fibrosa
Sutura	Suturae	Sutura
Sutura serrata	Sutura serrata	Sutura serrata
Sutura squamosa ...	Sutura squamalis ...	Sutura squamosa
.....	Sutura laevis	.....
.....	Sutura mendosa	.....
.....	.....	Sutura plana
Gomphosis	Gomphosis	Gomphosis
Synchondrosis	Synchondrosis	Junctura cartilaginea / Synchondrosis / Symphysis
Symphysis	Symphysis	Symphysis
Diarthrosis	Diarthrosis = Articulus	Junctura synovialis
Articulatio	Articulus	
Articulatio simplex ..	Articulus simplex ...	Articulatio simplex
Articulatio composita	Articulus compositus	Articulatio composita
.....	.....	Articulatio condylaris*
.....	Articulus planus	Articulatio plana
Articulatio trochoidea	Articulus trochoideus	Articulatio trochoidea
Articulatio cochlearis	.....	.....
Articulatio ellipsoidea	Articulus ellipsoideus	Articulatio ellipsoidea*
Articulatio sellaris ..	Articulus sellaris ...	Articulatio sellaris
Arthrodia	.....	.....
Articulatio sphaeroidea	Articulus sphaeroideus	Articulatio spheroidea* (cotylica)
Enarthrosis	Enarthrosis sphaeroidea	
Ginglymus	Ginglymus	Ginglymus
Amphiarthrosis	Amphiarthrosis	.....

BNA	JNA	PNA
Syndesmosis	Syndesmosis	Syndesmosis
.....	Synostosis	.....
Cartilago articularis	Cartilago articularis	Cartilago articularis
Cavum articulare	Cavum articulare	Cavum articulare
Labrum glenoidale	.....	.....
.....	Labium articulare	.....
Discus articularis	Discus articularis	Discus articularis
Meniscus articularis	Meniscus articularis	Meniscus articularis
Capsula articularis	Capsula articularis	Capsula articularis
Stratum fibrosum	Stratum fibrosum	Membrana fibrosa
Stratum synoviale	Stratum synoviale	Membrana synovialis
Plica synovialis	.....	Plica synovialis
.....	Plicae articulares	.....
Villi synoviales	Villi articulares	Villi synoviales
Synovia	Synovia	Synovia
.....	.....	Ligamenta**
.....	.....	Ligg. extracapsularia**
.....	.....	Ligg. intracapsularia**
JUNCTURAE OSSIUM EXTREMITATIS SUPERIORIS°	JUNCTURAE OSSIUM EXTREMITATIS THORACICAE	JUNCTURAE MEMBRI SUPERIORIS°
LIGG. CINGULI EXTREMITATIS SUPERIORIS	JUNCTURAE OSSIUM CINGULI EXTREMITATUM THORACICARUM	JUNCTURAE CINGULI MEMBRI SUPERIORIS
Lig. coracoacromiale	Lig. coracoacromiale	Lig. coracoacromiale*
Lig. transversum scapulae sup.	Lig. transv. scapulae	Lig. transversum scapulae superius*
Lig. transversum scapulae inf.	.....	(Lig. transversum scapulae inferius*)
ARTICULATIO STERNOCLAVICULARIS	ARTICULUS STERNOCLAVICULARIS	ARTICULATIO STERNOCLAVICULARIS
Capsula articularis	.....	Capsula articularis
Lig. sternoclaviculare	Lig. sternoclaviculare	Lig. sternoclaviculare anterius Lig. sternoclaviculare posterius
Lig. costoclaviculare	Lig. costoclaviculare	Lig. costoclaviculare

BNA	JNA	PNA
Lig. interclaviculare	Lig. interclaviculare	Lig. interclaviculare
Discus articularis	Discus articularis	Discus articularis
ARTICULATIO ACROMIOCLAVICULARIS	ARTICULUS ACROMIOCLAVICULARIS	ARTICULATIO ACROMIOCLAVICULARIS
Capsula articularis	.....	Capsula articularis
Lig. acromioclaviculare ..	Lig. acromioclaviculare ..	Lig. acromioclaviculare
Lig. coracoclaviculare ...	Lig. coracoclaviculare ...	Lig. coracoclaviculare
Lig. trapezoideum	Pars trapezoides (lig. coracoclav.)	Lig. trapezoideum
Lig. conoideum	Pars conoides (lig. coracoclav.)	Lig. conoideum
(Discus articularis)	Discus articularis	Discus articularis
.....	JUNCTURAE OSSIUM EXTREMITATIS THORACICAE LIBERAE	JUNCTURAE MEMBRI SUPERIORIS LIBERIS
ARTICULATIO HUMERI	ARTICULUS HUMERI	ARTICULATIO HUMERI
Capsula articularis	.....	Capsula articularis
Labrum glenoidale	Labium articulare	Labrum glenoidale
Lig. coracohumerale	Lig. coracohumerale	Lig. coracohumerale
.....	Ligamenta labiohumeralia	Ligg. glenohumeralia
ARTICULATIO CUBITI	ARTICULUS CUBITI	ARTICULATIO CUBITI
Articulatio humeroulnaris	Pars humeroulnaris	Articulatio humeroulnaris*
Articulatio humeroradialis	Pars humeroradialis	Art. humeroradialis
Articulatio radioulnaris proximalis	Pars radioulnaris (articuli cubiti)	Articulatio radioulnaris proximalis*
Capsula articularis	.....	Capsula articularis
Lig. collaterale ulnare ...	Lig. collaterale ulnare ...	Lig. collaterale ulnare
Lig. collaterale radiale ...	Lig. collaterale radiale ...	Lig. collaterale radiale
Lig. annulare radii	Lig. anulare radii	Lig. anulare radii
.....	.....	Lig. quadratum
Recessus sacciformis	Recessus sacciformis	.....
.....	Syndesmosis radioulnaris	.....
Membrana interossea antibrachii	*Membrana interossea antebrachii*	*Membrana interossea antebrachii*
Chorda obliqua	Chorda obliqua	Chorda obliqua

BNA	JNA	PNA
ARTICULATIO RADIOULNARIS DISTALIS	ARTICULUS RADIOULNARIS DISTALIS	ARTICULATIO RADIOULNARIS DISTALIS*
Capsula articularis	.....	Capsula articularis
Discus articularis	Discus articularis	Discus articularis
Recessus sacciformis	Recessus sacciformis	Recessus sacciformis
ARTICULATIO MANUS	ARTICULUS MANUS	ARTICULATIONES MANUS
Articulatio radiocarpea ..	Articulus radiocarpicus ..	Articulatio radiocarpea
.....	.....	Articulatio mediocarpea
Articulatio intercarpea ...	Articulus intercarpicus ...	Articulationes intercarpeae
Capsula articularis	.....	Capsula articularis
Lig. radiocarpeum dorsale	Lig. radiocarpicum dors.	Lig. radiocarpeum dors.
.....	Lig. ulnocarpicum volare	Lig. ulnocarpeum palmare
Lig. radiocarpeum volare	Lig. radiocarpicum volare	Lig. radiocarpeum palmare
Lig. carpi radiatum	Lig. carpi volare radiatum	Lig. carpi radiatum
Lig. collaterale carpi ulnare	.....	Lig. collaterale carpi ulnare
Lig. collaterale carpi radiale	.....	Lig. collaterale carpi radiale
.....	Lig. arcuatum carpi dorsale	.....
Ligg. intercarpea dorsalia	Ligg. intercarpica dorsalia	Ligg. intercarpea dorsalia
Ligg. intercarpea volaria .	Ligg. intercarpica volaria	Ligg. intercarpea palmaria
Ligg. intercarpea interossea	Ligg. intercarpica interossea	Ligg. intercarpea interossea
ARTICULATIO OSSIS PISIFORMIS	ARTICULUS OSSIS PISIFORMIS	ARTICULATIO OSSIS PISIFORMIS
Capsula articularis	.....	Capsula articularis
Lig. pisohamatum	Lig. pisohamatum	Lig. pisohamatum
Lig. pisometacarpeum ...	Lig. pisometacarpicum ...	Lig. pisometacarpeum
Canalis carpi	*Canalis carpi*	*Canalis carpi*
ARTICULATIONES CARPOMETACARPEAE	ARTICULUS CARPOMETACARPICUS COMMUNIS	ARTICULATIONES CARPOMETACARPEAE
Capsulae articulares	.....	Capsulae articulares

BNA	JNA	PNA
Ligg. carpometacarpea dorsalia	Ligg. carpometacarpica dorsalia	Ligg. carpometacarpea dorsalia
Ligg. carpometacarpea volaria	Ligg. carpometacarpica volaria	Ligg. carpometacarpea palmaria
ARTICULATIO CARPOMETACARPEA POLLICIS	ARTICULUS CARPOMETACARPICUS PRIMUS	ARTICULATIO CARPOMETACARPEA POLLICIS
Capsula articularis	.....	Capsula articularis
ARTICULATIONES INTERMETACARPEAE	.....	ARTICULATIONES INTERMETACARPEAE
Capsulae articulares	.....	Capsulae articulares
Ligg. basium (oss. metacarp.) dorsalia	Ligg. basium ossium metacarpi dorsalia	Ligg. metacarpea dorsalia
Ligg. basium (oss. metacarp.) volaria	Ligg. basium ossium metacarpi volaria	Ligg. metacarpea palmaria
Ligg. basium (oss. metacarp.) interossea	Ligg. basium ossium metacarpi interossea	Ligg. metacarpea interossea
Spatia interossea metacarpi	Spatia interossea metacarpi	Spatia interossea metacarpi
ARTICULATIONES METACARPOPHALANGEAE	ARTICULI METACARPOPHALANGICI	ARTICULATIONES METACARPOPHALANGEAE
Capsulae articulares	.....	Capsulae articulares
Ligg. collateralia	Ligg. collateralia	Ligg. collateralia
Ligg. accessoria volaria ..	Ligg. accessoria volaria ..	Ligg. palmaria
Ligg. capitulorum (oss. metacarp.) transversa ..	Ligg. capitulorum ossium metacarpi transversa ..	Ligg. metacarpeum transversum profundum
ARTICULATIONES DIGITORUM MANUS	ARTICULI DIGITORUM MANUS	ARTICULATIONES INTERPHALANGEAE MANUS
Capsulae articulares	.....	Capsulae articulares

BNA	JNA	PNA
Ligg. collateralia	Ligg. collateralia	Ligg. collateralia
.....	.....	Ligg. palmaria**
JUNCTURAE OSSIUM EXTREMITATIS INFERIORIS°	JUNCTURAE OSSIUM EXTREMITATIS PELVINAE	JUNCTURAE MEMBRI INFERIORIS°
LIGG. CINGULI EXTREMITATIS INFERIORIS	JUNCTURAE OSSIUM CINGULI EXTREMITATUM PELVINARUM	JUNCTURAE CINGULI MEMBRI INFERIORIS
Membrana obturatoria ..	Membrana obturans	Membrana obturatoria
Canalis obturatorius	Canalis obturatorius	Canalis obturatorius
Lig. iliolumbale	Lig. iliolumbale	Vide: Juncturae columnae vertebrae**
Lig. sacrotuberosum	Lig. sacrotuberale	Lig. sacrotuberale
Processus falciformis ..	Processus falciformis ...	Processus falciformis
Lig. sacrospinosum	Lig. sacrospinale	Lig. sacrospinale
Foramen ischiadicum majus	Foramen ischiadicum majus	Foramen ischiadicum majus
Foramen ischiadicum minus	Foramen ischiadicum minus	Foramen ischiadicum minus
SYMPHYSIS OSSIUM PUBIS	SYMPHYSIS OSSIUM PUBIS	SYMPHYSIS PUBICA
Lig. pubicum superius ...	Lig. pubicum	Lig. pubicum superius
Lig. arcuatum pubis	Lig. arcuatum pubis	Lig. arcuatum pubis
Lamina fibrocartilaginea interpubica	Lamina fibrocartilaginea interpubica	Discus interpubicus
ARTICULATIO SACROILIACA	ARTICULUS SACROILICUS	ARTICULATIO SACROILIACA*
Ligg. sacroiliaca anteriora	Ligg. sacroilica ventralia .	Ligg. sacroiliaca ventr.*
Ligg. sacroiliaca interossea	Ligg. sacroilica interossea	Ligg. sacroiliaca interossea*
Lig. sacroiliacum posterius breve	Lig. sacroilicum dorsale breve	Ligg. sacroiliaca dorsalia*
Lig. sacroiliacum posterius longum	Lig. sacroilicum dorsale longum	

BNA	JNA	PNA
.....	JUNCTURAE OSSIUM EXTREMITATIS PELVINAE LIBERAE	JUNCTURAE MEMBRI INFERIORIS LIBERI
ARTICULATIO COXAE	ARTICULUS COXAE	ARTICULATIO COXAE
Capsula articularis	.....	Capsula articularis
Lig. teres femoris	Lig. capitis femoris	Lig. capitis femoris
Lig. transversum acetabuli	Lig. transversum acetabuli	Lig. transversum acetabuli
Lig. iliofemorale	Lig. iliofemorale	Lig. iliofemorale
Lig. ischiocapsulare	Lig. ischiocapsulare	Lig. ischiofemorale
Lig. pubocapsulare	Lig. pubocapsulare	Lig. pubofemorale
Zona orbicularis	Zona orbicularis	Zona orbicularis
Labrum glenoidale	Labium articulare	Labrum acetabulare
ARTICULATIO GENU	ARTICULUS GENUS	ARTICULATIO GENUS*
Capsula articularis	.....	Capsula articularis
Lig. transversum genu ...	Lig. transversum genus .	Lig. transversum genus*
Ligg. cruciata genu	Ligg. decussata genus ...	Ligg. cruciata genus*
Lig. cruciatum anterius	Lig. decussatum anterius	Lig. cruciatum ant.
Lig. cruciatum post.	Lig. decussatum posterius	Lig. cruciatum post.
.....	Lig. menisci fibularis	.....
Plica synovialis patellaris	Plica synovialis patellaris	Plica synovialis infrapatellaris
.....	Corpus adiposum genus .	Corpus adiposum infrapatellare
Plicae alares	Plicae alares	Plicae alares
Meniscus medialis	Meniscus tibialis	Meniscus medialis
Meniscus lateralis	Meniscus fibularis	Meniscus lateralis
.....	.....	Lig. meniscofemorale ant.
.....	.....	Lig. meniscofemorale post.
Lig. collaterale fibulare .	Lig. collaterale fibulare .	Lig. collaterale fibulare
Lig. collaterale tibiale ...	Lig. collaterale tibiale ...	Lig. collaterale tibiale
Lig. popliteum obliquum	Lig. popliteum obliquum	Lig. popliteum obliquum
Lig. popliteum arcuatum	.....	Lig. popliteum arcuatum
Retinaculum lig. arcuati .	.....	.....
Retinaculum patellae mediale	Retinaculum patellae tibiale	Retinaculum patellae mediale
Retinaculum patellae lat.	Retinaculum patellae fibulare	Retinaculum patellae lat.
Ligamentum patellae	Ligamentum patellae	Ligamentum patellae

BNA	JNA	PNA
ARTICULATIO TIBIOFIBULARIS	ARTICULUS TIBIOFIBULARIS	ARTICULATIO TIBIOFIBULARIS
Capsula articularis	.....	Capsula articularis
Ligg. capituli fibulae	Ligg. capituli fibulae	Lig. capitis fibulae ant.
.....	.....	Lig. capitis fibulae post.
Membrana interossea cruris	*Membrana interossea cruris*	*Membrana interossea cruris*
SYNDESMOSIS TIBIOFIBULARIS	SYNDESMOSIS TIBIOFIBULARIS	SYNDESMOSIS (ARTICULATIO) TIBIOFIBULARIS
Lig. malleoli lateralis anterius	Lig. tibiofibulare anterius	Lig. tibiofibulare ant.
Lig. malleoli lateralis posterius	Lig. tibiofibulare post. ...	Lig. tibiofibulare post.
ARTICULATIONES PEDIS	ARTICULI PEDIS	ARTICULATIONES PEDIS
ARTICULATIO TALOCRURALIS	ARTICULUS TALOCRURALIS	ARTICULATIO TALOCRURALIS
Capsula articularis	.....	Capsula articularis
Lig. talofibulare anterius .	Lig. fibulotalare ant.	Lig. talofibulare ant.
Lig. talofibulare post. ...	Lig. fibulotalare post. ...	Lig. talofibulare post.
Lig. calcaneofibulare	Lig. fibulocalcaneare	Lig. calcaneofibulare
Lig. deltoideum	Lig. deltoides	Lig. mediale (deltoideum)*
Lig. tibionaviculare ...	Pars tibionavicularis (lig. deltoidis)	Pars tibionavicularis
Lig. calcaneotibiale	Pars tibiocalcanearis (lig. deltoidis)	Pars tibiocalcanea*
Lig. talotibiale anterius	Pars tibiotalaris (lig. deltoidis)	Pars tibiotalaris ant.
Lig. talotibiale posterius		Pars tibiotalaris post.
ARTICULATIONES INTERTARSEAE	.....	ARTICULATIONES INTERTARSEAE
ARTICULATIO TALOCALCANEO-NAVICULARIS	ARTICULUS TALOCALCANEO-NAVICULARIS	ARTICULATIO TALOCALCANEO-NAVICULARIS*
ARTICULATIO TALOCALCANEA	ARTICULUS TALOCALCANEARIS	ARTICULATIO SUBTALARIS
Capsula articularis	.....	Capsula articularis
Lig. talocalcaneum anterius	.....	.....

BNA	JNA	PNA
Lig. talocalcaneum posterius	.....	.....
Lig. talocalcaneum laterale	Lig. talocalcaneare fibulare	Lig. talocalcaneum lat.
Lig. talocalcaneum mediale	Lig. talocalcaneare tibiale	Lig. talocalcaneum med.
ARTICULATIO TARSI TRANSVERSA (CHOPARTI)	.....	ARTICULATIO TARSI TRANSVERSA
Capsula articularis	.....	Capsula articularis
.....	var. Articulus naviculocuboideus	.....
ARTICULATIO TALONAVICULARIS	.....	.....
Capsula articularis	.....	.....
ARTICULATIO CALCANEOCUBOIDEA	ARTICULUS CALCANEOCUBOIDEUS	ARTICULATIO CALCANEOCUBOIDEA
Capsula articularis	.....	Capsula articularis
ARTICULATIO CUNEONAVICULARIS	ARTICULUS CUNEONAVICULARIS + ARTICULUS TARSOMETATARSEUS SECUNDUS + TERTIUS + ARTICULUS INTERMETATARSEUS PRIMUS + SECUNDUS	ARTICULATIO CUNEONAVICULARIS
.....	ARTICULUS CUNEOCUBOIDEUS	.....
LIGG. TARSI INTEROSSEA	LIGG. TARSI INTEROSSEA	LIGG. TARSI INTEROSSEA
Lig. talocalcaneum interosseum	Lig. talocalcaneare interosseum	Lig. talocalcaneum interosseum
Lig. cuneocuboideum interosseum	.....	Lig. cuneocuboideum interosseum
Ligg. intercuneiformia interossea	Ligg. tarsi interossea	Ligg. intercuneiformia interossea
LIGG. TARSI DORSALIA	LIGG. TARSI DORSALIA	LIGG. TARSI DORSALIA
Lig. talonaviculare (dorsale)	Lig. talonaviculare	Lig. talonaviculare

BNA	JNA	PNA
.....	.....	Ligg. intercuneiformia dorsalia
Lig. cuneocuboideum dorsale	.....	Lig. cuneocuboideum dorsale
Lig. cuboideonaviculare dorsale	.....	Lig. cuboideonaviculare dorsale
.....	Lig. cubonaviculare obl.	.....
Lig. bifurcatum	Lig. bipartitum	Lig. bifurcatum
Pars calcaneonavicularis	Pars calcaneonavicularis	Lig. calcaneonaviculare
Pars calcaneocuboidea .	Pars calcaneocuboidea .	Lig. calcaneocuboideum
Lig. calcaneonaviculare dorsale	.....	.....
Ligg. navicularicuneiformia dorsalia	.....	Ligg. cuneonavicularia dorsalia
.....	Lig. calcaneocuboideum dorsale	.....
LIGG. TARSI PLANTARIA	LIGG. TARSI PLANTARIA	LIGG. TARSI PLANTARIA
Lig. plantare longum	Lig. plantare longum	Lig. plantare longum
Ligg. tarsi profunda	.....	.....
Lig. calcaneocuboideum plantare	Ligg. calcaneocuboidea plantaria	Lig. calcaneocuboideum plantare
Lig. calcaneonaviculare plantare	Lig. calcaneonaviculare	Lig. calcaneonaviculare plantare
Fibrocartilago navicularis	.....	.....
Ligg. navicularicuneiformia plantaria	.....	Ligg. cuneonavicularia plantaria
Lig. cuboideonaviculare plantare	.....	Lig. cuboideonaviculare plantare
Ligg. intercuneiformia plantaria	Ligg. tarsi plantaria	Ligg. intercuneiformia plantaria

BNA	JNA	PNA
Lig. cuneocuboideum plantare	.....	Lig. cuneocuboideum plantare
.....	Lig. calcaneocuboideum plantare obliquum	.....
.....	Lig. calcaneocuboideum plantare transversum ..	.....
ARTICULATIONES TARSOMETATARSEAE	ARTICULI TARSOMETATARSEI ET INTERMETATARSEI	ARTICULATIONES TARSOMETATARSEAE
Capsulae articulares	.....	Capsulae articulares
.....	Articulus tarsometatarseus primus	.....
.....	Articulus tarsometatarseus quartus + quintus + Articulus intermetatarseus tertius	.....
Ligg. tarsometatarsea dorsalia	Ligg. tarsometatarsea dorsalia	Ligg. tarsometatarsea dorsalia
Ligg. tarsometatarsea interossea	.....	.....
Ligg. tarsometatarsea plantaria	Ligg. tarsometatarsea plantaria	Ligg. tarsometatarsea plantaria
.....	Ligg. cuneometatarsea interossea	Ligg. cuneometatarsea interossea
ARTICULATIONES INTERMETATARSEAE	.....	ARTICULATIONES INTERMETATARSEAE
Capsulae articulares	.....	Capsulae articulares
Ligg. basium (oss. metatars.) interossea	Ligg. basium ossium metatarsi interossea	Ligg. metatarsea interossea
Ligg. basium (oss. metatars.) dorsalia	Ligg. basium ossium metatarsi dorsalia	Ligg. metatarsea dorsalia

BNA	JNA	PNA
Ligg. basium (oss. metatars.) plantaria	Ligg. basium ossium metatarsi plantaria	Ligg. metatarsea plantaria
Spatia interossea metatarsi	Spatia interossea metatarsi	Spatia interossea metatarsi
ARTICULATIONES METATARSOPHALANGEAE	ARTICULI METATARSOPHALANGICI	ARTICULATIONES METATARSOPHALANGEAE
Capsulae articulares	.....	Capsulae articulares
Ligg. collateralia	Ligg. collateralia	Ligg. collateralia
Ligg. accessoria plantaria	Ligg. accessoria plantaria	Ligg. plantaria
Ligg. capitulorum (oss. metatars.) transversa	Ligg. capitulorum ossium metatarsi transversa ...	Lig. metatarseum transversum profundum
ARTICULATIONES DIGITORUM PEDIS	ARTICULI DIGITORUM PEDIS	ARTICULATIONES INTERPHALANGEAE PEDIS
Capsulae articulares	.....	Capsulae articulares
Ligg. collateralia	Ligg. collateralia	Ligg. collateralia
.....	.....	Ligg. plantaria**
JUNCTURAE COLUMNAE VERTEBRALIS THORACIS ET CRANII°	JUNCTURAE COLUMNAE VERTEBRALIS THORACIS ET CRANII°	JUNCTURAE COLUMNAE VERTEBRALIS THORACIS ET CRANII
.....	ARTICULI INTERVERTEBRALES	.....
Fibrocartilagines intervertebrales	Disci intervertebrales	Disci intervertebrales
Annulus fibrosus	Anulus fibrosus	Anulus fibrosus
Nucleus pulposus	Nucleus pulposus	Nucleus pulposus
Capsulae articulares	.....	Capsula articularis
Ligg. flava	Ligg. interarcualia	Lig. flavum
.....	.....	Juncturae zygapophysealis**
Ligg. intertransversaria ..	Ligg. intertransversaria ..	Lig. intertransversarium
Ligg. interspinalia	Ligg. interspinalia	Lig. interspinale
Lig. supraspinale	Lig. supraspinale	Lig. supraspinale

BNA	JNA	PNA
Lig. nuchae	Septum nuchae	Lig. nuchae
Lig. longitudinale anterius	Lig. longitudinale commune ventrale	Lig. longitudinale ant.
Lig. longitudinale posterius	Lig. longitudinale commune dorsale	Lig. longitudinale post.
.....	.....	Junctura lumbosacralis**
Vide: Junct. cing. membri inf.	Vide: Junct. cing. membri inf.	Lig. iliolumbale
SYMPHYSIS SACROCOCCYGEA	SYMPHYSIS SACROCOCCYGICA	JUNCTURA SACROCOCCYGEA
Lig. sacrococcygeum posterius superficiale	Lig. sacrococcygicum dorsale superficiale	Lig. sacrococcygeum dorsale superficiale
Lig. sacrococcygeum posterius profundum	Lig. sacrococcygicum dorsale profundum	Lig. sacrococcygeum dorsale profundum
Lig. sacrococcygeum anterius	Lig. sacrococcygicum ventrale	Lig. sacrococcygeum ventrale
Lig. sacrococcygeum laterale	Lig. sacrococcygeum lat. .	Lig. sacrococcygeum lat.
ARTICULATIO ATLANTOOCCIPITALIS	ARTICULI ATLANTOOCCIPITALES	ARTICULATIO ATLANTOOCCIPITALIS*
Capsula articularis	.....	Capsula articularis
Membrana atlantooccipitalis anterior	Membrana atlantooccipitalis ventralis	Membrana atlantooccipitalis anterior
Membrana atlantooccipitalis posterior	Membrana atlantooccipitalis dorsalis	Membrana atlantooccipitalis posterior
ARTICULATIO ATLANTOEPISTROPHICA	ARTICULI ATLANTOEPISTROPHICI	ARTICULATIO ATLANTOAXIALIS MEDIANA*
.....	Articulus atlantodentalis dorsalis	.....

BNA	JNA	PNA
.....	Articulus atlantodentalis ventralis	.....
.....	Articuli atlantoepistrophici laterales	Articulatio atlantoaxialis lateralis*
Capsulae articulares	.....	Capsula articularis
Ligg. alaria	Ligg. alaria	Ligg. alaria
Lig. apicis dentis	Lig. apicis dentis	Lig. apicis dentis
Lig. transversum atlantis	Lig. transversum atlantis	Lig. transversum atlantis
.....	.....	Fasciculi longitudinales
Lig. cruciatum atlantis ..	Lig. cruciforme atlantis ..	Lig. cruciforme atlantis
Membrana tectoria	Membrana tectoria	Membrana tectoria
.....	Membrana atlantoepistrophica ventralis	.....
.....	Membrana atlantoepistrophica dorsalis	.....
ARTICULATIONES COSTOVERTEBRALES	ARTICULI COSTOVERTEBRALES	ARTICULATIONES COSTOVERTEBRALES
ARTICULATIONES CAPITULORUM	ARTICULI CAPITULORUM	ARTICULATIO CAPITIS COSTAE
Capsula articularis	.....	Capsula articularis
Lig. capituli costae radiatum	Lig. capituli costae radiatum	Lig. capitis costae radiatum
Lig. capituli costae interarticulare	Lig. capituli costae interarticulare	Lig. capitis costae intraarticulare
ARTICULATIONES COSTOTRANSVERSARIAE	ARTICULI COSTOTRANSVERSARII	ARTICULATIO COSTOTRANSVERSARIA
Capsulae articulares	.....	Capsula articularis
Lig. tuberculi costae	Lig. tuberculi costae	.....
Lig. colli costae	Lig. colli costae	Lig. costotransversarium
Lig. costotransversarium anterius	Lig. costotransversarium internum	Lig. costotransversarium superius
Lig. costotransversarium posterius	Lig. costotransversarium externum	Lig. costotransversarium laterale .....

BNA	JNA	PNA
Lig. lumbocostale	Lig. lumbocostale	Lig. lumbocostale
Foramen costotransversarium	Foramen costotransversarium	Foramen costotransversarium .....
ARTICULATIONES STERNOCOSTALES	ARTICULI STERNOCOSTALES	ARTICULATIONES STERNOCOSTALES
Capsulae articulares	.....	Capsula articularis
.....	Synchondrosis sternocostalis costae primae	.....
Lig. sternocostale interarticulare	Lig. sternocostale intraarticulare	Lig. sternocostale intraarticulare
Ligg. sternocostalia radiata	Ligg. sternocostalia radiata	Ligg. sternocostalia radiata
Membrana sterni	Membrana sterni	Membrana sterni
Ligg. costoxiphoidea	Ligg. costoensiformia	Ligg. costoxiphoidea
Ligg. intercostalia	Ligg. intercostalia	.....
Ligg. intercostalia externa	Ligg. intercostalia ext. .	Membrana intercostalis externa
Ligg. intercostalia interna	Ligg. intercostalia int.	Membrana intercostalis interna
Vide: Sternum	Vide: Sternum	SYNCHONDROSES STERNALES**
.....	.....	Synchondrosis manumbriosternalis**
.....	.....	Synchondrosis xiphosternalis**
.....	.....	ARTICULATIONES COSTOCHONDRALES**
ARTICULATIONES INTERCHONDRALES	ARTICULI INTERCARTILAGINEI	ARTICULATIONES INTERCHONDRALES
ARTICULATIO MANDIBULARIS	ARTICULUS MANDIBULARIS	ARTICULATIO TEMPOROMANDIBULARIS
Capsula articularis	.....	Capsula articularis
Lig. temporomandibulare	Lig. temporomandibulare	Lig. laterale
Lig. sphenomandibulare .	Lig. sphenomandibulare .	Lig. sphenomandibulare
Lig. stylomandibulare ...	Lig. stylomandibulare ...	Lig. stylomandibulare
Discus articularis	Discus articularis	Discus articularis

BNA	JNA	PNA
LIGAMENTA CRANII°	LIGAMENTA CRANII°	LIGAMENTA CRANII°
Lig. stylohyoideum	Lig. stylohyoideum	Lig. stylohyoideum
Lig. pterygospinosum	Lig. pterygospinale	Lig. pterygospinale
SUTURAE CRANII	SUTURAE CRANII	SUTURAE CRANII
Sutura coronalis	Sutura coronaria	Sutura coronalis
Sutura sagittalis	Sutura sagittalis	Sutura sagittalis
Sutura lambdoidea	Sutura lambdoides	Sutura lambdoidea
Sutura sphenofrontalis .	Sutura sphenofrontalis .	Sutura sphenofrontalis
Sutura sphenoorbitalis .	Sutura sphenoorbitalis .	.....
Sutura sphenosquamosa	Sutura sphenosquamalis	Sutura sphenosquamosa
Sutura sphenoethmoidalis	Sutura sphenoethmoidea	Sutura sphenoethmoidalis*
Sutura sphenoparietalis	Sutura sphenoparietalis var. Sutura occipitalis transversa	Sutura sphenoparietalis .....
Sutura occipitomastoidea	Sutura occipitomastoidea	Sutura occipitomastoidea
.....	(Sutura mastoideosquamalis)	.....
Sutura squamosa	Sutura parietotemporalis	Sutura squamosa
(Sutura frontalis)	(Sutura frontalis)	(Sutura frontalis) (Sutura metopica)*
Sutura parietomastoidea (Sutura squamosomastoidea)	Sutura parietomastoidea	Sutura parietomastoidea (Sutura squamosomastoidea)
Sutura nasofrontalis ...	Sutura nasofrontalis ...	Sutura frontonasalis
Sutura frontoethmoidalis	Sutura frontoethmoidea	Sutura frontoethmoidalis*
Sutura frontomaxillaris	Sutura frontomaxillaris	Sutura frontomaxillaris
Sutura frontolacrimalis	Sutura frontolacrimalis	Sutura frontolacrimalis
Sutura zygomaticofrontalis	Sutura zygomaticofrontalis	Sutura frontozygomatica

BNA	JNA	PNA
Sutura zygomaticomaxillaris	Sutura zygomaticomaxillaris	Sutura zygomaticomaxiilaris
Sutura ethmoideomaxillaris	Sutura ethmoideomaxillaris	Sutura ethmoidomaxillaris**
Sutura sphenozygomatica	Sutura sphenozygomatica	Sutura sphenozygomatica
(Sutura sphenomaxillaris)	(Sutura sphenomaxillaris)	Sutura sphenomaxillaris
Sutura zygomaticotemporalis	Sutura zygomaticotemporalis	Sutura temporozygomatica
Sutura internasalis	Sutura internasalis	Sutura internasalis
Sutura nasomaxillaris ..	Sutura nasomaxillaris ..	Sutura nasomaxillaris
.....	Sutura conchomaxillaris	.....
Sutura lacrimomaxillaris	Sutura lacrimomaxillaris	Sutura lacrimomaxillaris
Sutura lacrimoconchalis	Sutura lacrimoconchalis	Sutura lacrimoconchalis
.....	Sutura lacrimoethmoidea	.....
Sutura intermaxillaris ..	Sutura intermaxillaris ..	Sutura intermaxillaris
Sutura palatomaxillaris .	Sutura palatomaxillaris	Sutura palatomaxillaris
Sutura palatoethmoidalis	Sutura palatoethmoidea	Sutura palatoethmoidalis*
.....	Sutura conchopalatina .	.....
Sutura palatina mediana	Sutura palatina mediana	Sutura palatina mediana
Sutura palatina transversa	Sutura palatina transversa	Sutura palatina transversa
.....	Sutura vomeroethmoidea	.....
.....	Sutura vomeromaxillaris	.....
.....	Sutura vomeropalatina	.....

BNA	JNA	PNA
SYNCHONDROSES CRANII	SYNCHONDROSES CRANII	SYNCHONDROSES CRANII
Synchondrosis sphenooccipitalis	Synchondrosis sphenooccipitalis	Synchondrosis sphenooccipitalis
Synchondrosis sphenopetrosa	Synchondrosis sphenopetrosa	Synchondrosis sphenopetrosa
Synchondrosis petrooccipitalis	Synchondrosis petrooccipitalis	Synchondrosis petrooccipitalis
Synchondrosis intraoccipitalis anterior	Synchondrosis basilateralis ossis occipitalis	Synchondrosis intraoccipitalis anterior
Synchondrosis intraoccipitalis posterior	Synchondrosis squamolateralis ossis occipitalis	Synchondrosis intraoccipitalis posterior
Synchondrosis intersphenoidalis	Synchondrosis intersphenoidea	.....
FONTICULI CRANII	FONTICULI CRANII	FONTICULI CRANII
Fonticulus frontalis (major)	Fonticulus major	Fonticulus anterior
Fonticulus occipitalis (minor)	Fonticulus minor	Fonticulus posterior
Fonticulus mastoideus ..	Fonticulus mastoideus ..	Fonticulus mastoideus*
Fonticulus sphenoidalis .	Fonticulus sphenoideus ..	Fonticulus sphenoidalis*

MYOLOGIA

Myologia	*Systema musculorum (Myologia)*	*Myologia*
Musculus	Musculus	Musculus
Caput	Caput	Caput
Venter	Venter	Venter
Musculus unipennatus ..	Musculus unipennatus ..	Musculus unipennatus
Musculus bipennatus	Musculus bipennatus	Musculus bipennatus
.....	Musculus biventer	.....
Musculus fusiformis	Musculus fusiformis	Musculus fusiformis
Musculus sphincter	Musculus sphincter	Musculus sphincter
Musculus orbicularis	Musculus orbicularis	Musculus orbicularis
Musculus articularis	.....	Musculus articularis
Musculus skeleti	.....	Musculus skeleti
Musculus cutaneus	Musculus cutaneus	Musculus cutaneus
Tendo	Tendo	Tendo
.....	.....	Peritendineum
.....	.....	Mesotendineum
Vinculum	.....	.....
Aponeurosis	Aponeurosis	Aponeurosis
Perimysium	.....	Perimysium
Fascia	Fascia	Fascia
Fascia superficialis	.....	.....
.....	Septum intermusculare .	.....
Inscriptio tendinea	Inscriptio tendinea	Intersectio tendinea
Arcus tendineus	Arcus tendineus	Arcus tendineus
Juncturae tendinum	Juncturae tendinum	Vide: Mm. antebrachii**
Ligamentum vaginale	.....	.....
Vagina fibrosa tendinis ..	.....	Vagina fibrosa tendinis
.....	.....	Vagina synovialis tendinis
Trochlea muscularis	.....	Trochlea muscularis
Bursa mucosa	Bursa synovialis	Bursa synovialis
Bursa mucosa subcutanea	.....	Bursa synovialis subcutanea

BNA	JNA	PNA
Bursa mucosa submuscularis	.....	Bursa synovialis submuscularis
Bursa mucosa subfascialis	.....	Bursa synovialis subfascialis
Bursa mucosa subtendinea	.....	Bursa synovialis subtendinea
MUSCULI EXTREMITATIS SUPERIORIS	MUSCULI EXTREMITATIS THORACICAE	MUSCULI MEMBRI SUPERIORIS
MUSCULI CINGULI EXTREMITATIS SUPERIORIS°	*MUSCULI CINGULI EXTREMITATIS THORACICAE*°	*MUSCULI CINGULI MEMBRI SUPERIORIS*°
M. deltoideus	M. deltoides	M. deltoideus
M. supraspinatus	M. supra spinam	M. supraspinatus
.....	Bursa subcoracoidea	.....
M. infraspinatus	M. infra spinam	M. infraspinatus
M. teres minor	M. teres minor	M. teres minor
M. teres major	M. teres major	M. teres major
M. subscapularis	M. subscapularis	M. subscapularis
Fascia axillaris	Fascia axillaris	Fascia axillaris
Fascia subscapularis	Fascia subscapularis	.....
Fascia supraspinata	Fascia supra spinam	.....
Fascia infraspinata	Fascia infra spinam	.....
MUSCULI BRACHII°	*MUSCULI BRACHII*°	*MUSCULI BRACHII*°
Flexores°		
M. biceps brachii	M. biceps brachii	M. biceps brachii
Caput longum	Caput longum	Caput longum
Vagina mucosa intertubercularis	Vagina synovialis intertubercularis	Vagina synovialis intertubercularis
Caput breve	Caput breve	Caput breve
Lacertus fibrosus	Lacertus fibrosus	Aponeurosis m. bicipitis brachii
.....	Sulcus m. bicipitis brachii radialis	.....

BNA	JNA	PNA
.....	Sulcus m. bicipitis brachii ulnaris	.....
M. coracobrachialis	M. coracobrachialis	M. coracobrachialis
Bursa m. coracobrachialis	Bursa musculi coracobrachialis	(Bursa musculi coracobrachialis)
M. brachialis	M. brachialis	M. brachialis
Extensores°		
M. triceps brachii	M. triceps brachii	M. triceps brachii
Caput longum	Caput longum	Caput longum
Caput laterale	Caput radiale	Caput laterale
Caput mediale	Caput ulnare	Caput mediale
M. anconaeus	M. anconaeus	M. anconeus*
(M. epitrochleoanconaeus)	.....	.....
.....	.....	M. articularis cubiti
Fascia brachii	Fascia brachii	Fascia brachii
Septum intermusculare (humeri) mediale	Septum intermusculare brachii ulnare	Septum intermusculare brachii mediale
Septum intermusculare (humeri) laterale	Septum intermusculare brachii radiale	Septum intermusculare brachii laterale
Sulcus bicipitalis medialis	Sulcus bicipitalis ulnaris .	Sulcus bicipitalis medialis
Sulcus bicipitalis lateralis	Sulcus bicipitalis radialis .	Sulcus bicipitalis lateralis
Bursa subcutanea acromialis	Bursa subcutanea acromialis	(Bursa subcutanea acromialis)
Bursa subacromialis	Bursa subacromialis	Bursa subacromialis
Bursa subdeltoidea	Bursa subdeltoidea	Bursa subdeltoidea
Bursa m. infraspinati	Bursa m. infra spinam ..	Bursa subtendinea musculi infraspinati
Bursa m. subscapularis ..	Bursa tendinis musculi subscapularis	Bursa subtendinea musculi subscapularis
Bursa m. teretis majoris	var. Bursa m. teretis majoris	Bursa subtendinea m. teretis majoris

BNA	JNA	PNA
MUSCULI ANTIBRACHII°	*MUSCULI ANTEBRACHII°*	*MUSCULI ANTEBRACHII°*
Flexores°		
M. pronator teres	M. pronator teres	M. pronator teres
Caput humerale	Caput humerale	Caput humerale
Caput ulnare	Caput ulnare	Caput ulnare
M. flexor carpi radialis	M. flexor carpi radialis .. Canalis tendinis m. flexoris carpi radialis .	M. flexor carpi radialis .. ..
M. palmaris longus	M. palmaris longus	M. palmaris longus
M. flexor carpi ulnaris ..	M. flexor carpi ulnaris ..	M. flexor carpi ulnaris
Caput humerale	Caput humerale	Caput humerale
Caput ulnare	Caput ulnare	Caput ulnare
M. flexor digitorum sublimis	M. flexor digitorum superficialis	M. flexor digitorum superficialis
Caput humerale	Caput humerale	Caput humeroulnare*
Caput radiale	Caput radiale	Caput radiale
M. flexor digitorum profundus	M. flexor digitorum profundus	M. flexor digitorum profundus
M. flexor pollicis longus	M. flexor pollicis longus . var. Caput humerale m. flexoris pollicis longi ..	M. flexor pollicis longus .....
M. pronator quadratus .	M. pronator quadratus .	M. pronator quadratus
Extensores°		
M. brachioradialis	M. brachioradialis	M. brachioradialis
M. extensor carpi radialis longus	M. extensor carpi radialis longus	M. extensor carpi radialis longus
M. extensor carpi radialis brevis	M. extensor carpi radialis brevis	M. extensor carpi radialis brevis

BNA	JNA	PNA
M. extensor digitorum communis	M. extensor digitorum communis	M. extensor digitorum
Juncturae tendineum ..	Juncturae tendineum ..	Connexus intertendineus
M. extensor digiti quinti proprius	M. extensor digiti quinti proprius	M. extensor digiti minimi
M. extensor carpi ulnaris	M. extensor carpi ulnaris	M. extensor carpi ulnaris
		Caput humerale
		Caput ulnare
M. supinator	M. supinator	M. supinator
M. abductor pollicis longus	M. abductor pollicis longus	M. abductor pollicis longus
M. extensor pollicis brevis	M. extensor pollicis brevis	M. extensor pollicis brevis
M. extensor pollicis longus	M. extensor pollicis longus	M. extensor pollicis longus
M. extensor indicis proprius	M. extensor indicis proprius	M. extensor indicis
Fascia antibrachii	Fascia antebrachii	Fascia antebrachii
Ligamentum carpi volare	.....	.....
Ligamentum carpi dorsale	Ligamentum carpi dorsale	Retinaculum extensorum

MUSCULI MANUS°	*MUSCULI MANUS*°	*MUSCULI MANUS*°
Thenar	*Thenar*	*Thenar*
M. abductor pollicis brevis	M. abductor pollicis brevis	M. abductor pollicis brevis
M. flexor pollicis brevis ..	M. flexor pollicis brevis ..	M. flexor pollicis brevis ..
.....	Caput superficiale m. flexoris pollicis brevis .	Caput superficiale**
.....	Caput profundum m. flexoris pollicis brevis .	Caput profundum**
M. opponens pollicis	M. opponens pollicis	M. opponens pollicis
M. adductor pollicis	M. adductor pollicis	M. adductor pollicis
.....	Caput obliquum m. adductoris pollicis	Caput obliquum
.....	Caput transversum m. adductoris pollicis	Caput transversum

BNA	JNA	PNA
Hypothenar	*Hypothenar*	*Hypothenar*
M. palmaris brevis	M. palmaris brevis	M. palmaris brevis
M. abductor digiti quinti	M. abductor digiti quinti	M. abductor digiti minimi
M. flexor digiti quinti brevis	M. flexor digiti quinti brevis	M. flexor digiti minimi brevis
M. opponens digiti quinti	M. opponens digiti quinti	M. opponens digiti minimi
Mesothenar°		
Mm. lumbricales	Mm. lumbricales	Mm. lumbricales
Mm. interossei volares ..	Mm. interossei volares ..	Mm. interossei palmares
Mm. interossei dorsales .	Mm. interossei dorsales .	Mm. interossei dorsales
Fascia dorsalis manus ..	Fascia dorsalis manus ..	Fascia dorsalis manus
Aponeurosis palmaris ...	Aponeurosis palmaris ...	Aponeurosis palmaris
Fasciculi transversi	Lig. palmare transversum subcutaneum ...	Fasciculi transversi
Lig. carpi transversum ..	Lig. carpi transversum ..	Retinaculum flexorum
Chiasma tendinum	Chiasma tendinum	Chiasma tendinum
.....	.....	Lig. metacarpeum transversum superficiale
Vinculum tendinum	Vinculum tendinum	Vincula tendinum Vinculum longum Vinculum breve
Vaginae mucosae	Vaginae synoviales tendinum	Vaginae synoviales digitorum manus*
Ligg. vaginalia digitorum manus	Ligg. vaginalia digitorum manus	Vaginae fibrosae digitorum manus*
Ligg. annularia digitorum manus	Ligg. anularia digitorum manus	Pars anularis vaginae fibrosae
Ligg. cruciata digitorum manus	Ligg. cruciformia digitorum manus	Pars cruciformis vaginae fibrosae
Bursa subcutanea olecrani	Bursa subcutanea olecrani	Bursa subcutanea olecrani

BNA	JNA	PNA
Bursa intratendinea olecrani	Bursa intratendinea olecrani	(Bursa intratendinea olecrani)
Bursa subtendinea olecrani	Bursa subtendinea olecrani	Bursa subtendinea m. tricipitis brachii
Bursa subcutanea epicondyli lateralis	Bursa subcutanea epicondyli humeri radialis ...	.....
Bursa subcutanea epicondyli medialis	Bursa subcutanea epicondyli humeri ulnaris	.....
Bursa bicipitoradialis ...	Bursa bicipitoradialis ...	Bursa bicipitoradialis
Bursa cubitalis interossea	(Bursa cubiti interossea) .	(Bursa cubitalis interossea)
Vagina tendinum mm. abductoris longi et extensoris brevis pollicis	Vagina tendinum m. abductoris longi et m. extensoris brevis pollicis	Vagina tendinum mm. abductoris longi et extensoris brevis pollicis
Vagina tendinis m. extensoris digiti minimi	Vagina tendinis musculi extensoris digiti quinti	Vagina tendinis m. extensoris digiti minimi
Vagina tendinum mm. extensorum carpi radialium	Vagina tendinum musculorum extensorum carpi radialium	Vagina tendinum mm. extensorum carpi radialium
Vagina tendinis m. extensoris pollicis longi	Vagina tendinis musculi extensoris pollicis longi ..	Vagina tendinis m. extensoris pollicis longi
Vagina tendinum mm. extensoris digitorum communis et extensoris indicis	Vagina tendinum m. extensoris digitorum communis et m. extensoris indicis proprii	Vagina tendinum mm. extensoris digitorum et extensoris indicis

BNA	JNA	PNA
Vagina tendinis m. extensoris carpi ulnaris	Vagina tendinis musculi extensoris carpi ulnaris .	Vagina tendinis m. extensoris carpi ulnaris
Bursa m. extensoris carpi radialis brevis	Bursa m. extensoris carpi radialis brevis	Bursa m. extensoris carpi radialis brevis
Bursae subcutaneae metacarpophalangeae dorsales	Bursae subcutaneae metacarpophalangicae dorsales	.....
Bursae subcutaneae digitorum dorsales	Bursae subcutaneae digitorum dorsales	.....
Bursa m. flexoris carpi ulnaris	.....	.....
Bursa m. flexoris carpi radialis	Vagina tendinis m. flexoris carpi radialis	Vagina synovialis tendinis m. flexoris carpi radialis
Vagina tendinuum mm. flexorum communium ...	Vagina tendinum musculorum flexorum digitorum communis	Vagina synovialis communis mm. flexorum
Vagina tendinis m. flexoris pollicis longi	Vagina tendinis m. flexoris pollicis longi	Vagina tendinis m. flexoris pollicis longi
Bursae intermetacarpophalangeae	Bursae intermetacarpophalangicae	.....
Vaginae tendinum digitales	Vaginae tendinum digitorum	Vaginae synoviales tendinum digitorum manus**
MUSCULI EXTREMITATIS INFERIORIS	MUSCULI EXTREMITATIS PELVINAE	MUSCULI MEMBRI INFERIORIS
M. iliopsoas	M. iliopsoas	M. iliopsoas

BNA	JNA	PNA
M. iliacus	M. ilicus	M. iliacus
M. psoas major	M. psoas major	M. psoas major
M. psoas minor	M. psoas minor	(M. psoas minor)**
M. glutaeus maximus	M. glutaeus maximus	M. gluteus maximus*
M. glutaeus medius	M. glutaeus medius	M. gluteus medius*
M. glutaeus minimus	M. glutaeus minimus	M. gluteus minimus*
M. tensor fasciae latae	M. tensor fasciae latae	M. tensor fasciae latae
M. piriformis	M. piriformis	M. piriformis
M. obturator internus	M. obturator internus	M. obturatorius internus
M. gemellus superior	M. gemellus spinalis	M. gemellus superior
M. gemellus inferior	M. gemellus tuberalis	M. gemellus inferior
M. quadratus femoris	M. quadratus femoris	M. quadratus femoris
M. obturator externus	M. obturator externus	M. obturatorius externus
		Bursa subtendinea m. obturatorii interni*
Bursa trochanterica subcutanea	Bursa trochanterica subcutanea	Bursa subcutanea trochanterica
Bursa trochanterica m. glutaei maximi	Bursa trochanterica subfascialis	Bursa trochanterica m. glutei maximi*
Bursa trochanterica m. glutaei medii anterior	Bursa trochanterica m. glutaei medii superficialis	Bursae trochantericae m. glutei medii*
Bursa trochanterica m. glutaei medii posterior	Bursa trochanterica m. glutaei medii profunda	
Bursa trochanterica m. glutaei minimi	Bursa trochanterica m. glutaei minimi	Bursa trochanterica m. glutei minimi*
Bursa m. piriformis	Bursa m. piriformis	Bursa m. piriformis
Bursa m. obturatorii interni	Bursa m. obturatoris int.	Bursa ischiadica m. obturatorii interni*
Bursae glutaeofemorales	Bursae glutaeofemorales	Bursae intermusculares musculorum gluteorum

BNA	JNA	PNA
Bursa ischiadica m. glutaei maximi	Bursa ischiadica m. glutaei maximi	Bursa ischiadica m. glutei maximi
.....	Fascia psoica	.....
MUSCULI FEMORIS°	*MUSCULI FEMORIS*°	*MUSCULI FEMORIS*°
Extensores°		
Musculus sartorius	M. sartorius	M. sartorius
M. quadriceps femoris ..	M. quadriceps femoris ..	M. quadriceps femoris
M. rectus femoris	M. rectus femoris	M. rectus femoris
M. vastus lateralis	M. vastus fibularis ...	M. vastus lateralis
M. vastus intermedius .	M. vastus intermedius .	M. vastus intermedius
M. vastus medialis	M. vastus tibialis	M. vastus medialis
M. articularis genu ...	M. articularis genus ...	M. articularis genus*
Flexores°		
Musculus biceps femoris .	M. biceps femoris	M. biceps femoris
Caput longum	Caput longum	Caput longum
Caput breve	Caput breve	Caput breve
Musculus semitendinosus	M. semitendineus	M. semitendinosus
M. semimembranosus ...	M. semimembranaceus ..	M. semimembranosus
.....	Bursa m. semimembranacei tibialis	.....
Adductores°		
M. pectineus	M. pectineus	M. pectineus
M. gracilis	M. gracilis	M. gracilis
M. adductor longus	M. adductor longus	M. adductor longus
M. adductor brevis	M. adductor brevis	M. adductor brevis
M. adductor magnus	M. adductor magnus	M. adductor magnus
M. adductor minimus ...	.....	.....
Fascia lata	Fascia lata	Fascia lata
Tractus iliotibialis (Maissiati)	Tractus iliotibialis	Tractus iliotibialis
Septum intermusculare femoris laterale	.....	Septum intermusculare femoris laterale

BNA	JNA	PNA
Septum intermusculare femoris mediale	.....	Septum intermusculare femoris mediale
Canalis adductorius (Hunteri)	Canalis adductorius	Canalis adductorius
.....	Lamina vastoadductoria	.....
Hiatus tendineus (adductorius)	Hiatus can. adductorii .	Hiatus tendineus (adductorius)
Fascia iliaca	Fascia ilica	Fascia iliaca
Fascia iliopectinea	.....	.....
Lacuna musculorum	Lacuna musculorum	Lacuna musculorum
.....	.....	Arcus iliopectineus*
Lacuna vasorum	Lacuna vasorum	Lacuna vasorum
Trigonum femorale (Fossa Scarpae major)	Trigonum femorale	Trigonum femorale
Fossa iliopectinea	Fossa iliopectinea	
Fascia pectinea	Fascia pectinea	.....
Canalis femoralis	Canalis femoralis	Canalis femoralis
Annulus femoralis	Anulus femoralis	Anulus femoralis
Septum femorale (Cloqueti)	Septum anuli femoralis	Septum femorale
Fossa ovalis	Fossa ovalis	Hiatus saphenus
Margo falciformis ...	Margo falciformis ...	Margo falciformis
Cornu superius	Cornu proximale	Cornu superius
Cornu inferius	Cornu distale	Cornu inferius
Fascia cribrosa	Lamina cribriformis fossae ovalis	Fascia cribrosa
Bursa m. recti femoris ..	Bursa m. recti femoris ..	.....
Bursa iliopectinea	Bursa iliopectinea	(Bursa iliopectinea)
Bursa iliaca subtendinea	var. Bursa ilica subtendinea	Bursa subtendinea iliaca
Bursa m. pectinei	Bursa m. pectinei	.....
Bursa m. bicipitis femoris superior	Bursa musculi bicipitis femoris proximalis	Bursa m. bicipitis femoris superior
.....	Pes anserinus	.....
MUSCULI CRURIS°	*MUSCULI CRURIS*°	*MUSCULI CRURIS*°
Extensores°		
Musculus tibialis anterior	Musculus tibialis anterior	Musculus tibialis anterior

BNA	JNA	PNA
M. extensor digitorum longus	M. extensor digitorum longus	M. extensor digitorum longus
M. peronaeus tertius	M. fibularis tertius	M. peroneus tertius (M. fibularis tertius)*
M. peronaeus longus	M. fibularis longus	M. peroneus longus (M. fibularis longus)*
M. peronaeus brevis	M. fibularis brevis	M. peroneus brevis (M. fibularis brevis)*
Flexores°		
M. triceps surae	M. triceps surae	M. triceps surae
M. gastrocnemius	M. gastrocnemius	M. gastrocnemius
Caput laterale	Caput fibulare	Caput laterale
Caput mediale	Caput tibiale	Caput mediale
M. soleus	M. soleus	M. soleus
Arcus tendineus m. solei	Arcus tendineus m. solei	Arcus tendineus m. solei
Tendo calcaneus (Achillis)	Tendo m. tricipitis surae	Tendo calcaneus (Achillis)
M. plantaris	M. plantaris	M. plantaris
M. flexor digitorum longus	M. flexor digitorum longus	M. flexor digitorum longus
M. tibialis posterior	M. tibialis posterior	M. tibialis posterior
M. flexor hallucis longus	M. flexor hallucis longus	M. flexor hallucis longus
M. popliteus	M. popliteus	M. popliteus
Fascia cruris	Fascia cruris	Fascia cruris
Septum intermusculare anterius (fibulare)	Septum intermusculare cruris anterius	Septum intermusculare anterius cruris
Septum intermusculare posterius (fibulare)	Septum intermusculare cruris posterius	Septum intermusculare posterius cruris
Ligamentum transversum cruris	Ligamentum transversum cruris	Retinaculum mm. extensorum superius

BNA	JNA	PNA
M. extensor hallucis longus	M. extensor hallucis longus	M. extensor hallucis longus
Ligamentum laciniatum ..	Ligamentum laciniatum ..	Retinaculum mm. flexorum
Ligamentum cruciatum cruris	Lig. cruciforme	Retinaculum mm. extensorum inferius
.....	Lig. fundiforme	.....
Retinaculum musculorum peronaeorum superius .	Retinaculum mm. fibularium proximale	Retinaculum mm. peroneorum (fibularium) superius
Retinaculum musculorum peronaeorum inferius ..	Retinaculum mm. fibularium distale	Retinaculum mm. peroneorum (fibularium) inferius
MUSCULI PEDIS°	*MUSCULI PEDIS*°	*MUSCULI PEDIS*°
Musculi dorsalis pedis°		
M. extensor hallucis brevis	M. extensor hallucis brevis	M. extensor hallucis brevis
M. extensor digitorum brevis	M. extensor digitorum brevis	M. extensor digitorum brevis
Fascia dorsalis pedis	Fascia dorsalis pedis	Fascia dorsalis pedis
Musculi plantae°		
M. abductor hallucis ...	M. abductor hallucis ...	M. abductor hallucis
M. flexor hallucis brevis	M. flexor hallucis brevis	M. flexor hallucis brevis
M. adductor hallucis ...	M. adductor hallucis ...	M. adductor hallucis
Caput obliquum	Caput obliquum	Caput obliquum
Caput transversum ...	Caput transversum ...	Caput transversum
M. abductor digiti quinti	M. abductor digiti quinti	M. abductor digiti minimi
M. flexor digiti quinti brevis	M. flexor digiti quinti brevis	M. flexor digiti minimi brevis
M. opponens digiti quinti	(M. opponens digiti quinti)	.....

BNA	JNA	PNA
M. flexor digitorum brevis	M. flexor digitorum brevis	M. flexor digitorum brevis
M. quadratus plantae ...	M. quadratus plantae ...	M. quadratus plantae (M. flexor accessorius)
Mm. lumbricales	Mm. lumbricales	Mm. lumbricales
Mm. interossei dorsales .	Mm. interossei dorsales .	Mm. interossei dorsales
Mm. interossei plantares .	Mm. interossei plantares	Mm. interossei plantares
Aponeurosis plantaris ...	Aponeurosis plantaris ...	Aponeurosis plantaris
Fasciculi transversi	.....	Fasciculi transversi
.....	.....	Lig. metatarseum transversum superficiale
Vaginae mucosae	Vaginae synoviales tendinum	Vaginae synoviales digitorum pedis*
.....	.....	Vincula tendinum
Ligg. annularia	Ligg. anularia digitorum pedis	Pars anularis vaginae fibrosae
Ligg. vaginalia	Ligg. vaginalia digitorum pedis	Vaginae fibrosae digitorum pedis*
Ligg. cruciata	Ligg. cruciformia digitorum pedis	Pars cruciformis vaginae fibrosae
Bursa praepatellaris subcutanea	Bursa praepatellaris subcutanea	Bursa subcutanea prepatellaris
Bursa praepatellaris subfascialis	Bursa praepatellaris subfascialis	(Bursa subfascialis prepatellaris)
Bursa praepatellaris subtendinea	Bursa praepatellaris subaponeurotica	(Bursa subtendinea prepatellaris)
Bursa suprapatellaris	Bursa suprapatellaris	Bursa suprapatellaris
Bursa infrapatellaris subcutanea	Bursa infrapatellaris subcutanea	Bursa subcutanea infrapatellaris
Bursa infrapatellaris prof.	Bursa infrapatellaris prof.	Bursa infrapatellaris prof.

BNA	JNA	PNA
Bursa subcutanea tuberositatis tibiae	Bursa subcutanea tuberositatis tibiae	Bursa subcutanea tuberositatis tibiae
Bursa m. sartorii propria	Bursa m. sartorii propria	Bursae subtendineae m. sartorii
Bursa anserina	Bursa anserina	Bursa anserina
Bursa m. bicipitis femoris inferior	Bursa m. bicipitis femoris distalis	Bursa subtendinea m. bicipitis femoris inferior
Bursa m. poplitei	Bursa m. poplitei	Recessus subpopliteus
.....	Bursa gastrocnemiosemimembranacea	.....
Bursa bicipitogastrocnemialis	var. Bursa bicipitogastrocnemialis	.....
Bursa m. gastrocnemii lateralis	.....	Bursa subtendinea m. gastrocnemii lateralis
Bursa m. gastrocnemii medialis	Bursa capitis tibialis m. gastrocnemii	Bursa subtendinea m. gastrocnemii medialis
Bursa m. semimembranosi	Bursa m. semimembranacei fibularis	Bursa m. semimembranosi
Bursa subcutanea malleoli lateralis	Bursa subcutanea malleoli fibulae	Bursa subcutanea malleoli lateralis
Bursa subcutanea malleoli medialis	Bursa subcutanea malleoli tibiae	Bursa subcutanea malleoli medialis
.....	Vagina tendinis m. poplitei	.....
Vagina tendinis m. tibialis anterioris	Vagina tendinis m. tibialis anterioris	Vagina tendinis m. tibialis anterioris
Vagina tendinis m. extensoris hallucis longi ...	Vagina tendinis m. extensoris hallucis longi ...	Vagina tendinis m. extensoris hallucis longi

BNA	JNA	PNA
Vaginae tendinum m. extensoris digitorum pedis longi	Vaginae tendinum m. extensoris digitorum longi	Vaginae tendinum m. extensoris digitorum pedis longi
Vaginae tendinum m. flexoris digitorum pedis longi	Vaginae tendinum m. flexoris digitorum longi .	Vaginae tendinum m. flexoris digitorum pedis longi
.....	Vaginae tendinum mm. flexorum digitorum pedis	.....
Vagina tendinis m. tibialis posterioris	Vagina tendinis m. tibialis posterioris	Vagina synovialis tendinis m. tibialis posterioris
Vagina tendinis m. flexoris hallucis longi	Vagina tendinis m. flexoris hallucis longi	Vagina synovialis tendinis m. flexoris hallucis longi
Vagina tendinum mm. peronaeorum communis .	Vagina tendinum musculorum fibularium communis	Vagina synovialis musculorum peroneorum (fibularium) communis
Bursa subcutanea calcanea	Bursa subcutanea calcanearis	Bursa subcutanea calcanea
Bursa sinus tarsi	Bursa sinus tarsi	.....
Bursa subtendinea m. tibialis anterioris	Bursa subtendinea m. tibialis anterioris	Bursa subtendinea m. tibialis anterioris
Bursa subtendinea m. tibialis posterioris	Bursa subtendinea m. tibialis posterioris	.....
Bursa tendinis calcanei (Achillis)	Bursa tendinis m. tricipitis surae	Bursa tendinis calcanei (Achillis)

BNA	JNA	PNA
Vagina tendinis m. peronaei longi plantaris ...	Vagina tendinis m. fibularis longi plantaris	Vagina tendinis m. peronei (fibularis) longi plantaris
Bursae intermetatarsophalangeae	Bursae intermetatarsophalangicae	.....
Bursae mm. lumbricalium pedis	Bursae musculorum lumbricalium pedis	.....
Vaginae tendinum digitales pedis	.....	Vaginae synoviales tendinum digitorum pedis**
MUSCULI TRUNCI°	MUSCULI TRUNCI°	MUSCULI TRUNCI°
MUSCULI THORACIS	*MUSCULI THORACIS*	*MUSCULI THORACIS*
M. pectoralis major	M. pectoralis major	M. pectoralis major
Pars clavicularis	Pars clavicularis	Pars clavicularis
Pars sternocostalis	Pars sternocostalis	Pars sternocostalis
Pars abdominalis	Pars abdominalis	Pars abdominalis
M. pectoralis minor	M. pectoralis minor	M. pectoralis minor
M. subclavius	M. subclavius	M. subclavius
M. serratus anterior	M. serratus lateralis	M. serratus anterior
(M. sternalis)	var. M. sternalis	(M. sternalis)
Mm. levatores costarum	.....	Mm. levatores costarum
Mm. levatores costarum longi ..... / Mm. levatores costarum breves	Mm. transversocostales breves et longi	Mm. levatores costarum longi / Mm. levatores costarum breves
Mm. intercostales externi	Mm. intercostales externi	Mm. intercostales externi
Ligg. intercostalia ext. ...	Ligg. intercostalia ext. ...	Membrana intercostalis ext.
Mm. intercostales interni	Mm. intercostales interni	Mm. intercostales interni
Ligg. intercostalia int. ..	Ligg. intercostalia int. ...	Membrana intercostalis int.
.....	.....	Mm. intercostales intimi
Mm. subcostales	Mm. subcostales	Mm. subcostales
M. transversus thoracis ..	M. transversus thoracis ..	M. transversus thoracis
Diaphragma	Diaphragma	Diaphragma
Pars lumbalis	Pars lumbalis	Pars lumb. crus dext. / crus sin.

BNA	JNA	PNA
Crus mediale	Crus mediale	.....
Crus intermedium ...	.....	.....
Crus laterale	Crus laterale	.....
Pars costalis	Pars costalis	Pars costalis
Pars sternalis	Pars sternalis	Pars sternalis
Hiatus aorticus	Hiatus aorticus	Hiatus aorticus
Hiatus oesophageus ...	Foramen oesophagicum	Hiatus esophageus*
Centrum tendineum ...	Centrum tendineum ...	Centrum tendineum
Foramen venae cavae .	Foramen venae cavae .	Foramen venae cavae
Arcus lumbocostalis medialis (Halleri)	Arcus lumbocostalis medialis	Lig. arcuatum mediale*
Arcus lumbocostalis lateralis (Halleri)	Arcus lumbocostalis lateralis	Lig. arcuatum laterale*
.....	.....	Lig. arcuatum medianum*
.....	Fasciae pectorales	.....
Fascia pectoralis	Fascia pectoralis superficialis	Fascia pectoralis
Fascia coracoclavicularis .	Fascia coracocleidopectoralis	Fascia clavipectoralis
MUSCULI ABDOMINIS	*MUSCULI ABDOMINIS*	*MUSCULI ABDOMINIS*
M. rectus abdominis	M. rectus abdominis	M. rectus abdominis
Inscriptiones tendineae .	Inscriptiones tendineae .	Intersectiones tendineae
M. pyramidalis	M. pyramidalis	M. pyramidalis
M. obliquus externus abdominis	M. obliquus abdominis externus	M. obliquus externus abdominis
M. obliquus internus abdominis	M. obliquus abdominis internus	M. obliquus internus abdominis
M. cremaster	M. cremaster	M. cremaster
M. transversus abdominis	M. transversus abdominis	M. transversus abdominis
M. quadratus lumborum	M. quadratus lumborum	M. quadratus lumborum
Linea alba	Linea alba	Linea alba
Annulus umbilicalis ...	Anulus umbilicalis	Anulus umbilicalis

BNA	JNA	PNA
Adminiculum lineae albae	Adminiculum lineae albae	Adminiculum lineae albae
Falx (aponeurotica) inguinalis	Falx inguinalis	Falx inguinalis (Tendo conjunctivus)
Lig. suspensorium penis s. clitoridis	.....	Lig. suspensorium penis s. clitoridis
Lig. fundiforme penis ...	Lig. fundiforme penis ...	Lig. fundiforme penis
Vagina m. recti abdominis	Vagina m. recti abdominis	Vagina m. recti abdominis Lamina anterior
.....	.....	Lamina posterior
Linea semicircularis (Douglasi)	Linea semicircularis ...	Linea arcuata
Lig. inguinale (Pouparti)	Lig. inguinale	Lig. inguinale
Lig. lacunare (Gimbernati)	Lig. lacunare	Lig. lacunare
Lig. reflexum (Collesi) .	Lig. inguinale reflexum	Lig. reflexum
.....	.....	Lig. pectineale
Canalis inguinalis	Canalis inguinalis	Canalis inguinalis
Annulus inguinalis subcutaneus	Anulus inguinalis subcutaneus	Anulus inguinalis superficialis
Crus superius	Crus mediale	Crus mediale
Crus inferius	Crus laterale	Crus laterale
Fibrae intercrurales .	Fibrae intercrurales .	Fibrae intercrurales
Annulus inguinalis abdominalis	Anulus inguinalis praeperitonealis	Anulus inguinalis profundus
.....	Pars interlacunaris fasciae ilicae	Arcus iliopectineus
Lig. interfoveolare (Hesselbachi)	Lig. interfoveolare	Lig. interfoveolare
.....	var. M. interfoveolaris . .	.....
Trigonum lumbale (Petiti)	Trigonum lumbale	Trigonum lumbale
Linea semilunaris (Spigeli)	.....	Linea semilunaris
Fascia transversalis	Fascia transversalis	Fascia transversalis

BNA	JNA	PNA
MUSCULI DORSI	*MUSCULI DORSI*	*MUSCULI DORSI*
Musculi dorsi superficiales°		
M. trapezius	M. trapezius	M. trapezius
.....	.....	Bursa subtendinea m. trapezii
(M. transversus nuchae) .	M. transversus nuchae ..	(M. transversus nuchae)
M. latissimus dorsi	M. latissimus dorsi	M. latissimus dorsi
Bursa m. latissimi dorsi . . .	Bursa m. latissimi dorsi . . .	Bursa subtendinea m. latissimi dorsi
M. rhomboideus major ..	M. rhomboides major ..	M. rhomboideus major
M. rhomboideus minor ..	M. rhomboides minor ...	M. rhomboideus minor
M. levator scapulae	M. levator scapulae	M. levator scapulae
M. serratus posterior superior	M. serratus dorsalis cranialis	M. serratus posterior superior
M. serratus posterior inferior	M. serratus dorsalis caudalis	M. serratus posterior inf.
.....	M. splenius	.....
M. splenius capitis	M. splenius capitis	M. splenius capitis
M. splenius cervicis	M. splenius cervicis	M. splenius cervicis
.....	Aponeurosis lumbalis	.....
Fascia lumbodorsalis	Fascia lumbodorsalis	Fascia thoracolumbalis
.....	Pars aponeurotica fasciae lumbodorsalis	.....
Musculi dorsi profundi°		
M. sacrospinalis	M. sacrospinalis	M. erector spinae
M. iliocostalis	M. iliocostalis	M. iliocostalis
M. iliocostalis lumborum	.....	M. iliocostalis lumborum
M. iliocostalis dorsi .	.....	M. iliocostalis thoracis
M. iliocostalis cervicis	.....	M. iliocostalis cervicis
M. longissimus	M. longissimus	M. longissimus
M. longissimus cervicis ..... / M. longissimus dorsi	M. longissimus dorsi et cervicis	M. longissimus cervicis / M. longissimus thoracis
M. longissimus capitis	(M. longissimus capitis)	M. longissimus capitis

BNA	JNA	PNA
.....	Fasciculi mamillotendinei	.....
M. spinalis	M. spinalis	M. spinalis
M. spinalis dorsi	.....	M. spinalis thoracis
M. spinalis cervicis ...	.....	M. spinalis cervicis
M. spinalis capitis	.....	M. spinalis capitis
.....	.....	M. transversospinalis*
M. semispinalis	M. semispinalis	M. semispinalis
M. semispinalis dorsi ..	.....	M. semispinalis thoracis
M. semispinalis cervicis	.....	M. semispinalis cervicis
M. semispinalis capitis	M. transversooccipitalis	M. semispinalis capitis
M. multifidus	M. multifidus	Mm. multifidi**
Mm. rotatores	Mm. rotatores	Mm. rotatores
		Mm. rotatores cervicis
		Mm. rotatores lumborum
		Mm. rotatores thoracis
Mm. rotatores longi ..	.....	.....
Mm. rotatores breves .	.....	.....
Mm. interspinales	Mm. interspinales cervicis	Mm. interspinales
		Mm. interspinales cervicis
		Mm. interspinales lumborum
		Mm. interspinales thoracis
Mm. intertransversarii ..	.....	Mm. intertransversarii
.....	.....	Mm. intertransversarii thoracis
Mm. intertransversarii laterales	Mm. intercostales lumbales	Mm. intertransversarii laterales lumborum
Mm. intertransversarii mediales		Mm. intertransversarii mediales lumborum
Mm. intertransversarii anteriores	Mm. intercostotransversarii ventrales	Mm. intertransversarii anteriores cervicis
Mm. intertransversarii posteriores	Mm. intercostotransversarii cervicales	Mm. intertransversarii posteriores cervicis
		Pars lateralis
		Pars medialis

BNA	JNA	PNA
Musculi suboccipitales°		
M. rectus capitis posterior major	M. rectus capitis dorsalis major	M. rectus capitis posterior major
M. rectus capitis posterior minor	M. rectus capitis dorsalis minor	M. rectus capitis posterior minor
M. rectus capitis lateralis	M. rectus capitis lateralis	M. rectus capitis lateralis
M. obliquus capitis superior	M. obliquus capitis	M. obliquus capitis sup.
M. obliquus capitis inferior	M. obliquus atlantis	M. obliquus capitis inf.
Fascia nuchae	Fascia nuchae	Fascia nuchae
Musculi coccygei	*Musculi coccygici*	*Musculi coccygei*
M. coccygeus	M. coccygicus	M. coccygeus
M. sacrococcygeus anterior	M. sacrococcygicus ventralis	(M. sacrococcygeus ventralis)
M. sacrococcygeus posterior	M. sacrococcygicus dorsalis	(M. sacrococcygeus dors.)
Bursa subcutanea sacralis	Bursa subcutanea sacralis	.....
Bursa coccygea	Bursa coccygica	.....
MUSCULI COLLI	MUSCULI COLLI	MUSCULI COLLI
Musculi colli superficiales°		
Platysma	Platysma	Platysma
M. sternocleidomastoideus	M. sternocleidomastoideus	M. sternocleidomastoideus
Musculi ossis hyoidei	.....	.....
.....	.....	Mm. suprahyoidei
M. digastricus	M. biventer mandibulae .	M. digastricus
Venter anterior	Venter mandibularis ...	Venter anterior

BNA	JNA	PNA
Venter posterior	Venter mastoideus	Venter posterior
M. stylohyoideus	M. stylohyoideus	M. stylohyoideus
M. mylohyoideus	M. mylohyoideus	M. mylohyoideus
M. geniohyoideus	M. geniohyoideus	M. geniohyoideus
.....	.....	Mm. infrahyoidei
M. sternohyoideus	M. sternohyoideus	M. sternohyoideus
M. omohyoideus	M. omohyoideus	M. omohyoideus
Venter superior	Venter cranialis	Venter superior
Venter inferior	Venter caudalis	Venter inferior
M. sternothyreoideus ...	M. sternothyreoideus ...	M. sternothyroideus*
M. thyreohyoideus	M. thyreohyoideus	M. thyrohyoideus*
(M. levator glandulae thyreoideae)	var. M. levator glandulae thyreoideae	(M. levator glandulae thyroideae)**
Musculi colli profundi°		
Musculus longus colli ...	M. longus colli	M. longus colli
M. scalenus anterior	M. scalenus ventralis	M. scalenus anterior
M. scalenus medius	M. scalenus medius	M. scalenus medius
M. scalenus posterior ...	M. scalenus dorsalis	M. scalenus posterior
(M. scalenus minimus) ..	.....	(M. scalenus minimus)
Fascia colli	Fasciae colli	Fascia cervicalis
.....	Fascia colli superficialis	Lamina superficialis
.....	Fascia colli media	Lamina pretrachealis
Fascia praevertebralis ...	Fascia colli profunda (praevertebralis)	Lamina prevertebralis
Bursa subcutanea prominentiae laryngeae	Bursa subcutanea prominentiae laryngicae	Bursa subcutanea prominentiae laryngeae
Bursa m. sternohyoidei .	Bursa m. sternohyoidei .	Bursa retrohyoidea Bursa infrahyoidea
Bursa m. thyreohyoidei ..	Bursa m. thyreohyoidei ..	.....
.....	.....	Vagina carotica
MUSCULI CAPITIS	MUSCULI CAPITIS	MUSCULI CAPITIS
Musculi epicranii°		
M. longus capitis	M. longus capitis	M. longus capitis
M. rectus capitis anterior	M. rectus capitis ventr. ..	M. rectus capitis anterior

BNA	JNA	PNA
.....	.....	M. temporoparietalis
M. epicranius	Mm. epicranii	M. epicranius
.....	Pars triangularis (mm. epicranii temporoparietalis)	.....
.....	M. epicranius temporoparietalis	.....
.....	.....	M. occipitofrontalis
M. occipitalis	M. occipitalis	Venter occipitalis
M. frontalis	M. frontalis	Venter frontalis
M. auricularis anterior	M. auricularis temporalis	M. auricularis anterior
M. auricularis superior	Pars parietalis (m. epicranii temporoparietalis)	M. auricularis superior
M. auricularis posterior	M. auricularis nuchalis	M. auricularis posterior
Galea aponeurotica	Galea aponeurotica	Galea aponeurotica (Aponeurosis epicranialis)*
Musculi faciei°		
M. orbicularis oculi	M. orbicularis oculi	M. orbicularis oculi
Pars palpebralis	Pars palpebralis	Pars palpebralis
.....	M. depressor capitis supercilii	M. depressor supercilii
Pars orbitalis	Pars orbitalis	Pars orbitalis
Pars lacrimalis (Horneri)	Pars sacci lacrimalis ...	Pars lacrimalis
.....	(Fasciculus labialis) (M. orbicularis oculi)	.....
.....	M. corrugator glabellae	M. corrugator supercilii
M. procerus	M. depressor glabellae ..	M. procerus
M. nasalis	M. nasalis	M. nasalis
M. depressor septi	Origo nasalis (m. orbicularis oris)	M. depressor septi
Pars transversa	.....	Pars transversa*
Pars alaris	.....	Pars alaris*
M. orbicularis oris	M. orbicularis oris	M. orbicularis oris
		Pars marginalis
		Pars labialis
M. incisivi labii sup. .	Origo maxillaris (m. orbicularis oris)	.....
Musculi incisivi labii inferioris	Origo mandibularis (m. orbicularis oris)	.....

BNA	JNA	PNA
M. quadratus labii superioris	.....	.....
Caput zygomaticum (m. quadrati labii sup.) ...	M. zygomaticus minor	M. zygomaticus minor
Caput infraorbitale (m. quadrati labii sup.) ...	M. levator nasi et labii maxillaris lateralis ...	M. levator labii superioris
Caput angulare (m. quadrati labii sup.)	M. levator nasi et labii maxillaris medialis ..	M. levator labii superioris alaeque nasi
M. caninus	M. caninus	M. levator anguli oris
.....	Fasciculi (musculares) periostales maxillae	.....
M. zygomaticus	M. zygomaticus major ..	M. zygomaticus major
M. risorius	M. risorius	M. risorius
.....	Pars facialis platysmatis .	.....
M. triangularis	M. triangularis	M. depressor anguli oris
M. quadratus labii inferioris	M. quadratus labii mandibularis	M. depressor labii inferioris
.....	Fasciculi (musculares) periostales mandibulae ...	.....
M. mentalis	M. mentalis	M. mentalis
(M. transversus menti) ..	M. transversus menti	M. transversus menti
M. buccinator	M. bucinatorius	M. buccinator
.....	Fasciculus mentalis (m. bucinatorii)	.....
Musculi masseterici°		
M. masseter	M. masseter	M. masseter Pars superficialis Pars profunda
M. temporalis	M. temporalis	M. temporalis
M. pterygoideus externus	M. pterygoideus lateralis	M. pterygoideus lateralis
M. pterygoideus internus	M. pterygoideus medialis	M. pterygoideus medialis
Fascia buccopharyngea ..	Fascia pharyngobucinatoria	Fascia buccopharyngea
Fascia parotideomasseterica	Fascia masseterica	Fascia parotidea Fascia masseterica

BNA	JNA	PNA
Fascia temporalis	Fascia temporalis	Fascia temporalis
.....	Lamina profunda (fasciae temporalis)	Lamina profunda
.....	Lamina superficialis (fasciae temporalis)	Lamina superficialis
Bursa musculi trochlearis	Vagina synovialis trochleae	Vagina synovialis m. obliqui superioris
Bursa m. tensoris veli palatini	(Bursa synovialis tendinis musculi tensoris veli palatini)	Bursa m. tensoris veli palatini
Bursa subcutanea praementalis	.....	.....

Splanchnologia		*Splanchnologia*
Tunica mucosa		Tunica mucosa
Lamina propria mucosae		Lamina propria mucosae
Lamina muscularis mucosae		Lamina muscularis mucosae
Tela submucosa		Tela submucosa
Plica mucosa		
Mucus		
Tunica muscularis		Tunica muscularis
Tunica serosa		Tunica serosa
Tela subserosa (peritonaei)	Tela subserosa	Tela subserosa
Plica serosa		
Ligamentum serosum		
Serum		
Tunica albuginea		Tunica albuginea
Tunica fibrosa		Tunica fibrosa
Tunica adventitia		Tunica adventitia
Epithelium		Epithelium
Endothelium		Endothelium
Glandula		Glandula
Lobus		Lobus
Lobulus		Lobulus
Glandula mucosa	Glandula mucosa	Glandula mucosa
		Glandula serosa
		Glandula seromucosa
Musculus viscerum		
Organon parenchymatosum		
Parenchyma		Parenchyma
Stroma		Stroma

BNA	JNA	PNA
APPARATUS DIGESTORIUS	SYSTEMA DIGESTORIUM	APPARATUS DIGESTORIUS (SYSTEMA DIGESTORIUM)
CAVUM ORIS	CAVUM ORIS	CAVUM ORIS
Labia oris	Labia oris	Labia oris
Labium superius	Labium maxillare	Labium superius
Labium inferius	Labium mandibulare ..	Labium inferius
Commissura labiorum .	Commissura labiorum .	Commissura labiorum
Philtrum	Philtrum	Philtrum
		Tuberculum
Angulus oris	Angulus oris	Angulus oris
Rima oris	Rima oris	Rima oris
Vestibulum oris	Vestibulum oris	Vestibulum oris
Cavum oris proprium ...	.....	Cavum oris proprium
Palatum	Palatum	Palatum
Palatum durum	Palatum durum	Palatum durum
Palatum molle	Palatum molle	Palatum molle (Velum palatinum)**
Raphe palati	Rhaphe palati	Raphe palati
Bucca (Mala)	Bucca	Bucca
Corpus adiposum buccae	Corpus adiposum buccae	Corpus adiposum buccae
Tunica mucosa (oris)	*Tunica mucosa oris*	*Tunica mucosa oris*
Frenulum labii superioris	Frenulum labii maxillaris	Frenulum labii superioris
Frenulum labii inferioris	Frenulum labii mandibularis	Frenulum labii inferioris
Gingiva	Gingiva	Gingivae
Caruncula sublingualis ...	Papilla salivaria sublingualis	Caruncula sublingualis
.....	Carunculae sublinguales .	.....
Plica sublingualis	Plica sublingualis	Plica sublingualis

BNA	JNA	PNA
Plicae palatinae transversae	Plicae palatinae transversae	Plicae palatinae transversae
Papilla incisiva	Papilla incisiva	Papilla incisiva
Glandulae oris	*Glandulae oris*	*Glandulae oris*
Glandulae labiales	Glandulae labiales	Glandulae labiales
Glandulae buccales	Glandulae buccales	Glandulae buccales
Glandulae palatinae	Glandulae palatinae	Glandulae palatinae
Glandulae linguales	Glandulae linguales	Glandulae linguales
Glandulae molares	Glandulae retromolares ..	Glandulae molares
Glandula lingualis anterior (Blandini, Nuhni)	Glandula apicis linguae ..	Glandula lingualis ant.
Glandula sublingualis	*Glandula sublingualis*	*Glandula sublingualis*
.....	Glandulae sublinguales minores	.....
Ductus sublingualis major	Ductus sublingualis major	Ductus sublingualis major
Ductus sublinguales minores	Ductus sublinguales minores	Ductus sublinguales minores
Glandula submaxillaris	*Glandula submandibularis*	*Glandula submandibularis*
Ductus submaxillaris (Whartoni)	Ductus submandibularis .	Ductus submandibularis
Glandula parotis	*Glandula parotis*	*Glandula parotis*
		Pars superficialis
		Pars profunda
Ductus parotideus (Stenonis)	Ductus parotidicus	Ductus parotideus
Processus retromandibularis	Processus retromandibularis	.....
Glandula parotis accessoria	var. Glandula parotis accessoria	Gl. parotis accessoria
.....	Papilla salivaria buccalis .	Papilla parotidea

BNA	JNA	PNA
Saliva	.....	.....
DENTES	DENTES	DENTES
Dentes decidui	Dentes decidui	Dentes decidui
Dentes permanentes	Dentes permanentes	Dentes permanentes
Corona dentis	Corona dentis	Corona dentis
.....	.....	Cuspis (coronae) dentis**
.....	.....	Apex cuspidis**
Tubercula coronae dentis	Tubercula coronae dentis	Tuberculum (coronae) dentis**
.....	.....	Crista transversalis**
.....	.....	Crista triangularis**
.....	.....	Corona clinica**
Facies labialis (buccalis) .	Facies labialis, buccalis .	Facies vestibularis (facialis)**
Facies lingualis	Facies lingualis, palatina	Facies lingualis
Facies masticatoria	Facies masticatoria	Facies occlusalis**
Facies contactus	Facies contactus	Facies contactus
Facies medialis (dentium incisivorum et caninorum)	Facies medialis dentium incisivorum et caninorum	Facies mesialis**
Facies anterior (dentium praemolarium et molarium)	Facies anterior dentium praemolarium et molarium	
Facies lateralis (dentium incisivorum et caninorum)	Facies lateralis dentium incisivorum et caninorum	Facies distalis**
Facies posterior (dentium praemolarium et molarium)	Facies posterior dentium praemolarium et molarium	
.....	.....	Cingulum**

BNA	JNA	PNA
.....	.....	Crista marginalis**
.....	.....	Margo incisalis**
Cavum dentis	Cavum dentis	Cavum dentis
.....	.....	Cavum coronale**
Pulpa dentis	Pulpa dentis	Pulpa dentis
		Pulpa coronale**
		Pulpa radicularis**
Papilla dentis	.....	Papilla dentis
Colllum dentis	Collum dentis	Collum (cervix) dentis**
Radix (Radices) dentis ..	Radix dentis	Radix dentis**
.....	Rami radicis	.....
Canalis radicis dentis ..	Canalis radicis dentis ..	Canalis radicis dentis
.....	Canalis rami radicis	.....
Apex radicis dentis	Apex radicis dentis	Apex radicis dentis
.....	.....	Radix clinica**
.....	Apex rami radicis	.....
.....	Foramen apicis rami radicis	.....
Foramen apicis dentis	Foramen apicis dentis	Foramen apicis dentis
Substantia eburnea	Substantia eburnea	Dentinum
Substantia adamantina ..	Substantia adamantina ..	Enamelum
Substantia ossea	Substantia ossea	Cementum
Spatia interglobularia	.....	Spatia interglobularia
Canaliculi dentales	.....	Canaliculi dentales
Prismata adamantina ...	.....	Prismata adamantina
Cuticula dentis	Cuticula dentis	Cuticula dentis
Periosteum alveolare	Periosteum alveolare	Periodontium
Arcus dentalis superior .	Arcus dentalis maxillaris .	Arcus dentalis superior
Arcus dentalis inferior ...	Arcus dentalis mandibularis	Arcus dentalis inferior
Dentes incisivi	Dentes incisivi	Dentes incisivi
Dentes canini	Dentes canini	Dentes canini
Dentes praemolares	Dentes praemolares	Dentes premolares
Dentes molares	Dentes molares	Dentes molares
Dens serotinus	Dens serotinus	Dens serotinus
LINGUA	LINGUA	LINGUA
.....	Aponeurosis linguae	Aponeurosis linguae
Corpus linguae	Corpus linguae	Corpus linguae
Apex linguae	Apex linguae	Apex linguae
Radix linguae	Radix linguae	Radix linguae
Margo lateralis	Margo lateralis linguae .	Margo linguae
Dorsum linguae	Dorsum linguae	Dorsum linguae

BNA	JNA	PNA
Sulcus medianus linguae	Sulcus medianus linguae	Sulcus medianus linguae
Sulcus terminalis	Sulcus terminalis linguae	Sulcus terminalis
Foramen caecum linguae (Morgagnii)	Foramen caecum linguae	Foramen cecum linguae*
Papillae linguales	Papillae linguales	Papillae linguales
Papillae filiformes	Papillae filiformes	Papillae filiformes
Papillae conicae	.....	Papillae conicae
Papillae fungiformes ...	Papillae fungiformes ...	Papillae fungiformes
Papillae lenticulares ...	.....	.....
Papillae vallatae	Papillae circumvallatae .	Papillae vallatae
Papillae foliatae	Papillae foliatae { Regio foliata. Folia	Papillae foliatae
Tonsilla lingualis	Tonsilla lingualis	Tonsilla lingualis
Folliculi linguales ...	Folliculi linguales ...	Folliculi linguales
(Ductus lingualis)	var. Ductus lingualis ..	.....
Ductus thyreoglossus .	(Ductus thyreoglossus)	Ductus thyroglossus*
Facies inferior (linguae) .	Facies mylohyoidea linguae	Facies inferior linguae
Plica fimbriata	Plica fimbriata	Plica fimbriata
Frenulum linguae	Frenulum linguae	Frenulum linguae
Septum linguae	Septum linguae	Septum linguae
Tunica mucosa	Tunica mucosa linguae ..	Tunica mucosa linguae
Musculi linguae	*Musculi linguae*	*Musculi linguae*
M. longitudinalis superior	M. longitudinalis superficialis	M. longitudinalis superior
M. longitudinalis inferior	M. longitudinalis profundus	M. longitudinalis inferior
M. transversus linguae ..	M. transversus linguae ..	M. transversus linguae
M. verticalis linguae	M. verticalis linguae	M. verticalis linguae
M. genioglossus	M. genioglossus	M. genioglossus
M. hyoglossus	M. hyoglossus	M. hyoglossus
M. styloglossus	M. styloglossus	M. styloglossus
M. chondroglossus	.....	M. chondroglossus
FAUCES	FAUCES	FAUCES
Isthmus faucium	Isthmus faucium	Isthmus faucium
Velum palatinum	Velum palatinum	Velum palatinum
Uvula (palatina)	Uvula palatina	Uvula (palatina)
Arcus palatini	Arcus palatini	.....

BNA	JNA	PNA
Arcus glossopalatinus	Arcus glossopalatinus	Arcus palatoglossus
Arcus pharyngopalatinus	Arcus pharyngopalatinus	Arcus palatopharyngeus
Sinus tonsillaris	Sinus tonsillaris	.....
Tonsilla palatina	Tonsilla palatina	Tonsilla palatina
Fossulae tonsillares .	.....	Fossulae tonsillares
		Cryptae tonsillares
Plica salpingopalatina .	Plica palatotubalis	Plica salpingopalatina
Plica triangularis	Plica triangularis	Plica triangularis
.....	.....	Plica semilunaris*
.....	.....	Fossa tonsillaris*
Fossa supratonsillaris ..	Fossa supratonsillaris ..	Fossa supratonsillaris
Musculi palati et faucium	*Musculi palati et faucium*	*Musculi palati et faucium*
M. levator veli palatini ..	M. levator veli palatini ..	M. levator veli palatini
M. tensor veli palatini ..	M. tensor veli palatini ..	M. tensor veli palatini
M. uvulae	M. uvulae	M. uvulae
M. glossopalatinus	M. glossopalatinus	M. palatoglossus
M. pharyngopalatinus ...	M. pharyngopalatinus ...	M. palatopharyngeus
PHARYNX	PHARYNX	PHARYNX
Pars nasalis	Pars nasalis	Pars nasalis
Fornix pharyngis	Fornix pharyngis	Fornix pharyngis
Tonsilla pharyngea	Tonsilla pharyngica ...	Tonsilla pharyngea
Fossulae tonsillares .	.....	Fossulae tonsillares
		Cryptae tonsillares
Ostium pharyngeum tubae	Ostium pharyngicum tubae pharyngotympanicae	Ostium pharyngeum tubae auditivae**
Labium anterius	.....	.....
Labium posterius ...	.....	.....
Torus tubarius	Torus tubalis	Torus tubarius
.....	.....	Tonsilla tubaria
Plica salpingopharyngea	Plica pharyngotubalis ..	Plica salpingopharyngea
.....	Torus m. levatoris	Torus levatorius
Recessus pharyngeus (Rosenmülleri)	Recessus pharyngicus ..	Recessus pharyngeus

BNA	JNA	PNA
(Bursa pharyngea)	(Bursa pharyngica) ...	Bursa pharyngea
Pars oralis	Pars oralis	Pars oralis
Vallecula epiglottica ...	Vallecula epiglottidis ..	Vallecula epiglottica
Plica glossoepiglottica mediana	Plica glossoepiglottica mediana	Plica glossoepiglottica mediana*
Plica glossoepiglottica lateralis	Plica glossoepiglottica lateralis	Plica glossoepiglottica lateralis*
Pars laryngea	Pars laryngica	Pars laryngea
Recessus piriformis	Recessus piriformis	Recessus piriformis
Plica mucosa	Plica nervi laryngici ...	Plica nervi laryngei
Cavum pharyngis	Cavum pharyngis	Cavum pharyngis
Tunica mucosa	Tunica mucosa pharyngis	Tunica mucosa
.....	Tunica propria mucosae pharyngis	.....
Glandulae pharyngeae	Gll. pharyngicae	Glandulae pharyngeae
Tela submucosa	.....	Tela submucosa
Tunica muscularis	.....	Tunica muscularis pharyngis
Fascia pharyngobasilaris	Lamina pharyngobasilaris	Fascia pharyngobasilaris
Raphe pharyngis	Rhaphe pharyngis	Raphe pharyngis
Raphe pterygomandibularis	Rhaphe bucipharyngica ..	Raphe pterygomandibularis
Musculi pharyngis[o]		
M. stylopharyngeus	M. stylopharyngicus	M. stylopharyngeus
M. salpingopharyngeus ..	M. pharyngotubalis	M. salpingopharyngeus
M. constrictor pharyngis superior	M. cephalopharyngicus ..	M. constrictor pharyngis superior
M. pterygopharyngeus .	Pars pterygopharyngica	Pars pterygopharyngea
M. buccopharyngeus ..	Pars bucipharyngica ...	Pars buccopharyngea
M. mylopharyngeus ...	Pars mylopharyngica ..	Pars mylopharyngea
M. glossopharingeus ..	Pars glossopharyngica .	Pars glossopharyngea
M. constrictor pharyngis medius	M. hyopharyngicus	M. constrictor pharyngis medius
M. chondropharyngeus	Pars chondropharyngica	Pars chondropharyngea

BNA	JNA	PNA
M. ceratopharyngeus ..	Pars ceratopharyngica .	Pars ceratopharyngea
M. constrictor pharyngis inferior	M. laryngopharyngicus ..	M. constrictor pharyngis inferior
M. thyreopharyngeus ..	Pars thyreopharyngica	Pars thyropharyngea*
M. cricopharyngeus ...	Pars cricopharyngica ..	Pars cricopharyngea
TUBUS DIGESTORIUS	.....	*CANALIS ALIMENTARIUS*
OESOPHAGUS	OESOPHAGUS	ESOPHAGUS*
Pars cervicalis	.....	Pars cervicalis
Pars thoracalis	.....	Pars thoracica
Pars abdominalis	.....	Pars abdominalis
Tunica adventitia	.....	Tunica adventitia
Tunica muscularis	Tunica muscularis	Tunica muscularis
.....	.....	Tendo cricoesophageus*
Musculus bronchooesophageus	M. bronchooesophagicus	M. bronchoesophageus*
Musculus pleurooesophageus	M. pleurooesophagicus	M. pleuroesophageus*
Tela submucosa	Tela submucosa	Tela submucosa
Tunica mucosa	Tunica mucosa	Tunica mucosa
Lamina muscularis mucosae	Lamina muscularis mucosae	Lamina muscularis mucosae
Glandulae oesophageae	Gll. oesophagicae	Glandulae esophageae*
VENTRICULUS (GASTER)	VENTRICULUS = GASTER	VENTRICULUS (GASTER)
Paries anterior	Paries ventrocranialis	Paries anterior
Paries posterior	Paries dorsocaudalis	Paries posterior
Curvatura ventriculi major	Curvatura ventriculi major	Curvatura ventriculi major
Curvatura ventriculi minor	Curvatura ventriculi minor	Curvatura ventriculi minor
.....	Incisura angularis	Incisura angularis
Cardia	Cardia	Ostium cardiacum
Pars cardiaca	.....	Pars cardiaca
(Antrum cardiacum) ...	.....	.....
.....	.....	Incisura cardiaca
Fundus ventriculi	Fundus ventriculi	Fundus ventriculi

BNA	JNA	PNA
Corpus ventriculi	Corpus ventriculi	Corpus ventriculi
		Canalis ventriculi
Pylorus	Pylorus	Pylorus
Pars pylorica	Pars pylorica	Pars pylorica
		Canalis pyloricus
Antrum pyloricum	.....	Antrum pyloricum
.....	.....	Ostium pyloricum
Tunica serosa	Tunica serosa	Tunica serosa
.....	.....	Tela subserosa*
Tunica muscularis	Tunica muscularis	Tunica muscularis
Stratum longitudinale .	Stratum longitudinale .	Stratum longitudinale
Stratum circulare	Stratum circulare	Stratum circulare
Musculus sphincter pylori	Musculus sphincter pylori	Musculus sphincter pylori
Fibrae obliquae	Fibrae obliquae	Fibrae obliquae
Lig. pylori	.....	.....
Valvula pylori	.....	.....
Tela submucosa	Tela submucosa	Tela submucosa
Tunica mucosa	Tunica mucosa	Tunica mucosa
Lamina muscularis mucosae	Lamina muscularis mucosae	Lamina muscularis mucosae
Areae gastricae	Areae gastricae	Areae gastricae
Plicae villosae	.....	Plicae villosae
Foveolae gastricae	Foveolae gastricae	Foveolae gastricae
Glandulae gastricae (propriae)	Glandulae gastricae (propriae)	Glandulae gastricae (propriae)
Glandulae pyloricae ..	Glandulae pyloricae ..	Glandulae pyloricae
Noduli lymphatici gastrici	Lymphonoduli gastrici ...	Folliculi lymphatici gastrici
Succus gastricus	.....	.....
.....	.....	Plicae gastricae
INTESTINUM TENUE	**INTESTINUM TENUE**	**INTESTINUM TENUE**
Tunica serosa	Tunica serosa	Tunica serosa
.....	.....	Tela subserosa*
Tunica muscularis	Tunica muscularis	Tunica muscularis
Stratum longitudinale .	Stratum longitudinale .	Stratum longitudinale

BNA	JNA	PNA
Stratum circulare	Stratum circulare	Stratum circulare
Tela submucosa		Tela submucosa
Tunica mucosa	Tunica mucosa	Tunica mucosa
Lamina muscularis mucosae	Lamina muscularis mucosae	Lamina muscularis mucosae
Plicae circulares (Kerckringi)	Plicae circulares	Plicae circulares
Villi intestinales	Villi intestinales	Villi intestinales
Glandulae intestinales (Lieberkühni)	Glandulae intestinales	Glandulae intestinales
Noduli lymphatici solitarii	Lymphonoduli solitarii	Folliculi lymphatici solitarii
Noduli lymphatici aggregati (Peyeri)	Lymphonoduli aggregati	Folliculi lymphatici aggregati
Chymus		
Chylus		
Succus entericus		
DUODENUM	INTESTINUM DUODENUM	DUODENUM
Pars superior	Pars cranialis	Pars superior
Pars descendens	Pars descendens	Pars descendens
Pars inferior Pars horizontalis (inferior)	Pars caudalis	Pars horizontalis (inferior)*
Pars ascendens	Pars ascendens	Pars ascendens
Flexura duodeni superior	Flexura duodeni cranialis	Flexura duodeni superior
Flexura duodeni inferior	Flexura duodeni caudalis	Flexura duodeni inferior
Flexura duodenojejunalis	Flexura duodenojejunalis	Flexura duodenojejunalis
M. suspensorius duodeni	M. suspensorius duodeni	M. suspensorius duodeni
	Pars tecta duodeni	
Plica longitudinalis duodeni	Plica longitudinalis duodeni	Plica longitudinalis duodeni
Papilla duodeni (Santorini)	Papilla duodeni	Papilla duodeni major Papilla duodeni minor
Glandulae duodenales (Brunneri)	Glandulae duodenales	Glandulae duodenales

BNA	JNA	PNA
INTESTINUM JEJUNUM	INTESTINUM JEJUNUM	JEJUNUM
INTESTINUM ILEUM	INTESTINUM ILIUM	ILEUM
INTESTINUM CRASSUM	INTESTINUM CRASSUM	INTESTINUM CRASSUM
INTESTINUM CAECUM	INTESTINUM CAECUM	CECUM*
Valvula coli	Valvula coli	Valva ileocecalis*
.....	Ostium iliocaecocolicum	Ostium ileocecale*
Labium superius	Labium craniale	.....
Labium inferius	Labium caudale	.....
Frenulum valvulae coli	Frenula valvulae	Frenulum valvae ileocecalis*
PROCESSUS VERMIFORMIS	PROCESSUS VERMIFORMIS	APPENDIX VERMIFORMIS
.....	.....	Ostium appendicis vermiformis
(Valvula processus vermiformis)	Valvula processus vermiformis	.....
Noduli aggregati processus vermiformis	Lymphonoduli aggregati processus vermiformis .	Folliculi lymphatici aggregati appendicis vermiformis
COLON	INTESTINUM COLON	COLON
Colon ascendens	Colon ascendens	Colon ascendens
Flexura coli dextra	Flexura coli hepatica = dextra	Flexura coli dextra
Colon transversum	Colon transversum	Colon transversum
Flexura coli sinistra	Flexura coli lienalis = sinistra	Flexura coli sinistra
Colon descendens	Colon descendens	Colon descendens
Colon sigmoideum	Colon sigmoides	Colon sigmoideum
Haustra coli	Haustra coli	Haustra coli
Tunica serosa	Tunica serosa	Tunica serosa
.....	.....	Tela subserosa*
Appendices epiploicae ...	Appendices epiploicae ...	Appendices epiploicae
Plicae semilunares coli ..	Plicae semilunares coli ..	Plicae semilunares coli
Tunica muscularis	Tunica muscularis	Tunica muscularis
		Stratum circulare
		Stratum longitudinale*

BNA	JNA	PNA
Taeniae coli	Taeniae coli	Teniae coli*
Taenia mesocolica ..	Taenia mesocolica ..	Tenia mesocolica*
Taenia omentalis	Taenia omentalis	Tenia omentalis*
Taenia libera	Taenia libera	Tenia libera*
Tela submucosa	Tela submucosa	Tela submucosa
Tunica mucosa	Tunica mucosa	Tunica mucosa
Lamina muscularis mucosae	Lamina muscularis mucosae	Lamina muscularis mucosae
Glandulae intestinales (Lieberkühni)	Glandulae intestinales .	Glandulae intestinales
Noduli lymphatici solitarii	Lymphonoduli solitarii	Folliculi lymphatici solitarii
.....	Lymphonoduli aggregati (intestini coli)	.....
INTESTINUM RECTUM	INTESTINUM RECTUM = TERMINALE	RECTUM
Flexura sacralis recti	Flexura sacralis	Flexura sacralis
Flexura perinealis recti ..	Flexura perinealis	Flexura perinealis
Ampulla recti	Pars ampullaris	Ampulla recti
Pars analis (recti)	Pars analis recti	Canalis analis
Anus	Anus	Anus
M. sphincter ani ext.	M. sphincter ani ext.	M. sphincter ani externus*
Tunica muscularis	Tunica muscularis	Tunica muscularis Stratum longitudinale Stratum circulare
M. sphincter ani int.	M. sphincter ani int.	M. sphincter ani internus
M. rectococcygeus	M. rectococcygicus	M. rectococcygeus
.....	.....	M. rectourethralis
.....	.....	M. rectovesicalis**
Tela submucosa	Tela submucosa	Tela submucosa
Tunica mucosa	Tunica mucosa	Tunica mucosa
Lamina muscularis mucosae	Lamina muscularis mucosae	Lamina muscularis mucosae
Glandulae intestinales (Lieberkühni)	Glandulae intestinales .	Glandulae intestinales
Noduli lymphatici	Lymphonoduli	Folliculi lymphatici

BNA	JNA	PNA
Plicae transversales recti	Plicae transversae	Plicae transversales recti
Columnae rectales (Morgagnii)	Columnae rectales	Columnae anales
Sinus rectales	Sinus rectales	Sinus anales
.....	.....	Valvulae anales
Annulus haemorrhoidalis	Anulus haemorrhoidalis	Zona hemorrhoidalis*
PANCREAS	PANCREAS	PANCREAS
Caput pancreatis	Caput pancreatis	Caput pancreatis
Corpus pancreatis	Corpus pancreatis	Corpus pancreatis
Facies anterior	Facies ventralis	Facies anterior
Facies posterior	Facies dorsalis	Facies posterior
Facies inferior	.....	Facies inferior
Margo superior	.....	Margo superior
Margo anterior	.....	Margo anterior
Margo posterior	.....	Margo inferior
Cauda pancreatis	Cauda pancreatis	Cauda pancreatis
Processus uncinatus (Pancreas Winslowi)	Processus uncinatus	Processus uncinatus
Incisura pancreatis	Incisura pancreatis	Incisura pancreatis
Tuber omentale	Tuber omentale	Tuber omentale
Ductus pancreaticus (Wirsungi)	Ductus pancreaticus major	Ductus pancreaticus
Ductus pancreaticus accessorius (Santorini)	Ductus pancreaticus minor	Ductus pancreaticus accessorius
Pancreas accessorium	var. Pancreas accessorium	(Pancreas accessorium)
Succus pancreaticus	.....	.....
HEPAR	HEPAR	HEPAR
Lobus hepatis dexter ...	Lobus dexter	Lobus hepatis dexter
		Segmentum anterius**
		Segmentum posterius**
Lobus hepatis sinister ...	Lobus sinister	Lobus hepatis sinister
		Segmentum mediale**
		Pars quadrata**
		Segmentum laterale**
Incisura umbilicalis	Incisura hepatis	Incisura lig. teretis

BNA	JNA	PNA
		Facies diaphragmatica
		Pars superior
Facies superior	Facies diaphragmatica Pars affixa	Impressio cardiaca
	Facies diaphragmatica Pars libera	Pars anterior
		Pars dextra
		Pars posterior
.....	.....	Area nuda*
Facies posterior	.....	Pars posterior
Facies inferior	Facies visceralis	Facies visceralis
Margo anterior	Margo ventralis	Margo inferior
Fossae sagittales dextrae	.....	.....
Fossa vesicae felleae	Fossa vesicae felleae	Fossa vesicae felleae
Fossa venae cavae ..	Fossa venae cavae caudalis	Sulcus venae cavae
Fossa sagittalis sinistra	Fissura sagittalis (sin.) .	.....
Fossa venae umbilicalis	Pars chordae venae umbilicalis	Fissura lig. teretis (in fetu: Sulcus venae umbilicalis)
Fossa ductus venosi .	Pars chordae ductus venosi	Fissura lig. venosi (in fetu: Fossa ductus venosi)
Lig. teres hepatis	Chorda venae umbilicalis	Lig. teres hepatis
Lig. venosum (Arantii)	Chorda ductus venosi .	Lig. venosum
Porta hepatis	Porta hepatis	Porta hepatis
Lobus caudatus (Spigeli)	Lobus caudatus	Lobus caudatus
Processus papillaris ...	Processus papillaris ...	Processus papillaris
Processus caudatus	Processus caudatus	Processus caudatus
Lobus quadratus	Lobus quadratus	Lobus quadratus
Impressio cardiaca	Impressio cardiaca	Vide: Facies diaphragmatica
Impressio gastrica	Impressio gastrica	Impressio gastrica
Impressio oesophagea .	Impressio oesophagica .	Impressio esophagea*
Impressio duodenalis ..	Impressio duodenalis ..	Impressio duodenalis
Impressio colica	Impressio colica	Impressio colica
Impressio renalis	Impressio renalis	Impressio renalis
Impressio suprarenalis	Impressio suprarenalis	Impressio suprarenalis
Tuber omentale	Tuber omentale	Tuber omentale
(Appendix fibrosa hepatis)	Appendix fibrosa hepatis .	(Appendix fibrosa hepatis)
Tunica serosa	Tunica serosa	Tunica serosa

BNA	JNA	PNA
.....	.....	Tela subserosa*
Capsula fibrosa (Glissoni)	Capsula hepatis	Capsula fibrosa perivascularis
.....	.....	Tunica fibrosa
Lobuli hepatis	Lobuli hepatis	Lobuli hepatis
Rami arteriosi interlobulares	Rami arteriosi interlobulares	Arteriae interlobulares
Venae interlobulares	Vv. interlobulares	Venae interlobulares
Venae centrales	Venae centrales	Venae centrales
Ductus biliferi	Ductus biliferi	Ductuli biliferi
Ductus interlobulares	Ductus biliferi interlobulares	Ductus interlobulares
Ductus hepaticus	Ductus hepaticus	Ductus hepaticus communis Ductus hepaticus dext. Ramus anterior** Ramus posterior** Ductus hepaticus sin. Ramus lateralis** Ramus medialis** Ductus lobi caudati dexter** Ductus lobi caudati sinister**
Vasa aberrantia hepatis ..	Vasa aberrantia hepatis ..	.....
Fel (Bilis)	.....	.....
VESICA FELLEA	VESICA FELLEA	VESICA FELLEA
Fundus vesicae felleae ...	Fundus vesicae felleae ...	Fundus vesicae felleae
Corpus vesicae felleae ...	Corpus vesicae felleae ...	Corpus vesicae felleae
Collum vesicae felleae ..	Collum vesicae felleae ..	Collum vesicae felleae
Tunica serosa	Tunica serosa vesicae felleae	Tunica serosa vesicae felleae
.....	.....	Tela subserosa vesicae felleae*
Tunica muscularis	Tunica muscularis vesicae felleae	Tunica muscularis vesicae felleae
Tunica mucosa	Tunica mucosa vesicae felleae	Tunica mucosa vesicae felleae

BNA	JNA	PNA
Plicae tunicae mucosae vesicae felleae	Plicae reticulares tunicae mucosae	Plicae tunicae mucosae vesicae felleae
Valvula spiralis (Heisteri)	Valvula spiralis	Plica spiralis
Glandulae mucosae biliosae	Glandulae mucosae biliosae	Glandulae mucosae biliosae
Ductus cysticus	Ductus cysticus	Ductus cysticus
Ductus choledochus	Ductus choledochus	Ductus choledochus
		M. sphincter ductus choledochi*
		Ampulla hepatopancreatica
		M. sphincter ampullae hepatopancreaticae* (M. sphincter ampullae)
LIEN	LIEN	LIEN
Extremitas superior	Extremitas vertebralis ...	Extremitas posterior
Extremitas inferior	Extremitas ventralis	Extremitas anterior
Margo posterior	Margo obtusus	Margo inferior
Margo anterior	Margo acutus	Margo superior
Facies diaphragmatica ..	Facies diaphragmatica ..	Facies diaphragmatica
.....	Facies visceralis	Facies visceralis
Facies renalis	Pars renalis	Facies renalis
Facies gastrica	Pars gastrica	Facies gastrica
.....	.....	Facies colica
.....	Pars pancreatica (faciei visceralis lienis)	.....
Hilus lienis	Hilus lienis	Hilus lienis
Tunica serosa	Tunica serosa	Tunica serosa
.....	.....	Tunica fibrosa
Tunica albuginea	Capsula lienis	Tunica fibrosa
Trabeculae lienis	Trabeculae lienis	Trabeculae lienis
Pulpa lienis	Pulpa lienis	Pulpa lienis
.....	.....	Sinus lienis
Rami lienales	.....	Rami lienales (a. lienalis)
Penicilli	Penicilli	Penicillii

BNA	JNA	PNA
Noduli lymphatici lienales (Malpighii)	Lymphonoduli lienales ...	Folliculi lymphatici lienales
(Lien accessorius)	var. Lien accessorius ..	(Lien accessorius)
APPARATUS RESPIRATORIUS	SYSTEMA RESPIRATORIUM	APPARATUS RESPIRATORIUS (SYSTEMA RESPIRATORIUM)
NASUS	NASUS	NASUS
CAVUM NASI	CAVUM NASI	CAVUM NASI
Nares	Naris = Apertura nasi externa	Nares
Choanae	Choana	Choanae
Septum nasi	Septum nasi	Septum nasi
.....	Pars ossea (septi nasi) .	Pars ossea
Septum cartilagineum .	Pars cartilaginea (septi nasi)	Cartilago septi nasi**
Septum membranaceum	Pars cutanea (septi nasi)	Pars membranacea
Organon vomeronasale (Jacobsoni)	(Organon vomeronasale)	Organum vomeronasale
Vestibulum nasi	Vestibulum nasi	Vestibulum nasi
Limen nasi	Limen nasi	Limen nasi
Sulcus olfactorius	Sulcus olfactorius	Sulcus olfactorius
Concha nasalis suprema (Santorini)	Concha nasalis suprema .	.....
Concha nasalis superior .	Concha nasalis superior .	Concha nasalis superior
Concha nasalis media ...	Concha nasalis media ...	Concha nasalis media
Concha nasalis inferior .	Concha nasalis inferior .	Concha nasalis inferior
Plexus cavernosi concharum	Plexus cavernosi concharum	Plex. cavernosi concharum
Agger nasi	Agger nasi	Agger nasi
Recessus sphenoethmoidalis	Recessus sphenoethmoideus	Recessus sphenoethmoidalis*
Meatus nasi	.....	.....
Meatus nasi superior ..	Meatus nasi superior ..	Meatus nasi superior
Meatus nasi medius ...	Meatus nasi medius ...	Meatus nasi medius
Atrium meatus medii	Atrium meatus nasi medii	Atrium meatus medii

BNA	JNA	PNA
Meatus nasi inferior ..	Meatus nasi inferior ..	Meatus nasi inferior
Meatus nasi communis	Meatus nasi communis	.....
Meatus nasopharyngeus (Ductus incisivus)	Meatus nasopharyngicus (Ductus incisivus)	Meatus nasopharyngeus (Ductus incisivus)
Membrana mucosa nasi .	Tunica mucosa nasi	Tunica mucosa nasi*
Regio respiratoria	Regio respiratoria	Regio respiratoria
Regio olfactoria	Regio olfactoria	Regio olfactoria
.....	Pars olfactoria tunicae mucosae nasi	.....
Glandulae olfactoriae ..	Glandulae olfactoriae ..	Glandulae olfactoriae
Sinus paranasales	*Sinus nasales*	*Sinus paranasales*
Sinus maxillaris (Highmori)	Sinus maxillaris	Sinus maxillaris
Sinus sphenoidalis	Sinus sphenoideus	Sinus sphenoidalis
Sinus frontalis	Sinus frontalis	Sinus frontalis
Cellulae ethmoidales	Sinus ethmoidei	Sinus ethmoidalis
	Sinus ethmoidei anteriores	Cellulae anteriores
	.....	Cellulae mediae
	Sinus ethmoidei posteriores	Cellulae posteriores
Bulla ethmoidalis	Bulla ethmoidea	Bulla ethmoidalis
Infundibulum ethmoidale	Infundibulum ethmoideum	Infundibulum ethmoidale
Hiatus semilunaris	Hiatus semilunaris	Hiatus semilunaris
Glandulae nasales	Glandulae nasales	Glandulae nasales
NASUS EXTERNUS	NASUS EXTERNUS	NASUS EXTERNUS
Radix nasi	Radix nasi	Radix nasi
Dorsum nasi	Dorsum nasi	Dorsum nasi
Apex nasi	Apex nasi	Apex nasi
Ala nasi	Ala nasi	Alae nasi*
Basis nasi	.....	.....
Septum mobile nasi	Pars cutanea (septi nasi)	Pars mobilis septi nasi
Margo nasi	.....	.....
Cartilagines nasi	Cartilagines nasi	Cartilagines nasi
.....	Cartilago septodorsalis .	.....
Cartilago septi nasi ...	Lamina septi (cartilago septodorsalis)	Vide: Septum nasi**

BNA	JNA	PNA
Processus sphenoidalis septi cartilaginei ..	Processus sphenoideus (cartilaginis septo-dorsalis)	Processus posterior (sphenoidalis)
Cartilago nasi lateralis	Lamina dorsi nasi (cartilago septodorsalis) .	Cartilago nasi lateralis
Cartilago alaris major	Cartilago apicis nasi ...	Cartilago alaris major
Crus mediale	Crus mediale (cartilag. apicis nasi) ...	Crus mediale
Crus laterale	Crus laterale (cartilag. apicis nasi)	Crus laterale
Cartilagines alares minores	Processus alaris cruris lateralis (cartilaginis apicis nasi)	Cartilagines alares minores
Cartilagines sesamoideae nasi	Cartilagines nasales accessoriae	Cartilagines nasales accessoriae
Cartilago vomeronasalis (Jacobsoni)	Cartilago vomeronasalis	Cartilago vomeronasalis
LARYNX	LARYNX	LARYNX
Prominentia laryngea	Prominentia laryngica ...	Prominentia laryngea
CARTILAGINES LARYNGIS	CARTILAGINES LARYNGIS	CARTILAGINES LARYNGIS
Cartilago thyreoidea	*Cartilago thyreoides*	*Cartilago thyroidea**
Lamina (dextra et sinistra)	Lamina dextra et sinistra	Lamina (dext. et sin.)
Incisura thyreoidea sup.	Incisura thyreoidea cranialis	Incisura thyroidea superior*
Incisura thyreoidea inf.	Incisura thyreoidea caudalis	Incisura thyroidea inf.*
Tuberculum thyreoideum superius	Tuberculum thyreoideum craniale	Tuberculum thyroideum superius*

BNA	JNA	PNA
Tuberculum thyreoideum inferius	Tuberculum thyreoideum caudale	Tuberculum thyroideum inferius*
(Linea obliqua)	Linea obliqua	Linea obliqua
(Foramen thyreoideum)	(Foramen thyreoideum)	(Foramen thyroideum)*
Cornu superius	Cornu hyoideum	Cornu superius
Cornu inferius	Cornu cricoideum	Cornu inferius
Cartilago triticea	*Cartilago triticea*	*Cartilago triticea*
Cartilago cricoidea	*Cartilago cricoides*	*Cartilago cricoidea*
Arcus (cartilaginis cricoideae)	Arcus	Arcus cartilaginis cricoideae
Lamina (cartilaginis cricoideae)	Lamina	Lamina cartilaginis cricoideae
Facies articularis arytaenoidea	Facies articularis arytaenoidea	Facies articularis arytenoidea
Facies articularis thyreoidea	Facies articularis thyreoidea	Facies articularis thyroidea*
Cartilago arytaenoidea	*Cartilago arytaenoides*	*Cartilago arytenoidea**
.....	.....	Facies anterolateralis
.....	.....	Facies medialis
.....	.....	Facies posterior
Basis (cartilaginis arytaenoideae)	Basis	Basis cartilaginis arytenoideae*
Facies articularis (cartilaginis arytaenoideae)	Facies articularis	Facies articularis
Apex (cartilaginis arytaenoideae)	Apex	Apex cartilaginis arytenoideae

BNA	JNA	PNA
Fovea oblonga (cartilaginis arytaenoideae)	Fovea oblonga	Fovea oblonga
Fovea triangularis (cartilaginis arytaenoideae) ...	Fovea triangularis	Fovea triangularis
Crista arcuata (cartilaginis arytaenoideae)	Crista arcuata	Crista arcuata
Colliculus (cartilaginis arytaenoideae)	Colliculus	Colliculus
Processus vocalis (cartilaginis arytaenoideae) ...	Processus vocalis	Processus vocalis
Processus muscularis cartilaginis (arytaenoideae)	Processus muscularis	Processus muscularis
Cartilago corniculata (Santorini)	*Cartilago corniculata*	*Cartilago corniculata*
Epiglottis	*Epiglottis*	*Epiglottis*
Petiolus epiglottidis	Petiolus cartilaginis epiglottidis	Petiolus epiglottidis
Tuberculum epiglotticum .	Tuberculum epiglottidis ..	Tuberculum epiglotticum
Cartilago epiglottica	Cartilago epiglottidis	Cartilago epiglottica
Cartilago cuneiformis (Wrisbergi)	*Cartilago cuneiformis*	*Cartilago cuneiformis*
ARTICULATIONES ET LIGAMENTA LARYNGIS°		
Membrana hyothyreoidea	Membrana hyothyreoidea	Membrana thyrohyoidea*
Lig. hyothyreoideum medium	Lig. hyothyreoideum medium	Lig. thyrohyoideum medianum*
Lig. hyothyreoideum laterale	Lig. hyothyreoideum lat.	Lig. thyrohyoideum*
Articulatio cricothyreoidea	Articulus cricothyreoideus	Articulatio cricothyroidea*
Capsula articularis cricothyreoidea	.....	Capsula articularis cricothyroidea*
Lig. ceratocricoideum anterius	Ligg. articuli cricothyreoidei	.....
Ligg. ceratocricoidea posteriora		
Ligg. ceratocricoidea lateralia		

BNA	JNA	PNA
Lig. cricothyreoideum (medium)	Lig. cricothyreoideum = Pars libera coni elastici	Lig. cricothyroideum*
Lig. cricotracheale	.....	Lig. cricotracheale
Synchondrosis arycorniculata	.....	.....
Articulatio cricoarytaenoidea	Articulus crycoarytaenoideus	Articulatio cricoarytenoidea*
Capsula articularis cricoarytaenoidea	.....	Capsula articularis cricoarytenoidea*
Lig. cricoarytaenoideum posterius	Lig. cricoarytaenoideum dorsale	Lig. cricoarytenoideum posterius*
Lig. cricopharyngeum ...	Lig. cricopharyngicum ...	Lig. cricopharyngeum
Lig. corniculopharyngeum	Lig. corniculopharyngicum	.....
Lig. ventriculare	.....	Lig. vestibulare*
Lig. vocale	Lig. vocale	Lig. vocale
Lig. thyreoepiglotticum ..	Lig. thyreoepiglotticum ..	Lig. thyroepiglotticum*
Lig. hyoepiglotticum	.....	Lig. hyoepiglotticum*
Tuberculum cuneiforme (Wrisbergi)	Tuberculum cuneiforme ..	Tuberculum cuneiforme
Tuberculum corniculatum (Santorini)	Tuberculum corniculatum	Tuberculum corniculatum
(Cartilago sesamoidea) ...	(Cartilago sesamoidea) ...	(Cartilago sesamoidea)
MUSCULI LARYNGIS	MUSCULI LARYNGIS	MUSCULI LARYNGIS
Musculus cricothyreoideus	Musculus cricothyreoideus	Musculus cricothyroideus*
Pars recta	Pars recta	Pars recta
Pars obliqua	Pars obliqua	Pars obliqua
Musculus cricoarytaenoideus posterior	M. cricoarytaenoideus dorsalis	M. cricoarytenoideus posterior*
Musculus cricoarytaenoideus lateralis	M. cricoarytaenoideus lateralis	M. cricoarytenoideus lateralis*

BNA	JNA	PNA
.....	M. thyreoarytaenoideus ..	.....
M. thyreoarytaenoideus (externus)	Pars lateralis (m. thyreoarytaenoidei)	M. thyroarytenoideus*
M. vocalis	Pars vocalis (m. thyreoarytaenoidei = m. vocalis)	M. vocalis
M. ventricularis	.....	.....
M. thyreoepiglotticus	M. thyreoepiglotticus	M. thyroepiglotticus*
M. aryepiglotticus	M. aryepiglotticus	M. aryepiglotticus
.....	M. arytaenoideus	.....
M. arytaenoideus obliquus	Pars obliqua (m. arytaenoidei)	M. arytenoideus obliquus*
M. arytaenoideus transversus	Pars transversa (m. arytaenoidei)	M. arytenoideus transversus*
(M. ceratocricoideus) ...	(M. ceratocricoideus) ...	(M. ceratocricoideus)*

CAVUM LARYNGIS	CAVUM LARYNGIS	CAVUM LARYNGIS
Aditus laryngis	Aditus laryngis	Aditus laryngis
Plica aryepiglottica	Plica aryepiglottica	Plica aryepiglottica
Vestibulum laryngis	Vestibulum laryngis	Vestibulum laryngis
Rima vestibuli	Rima vestibuli	Rima vestibuli
Glottis	Glottis	Glottis
Rima glottidis	Rima glottidis	Rima glottidis
Pars intermembranacea	Pars intermembranacea	Pars intermembranacea
Pars intercartilaginea	Pars intercartilaginea	Pars intercartilaginea
Labium vocale	Labium vocale	.....
Plica ventricularis	Plica ventricularis	Plica vestibularis*
Plica vocalis	Plica vocalis	Plica vocalis
Macula flava	Macula flava	.....
Aditus glottidis superior	.....	.....
Aditus glottidis inferior	.....	.....
.....	.....	Cavum infraglotticum
Ventriculus laryngis (Morgagnii)	Ventriculus laryngis	Ventriculus laryngis

BNA	JNA	PNA
Appendix ventriculi laryngis	Appendix ventriculi laryngis	Sacculus laryngis
Membrana elastica laryngis	Membrana elastica laryngis	Membrana fibroelastica laryngis*
		Membrana quadrangularis
		Lig. vestibulare
Conus elasticus	Conus elasticus	Conus elasticus*
Tunica mucosa (laryngis)	Tunica mucosa laryngis .	Tunica mucosa
Glandulae laryngeae ...	Glandulae laryngicae ..	Glandulae laryngeae
Glandulae laryngeae anteriores	.....	.....
Glandulae laryngeae mediae	.....	.....
Glandulae laryngeae posteriores	.....	.....
Noduli lymphatici laryngei	Lymphonoduli laryngici	Folliculi lymphatici laryngei
Incisura interarytaenoidea	Incisura interarytaenoidea	Incisura interarytenoidea*
TRACHEA ET BRONCHI	TRACHEA ET BRONCHI	TRACHEA ET BRONCHI
Cartilagines tracheales ..	Cartilagines tracheales ..	Cartilagines tracheales
Ligg. annularia (trachealia)	.....	Ligg. anularia (trachealia)
Paries membranacea	Paries membranaceus	Paries membranaceus
.....	.....	Tunica mucosa
Glandulae tracheales	Glandulae tracheales	Glandulae tracheales
Bifurcatio tracheae	Bifurcatio tracheae	Bifurcatio tracheae
		Carina tracheae
.....	.....	M. trachealis
Bronchus (dexter et sinister)	Bronchus (dexter et sinister)	Bronchus principalis (dexter et sinister)
Rami bronchiales	Rami bronchales	Bronchi lobares et segmentales***
Ramus bronchialis eparterialis	.....	.....

BNA	JNA	PNA
Rami bronchiales hyparteriales	.....	.....
Tunica muscularis	Tunica muscularis	Tunica muscularis
Tela submucosa	.....	Tela submucosa
Tunica mucosa	Tunica mucosa	Tunica mucosa
Glandulae bronchiales	Glandulae bronchales	Glandulae bronchiales
PULMO	**PULMO**	**PULMO**
Basis pulmonis	Basis pulmonis	Basis pulmonis
Apex pulmonis	Apex pulmonis	Apex pulmonis
Facies costalis	Facies costalis	Facies costalis
Facies mediastinalis	Facies mediastinalis	Facies medialis
		Pars vertebralis
		Pars mediastinalis
Hilus pulmonis	Hilus pulmonis	Hilus pulmonis
Radix pulmonis	Radix pulmonis	Radix pulmonis
.....	Impressio cardiaca	Impressio cardiaca
.....	Impressio costae primae	.....
.....	Sulcus aorticus (pulmonis sinistri)	.....
.....	Sulcus v. cavae cranialis (pulmonis dextri) ...	.....
Facies diaphragmatica ..	Facies diaphragmatica ..	Facies diaphragmatica
.....	Facies contactus loborum	Facies interlobares
Margo anterior	Margo sternalis	Margo anterior
Margo inferior	Margo diaphragmaticus ..	Margo inferior
Sulcus subclavius	Sulcus arteriae subclaviae	.....
Incisura cardiaca	Incisura cardiaca	Incisura cardiaca pulmonis sinistri
.....	Fissura accessoria pulmonis dextri	Fissura horizontalis (pulmonis dext.)
.....	Lingula pulmonis sinistri	Lingula pulmonis sinistri
Lobus superior	Lobus ventrocranialis	Lobus superior
Lobus medius	Lobus medius	Lobus medius (pulmonis dext.) .....
Lobus inferior	Lobus dorsocaudalis	Lobus inferior
Incisura interlobaris	Fissura interlobaris	Fissura obliqua Fissura horizontalis (pulmonis dext.)

BNA	JNA	PNA
Lobuli pulmonum	Lobuli pulmonis	Segmenta bronchopulmonalia***
Rami bronchiales	Rr. bronchales	Vide: Trachea et bronchi**
Bronchioli	Bronchuli	Bronchioli
Bronchioli respiratorii .	Bronchuli respiratorii ..	Bronchioli respiratorii
Ductuli alveolares	Ductuli alveolares	Ductuli alveolares Sacculi alveolares
Alveoli pulmonum	Alveoli pulmonis	Alveoli pulmonis
CAVUM THORACIS ET PLEURA	**CAVUM THORACIS ET PLEURA**	**CAVUM THORACIS**
Cavum pleurae	Cavum pleurae (dextrum et sinistrum)	Cavum pleurae
Pleura	Pleura	Pleura
Pleura pulmonalis	Pleura pulmonalis	Pleura pulmonalis
Pleura parietalis	Pleura parietalis	Pleura parietalis
Pleura mediastinalis ...	Pars mediastinalis (pleurae)	Pleura mediastinalis
Laminae mediastinales	.....	.....
Pleura pericardiaca	Pars pericardiaca (pleurae)	.....
Pleura costalis	Pars costovertebralis (pleurae)	Pleura costalis
Pleura diaphragmatica .	Pars diaphragmatica (pleurae)	Pleura diaphragmatica
Cupula pleurae	Cupula	Cupula pleurae
Sulcus subclavius apicis pleurae	.....	.....
Sinus pleurae	Sinus pleurae	Recessus pleurales**
Sinus phrenicocostalis .	Sinus phrenicocostalis .	Recessus costodiaphragmaticus
Sinus costomediastinalis	Sinus costomediastinalis	Recessus costomediastinalis
.....	Sinus phrenicomediastinalis	.....
.....	Recessus praecardiacus	.....
Lig. pulmonale	Plica mediastinopulmonalis	Lig. pulmonale
.....	Mesopneumonium	.....
Plicae adiposae	Plicae adiposae	.....

BNA	JNA	PNA
Villi pleurales	Villi pleurales	.....
Septum mediastinale	Mediastinum	Mediastinum
Cavum mediastinale anterius	Pars ventralis (mediastini)	Mediastinum anterius*
Cavum mediastinale posterius	Pars dorsalis (mediastini)	Mediastinum posterius*
.....	.....	Mediastinum medium*
.....	Pars cranialis (mediastini)	Mediastinum superius*
Fascia endothoracica	Fascia endothoracica	Fascia endothoracica
		Membrana suprapleuralis
		Fascia phrenicopleuralis
APPARATUS UROGENITALIS	SYSTEMA UROGENITALE	APPARATUS UROGENITALIS (SYSTEMA UROGENITALE)
ORGANA UROPOETICA	*ORGANA URINALIA*	*ORGANA UROPOETICA*
REN	REN	REN
Facies anterior	Facies ventralis	Facies anterior
Facies posterior	Facies dorsalis	Facies posterior
Extremitas superior	Extremitas cranialis	Extremitas superior
Extremitas inferior	Extremitas caudalis	Extremitas inferior
Margo lateralis	Margo lateralis	Margo lateralis
Margo medialis	Margo medialis	Margo medialis
Hilus renalis	Hilus renalis	Hilus renalis
Sinus renalis	Sinus renalis	Sinus renalis
(Impressio muscularis) ...	.....	.....
(Impressio hepatica)	.....	.....
(Impressio gastrica)	.....	.....
Capsula adiposa	Capsula adiposa	Capsula adiposa
Tunica fibrosa renis ...	Tunica fibrosa	Capsula fibrosa
.....	.....	Segmenta renalia**
		Segm. superius**
		Segm. anterius superius**
		Segm. anterius inferius**
		Segm. inferius**
		Segm. posterius**

BNA	JNA	PNA
Lobi renales	Lobi renales (Renculi)	Lobi renales
Substantia corticalis	Substantia corticalis	Cortex renis
Glomeruli		Glomeruli
Capsula glomeruli		Capsula glomeruli
Corpuscula renis (Malpighii)	Corpuscula renis	Corpuscula renis
Lobuli corticales		Lobuli corticales
Pars radiata (Processus Ferreini)	Striae medullares corticis (renis)	Pars radiata
Pars convoluta		Pars convoluta
Columnae renales (Bertini)	Columnae renales	Columnae renales
Tubuli renales	Tubuli renales	Tubuli renales
Tubuli renales contorti	Tubuli renales contorti	Tubuli renales contorti
Tubuli renales recti	Tubuli renales recti	Tubuli renales recti
Substantia medullaris	Substantia medullaris	Medulla renis
Pyramides renales (Malpighii)	Pyramides renales	Pyramides renales
Basis pyramidis	Basis pyramidis	Basis pyramidis
Papillae renales	Papillae renales	Papillae renales
Area cribrosa	Area cribriformis	Area cribrosa
Foramina papillaria	Foramina papillarum	Foramina papillaria
Pelvis renalis	Pelvis renalis	Pelvis renalis
Calyces renales	Calices renales	Calices renales**
Calyces renales majores		Calices renales majores*
Calyces renales minores		Calices renales minores*
Glandula pelvis renalis		*
Arteriae renis	*Arteriae renis*	*Arteriae renis*
Aa. interlobares renis	Aa. interlobares renis	Aa. interlobares renis
Aa. arciformes		Aa. arcuatae
Aa. interlobulares	Aa. corticales radiatae	Aa. interlobulares
Vas afferens	Arteriola afferens	Vas afferens
Vas efferens	Arteriola efferens	Vas efferens
Rami capsulares	Rami capsulares	Rami capsulares
Arteriolae rectae	Arteriolae rectae medullares	Arteriolae rectae

BNA	JNA	PNA
Aa. nutriciae pelvis renalis	.....	.....
Venae renis	*Venae renis*	*Venae renis*
Vv. interlobares	Vv. interlobares	Vv. interlobares
Vv. arciformes	Vv. arciformes	Vv. arcuatae
Vv. interlobulares	Vv. corticales radiatae .	Vv. interlobulares
Venulae rectae	Venulae rectae medullares	Venulae rectae
Vv. stellatae	Vv. stellatae	Venulae stellatae
URETER	URETER	URETER
Pars abdominalis	Pars abdominalis	Pars abdominalis
Pars pelvina	Pars pelvina	Pars pelvina
Tunica adventitia	.....	Tunica adventitia
Tunica muscularis	Tunica muscularis	Tunica muscularis
Stratum externum	Stratum externum	.....
Stratum medium	Stratum medium	.....
Stratum internum	Stratum internum	.....
Tunica mucosa	Tunica mucosa	Tunica mucosa
Glandulae mucosae ureteris	.....	.....
VESICA URINARIA	VESICA URINARIA	VESICA URINARIA
Fundus vesicae	Fundus vesicae	Fundus vesicae
Vertex vesicae	Vertex vesicae	Apex vesicae
Corpus vesicae	Corpus vesicae	Corpus vesicae
.....	.....	Cervix vesicae
Lig. umbilicale medium .	Chorda urachi	Lig. umbilicale medianum
Urachus	*Urachus*	*Urachus*
Tunica serosa	Tunica serosa	Tunica serosa
.....	.....	Tela subserosa*
Tunica muscularis	Tunica muscularis	Tunica muscularis
Stratum externum	.....	.....
Stratum medium	.....	.....
Stratum internum	.....	.....
.....	M. sphincter vesicae ..	.....
M. pubovesicalis	.....	M. pubovesicalis
M. rectovesicalis	.....	M. rectovesicalis

BNA	JNA	PNA
.....	.....	M. rectourethralis*
Tela submucosa	.....	Tela submucosa
Tunica mucosa	Tunica mucosa	Tunica mucosa
Glandulae vesicales ...	Gll. trigonales	.....
Noduli lymphatici vesicales	Lymphonoduli vesicae	.....
Trigonum vesicae (Lieutaudi)	Trigonum vesicae	Trigonum vesicae
Orificium ureteris ...	Orificium ureteris ...	Ostium ureteris
Uvula vesicae	Uvula vesicae	Uvula vesicae
Plica ureterica	Plica ureterica	Plica interureterica
Orificium urethrae internum	Orificium urethrae internum	Ostium urethrae internum
Annulus urethralis ..	Anulus urethralis	.....

ORGANA GENITALIA	*ORGANA GENITALIA*	*ORGANA GENITALIA*
ORGANA GENITALIA VIRILIA	ORGANA GENITALIA MASCULINA	ORGANA GENITALIA MASCULINA
PARTES GENITALES INTERNAE°	*PARTES GENITALES INTERNAE°*	*PARTES GENITALES MASCULINAE INTERNAE°*
TESTIS	TESTIS	TESTIS
Extremitas superior	Extremitas capitalis	Extremitas superior
Extremitas inferior	Extremitas caudalis	Extremitas inferior
Facies lateralis	Facies lateralis	Facies lateralis
Facies medialis	Facies medialis	Facies medialis
Margo anterior	Margo liber	Margo anterior
Margo posterior	Margo mesorchicus	Margo posterior
Tunica albuginea	Tunica albuginea	Tunica albuginea
Septula testis	Septula testis	Septula testis
Lobuli testis	Lobuli testis	Lobuli testis
Tubuli seminiferi contorti	Tubuli contorti	Tubuli seminiferi contorti
Tubuli seminiferi recti .	.....	Tubuli seminiferi recti
Tunica propria	.....	.....
Rete testis (Halleri) ...	Rete testis	Rete testis

BNA	JNA	PNA
Mediastinum testis (Corpus Highmori)	Mediastinum testis	Mediastinum testis
Ductuli efferentes testis	Ductuli efferentes	Ductuli efferentes testis
.....	Coni vasculosi	.....
Parenchyma testis	.....	Parenchyma testis
Sperma (semen)	.....	.....
EPIDIDYMIS	EPIDIDYMIS	EPIDIDYMIS
Caput epididymidis	Caput epididymidis	Caput epididymidis
Corpus epididymidis	Corpus epididymidis	Corpus epididymidis
Cauda epididymidis	Cauda epididymidis	Cauda epididymidis
Lobuli epididymidis	Lobuli epididymidis	Lobuli epididymidis (Coni epididymidis)
Ductus epididymidis	Ductus epididymidis	Ductus epididymidis
Ductuli aberrantes	Ductuli aberrantes	Ductuli aberrantes
(Ductulus aberrans superior)	.....	(Ductulus aberrans superior)
Appendices testis	.....	.....
Appendix testis (Morgagnii)	Appendix testis	Appendix testis
(Appendix epididymidis)	Appendix epididymidis	(Appendix epididymidis)
Paradidymis	Paradidymis	Paradidymis
DUCTUS DEFERENS	DUCTUS DEFERENS	DUCTUS DEFERENS
Tunica adventitia	.....	Tunica adventitia
Tunica muscularis	Tunica muscularis	Tunica muscularis
Stratum externum	Stratum externum	.....
Stratum medium	Stratum medium	.....
Stratum internum	Stratum internum	.....
Tunica mucosa	Tunica mucosa	Tunica mucosa
.....	Pars epididymica (ductus deferentis)	.....
.....	Pars funicularis (ductus deferentis)	.....
.....	Pars inguinalis (ductus deferentis)	.....
.....	Pars libera (ductus deferentis)	.....
.....	Pars pelvina (ductus deferentis)	.....

BNA	JNA	PNA
Ampulla ductus deferentis	Ampulla ductus deferentis	Ampulla ductus deferentis
Diverticula ampullae ..	Diverticula ampullae ..	Diverticula ampullae
Ductus ejaculatorius	Ductus ejaculatorius	Ductus ejaculatorius
VESICULA SEMINALIS	GLANDULA VESICULOSA	VESICULA SEMINALIS
Corpus vesiculae seminalis	.....	.....
Tunica adventitia	.....	Tunica adventitia
Tunica muscularis	Tunica muscularis	Tunica muscularis
Tunica mucosa	Tunica mucosa	Tunica mucosa
Ductus excretorius	Ductus excretorius	Ductus excretorius
FUNICULUS SPERMATICUS ET TUNICAE TESTIS ET FUNICULI SPERMATICI	FUNICULUS SPERMATICUS TUNICAE TESTIS ET FUNICULI SPERMATICI	FUNICULUS SPERMATICUS
Tunica testis	.....	Tunicae funiculi spermatici et testis
(Rudimentum processus vaginalis)	(Rudimentum processus vaginalis)	(Vestigium processus vaginalis)
Tunica vaginalis communis (testis et funiculi spermatici)	Tunica vaginalis testis et funiculi spermatici	Fascia spermatica ext. Fascia spermatica int.
Tunica vaginalis propria testis	Periorchium + Epiorchium	Tunica vaginalis testis
Lamina parietalis	Periorchium	Lamina parietalis
Lamina visceralis	Epiorchium	Lamina visceralis
.....	M. intervaginalis testis ..	.....
M. cremaster	M. cremaster	M. cremaster
Fascia cremasterica (Cooperi)	Fascia cremasterica	Fascia cremasterica
Lig. epididymidis superius	Plica capitis epididymidis	Lig. epididymidis sup.
Lig. epididymidis inferius	Plica caudae epididymidis	Lig. epididymidis inf.
Sinus epididymidis	Bursa testicularis	Sinus epididymidis
Descensus testis	.....	*Descensus testis*
Gubernaculum testis (Hunteri)	*Gubernaculum testis*	*Gubernaculum testis*
.....	.....	*Lig. genitoinguinale**

BNA	JNA	PNA
PROSTATA	PROSTATA	PROSTATA
Basis prostatae	Facies vesicalis	Basis prostatae
Apex prostatae		Apex prostatae
Facies anterior	Facies pubica	Facies anterior
Facies posterior	Facies rectalis	Facies posterior
		Facies inferolateralis
	Pars praeurethralis (prostatae)	
Lobus (dexter et sinister)	Partes laterales	Lobus (dexter et sinister)
Isthmus prostatae	Isthmus prostatae	Isthmus prostatae
(Lobus medius)		(Lobus medius)
Corpus glandulare		Substantia glandularis
Ductus prostatici	Ductuli prostatici	Ductuli prostatici
Succus prostaticus		
M. prostaticus	M. prostaticus	Substantia muscularis
	M. puboprostaticus	M. puboprostaticus
GLANDULA BULBOURETHRALIS (COWPERI)	GLANDULA BULBOURETHRALIS	GLANDULA BULBOURETHRALIS
Corpus glandulae bulbourethralis	Corpus glandulae bulbourethralis	
Ductus excretorius	Ductus excretorius	Ductus gl. bulbourethralis*
PARTES GENITALES EXTERNAE	*PARTES GENITALES EXTERNAE*	*PARTES GENITALES MASCULINAE EXTERNAE*
PENIS	PENIS	PENIS
Radix penis	Radix penis	Radix penis
Corpus penis	Corpus penis	Corpus penis
Crus penis	Crura corporis cavernosi penis	Crus penis
Dorsum penis	Dorsum penis	Dorsum penis
Facies urethralis penis	Facies urethralis	Facies urethralis
Glans penis	Glans penis	Glans penis
Corona glandis	Corona glandis	Corona glandis
Septum glandis	(Septum glandis)	Septum glandis
Collum glandis	Collum glandis	Collum glandis
Praeputium	Praeputium	Preputium

BNA	JNA	PNA
Frenulum praeputii ...	Frenulum praeputii ...	Frenulum preputii
Glandulae praeputiales	.....	Glandulae preputiales
Smegma praeputii	.....	.....
Raphe penis	Rhaphe penis	Raphe penis
Corpus cavernosum penis	Corpus cavernosum penis	Corpus cavernosum penis
Septum penis	Septum pectiniforme corporis cavernosi penis .	Septum penis
Trabeculae corporum cavernosorum	Trabeculae corporis cavernosi	Trabeculae corporum cavernosorum
Cavernae corporum cavernosorum	Cavernae corporis cavernosi	Cavernae corporum cavernosorum
.....	.....	Tunica albuginea corporis spongiosi
Corpus cavernosum urethrae	Corpus cavernosum urethrae	Corpus spongiosum penis
.....	.....	Cavernae corporis spongiosi
.....	.....	Trabeculae corporis spongiosi
Bulbus urethrae	Bulbus corporis cavernosi urethrae	Bulbus penis
Hemisphaeria bulbi urethrae	.....	.....
Septum bulbi urethrae .	(Septum bulbi urethrae)	.....
Aa. helicinae	Aa. helicinae	Aa. helicinae
Vv. cavernosae	.....	Vv. cavernosae
Tunica albuginea corporum cavernosorum	Tunica albuginea corporis cavernosi penis	Tunica albuginea corporum cavernosorum
Fascia penis	Fascia penis	Fascia penis profunda Fascia penis superficialis
Lig. suspensorium penis .	Lig. suspensorium penis .	.....
URETHRA VIRILIS	URETHRA MASCULINA	URETHRA MASCULINA
.....	Pars intramuscularis	.....
Pars prostatica	Pars prostatica	Pars prostatica

BNA	JNA	PNA
.....	Portio externa (partis prostaticae urethrae) .	.....
.....	Portio interna (partis prostaticae urethrae) .	.....
Colliculus seminalis ...	Colliculus seminalis ...	Colliculus seminalis
Crista urethralis	Crista urethralis	Crista urethralis
Utriculus prostaticus ..	Utriculus prostaticus ..	Utriculus prostaticus Sinus prostaticus
Pars membranacea	Pars diaphragmatica	Pars membranacea
Pars cavernosa	Pars cavernosa	Pars spongiosa
.....	Portio intermedia (partis cavernosae urethrae)	.....
Fossa navicularis urethrae (Morgagnii) ..	Fossa navicularis urethrae	Fossa navicularis urethrae
(Valvula fossae navicularis)	Plica fossae navicularis	(Valvula fossae navicularis)
Orificium urethrae externum	Orificium urethrae ext.	Ostium urethrae ext.
.....	Ampulla urethrae	.....
Lacunae urethrales (Morgagnii)	Lacunae urethrales ...	Lacunae urethrales
Glandulae urethrales (Littrei)	Gll. paraurethrales	Glandulae urethrales
SCROTUM	SCROTUM	SCROTUM
Raphe scroti	Rhaphe scroti	Raphe scroti
Septum scroti	Septum scroti	Septum scroti
Tunica dartos	Tunica dartos	Tunica dartos
ORGANA GENITALIA MULIEBRIA	ORGANA GENITALIA FEMININA	ORGANA GENITALIA FEMININA
PARTES GENITALES INTERNAE°	*PARTES GENITALES INTERNAE°*	*PARTES GENITALES FEMININAE INTERNAE°*
OVARIUM	OVARIUM	OVARIUM
Facies medialis	Facies medialis	Facies medialis
Facies lateralis	Facies lateralis	Facies lateralis
Extremitas tubaria	Extremitas tubalis	Extremitas tubaria

BNA	JNA	PNA
Extremitas uterina	Extremitas uterina	Extremitas uterina
Margo liber	Margo liber	Margo liber
Margo mesovaricus	Margo mesovaricus	Margo mesovaricus
Hilus ovarii	Hilus ovarii	Hilus ovarii
Stroma ovarii	.....	Stroma ovarii
.....	Folliculi ovarii	.....
Folliculi oophori primarii	Folliculi ovarii primarii	Folliculi ovarici primarii
.....	Folliculi ovarii secundarii	.....
Folliculi oophori vesiculosi (Graafi)	Folliculi ovarii vesiculosi	Folliculi ovarici vesiculosi
Theca folliculi	Theca folliculi	Theca folliculi
Tunica externa	Stratum externum ...	Tunica externa
Tunica interna	Stratum internum ..	Tunica interna
Liquor folliculi	Liquor folliculi	.....
Stratum granulosum ...	Granulosa folliculi	Stratum granulosum
Cumulus oophorus	Cumulus oviger	Cumulus oophorus
Ovulum	Ovulum	Ovum
Corpus luteum	Corpus luteum (menstruationis, graviditatis) .	Corpus luteum
.....	Corpus atreticum	.....
Corpus albicans	Corpus albicans	Corpus albicans
Lig. ovarii proprium	Chorda uteroovarica	Lig. ovarii proprium
TUBA UTERINA (FALLOPPII)	TUBA UTERINA	TUBA UTERINA
Infundibulum tubae uterinae	Infundibulum	Infundibulum tubae uterinae
Ostium abdominale tubae uterinae	Ostium abdominale ...	Ostium abdominale tubae uterinae
Fimbriae tubae	Fimbriae	Fimbriae tubae
Fimbria ovarica	Fimbria ovarica	Fimbria ovarica
Ampulla tubae uterinae	Ampulla	Ampulla tubae uterinae
Pars uterina	Pars interstitialis	Pars uterina
Ostium uterinum tubae	Ostium uterinum tubae	Ostium uterinum tubae
Isthmus tubae uterinae	Isthmus	Isthmus tubae uterinae
.....	Appendix vesiculosa .	.....
Tunica serosa	Tunica serosa	Tunica serosa
Tunica adventitia	.....	Tela subserosa

BNA	JNA	PNA
Tunica muscularis	Tunica muscularis	Tunica muscularis
Stratum longitudinale .	.....	.....
Stratum circulare	.....	.....
Tela submucosa	.....	.....
Tunica mucosa	Tunica mucosa	Tunica mucosa
Plicae tubariae	Plicae tubae	Plicae tubariae
Plicae ampullares ...	Plicae ampullares ...	.....
Plicae isthmicae	Plicae isthmicae	.....
UTERUS	UTERUS	UTERUS
Corpus uteri	Corpus uteri	Corpus uteri
Fundus uteri	Fundus	Fundus uteri
Margo lateralis	Margo lateralis	Margo uteri (dexter et sinister)
Facies vesicalis uteri ..	Facies vesicalis	Facies vesicalis
Facies intestinalis uteri	Facies rectalis	Facies intestinalis
Cavum uteri	Cavum corporis uteri .	Cavum uteri
Orificium internum uteri	Orificium internum canalis isthmi	.....
.....	Isthmus uteri	Isthmus uteri
.....	Canalis isthmi	.....
Cervix uteri	Cervix uteri	Cervix uteri
Portio supravaginalis (cervicis)	Portio supravaginalis ..	Portio supravaginalis (cervicis)
Portio vaginalis (cervicis)	Portio vaginalis	Portio vaginalis (cervicis)
Tunica muscularis cervicis (uteri)	.....	.....
.....	Orificium externum canalis isthmi = Orificium internum canalis cervicis	.....
Orificium ext. uteri ...	Orificium externum uteri = Orificium externum canalis cervicis .	Ostium uteri
Labium anterius	Labium ventrale	Labium anterius
Labium posterius ...	Labium dorsale	Labium posterius
Canalis cervicis uteri ..	Canalis cervicis	Canalis cervicis uteri
Plicae palmatae	Plicae palmatae	Plicae palmatae

BNA	JNA	PNA
Glandulae cervicales (uteri)	Glandulae cervicales .	Glandulae cervicales (uteri)
Parametrium	Parametrium	Parametrium
Tunica serosa (Perimetrium)	Perimetrium	Tunica serosa (Perimetrium)
.....	.....	Tela subserosa*
Tunica muscularis	Myometrium	Tunica muscularis (Myometrium)
Tunica muscularis cervicis	.....	.....
Tunica mucosa	Endometrium	Tunica mucosa (Endometrium)
Glandulae uterinae	.....	Glandulae uterinae
M. rectouterinus	M. rectouterinus	M. rectouterinus
Lig. teres uteri	Chorda uteroinguinalis (teres)	Lig. teres uteri
VAGINA	VAGINA	VAGINA
Fornix vaginae	Fornix vaginae	Fornix vaginae
Paries anterior	Paries ventralis	Paries anterior
Paries posterior	Paries dorsalis	Paries posterior
Hymen	Hymen	Hymen
Carunculae hymenales	Carunculae hymenales	Carunculae hymenales
Tunica muscularis	Tunica muscularis	Tunica muscularis
Tunica mucosa	Tunica mucosa	Tunica mucosa
Noduli lymphatici vaginales	Lymphonoduli vaginales	.....
Rugae vaginales	Rugae vaginales	Rugae vaginales
Columnae rugarum ...	.....	Columnae rugarum
Columna rugarum posterior	Columna rugarum dorsalis	Columna rugarum posterior
Columna rugarum anterior	Columna rugarum ventralis	Columna rugarum anterior
Carina urethralis vaginae	Carina urethralis vaginae	Carina urethralis vaginae

BNA	JNA	PNA
Epoophoron	*Epoophoron*	*Epoophoron*
Ductus epoophori longitudinalis (Gartneri)	Ductus epoophori longitudinalis	Ductus epoophori longitudinalis
Ductuli transversi	Ductuli transversi	Ductuli transversi
Appendices vesiculosi (Morgagnii)	Appendix vesiculosa	Appendices vesiculosae
Paroophoron	*Paroophoron*	*Paroophoron*
PARTES GENITALES EXTERNAE	*PARTES GENITALES EXTERNAE*	*PARTES GENITALES FEMININAE EXTERNAE*
PUDENDUM MULIEBRE	PUDENDUM FEMININUM	PUDENDUM FEMININUM
Mons pubis	Mons pubis	Mons pubis
Labium majus pudendi	Labium majus pudendi .	Labium majus pudendi
Commissura labiorum anterior	Commissura labiorum ventralis	Commissura labiorum anterior
Commissura labiorum posterior	Commissura labiorum dorsalis	Commissura labiorum posterior
Frenulum labiorum pudendi	Frenulum labiorum pudendi	Frenulum labiorum pudendi
Rima pudendi	Rima pudendi	Rima pudendi
Labium minus pudendi ..	Labium minus pudendi ..	Labium minus pudendi
Vestibulum vaginae	Vestibulum vaginae	Vestibulum vaginae
Fossa navicularis (vestibuli vaginae)	Fossa navicularis	Fossa vestibuli vaginae
Bulbus vestibuli	Bulbus vestibuli	Bulbus vestibuli
Glandulae sebaceae	.....	.....
Glandulae vestibulares minores	Glandulae vestibulares minores	Gll. vestibulares minores
Orificium vaginae	Ostium vaginae	Ostium vaginae

BNA	JNA	PNA
GLANDULA VESTIBULARIS MAJOR (BARTHOLINI)	GLANDULA VESTIBULARIS MAJOR	GLANDULA VESTIBULARIS MAJOR
CLITORIS	CLITORIS	CLITORIS
Crus clitoridis	Crura clitoridis	Crus clitoridis
Corpus clitoridis	Corpus clitoridis	Corpus clitoridis
Corpus cavernosum clitoridis	Corpus cavernosum clitoridis	Corpus cavernosum clitoridis (dext. et sin.)
Septum corporum cavernosorum	Septum pectiniforme ..	Septum corporum cavernosorum
Glans clitoridis	Glans clitoridis	Glans clitoridis
Frenulum clitoridis	Frenulum clitoridis	Frenulum clitoridis
Praeputium clitoridis ..	Praeputium clitoridis ..	Preputium clitoridis
Smegma clitoridis ..	.....	.....
Fascia clitoridis	Fascia clitoridis	Fascia clitoridis
Lig. suspensorium clitoridis	Lig. suspensorium clitoridis	.....
URETHRA MULIEBRIS	URETHRA FEMININA	URETHRA FEMININA
.....	Pars intramuscularis	.....
.....	Pars cavernosa	.....
Orificium urethrae ext. ..	Orificium urethrae ext. ..	Ostium urethrae ext.
Corpus spongiosum urethrae	Corpus spongiosum urethrae	.....
Crista urethralis	Crista urethralis	Crista urethralis
(Ductus paraurethrales) ..	(Ductus paraurethrales) ..	(Ductus paraurethrales)
Tunica muscularis	Tunica muscularis	Tunica muscularis
Stratum circulare	.....	.....
Stratum longitudinale .	.....	.....
Tunica submucosa	.....	.....
Tunica mucosa	Tunica mucosa	Tunica mucosa
Glandulae urethrales ..	Gll. paraurethrales	Glandulae urethrales
.....	.....	Lacunae urethrales
Termini ontogenetici°		*Termini ontogenetici*
Funiculus umbilicalis ...	Funiculus umbilicalis ...	Funiculus umbilicalis
Corpus Wolffi	.....	Mesonephros

BNA	JNA	PNA
Ductus Wolffi		Ductus mesonephricus
Ductus Mülleri		Ductus paramesonephricus
Sinus urogenitalis		Sinus urogenitalis
Membranae deciduae	Membrana decidua	Membranae deciduae
Decidua vera	Decidua parietalis	Decidua parietalis
Decidua capsularis	Decidua capsularis	Decidua capsularis
Decidua basalis	Decidua basalis	Decidua basalis
Placenta	Placenta	Placenta
Placenta uterina	Placenta materna	Pars uterina
Placenta foetalis	Placenta foetalis	Pars fetalis*
	Amnion	
	Chorion	
PERINEUM	PERINEUM	PERINEUM
Raphe perinei	Rhaphe perinei	Raphe
Mm. perinei	Mm. perinei	Mm. perinei
		Centrum tendineum perinei*
Diaphragma pelvis	*Diaphragma pelvis*	*Diaphragma pelvis*
M. levator ani	M. levator ani	M. levator ani
		M. pubococcygeus
		M. levator prostatae (M. pubovaginalis)
		M. puborectalis
		M. iliococcygeus
Arcus tendineus m. levatoris ani	Arcus tendineus fasciae obturatoriae	(Arcus tendineus m. levatoris ani)
M. coccygeus	M. coccygicus	M. coccygeus
M. sphincter ani ext.	M. sphincter ani ext.	M. sphincter ani ext.
		Pars subcutanea
		Pars superficialis
		Pars profunda
Lig. anococcygeum	Septum anococcygicum	Lig. anococcygeum
Fascia pelvis	Fascia pelvis	Fascia pelvis
		Fascia pelvis parietalis
Fascia obturatoria	Fascia m. obturatoris int.	Fascia obturatoria

BNA	JNA	PNA
.....	.....	Fascia pelvis visceralis
Fascia prostatae	Capsula prostatae	Fascia prostatae
.....	.....	Septum rectovesicale
.....	.....	Septum rectovaginale
Fascia endopelvina ..	Fascia intrapelvina .	.....
Fascia diaphragmatis pelvis superior	Fascia diaphragmatis pelvis interna	Fascia diaphragmatis pelvis superior
Arcus tendineus fasciae pelvis	Arcus tendineus fasciae pelvis	Arcus tendineus fasciae pelvis
Lig. puboprostaticum (pubovesicale) medium	Ligg. pubovesicalia	Lig. puboprostaticum (pubovesicale)
Lig. puboprostaticum (pubovesicale) laterale	Ligg. puboprostatica ...	
Fascia diaphragmatis pelvis inferior	Fascia diaphragmatis pelvis externa	Fascia diaphragmatis pelvis inferior
Diaphragma urogenitale	*Diaphragma urogenitale*	*Diaphragma urogenitale*
.....	.....	Spatium perinei prof.
M. transversus perinei profundus	M. transversus perinei profundus	M. transversus perinei prof.
M. sphincter urethrae membranaceae	M. sphincter urethrae diaphragmaticae	M. sphincter urethrae
Fascia diaphragmatis urogenitalis superior	Fascia diaphragmatis urogenitalis interna	Fascia diaphragmatis urogenitalis superior
Fascia diaphragmatis urogenitalis inferior	Fascia diaphragmatis urogenitalis externa	Fascia diaphragmatis urogenitalis inferior (Membrana perinei)
Lig. transversum pelvis .	Lig. praeurethrale	Lig. transversum perinei

BNA	JNA	PNA
.....	.....	Spatium perinei superficiale
M. transversus perinei superficialis	M. transversus perinei superficialis	M. transversus perinei superficialis
M. ischiocavernosus	M. ischiocavernosus	M. ischiocavernosus
M. bulbocavernosus	M. bulbocavernosus	M. bulbospongiosus
Fascia superficialis perinei	.....	Fascia perinei superfic.**
Fossa ischiorectalis	Fossa ischiorectalis	Fossa ischiorectalis
		Corpus adiposum fossae ischiorectalis
		Canalis pudendalis
.....	*CAVUM ABDOMINIS*	.....
PERITONAEUM	*PERITONAEUM = TUNICA SEROSA*	*PERITONEUM*
Peritonaeum parietale ...	Peritonaeum parietale ...	Peritoneum parietale
		Tunica serosa*
		Tela subserosa*
Peritonaeum viscerale ...	Peritonaeum viscerale ...	Peritoneum viscerale
		Tunica serosa
		Tela subserosa*
Cavum peritonaei	Cavum peritonaei	Cavum peritonei
Tunica serosa	.....	Tunica serosa
Tela subserosa	Tela subserosa	Tela subserosa
.....	.....	Fascia subperitonealis
.....	Mesenteria	.....
Mesenterium	Mesostenium	Mesenterium
Intestinum tenue mesenteriale	Intestinum tenue mesosteniale	.....
Radix mesenterii	Radix mesostenii	Radix mesenterii
Lamina mesenterii propria	.....	.....
Mesocolon	.....	Mesocolon
Mesocolon ascendens ..	var. Mesocolon ascendens	(Mesocolon ascendens)
Mesocolon transversum	Mesocolon (transversum)	Mesocolon transversum
.....	Radix mesocoli transversi	.....

BNA	JNA	PNA
Mesocolon descendens .	var. Mesocolon descendens	(Mesocolon descendens)
Mesocolon sigmoideum	Mesosigmoideum	Mesocolon sigmoideum
Mesorectum	.....	.....
Mesenteriolum processus vermiformis	Mesenteriolum processus vermiformis	Mesoappendix*
Omentum minus	*Omentum minus*	*Omentum minus*
.....	Portio densa (omenti minoris)	.....
.....	Portio flaccida (omenti minoris)	.....
Lig. hepatogastricum ..	Pars hepatogastrica ...	Lig. hepatogastricum
Lig. hepatoduodenale ..	Pars hepatoduodenalis .	Lig. hepatoduodenale
.....	Pars phrenicogastrica (omenti minoris) ...	.....
(Lig. hepatocolicum) ..	.....	(Lig. hepatocolicum)
.....	Pars phrenicogastrica (mesogastrii dorsalis)	.....
Lig. gastrolienale	Pars gastrolienalis	Lig. gastrolienale
Lig. gastrocolicum	Pars gastromesocolica ...	Lig. gastrocolicum
.....	var. Omentum lienale ...	.....
Omentum majus	*Omentum majus*	*Omentum majus*
.....	.....	Lig. gastrophrenicum
Bursa omentalis	*Bursa omentalis*	*Bursa omentalis*
Foramen epiploicum (Winslowi)	Foramen epiploicum ..	Foramen epiploicum
Vestibulum bursae omentalis	Vestibulum bursae omentalis	Vestibulum bursae omentalis
Plica gastropancreatica ..	Plica gastropancreatica ..	Plicae gastropancreaticae
Recessus superior omentalis	Recessus cranialis (bursae omentalis)	Recessus superior omentalis

BNA	JNA	PNA
Recessus inferior omentalis	Recessus caudalis (bursae omentalis)	Recessus inferior omentalis
Recessus lienalis	.....	Recessus lienalis
.....	Plica a. hepaticae communis	.....
Lig. phrenicocolicum	Plica phrenicocolica	Lig. phrenicocolicum
Lig. phrenicolienale	Plicae phrenicolienales ...	Lig. phrenicolienale (lig. lienorenale)
Lig. falciforme hepatis ..	Mesohepaticum ventrale .	Lig. falciforme hepatis
Lig. coronarium hepatis .	.....	Lig. coronarium hepatis
Lig. triangulare dextrum	Mesohepaticum laterale dextrum	Lig. triangulare dextrum
Lig. triangulare sinistrum	Mesohepaticum laterale sinistrum	Lig. triangulare sinistrum
Lig. hepatorenale	.....	Lig. hepatorenale
(Lig. duodenorenale)	.....	.....
.....	.....	(Recessus retroduodenalis)
.....	.....	Recessus hepatorenalis
.....	.....	(Recessus paraduodenalis)
.....	.....	Recessus subhepatici
Recessus duodenojejunalis	Recessus duodenomesocolicus cranialis	Recessus duodenalis superior
	Recessus duodenomesocolicus caudalis	Recessus duodenalis inf.
Plica duodenojejunalis ..	Plica duodenomesocolica cranialis	Plica duodenalis sup. (Plica duodenojejunalis)*
.....	.....	(Plica paraduodenalis)
(Plica duodenomesocolica)	Plica duodenomesocolica caudalis	Plica duodenalis inferior (Plica duodenomesocolica)*
Recessus intersigmoideus .	Recessus intersigmoideus .	Recessus intersigmoideus
Recessus ileocaecalis superior	Recessus iliocaecalis cranialis	Recessus ileocecalis superior*
.....	.....	Plica cecalis vascularis*

BNA	JNA	PNA
Recessus ileocaecalis inf. .	Recessus iliocaecalis caudalis	Recessus ileocecalis inferior*
Plica ileocaecalis	Plica iliocaecalis caudalis ..... / Plica iliocaecalis cranialis	Plica ileocecalis*
Fossa caecalis	.....	.....
Recessus retrocaecalis ...	Recessus retrocaecalis ...	Recessus retrocecalis*
Plica caecalis	Plica caecalis	Plicae cecales*
Recessus paracolici	Recessus paracolici	Sulci paracolici
.....	Plicae epididymidis	.....
(Fossa iliacosubfascialis) .	.....	.....
(Recessus phrenicohepatici)	(Recessus phrenicohepatici)	Recessus subphrenici
Plica umbilicalis media ..	Plica umbilicalis media ..	Plica umbilicalis mediana
Plica umbilicalis lateralis	Plica umbilicalis lateralis	Plica umbilicalis medialis
Plica epigastrica	Plica epigastrica	Plica umbilicalis lateralis
Fovea inguinalis lateralis	Fovea inguinalis lateralis	Fossa inguinalis lateralis
Fovea inguinalis medialis	Fovea inguinalis medialis	Fossa inguinalis medialis
Fovea supravesicalis	Fovea supravesicalis	Fossa supravesicalis
.....	.....	Trigonum inguinale*
Plica pubovesicalis	.....	.....
Plica vesicalis transversa .	Plica vesicalis transversa .	Plica vesicalis transversa
.....	Spatium praevesicale	Spatium retropubicum
Lig. latum uteri	Plica lata uteri	Lig. latum uteri
Mesometrium	Mesometrium	Mesometrium
Mesosalpinx	Mesosalpinx	Mesosalpinx
Mesovarium	Mesovarium	Mesovarium
.....	Paracolpium	.....
.....	Paracysticum	.....
Parametrium	Parametrium	Parametrium
.....	Paraproctium	.....
.....	Plica chordae uteroinguinalis (teretis)	.....
Bursa ovarica	.....	.....
Lig. suspensorium ovarii	Plica suspensoria ovarii ..	Lig. suspensorium ovarii
Plica rectouterina (Douglasi)	Plica rectouterina	Plica rectouterina
Excavatio rectouterina (Cavum Douglasi)	Excavatio rectouterina ...	Excavatio rectouterina*
Excavatio vesicouterina .	Excavatio vesicouterina .	Excavatio vesicouterina*

BNA	JNA	PNA
Excavatio rectovesicalis .	Excavatio rectovesicalis .	Excavatio rectovesicalis
Spatium retroperitoneale .	.....	Spatium retroperitoneale
.....	Spatium retroperitoneale pelvis	.....
Termini ontogenetici°		
Mesenterium commune ..	Mesenterium	Mesenterium dorsale commune
Mesogastrium	Mesogastrium ventrale ...	Mesogastrium
.....	Mesogastrium dorsale ...	.....
Mesorchium	Mesorchium	Mesorchium
(Processus vaginalis peritonaei)	Processus vaginalis peritonaei	Processus vaginalis peritonei
GLANDULAE ENDOCRINALES°	GLANDULAE ENDOCRINALES°	GLANDULAE SINE DUCTIBUS**
GLANDULA THYREOIDEA	GLANDULA THYREOIDEA	GLANDULA THYROIDEA*
Lobus (dexter et sinister)	Lobus dexter et sinister .	Lobus (dexter et sinister)
(Lobus pyramidalis)	var. Lobus pyramidalis .	(Lobus pyramidalis)
Isthmus glandulae thyreoideae	Isthmus glandulae thyreoideae	Isthmus gl. thyroideae*
.....	Capsula gl. thyreoideae ..	Capsula fibrosa
(M. levator glandulae thyreoideae)	var. M. levator glandulae thyreoideae	M. levator glandulae thyroideae*
Lobuli gl. thyreoideae ..	Lobuli gl. thyreoideae ..	Lobuli gl. thyroideae*
Stroma glandulae thyreoideae	.....	Stroma gl. thyroideae*
.....	.....	Folliculi gl. thyroideae*
(Glandulae thyreoideae accessoriae)	var. Glandulae thyreoideae accessoriae	(Glandulae thyroideae accessoriae)*
(Glandula thyreoidea accessoria suprahyoidea)	.....	.....

BNA	JNA	PNA
.....	GLANDULAE PARATHYREOIDEAE CRANIALES ET CAUDALES	GLANDULA PARATHYROIDEA SUP.* / GLANDULA PARATHYROIDEA INF.*
THYMUS	THYMUS	THYMUS
Lobus (dexter et sinister)	Lobus dexter et sinister .	Lobus (dexter et sinister)
Tractus centralis	Tractus centralis	.....
Lobuli thymi	Lobuli thymi	Lobuli thymi
.....	.....	(Noduli thymici accessorii)
HYPOPHYSIS	HYPOPHYSIS	HYPOPHYSIS (GLANDULA PITUITARIA)*
.....	Pars principalis (hypophyseos)	.....
Lobus anterior	Lobus glandularis = anterior	Lobus anterior (Adenohypophysis)**
.....	Pars tuberalis	Pars infundibularis**
.....	Pars intermedia	Pars intermedia
.....	.....	Pars distalis**
.....	.....	(Pars pharyngea)**
Lobus posterior	Lobus nervosus = posterior	Lobus posterior (Neurohypophysis)**
CORPUS PINEALE	CORPUS PINEALE	CORPUS PINEALE
GLANDULA SUPRARENALIS	CORPUS SUPRARENALE	GLANDULA SUPRARENALIS
Basis glandulae suprarenalis	Facies renalis	Facies renalis
Facies anterior	Facies ventralis	Facies anterior
Facies posterior	Facies dorsalis	Facies posterior
Apex suprarenalis (glandulae dextrae)	.....	.....
Margo superior	Margo cranialis	Margo superior
Margo medialis	Margo medialis	Margo medialis
Hilus glandulae suprarenalis	Hilus corporis suprarenalis	Hilus
Vena centralis	.....	Vena centralis
Substantia corticalis	Substantia corticalis	Cortex
Substantia medullaris	Substantia medullaris	Medulla
(Glandulae suprarenales accessoriae)	(Corpora interrenalia accessoria)	(Glandulae suprarenales accessoriae)

ANGIOLOGIA

Angiologia	*Systema vasorum*	*Angiologia*
Arteria	Arteria	Arteria
Arteriola	Arteriola	Arteriola
Vena	Vena	Vena
Venula	Venula	Venula
Vena cutanea	Vena cutanea	Vena cutanea
Vena comitans	Vena comitans	Vena comitans
Plexus venosus	Plexus venosus	Plexus venosus
		Rete arteriosum
		Circulus articularis vasculosus**
Rete venosum	Rete venosum	Rete venosum
Sinus (venosus)	Sinus venosus	Sinus venosus**
Vas collaterale	Vas collaterale	Vas collaterale
Vas anastomoticum	Vas communicans	Vas anastomoticum
		Anastomosis arteriovenosa
Ramus communicans	Ramus communicans	
Plexus vasculosus	Plexus vasculosus	Plexus vasculosus
Rete vasculosum	Rete vasculosum	
Rete mirabile	Rete mirabile	Rete mirabile
Emissarium	Emissarium	Vena emissaria
Corpus cavernosum	Corpus cavernosum	
Vas capillare	Vas capillare	Vas capillare
Vas lymphaticum	Vas lymphaceum	Vas lymphaticum
	Valvulae vasorum lymphaceorum	Valvula lymphatica
Plexus lymphaticus	Plexus lymphaceus	Plexus lymphaticus
Lymphoglandula	Lymphonodus	Nodus lymphaticus (Lymphonodus)
Nodulus lymphaticus	Lymphonodulus	Folliculus lymphaticus
Cisterna	Cisterna	Cisterna
Tunica externa (adventitia)	Tunica externa	Tunica externa

BNA	JNA	PNA
Tunica media	Tunica media	Tunica media
Tunica intima	Tunica intima	Tunica intima
.....	Valvulae vasorum	.....
.....	Valvulae venarum	Valvula venosa
Vasa vasorum	Vasa vasorum	Vasa vasorum
Vagina vasorum	Vagina vasorum	.....
Sanguis	Sanguis	Sanguis
Lympha	Lympha	Lympha
COR	COR	COR
Facies sternocostalis	Facies sternocostalis	Facies sternocostalis
Facies diaphragmatica ..	Facies diaphragmatica ..	Facies diaphragmatica
.....	.....	Facies pulmonalis
.....	.....	Margo dexter
Basis cordis	Basis cordis	Basis cordis
Apex cordis	Apex cordis	Apex cordis
Incisura (apicis) cordis	Incisura apicis cordis ..	Incisura apicis cordis
Sulcus longitudinalis anterior	Sulcus interventricularis ventralis	Sulcus interventricularis (cordis) anterior**
Sulcus longitudinalis posterior	Sulcus interventricularis dorsalis	Sulcus interventricularis (cordis) posterior**
Sulcus coronarius	Sulcus coronarius	Sulcus coronarius
Pericardium	Pericardium	Pericardium
		Pericardium fibrosum
		Pericardium serosum
		Lamina parietalis
.....	Pars sternocostalis	.....
.....	Pars diaphragmatica	.....
.....	Pars dorsalis	.....
.....	Pars lateralis	.....
.....	Cupula pericardii	.....
.....	Cavum pericardii	Cavum pericardii
Liquor pericardii	.....	.....
.....	.....	Sinus obliquus pericardii
Ligg. sternopericardiaca	Chordae sternopericardiacae	Ligg. sternopericardiaca

BNA	JNA	PNA
.....	Porta arteriarum	.....
.....	Porta venarum	.....
Sinus transversus pericardii	Sinus transv. pericardii	Sinus transv. pericardii
Epicardium	Epicardium	Lamina visceralis (Epicardium)
.....	Nodus sinuatrialis	Nodus sinuatrialis*
.....	Fasciculus atrioventricularis	Fasciculus atrioventricularis
.....	Nodus (fasciculi atrioventricularis)	Nodus atrioventricularis
.....	Crura (fasciculi atrioventricularis)	Crus (dextrum et sinistrum)
.....	Truncus (fasciculi atrioventricularis)	Truncus (fasciculi atrioventricularis)
Myocardium	Myocardium	Myocardium
Vortex cordis	Vortex cordis	Vortex cordis
Mm. papillares	Mm. papillares	Mm. papillares
Chordae tendineae ..	Chordae tendineae ..	Chordae tendineae
Trabeculae carneae	Trabeculae carneae	Trabeculae carneae
Endocardium	Endocardium	Endocardium
Annuli fibrosi	Anuli fibrosi	Anuli fibrosi
Trigona fibrosa	Trigona fibrosa	Trigona fibrosa
.....	Septum atrioventriculare	Septum atrioventriculare
Ventriculus cordis	Ventriculi cordis	Ventriculus cordis
.....	Trabeculae carneae ventriculorum	.....
Septum ventriculorum .	Septum ventriculorum .	Septum interventriculare
Septum musculare ventriculorum	Pars muscularis	Pars muscularis
Septum membranaceum ventriculorum .	Pars membranacea ..	Pars membranacea
Atrium cordis	Atria cordis	Atrium cordis
.....	Trabeculae carneae atriorum	.....
Auricula cordis	Auriculae cordis	Auricula atrii
Septum atriorum	Septum atriorum	Septum interatriale
Pars membranacea septi atriorum	Pars membranacea	.....
.....	Pars muscularis septi atriorum	.....

BNA	JNA	PNA
Ostium venosum	Ostia venosa (atrioventricularia)	Ostia atrioventricularia (dext. et sin.)
.....	Ostium atrioventriculare dextrum	Vide: Ventriculus dexter**
.....	Ostium atrioventriculare sinistrum	Vide: Ventriculus sinister**
Ostium arteriosum	Ostia arteriosa	.....
.....	Ostium arteriosum dext.	Ostium trunci pulmonalis
.....	Ostium arteriosum sin. ..	Ostium aortae
ATRIUM DEXTRUM	ATRIUM DEXTRUM	ATRIUM DEXTRUM
Auricula dextra	Auricula dextra	Auricula dextra
Mm. pectinati	Trabeculae carneae ...	Mm. pectinati
Sulcus terminalis atrii dextri	Sulcus terminalis atrii dextri	Sulcus terminalis
Crista terminalis	Crista terminalis	Crista terminalis
Sinus venarum (cavarum)	Sinus venarum cavarum .	Sinus venarum cavarum
Fossa ovalis	Fossa ovalis	Fossa ovalis
Limbus fossae ovalis (Vieussensi)	Limbus fossae ovalis ..	Limbus fossae ovalis
.....	Foramen ovale	Foramen ovale
Tuberculum intervenosum (Loweri)	var. Torus intervenosus ..	Tuberculum intervenosum
.....	.....	Ostium venae cavae superioris*
.....	.....	Ostium venae cavae inferioris*
Valvula venae cavae inferioris (Eustachii)	Valvula v. cavae caudalis	Valvula venae cavae inf.
Valvula sinus coronarii (Thebesii)	Valvula sinus coronarii .	Valvula sinus coronarii
Foramina venarum minimarum (Thebesii)	Foramina venarum minimarum	Foramina venarum minimarum
VENTRICULUS DEXTER	VENTRICULUS DEXTER	VENTRICULUS DEXTER
.....	Vide: Cor	Ostium atrioventriculare dextrum**

BNA	JNA	PNA
Valvula tricuspidalis	Valvula tricuspidalis	Valva atrioventricularis dextra (Valva tricuspidalis)
Cuspis anterior	Cuspis ventralis	Cuspis anterior*
Cuspis posterior	Cuspis dorsalis	Cuspis posterior*
Cuspis medialis	Cuspis septalis	Cuspis septalis
.....	Mm. papillares parvi ..	{M. papillaris posterior {Mm. papillares septales
.....	M. papillaris ventralis	M. papillaris anterior
.....	Trabecula septomarginalis	Trabecula septomarginalis
Crista supraventricularis .	Crista supraventricularis .	Crista supraventricularis
Conus arteriosus	Conus arteriosus	Conus arteriosus (infundibulum)
.....	Vide: Cor	Ostium trunci pulmonalis**
Valvulae semilunares (a. pulmonalis)	Valvula a. pulmonalis ...	Valva trunci pulmonalis
Valvula semilunaris anterior	Velum semilunare sinistrum	Valvula semilunaris anterior
Valvula semilunaris dextra	Velum semilunare dextrum	Valvula semilunaris dextra
Valvula semilunaris sinistra	Velum semilunare dorsale	Valvula semilunaris sin.
Noduli valvularum semilunarium	Noduli velorum semilunarium	Noduli valvularum semilunarium
Lunulae valvularum semilunarium	Lunulae velorum semilunarium	Lunulae valvularum semilunarium
ATRIUM SINISTRUM	ATRIUM SINISTRUM	ATRIUM SINISTRUM
Auricula sinistra	Auricula sinistra	Auricula sinistra
.....	Falx septi	.....

BNA	JNA	PNA
Musculi pectinati	Trabeculae carneae	.....
Valvula foraminis ovalis	.....	Valvula foraminis ovalis (Falx septi)
.....	.....	Ostia venarum pulmonalium*
VENTRICULUS SINISTER	VENTRICULUS SINISTER	VENTRICULUS SINISTER
.....	Vide: Cor	Ostium atrioventriculare sinistrum**
Valvula bicuspidalis (mitralis)	Valvula bicuspidalis (mitralis)	Valva atrioventricularis sinistra (Valva mitralis)
Cuspis anterior	Cuspis ventralis	Cuspis anterior
Cuspis posterior	Cuspis dorsalis	Cuspis posterior
.....	M. papillaris dexter ..	M. papillaris posterior
.....	M. papillaris sinister ..	M. papillaris anterior
.....	Vide: Cor	Ostium aortae**
Valvulae semilunares aortae	Valvuli aortae	Valva aortae
Valvula semilunaris posterior	Velum semilunare dext.	Valvula semilunaris posterior
Valvula semilunaris dextra	Velum semilunare ventrale	Valvula semilunaris dextra
Valvula semilunaris sinistra	Velum semilunare sinistrum	Valvula semilunaris sin.
Noduli valvularum semilunarium (Arantii)	Noduli velorum semilunarium	Noduli valvularum semilunarium**
Lunulae valvularum semilunarium	Lunulae velorum semilunarium	Lunulae valvularum semilunarium**

BNA	JNA	PNA
ARTERIAE	ARTERIAE	ARTERIAE
A. PULMONALIS	A. PULMONALIS	TRUNCUS PULMONALIS
.....	Sinus a. pulmonalis	Sinus trunci pulmonalis
Ramus dexter	Ramus dexter	A. pulmonalis dextra***
Ramus sinister	Ramus sinister	A. pulmonalis sinistra***
Ductus arteriosus (Botalli)	Ductus arteriosus	Ductus arteriosus
Ligamentum arteriosum .	Chorda ductus arteriosi .	Ligamentum arteriosum
AORTA	AORTA	AORTA
Aorta ascendens	Aorta ascendens	Aorta ascendens
Bulbus aortae	Bulbus aortae	Bulbus aortae
Sinus aortae (Valsalvae)	Sinus aortae	Sinus aortae
A. coronaria (cordis) dextra	A. coronaria (cordis) dextra	A. coronaria dextra
Ramus descendens posterior	Ramus interventricularis	Ramus interventricularis posterior
A. coronaria (cordis) sinistra	A. coronaria (cordis) sinistra	A. coronaria sinistra
Ramus circumflexus	Ramus circumflexus	Ramus circumflexus
R. descendens ant. ..	Ramus interventricularis	Ramus interventricularis anterior
Arcus aortae	Arcus aortae	Arcus aortae
Isthmus aortae	Isthmus aortae	Isthmus aortae
.....	.....	Corpora paraaortica**
A. ANONYMA	TRUNCUS BRACHIOCEPHALICUS	TRUNCUS BRACHIOCEPHALICUS
(A. thyreoidea ima)	var. A. thyreoidea ima ..	(A. thyroidea ima)*
A. CAROTIS COMMUNIS	A. CAROTIS COMMUNIS	A. CAROTIS COMMUNIS
Glomus caroticum	Glomus caroticum	Glomus caroticum
.....	.....	Sinus caroticus*

BNA	JNA	PNA
A. CAROTIS EXTERNA	A. CAROTIS EXTERNA	A. CAROTIS EXTERNA
A. thyreoidea superior	*A. thyreoidea cranialis*	*A. thyroidea superior**
Ramus hyoideus	Ramus hyoideus	Ramus infrahyoideus
Ramus sternocleidomastoideus	Ramus sternocleidomastoideus	R. sternocleidomastoideus
A. laryngea superior	A. laryngica cranialis	A. laryngea superior
Ramus cricothyreoideus .	Ramus cricothyreoideus .	Ramus cricothyroideus*
Ramus anterior	Ramus ventralis	Ramus anterior
Ramus posterior	Ramus dorsalis	Ramus posterior
Rami glandulares	.....	.....
A. pharyngea ascendens	*A. pharyngica ascendens*	*A. pharyngea ascendens*
A. meningea posterior ...	A. meningica occipitalis .	A. meningea posterior
Rami pharyngei	Rami pharyngici	Rami pharyngei
A. tympanica inferior ...	A. tympanica inferior ...	A. tympanica inferior
.....	.....	*(Truncus linguofacialis)*
A. lingualis	*A. lingualis*	*A. lingualis*
Ramus hyoideus	Ramus hyoideus	R. suprahyoideus
A. sublingualis	A. sublingualis	A. sublingualis
Rami dorsales linguae ...	Rami dorsales linguae ...	Rami dorsales linguae
A. profunda linguae	A. profunda linguae	A. profunda linguae
A. maxillaris externa	*A. facialis*	*A. facialis*
A. palatina ascendens ...	A. palatina ascendens ...	A. palatina ascendens
Ramus tonsillaris	Ramus tonsillaris	Ramus tonsillaris
A. submentalis	A. submentalis	A. submentalis
Rami glandulares.....	Rami glandulares	Rami glandulares
A. labialis superior	A. labialis maxillaris	A. labialis superior
A. labialis inferior	A. labialis mandibularis .	A. labialis inferior
A. angularis	A. angularis	A. angularis
A. sternocleidomastoidea	*A. sternocleidomastoidea*	.....
A. occipitalis	*A. occipitalis*	*A. occipitalis*
.....	.....	Rr. sternocleidomastoidei
Ramus mastoideus	Ramus mastoideus	Ramus mastoideus
Ramus auricularis	Ramus auricularis	Ramus auricularis

BNA	JNA	PNA
Rami musculares	.....	.....
Ramus descendens	Ramus descendens	Ramus descendens*
(Ramus meningeus)	(Ramus meningicus)	(Ramus meningeus)
Rami occipitales	.....	Rami occipitales
A. auricularis posterior	*A. retroauricularis*	*A. auricularis posterior*
A. stylomastoidea	A. stylomastoidea	A. stylomastoidea
A. tympanica posterior	R. tympanicus post. ...	A. tympanica posterior
Rami mastoidei	Rami mastoidei	Rami mastoidei
Ramus stapedius	Ramus stapedius	(Ramus stapedius)
Ramus auricularis	Ramus auricularis	Ramus auricularis
Ramus occipitalis	Ramus occipitalis	Ramus occipitalis
A. temporalis superficialis	*A. temporalis superficialis*	*A. temporalis superficialis*
Rami parotidei	Rami parotidici	Rami parotidei
A. transversa faciei	A. transversa faciei	A. transversa faciei
Rami auriculares anteriores	Rami praeauriculares	Rami auriculares anteriores
A. zygomaticoorbitalis ...	A. zygomaticoorbitalis ...	A. zygomaticoorbitalis*
A. temporalis media	A. temporalis media ...	A. temporalis media
Ramus frontalis	Ramus frontalis	Ramus frontalis
Ramus parietalis	Ramus parietalis	Ramus parietalis
A. maxillaris interna	*A. maxillaris*	*A. maxillaris*
A. auricularis profunda ..	A. auricularis profunda ..	A. auricularis profunda
A. tympanica anterior ...	A. tympanica anterior ...	A. tympanica anterior
A. alveolaris inferior	A. alveolaris mandibularis	A. alveolaris inferior
.....	....	Rami dentales
Ramus mylohyoideus ..	Ramus mylohyoideus ..	Ramus mylohyoideus
A. mentalis	A. mentalis	A. mentalis*
A. meningea media	A. meningica media	A. meningea media
.....	.....	R. frontalis
.....	.....	R. parietalis
Ramus meningeus accessorius)	var. Ramus meningicus accessorius	(Ramus meningeus accessorius)

BNA	JNA	PNA
Ramus petrosus superficialis	Ramus pyramidis superficialis	Ramus petrosus
A. tympanica superior .	Ramus tympanicus superior	A. tympanica superior
.....	.....	R. anastomoticus cum a. lacrimali
A. masseterica	A. masseterica	A. masseterica
A. temporalis profunda posterior	A. temporalis profunda posterior	Aa. temporales profundae
A. temporalis profunda anterior	A. temporalis profunda anterior	
Rami pterygoidei	Rami pterygoidei	Rami pterygoidei
A. buccinatoria	A. buccalis	A. buccalis
A. alveolaris superior posterior	A. alveolaris maxillaris posterior	A. alveolaris superior posterior
.....	.....	Rami dentales
A. infraorbitalis	A. infraorbitalis	A. infraorbitalis
Aa. alveolares superiores anteriores	Aa. alveolares maxillares anteriores	Aa. alveolares superiores anteriores
.....	.....	Rami dentales
A. palatina descendens ..	A. palatina descendens ..	A. palatina descendens
A. canalis pterygoidei (Vidii)	A. canalis pterygoidei .	A. canalis pterygoidei
A. palatina major	A. palatina major	A. palatina major
Aa. palatinae minores	Aa. palatinae minores	Aa. palatinae minores
A. sphenopalatina	A. pterygopalatina	A. sphenopalatina
Aa. nasales posteriores laterales et septi	Aa. nasales posteriores laterales et septi	Aa. nasales posteriores laterales et septi
A. CAROTIS INTERNA	A. CAROTIS INTERNA	A. CAROTIS INTERNA
.....	var. Sinus a. carotidis internae	Sinus caroticus

BNA	JNA	PNA
Ramus caroticotympanicus	*Ramus caroticotympanicus*	*Rami caroticotympanici*
A. ophthalmica	*A. ophthalmica*	*A. ophthalmica*
A. centralis retinae	A. centralis retinae	A. centralis retinae
A. lacrimalis	A. lacrimalis	A. lacrimalis
Aa. palpebrales laterales	Aa. palpebrales temporales	Aa. palpebrales laterales
Aa. conjunctivales posteriores	Ramuli conjunctivales .	Aa. conjunctivales posteriores
Rami musculares	Rami musculares	.....
Aa. ciliares anteriores .	Ramuli ciliares	Aa. ciliares anteriores
Aa. conjunctivales anteriores	Ramuli conjunctivales	Aa. conjunctivales anteriores
Aa. episclerales	Ramuli episclerales ..	Aa. episclerales
Aa. ciliares posteriores breves	Aa. chorioideae	Aa. ciliares posteriores breves
Aa. ciliares posteriores longae	Aa. iridis { A. iridis nasalis / A. iridis temporalis ..... }	Aa. ciliares posteriores longae
A. supraorbitalis	A. frontalis lateralis	A. supraorbitalis
A. ethmoidalis posterior	A. ethmoidea posterior .	A. ethmoidalis posterior
A. ethmoidalis anterior ..	A. ethmoidea anterior ...	A. ethmoidalis anterior
A. meningea anterior ..	A. meningica frontalis .	(A. meningea anterior)
Aa. palpebrales mediales	Aa. palpebrales mediales	Aa. palpebrales mediales
Arcus tarseus superior ...	Arcus tarseus superior ...	Arcus palpebralis superior
Arcus tarseus inferior ...	Arcus tarseus inferior ...	Arcus palpebralis inferior
A. frontalis	A. frontalis medialis	A. supratrochlearis
A. dorsalis nasi	A. dorsalis nasi	A. dorsalis nasi
Aa. cerebri	*Aa. encephali*	*Aa. cerebri*
A. chorioidea	A. chorioidea	A. choroidea anterior*
A. cerebri anterior	A. cerebralis anterior	A. cerebri anterior***
.....	Rr. perforantes	.....
A. communicans anterior	A. communicans anterior	A. communicans anterior
A. cerebri media	A. cerebralis media	A. cerebri media***

BNA	JNA	PNA
A. communicans posterior	A. communicans post.	A. communicans posterior
Circulus arteriosus (Willisi)	*Circulus arteriosus cerebri*	*Circulus arteriosus cerebri*
A. SUBCLAVIA	A. SUBCLAVIA	A. SUBCLAVIA
A. vertebralis	*A. vertebralis*	*A. vertebralis*
Rami spinales	Rami spinales	Rami spinales
A. spinalis posterior	A. spinalis dorsalis	A. spinalis posterior
A. spinalis anterior	A. spinalis ventralis	A. spinalis anterior
Ramus meningeus	Ramus meningicus	Ramus meningeus
A. cerebelli inferior posterior	A. cerebellaris inferior posterior	A. cerebelli inferior post.
A. basilaris	*A. basialis*	*A. basilaris*
A. cerebelli inferior anterior	A. cerebellaris inferior anterior	A. cerebelli inferior anterior
A. auditiva interna	A. labyrinthi	A. labyrinthici
Rami ad pontem	Ramus pontis	Rami ad pontem
A. cerebelli superior	A. cerebellaris superior	A. cerebelli superior
A. cerebri posterior	A. cerebralis posterior	A. cerebri posterior***
A. mammaria interna	*A. thoracica interna*	*A. thoracica interna*
Aa. mediastinales anteriores	Aa. mediastinales ventrales	Rr. mediastinales
Aa. thymicae	Aa. thymicae	Rr. thymici
Rami bronchiales	Rami bronchales	Rami bronchiales
Rami sternales	Rami sternales	Rami sternales
A. pericardiacophrenica	A. pericardiacophrenica	A. pericardiacophrenica
Rami intercostales	Rami intercostales	Rr. intercostales anteriores
Rami perforantes	Aa. perforantes	Rami perforantes
Rami mammarii	Rami mammarii	Rami mammarii
Rami cutanei	Rami cutanei	
Rami musculares	Rami musculares	
(Ramus costalis lateralis)	(Ramus costalis lateralis)	(Ramus costalis lateralis)

BNA	JNA	PNA
A. musculophrenica	A. musculophrenica	A. musculophrenica
A. epigastrica superior ..	A. epigastrica cranialis ..	A. epigastrica superior
TRUNCUS THYREOCERVICALIS	TRUNCUS THYREOCERVICALIS	TRUNCUS THYROCERVICALIS*
A. thyreoidea inferior	*A. thyreoidea caudalis*	*A. thyroidea inferior**
A. laryngea inferior ..	A. laryngica caudalis ..	A. laryngea inferior
Rami glandulares	.....	Rami glandulares**
Rami pharyngei	Rami pharyngici	Rami pharyngei
Rami oesophagei	Rami oesophagici	Rami esophagei*
Rami tracheales	Rami tracheales	Rami tracheales
A. cervicalis ascendens	A cervicalis ascendens	A. cervicalis ascendens
Rami spinales	Rami spinales	Rami spinales
Rami musculares	Rami musculares	.....
Ramus profundus	Ramus profundus	.....
A. cervicalis superficialis	*A. cervicalis superficialis*	.....
A. transversa colli	*A. transversa colli*	*A. transversa colli*
Ramus ascendens	Ramus ascendens	R. superficialis (A. cervicalis superficialis)**
Ramus descendens	Ramus descendens	(R. profundus) (A. scapularis descendens)**
A. transversa scapulae	*A. suprascapularis*	*A. suprascapularis*
Ramus acromialis	Ramus acromialis	Ramus acromialis
TRUNCUS COSTOCERVICALIS	TRUNCUS COSTOCERVICALIS	TRUNCUS COSTOCERVICALIS
A. intercostalis suprema	*A. intercostalis suprema*	*A. intercostalis suprema*
.....	.....	Aa. intercostales posteriores (I et II)
Rr. dorsales	Rr. dorsales	Rr. dorsales
Rr. spinales	Rr. spinales	Rr. spinales
.....	.....	(A. scapularis descendens) (dorsalis)**
A. cervicalis profunda	*A. cervicalis profunda*	*A. cervicalis profunda*

BNA	JNA	PNA
A. AXILLARIS	A. AXILLARIS	A. AXILLARIS
Rami subscapulares	Rami subscapulares	Rami subscapulares
A. THORACALIS SUPREMA A. THORACOACROMIALIS	A. THORACICA SUPREMA A. THORACOACROMIALIS	A. THORACICA SUPREMA A. THORACOACROMIALIS
Ramus acromialis	Ramus acromialis	Ramus acromialis
Rete acromiale	Rete acromiale	Rete acromiale
.....	.....	Ramus clavicularis
Ramus deltoideus	Ramus deltoideus	Ramus deltoideus
Rami pectorales	Rami pectorales	Rami pectorales
A. THORACALIS LATERALIS	A. THORACICA LATERALIS	A. THORACICA LATERALIS
Rami mammarii externi .	Rami mammarii externi .	Rr. mammarii laterales
A. subscapularis	*A. subscapularis*	*A. subscapularis*
A. thoracodorsalis	A. thoracodorsalis	A. thoracodorsalis
A. circumflexa scapulae	A. circumflexa scapulae	A. circumflexa scapulae
A. circumflexa humeri anterior	*A. circumflexa humeri volaris*	*A. circumflexa humeri anterior*
A. circumflexa humeri posterior	*A. circumflexa humeri dorsalis*	*A. circumflexa humeri posterior*
A. BRACHIALIS	A. BRACHIALIS	A. BRACHIALIS
.....	.....	*(A. brachialis superficialis)*
A. profunda brachii	A. profunda brachii	A. profunda brachii
A. nutricia humeri ...	Aa. nutriciae humeri ..	Aa. nutriciae humeri
R. deltoideus	R. deltoideus	R. deltoideus
A. collateralis media ..	A. collateralis media ..	A. collateralis media
A. collateralis radialis .	A. collateralis radialis .	A. collateralis radialis
.....	R. dorsalis (a. collateralis radialis)	.....
.....	R. volaris (a. collateralis radialis)	.....
A. collateralis ulnaris sup.	A. collateralis ulnaris proximalis	A. collateralis ulnaris sup.
A. collateralis ulnaris inf.	A. collateralis ulnaris distalis	A. collateralis ulnaris inf.

BNA	JNA	PNA
A. RADIALIS	A. RADIALIS	A. RADIALIS
A. recurrens radialis	A. recurrens radialis	A. recurrens radialis
Rami musculares	.....	.....
Ramus carpeus volaris ..	Ramus carpicus volaris ..	R. carpeus palmaris
Ramus volaris superficialis	Ramus volaris superficialis	R. palmaris superficialis
Ramus carpeus dorsalis .	Ramus carpicus dorsalis	Ramus carpeus dorsalis
.....	Rete carpi volare	.....
Rete carpi dorsale	Rete carpi dorsale	Rete carpi dorsale
Aa. metacarpeae dorsales	Aa. metacarpicae dorsales	Aa. metacarpeae dorsales
Aa. digitales dorsales	Aa. digitales dorsales	Aa. digitales dorsales
A. princeps pollicis	A. princeps pollicis	A. princeps pollicis
A. volaris indicis radialis	A. volaris indicis radialis	A. radialis indicis
Arcus volaris profundus .	Arcus volaris profundus .	Arcus palmaris profundus
Aa. metacarpeae volares	Aa. metacarpicae volares	Aa. metacarpeae palmares
Rami perforantes ...	Rami perforantes ...	Rami perforantes
A. ULNARIS	A. ULNARIS	A. ULNARIS
Aa. recurrentes ulnares .	A. recurrens ulnaris	A. recurrens ulnaris
		R. anterior
		R. posterior
.....	R. dorsalis (a. recurrentis ulnaris)	.....
.....	R. volaris (a. recurrentis ulnaris)	.....
Rete articulare cubiti	Rete articulare cubiti	Rete articulare cubiti
A. interossea communis .	A. interossea communis .	A. interossea communis
A. interossea dorsalis .	A. interossea dorsalis .	A. interossea posterior
A. interossea recurrens	A. interossea recurrens	A. interossea recurrens
A. interossea volaris ..	A. interossea volaris ..	A. interossea anterior
A. mediana	A. mediana	A. mediana
Rami musculares	.....	.....
Ramus carpeus dorsalis .	Ramus carpicus dorsalis	Ramus carpeus dorsalis
Ramus carpeus volaris ..	Ramus carpicus volaris ..	Ramus carpeus palmaris
Ramus volaris profundus	Ramus volaris profundus	Ramus palmaris prof.
Arcus volaris superficialis	Arcus volaris superficialis	Arcus palmaris superficialis

BNA	JNA	PNA
Aa. digitales volares communes	Aa. digitales volares communes	Aa. digitales palmares communes
Aa. digitales volares propriae	Aa. digitales volares propriae	Aa. digitales palmares propriae
AORTA DESCENDENS	AORTA DESCENDENS	AORTA DESCENDENS
AORTA THORACALIS	AORTA THORACICA	AORTA THORACICA
RAMI VISCERALES	.....	.....
Rr. bronchiales	.....	Rr. bronchiales
Aa. bronchiales	Aa. bronchales	
Aa. oesophageae	Aa. oesophagicae	Rr. esophagei*
Rr. oesophagei	Rr. oesophagici	
Rr. pericardiaci	Rr. pericardiaci	Rr. pericardiaci
RAMI PARIETALES	.....	.....
Rr. mediastinales	*Rr. mediastinales*	*Rr. mediastinales*
Aa. phrenicae superiores .	Aa. phrenicae thoracicae	Aa. phrenicae superiores
Aa. intercostales	*Aa. intercostales*	*Aa. intercostales posteriores (III–XI)*
Rami posteriores	Rami dorsales	R. dorsalis
Ramus spinalis	Ramus spinalis	R. spinalis
Rami musculares ...	.....	.....
Ramus cutaneus medialis	Ramus cutaneus medialis	R. cutaneus medialis
Ramus cutaneus lateralis	Ramus cutaneus lat.	R. cutaneus lateralis
.....	.....	R. collateralis
Rami anteriores	.....	.....
Rami musculares ...	.....	.....
Rami cutanei laterales	Rami cutanei laterales	R. cutaneus lateralis
Ramus posterior .	Ramulus dorsalis .	.....
Ramus anterior ...	Ramus ventralis ..	.....

BNA	JNA	PNA
Rami mammarii laterales	Rami mammarii laterales	Rr. mammarii
Rami cutanei anteriores	Rami cutanei ventrales	.....
.....	Rami pectorales	.....
Rami mammarii mediales	Rami mammarii mediales	.....
.....	A. subcostalis	A. subcostalis R. dorsalis R. spinalis
.....	Rr. abdominales	.....
AORTA ABDOMINALIS	AORTA ABDOMINALIS	AORTA ABDOMINALIS
RAMI PARIETALES	.....	.....
A. phrenica inferior	*A. phrenica abdominalis*	*Aa. phrenicae inferiores***
Rami suprarenales superiores	Rami suprarenales	A. suprarenalis superior
Aa. lumbales	*Aa. lumbales*	*Aa. lumbales*
Ramus dorsalis ..... Ramus spinalis	Ramus dorsalis ..... Ramus spinalis	Ramus dorsalis Ramus spinalis
A. sacralis media	*Aorta caudalis*	*A. sacralis mediana*
A. lumbalis ima ..... Glomus coccygeum ...	A. lumbalis ima ..... Glomus coccygicum ..	A. lumbalis ima Corpus coccygeum**
RAMI VISCERALES	.....	.....
A. coeliaca	*A. coeliaca*	*Truncus celiacus**
A. gastrica sinistra ..... Rami oesophagei ..... A. hepatica ..... A. gastrica dextra ..... A. hepatica propria ... Ramus dexter ..... A. cystica	A. gastrica sinistra .... A. hepatica communis ... A. gastrica dextra ..... A. hepatica propria ... Ramus dexter ..... A. vesicae felleae	A. gastrica sinistra Rami esophagei* A. hepatica communis A. gastrica dextra A. hepatica propria Ramus dexter A. cystica A. lobi caudati**

BNA	JNA	PNA
.....	.....	A. segmenti anterioris**
.....	.....	A. segmenti posterioris**
Ramus sinister	Ramus sinister	Ramus sinister
.....	.....	A. lobi caudati**
.....	.....	A. segmenti medialis**
.....	.....	A. segmenti lateralis**
A. gastroduodenalis ...	A. gastroduodenalis ...	A. gastroduodenalis
A. pancreaticoduodenalis sup.	A. pancreaticoduodenalis cranialis	Aa. supraduodenales superiores**
Rami pancreatici ..	.....	Rami pancreatici
Rami duodenales .	.....	Rami duodenales
.....	.....	Aa. retroduodenales**
A. gastroepiploica dextra	A. gastroepiploica dextra	A. gastroepiploica dextra*
Rami epiploici	.....	Rami epiploici
A. lienalis	A. lienalis	A. lienalis
Rami pancreatici	Rami pancreatici	Rami pancreatici
.....	.....	A. pancreatica dorsalis**
.....	.....	A. pancreatica inferior**
.....	.....	A. pancreatica magna**
.....	.....	A. caudae pancreatis**
A. gastroepiploica sinistra	A. gastroepiploica sin.	A. gastroepiploica sinistra*
.....	.....	Rami epiploici
Aa. gastricae breves ...	Aa. gastricae breves ...	Aa. gastricae breves
Rami lienales	.....	Rami lienales
A. mesenterica superior	*A. mesenterica cranialis*	*A. mesenterica superior*
Aa. intestinales	.....	.....

BNA	JNA	PNA
A. pancreaticoduodenalis inferior	A. pancreaticoduodenalis caudalis	Aa. pancreaticoduodenales inferiores**
Aa. jejunales	Aa. jejunales	Aa. jejunales
Aa. ileae	Aa. ilicae	Aa. ilei
A. ileocolica	A. iliocolica	A. ileocolica
.....	.....	A. ascendens**
.....	.....	A. cecalis anterior**
.....	.....	A. cecalis posterior**
A. appendicularis .	A. appendicularis .	A. appendicularis*
A. colica dextra	A. colica dextra	A. colica dextra
A. colica media	A. colica media	A. colica media
A. mesenterica inferior	*A. mesenterica caudalis*	*A. mesenterica inferior*
A. colica sinistra	A. colica sinistra	A. colica sinistra
Aa. sigmoideae	Aa. sigmoideae	Aa. sigmoideae
A. haemorrhoidalis sup.	A. rectalis cranialis ...	A. rectalis superior
A. suprarenalis media	*A. suprarenalis*	*A. suprarenalis media*
A. renalis	*A. renalis*	*A. renalis*
.....	.....	Rr. ureterici
A. suprarenalis inferior	Rami suprarenales (a. renalis)	A. suprarenalis inferior
.....	.....	Ramus anterior**
		A. segmenti superioris**
		A. segmenti anterioris superioris**
		A. segmenti anterioris inferioris**
		A. segmenti inferioris**
.....	.....	Ramus posterior**
		A. segmenti posterioris**
A. spermatica interna	*A. spermatica = A. testicularis*	.....

BNA	JNA	PNA
A. testicularis		*A. testicularis*
.....	.....	Rr. ureterici
A. ovarica	*A. ovarica*	*A. ovarica*
.....	.....	Rr. ureterici
A. ILIACA COMMUNIS	A. ILICA COMMUNIS	A. ILIACA COMMUNIS
A. HYPOGASTRICA	A. ILICA INTERNA	A. ILIACA INTERNA
RAMI PARIETALES	.....	.....
A. iliolumbalis	*A. iliolumbalis*	*A. iliolumbalis*
Ramus lumbalis	Ramus lumbalis	Ramus lumbalis
Ramus spinalis	Ramus spinalis	Ramus spinalis
Ramus iliacus	Ramus ilicus	Ramus iliacus
A. sacralis lateralis	*A. sacralis lateralis*	*Aa. sacrales laterales*
Rami spinales	Rami spinales	Rami spinales
A. obturatoria	*A. obturatoria*	*A. obturatoria*
Ramus pubicus	Ramus pubicus	Ramus pubicus
Ramus anterior	Ramus superficialis	Ramus anterior
Ramus posterior	Ramus profundus	Ramus posterior
A. acetabuli	Ramus acetabularis (a. obturatoriae)	Ramus acetabularis
A. glutaea superior	*A. glutaea cranialis*	*A. glutea superior*
Ramus superior	Ramus superficialis	Ramus superficialis
Ramus inferior	Ramus profundus	Ramus profundus
		Ramus superior
		Ramus inferior
A. glutaea inferior	*A. glutaea caudalis*	*A. glutea inferior*
A. comitans n. ischiadici	A. comitans n. ischiadici	A. comitans n. ischiadici
RAMI VISCERALES	.....	.....
A. umbilicalis	*A. umbilicalis*	*A. umbilicalis*
A. vesicalis superior	Aa. vesicales craniales ...	Aa. vesicales superiores
(Lig. umbilicale laterale) .	Chorda arteriae umbilicalis	Lig. umbilicale mediale**
Aa. vesicales inferiores	*Aa. vesicales caudales*	*A. vesicalis inferior*
A. deferentialis	*A. deferentialis*	*A. ductus deferentis*
.....	.....	Rr. ureterici

BNA	JNA	PNA
A. uterina	*A. uterina*	*A. uterina*
A. vaginalis	A. vaginalis	(A. vaginalis)**
Ramus ovarii	Ramus ovaricus	Ramus ovaricus
Ramus tubarius	Ramus tubalis	Ramus tubarius
.....	.....	*A. vaginalis***
A. haemorrhoidalis media	*A. rectalis caudalis*	*A. rectalis media*
A. pudenda interna	*A. pudendalis interna*	*A. pudenda interna*
A. haemorrhoidalis inferior	A. analis	A. rectalis inferior
A. perinei	A. perinealis	A. perinealis
Aa. scrotales posteriores	Aa. scrotales	Rr. scrotales posteriores
Aa. labiales posteriores	Aa. labiales	Rr. labiales posteriores
A. penis	A. penis	.....
A. bulbi urethrae	A. bulbi urethrae	A. bulbi penis
A. urethralis	A. urethralis	A. urethralis
A. bulbi vestibuli (vaginae)	A. bulbi vestibuli vaginae	A. bulbi vestibuli (vaginae)
A. profunda penis.....	A. profunda penis	A. profunda penis
A. dorsalis penis	A. dorsalis penis	A. dorsalis penis
A. clitoridis	A. clitoridis	.....
A. profunda clitoridis .	A. profunda clitoridis .	A. profunda clitoridis
A. dorsalis clitoridis ..	A. dorsalis clitoridis ..	A. dorsalis clitoridis
A. ILIACA EXTERNA	A. ILICA EXTERNA	A. ILIACA EXTERNA
A. epigastrica inferior	*A. epigastrica caudalis*	*A. epigastrica inferior*
.....	.....	(A. obturatoria accessoria)*
Ramus pubicus	Ramus pubicus	Ramus pubicus
Ramus obturatorius	Ramus obturatorius	Ramus obturatorius
A. spermatica externa .	A. m. cremasteris	A. cremasterica
A. lig. teretis uteri	A. chordae uteroinguinalis	A. lig. teretis uteri
A. circumflexa ilium profunda	*A. circumflexa ilium profunda*	*A. circumflexa ilium profunda*
		R. ascendens

BNA	JNA	PNA
A. FEMORALIS	A. FEMORALIS	A. FEMORALIS
A. epigastrica superficialis	A. epigastrica superfic. ..	A. epigastrica superficialis
A. circumflexa ilium superficialis	A. circumflexa ilium superficialis	A. circumflexa ilium superficialis
Aa. pudendae externae ..	Aa. pudendales externae .	Aa. pudendae externae
Aa. scrotales anteriores	Rami scrotales	Rr. scrotales anteriores
Aa. labiales anteriores .	Rami labiales	Rr. labiales anteriores
Rami inguinales	Rami inguinales	Rami inguinales
A. profunda femoris	*A. profunda femoris*	*A. profunda femoris*
A. circumflexa femoris medialis	A. circumflexa femoris tibialis	A. circumflexa femoris medialis .....
Ramus superficialis ..	Ramus superficialis ..	Ramus profundus
Ramus profundus ...	Ramus profundus ...	Ramus acetabularis
Ramus acetabuli ...	Ramus acetabularis .	Ramus ascendens
.....	.....	Ramus transversus
.....	.....	
A. circumflexa femoris lateralis	A. circumflexa femoris fibularis	A. circumflexa femoris lateralis
Ramus ascendens ...	Ramus ascendens ...	Ramus ascendens
Ramus descendens ..	Ramus descendens ..	Ramus descendens
.....	.....	Ramus transversus
A. nutricia femoris superior	A. nutricia femoris proximalis	.....
A. perforans prima ...	A. perforans prima ..	Aa. perforantes
A. perforans secunda ..	A. perforans secunda .	
A. perforans tertia ...	A. perforans tertia ..	
A. nutricia femoris inf.	A. nutricia femoris distalis	.....
Rami musculares	.....	.....
A. genu suprema	A. genus descendens	A. genus descendens*
Rami musculares	.....	.....
Ramus saphenus	Ramus saphenus	Ramus saphenus
Rami articulares	Rami articulares	Rr. articulares

BNA	JNA	PNA
A. POPLITEA	A. POPLITEA	A. POPLITEA
A. genu superior lateralis	A. genus proximalis fibularis	A. genus sup. lateralis*
A. genu superior medialis	A. genus proximalis tibialis	A. genus sup. medialis*
A. genu media	A. genus media	A. genus media*
A. genu inferior lateralis	A. genus distalis fibularis	A. genus inferior lateralis*
A. genu inferior medialis	A. genus distalis tibialis	A. genus inferior medialis*
Aa. surales	Aa. surales	Aa. surales
Rete articulare genu	Rete articulare genus	Rete articulare genus*
Rete patellae	Rete patellae	Rete patellae
A. TIBIALIS ANTERIOR	A. TIBIALIS ANTERIOR	A. TIBIALIS ANTERIOR
(A. recurrens tibialis posterior)	A. recurrens tibialis post.	(A. recurrens tibialis posterior)
A. recurrens tibialis anterior	A. recurrens tibialis anterior	A. recurrens tibialis anterior
A. malleolaris anterior lat.	A. malleolaris fibularis ant.	A. malleolaris anterior lat.
A. malleolaris anterior medialis	A. malleolaris tibialis anterior	A. malleolaris ant. med.
Rete malleolare mediale	Rete malleolare tibiale	Rete malleolare mediale
Rete malleolare laterale	Rete malleolare fibulare	Rete malleolare laterale
A. DORSALIS PEDIS	A. DORSALIS PEDIS	A. DORSALIS PEDIS
A. tarsea lateralis	A. tarsea fibularis	A. tarsea lateralis
Aa. tarseae mediales	Aa. tarseae tibiales	Aa. tarseae mediales
A. arcuata	A. arcuata	A. arcuata
Aa. metatarseae dorsales	Aa. metatarseae dorsales	Aa. metatarseae dorsales
Aa. digitales dorsales	Aa. digitales dorsales	Aa. digitales dorsales
Ramus plantaris prof.	A. metatarsea perforans	Ramus plantaris prof.
Rete dorsale pedis	Rete dorsale pedis	.....
A. TIBIALIS POSTERIOR	A. TIBIALIS POSTERIOR	A. TIBIALIS POSTERIOR
Ramus fibularis	Ramus fibularis	R. circumflexus fibulae

BNA	JNA	PNA
A. peronaea	*A. fibularis*	*A. peronea (fibularis)*
A. nutricia fibulae	A. nutricia fibulae	.....
Ramus perforans	Ramus perforans	R. perforans
Ramus communicans ..	Ramus communicans ..	R. communicans
A. malleolaris posterior lateralis	A. malleolaris fibularis posterior	Rr. malleolares laterales
Rami calcanei laterales	Rami calcaneares fibulares	Rr. calcanei
A. nutricia tibiae	Arteria nutricia tibiae ...	.....
A. malleolaris posterior medialis	A. malleolaris tibialis posterior	Rr. malleolares mediales
Rami calcanei mediales ..	Rami calcaneares tibiales	Rr. calcanei
Rete calcaneum	Rete calcaneare	Rete calcaneum
A. plantaris medialis	*A. plantaris tibialis*	*A. plantaris medialis*
Ramus profundus	Ramus profundus	Ramus profundus
Ramus superficialis	Ramus superficialis	Ramus superficialis
A. plantaris lateralis	*A. plantaris fibularis*	*A. plantaris lateralis*
.....	R. superficialis (a. plantaris fibularis)	.....
Arcus plantaris	Arcus plantaris	Arcus plantaris
Aa. metatarseae plantares	Aa. metatarseae plantares	Aa. metatarseae plantares
Rami perforantes	Rami perforantes	Rami perforantes
Aa. digitales plantares .	Aa. digitales plantares .	Aa. digitales plantares communes
		Aa. digitales plantares propriae*
VENAE	VENAE	VENAE
VENAE PULMONALES	VENAE PULMONALES	VENAE PULMONALES
Vv. pulmonales dextrae ..	Vv. pulmonales dextrae ..	(Vv. pulmonales dextrae)***
Vv. pulmonales sinistrae .	Vv. pulmonales sinistrae .	(Vv. pulmonales sinistrae)***

BNA	JNA	PNA
VV. CORDIS	VV. CORDIS	VV. CORDIS
Sinus coronarius	Sinus coronarius	Sinus coronarius
V. cordis magna	V. cordis magna	V. cordis magna
V. posterior ventriculi sinistri	V. dorsalis ventriculi sin.	V. posterior ventriculi sin.
V. obliqua atrii sinistri (Marschalli)	V. obliqua atrii sinistri .	V. obliqua atrii sinistri
.....	Plica v. cavae cranialis (sinistrae)	Plica v. cavae sinistrae
V. cordis media	V. interventricularis dorsalis cordis	V. cordis media
V. cordis parva	V. cordis parva	V. cordis parva
Vv. cordis anteriores	Vv. cordis ventrales	Vv. cordis anteriores
Vv. cordis minimae	Vv. cordis minimae	Vv. cordis minimae
VENA CAVA SUPERIOR	*VENA CAVA CRANIALIS*	*VENA CAVA SUPERIOR*
VV. ANONYMAE DEXTRA ET SINISTRA	V. BRACHIOCEPHALICA DEXTRA ET SINISTRA	VV. BRACHIOCEPHALICAE (DEXTRA ET SINISTRA)
Plexus thyreoideus impar	Plexus thyreoideus impar	Plexus thyroideus impar*
Vv. thyreoideae inferiores	Vv. thyreoideae caudales .	V. thyroidea inferior*
V. thyreoidea ima	Vv. thyreoideae imae	.....
V. laryngea inferior	V. laryngica caudalis ...	V. laryngea inferior
Vv. thymicae	Vv. thymicae	Vv. thymicae
Vv. pericardiacae	Vv. pericardiacae	Vv. pericardiacae
Vv. phrenicae superiores .	Vv. phrenicae thoracicae	Vv. pericardiacophrenicae
Vv. mediastinales anteriores	Vv. mediastinales ventrales	Vv. mediastinales
Vv. bronchiales anteriores	Vv. bronchales ventrales .	Vv. bronchiales
Vv. tracheales	Vv. tracheales	Vv. tracheales
Vv. oesophageae	Vv. oesophagicae	Vv. esophageae*
V. vertebralis	V. vertebralis	V. vertebralis
.....	.....	V. vertebralis anterior
.....	Plexus venosus suboccipitalis	V. vertebralis accessoria
		Plexus venosus suboccipitalis
V. cervicalis profunda ..	V. cervicalis profunda ..	V. cervicalis profunda
V. mammaria interna ...	V. thoracica interna	Vv. thoracicae internae

BNA	JNA	PNA
Vv. subcutaneae abdominis	Vv. subcutaneae abdominis	Vv. subcutaneae abdominis
.....	.....	Vv. musculophrenicae*
V. epigastrica superior	V. epigastrica cranialis	Vv. epigastricae superiores
.....	.....	Vv. intercostales anteriores*
V. intercostalis suprema .	V. intercostalis suprema .	V. intercostalis suprema
.....	.....	V. intercostalis superior sinistra*
V. JUGULARIS INTERNA	V. JUGULARIS INTERNA	V. JUGULARIS INTERNA
Bulbus venae jugularis superior	Bulbus cranialis v. jugularis	Bulbus v. jugularis sup.
V. canaliculi cochleae ...	V. canaliculi cochleae ...	V. canaliculi cochleae
Plexus pharyngeus	Plexus pharyngicus .... / Plexus pharyngooesophagicus dorsalis .... / Plexus pharyngooesophagicus ventralis ..	Plexus pharyngeus
Vv. pharyngeae	Vv. pharyngicae	Vv. pharyngeae
Vv. meningeae	Vv. meningicae	Vv. meningeae
V. canalis pterygoidei (Vidii)	Vv. canalis pterygoidei ..	V. canalis pterygoidei
V. lingualis	V. lingualis	V. lingualis
.....	.....	V. profunda linguae
Vv. dorsales linguae	Vv. dorsales linguae	Vv. dorsales linguae
V. sublingualis	V. sublingualis	V. sublingualis
V. comitans n. hypoglossi	V. comitans nervi hypoglossi	V. comitans n. hypoglossi
(Vv. thyreoideae superiores)	.....	V. thyroidea superior*
.....	.....	Vv. thyroideae mediae*
V. sternocleidomastoidea .	V. sternocleidomastoidea .	V. sternocleidomastoidea
V. laryngea superior	V. laryngica cranialis	V. laryngea superior
Bulbus v. jugularis inf. .	Bulbus valvularis v. jugularis internae	Bulbus venae jugularis inferior

BNA	JNA	PNA
V. facialis communis *V. facialis anterior*	*V. facialis*	*V. facialis*
V. angularis	V. angularis	V. angularis
Vv. frontales	Vv. frontales	Vv. supratrochleares
V. supraorbitalis		V. supraorbitalis
Vv. palpebrales superiores Vv. nasales externae	Vv. palpebrales superiores Vv. nasales externae	Vv. palpebrales superiores Vv. nasales externae
Vv. palpebrales inferiores	Vv. palpebrales inferiores	Vv. palpebrales inferiores
V. labialis superior	V. labialis maxillaris	V. labialis superior
V. labialis inferior	V. labialis mandibularis	Vv. labiales inferiores
Vv. massetericae	Vv. massetericae	
		V. faciei profunda
Vv. parotideae anteriores	Rami parotidici	Rami parotidei
V. palatina	V. palatina	V. palatina externa
V. submentalis	V. submentalis	V. submentalis
V. facialis posterior	*V. retromandibularis*	*V. retromandibularis*
Vv. temporales superficiales	Vv. temporales superficiales	Vv. temporales superficiales
Vv. auriculares anteriores	Vv. praeauriculares	Vv. auriculares anteriores**
	Rami parotidici	
Vv. parotideae posteriores		Vv. parotideae
Vv. articulares mandibulae	Vv. articulares mandibulae	Vv. articulares temporomandibulares*
	Vv. nasales internae	
Vv. tympanicae	Vv. tympanicae	Vv. tympanicae
V. stylomastoidea	V. stylomastoidea	V. stylomastoidea
V. transversa faciei	V. transversa faciei	V. transversa faciei
V. temporalis media	V. temporalis media	V. temporalis media
		Vv. maxillares
Plexus pterygoideus	*Plexus pterygoideus*	*Plexus pterygoideus*
Vv. meningeae mediae	Vv. meningicae mediae	Vv. meningeae mediae

BNA	JNA	PNA
Vv. temporales profundae	Vv. temporales profundae	Vv. temporales profundae .....
V. thyreoidea superior .	V. thyreoidea cranialis	
V. JUGULARIS EXTERNA	V. JUGULARIS SUPERFICIALIS DORSALIS	V. JUGULARIS EXTERNA
.....	Vv. jugulares superficiales	.....
V. occipitalis	V. occipitalis	V. occipitalis
V. auricularis posterior .	V. retroauricularis	V. auricularis posterior
V. jugularis anterior	V. jugularis superficialis ventralis	V. jugularis anterior
Arcus venosus juguli ..	Arcus venosus juguli ..	Arcus venosus juguli
(V. mediana colli) ..	var. V. mediana colli	.....
V. transversa scapulae ...	V. suprascapularis	V. suprascapularis
Vv. transversae colli	Vv. transversae colli	Vv. transversae colli
V. SUBCLAVIA	V. SUBCLAVIA	V. SUBCLAVIA
.....	.....	Vv. pectorales**
.....	.....	V. scapularis dorsalis**
V. thoracoacromialis	.....	(V. thoracoacromialis)*
V. AXILLARIS	V. AXILLARIS	V. AXILLARIS
V. thoracalis lateralis	V. thoracica lateralis	V. thoracica lateralis*
Vv. costoaxillares	Vv. costoaxillares	.....
Vv. thoracoepigastricae ..	Vv. thoracoepigastricae ..	Vv. thoracoepigastricae*
Plexus venosus mamillae .	Plexus venosus mamillae .	Plexus venosus areolaris
Vv. brachiales	Vv. brachiales	Vv. brachiales*
Vv. radiales	Vv. radiales	Vv. radiales*
Vv. ulnares	Vv. ulnares	Vv. ulnares*
V. cephalica	V. cephalica	V. cephalica
V. thoracoacromialis	.....	V. thoracoacromialis*
V. cephalica accessoria	V. cephalica accessoria	(V. cephalica accessoria)
V. basilica	V. basilica	V. basilica
V. mediana cubiti	V. mediana cubiti	V. mediana cubiti
(V. mediana antibrachii)	V. mediana antebrachii	(V. mediana antebrachii)
(V. mediana basilica) ..	V. mediana basilica ...	(V. mediana basilica)
(V. mediana cephalica)	V. mediana cephalica .	(V. mediana cephalica)

BNA	JNA	PNA
Rete venosum dorsale manus	Rete venosum dorsale manus	Rete venosum dorsale manus
Vv. intercapitulares	Vv. intercapitulares	Vv. intercapitales
Arcus volaris venosus superficialis	Arcus volaris venosus superficialis	Arcus venosus palmaris superficialis
Arcus volaris venosus profundus	Arcus volaris venosus profundus	Arcus venosus palmaris profundus
Vv. digitales volares communes		Vv. digitales palmares
Vv. digitales volares propriae	Vv. digitales volares propriae	
Vv. metacarpeae volares	Vv. metacarpicae volares	Vv. metacarpeae palmares
Vv. metacarpeae dorsales	Vv. metacarpicae dors.	Vv. metacarpeae dorsales
Arcus venosi digitales	Arcus venosi digitales	

SINUS DURAE MATRIS	SINUS DURAE MATRIS	SINUS DURAE MATRIS
	Lacunae laterales sinuum	Lacunae laterales*
	Sinus sigmoides	Sinus sigmoideus
Sinus transversus	Sinus transversus	Sinus transversus
Confluens sinuum	Confluens sinuum	Confluens sinuum
Vv. auditivae internae	Vv. labyrinthi	Vv. labyrinthi
Sinus occipitalis	Sinus occipitalis	Sinus occipitalis
Plexus basilaris	Plexus basialis	Plexus basilaris
Sinus sagittalis superior	Sinus sagittalis superior	Sinus sagittalis superior
Sinus sagittalis inferior	Sinus sagittalis inferior	Sinus sagittalis inferior
Sinus rectus	Sinus rectus	Sinus rectus
Sinus petrosus inferior	Sinus petrosus inferior	Sinus petrosus inferior
Sinus petrosus superior	Sinus petrosus superior	Sinus petrosus superior
Sinus cavernosus	Sinus cavernosus	Sinus cavernosus

BNA	JNA	PNA
Sinus intercavernosus anterior Sinus intercavernosus posterior	Sinus intercavernosi ...	Sinus intercavernosi
Sinus circularis	.....	.....
Sinus sphenoparietalis ...	Sinus sphenoparietalis ...	Sinus sphenoparietalis
VENAE DIPLOICAE	VENAE DIPLOICAE	VENAE DIPLOICAE
V. diploica frontalis	V. diploica frontalis	V. diploica frontalis
V. diploica temporalis anterior V. diploica temporalis posterior	Vv. diploicae temporales .	V. diploica temporalis anterior V. diploica temporalis posterior
V. diploica occipitalis ...	V. diploica occipitalis ...	V. diploica occipitalis
EMISSARIA°	EMISSARIA°	VV. EMISSARIAE
Emissarium parietale	Emissarium parietale	V. emissaria parietalis
Emissarium mastoideum .	Emissarium mastoideum .	V. emissaria mastoidea
Emissarium condyloideum	Emissarium condylicum ..	V. emissaria condylaris*
Emissarium occipitale ...	Emissarium occipitale ...	V. emissaria occipitalis
Rete canalis hypoglossi ..	Rete canalis nervi hypoglossi	Plexus venosus canalis hypoglossi
Rete foraminis ovalis	Rete foraminis ovalis	Plexus venosus foraminis ovalis
Plexus venosus caroticus internus	Plexus venosus caroticus internus	Plexus venosus caroticus internus
VENAE CEREBRI	VENAE ENCEPHALI	VENAE CEREBRI
Vv. cerebri superiores ...	Vv. cerebrales superiores	Vv. cerebri superiores
Vv. cerebri inferiores	Vv. cerebrales inferiores .	Vv. cerebri inferiores
V. cerebri media	V. cerebralis media ...	V. cerebri media superficialis V. anastomotica inferior V. anastomotica superior
Vv. cerebelli superiores .	Vv. cerebellares superiores	Vv. cerebelli superiores
Vv. cerebelli inferiores ...	Vv. cerebellares inferiores	Vv. cerebelli inferiores
Vv. cerebri internae	Vv. cerebrales internae ..	Vv. cerebri internae

BNA	JNA	PNA
V. cerebri magna (Galeni)	V. cerebralis magna	V. cerebri magna
V. septi pellucidi	V. septi pellucidi	V. septi pellucidi
V. terminalis	V. thalamostriata	V. thalamostriata
V. basalis (Rosenthali) ..	Vv. basiales	V. basalis
		V. cerebri media prof.
		V. cerebri anterior
		V. striata
V. chorioidea	V. chorioidea	V. choroidea*
V. ophthalmomeningea ..	var. V. ophthalmomeningica	.....
V. OPHTHALMICA SUPERIOR	V. OPHTHALMICA SUPERIOR	V. OPHTHALMICA SUPERIOR
V. nasofrontalis	V. nasofrontalis	V. nasofrontalis
V. ethmoidalis anterior .	V. ethmoidea anterior .	Vv. ethmoidales
V. ethmoidalis posterior .	V. ethmoidea posterior	
V. lacrimalis	V. lacrimalis	V. lacrimalis
Vv. musculares	Vv. musculares	.....
Vv. vorticosae	Vv. vorticosae = chorioideae majores	Vv. vorticosae (Vv. choroideae oculi)*
Vv. ciliares posteriores ..	Vv. chorioideae minores	Vv. ciliares
Vv. ciliares anteriores ...	Vv. ciliares	
.....	var. Plexus venosus sclerae	.....
V. centralis retinae	V. centralis retinae	V. centralis retinae
Vv. episclerales	Vv. episclerales	Vv. episclerales
Vv. palpebrales	Vv. palpebrales	Vv. palpebrales
Vv. conjunctivales anteriores	Vv. conjunctivales	Vv. conjunctivales
Vv. conjunctivales posteriores		
V. ophthalmica inferior ..	var. V. ophthalmica inferior	V. ophthalmica inferior
V. AZYGOS	V. THORACICA LONGITUDINALIS DEXTRA	V. AZYGOS
V. hemiazygos	V. thoracica longitudinalis sinistra	V. hemiazygos
V. hemiazygos accessoria	V. thoracica longitudinalis sinistra accessoria	V. hemiazygos accessoria
.....	V. subcostalis	V. subcostalis
Vv. intercostales	Vv. intercostales	.....

BNA	JNA	PNA
Ramus dorsalis	Ramus dorsalis	Ramus dorsalis
Ramus spinalis	Ramus spinalis	R. spinalis
.....	.....	Vv. intercostales posteriores (IV – XI)
.....	.....	V. intercostalis superior dextra
Vv. oesophageae	Vv. oesophagicae	Vv. esophageae*
Vv. bronchiales post.	Vv. bronchales dorsales .	Vv. bronchiales
Vv. pericardiacae	Vv. pericardiacae	Vv. pericardiacae
.....	.....	Vv. mediastinales
.....	.....	Vv. phrenicae superiores*
.....	Vv. thoracicae longitudinales	.....
V. lumbalis ascendens ..	V. lumbalis ascendens ..	V. lumbalis ascendens
		Vv. lumbales (I et II)
Vv. basivertebrales	Vv. basivertebrales	Vv. basivertebrales
Plexus venosi vertebrales externi	Plexus venosi vertebrales externi	Plexus venosi vertebrales externi (ant. et post.)
Plexus venosi vertebrales anteriores	Plexus venosi vertebrales ventrales	.....
Plexus venosi vertebrales posteriores	Plexus venosi vertebrales dorsales	.....
Plexus venosi vertebrales interni	Plexus venosi vertebrales interni	Plexus venosi vertebrales interni (ant. et post.)
Retia venosa vertebrarum	.....	.....
Sinus vertebrales longitudinales	.....	.....
Vv. intervertebrales	Vv. intervertebrales	V. intervertebralis
Vv. spinales externae anteriores	Vv. spinales externae ventrales	Vv. spinales
Vv. spinales externae posteriores	Vv. spinales externae dorsales	
Vv. spinales internae	Vv. spinales internae ...	

BNA	JNA	PNA
V. CAVA INFERIOR	*V. CAVA CAUDALIS*	*V. CAVA INFERIOR*
RADICES PARIETALES	.....	.....
V. phrenica inferior	V. phrenica abdominalis .	Vv. phrenicae inferiores*
Vv. lumbales	Vv. lumbales	Vv. lumbales (III et IV)
RADICES VISCERALES	.....	.....
Vv. hepaticae	Vv. hepaticae	Vv. hepaticae Vv. hepaticae dextrae** Vv. hepaticae mediae** Vv. hepaticae sinistrae**
V. centralis (glandulae suprarenalis)	.....	.....
Vv. renales	Vv. renales	Vv. renales
Vv. suprarenales	V. suprarenalis dextra . V. suprarenalis sinistra .	V. suprarenalis dextra V. suprarenalis sinistra
V. spermatica	V. spermatica (testicularis) dextra ..... V. spermatica (testicularis) sinistra	V. testicularis dextra V. testicularis sinistra
V. testicularis	.....	V. testicularis dextra V. testicularis sinistra
V. ovarica	V. ovarica dextra ..... V. ovarica sinistra	V. ovarica dextra V. ovarica sinistra
Plexus pampiniformis	Plexus pampiniformis	Plexus pampiniformis
V. PORTAE	V. PORTAE	V. PORTAE
.....	R. dexter	R. dexter**
.....	.....	R. anterior**
.....	.....	R. posterior**
.....	R. sinister	R. sinister**
.....	.....	Pars transversa**
.....	.....	Rr. caudati**
.....	.....	Pars umbilicalis**
Ductus venosus (Arantii)	Ductus venosus	(Ductus venosus)**
.....	.....	Lig. venosum**
.....	.....	Rr. laterales**
V. umbilicalis	V. umbilicalis	(V. umbilicalis sinistra)**
.....	.....	Lig. teres hepatis**
.....	.....	Rr. mediales**

BNA	JNA	PNA
V. coronaria ventriculi ..	V. coronaria ventriculi ..	V. gastrica dextra V. gastrica sinistra V. prepylorica
V. mesenterica superior ..	V. mesenterica cranialis .	V. mesenterica superior
Vv. intestinales	Vv. intestinales	Vv. jejunales et ilei
V. gastroepiploica dextra	V. gastroepiploica dext.	V. gastroepiploica dextra*
Vv. pancreaticae	Vv. pancreaticae	Vv. pancreaticae
V. ileocolica	V. iliocolica	V. ileocolica
V. appendicularis	.....	V. appendicularis*
Vv. colicae dextrae	Vv. colicae dextrae	V. colica dextra
V. colica media	V. colica media	V. colica media
Vv. pancreaticoduodenales	Vv. pancreaticoduodenales	Vv. pancreaticoduodenales
Vv. duodenales	Vv. duodenales	.....
V. mesenterica inferior ..	V. mesenterica caudalis ..	V. mesenterica inferior
V. colica sinistra	V. colica sinistra	V. colica sinistra
Vv. sigmoideae	Vv. sigmoideae	Vv. sigmoideae
V. haemorrhoidalis superior	V. rectalis cranialis ...	V. rectalis superior
V. lienalis	V. lienalis	V. lienalis
Vv. gastricae breves ...	Vv. gastricae breves ...	Vv. gastricae breves
V. gastroepiploica sin. .	V. gastroepiploica sin. .	V. gastroepiploica sinistra*
.....	.....	Vv. pancreaticae
V. cystica	.....	V. cystica
Vv. parumbilicales (Sappeyi)	Vv. adumbilicales	Vv. paraumbilicales
V. ILIACA COMMUNIS	V. ILICA COMMUNIS	V. ILIACA COMMUNIS
V. sacralis media	V. sacralis media	V. sacralis mediana
.....	V. sacralis caudalis	.....
V. iliolumbalis	V. iliolumbalis	V. iliolumbalis
V. HYPOGASTRICA	V. ILICA INTERNA	V. ILIACA INTERNA
Vv. glutaeae superiores .	Vv. glutaeae craniales ...	Vv. gluteae superiores
Vv. glutaeae inferiores ...	Vv. glutaeae caudales ...	Vv. gluteae inferiores
Vv. obturatoriae	Vv. obturatoriae	Vv. obturatoriae

BNA	JNA	PNA
Vv. sacrales laterales	Vv. sacrales laterales	Vv. sacrales laterales
Plexus sacralis anterior ..	Plexus sacralis ventralis ..	Plexus venosus sacralis
Plexus haemorrhoidalis ..	Plexus rectalis	Plexus venosus rectalis
.....	.....	Vv. vesicales
Plexus vesicalis	Plexus vesicopudendalis (Plexus vesicalis et Plexus pudendalis)	Plexus venosus vesicalis
Plexus pudendalis	Plexus vesicopudendalis (Plexus vesicalis et Plexus pudendalis)	Plexus venosus prostaticus
V. dorsalis penis	V. dorsalis penis subfascialis	V. dorsalis penis profunda**
Vv. profundae penis	Vv. profundae penis	Vv. profundae penis
V. dorsalis clitoridis	V. dorsalis clitoridis subfascialis	V. dorsalis clitoridis profunda**
Vv. profundae clitoridis .	Vv. profundae clitoridis .	Vv. profundae clitoridis
Vv. uterinae	Vv. uterinae	Vv. uterinae
.....	.....	V. bulbi penis (vel vestibuli)
.....	.....	V. pudenda interna
.....	Vv. labiales	.....
.....	Plexus analis (venosus) ..	.....
Plexus uterovaginalis	Plexus uterovaginalis	Plexus venosus uterinus Plexus venosus vaginalis
V. haemorrhoidalis media	.....	Vv. rectales mediae
Vv. haemorrhoidales inferiores	Vv. anales	Vv. rectales inferiores
Vv. scrotales posteriores	Vv. scrotales	Vv. scrotales (vel labiales) posteriores
V. ILIACA EXTERNA	V. ILICA EXTERNA	V. ILIACA EXTERNA
V. epigastrica inferior ...	V. epigastrica caudalis ...	V. epigastrica inferior
V. circumflexa ilium profunda	V. circumflexa ilium profunda	V. circumflexa ilium prof.
V. FEMORALIS	V. FEMORALIS	V. FEMORALIS
Vv. dorsales penis subcutaneae	Vv. dorsales penis subcutaneae	Vv. dorsales penis (vel clitoridis) superficialis

BNA	JNA	PNA
Vv. scrotales anteriores ..	Rami scrotales	Vv. scrotales (vel labiales) anteriores
Vv. pudendae externae ..	Vv. pudendales externae	Vv. pudendae externae
.....	Rr. inguinales (vv. pudendales ext.)	.....
.....	Rr. labiales	.....
V. epigastrica superficialis	V. epigastrica superfic. ..	V. epigastrica superficialis
V. circumflexa ilium superficialis	V. circumflexa ilium superficialis	V. circumflexa ilium superficialis
V. saphena magna	V. saphena magna	V. saphena magna
V. saphena accessoria ...	V. saphena accessoria ...	V. saphena accessoria
Vv. circumflexae femoris mediales	Vv. circumflexae femoris tibiales	Vv. circumflexae femoris mediales
Vv. circumflexae femoris laterales	Vv. circumflexae femoris fibulares	Vv. circumflexae femoris laterales
Vv. comitantes	.....	.....
Vv. profundae femoris ..	Vv. profundae femoris ..	V. profunda femoris
Vv. perforantes	Vv. perforantes	Vv. perforantes
V. saphena parva	V. saphena parva	V. saphena parva
V. femoropoplitea	V. femoropoplitea	.....
Vv. peronaeae	Vv. fibulares	Vv. peroneae (fibulares)
Vv. popliteae	Vv. popliteae	V. poplitea
.....	.....	Vv. genus*
Vv. tibiales posteriores ..	Vv. tibiales posteriores ..	Vv. tibiales posteriores
Vv. tibiales anteriores ...	Vv. tibiales anteriores ...	Vv. tibiales anteriores
Rete venosum dorsale pedis	Rete venosum dorsale pedis	Rete venosum dorsale pedis
Arcus venosus dorsalis pedis	Arcus venosus dorsalis pedis	Arcus venosus dorsalis pedis
Vv. digitales communes pedis	Vv. digitales communes pedis	Vv. digitales dorsales pedis

BNA	JNA	PNA
Vv. metatarseae dorsales pedis	Vv. metatarseae dorsales pedis	Vv. metatarseae dorsales pedis
Vv. intercapitulares	Vv. intercapitulares	.....
Rete venosum plantare ..	Rete venosum plantare ..	Rete venosum plantare
Arcus venosus plantaris .	Arcus venosus plantaris .	Arcus venosus plantaris
Vv. metatarseae plantares	Vv. metatarseae plantares	Vv. metatarseae plantares
Vv. digitales pedis dorsales	Vv. digitales dorsales pedis	.....
Vv. digitales plantares ...	Vv. digitales plantares ...	Vv. digitales plantares
SYSTEMA LYMPHATICUM	VASA LYMPHACEA	SYSTEMA LYMPHATICUM
VASA LYMPHATICA	VASA LYMPHACEA°	VASA LYMPHATICA
Vasa lymphatica superficialia	.....	Vasa lymphatica superficialia
Vasa lymphatica profunda	.....	Vasa lymphatica profunda
DUCTUS THORACICUS	DUCTUS THORACICUS	DUCTUS THORACICUS
Truncus jugularis	Truncus jugularis	Truncus jugularis
Truncus subclavius	Truncus subclavius	Truncus subclavius
Truncus bronchomediastinalis (dexter)	Truncus bronchomediastinalis dexter	Truncus bronchomediastinalis
Ductus lymphaticus dexter	Truncus lymphaceus dexter	Ductus lymphaticus dexter (Ductus thoracicus dexter)
Trunci lumbales	Trunci lumbales	Trunci lumbales (dexter et sinister)
Truncus intestinalis	Truncus intestinalis	Trunci intestinales
Cisterna chyli	Cisterna chyli	Cisterna chyli
LYMPHOGLANDULA	LYMPHONODUS	NODI LYMPHATICI (LYMPHONODI)**
Vasa afferentia	Vasa afferentia	Vasa afferentia
Vasa efferentia	Vasa efferentia	Vasa efferentia
Substantia corticalis	Substantia corticalis	Cortex
Substantia medullaris	Substantia medullaris	Medulla

BNA	JNA	PNA
.....	Lymphocentrum	.....
Hilus	Hilus	Hilus
Nodulus lymphaticus ...	Lymphonodulus	Folliculus lymphaticus
.....	Haemolymphonodus	.....
Lymphoglandulae capitis°		
Lymphoglandulae occipitales	Lymphonodi occipitales ..	Nodi lymphatici occipitales
Lymphoglandulae auriculares posteriores	Lymphonodi retroauriculares	Nodi lymphatici retroauriculares
Lymphoglandulae auriculares anteriores	.....	.....
Lymphoglandulae parotideae	Lymphonodi parotidici ..	Nodi lymphatici parotidei superficiales et profundi
Lymphoglandulae colli°		
.....	.....	Nodi lymphatici mandibulares
.....	Lymphonodi submentales	Nodi lymphatici submentales
Lymphoglandulae submaxillares	Lymphonodi submandibulares	Nodi lymphatici submandibulares
Lymphoglandulae faciales profundae	Lymphonodi faciales profundi	Nodi lymphh. buccales
Lymphoglandulae cervicales superficiales	Lymphonodi cervicales superficiales	Nodi lymphatici cervicales superficiales
Lymphoglandulae cervicales profundae superiores	Lymphonodi cervicales profundi craniales	Nodi lymphatici linguales Nodus lymphaticus jugulomohyoideus
Lymphoglandulae cervicales profundae inferiores	Lymphonodi cervicales profundi caudales	Nodi lymphatici cervicales profundi Nodus lymphaticus jugulodigastricus

BNA	JNA	PNA
Lymphoglandulae linguales	Lymphonodi linguales	Nodi lymphatici linguales
.....	Lymphonodi retropharyngici	Nodi lymphatici retropharyngei
Lymphoglandulae extremitatis superioris°		
Lymphoglandulae axillares	Lymphonodi axillares	Nodi lymphatici axillares
.....	.....	Nodi lymphatici apicales
.....	.....	Nodi lymphatici centrales
.....	.....	Nodi lymphatici laterales
Lymphoglandulae pectorales	Lymphonodi pectorales	Nodi lymphatici pectorales
Lymphoglandulae subscapulares	Lymphonodi subscapulares	Nodi lymphatici subscapulares
Lymphoglandulae epigastricae	Lymphonodi epigastrici	Nodi lymphh. epigastrici
Lymphoglandulae cubitales superficiales	Lymphonodi cubitales superficiales	Nodi lymphatici cubitales
Lymphoglandulae cubitales profundae	Lymphonodi cubitales profundi	
Lymphoglandulae thoracis°		
Lymphoglandulae tracheales	Lymphonodi tracheales	Nodi lymphh. tracheales
Lymphoglandulae bronchiales	Lymphonodi bronchales	.....
.....	Lymphonodi bronchopulmonales	Nodi lymphatici bronchopulmonales
.....	Lymphonodi tracheobronchales caudales	Nodi lymphatici tracheobronchiales inferiores

BNA	JNA	PNA
.....	Lymphonodi tracheobronchales craniales	Nodi lymphatici tracheobronchiales superiores
Noduli lymphatici bronchiales	Lymphonoduli bronchales	.....
Lymphoglandulae pulmonales	Lymphonodi pulmonales .	Nodi lymphatici pulmonales
.....	Lymphonodi praelaryngici	.....
Lymphoglandulae intercostales	Lymphonodi intercostales	Nodi lymphatici intercostales*
.....	.....	Nodi lymphatici phrenici
Lymphoglandulae mediastinales posteriores	Lymphonodi mediastinales dorsales	Nodi lymphatici mediastinales posteriores
Lymphoglandulae mediastinales anteriores	Lymphonodi mediastinales ventrales	Nodi lymphatici mediastinales anteriores
Lymphoglandulae sternales	Lymphonodi sternales ...	Nodi lymphatici parasternales*
Lymphoglandulae abdominales°		
Lymphoglandulae iliacae .	Lymphonodi ilici	Nodi lymphatici iliaci
Lymphoglandulae lumbales	Lymphonodi lumbales ..	Nodi lymphatici lumbales
Lymphoglandulae coeliacae	Lymphonodi coeliaci	Nodi lymphatici celiaci*
.....	.....	Nodi lymphatici pylorici
Lymphoglandulae gastricae superiores	Lymphonodi gastrici craniales	Nodi lymphatici gastrici sinistri
Lymphoglandulae gastricae inferiores	Lymphonodi gastrici caudales	Nodi lymphatici gastrici dextri

BNA	JNA	PNA
.....	.....	Nodi lymphatici gastroepiploici dextri**
.....	.....	Nodi lymphatici gastroepiploici sinistri**
Lymphoglandulae hepaticae	Lymphonodi hepatici	Nodi lymphatici hepatici
Lymphoglandulae pancreaticolienales	Lymphonodi pancreaticolienales	Nodi lymphatici pancreaticolienales
.....	.....	Nodi lymphatici pylorici**
Lymphoglandulae mesentericae	Lymphonodi mesosteniales	Nodi lymphatici mesenterici superiores**
Lymphoglandulae mesocolicae	Lymphonodi mesocolici ..	Nodi lymphatici mesenterici inferiores Nodi lymphatici ileocolici Nodi lymphatici colici dextri Nodi lymphatici colici medii Nodi lymphatici colici sinistri
Lymphoglandulae pelvis°		
.....	.....	Nodi lymphatici iliaci communes**
Lymphoglandulae hypogastricae	Lymphonodi ilici interni .	Nodi lymphatici iliaci interni
.....	.....	Nodi lymphatici iliaci externi**
Lymphoglandulae sacrales	Lymphonodi sacrales ...	Nodi lymphatici sacrales
.....	Lymphonodi anorectales	.....
Lymphoglandulae extremitatis inferioris°		
Lymphoglandulae inguinales	Lymphonodi subinguinales superficiales	.....

BNA	JNA	PNA
Lymphoglandulae subinguinales superficiales ..	Lymphonodi subinguinales superficiales	Nodi lymphatici inguinales superficiales
Lymphoglandulae subinguinales profundae ...	Lymphonodi subinguinales profundi	Nodi lymphatici inguinales profundi
Lymphoglandulae popliteae	Lymphonodi poplitei	Nodi lymphatici poplitei
(Lymphoglandula tibialis anterior)	Lymphonodus tibialis anterior	(Nodus lymphaticus tibialis anterior)
PLEXUS LYMPHATICI	.....	.....
Plexus jugularis	.....	.....
Plexus axillaris	.....	.....
Plexus mammarius	.....	.....
Plexus lumbalis	.....	.....
Plexus aorticus	.....	.....
Plexus sacralis medius ...	.....	.....
Plexus hypogastricus	.....	.....
Plexus coeliacus	.....	.....
Plexus iliacus externus ...	.....	.....
Plexus inguinalis	.....	.....

NEUROLOGIA

Neurologia	*Systema nervorum*	*Systema nervosum*
Nervus	Nervus	Nervus
.....	Radix	.....
Ganglion	Ganglion	Ganglion
Substantia alba	Substantia alba	Substantia alba
Substantia grisea	Substantia grisea	Substantia grisea
.....	Strata alba corticis	.....
Substantia gelatinosa ..	Substantia gelatinosa ..	Substantia gelatinosa
.....	Gyrus	.....
.....	Sulcus	.....
Taeniae telarum	Taenia telae	Tenia telae*
Ependyma ventriculorum .	Ependyma ventriculorum .	Ependyma
.....	.....	Lamina epithelialis*
Sulcus limitans ventriculorum	Sulcus limitans ventriculorum	Sulcus limitans
.....	.....	Lamina alaris
.....	.....	Lamina basalis
Nuclei nervorum cerebralium	Nuclei nervorum capitalium	Nuclei nervorum cranialium**
Nuclei originis	Nuclei originis	Nuclei originis
Nuclei terminales	Nuclei terminales	Nuclei terminationis
.....	Fasciculus	.....
.....	Fibra	.....
.....	Tractus	.....
Ramus communicans	Ramus communicans ...	Ramus communicans
Ramus anastomoticus ...	.....	
Ramus muscularis	Ramus muscularis	Ramus muscularis
Nervus cutaneus	Nervus cutaneus	Nervus cutaneus
Nervus articularis	Nervus articularis	Nervus articularis
.....	.....	Nervus vascularis

BNA	JNA	PNA
.....	.....	Plexus periarterialis
Plexus nervorum spinalium	Plexus nervorum spinalium	Plexus nervorum spinalium
.....	Filum	.....
.....	.....	Corpuscula nervosa terminalia
.....	.....	Terminationes nervorum liberae
SYSTEMA NERVORUM CENTRALE	SYSTEMA NERVORUM CENTRALE	SYSTEMA NERVOSUM CENTRALE
MEDULLA SPINALIS	MEDULLA SPINALIS	MEDULLA SPINALIS
Pars cervicalis	Pars cervicalis	Pars cervicalis
Intumescentia cervicalis	Intumescentia cervicalis	Intumescentia cervicalis
Pars thoracalis	Pars thoracica	Pars thoracica
Pars lumbalis	Pars lumbalis	Pars lumbalis
Intumescentia lumbalis	Intumescentia lumbalis	Intumescentia lumbalis
Conus medullaris	Conus medullaris	Conus medullaris
Filum terminale	Filum terminale	Filum terminale
Ventriculus terminalis ...	Ventriculus terminalis ...	Ventriculus terminalis
Fissura mediana anterior	Fissura mediana ventralis	Fissura mediana (anterior)**
Sulcus medianus posterior	Sulcus medianus dorsalis	Sulcus medianus (posterior)**
Sulcus lateralis anterior ..	Sulcus ventrolateralis ...	.....
Sulcus lateralis posterior .	Sulcus dorsolateralis	Sulcus lateralis posterior
(Sulcus intermedius posterior)	Sulcus intermedius dorsalis	Sulcus intermedius posterior
(Sulcus intermedius anterior)	Sulcus intermedius ventralis	.....
Funiculi medullae spinalis	Fasciculi medullae spinalis	Funiculi medullae spinalis
Funiculus anterior	Fasciculus ventralis	Funiculus anterior
Funiculus lateralis	Fasciculus lateralis	Funiculus lateralis
Funiculus posterior	Fasciculus dorsalis	Funiculus posterior
Sectiones medullae spinalis	.....	*Sectiones medullae spinalis****
Canalis centralis	Canalis centralis	Canalis centralis
.....	.....	Substantia alba*
.....	.....	Substantia grisea

BNA	JNA	PNA
.....	.....	Substantia intermedia lateralis
Substantia grisea centralis	Substantia grisea centralis	Substantia intermedia centralis
Substantia gelatinosa centralis	Substantia gelatinosa centralis	.....
Commissura anterior alba	Commissura ventralis alba	Commissura alba*
Commissura anterior grisea ..... Commissura posterior ..	Commissura grisea	.....
Columnae griseae	Columnae griseae	Columnae griseae
Columna anterior	Columna ventralis	Columna anterior
Columna lateralis	Columna lateralis	Columna lateralis
Columna posterior	Columna dorsalis	Columna posterior
.....	.....	Cornu anterius
.....	.....	Cornu laterale
.....	.....	Cornu posterius
Cervix columnae posterioris	Isthmus columnae dorsalis	.....
Apex columnae posterioris	Crista columnae dorsalis	Apex cornus post.*
Substantia gelatinosa (Rolandi)	Substantia gelatinosa dorsalis	Substantia gelatinosa
Nucleus dorsalis (Stillingi, Clarkii)	Nucleus dorsalis	Nucleus thoracicus*
Formatio reticularis	Formatio reticularis	Formatio reticularis
Funiculus anterior	Fasciculus ventralis	Funiculus anterior
		Tractus pyramidalis (corticospinalis) anterior**
		Tractus vestibulospinalis
		Tractus spinothalamicus anterior
		Fasciculi proprii
Fasciculus cerebrospinalis anterior (pyramidalis anterior)	Tractus cortico-spinalis ventralis	Tractus pyramidalis (corticospinalis) ant.**

BNA	JNA	PNA
Fasciculus anterior proprius (Flechsigi)	.....	Fasciculi proprii
Funiculus lateralis	Fasciculus lateralis	Funiculus lateralis
		Tractus pyramidalis (corticospinalis) lat.**
		Tractus spinocerebellaris anterior
		Tractus spinocerebellaris posterior
		Tractus spinotectalis
		Tractus tectospinalis
		Tractus spinothalamicus lateralis
		Tractus reticulospinalis
		Tractus rubrospinalis
		Tractus dorsolateralis
Fasciculus cerebrospinalis lateralis (pyramidalis lateralis)	Tractus cortico-spinalis lateralis	Tractus pyramidalis (corticospinalis) lateralis**
Fasciculus cerebellospinalis	Tractus spino-cerebellaris dorsalis	Tractus spinocerebellaris posterior
Fasciculus anterolateralis superficialis (Gowersi)	Tractus spino-cerebellaris ventralis	Tractus spinocerebellaris anterior
Fasciculus lateralis proprius (Flechsigi)	.....	Fasciculi proprii medullae spinalis (Fasciculi intersegmentales)
Funiculus posterior	Fasciculus dorsalis	Funiculus posterior
.....	Pars propria (fasc. dors. medull. spin.)	.....
Fasciculus gracilis (Golli)	Pars medialis (fasciculi dorsalis)	Fasciculus gracilis
Fasciculus cuneatus (Burdachi)	Pars lat. (fasciculi dors.)	Fasciculus cuneatus

BNA	JNA	PNA
ENCEPHALON	*ENCEPHALON*	*ENCEPHALON*
RHOMBENCEPHALON	RHOMBENCEPHALON	RHOMBENCEPHALON
.....	.....	METENCEPHALON*
MYELENCEPHALON	*MYELENCEPHALON*	*MYELENCEPHALON*
MEDULLA OBLONGATA	MEDULLA OBLONGATA	MEDULLA OBLONGATA
Fissura mediana anterior	Fissura mediana ventralis	Fissura mediana (anterior)**
Foramen caecum	Foramen caecum	.....
Pyramis (medullae oblongatae)	Pyramis medullae oblongatae	Pyramis (medullae oblongatae)
Decussatio pyramidum	Decussatio pyramidum	Decussatio pyramidum
Fissura mediana posterior	Sulcus medianus dorsalis	Sulcus medianus (post.)**
Sulcus lateralis anterior ..	Sulcus ventrolateralis ...	Sulcus lateralis anterior
Sulcus lateralis posterior .	Sulcus dorsolateralis	Sulcus lateralis posterior
Oliva	Oliva	Oliva
Corpus restiforme	Corpus restiforme = Crus medullo-cerebellare ...	Pedunculus cerebellaris inferior
Funiculus lateralis	Fasciculus lateralis	Funiculus lateralis
.....	Fasciculus dorsalis	.....
Funiculus cuneatus	Pars lateralis (fasciculi dorsalis)	Fasciculus cuneatus*
.....	Tuberculum partis lat. ...	Tuberculum nuclei cuneati
Tuberculum cinereum ...	Tuberculum cinereum ...	.....
Funiculus gracilis	Pars med. (fasciculi dors.)	Fasciculus gracilis*
Clava	Clava	Tuberculum nuclei gracilis
Fibrae arcuatae externae .	Fibrae arcuatae externae .	Fibrae arcuatae externae
Sectiones medullae oblongatae	.....	*Sectiones medullae oblongatae****
Raphe	Rhaphe	Raphe
.....	.....	Tegmentum rhombencephali
Stratum nucleare	.....	.....
.....	Nucleus originis dorsalis (parasympathicus) n. vagi	Nucleus dorsalis n. vagi

BNA	JNA	PNA
.....	Nucleus originis salivatorius medullae oblongatae = Nucleus originis accessorius n. glossopharyngici	.....
Nucleus n. hypoglossi ...	Nucleus originis nervi hypoglossi	Nucleus n. hypoglossi
Nucleus ambiguus	Nucleus ambiguus = Nucleus originis ventralis nervi glossopharyngici et nervi vagi	Nucleus ambiguus
.....	.....	Nucleus dorsalis n. glossopharyngei*
Nucleus alae cinereae ...	Nucleus terminalis alae cinereae = Nucleus terminalis nervi glossopharyngici et nervi vagi	Nucleus dorsalis n. vagi
Tractus solitarius	Fasciculus solitarius	Tractus solitarius
Nucleus tractus solitarii .	Nucleus tractus solitarii = Nucleus terminalis nervi intermedii et nucleus terminalis accessorius nervi glossopharyngici	Nucleus tractus solitarii
.....	Nucleus originis n. accessorii	.....
Tractus spinalis n. trigemini	.....	Tractus spinalis n. trigemini
Nucleus tractus spinalis n. trigemini	Nucleus terminalis tractus spinalis nervi trigemini	Nucleus tractus spinalis n. trigemini
Nucleus funiculi gracilis .	Nucleus partis medialis fasciculi dorsalis	Nucleus gracilis
Nucleus funiculi cuneati .	Nucleus partis lateralis fasciculi dorsalis	Nucleus cuneatus
.....	.....	Nucleus intercalatus
Nuclei laterales	.....	Nucleus lateralis
Nuclei laterales	.....	Nucleus cuneatus accessorius
Nucleus olivaris inferior .	Nucleus olivae	Nucleus olivaris
Hilus nuclei olivaris ...	Hilus nuclei olivae ...	Hilus nuclei olivaris

BNA	JNA	PNA
Nucleus olivaris accessorius medialis	Nucleus olivaris accessorius medialis	Nucleus olivaris accessorius medialis
Nucleus olivaris accessorius dorsalis	Nucleus olivaris accessorius dorsalis	Nucleus olivaris accessorius dorsalis
Nuclei arcuati	Nuclei arcuati	Nuclei arcuati
Fibrae arcuatae internae .	Fibrae arcuatae internae .	Fibrae arcuatae internae
Substantia reticularis grisea	Substantia reticularis grisea	Formatio reticularis*
Substantia reticularis alba	Substantia reticularis alba	
Fasciculus longitudinalis medialis	Tractus longitud. med. ..	Fasciculus longitud. med.
.....	.....	Fasciculus longitudinalis dorsalis**
Stratum interolivare lemnisci	Stratum interolivare lemnisci	.....
.....	.....	Lemniscus medialis*
Decussatio lemniscorum .	Decussatio lemniscorum .	Decussatio lemniscorum
Corpus restiforme	Corpus restiforme = Crus medullo-cerebellare ...	Pedunculus cerebellaris inf.
Fasciculi corporis restiformis	.....	.....
Fibrae arcuatae externae .	Fibrae arcuatae externae	Fibrae arcuatae externae
.....	Fibrae arcuatae externae ventrales	.....
.....	Fibrae arcuatae externae dorsales	.....
Fibrae cerebelloolivares ..	Tractus olivocerebellares ..	Tractus olivocerebellaris
Fasciculi pyramidales	Fasciculi pyramidici = Tractus corticospinalis .	Tractus pyramidalis**
		Fibrae corticonucleares**
		Fibrae corticospinales**
VENTRICULUS QUARTUS	VENTRICULUS QUARTUS	VENTRICULUS QUARTUS
Fossa rhomboidea	Fossa rhomboides	Fossa rhomboidea
.....	.....	Sulcus medianus

BNA	JNA	PNA
Pars inferior fossae rhomboideae (Calamus scriptorius)	Calamus scriptorius ...	.....
Pars superior fossae rhomboideae	.....	.....
Pars intermedia fossae rhomboideae	.....	.....
Recessus lateralis fossae rhomboideae	Recessus lateralis ventriculi quarti	Recessus lateralis ventriculi quarti
Sulcus limitans (fossae rhomboideae)	Sulcus limitans fossae rhomboidis	Sulcus limitans
Fovea inferior	Fovea caudalis	Fovea inferior
Fovea superior	Fovea rostralis	Fovea superior
Trigonum n. hypoglossi .	Trigonum n. hypoglossi .	Trigonum n. hypoglossi
Striae medullares	Striae medullares	Striae medullares ventriculi quarti
Area acustica	Area vestibularis	Area vestibularis
Eminentia medialis	Eminentia medialis	Eminentia medialis
Colliculus facialis	Colliculus facialis	Colliculus facialis
Ala cinerea	Ala cinerea	Trigonum n. vagi
.....	Area postrema	.....
Locus caeruleus	Locus caeruleus	Locus ceruleus*
Tegmen ventriculi quarti	(Tegmen ventriculi quarti)	Tegmen ventriculi quarti
Velum medullare posterius	Velum medullare post. ..	Velum medullare inferius*
Velum medullare anterius	Velum medullare anterius	Velum medullare superius*
Frenulum veli medullaris ant.	Frenulum veli medullaris ant.	Frenulum veli medullaris superioris
Taenia ventriculi quarti ..	Taenia rhombencephali ..	Tenia ventriculi quarti*
Obex	Obex	Obex
.....	.....	Tela choroidea ventriculi quarti*
Lamina chorioidea epithelialis	Lamina tectoria ventriculi quarti	.....
(Apertura medialis ventriculi quarti [Foramen Magendii])	Apertura mediana rhombencephali	Apertura mediana ventriculi quarti

BNA	JNA	PNA
(Apertura lateralis ventriculi quarti)	Apertura lateralis rhombencephali	Apertura lateralis ventriculi quarti
Fastigium	Fastigium	.....
(Calamus scriptorius)	Calamus scriptorius	.....
METENCEPHALON	*METENCEPHALON*	*METENCEPHALON*
PONS (VAROLI)	PONS	PONS
Sulcus basilaris pontis ...	Sulcus medianus	Sulcus basilaris
Fasciculus obliquus (pontis)	Fasciculus obl. pontis ...	.....
(Fila lateralia pontis)	Fila lateralia pontis	.....
Brachium pontis	Brachium pontis = Crus ponto-cerebellare	Pedunculus cerebellaris medius
Sectiones pontis	.....	*Sectiones pontis***
Pars dorsalis pontis	Pars dorsalis pontis	Pars dorsalis pontis
Raphe	Rhaphe	Raphe
Formatio reticularis ...	Formatio reticularis ...	Formatio reticularis
Corpus trapezoideum ..	Corpus trapezoides	Corpus trapezoideum
Lemniscus	.....	.....
Lemniscus medialis (sensitivus)	Lemniscus medialis ..	Lemniscus medialis
.....	.....	Lemniscus spinalis**
.....	.....	Lemniscus trigeminalis**
Lemniscus lateralis (acusticus)	Lemniscus lateralis .	Lemniscus lateralis
Nucleus n. abducentis	Nucleus originis n. abducentis	Nucleus n. abducentis
Nucleus n. facialis	Nucleus originis nervi facialis	Nucleus n. facialis
Radix n. facialis	.....	.....
Pars prima	.....	.....
Genu (internum)	.....	Genu n. facialis
Pars secunda	.....	.....
.....	Nucleus terminalis n. trigemini	Nucleus sensorius principalis n. trigemini

BNA	JNA	PNA
Nuclei motorii n. trigemini	Nucleus originis n. trigemini	Nucleus motorius n. trigemini
Radix descendens (mesencephalica) n. trigemini	.....	Nucleus tractus mesencephalicus n. trigemini**
Tractus spinalis n. trigemini	.....	Tractus spinalis n. trigemini
Nucleus tractus spinalis n. trigemini	Nucleus terminalis tractus spinalis n. trigemini ..	Nucleus tractus spinalis n. trigemini .....
.....	.....	Nuclei n. vestibulocochlearis*
Nuclei n. acustici	Nucleus terminalis dorsalis nervi cochleae . Nucleus terminalis ventralis nervi cochleae	Nuclei cochleares, ventralis et dorsalis
Nuclei n. vestibularis	Nucleus terminalis dorsalis nervi vestibuli .... Nucleus terminalis medialis (triangularis) nervi vestibuli ..... Nucleus terminalis lateralis nervi vestibuli ... Nucleus terminalis spinalis nervi vestibuli	Nuclei vestibulares Nucleus superior Nucleus medialis Nucleus lateralis Nucleus inferior
.....	.....	Nucleus ventralis corporis trapezoidei*
Nucleus olivaris superior	Nucleus olivaris metencephali	Nucleus dorsalis corporis trapezoidei*
Nucleus lemnisci lateralis	Nucleus lemnisci lat. ..	Nucleus lemnisci lat.
.....	Nucleus originis salivatorius pontis = Nucleus secretorius n. intermedii	.....

BNA	JNA	PNA
Fasciculus longitudinalis medialis	Tractus longitudinalis medialis	Fasciculus longitudinalis medialis
.....	Fasciculus longitudinalis dorsalis	Fasciculus longitudinalis dorsalis
Pars basilaris pontis	Pars basialis pontis	Pars ventralis pontis**
Fibrae pontis profundae	Fibrae pontis profundae	Fibrae pontis transversae
Fasciculi longitudinales (pyramidales)	Fasciculi longitudinales = tractus corticospinalis	Tractus pyramidalis**
		Fibrae corticonucleares
		Fibrae corticospinales
		Fibrae corticoreticulares**
		Tractus corticopontinus**
Nuclei pontis	Nuclei pontis	Nuclei pontis
Fibrae pontis superficiales	Fibrae pontis superficiales	.....
CEREBELLUM	CEREBELLUM	CERFBELLUM
Gyri cerebelli	Gyri cerebelli	Folia cerebelli
Sulci cerebelli	Sulci cerebelli	Fissurae cerebelli
Vallecula cerebelli	Vallecula cerebelli	Vallecula cerebelli
Incisura cerebelli anterior	Incisura cerebelli anterior	.....
Incisura cerebelli post. ..	Incisura cerebelli post. ..	.....
Sulcus horizontalis cerebelli	.....	Fissura horizontalis**
Fissura transversa cerebelli	.....	.....
.....	Fissura cerebrocerebellaris	.....
.....	.....	Fissura prima
.....	.....	Fissura secunda**
Vermis	Vermis	Vermis
Lingula cerebelli	Lingula cerebelli	Lingula cerebelli
Vincula lingulae	Vincula lingulae cerebelli	.....

BNA	JNA	PNA
Lobulus centralis	Lobulus centralis	Lobulus centralis*
Monticulus	Monticulus	.....
Culmen	Culmen	Culmen
Declive	Declive	Declive
Folium vermis	Folium vermis	Folium vermis
Tuber vermis	Tuber vermis	Tuber vermis
Pyramis (vermis)	Pyramis vermis	Pyramis vermis**
Uvula (vermis)	Uvula vermis	Uvula vermis**
Nodulus	Nodulus	Nodulus
Hemisphaerium cerebelli .	Hemisphaerium cerebelli .	Hemispherium cerebelli*
Facies superior	Facies superior	Facies superior
Ala lobuli centralis .	Ala lobuli centralis .	Ala lobuli centralis
Lobulus quadrangularis	Lobulus quadrangularis	Lobulus quadrangularis
Pars anterior	Pars anterior	.....
Pars posterior	Pars posterior	.....
.....	.....	Lobulus simplex
Lobulus semilunaris superior	Lobulus semilunaris superior	Lobulus semilunaris superior
Facies inferior	Facies inferior	Facies inferior
Lobulus semilunaris inferior	Lobulus semilunaris inferior	Lobulus semilunaris inferior
Lobulus biventer	Lobulus biventer	Lobulus biventer
Tonsilla cerebelli	Tonsilla cerebelli	Tonsilla cerebelli
Flocculus	Flocculus	Flocculus
(Flocculi secundarii) .	var. Flocculi secundarii	.....
.....	.....	Fissura posterolat.*
Pedunculus flocculi ..	Pedunculus flocculi ..	Pedunculus flocculi
Nidus avis	.....	.....
.....	Crura cerebelli	.....
Sectiones cerebelli	.....	*Sectiones cerebelli*
Corpus medullare	Corpus medullare	Corpus medullare
Laminae medullares ..	Laminae medullares ..	Laminae albae
Arbor vitae	Arbor vitae	Arbor vitae cerebelli*

BNA	JNA	PNA
Substantia corticalis	Substantia corticalis	Cortex cerebelli
(Lamina basalis)	.....	.....
(Stratum cinereum)	Stratum cinereum	Stratum moleculare
(Stratum gangliosum) ..	.....	.....
Stratum granulosum ...	Stratum ferrugineum ..	Stratum granulosum
Nucleus dentatus	Nucleus dentatus	Nucleus dentatus
Hilus nuclei dentati ...	Hilus nuclei dentati ...	Hilus nuclei dentati
Capsula nuclei dentati .	.....	.....
Nucleus fastigii	Nucleus fastigii	Nucleus fastigii
Nucleus globosus	Nuclei globiformes	Nucleus globosus
Nucleus emboliformis ...	Nucleus emboliformis ...	Nucleus emboliformis
ISTHMUS RHOMBENCEPHALI	*ISTHMUS RHOMBENCEPHALI°*	*(ISTHMUS RHOMBENCEPHALI)*
Brachium conjunctivum (cerebelli)	Crus cerebellocerebrale = Brachium conjunctivum	Pedunculus cerebellaris superior
MESENCEPHALON	MESENCEPHALON	MESENCEPHALON
PEDUNCULUS CEREBRI	CRUS CEREBRI + TEGMENTUM	PEDUNCULUS CEREBRI
Basis pedunculi	Crus cerebri	Crus cerebri
Fossa interpeduncularis (Tarini)	Fossa intercruralis	Fossa interpeduncularis
Recessus anterior	Recessus rostralis	.....
Recessus posterior	Recessus caudalis	.....
Substantia perforata posterior	Substantia perforata intercruralis	Substantia perforata posterior
Sulcus lateralis	Sulcus lat. mesencephali	.....
Sulcus n. oculomotorii	Sulcus n. oculomotorii ..	Sulcus medialis cruris cerebri
(Facies inferior)	.....	.....
Corpora quadrigemina	*Corpora quadrigemina*	.....
.....	.....	*Tectum mesencephali*
Lamina quadrigemina ...	Lamina quadrigemina ...	Lamina tecti
Colliculus superior	Colliculus rostralis	Colliculus superior

BNA	JNA	PNA
Colliculus inferior	Colliculus caudalis	Colliculus inferior
Brachium quadrigeminum superius	Brachium colliculi rostralis	Brachium colliculi superioris
Brachium quadrigeminum inferius	Brachium colliculi caudalis	Brachium colliculi inferioris
Sectiones pedunculi cerebri	.....	*Sectiones mesencephali***
Tegmentum	Tegmentum	Tegmentum
Stratum griseum centrale	Stratum griseum centrale	Substantia grisea centralis
Aquaeductus cerebri (Sylvii)	Aquaeductus mesencephali	Aqueductus cerebri*
Formatio reticularis ...	Formatio reticularis ...	Formatio reticularis
.....	.....	Fibrae corticoreticulares**
Fasciculus longitudinalis medialis	Tractus longitudinalis medialis	Fasciculus longitudinalis medialis
.....	Fasciculus longitudinalis dorsalis	Fasciculus longitudinalis dorsalis
Radix descendens n. trigemini	.....	Tractus mesencephalicus n. trigemini
Nucleus radicis descendentis n. trigemini ..	Nucleus accessorius (mesencephalicus) nervi trigemini	Nucleus tractus mesencephalici n. trigemini
Nucleus n. oculomotorii	Nucleus originis nervi oculomotorii	Nucleus n. oculomotorii
.....	Nucl. originis accessorius (parasympathicus) n. oculomotorii	.....
Ggl. interpedunculare .	Ganglion intercrurale ..	Nucleus interpeduncularis
Nucleus n. trochlearis .	Nucleus nervi originis trochlearis	Nucleus n. trochlearis

BNA	JNA	PNA
Nuclei tegmenti	.....	Nuclei tegmenti
Nucleus ruber	Nucleus ruber	Nucleus ruber
Decussationes tegmentorum	.....	Decussationes tegmenti
Decussatio brachii conjunctivi	Decussatio crurum cerebellocerebralium .	Decussatio pedunculorum cerebellium superiorum
Lemniscus lateralis (acusticus)	Lemniscus lateralis ...	Lemniscus lateralis
Lemniscus medialis (sensitivus)	Lemniscus medialis	Lemniscus medialis Lemniscus spinalis Lemniscus trigeminalis*
Substantia nigra	Nucleus niger	Substantia nigra
Fasciculi pyramidales	Tractus cortico-spinalis ..	Tractus pyramidalis** Fibrae corticonucleares** Fibrae corticospinales**
.....	.....	Tractus tegmentalis centr.
.....	Tractus corticopontini ...	Tractus corticopontini
.....	Pars frontalis (tractum corticopontinorum)	.....
.....	Pars occipitotemporalis (tractum corticopontinorum)	.....
Sectiones corporum quadrigeminorum	.....	.....
Stratum zonale	Stratum zonale	.....
Stratum griseum colliculi superioris	Stratum griseum colliculi rostralis	Stratum griseum colliculi superioris
Nucleus colliculi inf. ..	Nucleus colliculi caudalis	Nucleus colliculi inf.
.....	Nucleus colliculi rostralis	.....
Stratum album prof. ..	Stratum album prof. ..	.....

BNA	JNA	PNA
PROSENCEPHALON	PROSENCEPHALON	PROSENCEPHALON
DIENCEPHALON	*DIENCEPHALON*	*DIENCEPHALON*
VENTRICULUS TERTIUS	VENTRICULUS TERTIUS	VENTRICULUS TERTIUS
Aditus ad aquaeductum cerebri		
Commissura posterior (cerebri)	Commissura caudalis	Commissura posterior
	Fossa commissurae caudalis	
Foramen interventriculare (Monroi)	Foramen interventriculare	Foramen interventriculare
		Tela choroidea ventriculi tertii*
Sulcus hypothalamicus (Monroi)	Sulcus hypothalamicus	Sulcus hypothalamicus
Massa intermedia	Massa intermedia	Adhesio interthalamica
Recessus opticus	Recessus opticus	Recessus opticus
Recessus infundibuli	Recessus infundibuli	Recessus infundibuli
Recessus triangularis	Recessus triangularis	
	Pars diencephalica ventriculi tertii	
	Pars impar ventriculi telencephali = Pars telencephalica ventriculi tertii	
HYPOTHALAMUS	HYPOTHALAMUS	HYPOTHALAMUS
Pars mamillaris hypothalami		
Corpus mamillare	Corpus mamillare	Corpus mamillare
Pars optica hypothalami		
Tuber cinereum	Tuber cinereum	Tuber cinereum
	Stria alba tuberis	
Infundibulum	Infundibulum	Infundibulum
Tractus opticus	Tractus opticus	Tractus opticus
Radix medialis	Radiatio tractus optici	Radix medialis*
Radix lateralis	Radiatio tractus optici	Radix lateralis*
Chiasma opticum	Chiasma fasciculorum opticorum	Chiasma opticum

BNA	JNA	PNA
Lamina terminalis	Lamina terminalis cinerea ventriculi tertii .	Lamina terminalis
Vide: Gl. endocrinales ..	Vide: Gl. endocrinales ..	Hypophysis (Glandula pituitaria)**
Sectiones hypothalami	.....	*Sectiones hypothalami*
.....	.....	Nuclei tuberales
.....	.....	Nucleus ventromedialis
.....	.....	Nucleus dorsomedialis
.....	.....	Nucleus paraventricularis
.....	.....	Nucleus supraopticus
.....	.....	Nucleus posterior
Nucleus hypothalamicus (Corpus Luysi)	Nucleus hypothalamicus .	Vide: Sectiones thalamencephali, Nucleus subthalamicus
.....	.....	Fibrae periventriculares
Pars grisea hypothalami .	Pars grisea hypothalami .	
Commissura superior (Meynerti)	Commissura dorsalis ...	Commissurae supraopticae
Commissura inferior (Guddeni)	Commissura basialis	Nuclei corporis mamillaris
Nuclei corporis mamillaris	Nuclei corporis mamillaris	
.....	Pedunculus corporis mamillaris	.....
Fasciculus thalamomamillaris (Vicq d'Azyri) ...	Fasciculus mamillothalamicus	Fasciculus mamillothalamicus
Fasciculi pedunculomamillares	Tractus mamillotegmentalis	Vide: Tractus nervosi projectionis**
		.....
Pars tegmentalis	.....	.....
Pars basilaris	.....	Vide: Thalamus**
Ansa peduncularis	Ansa cruralis	Vide: Thalamus**
Ansa lenticularis	Ansa lenticularis	
Pedunculus thalami inferior	Pedunculus thalami basialis	Vide: Thalamus**
THALAMENCEPHALON	*THALAMENCEPHALON°*	*THALAMENCEPHALON*
THALAMUS	THALAMUS	THALAMUS
Pulvinar	Pulvinar	Pulvinar

BNA	JNA	PNA
Tuberculum anterius thalami	Tuberculum rostrale	Tuberculum ant. thalami
Taenia thalami	Taenia chorioidea thalami	Tenia thalami*
Stria medullaris	Stria medullaris	Stria medullaris thalami
.....	Fibrae striarum medullarium	.....
Lamina chorioidea epithelialis	Lamina tectoria ventriculi tertii	.....
METATHALAMUS	.....	METATHALAMUS
Corpus geniculatum mediale	Corpus geniculatum mediale	Corpus geniculatum med.
Corpus geniculatum laterale	Corpus geniculatum laterale	Corpus geniculatum lat.
EPITHALAMUS	.....	EPITHALAMUS
Corpus pineale	Corpus pineale	Corpus pineale
Recessus pinealis	Recessus pinealis	Recessus pinealis
Recessus suprapinealis ...	Recessus suprapinealis ...	Recessus suprapinealis
Habenula	Habenula	Habenula
Commissura habenularum	Commissura pinealis habenularum	Commissura habenularum
Trigonum habenulae	Trigonum habenulae	Trigonum habenulae
.....	Trigonum subpineale	.....
Sectiones thalamencephali	.....	*Sectiones thalamencephali*
Stratum zonale	Stratum zonale	Stratum zonale
.....	Nuclei thalami	.....
Nucleus anterior thalami	Nucleus rostralis	Nuclei anteriores thalami**
.....	.....	Nucleus anterodorsalis**
.....	.....	Nucleus anteroventralis**
.....	.....	Nucleus anteromedialis**

BNA	JNA	PNA
Nucleus medialis thalami	Nucleus medialis	Nucleus medialis thalami
Nucleus lateralis thalami	Nucleus lateralis = magnus	Nuclei laterales thalami**
.....	.....	Nucleus ventralis anterolateralis**
.....	.....	Nucleus ventralis intermedius**
.....	.....	Nucleus ventralis posteromedialis**
.....	.....	Nucleus ventralis posterolateralis**
.....	.....	Nucleus lateralis dorsalis**
.....	.....	Nucleus posterior (Pulvinar thalami)**
.....	.....	Nucleus reticularis thalami**
Laminae medullares	Laminae medullares thalami	Laminae medullares thalami
.....	.....	Nuclei intralaminares**
.....	.....	Nucleus medialis centralis (centromedianus)**
Nucleus corporis geniculati medialis	Nucleus corporis geniculati medialis	Nucleus corporis geniculati medialis
Nucleus corporis geniculati lateralis	Nucleus corporis geniculati lateralis	Nuclei corporis geniculati laterales**
Nucleus habenulae	Nucleus habenulae	Nuclei habenulae medialis et lateralis**
Fasciculus retroflexus (Meynerti)	Fasciculus retroflexus ..	Fasciculus retroflexus
.....	.....	Zona incerta**
Vide: Hypothalamus, Nucleus hypothalamicus	.....	Nucleus subthalamicus**
		Ansa lenticularis**
Vide: Hypothalamus	Vide: Hypothalamus	Ansa peduncularis**
Vide: Hypothalamus	Vide: Hypothalamus	Pedunculus thalami inferior**
Vide: Hypothalamus	Vide: Hypothalamus	

BNA	JNA	PNA
TELENCEPHALON	*TELENCEPHALON*	*TELENCEPHALON*
CEREBRUM	CEREBRUM	CEREBRUM
Facies convexa cerebri ..	Facies convexa cerebri ..	Facies superolateralis cerebri*
Facies medialis	Facies medialis cerebri ..	Facies medialis cerebri
Basis cerebri	Facies basialis cerebri ...	Facies inferior cerebri*
.....	.....	Margo superior (superomedialis)**
.....	.....	Margo inferior (inferolateralis)**
.....	.....	Margo medialis (inferomedialis)**
HEMISPHAERIUM	HEMISPHAERIUM	HEMISPHERIUM
.....	.....	*Facies superolateralis cerebri***
Pallium	*Pallium*	*Pallium*
Fissura longitudinalis cerebri	Fissura interhemisphaerica	Fissura longitudinalis cerebri
Fissura transversa cerebri	Fissura telodiencephalica .	Fissura transversa cerebri
Gyri cerebri	Gyri cerebri	Gyri cerebri
Gyri profundi	Gyri profundi	.....
Gyri transitivi	Gyri transitivi	.....
Sulci cerebri	Sulci cerebri	Sulci cerebri
Impressio petrosa	Impressio petrosa	.....
Fossa cerebri lateralis (Sylvii)	.....	Fossa lateralis cerebri
Fissura cerebri lateralis (Sylvii)	Fissura cerebri lateralis .	Sulcus lateralis
Ramus posterior	Ramus occipitalis	Ramus posterior
Ramus anterior ascendens	Ramus ascendens	Ramus ascendens
Ramus anterior horizontalis	Ramus frontalis	Ramus anterior
.....	Vallecula cerebri lateralis	.....
Lobi cerebri	Lobi cerebri	Lobi cerebri
Insula	Insula	Insula
Gyri insulae	Gyri insulae	Gyri insulae

BNA	JNA	PNA
Gyrus longus insulae	Gyrus longus insulae	Gyrus longus insulae
Gyri breves insulae .	Gyri breves insulae .	Gyri breves insulae
Sulcus circularis (Reili)	Sulcus circularis	Sulcus circularis insulae
.....	.....	Sulcus centralis insulae
Vide: Rhinencephalon ..	Vide: Rhinencephalon ...	Limen insulae
Operculum: Pars frontalis	Operculum frontale	Operculum frontale
Operculum: Pars parietalis	Operculum parietale	Operculum frontoparietale*
Operculum: Pars temporalis	Operculum temporale ...	Operculum temporale
Sulcus centralis (Rolandi)	Sulcus centralis	Sulcus centralis
Lobus frontalis	*Lobus frontalis*	*Lobus frontalis*
Polus frontalis	.....	Polus frontalis
Sulcus praecentralis ...	Sulcus praecentralis ...	Sulcus precentralis
Gyrus centralis anterior .	Gyrus praecentralis	Gyrus precentralis
Gyrus frontalis superior	Gyrus frontalis superior	Gyrus frontalis sup.
Sulcus frontalis sup. ..	Sulcus frontalis sup. ..	Sulcus frontalis sup.
Gyrus frontalis medius	Gyrus frontalis medius	Gyrus frontalis medius
Pars superior	.....	.....
Pars inferior	.....	.....
Sulcus frontalis inferior	Sulcus frontalis inferior	Sulcus frontalis inferior
Gyrus frontalis inferior	Gyrus frontalis inferior	Gyrus frontalis inferior
Pars opercularis	Pars opercularis	.....**
Pars triangularis	Pars triangularis	.....**
Pars orbitalis	Pars orbitalis	.....**
Gyrus rectus	Gyrus rectus	Gyrus rectus
Sulcus olfactorius	Sulcus olfactorius	Sulcus olfactorius
Gyri orbitales	Gyri orbitales	Gyri orbitales
Sulci orbitales	Sulci orbitales	Sulci orbitales
Lobus temporalis	*Lobus temporalis*	*Lobus temporalis*
Polus temporalis	.....	Polus temporalis
Sulci temporales transversi	Sulci temporales transversi	Sulci temporales transversi
Gyri temporales transversi	Gyri temporales transversi	Gyri temporales transversi

BNA	JNA	PNA
Gyrus temporalis superior	Gyrus temporalis superior	Gyrus temporalis sup.
Sulcus temporalis superior	Sulcus temporalis superior	Sulcus temporalis sup.
Gyrus temporalis medius	Gyrus temporalis medius	Gyrus temporalis medius
Sulcus temporalis medius	Sulcus temporalis medius	.....
Gyrus temporalis inferior	Gyrus temporalis inferior	Gyrus temporalis inf.
Sulcus temporalis inferior	Sulcus temporalis inferior	Sulcus temporalis inferior
Lobus occipitalis	*Lobus occipitalis*	*Lobus occipitalis*
Polus occipitalis	.....	Polus occipitalis
Sulcus occipitalis transversus	Sulcus occipitalis transversus	Sulcus occipitalis transversus
.....	.....	(Sulcus lunatus)
Gyri occipitales superiores	Gyri occipitales superiores	.....
Sulci occipitales superiores	Sulci occipitales superiores	.....
Gyri occipitales laterales	Gyri occipitales laterales	.....
Sulci occipitales laterales	Sulci occipitales laterales	.....
.....	.....	Incisura preoccipitalis
Lobus parietalis	*Lobus parietalis*	*Lobus parietalis*
.....	Sulcus postcentralis ...	Sulcus postcentralis
Gyrus centralis posterior	Gyrus postcentralis	Gyrus postcentralis

BNA	JNA	PNA
Lobulus parietalis superior	Lobulus parietalis superior	Lobulus parietalis superior
Sulcus interparietalis	Sulcus interparietalis	Sulcus intraparietalis
Lobulus parietalis inferior	Lobulus parietalis inferior	Lobulus parietalis inf.
Gyrus supramarginalis	Gyrus circumflexus	Gyrus supramarginalis
Gyrus angularis	Gyrus angularis	Gyrus angularis
Facies medialis (hemisphaerii cerebri)	*Facies medialis hemisphaerii*	*Facies medialis et facies inferior hemispherii***
Sulcus corporis callosi	Sulcus corporis callosi	Sulcus corporis callosi
Sulcus cinguli	Sulcus cinguli	Sulcus cinguli
Pars subfrontalis	Pars subfrontalis	
Pars marginalis	Pars marginalis	
Sulcus subparietalis	Sulcus subparietalis	Sulcus subparietalis
		Gyrus frontalis medialis**
Fissura collateralis	Sulcus collateralis	Sulcus collateralis
		Sulcus rhinalis*
Gyrus fusiformis	Gyrus occipitotemporalis lateralis	Gyrus occipititomporalis lateralis
Vide: Lobus frontalis	Vide: Lobus frontalis	Gyrus rectus**
Vide: Lobus frontalis	Vide: Lobus frontalis	Sulcus olfactorius**
Vide: Lobus frontalis	Vide: Lobus frontalis	Gyri orbitales**
Vide: Lobus frontalis	Vide: Lobus frontalis	Sulci orbitales**
Gyrus lingualis	Gyrus occipitotemporalis medialis	Gyrus occipitotemporalis medialis
		Sulcus occipitotemporalis
Vide: Ventriculus lat.	Vide: Pars lat. ventr.	Gyrus dentatus**
Fissura hippocampi	Sulcus hippocampi	Sulcus hippocampi
	Pars fornicata pallii	
Gyrus fornicatus	Gyrus fornicatus	
Gyrus cinguli	Gyrus cinguli	Gyrus cinguli
Isthmus gyri fornicati	Isthmus gyri fornicati	Isthmus gyri cinguli
Gyrus hippocampi	Gyrus hippocampi	Gyrus parahippocampalis
		Gyrus lingualis*
Uncus gyri hippocampi	Uncus gyri hippocampi	Uncus
Substantia reticularis alba (Arnoldi)	Substantia reticularis alba	
Lobulus paracentralis	Lobulus paracentralis	Lobulus paracentralis

BNA	JNA	PNA
Praecuneus	Praecuneus	Precuneus
Fissura parietooccipitalis .	Sulcus parietooccipitalis .	Sulcus parietooccipitalis*
Fissura calcarina	Sulcus calcarinus	Sulcus calcarinus
Cuneus	Cuneus	Cuneus
Vide: Rhinencephalon ..	Vide: Rhinencephalon ..	Bulbus olfactorius**
Vide: Rhinencephalon ..	Vide: Rhinencephalon ..	Tractus olfactorius**
Vide: Rhinencephalon ..	Vide: Rhinencephalon ..	Trigonum olfactorium**
Vide: Rhinencephalon ..	Vide: Rhinencephalon ..	Striae olfactoriae**
Vide: Rhinencephalon ..	Vide: Rhinencephalon ..	Substantia perforata ant.**
Vide: Rhinencephalon, Area parolfactoria	Vide: Rhinencephalon ..	Area subcallosa**
Vide: Rhinencephalon, Gyrus subcallosus	Vide: Rhinencephalon ..	Gyrus paraterminalis**
Corpus callosum	*Corpus callosum*	*Corpus callosum*
Splenium corporis callosi	Splenium corporis callosi	Splenium corporis callosi
Truncus corporis callosi .	Truncus corporis callosi .	Truncus corporis callosi
Genu corporis callosi ...	Genu corporis callosi ...	Genu corporis callosi
Rostrum corporis callosi	Rostrum corporis callosi .	Rostrum corporis callosi
Lamina rostralis	.....	.....
Striae transversae	Striae transversae	.....
.....	Stratum griseum	Indusium griseum
Stria longitudinalis med. .	Stria longitudinalis med. .	Stria longitudinalis med.
Stria longitudinalis lat. ..	Stria longitudinalis lat. ..	Stria longitudinalis lat.
Fasciola cinerea	Gyrus fasciolaris	Gyrus fasciolaris
Fornix	*Fornix*	*Fornix*
Crus fornicis	Crus fornicis	Crus fornicis
Corpus fornicis	Corpus fornicis	Corpus fornicis
Taenia fornicis	Taenia fornicis	Tenia fornicis*
Columna fornicis	Columna fornicis	Columna fornicis
Pars libera	Pars libera columnae fornicis	.....
Pars tecta	Pars tecta columnae fornicis	.....
Vide: Ventriculus lat., Commissura hippocampi	.....	Commissura fornicis**
Septum pellucidum	*Septum pellucidum*	*Septum pellucidum*
Lamina septi pellucidi ...	Lamina septi pellucidi ...	Lamina septi pellucidi
Cavum septi pellucidi ...	Cavum septi pellucidi ...	Cavum septi pellucidi

BNA	JNA	PNA
VENTRICULUS LATERALIS	PARS LATERALIS VENTRICULI TELENCEPHALI	VENTRICULI LATERALIS
.....	Ventriculus telencephali ..	.....
Pars centralis	Pars parietalis	Pars centralis
Cornu anterius	Cornu frontale	Cornu anterius
Cornu posterius	Cornu occipitale	Cornu posterius
(Bulbus cornu posterioris)	.....	Bulbus cornus posterioris*
Calcar avis	Calcar avis	Calcar avis
Eminentia collateralis ..	Eminentia collateralis ..	Eminentia collateralis
Trigonum collaterale	Trigonum collaterale .	Trigonum collaterale
Cornu inferius	Pars temporalis	Cornu inferius
Hippocampus	.....	Hippocampus
.....	Pes hippocampi	Pes hippocampi
.....	.....	Alveus hippocampi*
Fimbria hippocampi .	Fimbria hippocampi .	Fimbria hippocampi
Taenia fimbriae	.....	.....
Digitationes hippocampi	Digitationes hippocampi	.....
Fascia dentata hippocampi	Gyrus dentatus	Vide: Facies med.**
Nucleus caudatus	Nucleus caudatus	Nucleus caudatus
Caput nuclei caudati ..	Caput nuclei caudati ..	Caput nuclei caudati
.....	.....	Corpus nuclei caudati*
Cauda nuclei caudati ..	Cauda nuclei caudati ..	Cauda nuclei caudati
Stria terminalis	Stria terminalis	Stria terminalis
Lamina affixa	Lamina affixa	Lamina affixa
.....	.....	Fissura choroidea*
Taenia chorioidea	Taenia chorioidea	Tenia choroidea*
Lamina chorioidea epithelialis	.....	.....
Commissura hippocampi .	.....	Vide: Fornix**, Commissura fornicis
RHINENCEPHALON	RHINENCEPHALON	.....
Sulcus parolfactorius anterior	Sulcus adolfactorius ant.	.....
Pars anterior (rhinencephali)	.....	.....
Lobus olfactorius	.....	.....
Bulbus olfactorius ..	Bulbus olfactorius ...	Vide: Facies inf.**
.....	Nuclei terminales filarum olfactoriarum (glomerula olfactoria)	.....

BNA	JNA	PNA
Tractus olfactorius ..	Tractus olfactorius ..	Vide: Facies inf.**
Trigonum olfactorium	Trigonum olfactorium	Vide: Facies inf.**
Stria medialis	Stria olfactoria medialis	.....
Stria intermedia	Stria olfactoria intermedia	.....
Area parolfactoria (Brocae)	Area adolfactoria ...	Vide: Facies inf.**, area subcallosa
Sulcus parolfactorius posterior	Sulcus adolfactorius posterior	.....
Pars posterior (rhinencephali)	.....	.....
Gyrus subcallosus (Pedunculus corporis callosi)	Gyrus subcallosus	Vide: Facies inf.**, Gyrus paraterminalis
Substantia perforata anterior	Area olfactoria	Vide: Facies inf.**
Stria olfactoria lat. ..	Stria olfactoria lat.	Vide: Facies inf.**
Limen insulae	Limen insulae	Vide: Facies superolat.**
Sectiones telencephali	.....	*Sectiones telencephali*
Substantia corticalis	Substantia corticalis	Cortex cerebri
Centrum semiovale	Centrum semiovale	Centrum semiovale
.....	Strata alba corticis	.....
Decursus fibrarum cerebralium	.....	.....
Fibrae arcuatae cerebri .	Fibrae arcuatae cerebri .	Fibrae arcuatae cerebri
Cingulum	Cingulum	Cingulum
Fasciculus longitudinalis superior	Fasciculus frontooccipitalis	Fasciculus longitudinalis superior
Fasciculus longitudinalis inferior	Fasciculus temporooccipitalis	Fasciculus longitudinalis inferior
Fasciculus uncinatus ..	Fasciculus uncinatus ..	Fasciculus uncinatus
Radiatio corporis callosi	Radiatio corporis callosi	Radiatio corporis callosi
Pars frontalis	Pars frontalis	.....
Pars parietalis	Pars parietalis	.....

BNA	JNA	PNA
Pars temporalis ..	Pars temporalis ..	.....
Pars occipitalis ...	Pars occipitalis ...	.....
Tapetum	Tapetum	.....
Corpus striatum	Corpus striatum	Corpus striatum
Vide: Ventriculus lat. .	Vide: Pars lat. ventriculi	Nucleus caudatus (vide: supra)*
Nucleus lentiformis ...	Nucleus lentiformis ...	Nucleus lentiformis
.....	Laminae medullares	Lamina medullaris lateralis Lamina medullaris medialis
Putamen	Putamen	Putamen
Globus pallidus	Pars pallida nuclei lentiformis	Globus pallidus
Claustrum	Claustrum	Claustrum
Capsula externa	Capsula externa nuclei lentiformis	Capsula externa
Capsula interna	Capsula interna nuclei lentiformis	Capsula interna
Genu capsulae int. ..	Genu	Genu capsulae int.
Pars frontalis	Crus frontale	Crus anterius capsulae internae
Pars occipitalis	Crus occipitale	Crus posterius capsulae internae
.....	.....	Pars sublentiformis capsulae internae
.....	.....	Pars retrolentiformis capsulae internae
Nucleus amygdalae	Nucleus amygdalae	Corpus amygdaloideum
.....	.....	Radiatio acustica
Corona radiata	Corona radiata	Corona radiata
Pars frontalis	Pars frontalis	.....
Pars parietalis	Pars parietalis	.....
Pars temporalis	Pars temporalis	.....
Pars occipitalis	Pars occipitalis	.....
Radiatio corporis striati	Radiatio corporis striati	.....
.....	Pars striothalamica (radiationis corporis striati)	.....
.....	Pars corticostrialis radiationis corporis striati)	.....

BNA	JNA	PNA
.....	Pars striosubthalamica (radiationis corporis striati)	.....
Radiatio occipitothalamica (Gratioleti) ...	Radiatio optica	Radiatio optica
.....	Pars geniculata (radiationis tractus optici) .	.....
.....	Pars mesencephalica (radiationis tractus optici)	.....
.....	Pars thalamica (radiationis tractus optici) .	.....
Commissura anterior (cerebri)	Commissura rostralis .	Commissura anterior
Pars anterior	Pars anterior (commissurae rostr.) .	Pars anterior
Pars posterior	Pars post. (commissurae rostr.) .	Pars posterior
TRACTUS SYSTEMATIS NERVORUM CENTRALIS°	*TRACTUS SYSTEMATIS NERVORUM CENTRALIS*°	*TRACTUS SYSTEMATIS NERVOSI CENTRALIS*
.....	TRACTUS NERVOSI ASSOCIATIONIS	TRACTUS NERVOSI ASSOCIATIONES
Fibrae arcuatae cerebri .	Fibrae arcuatae cerebri .	Fibrae arcuatae cerebri
Fasciculus longitudinalis superior	Fasciculus frontooccipitalis	Fasciculus longitudinalis superior
Fasciculus longitudinalis inferior	Fasciculus temporooccipitalis	Fasciculus longitudinalis inferior
Fasciculus uncinatus	Fasciculus uncinatus	Fasciculus uncinatus
Cingulum	Cingulum	Cingulum
.....	.....	Fasciculi proprii medullae spinalis (Fasciculi intersegmentales)

BNA	JNA	PNA
.....	TRACTŪS NERVOSI COMMISSURALES	TRACTUS NERVOSI COMMISSURALES
Corpus callosum	Corpus callosum	Corpus callosum
Radiatio corporis callosi	Radiatio corporis callosi	Radiatio corporis callosi
Pars frontalis	Pars frontalis	Forceps minor
Pars parietalis	Pars parietalis ...	
Pars temporalis ..	Pars temporalis .	Forceps major
Pars occipitalis ...	Pars occipitalis ..	
Commissura anterior	Commissura rostralis ...	Commissura anterior
Pars anterior	Pars anterior (commissurae rostr.)	Pars anterior
Pars posterior	Pars posterior (commissurae rostr.)	Pars posterior
Commissura habenularum	Commissura pinealis = habenularum	Commissura habenularum
.....	.....	Commissura posterior*
Commissura hippocampi .	.....	Commissura fornicis
Commissura superior (Meynerti)	Commissura dorsalis	Commissurae supraopticae
Decussationes tegmentorum	.....	.....**
.....	TRACTŪS NERVOSI PROJECTIONIS	TRACTUS NERVOSI PROJECTIONES
Corona radiata	Corona radiata	Corona radiata
Pars frontalis	Pars frontalis	.....
Pars parietalis	Pars parietalis	.....
Pars temporalis	Pars temporalis	.....
Pars occipitalis	Pars occipitalis	.....
Tractus thalamo-corticales+	Tractūs thalamocorticales	Fasciculi thalamocorticales
Tractus cortico-thalamici+	Tractūs corticothalamici .	Fasciculi corticothalamici
Pedunculus thalami inf. .	Pedunculus thalami basialis	Pedunculus thalami inf.
Radiatio occipitothalamica (Gratioleti)	Radiatio optica	Radiatio optica
.....	Tractus geniculocorticalis (radiatio optica)	.....
.....	.....	Radiatio acustica
.....	Tractus geniculocorticalis (cochlearis)	.....
Radiatio corporis striati .	Radiatio corporis striati .	.....

BNA	JNA	PNA
.....	Pars corticostrialis (radiationis corporis striati) .	.....
.....	Pars striothalamica (radiationis corporis striati) .	.....
.....	Pars striosubthalamica (radiationis corporis striati)	.....
Fornix	Fornix	Fornix
Crus fornicis	Crus fornicis	Crus fornicis
Corpus fornicis	Corpus fornicis	Corpus fornicis
Columna fornicis	Columna fornicis	Columna fornicis
Taenia fornicis	Taenia fornicis	.....**
Fasciculus thalamomamillaris (Vicq d'Azyri) ...	Fasciculus mamillothalamicus	Fasciculus mamillothalamicus
Fasciculi pedunculomamillaris	Tractus mamillotegmentalis	Fasciculus mamillotegmentalis
.....	.....	Tractus pyramidales**
Decussatio pyramidum ..	Decussatio pyramidum ..	Decussatio pyramidum (Decussatio motoria)
Fasciculus cerebrospinalis anterior (pyramidalis anterior)	Tractus cortico-spinalis ventralis	Tractus corticospinalis (pyramidalis) anterior
Fasciculus cerebrospinalis lat. (pyramidalis lat.) ..	Tractus cortico-spinalis lateralis	Tractus corticospinalis (pyramidalis) lateralis
.....	.....	Fibrae corticoreticulares**
Tractus corticis ad pontem+	Tractus corticopontini ...	Tractus corticopontini
.....	Pars frontalis	{Tractus frontopontinus {Tractus parietopontinus
.....	Pars occipitotemporalis ..	{Tractus temporopontinus {Tractus occipitopontinus
Tractus cortico-bulbaris+	Tractus corticobulbaris ..	Fibrae corticonucleares**
Tractus cortico-tectalis+ .	Tractus corticotectalis ...	.....
Tractus cortico-cerebellaris+	Tractus corticocerebellaris	.....

BNA	JNA	PNA
Tractus cortico-habenularis+	Tractus corticohabenularis	.....
Tractus cortico-mamillaris+	Tracti corticomamillaris	.....
.....	.....	Tracti corticohypothalamici
Tractus cortico-tegmentalis+	Tractus corticotegmentalis	.....
Tractus cerebello-nuclearis+	Tractūs cerebellonucleares	.....
Tractus cerebello-tegmentalis+	Tractus cerebellotegmentalis mesencephali	Tractus cerebellorubralis
Decussatio brachii conjunctivi	Decussatio crurum cerebellocerebralium	Decussatio pedunculorum cerebellarium superiorum
Tractus cerebello-thalamicus+	Tractus cerebellothalamicus	Tractus cerebellothalamicus
Tractus fastigio-bulbaris .	Tractus fastigiobulbaris (cerebellobulbaris)	.....
.....	var. Tractus cruralis transversus	.....
Tractus habenulo-pedunculari+	Tractus habenulointercruralis	.....
.....	Tractus olfactohippocampicus	.....
Tractus olfacto-habenularis+	Tractus olfactohabenularis	.....
Tractus olfacto-mesencephalicus+	Tractus olfactomesencephalicus	.....
Fibrae cerebelloolivares ..	{Tractūs olivocerebellares {Tractus dentatoolivaris	Tractus olivocerebellaris
Tractus ponto-cerebellares+	Tractūs pontocerebellares	.....
.....	Tractus pulvinocorticalis (radiationis opticae) ...	.....

BNA	JNA	PNA
.....	Tractus rubrolemniscalis .	.....
Tractus rubro-reticularis+	Tractus rubroreticularis ..	Fasciculi rubroreticulares
Tractus rubro-spinalis+ .	Tractus rubrospinalis ...	Tractus rubrospinalis
.....	.....	Tractus reticulospinales
.....	Tractus rubrothalamicus .	.....
.....	Tractus spinobulbaris	.....
Tractus spino-olivaris+ ..	Tractus spinoolivaris	.....
Fasciculus anterolateralis superficialis (Gowersi) .	Tractus spino-cerebellaris ventralis	Tractus spinocerebellaris anterior
Fasciculus cerebellospinalis	Tractus spino-cerebellaris dorsalis	Tractus spinocerebellaris posterior
.....	.....	Fasciculus dorsolateralis
Tractus bulbo-thalamicus+	Tractus bulbothalamicus	.....
Tractus spino-tectalis+ ...	Tractus spinotectalis	Tractus spinotectalis
Tractus spino-thalamicus	Tractus spinothalamicus .	Tractus spinothalamicus anterior Tractus spinothalamicus lateralis
Tractus tecto-bulbaris+ ..	Tractus tectobulbaris	.....
Tractus tecto-spinalis+ ...	Tractus tectospinalis medialis, lateralis	Tractus tectospinalis
Tractus thalamo-habenularis+	Tractus thalamohabenularis	.....
.....	Tractus thalamoolivaris ..	Tractus tegmentalis centralis
Tractus thalamo-spinalis+	Tractus thalamospinalis ..	.....
Tractus vestibulo-spinalis+	Tractus vestibulospinalis .	Tractus vestibulospinalis
Fasciculus gracilis (Golli)	Pars medialis (fasciculi dorsalis)	Fasciculus gracilis
Fasciculus cuneatus (Burdachi)	Pars lateralis (fasciculi dorsalis)	Fasciculus cuneatus
.....	.....	Fasciculus septomarginalis
.....	.....	Fasciculus triangularis
.....	.....	Fasciculus semilunaris (Fasciculus interfascicularis)

BNA	JNA	PNA
Fibrae arcuatae internae .	Fibrae arcuatae internae .	Fibrae arcuatae internae
Fibrae arcuatae externae .	Fibrae arcuatae externae .	.....
.....	Fibrae arcuatae externae ventrales	Fibrae arcuatae externae ventrales
.....	Fibrae arcuatae externae dorsales	Fibrae arcuatae externae dorsales
Lemniscus medialis (sensitivum)	Lemniscus medialis	Lemniscus medialis Lemniscus spinalis Lemniscus trigeminalis
Decussatio lemniscorum .	Decussatio lemniscorum .	Decussatio lemniscorum (Decussatio sensoria)
.....	Tractus lemnisci medialis	.....
.....	Tractus lemnisci lateralis (acustici)	.....
Lemniscus lateralis (acusticus)	Lemniscus lateralis	Lemniscus lateralis
Tractus solitarius	Fasciculus solitarius	Tractus solitarius
Tractus spinalis n. trigemini	.....	Tractus spinalis n. trigemini
Striae medullares	Striae medullares	Striae medullares ventriculi quarti**
Radix descendens (mesencephalica) n. trigemini .	.....	Tractus mesencephalicus n. trigemini
Fasciculus longitudinalis medialis	Tractus longitudinalis medialis	Fasciculus longitudinalis medialis
.....	Tractūs medullae spin. ..	.....
Tractus nucleo-cerebellaris+	Tractūs nucleocerebellares	.....
.....	Fasciculus longitudinalis dorsalis	Fasciculus longitudinalis dorsalis
.....	.....	Fibrae periventriculares
Fibrae pontis profundae .	Fibrae pontis profundae .	Fibrae pontis transversae
Fibrae pontis superfic. ...	Fibrae pontis superfic. ...	.....
Ansa peduncularis	Ansa cruralis	Ansa peduncularis

BNA	JNA	PNA
Ansa lenticularis	Ansa lenticularis	Ansa lenticularis
Brachium quadrigeminum superius	Brachium colliculi rostralis	Brachium colliculi sup.
Brachium quadrigeminum inferius	Brachium colliculi caudalis	Brachium colliculi inf.
Stria medullaris	Stria medullaris	Stria medullaris thalami
.....	Fibrae striarum medullarium	.....
Stria longitudinalis med. .	Stria longitudinalis med. .	Stria longitudinalis med.
Stria longitudinalis lat. ..	Stria longitudinalis lat. ..	Stria longitudinalis lat.
Fasciculus retroflexus (Meynerti)	Fasciculus retroflexus	Fasciculus retroflexus
Stria terminalis	Stria terminalis	Stria terminalis
Tractus olfactorius	Tractus olfactorius	Tractus olfactorius
Tractus opticus	Tractus opticus	Tractus opticus
.....	.....	Tractus supraopticohypophysialis*
.....	.....	Pedunculus cerebellaris inferior
.....	.....	Pedunculus cerebellaris medius
.....	.....	Pedunculus cerebellaris superior
Pedunculus corporis mamillaris+	Pedunculus corporis mamillaris	Pedunculus corporis mamillaris
Corpus trapezoideum	Corpus trapezoides	Corpus trapezoideum
.....	.....	Fasciculus subcallosus
MENINGES	*MENINGES*	*MENINGES*
DURA MATER ENCEPHALI	PACHYMENINX = DURA MATER ENCEPHALI	DURA MATER ENCEPHALI
Falx cerebri	Falx cerebri	Falx cerebri
Tentorium cerebelli	Tentorium cerebelli	Tentorium cerebelli
Falx cerebelli	Falx cerebelli	Falx cerebelli
Diaphragma sellae	Diaphragma sellae	Diaphragma sellae
Foramen diaphragmatis (sellae)	.....	.....
Incisura tentorii	Incisura tentorii	Incisura tentorii
.....	.....	Cavum trigeminale*

BNA	JNA	PNA
DURA MATER SPINALIS	DURA MATER SPINALIS	DURA MATER SPINALIS
Filum durae matris spinalis	Filum durae matris spinalis	Filum durae matris spinalis
Cavum epidurale	Cavum extradurale	Cavum epidurale
Cavum subdurale	Cavum subdurale	.....*
.....	Leptomeninx	.....
.....	Septum leptomeningicum spinale	.....
ARACHNOIDEA SPINALIS	ARACHNOIDES SPINALIS	ARACHNOIDEA SPINALIS
.....	.....	Cavum subarachnoideale**
.....	.....	Liquor cerebrospinalis**
ARACHNOIDEA ENCEPHALI	ARACHNOIDES ENCEPHALI	ARACHNOIDEA ENCEPHALI
Cavum subarachnoidale .	Cavum leptomeningicum .	Cavum subarachnoideale
.....	.....	Liquor cerebrospinalis*
Cisternae subarachnoidales	*Cisternae leptomeningicae*	*Cisternae subarachnoideales*
Cisterna cerebellomedullaris	Cisterna cerebellomedullaris	Cisterna cerebellomedullaris
Cisterna fossae lateralis cerebri (Sylvii)	Cisterna valleculae lateralis cerebri	Cisterna fossae lateralis cerebri
Cisterna chiasmatis	Cisterna chiasmatis	Cisterna chiasmatis
Cisterna ambiens	Cisterna ambiens	.....
.....	Cisterna corporis callosi .	.....
Cisterna interpeduncularis	Cisterna intercruralis	Cisterna interpeduncularis
Cisterna venae magnae cerebri	Cisterna venae cerebralis magnae	.....
Granulationes arachnoidales (Pacchioni)	Granula meningica	Granulationes arachnoideales
PIA MATER SPINALIS	PIA MATER SPINALIS	PIA MATER SPINALIS
Lig. denticulatum	Lig. denticulatum	Lig. denticulatum
Septum cervicale intermedium	Septum cervicale medium	Septum cervicale intermedium

BNA	JNA	PNA
PIA MATER ENCEPHALI	PIA MATER ENCEPHALI	PIA MATER ENCEPHALI
Tela chorioidea ventriculi quarti	Tela chorioidea ventriculi quarti	Tela choroidea ventriculi quarti*
Plexus chorioideus ventriculi quarti	Plexus chorioideus ventriculi quarti	Plexus choroideus ventriculi quarti*
Tela chorioidea ventriculi tertii	Tela chorioidea ventriculi tertii	Tela choroidea ventriculi tertii*
Plexus chorioideus ventriculi tertii	Plexus chorioideus ventriculi tertii	Plexus choroideus ventriculi tertii*
.....	Tela chorioidea partis lat. ventriculi telencephali .	.....
Plexus chorioideus ventriculi laterialis	Plexus chorioideus partis lateralis ventriculi telencephali	Plexus choroideus ventriculi lateralis*
Glomus chorioideum	Glomus chorioideum	Glomus choroideum*
Acervulus	.....	.....
SYSTEMA NERVORUM PERIPHERICUM	SYSTEMA NERVORUM PERIPHERICUM	SYSTEMA NERVOSUM PERIPHERICUM
NERVI CEREBRALES	*NERVI CAPITALES*	*NERVI CRANIALES*
NN. OLFACTORII	FILA OLFACTORIA	NN. OLFACTORII
N. OPTICUS	FASCICULUS OPTICUS	N. OPTICUS
N. OCULOMOTORIUS	N. OCULOMOTORIUS	N. OCULOMOTORIUS
Ramus superior	Ramus superior	Ramus superior
Ramus inferior	Ramus inferior	Ramus inferior
.....	Rami musculares intrabulbares	.....
Radix brevis ganglii ciliaris	Radix brevis ganglii ciliaris	Radix oculomotoria

BNA	JNA	PNA
N. TROCHLEARIS	N. TROCHLEARIS	N. TROCHLEARIS
Decussatio nervorum trochlearium	Decussatio nervorum trochlearium	Decussatio nervorum trochlearium
N. TRIGEMINUS	N. TRIGEMINUS	N. TRIGEMINUS
Portio major	Portio major	Radix sensoria*
Ganglion semilunare (Gasseri)	Ganglion semilunare ..	Ganglion trigeminale*
Portio minor	Portio minor	Radix motoria*
N. ophthalmicus	*N. ophthalmicus*	*N. ophthalmicus*
N. tentorii	R. meningicus	R. tentorii
N. lacrimalis	N. lacrimalis	N. lacrimalis
R. anastomoticus cum n. zygomatico	R. communicans cum n. zygomatico	R. communicans cum n. zygomatico
N. frontalis	N. frontalis	N. frontalis
N. supraorbitalis	R. lateralis (n. frontalis)	N. supraorbitalis*
		Ramus lateralis
		Ramus medialis
Ramus frontalis	R. medialis (n. frontalis)	.....
N. supratrochlearis	N. supratrochlearis	N. supratrochlearis
N. nasociliaris	N. nasociliaris	N. nasociliaris
Radix longa ganglii ciliaris	.....	R. communicans cum ganglione ciliari
Nn. ciliares longi	Nn. ciliares longi	Nn. ciliares longi
N. ethmoidalis posterior	N. ethmoideus posterior	N. ethmoidalis post.
N. ethmoidalis anterior	N. ethmoideus anterior	N. ethmoidalis anterior
Rami nasales interni	Rami nasales interni	Rami nasales interni
Rami nasales anteriores	Rr. nasales	Rr. nasales (n. ethmoidalis ant.)
Rami nasales laterales	Rr. nasales anteriores laterales	Rr. nasales laterales
Rami nasales mediales	Rr. nasales anteriores septi	Rami nasales mediales

BNA	JNA	PNA
Ramus nasalis externus	Ramus nasalis externus	Ramus nasalis ext.
N. infratrochlearis	N. infratrochlearis	N. infratrochlearis
R. palpebralis superior	R. palpebralis superior	Rr. palpebrales
R. palpebralis inferior	R. palpebralis inferior	
Ganglion ciliare	*Ganglion ciliare*	*Ganglion ciliare*
Nn. ciliares breves	Nn. ciliares breves	Nn. ciliares breves
.....	.....	R. communicans cum n. nasociliari
Radices sympathicae ganglii ciliaris	Radices sympathicae ganglii ciliaris	(Ramus sympathicus ad ganglion ciliare)
N. maxillaris	*N. maxillaris*	*N. maxillaris*
N. meningeus (medius) ..	R. meningicus	R. meningeus (medius)
N. zygomaticus	N. zygomaticus	N. zygomaticus
R. zygomaticotemporalis	N. zygomaticotemporalis	R. zygomaticotemporalis
R. zygomaticofacialis ..	N. zygomaticofacialis ..	R. zygomaticofacialis
Nn. sphenopalatini	Nn. pterygopalatini	Nn. pterygopalatini
Nn. alveolares superiores	.....	Nn. alveolares superiores
Rr. alveolares superiores posteriores	Rr. alveolares maxillares posteriores	Rr. alveolares superiores posteriores
N. infraorbitalis	N. infraorbitalis	N. infraorbitalis
R. alveolaris superior medius	R. alveolaris maxillaris medius	R. alveolaris superior medius

BNA	JNA	PNA
Rr. alveolares superiores anteriores	Rr. alveolares maxillares anteriores	Rr. alveolares superiores anteriores
Plexus dentalis sup. ...	Plexus dentalis maxillaris	Plexus dentalis sup.
Rami dentales superiores	Rr. dentales maxillares	Rr. dentales superiores
Rami gingivales superiores	Rr. gingivales maxillares	Rr. gingivales superiores
Rami palpebrales inferiores	Rr. palpebrales inferiores	Rr. palpebrales inferiores
.....	Ramus nasalis	.....
Rami nasales externi	Rr. nasales externi	Rr. nasales externi
Rami nasales interni	Rr. nasales interni	Rr. nasales interni
Rami labiales superiores	Rr. labiales maxillares	Rr. labiales superiores
Ganglion sphenopalatinum	*Ganglion pterygopalatinum*	*Ganglion pterygopalatinum*
Rami orbitales	Rr. orbitales	Rr. orbitales .....
N. canalis pterygoidei (Vidii)	N. canalis pterygoidei ...	N. canalis pterygoidei (Radix facialis)
N. petrosus superficialis major	N. petrosus superficialis major	N. petrosus major
.....	Rr. lacrimales n. petrosi superficialis majoris .	.....
N. petrosus profundus	N. petrosus profundus	N. petrosus profundus
Rami nasales posteriores superiores laterales ...	Rr. nasales posteriores laterales	Rami nasales posteriores superiores laterales

BNA	JNA	PNA
Rami nasales posteriores superiores mediales	Rr. nasales posteriores septi	Rami nasales posteriores superiores mediales
N. nasopalatinus (Scarpae)	N. nasopalatinus	N. nasopalatinus
Nn. palatini	Nn. palatini	.....
N. palatinus anterior	N. palatinus major	N. palatinus major*
Rami nasales posteriores inferiores (laterales)	.....	Rami nasales posteriores inferiores (laterales)
N. palatinus medius .	N. palatinus medius ..	Nn. palatini minores*
N. palatinus post. ..	N. palatinus minor ..	
.....	.....	Ramus pharyngeus*
.....	Radix sympathica ganglii pterygopalatini	.....
N. mandibularis	*N. mandibularis*	*N. mandibularis*
N. spinosus	Ramus meningicus	Ramus meningeus (n. mandibularis)
N. masticatorius	.....	.....
N. massetericus	N. massetericus	N. massetericus
Nn. temporales profundi	Nn. temporales profundi	Nn. temporales profundi
N. temporalis profundus posterior.	N. temporalis profundus posterior.	.....
N. temporalis profundus anterior .	N. temporalis profundus anterior .	.....
N. buccinatorius	N. buccalis	N. buccalis
N. pterygoideus externus	N. pterygoideus lateralis	N. pterygoideus lateralis
N. pterygoideus internus	N. pterygoideus medialis	N. pterygoideus medialis
N. auriculotemporalis ...	N. auriculotemporalis ...	N. auriculotemporalis
N. meatus auditorii externi	N. meatus acustici externi	N. meatus acustici externi
R. membranae tympani	R. membranae tympani	R. membranae tympani

BNA	JNA	PNA
Rami parotidei	Rami parotidici	Rami parotidei
Rami anastomotici cum n. faciali	Rami communicantes cum n. faciali	Rami communicantes cum n. faciali
Nn. auriculares anteriores	Nn. auriculares temporales	Nn. auriculares anteriores
Rami temporales superficiales	Rami temporales superficiales	Rami temporales superficiales
N. lingualis	N. lingualis	N. lingualis
Rami isthmi faucium ..	Rami palatini	Rami isthmi faucium
Ramus anastomoticus cum n. hypoglosso ..	Rami communicantes cum n. hypoglosso ..	Rami communicantes cum n. hypoglosso
.....	.....	Ramus communicans cum chorda tympani*
N. sublingualis	N. sublingualis	N. sublingualis
Rami linguales	Rami linguales	Rami linguales
N. alveolaris inferior ...	N. alveolaris mandibularis	N. alveolaris inferior
Plexus dentalis inferior	Plexus dentalis mandibularis	Plexus dentalis inferior
Rami dentales inferiores	Rami dentales mandibulares	Rami dentales inferiores
Rami gingivales inferiores	Rami gingivales mandibulares	Rami gingivales inferiores
N. mylohyoideus	N. mylohyoideus	N. mylohyoideus
N. mentalis	N. mentalis	N. mentalis
Rami mentales	Rami mentales	Rami mentales
Rami labiales inferiores	Rami labiales mandibulares	Rami labiales inferiores

BNA	JNA	PNA
Ganglion oticum	*Ganglion oticum*	*Ganglion oticum*
N. petrosus superficialis minor	N. petrosum superficialis minor	N. petrosus minor
N. tensoris veli palatini .	N. musculi tensoris veli palatini	N. tensoris veli palatini
N. tensoris tympani	N. musculi tensoris tympani	N. tensoris tympani
Ramus anastomoticus cum n. spinoso	Rr. communicantes	R. communicans cum ramo meningeo (N. mandibularis)
Ramus anastomoticus cum n. auriculotemporali ...	Rr. communicantes	R. communicans cum n. auriculotemporali
Ramus anastomoticus cum chorda tympani	Rr. communicantes cum chorda tympani	R. communicans cum chorda tympani
.....	Radix sympathica ganglii otici	.....
Ganglion submaxillare	*Ganglion submandibulare*	*Ganglion submandibulare*
.....	*var. Ganglion sublinguale*	.....
Rami communicantes cum n. linguali	.....	Rami communicantes cum n. linguali
Rami submaxillares	Rami glandulares	Rami glandulares
Radix sympathica ganglii submaxillaris	Radix sympathica ganglii submandibularis (et sublingualis)	(Ramus sympathicus ad ganglion submandibulare)
N. ABDUCENS	N. ABDUCENS	N. ABDUCENS
N. FACIALIS	N. FACIALIS	N. FACIALIS
Geniculum n. facialis	Geniculum n. facialis	Geniculum n. facialis
Vide: N. intermedius	Vide: N. intermedius	Ganglion geniculi (vide infra)

BNA	JNA	PNA
N. stapedius	N. stapedius	N. stapedius
N. petrosus superficialis major	N. petrosus superficialis major	N. petrosus major*
Ramus anastomoticus cum plexu tympanico	R. communicans cum plexu tympanico	R. communicans cum plexu tympanico
N. auricularis posterior ..	N. retroauricularis	N. auricularis posterior
Ramus occipitalis	Ramus occipitalis	Ramus occipitalis
Ramus digastricus	Ramus biventricus	Ramus digastricus
Ramus stylohyoideus .	Ramus stylohyoideus .	Ramus stylohyoideus*
Ramus anastomoticus cum n. glossopharyngeo	(R. communicans cum n. glossopharyngico)	R. communicans cum n. glossopharyngeo
Plexus parotideus	Plexus parotidicus	Plexus parotideus
Rami temporales	Rami temporofrontales ..	Rami temporales
Rami zygomatici	Rami zygomatici	Rami zygomatici
Rami buccales	Rami bucinatorii	Rami buccales
.....	.....	(Ramus lingualis)*
Ramus marginalis mandibulae	Ramus marginalis mandibulae	Ramus marginalis mandibulae
Ramus colli	Ramus colli	Ramus colli
.....	Ansa cervicalis superfic. .	.....
N. intermedius	*N. intermedius*	*N. intermedius*
Ganglion geniculi	Ganglion geniculi	Ganglion geniculi
Chorda tympani	Chorda tympani	Chorda tympani
.....	Rami glandulares chordae tympani	.....
N. ACUSTICUS	N. STATOACUSTICUS	N. VESTIBULOCOCHLEARIS* (N. OCTAVUS)
Radix vestibularis	.....	Radix superior (vestibularis)**
Radix cochlearis	.....	Radix inferior (cochlearis)**
Fila anastomotica	.....	.....

BNA	JNA	PNA
N. vestibuli	*N. vestibuli = N. staticus*	*Pars vestibularis (n. octavi)*
Ganglion vestibulare	Ganglion vestibuli	Ganglion vestibulare Pars inferior Pars superior
N. utricularis	Ramus utriculi	N. utricularis*
.....	N. utriculoampullaris	N. utriculoampullaris
N. ampullaris superior ..	Ramus ampullae superioris	N. ampullaris anterior
N. ampullaris lateralis ...	Ramus ampullae lateralis .	N. ampullaris lateralis
N. ampullaris inferior ...	Nervus ampullae posterioris	N. ampullaris posterior
N. cochleae	*N. cochleae = N. acusticus*	*Pars cochlearis (n. octavi)*
Ganglion spirale	.....	Ganglion spirale
N. saccularis	N. sacculi	N. saccularis
N. GLOSSOPHARYNGEUS	N. GLOSSOPHARYNGICUS	N. GLOSSOPHARYNGEUS
Ganglion superius	Ganglion intracraniale ...	Ganglion superius
Ganglion petrosum	Ganglion extracraniale ...	Ganglion inferius
N. tympanicus	N. tympanicus	N. tympanicus
Intumescentia tympanica .	Intumescentia tympanica .	Ganglion tympanicum
Plexus tympanicus (Jacobsoni)	Plexus tympanicus	Plexus tympanicus
.....	.....	N. petrosus minor*
N. caroticotympanicus superior .... N. caroticotympanicus inferior	Nn. caroticotympanici	Nn. caroticotympanici
Ramus tubae	R. tubae pharyngotympanicae	R. tubarius*
R. anastomoticus cum ramo auriculari n. vagi .	(Ramus communicans cum ramo auriculari n. vagi)	R. communicans cum ramo auriculari n. vagi
.....	Rami glandulares n. glossopharyngici	.....
Rami pharyngei	Rami pharyngici	Rami pharyngei
.....	.....	R. sinus carotici
R. stylopharyngeus	R. stylopharyngicus	R. m. stylopharyngei
Rr. tonsillares	Rr. tonsillares	Rr. tonsillares
Rr. linguales	Rr. linguales	Rr. linguales

BNA	JNA	PNA
N. VAGUS	N. VAGUS	N. VAGUS
Ganglion jugulare	Ganglion jugulare	Ganglion superius
Ganglion nodosum	Ganglion nodosum	Ganglion inferius
R. meningeus	R. meningicus	R. meningeus
R. auricularis	R. auricularis	R. auricularis
R. anastomoticus cum nervo glossopharyngeo ...	(R. communicans cum n. glossopharyngico)	R. communicans cum n. glossopharyngeo
Rr. pharyngei	Rami pharyngici	Rr. pharyngei
Plexus pharyngeus	Plexus pharyngicus	Plexus pharyngeus
N. laryngeus superior ...	N. laryngicus cranialis ...	N. laryngeus superior
.....	Ganglion n. laryngici cranialis	.....
Ramus externus	Ramus externus	Ramus externus
Ramus internus	Ramus internus	Ramus internus
R. anastomoticus cum n. laryngeo inferiore ...	R. communicans cum nervo laryngico caudali	R. communicans cum n. laryngeo inferiore
Rr. cardiaci superiores ..	Rr. cardiaci craniales	Rr. cardiaci cervicales superiores**
(N. depressor)	.....	.....
N. recurrens	N. recurrens	N. laryngeus recurrens
Rr. cardiaci inferiores .	Rr. cardiaci caudales ..	Rr. cardiaci cervicales inferiores**
Rr. tracheales	Rr. tracheales	Rr. tracheales
Rr. oesophagei	Rr. oesophagici	Rr. esophagei*
N. laryngeus inferior .	N. laryngicus caudalis .	N. laryngeus inferior
.....	.....	R. communicans cum r. laryngeo interno*
.....	.....	Rami cardiaci thoracici**
R. anterior	R. ventralis	.....
R. posterior	R. dorsalis	.....
Rr. bronchiales anteriores	Rr. bronchales ventrales	Rr. bronchiales
Rr. bronchiales posteriores	Rr. bronchales dorsales .	
Plexus pulmonalis anterior	Plexus pulmonalis ventralis	Plexus pulmonalis
Plexus pulmonalis post. .	Plexus pulmonalis dorsalis	
Rami oesophagei	Rr. oesophagici	.....

BNA	JNA	PNA
Plexus oesophageus anterior Plexus oesophageus posterior	Plexus oesophagicus	Plexus esophageus*
.....	.....	Truncus vagalis anterior
.....	.....	Truncus vagalis posterior
Rr. gastrici	Rr. gastrici	Rr. gastrici anteriores Rr. gastrici posteriores
Plexus gastricus anterior	Plexus gastricus ventralis	Rami gastrici anteriores
Plexus gastricus posterior	Plexus gastricus dorsalis	Rami gastrici posteriores
Rami hepatici	Rami hepatici	Rami hepatici
Rami coeliaci	Rami coeliaci	Rami celiaci*
Rami lienales	Rami lienales	.....
Rami renales	Rami renales	Rami renales
.....	Rami intestinales	.....
N. ACCESSORIUS	N. ACCESSORIUS	N. ACCESSORIUS
.....	Radix myelencephalica (n. accessorii)	Radices craniales
.....	Radix spinalis (n. accessorii)	Radices spinales
R. internus	R. medialis	R. internus
R. externus	R. lateralis	R. externus
N. HYPOGLOSSUS	N. HYPOGLOSSUS	N. HYPOGLOSSUS
Rr. linguales	Rr. linguales	Rr. linguales
NERVI SPINALES	*NERVI SPINALES*	*NERVI SPINALES*
Fila radicularia	Fila radicularia	Fila radicularia
Radix anterior	Radix ventralis	Radix ventralis
Radix posterior	Radix dorsalis	Radix dorsalis
Ganglion spinale	Ganglion spinale	Ganglion spinale
Ramus anterior	Ramus ventralis	Ramus ventralis
Ramus posterior	Ramus dorsalis	Ramus dorsalis
Ramus communicans	Ramus communicans	Rr. communicantes
Ramus meningeus	Ramus meningicus	Ramus meningeus
Cauda equina	Cauda equina	Cauda equina
Ansae	Ansae	Ansae

BNA	JNA	PNA
NN. CERVICALES	NN. CERVICALES	NN. CERVICALES
Rami posteriores	Rami dorsales	Rami dorsales
Ramus medialis	Ramus medialis	Ramus medialis
Ramus lateralis	Ramus lateralis	Ramus lateralis
N. suboccipitalis	N. suboccipitalis	N. suboccipitalis
N. occipitalis major	N. occipitalis major	N. occipitalis major
(N. occipitalis tertius)	var. N. occipitalis tertius	(N. occipitalis tertius)
Rami anteriores	Rami ventrales	Rami ventrales
PLEXUS CERVICALIS	*PLEXUS CERVICALIS*	*PLEXUS CERVICALIS*
Ansa n. hypoglossi	Ansa n. hypoglossi	Ansa cervicalis
R. descendens	R. descendens	Radix superior*
	N. cervicalis descendens	Radix inferior*
R. thyreohyoideus	R. thyreohyoideus	Ramus thyrohyoideus*
N. occipitalis minor	N. occipitalis minor	N. occipitalis minor
N. auricularis magnus	N. auricularis magnus	N. auricularis magnus
R. posterior	R. posterior	R. posterior
R. anterior	R. anterior	R. anterior
N. cutaneus colli	N. cutaneus colli	N. transversus colli
Rr. superiores	Rr. craniales	Rr. superiores
Rr. inferiores	Rr. caudales	Rr. inferiores
Nn. supraclaviculares	Nn. supraclaviculares	Nn. supraclaviculares
Nn. supraclaviculares anteriores		Nn. supraclaviculares mediales*
Nn. supraclaviculares medii		Nn. supraclaviculares intermedii*
Nn. supraclaviculares posteriores		Nn. supraclaviculares laterales (posteriores)*
N. phrenicus	N. phrenicus	N. phrenicus
R. pericardiacus	R. pericardiacus	R. pericardiacus
Rr. phrenicoabdominales	Rr. abdominales Rr. phrenici	Rr. phrenicoabdominales*
		Nn. phrenici accessorii
PLEXUS BRACHIALIS	*PLEXUS BRACHIALIS*	*PLEXUS BRACHIALIS*
	RADICES PLEXŪS (BRACHIALIS)	TRUNCI PLEXUS
	Truncus caudalis	Truncus inferior

BNA	JNA	PNA
.....	Truncus cranialis	Truncus superior
.....	Truncus intermedius	Truncus medius
PARS SUPRACLAVICULARIS	PARS SUPRACLAVICULARIS	PARS SUPRACLAVICULARIS
Nn. thoracales post.	Nn. thoracici dorsales ..	.....
N. dorsalis scapulae ...	N. dorsalis scapulae ...	N. dorsalis scapulae
N. thoracalis longus ..	N. thoracicus longus ..	N. thoracicus longus
Nn. thoracales anteriores	Nn. thoracici ventrales ..	.....
N. subclavius	N. subclavius	N. subclavius
N. suprascapularis	N. suprascapularis	N. suprascapularis
Nn. subscapulares	Nn. subscapulares	Vide: N. radialis**
N. thoracodorsalis	N. thoracodorsalis	Vide: N. radialis**
PARS INFRACLAVICULARIS	PARS INFRACLAVICULARIS	PARS INFRACLAVICULARIS
Fasciculus lateralis	Fasciculus radialis	Fasciculus lateralis
Fasciculus medialis	Fasciculus ulnaris	Fasciculus medialis
Fasciculus posterior	Fasciculus dorsalis	Fasciculus posterior
.....	.....	N. pectoralis medialis*
.....	.....	N. pectoralis lateralis*
N. MUSCULOCUTANEUS	N. MUSCULOCUTANEUS	N. MUSCULOCUTANEUS
Rr. musculares	.....	Rr. musculares
N. cutaneus antibrachii lateralis	N. cutaneus antebrachii radialis	N. cutaneus antebrachii lateralis
N. CUTANEUS BRACHII MEDIALIS	N. CUTANEUS BRACHII ULNARIS	N. CUTANEUS BRACHII MEDIALIS
N. CUTANEUS ANTIBRACHII MEDIALIS	N. CUTANEUS ANTEBRACHII ULNARIS	N. CUTANEUS ANTEBRACHII MEDIALIS
Ramus volaris	R. volaris	R. anterior
Ramus ulnaris	R. ulnaris	R. ulnaris
N. MEDIANUS	N. MEDIANUS	N. MEDIANUS
.....	Radix medialis	Radix medialis
.....	Radix lateralis	Radix lateralis
Rami musculares	.....	Rami musculares
N. interosseus (antibrachii) volaris	N. interosseus antebrachii volaris	N. interosseus (antebrachii) anterior

BNA	JNA	PNA
R. palmaris n. mediani ..	Ramus palmaris	R. palmaris n. mediani
Ramus anastomoticus cum n. ulnari	R. communicans cum n. ulnari	R. communicans cum n. ulnari
Nn. digitales volares communes	Nn. digitales volares communes	Nn. digitales palmares communes
Nn. digitales volares proprii	Nn. digitales volares proprii	Nn. digitales palmares proprii
N. ULNARIS	N. ULNARIS	N. ULNARIS
Ramus cutaneus palmaris	Ramus palmaris	.....**
Ramus dorsalis manus ..	Ramus dorsalis manus ..	Ramus dors. n. ulnaris*
Nn. digitales dorsales .	Nn. digitales manus dorsales	Nn. digitales dorsales
Ramus volaris manus ...	Ramus volaris manus ...	R. palmaris n. ulnaris*
Ramus superficialis	Ramus superficialis	Ramus superficialis
Nn. digitales volares communes	Nn. digitales volares communes	Nn. digitales palmares communes
Nn. digitales volares proprii	Nn. digitales volares proprii	Nn. digitales palmares proprii
Ramus profundus	Ramus profundus	Ramus profundus
Rami musculares	.....	Rami musculares
N. RADIALIS	N. RADIALIS	N. RADIALIS
N. cutaneus brachii post.	N. cutaneus brachii dors.	N. cutaneus brachii post.
.....	.....	N. cutaneus brachii lateralis inferior*
Rami musculares	.....	Rami musculares
N. cutaneus antibrachii dorsalis	N. cutaneus antebrachii dorsalis	N. cutaneus antebrachii posterior
Ramus profundus	Ramus profundus	Ramus profundus

BNA	JNA	PNA
N. interosseus (antibrachii) dorsalis	N. interosseus antebrachii dorsalis	N. interosseus (antebrachii) posterior
Ramus superficialis	Ramus superficialis	Ramus superficialis
R. anastomoticus ulnaris	Ramus communicans ulnaris	Ramus communicans ulnaris
Nn. digitales dorsales .	Nn. digitales manus dorsales	Nn. digitales dorsales
Vide: Pars supraclavicularis	Vide: Pars supraclavicularis	N. subscapularis**
Vide: Pars supraclavicularis	Vide: Pars supraclavicularis	N. thoracodorsalis**
N. AXILLARIS	N. AXILLARIS	N. AXILLARIS
Rr. musculares	.....	Rr. musculares
N. cutaneus brachii lateralis	R. cutaneus brachii radialis	N. cutaneus brachii lateralis superior*
NN. THORACALES	NN. THORACICI	NN. THORACICI
Rami posteriores	Rami dorsales	Rami dorsales
Ramus cutaneus lat. ..	Ramus cutaneus lat. ..	Ramus cutaneus lat.
Ramus cutaneus medialis	Ramus cutaneus medialis	Ramus cutaneus med.
Rami anteriores (Nn. intercostales)	Rami ventrales = Nn. intercostales	Rr. ventrales (Nn. intercostales)
Rami musculares	.....	.....
Ramus cutaneus lateralis (pectoralis et abdominalis)	Ramus cutaneus lateralis	R. cutaneus lateralis (pectoralis et abdominalis)

BNA	JNA	PNA
Ramus posterior (pectoralis et abdominalis)	Ramus dorsalis	.....
Ramus anterior	Ramus ventralis	.....
Rami mammarii laterales	Rami mammarii laterales	Rami mammarii laterales
Nn. intercostobrachiales	Nn. intercostobrachiales	Nn. intercostobrachiales
Ramus cutaneus anterior (pectoralis et abdominalis)	Ramus cutaneus ventralis	Ramus cutaneus anterior (pectoralis et abdominalis)
Rami mammarii mediales	Rami mammarii mediales	Rami mammarii mediales
N. subcostalis	N. subcostalis	N. subcostalis*
NN. LUMBALES, NN. SACRALES, N. COCCYGEUS	**NN. LUMBALES, NN. SACRALES, N. COCCYGICUS**	**NN. LUMBALES, NN. SACRALES, N. COCCYGEUS**
NN. LUMBALES	NN. LUMBALES	NN. LUMBALES
Rami posteriores	Rami dorsales	Rami dorsales
Ramus medialis	Ramus medialis	Ramus medialis
Ramus lateralis	Ramus lateralis	Ramus lateralis
Nn. clunium superiores	Nn. clunium craniales	Nn. clunium superiores
Rami anteriores	Rami ventrales	Rami ventrales
NN. SACRALES ET N. COCCYGEUS	NN. SACRALES ET N. COCCYGICUS	NN. SACRALES ET N. COCCYGEUS
Rami posteriores	Rami dorsales	Rami dorsales
Ramus medialis	Ramus medialis	Ramus medialis
Ramus lateralis	Ramus lateralis	Ramus lateralis
Nn. clunium medii	Nn. clunium medii	Nn. clunium medii
.....	.....	Rami ventrales

BNA	JNA	PNA
PLEXUS LUMBOSACRALIS	*PLEXUS LUMBOSACRALIS*	*PLEXUS LUMBOSACRALIS*
PLEXUS LUMBALIS	*PLEXUS LUMBALIS*	*PLEXUS LUMBALIS*
Rami musculares	.....	.....
N. ILIOHYPOGASTRICUS	N. ILIOHYPOGASTRICUS	N. ILIOHYPOGASTRICUS
Rami musculares	.....	.....
Ramus cutaneus lateralis	Ramus cutaneus lateralis	Ramus cutaneus lateralis
Ramus cutaneus anterior	Ramus cutaneus ventr. ..	Ramus cutaneus anterior
N. ILIOINGUINALIS	N. ILIOINGUINALIS	N. ILIOINGUINALIS
Rami musculares	.....	.....
Nn. scrotales anteriores .	Rami scrotales (n. ilioinguinalis)	Nn. scrotales anteriores
Nn. labiales anteriores ..	Rami labiales (n. ilioinguinalis)	Nn. labiales anteriores
N. GENITOFEMORALIS	N. GENITOFEMORALIS	N. GENITOFEMORALIS
N. lumboinguinalis	Ramus femoralis	Ramus femoralis
N. spermaticus externus .	Ramus genitalis	Ramus genitalis
N. CUTANEUS FEMORIS LATERALIS	N. CUTANEUS FEMORIS FIBULARIS	N. CUTANEUS FEMORIS LATERALIS
N. OBTURATORIUS	N. OBTURATORIUS	N. OBTURATORIUS
Ramus anterior	Ramus superficialis	Ramus anterior
Ramus cutaneus	Ramus cutaneus	Ramus cutaneus
Ramus posterior	Ramus profundus	Ramus posterior
.....	.....	Rami musculares
N. FEMORALIS	N. FEMORALIS	N. FEMORALIS
Rami cutanei anteriores .	Rami cutanei ventrales ..	Rami cutanei anteriores
Rami musculares	.....	Rami musculares
N. saphenus	N. saphenus	N. saphenus
Ramus infrapatellaris ..	Ramus infrapatellaris ..	Ramus infrapatellaris
Rami cutanei cruris mediales	Rami cutanei cruris tibiales	Rami cutanei cruris mediales
PLEXUS SACRALIS	*PLEXUS SACRALIS*	*PLEXUS SACRALIS*
.....	*PLEXUS ISCHIADICUS*	.....
Truncus lumbosacralis ...	Truncus lumbosacralis ...	Truncus lumbosacralis

BNA	JNA	PNA
N. glutaeus superior	N. glutaeus cranialis	N. gluteus superior
N. glutaeus inferior	N. glutaeus caudalis	N. gluteus inferior
N. cutaneus femoris posterior	N. cutaneus femoris dorsalis	N. cutaneus femoris posterior
Nn. clunium inferiores	Nn. clunium caudales	Nn. clunium inferiores
Rami perineales	Rami perineales	Rami perineales
N. ISCHIADICUS	N. ISCHIADICUS	N. ISCHIADICUS
Rami musculares	.....	.....
N. PERONAEUS COMMUNIS	N. FIBULARIS COMMUNIS	N. PERONEUS (FIBULARIS) COMMUNIS
Rami musculares	.....	.....
N. cutaneus surae lateralis	N. cutaneus surae fibularis	N. cutaneus surae lat.
Ramus anastomoticus peronaeus	Ramus communicans fibularis	R. communicans peroneus (fibularis)
N. peronaeus superficialis	N. fibularis superficialis .	N. peroneus (fibularis) superficialis
Rami musculares	.....	Rami musculares
N. cutaneus dorsalis medialis	N. cutaneus dorsi pedis tibialis	N. cutaneus dorsalis med.
N. cutaneus dorsalis intermedius	N. cutaneus dorsi pedis medius	N. cutaneus dorsalis intermedius
Nn. digitales dorsales pedis	Nn. digitales dorsales pedis	Nn. digitales dorsales pedis
N. peronaeus profundus	N. fibularis profundus ...	N. peroneus (fibularis) profundus
Rami musculares	.....	Rami musculares

BNA	JNA	PNA
Nn. digitales dorsales hallucis lat. et digiti secundi medialis	Nn. digitales dorsales hallucis fibularis et digiti secundi tibialis ..	Nn. digitales dorsales hallucis lateralis et digiti secundi medialis
N. TIBIALIS	N. TIBIALIS	N. TIBIALIS
Rami musculares	.....	Rami musculares
N. interosseus cruris	N. interosseus cruris	N. interosseus cruris
N. cutaneus surae medialis ..... (N. suralis)	N. suralis	N. cutaneus surae medialis N. suralis
Rami calcanei laterales	Rami calcaneares fibulares	Rami calcanei laterales
N. cutaneus dorsalis lateralis	N. cutaneus dorsi pedis fibularis	N. cutaneus dorsalis lateralis
Rami calcanei mediales ..	Rami calcaneares tibiales	Rami calcanei mediales
N. plantaris medialis ...	N. plantaris tibialis	N. plantaris medialis
Nn. digitales plantares communes	Nn. digitales plantares communes	Nn. digitales plantares communes
Nn. digitales plantares proprii	Nn. digitales plantares proprii	Nn. digitales plantares proprii
N. plantaris lateralis	N. plantaris fibularis	N. plantaris lateralis
Ramus superficialis	Ramus superficialis	Ramus superficialis
Nn. digitales plantares communes	Nn. digitales plantares communes	Nn. digitales plantares communes
Nn. digitales plantares proprii	Nn. digitales plantares proprii	Nn. digitales plantares proprii
Ramus profundus	Ramus profundus	Ramus profundus

BNA	JNA	PNA
PLEXUS PUDENDUS	*PLEXUS PUDENDALIS*	*NERVUS PUDENDUS*
Nn. haemorrhoidales medii	Nn. rectales caudales	
Nn. vesicales inferiores	Nn. vesicales caudales	
N. pudendus	N. pudendalis	N. pudendus
Nn. haemorrhoidales inferiores	Nn. anales	Nn. rectales inferiores
Nn. perinei	N. perinealis	Nn. perineales*
Nn. scrotales posteriores	Nn. scrotales	Nn. scrotales posteriores
Nn. labiales posteriores	Nn. labiales	Nn. labiales posteriores
N. dorsalis penis	N. dorsalis penis	N. dorsalis penis
N. dorsalis clitoridis	N. dorsalis clitoridis	N. dorsalis clitoridis
	N. m. coccygici	
	N. m. levatoris ani	
N. COCCYGEUS	N. COCCYGICUS	N. COCCYGEUS
Plexus coccygeus		Plexus coccygeus
Nn. anococcygei	Nn. anococcygici	Nn. anococcygei
SYSTEMA NERVORUM SYMPATHICUM	*SYSTEMA NERVORUM SYMPATHICUM*	*SYSTEMA NERVOSUM AUTONOMICUM*
		Pars sympathica
Truncus sympathicus	Truncus sympathicus	Truncus sympathicus
		Ganglia intermedia
Ganglia trunci sympathici	Ganglia trunci sympathici	Ganglia tr. sympathici
		Rr. interganglionares
		Rr. communicantes
Plexus sympathici	Plexus sympathici	Plexus autonomici
Ganglia plexuum sympathicorum	Ganglia plexuum sympathicorum	Ganglia plexuum autonomicorum
		Pars parasympathica
PARS CEPHALICA ET CERVICALIS SYSTEMATIS SYMPATHICI	PARS CEPHALICA ET CERVICALIS SYSTEMATIS SYMPATHICI	PARS CEPHALICA ET CERVICALIS SYSTEMATIS AUTONOMICI
	Nervus terminalis	Nn. terminales
		Ganglion terminale

BNA	JNA	PNA
Ganglion ciliare	Ganglion ciliare	Ganglion ciliare
Ganglion sphenopalatinum	Ganglion pterygopalatinum	Ganglion pterygopalatinum
Ganglion oticum	Ganglion oticum	Ganglion oticum
Ganglion submaxillare	Ganglion submandibulare	Ganglion submandibulare
Ganglion cervicale sup.	Ganglion cervicale craniale	Ganglion cervicale superius
N. jugularis	N. jugularis	N. jugularis
N. caroticus internus	N. caroticus internus	N. caroticus internus
Plexus caroticus internus	Plexus caroticus internus	Plexus caroticus internus
Plexus cavernosus		
Plexus arteriae cerebri anterioris		
Plexus arteriae cerebri mediae		
Plexus arteriae choriodeae		
Plexus ophthalmicus		
Radices sympathicae ganglii ciliaris	Radices sympathicae ganglii ciliaris	Vide: N. oculomotorius.*
Nn. carotici externi	Nn. carotici externi	Nn. carotici externi
Plexus caroticus externus	Plexus caroticus externus	Plexus caroticus externus
lexus thyreoideus superior		
Plexus lingualis		
Plexus maxillaris externus		
Radix sympathica ganglii submaxillaris	Radix sympathica ganglii submandibularis (et sublingualis)	Vide: N. trigeminus ....*
Plexus occipitalis		
Plexus auricularis posterior		
Plexus temporalis superficialis		
Plexus maxillaris internus		
Plexus meningeus		
Plexus caroticus communis	Plexus caroticus communis	Plexus caroticus communis
Rami laryngopharyngei	Rami laryngopharyngici	Rami laryngopharyngei
Plexus pharyngeus ascendens		

BNA	JNA	PNA
N. cardiacus superior ...	N. cardiacus cranialis ...	N. cardiacus cervicalis superior
Ganglion cervicale medium	Ganglion cervicale medium	Ganglion cervicale medium
N. cardiacus medius	N. cardiacus medius	N. cardiacus cervicalis medius
.....	.....	Ganglion vertebrale
Ganglion cervicale inferius	Ganglion cervicale caudale	Ganglion cervicothoracicum (stellatum)
Ansa subclavia (Vieussenii)	Ansa subclavia	Ansa subclavia
N. cardiacus inferior	N. cardiacus caudalis ...	N. cardiacus cervicalis inferior
Plexus subclavius	Plexus subclavius	Plexus subclavius
Plexus thyreoideus inferior	.....	.....
.....	.....	N. vertebralis
Plexus vertebralis	.....	Plexus vertebralis
PARS THORACALIS SYSTEMATIS SYMPATHICI	PARS THORACICA SYSTEMATIS SYMPATHICI	PARS THORACICA SYSTEMATIS AUTONOMICI
Ganglia thoracalia	Ganglia thoracica	Ganglia thoracica
.....	.....	Nn. cardiaci thoracici
.....	Rami oesophagici	.....
N. splanchnicus major ..	N. splanchnicus major ..	N. splanchnicus major
Ganglion splanchnicum ..	Ganglion splanchnicum ..	Ganglion splanchnicum
N. splanchnicus minor ..	N. splanchnicus minor ..	N. splanchnicus minor
Ramus renalis	Ramus renalis	Ramus renalis
(N. splanchnicus imus) ..	.....	(N. splanchnicus imus)
Plexus mammarius internus	.....	.....
Plexus aorticus thoracalis	Plexus aorticus thoracicus	Plexus aorticus thoracicus
Plexus cardiacus	Plexus cardiacus profundus ..... / Plexus cardiacus superficialis	Plexus cardiacus
Plexus coronarius (cordis) anterior ..... / Plexus coronarius (cordis) posterior	Plexus coronarii cordis ..	.....
Ganglion cardiacum (Wrisbergi)	Ganglion cardiacum	Ganglia cardiaca
Rami pulmonales	Rami pulmonales	Rami pulmonales
Plexus pulmonalis	Plexus pulmonalis	Plexus pulmonalis

BNA	JNA	PNA
PARS ABDOMINALIS ET PELVINA SYSTEMATIS SYMPATHICI	PARS ABDOMINALIS ET PELVINA SYSTEMATIS SYMPATHICI	PARS ABDOMINALIS ET PELVINA SYSTEMATIS AUTONOMICI
Ganglia lumbalia	Ganglia lumbalia	Ganglia lumbalia
.....	.....	Nn. splanchnici lumbales
Ganglia sacralia	Ganglia sacralia	Ganglia sacralia
.....	.....	Ganglion impar
Plexus aorticus abdominalis	Plexus aorticus abdominalis	Plexus aorticus abdominalis
Plexus coeliacus	Plexus coeliacus	Plexus celiacus*
Ganglia coeliaca	Ganglion coeliacum dextrum ..... Ganglion coeliacum sinistrum ..... var. Ganglion coeliacum impar	Ganglia celiaca**
Ganglion mesentericum superius	Ganglion mesentericum craniale	Ganglion mesentericum superius
.....	.....	Ganglia aorticorenalia**
Plexus phrenicus	Plexus phrenicus	.....
Ganglia phrenica	.....	Ganglia phrenica
Plexus hepaticus	Plexus hepaticus	Plexus hepaticus
.....	.....	Plexus entericus
.....	.....	Plexus subserosus
Plexus myentericus ...	Plexus myentericus ...	Plexus myentericus
Plexus submucosus	Plexus submucosus	Plexus submucosus
Plexus lienalis	Plexus lienalis	Plexus lienalis
.....	.....	Plexus pancreaticus
Plexus gastricus superior Plexus gastricus inferior .	Plexus gastrici	Plexus gastrici
Plexus suprarenalis	Plexus suprarenalis	Plexus suprarenalis
Plexus renalis	Plexus renalis	Plexus renalis
.....	.....	Ganglia renalia
Plexus spermaticus	Plexus spermaticus	Plexus testicularis
.....	.....	Plexus uretericus
Plexus arteriae ovaricae .	Plexus ovaricus	Plexus ovaricus
Plexus mesentericus sup. .	Plexus mesentericus cranialis	Plexus mesentericus superior

BNA	JNA	PNA
.....	.....	Plexus intermesentericus
Plexus mesentericus inferior	Plexus mesentericus caudalis	Plexus mesentericus inf.
.....	.....	Ganglion mesentericum inferius
Nn. haemorrhoidales superiores	Nn. rectales craniales ...	.....
Plexus haemorrhoidalis superior	Plexus rectalis cranialis .	Plexus rectalis superior
Plexus iliacus	Plexus ilicus	Plexus iliaci
Plexus hypogastricus	.....	Plexus hypogastricus superior (N. presacralis) Plexus hypogastricus inferior (Plexus pelvinus)
.....	Ganglia pelvica	Ganglia pelvina
.....	.....	N. hypogastricus (dexter et sinister)
.....	.....	Nn. splanchnici pelvini (nn. erigentes)
.....	.....	Nn. splanchnici sacrales
Plexus haemorrhoidalis medius	Plexus rectalis caudalis ..	Plexus rectales medii
.....	.....	Plexus rectales inferiores*
Plexus prostaticus	Plexus prostaticus	Plexus prostaticus
Plexus deferentialis	Plexus ductūs deferentis .	Plexus deferentialis
.....	Plexus glandulae vesiculosae	.....
Plexus uterovaginalis	Plexus uterovaginalis	Plexus uterovaginalis
Nn. vaginales	Nn. vaginales	Nn. vaginales
Plexus vesicalis	Plexus vesicalis	Plexus vesicalis
Nn. vesicales superiores Nn. vesicales inferiores .	Nn. vesicales	.....
.....	Ansa sacrococcygica	.....
Plexus cavernosus penis .	Plexus corporis cavernosi penis	.....
N. cavernosus penis major	N. corporis cavernosi penis major	Nn. cavernosi penis
Nn. cavernosi penis minores	Nn. corporis cavernosi penis minores	

BNA	JNA	PNA
Plexus cavernosus clitoridis	Plexus corporis cavernosi clitoridis	.....
N. cavernosus clitoridis major	N. corporis cavernosi clitoridis major	Nn. cavernosi clitoridis
Nn. cavernosi clitoridis minores	Nn. corporis cavernosi clitoridis minores ..	
Plexus femoralis	Plexus femoralis	Plexus femoralis
Plexus popliteus	.....	.....
.....	*SYSTEMA NERVORUM PARASYMPATHICUM*	.....
.....	*Pars encephalica*	.....
.....	Pars mesencephalica	.....
.....	Pars rhombencephalica ..	.....
.....	Rr. musculares parasympathici (partis encephalicae systematis parasympathici)	.....
.....	*Pars sacralis*	.....
.....	Rr. musculares parasympathici (partis sacralis systematis sympathici) ...	.....

ORGANA SENSUUM

ORGANON VISUS	ORGANON VISUS	ORGANUM VISUS
OCULUS	*OCULUS*	*OCULUS*
N. opticus	Fasciculus opticus	N. opticus
Vaginae n. optici	Vaginae fasciculi optici	
	Vagina externa	Vagina externa n. optici
	Vagina interna	Vagina interna n. optici
Spatia intervaginalia	Spatium intervaginale	Spatia intervaginalia
BULBUS OCULI	BULBUS OCULI	BULBUS OCULI
Polus anterior	Polus anterior	Polus anterior
Polus posterior	Polus posterior	Polus posterior
Aequator	Aequator	Equator
Meridiani	Meridiani	Meridiani
Axis oculi externa	Axis oculi externus	Axis bulbi externus
Axis oculi interna	Axis oculi internus	Axis bulbi internus
Axis optica	Axis opticus	Axis opticus
(Linea visus)		
Vesicula ophthalmica		Vesicula ophthalmica
Caliculus ophthalmicus		Caliculus ophthalmicus
TUNICA FIBROSA OCULI	*TUNICA EXTERNA OCULI*	*TUNICA FIBROSA BULBI*
SCLERA	SCLERA	SCLERA
		Substantia propria sclerae
Sulcus sclerae	Sulcus sclerae	Sulcus sclerae
Rima cornealis		
Sinus venosus sclerae (Canalis Schlemmi, Lauthi)	Sinus venosus sclerae	Sinus venosus sclerae
Lamina fusca		Lamina fusca sclerae
Lamina cribrosa sclerae	Area cribriformis sclerae	
		Lamina episcleralis
(Raphe sclerae)		
(Funiculus sclerae)		

BNA	JNA	PNA
CORNEA	CORNEA	CORNEA
Annulus conjunctivae	.....	Anulus conjunctivae
Vertex corneae	Vertex corneae	Vertex corneae
Limbus corneae	Limbus corneae	Limbus corneae
Facies anterior	Facies externa	Facies anterior
Facies posterior	Facies interna	Facies posterior
Epithelium corneae	Epithelium corneae	Epithelium ant. corneae
Lamina elastica anterior (Bowmani)	Lamina limitans externa	Lamina limitans anterior
Substantia propria	Substantia propria	Substantia propria corneae
Lamina elastica posterior (Demoursi, Descemeti)	Lamina limitans interna .	Lamina limitans post.
Endothelium camerae anterioris	Endothelium camerae anterioris	Endothelium camerae ant.
TUNICA VASCULOSA OCULI	*TUNICA MEDIA OCULI*	*TUNICA VASCULOSA BULBI*
CHORIOIDEA	CHORIOIDES	CHOROIDEA*
Lamina suprachorioidea .	Stratum perichorioideum .	Lamina suprachoroidea*
Spatium perichorioideale .	Spatium perichorioideum .	Spatium perichoroideale*
Lamina vasculosa	Lamina vasculosa	Lamina vasculosa
Lamina choriocapillaris ..	Lamina capillarium	Lamina choroidocapillaris**
Lamina basalis	Lamina basialis	Lamina basalis
(Raphe chorioideae)	.....	.....
CORPUS CILIARE	CORPUS CILIARE	CORPUS CILIARE
Corona ciliaris	Corona ciliaris	Corona ciliaris
.....	Processūs ciliares = Plicae ciliares	.....
Processus ciliares	Processūs (ciliares) majores	Processus ciliares
Plicae ciliares	Processūs (ciliares) minores	Plicae ciliares
.....	Lamina basialis	.....
.....	Lamina circularis	.....
Orbiculus ciliaris	Orbiculus ciliaris	Orbiculus ciliaris
M. ciliaris	M. ciliaris	M. ciliaris
Fibrae meridionales (Brueckei)	.....	Fibrae meridionales

BNA	JNA	PNA
Fibrae circulares (Muelleri)	.....	Fibrae circulares
.....	.....	Lamina basalis
Plexus gangliosus ciliaris	.....	.....
IRIS	IRIS	IRIS
Margo pupillaris	Margo pupillaris	Margo pupillaris
Margo ciliaris	Margo ciliaris	Margo ciliaris
Facies anterior	Facies anterior	Facies anterior
Facies posterior	Facies posterior	Facies posterior
Annulus iridis major	Anulus iridis major	Anulus iridis major
Annulus iridis minor ...	Anulus iridis minor	Anulus iridis minor
Plicae iridis	Rugae iridis	Plicae iridis
Stroma iridis	Stroma iridis	Stroma iridis
Vide: Cornea	Vide: Cornea	Endothelium camerae ant.
Lig. pectinatum iridis ...	Spongium anguli iridocornealis	Lig. pectinatum anguli iridocornealis
Spatia anguli iridis (Fontanae)	.....	Spatia anguli iridocornealis
Circulus arteriosus major	Circulus arteriosus iridis major	Circulus arteriosus iridis major
Circulus arteriosus minor	Circulus arteriosus iridis minor	Circulus arteriosus iridis minor
M. sphincter pupillae ...	M. sphincter pupillae ...	M. sphincter pupillae
M. dilatator pupillae ...	M. dilatator pupillae ...	(M. dilator pupillae)*
Membrana pupillaris	var. Membrana pupillaris	(Membrana pupillaris)
Pupilla	Pupilla	Pupilla
.....	*TUNICA INTERNA OCULI*	*TUNICA INTERNA BULBI*
STRATUM PIGMENTI	STRATUM PIGMENTI	STRATUM PIGMENTI
Stratum pigmenti retinae	Stratum pigmenti retinae	Stratum pigmenti retinae
Stratum pigmenti corporis ciliaris	Stratum pigmenti corporis ciliaris	Stratum pigmenti corporis ciliaris
Stratum pigmenti iridis .	Stratum pigmenti iridis .	Stratum pigmenti iridis

BNA	JNA	PNA
RETINA	RETINA	RETINA
Pars optica retinae	Pars optica	Pars optica retinae
.....	.....	Stratum cerebrale
		Stratum ganglionare nervi optici
		Stratum ganglionare retinae
		Stratum neuroepitheliale*
Ora serrata	Ora serrata	Ora serrata
.....	Pars caeca (retinae) ...	.....
Pars ciliaris retinae	Pars ciliaris	Pars ciliaris retinae
Pars iridica retinae	Pars iridica	Pars iridica retinae
Papilla n. optici	Papilla fasciculi optici ...	Discus n. optici*
Excavatio papillae n. optici	Excavatio papillae fasciculi optici	Excavatio disci**
Macula lutea	Macula lutea	Macula
Fovea centralis	Fovea centralis	Fovea centralis
Vasa sanguinea retinae	*Vasa sanguinea retinae*	*Vasa sanguinea retinae*
Circulus vasculosus n. optici (Halleri)	Circulus vasculosus fasciculi optici	Circulus vasculosus n. optici
Arteriola (Venula) temporalis retinae sup.	Arteriola et venula temporalis retinae sup. ...	Arteriola (Venula) temporalis retinae sup.
Arteriola (Venula) temporalis retinae inferior	Arteriola et venula temporalis retinae inferior	Arteriola (Venula) temporalis retinae inferior
Arteriola (Venula) nasalis retinae sup.	Arteriola et venula nasalis retinae sup. ..	Arteriola (Venula) nasalis retinae sup.

BNA	JNA	PNA
Arteriola (Venula) nasalis retinae inf.	Arteriola et venula nasalis retinae inf. ..	Arteriola (Venula) nasalis retinae inf.
Arteriola (Venula) macularis sup. ... Arteriola (Venula) macularis inferior	Arteriolae et venulae maculares (superior, inferior)	Arteriola (Venula) macularis sup. Arteriola (Venula) macularis inferior
Arteriola (Venula) retinae medialis ...	.....	Arteriola (Venula) medialis retinae
CAMERA OCULI ANTERIOR	CAMERA OCULI ANTERIOR	CAMERA ANTERIOR BULBI*
Angulus iridis	Angulus iridocornealis ...	Angulus iridocornealis
.....	.....	Humor aquosus**
CAMERA OCULI POSTERIOR	CAMERA OCULI POSTERIOR	CAMERA POSTERIOR BULBI*
.....	Recessus camerae posterioris (oculi)	.....
.....	Humor aqueus	Humor aquosus*
.....	.....	CAMERA VITREA BULBI**
CORPUS VITREUM	CORPUS VITREUM	CORPUS VITREUM
A. hyaloidea	var. A. hyaloidea	(A. hyaloidea)
Canalis hyaloideus	.....	Canalis hyaloideus
Fossa hyaloidea	Fossa hyaloidea	Fossa hyaloidea
Membrana hyaloidea ...	Membrana hyaloidea ...	Membrana vitrea
Stroma vitreum	Stroma corporis vitrei	Stroma vitreum
Humor vitreus	Humor corporis vitrei	Humor vitreus
LENS CRYSTALLINA	LENS CRYSTALLINA	LENS
Capsula lentis	Capsula lentis	Capsula lentis
Substantia lentis	Substantia lentis	Substantia lentis
Substantia corticalis ..	Cortex lentis	Cortex lentis
Nucleus lentis	Nucleus lentis	Nucleus lentis
.....	Stella lentis anterior ...	.....
.....	Stella lentis posterior ..	.....
Fibrae lentis	Fibrae lentis	Fibrae lentis
Epithelium lentis	Epithelium lentis	Epithelium lentis
Polus anterior	Polus anterior	Polus anterior lentis
Polus posterior	Polus posterior	Polus posterior lentis

BNA	JNA	PNA
Facies anterior	Facies anterior	Facies anterior lentis
Facies posterior	Facies posterior	Facies posterior lentis
Axis lentis	Axis lentis	Axis lentis
Aequator lentis	Aequator lentis	Equator lentis
Radii lentis	Radii stellarum lentis ...	Radii lentis
ZONULA CILIARIS (ZINNI)	APPARATUS SUSPENSORIUS LENTIS	ZONULA CILIARIS
Fibrae zonulares	Fibrae suspensoriae (lentis)	Fibrae zonulares
Spatia zonularia	Spatium apparatūs suspensorii	Spatia zonularia
ORGANA OCULI ACCESSORIA	ORGANA OCULI ACCESSORIA	ORGANA OCULI ACCESSORIA
MUSCULI OCULI, FASCIAE ORBITALES	.....	MUSCULI BULBI, FASCIAE ORBITALES
M. rectus superior	M. rectus bulbi superior .	M. rectus superior
M. rectus inferior	M. rectus bulbi inferior .	M. rectus inferior
M. rectus medialis	M. rectus bulbi nasalis .	M. rectus medialis
M. rectus lateralis	M. rectus bulbi temporalis	M. rectus lateralis
Lacertus musculi recti lateralis	.....	Lacertus musculi recti lateralis
M. obliquus superior	M. obliquus bulbi sup. ..	M. obliquus superior
Trochlea	Trochlea	Trochlea
.....	Vagina synovialis trochleae	Vagina synovialis m. obliqui superioris**
Annulus tendineus communis (Zinni)	Anulus tendineus communis	Anulus tendineus communis
M. obliquus inferior	M. obliquus bulbi inf. ..	M. obliquus inferior
M. levator palpebrae superioris	M. levator palpebrae superioris	M. levator palpebrae superioris
.....	Lamina profunda	Lamina profunda
.....	Lamina superficialis	Lamina superficialis
M. orbitalis	M. orbitalis	M. orbitalis
Periorbita	Periorbita	Periorbita

BNA	JNA	PNA
Septum orbitale	Septum orbitale	Septum orbitale
Fasciae musculares	Fasciae musculares	Fasciae musculares
Fascia bulbi (Tenoni) ...	Capsula bulbi	Vagina bulbi**
Spatium interfasciale (Tenoni)	Spatium circumbulbare ..	Spatium episclerale**
Corpus adiposum orbitae	Corpus adiposum orbitae	Corpus adiposum orbitae
SUPERCILIUM	SUPERCILIUM	SUPERCILIUM
PALPEBRAE	PALPEBRAE	PALPEBRAE
Palpebra superior	Palpebra superior	Palpebra superior
Palpebra inferior	Palpebra inferior	Palpebra inferior
.....	Margines palpebrales ...	.....
Facies anterior palpebrarum	Facies cutanea palpebrae	Facies ant. palpebrarum
Facies posterior palpebrarum	Facies conjunctivalis palpebrae	Facies post. palpebrarum
Rima palpebrarum	Rima palpebrarum	Rima palpebrarum
Commissura palpebrarum lateralis	Commissura palpebrarum temporalis	Commissura palpebrarum lateralis
Commissura palpebrarum medialis	Commissura palpebrarum nasalis	Commissura palpebrarum medialis
Angulus oculi lateralis ...	Angulus oculi temporalis	Angulus oculi lateralis
Angulus oculi medialis ..	Angulus oculi nasalis	Angulus oculi medialis
Limbi palpebrales anteriores	Limbi palpebrales cutanei	Limbi palpebrales anteriores
Limbi palpebrales posteriores	Limbi palpebrales conjunctivales	Limbi palpebrales posteriores
Cilia	Cilia	Cilia
Tarsus superior ..... Tarsus inferior	Tarsus palpebrae	Tarsus superior Tarsus inferior
Lig. palpebrale mediale ..	Lig. palpebrale nasale ...	Lig. palpebrale mediale
.....	Lig. palpebrale temporale	Lig. palpebrale laterale
Raphe palpebralis lateralis	.....	Raphe palpebralis lateralis

BNA	JNA	PNA
Glandulae tarsales (Meibomi)	Gll. tarseae	Glandulae tarsales
Sebum palpebrale		
M. tarsalis superior M. tarsalis inferior	Mm. tarsei	M. tarsalis superior M. tarsalis inferior
	(var. Plica palpebro-nasalis)	(Plica palpebronasalis)
	Sulcus frontopalpebralis	
Sulcus infrapalpebralis	Sulcus palpebromalaris Sulcus palpebralis superior	Sulcus infrapalpebralis
	Sulcus palpebralis inferior	
CONJUNCTIVA	TUNICA CONJUNCTIVA	TUNICA CONJUNCTIVA
Tunica conjunctiva bulbi	Tunica conjunctiva bulbi	Tunica conjunctiva bulbi
Tunica conjunctiva palpebrarum	Tunica conjunctiva palpebrae	Tunica conjunctiva palpebrarum
	Saccus conjunctivae	Saccus conjunctivae
Fornix conjunctivae superior	Fornix conjunctivae sup.	Fornix conjunctivae sup.
Fornix conjunctivae inferior	Fornix conjunctivae inf.	Fornix conjunctivae inf.
Plica semilunaris conjunctivae	Plica semilunaris conjunctivae	Plica semilunaris conjunctivae
Caruncula lacrimalis	Caruncula lacrimalis	Caruncula lacrimalis
Gll. ciliares (Molli)	Gll. sudoriferae ciliares	Gll. ciliares
Gll. mucosae (Krausei)	Gll. conjunctivales	Gll. conjunctivales
		Gll. sebaceae
Noduli lymphatici conjunctivales	Noduli lymphacei conjunctivales	
(Pinguecula)		
APPARATUS LACRIMALIS	ORGANA LACRIMALIA	APPARATUS LACRIMALIS
Glandula lacrimalis superior Glandula lacrimalis inferior	Gl. lacrimalis: Pars orbitalis; Pars palpebralis	Glandula lacrimalis: Pars orbitalis; Pars palpebralis

BNA	JNA	PNA
(Gll. lacrimales accessoriae)	(Gll. lacrimales accessoriae)	(Gll. lacrimales accessoriae)
Ductuli excretorii (gl. lacrimalis)	Ductuli excretorii ...	Ductuli excretorii (gl. lacrimalis)
Rivus lacrimalis	(Rivus lacrimalis)	Rivus lacrimalis
Lacus lacrimalis	Lacus lacrimalis	Lacus lacrimalis
Puncta lacrimalia	Puncta lacrimalia	Punctum lacrimale
Ductus lacrimales	Ductuli lacrimales	Canaliculus lacrimalis
Papillae lacrimales	Papillae lacrimales	Papilla lacrimalis
Ampulla ductus lacrimalis	Ampulla ductuli lacrimalis	Ampulla canaliculi lacrimalis
Saccus lacrimalis	Saccus lacrimalis	Saccus lacrimalis
Fornix sacci lacrimalis	Fornix sacci lacrimalis	Fornix sacci lacrimalis
Ductus nasolacrimalis ...	Ductus nasolacrimalis ...	Ductus nasolacrimalis
Plica lacrimalis (Hasneri)	Plica ductus nasolacrimalis	Plica lacrimalis
Lacrimae	.....	.....
ORGANON AUDITUS	ORGANON STATUUS ET AUDITUS	ORGANUM VESTIBULOCOCHLEARE*
AURIS INTERNA	*AURIS INTERNA*	*AURIS INTERNA*
LABYRINTHUS MEMBRANACEUS	**LABYRINTHUS MEMBRANACEUS**	**LABYRINTHUS MEMBRANACEUS**
Ductus endolymphaticus	Ductus endolymphaceus .	Ductus endolymphaticus (Aqueductus vestibuli)**
Saccus endolymphaticus .	Saccus endolymphaceus ..	Saccus endolymphaticus
Ductus utriculosaccularis .	Ductus utriculosaccularis	Ductus utriculosaccularis
Utriculus	Utriculus	Utriculus
Sacculus	Sacculus	Sacculus
Ductus semicirculares ...	Ductus semicirculares ...	Ductus semicirculares
.....	.....	Epithelium ductus semicircularis
.....	.....	Membrana basalis ductus semicircularis
.....	.....	Membrana propria ductus semicircularis

BNA	JNA	PNA
Ductus semicircularis superior	Ductus semicircularis superior	Ductus semicircularis anterior
Ductus semicircularis posterior	Ductus semicircularis posterior	Ductus semicircularis posterior
Ductus semicircularis lateralis	Ductus semicircularis lateralis	Ductus semicircularis lateralis
		Crura membranacea
	Crura membranacea ampullaria	Crura membranacea ampullaria*
	Crus membranaceum commune	Crus membranaceum commune
	Crus membranaceum simplex	Crus membranaceum simplex
Ampullae membranaceae	Ampullae membranaceae	Ampullae membranaceae
Sulcus ampullaris	Sulcus ampullaris	Sulcus ampullaris
Crista ampullaris	Crista ampullaris	Crista ampullaris Neuroepithelium* Cupula
Ampulla membranacea superior	Ampulla membranacea superior	Ampulla membranacea anterior
Ampulla membranacea posterior	Ampulla membranacea posterior	Ampulla membranacea posterior
Ampulla membranacea lateralis	Ampulla membranacea lateralis	Ampulla membranacea lateralis
Ductus reuniens (Henseni)	Ductus reuniens	Ductus reuniens
Maculae acusticae	Maculae staticae	Maculae
Macula sacculi	Macula sacculi	Macula sacculi

BNA	JNA	PNA
Macula utriculi	Macula utriculi	Macula utriculi
Otoconia	Statoconia	Statoconia
.....	.....	Membrana statoconiorum
.....	.....	Neuroepithelium
Endolympha	Endolympha	Endolympha
Perilympha	Perilympha	Perilympha
Spatium perilymphaticum	Spatium perilymphaceum	Spatium perilymphaticum
Vide: Cochlea	Vide: Cochlea	Scala vestibuli**
Vide: Cochlea	Vide: Cochlea	Scala tympani**
Ductus perilymphatici ...	Ductus perilymphacei ...	Ductus perilymphatici
.....	Pars auditiva (labyrinthi membranacei)	.....
.....	Pars statica (labyrinthi membranacei)	.....
Ductus cochlearis	*Ductus cochlearis*	*Ductus cochlearis*
.....	.....	Paries tympanicus ductus cochlearis (Membrana spiralis)**
.....	.....	Membrana reticularis
.....	.....	Membrana tectoria
.....	.....	Dentes acustici
Caecum cupulare	Caecum cupulare	Cecum cupulare*
Caecum vestibulare	Caecum vestibulare	Cecum vestibulare*
Lamina basilaris	Lamina basialis	Lamina basilaris
Membrana vestibularis (Reissneri)	Membrana vestibularis ..	Paries vestibularis ductus cochlearis (Membrana vestibularis)**
.....	.....	Paries ext. ductus cochlearis
Lig. spirale cochleae	Lig. spirale cochleae	Lig. spirale cochleae
.....	.....	Vas spirale
.....	.....	Crista basilaris
Prominentia spiralis	Prominentia spiralis	Prominentia spiralis
Stria vascularis	Stria vascularis	Stria vascularis
Sulcus spiralis	Sulcus spiralis	Sulcus spiralis externus
.....	.....	Sulcus spiralis internus
Labium tympanicum ..	Labium tympanicum ..	Labium limbi tympanicum

BNA	JNA	PNA
Foramina nervosa ...	Foramina nervorum .	Foramina nervosa
.....	.....	Limbus laminae spiralis osseae
Labium vestibulare	Labium vestibulare	Labium limbi vestibulare
Ganglion spirale cochleae	Ganglion spirale cochleae	Ganglion spirale cochleae
Organon spirale (Cortii)	Organon spirale	Organum spirale
Vasa auris interna	*Vasa labyrinthi*	*Vasa auris internae**
A. auditiva interna	A. labyrinthi	A. labyrinthi
Rami vestibulares	Rami vestibulares	Rami vestibulares
R. cochleae	R. cochleae	R. cochlearis*
Glomeruli arteriosi cochleae	.....	Glomeruli arteriosi cochleae
Vv. auditivae internae ..	Vv. labyrinthi	Vv. labyrinthi
V. spiralis modioli	V. spiralis modioli	V. spiralis modioli
Vas prominens	Vas prominens	Vas prominens
Vv. vestibulares	Vv. vestibulares	Vv. vestibulares
V. aquaeductus vestibuli	V. canaliculi vestibuli .	V. aqueductus vestibuli
V. canaliculi cochleae .	V. canaliculi cochleae .	V. aqueductus cochleae**

LABYRINTHUS OSSEUS	CAPSULA OSSEA LABYRINTHI	LABYRINTHUS OSSEUS
VESTIBULUM	VESTIBULUM	VESTIBULUM
Recessus sphaericus	Recessus sacculi	Recessus sphericus
Recessus ellipticus	Recessus utriculi	Recessus ellipticus
Crista vestibuli	Crista vestibuli	Crista vestibuli
Pyramis vestibuli	Pyramis vestibuli	Pyramis vestibuli
Recessus cochlearis	Recessus cochlearis	Recessus cochlearis
Maculae cribrosae	Areae cribriformes	Maculae cribrosae
Macula cribrosa superior	Area cribriformis utriculoampullaris	Macula cribrosa superior

BNA	JNA	PNA
Macula cribrosa media	Area cribriformis sacccularis	Macula cribrosa media
Macula cribrosa inferior	Area cribriformis ampullaris	Macula cribrosa inferior
.....	Apertura labyrinthica canaliculi cochleae ..	.....
.....	Apertura vestibularis canaliculi vestibuli	.....
Canales semicirculares ossei	Canales semicirculares ..	Canales semicirculares ossei
Canalis semicircularis superior	Canalis semicircularis superior	Canalis semicircularis anterior
Canalis semicircularis posterior	Canalis semicircularis posterior	Canalis semicircularis posterior
Canalis semicircularis lateralis	Canalis semicircularis lateralis	Canalis semicircularis lateralis
Ampullae osseae	Ampullae osseae	Ampullae osseae
Ampulla ossea superior	Ampulla ossea superior	Ampulla ossea anterior
Ampulla ossea posterior	Ampulla ossea posterior	Ampulla ossea posterior
Ampulla ossea lateralis	Ampulla ossea lateralis	Ampulla ossea lateralis
Crura ampullaria	Crura ampullaria	Crura ossea*
Crus commune	Crus commune	Crus osseum commune*
Crus simplex	Crus simplex	Crus osseum simplex*
.....	.....	Crura ossea ampullaria*
COCHLEA	COCHLEA	COCHLEA
Cupula	Cupula	Cupula cochleae
Basis cochleae	Basis cochleae	Basis cochleae
Canalis spiralis cochleae	Canalis spiralis cochleae	Canalis spiralis cochleae
Modiolus	Modiolus	Modiolus
Basis modioli	Basis modioli	Basis modioli
Lamina modioli	Lamina modioli	Lamina modioli
Canalis spiralis modioli ..	Canalis spiralis modioli ..	Canalis spiralis modioli

BNA	JNA	PNA
Canales longitudinales modioli	Canales longitudinales modioli	Canales longitudinales modioli
Lamina spiralis ossea ...	Lamina spiralis ossea ...	Lamina spiralis ossea
Hamulus laminae spiralis	Hamulus laminae spiralis	Hamulus laminae spiralis
Scala vestibuli	Scala vestibuli	Vide: Labyrinthus membranaceus**
Scala tympani	Scala tympani	Vide: Labyrinthus membranaceus**
Helicotrema	Helicotrema	Helicotrema
Lamina spiralis secundaria	Lamina spiralis secundaria	Lamina spiralis secundaria
MEATUS ACUSTICUS INTERNUS	MEATUS ACUSTICUS INTERNUS	MEATUS ACUSTICUS INTERNUS
Porus acusticus internus .	Porus acusticus internus .	Porus acusticus internus
Fundus meatus acustici interni	Fundus meatūs acustici interni	Fundus meatus acustici interni
Crista transversa	Crista transversa	Crista transversa
Area n. facialis	Introitus canalis nervi facialis	Area n. facialis
Area cochleae	Area cochleae	Area cochleae
Tractus spiralis foraminosus	Tractus spiralis foraminosus	Tractus spiralis foraminosus
Area vestibularis superior	Area vestibularis utriculoampullaris	Area vestibularis superior
Area vestibularis inferior	Area vestibularis saccularis	Area vestibularis inferior
Foramen singulare	Foramen singulare	Foramen singulare

BNA	JNA	PNA
CAVUM TYMPANI	*CAVUM TYMPANI TYMPANUM*	*AURIS MEDIA (CAVUM TYMPANI)*
Paries tegmentalis	*Paries tegmentalis*	*Paries tegmentalis*
Recessus epitympanicus ..	Recessus epitympanicus ..	Recessus epitympanicus
Pars cupularis	.....	Pars cupularis
.....	Apertura tympanica canaliculi n. petrosi superficialis minoris ...	.....
Paries jugularis	*Paries jugularis*	*Paries jugularis*
.....	Solum tympani	.....
Prominentia styloidea ...	Prominentia styloidea ...	Prominentia styloidea
.....	Apertura tympanica canaliculi tympanici	.....
Paries labyrinthica	*Paries labyrinthicus*	*Paries labyrinthicus*
Fenestra vestibuli	Fenestra vestibuli	Fenestra vestibuli
Fossula fenestrae vestibuli	Fossula fenestrae vestibuli	Fossula fenestrae vestibuli
Promontorium	Promunturium	Promontorium
Sulcus promontorii	Sulcus promunturii	Sulcus promontorii
Subiculum promontorii	.....	Subiculum promontorii
Sinus tympani	Sinus tympani	Sinus tympani
Fenestra cochleae	Fenestra cochleae	Fenestra cochleae
Fossula fenestrae cochleae	Fossula fenestrae cochleae	Fossula fenestrae cochleae
Crista fenestrae cochleae	Crista fenestrae cochleae	Crista fenestrae cochleae
Processus cochleariformis	Processus cochleariformis	Processus cochleariformis
Membrana tympani secundaria	Membrana tympani secundaria	Membrana tympani secundaria
Paries mastoidea	*Paries mastoideus*	*Paries mastoideus*
Antrum tympanicum	Antrum mastoideum	Antrum mastoideum
		Aditus ad antrum

BNA	JNA	PNA
Prominentia canalis semicircularis lateralis	Prominentia canalis semicircularis lateralis	Prominentia canalis semicircularis lateralis
Prominentia canalis facialis	Prominentia canalis nervi facialis	Prominentia canalis facialis
Eminentia pyramidalis ...	Eminentia pyramidalis ...	Eminentia pyramidalis
.....	Ponticulus	.....
Fossa incudis	Fossa incudis	Fossa incudis
Sinus posterior	.....	Sinus posterior
Apertura tympanica canaliculi chordae	Apertura tympanica canaliculi chordae	Apertura tympanica canaliculi chordae tympani
Cellulae mastoideae	Cellulae mastoideae	Cellulae mastoideae
Cellulae tympanicae	Cellulae tympanicae	Cellulae tympanicae
Paries carotica	*Paries caroticus*	*Paries caroticus*
Paries membranacea	*Paries membranaceus*	*Paries membranaceus*
MEMBRANA TYMPANI	MEMBRANA TYMPANI	MEMBRANA TYMPANI
Pars flaccida	Pars flaccida	Pars flaccida
Pars tensa	Pars tensa	Pars tensa
.....	Stria membranae tympani anterior	.....
.....	Stria membranae tympani posterior	.....
Limbus membranae tympani	Limbus membranae tympani	.....
Plica malleolaris anterior	Plica mallearis anterior .	Plica mallearis anterior
Plica malleolaris posterior	Plica mallearis posterior .	Plica mallearis posterior
Prominentia malleolaris ..	Prominentia mallearis ...	Prominentia mallearis
Stria malleolaris	Stria mallearis	Stria mallearis
Umbo membranae tympani	Umbo membranae tympani	Umbo membranae tympani
Annulus fibrocartilagineus	Anulus fibrocartilagineus .	Anulus fibrocartilagineus

BNA	JNA	PNA
Stratum cutaneum	Stratum cutaneum	Stratum cutaneum
Stratum radiatum	Stratum radiatum	Stratum radiatum
Stratum circulare	Stratum circulare	Stratum circulare
Stratum mucosum	Stratum mucosum	Stratum mucosum
OSSICULA AUDITUS	OSSICULA TYMPANI	OSSICULA AUDITUS
Stapes	*Stapes*	*Stapes*
Capitulum stapedis	Capitulum stapedis	Caput stapedis
Crus anterius	Crus rectilineum	Crus anterius
Crus posterius	Crus curvilineum	Crus posterius
Basis stapedis	Basis stapedis	Basis stapedis
Incus	*Incus*	*Incus*
Corpus incudis	Corpus incudis	Corpus incudis
Crus longum	Crus longum	Crus longum
Processus lenticularis ..	Processus lenticularis ..	Processus lenticularis
Crus breve	Crus breve	Crus breve
Malleus	*Malleus*	*Malleus*
Manubrium mallei	Manubrium mallei	Manubrium mallei
Capitulum mallei	Capitulum mallei	Caput mallei
Collum mallei	Collum mallei	Collum mallei
Processus lateralis	Processus brevis	Processus lateralis
Processus anterior (Folii)..	Processus longus	Processus anterior
LIGG. OSSICULORUM AUDITUS	LIGG. OSSICULORUM TYMPANI	LIGG. OSSICULORUM AUDITUS
Lig. mallei anterius	Lig. processūs longi mallei	Lig. mallei anterius
Lig. mallei superius	Lig. capituli mallei sup. .	Lig. mallei superius
Lig. mallei laterale	Lig. mallei laterale	Lig. mallei laterale
Lig. incudis superius	Lig. incudis superius	Lig. incudis superius
Lig. incudis posterius ...	Lig. incudis posterius ...	Lig. incudis posterius
Membrana obturatoria ..	Membrana obturans stapedis	Membrana stapedis
Lig. annulare baseos stapedis	Lig. anulare baseos stapedis	Lig. anulare stapedis
(M. fixator baseos stapedis)	.....	.....

BNA	JNA	PNA
ARTICULATIONES OSSICULORUM AUDITUS	JUNCTURAE OSSICULORUM TYMPANI	ARTICULATIONES OSSICULORUM AUDITUS
Articulatio incudomalleolaris	Articulus incudomallearis	Articulatio incudomallearis
Articulatio incudostapedia	Articulus incudostapedius	Articulatio incudostapedia
Syndesmosis tympanostapedia	Syndesmosis tympanostapedia	Syndesmosis tympanostapedia
MUSCULI OSSICULORUM AUDITUS	MUSCULI OSSICULORUM TYMPANI	MUSCULI OSSICULORUM AUDITUS
M. tensor tympani	M. tensor tympani	M. tensor tympani
M. stapedius	M. stapedius	M. stapedius
TUNICA MUCOSA TYMPANICA	TUNICA MUCOSA TYMPANICA	TUNICA MUCOSA CAVI TYMPANI
(Gll. tympanicae)		
Plica malleolaris post.	Plica mallearis posterior	Plica mallearis posterior
Plica malleolaris anterior	Plica mallearis anterior	Plica mallearis anterior
	Plica chordae tympani	Plica chordae tympani
Recessus membranae tympani anterior	Recessus membranae tympani anterior	Recessus membranae tympani anterior
Recessus membranae tympani superior	Recessus membranae tympani superior	Recessus membranae tympani superior
Recessus membranae tympani posterior	Recessus membranae tympani posterior	Recessus membranae tympani posterior
Plica incudis	Plica incudis	Plica incudis
Plica stapedis	Plica stapedis	Plica stapedis
TUBA AUDITIVA (EUSTACHII)	TUBA PHARYNGO-TYMPANICA	TUBA AUDITIVA
Ostium tympanicum tubae auditivae	Ostium tympanicum tubae pharyngotympanicae	Ostium tympanicum tubae auditivae

BNA	JNA	PNA
Pars ossea tubae auditivae	Pars ossea tubae pharyngotympanicae	Pars ossea tubae auditivae
Isthmus tubae auditivae	Isthmus tubae pharyngotympanicae	Isthmus tubae auditivae
Cellulae pneumaticae tubariae	Cellulae pneumaticae tubales	Cellulae pneumaticae
Pars cartilaginea tubae auditivae	Pars cartilaginea tubae pharyngotympanicae ...	Pars cartilaginea tubae auditivae
Cartilago tubae auditivae	Cartilago tubae pharyngotympanicae .	Cartilago tubae auditivae
Lamina (cartilaginis) medialis	Lamina cartilaginis medialis	Lamina (cartilaginis) medialis
Lamina (cartilaginis) lateralis ...	Lamina cartilaginis lateralis	Lamina (cartilaginis) lateralis
Lamina membranacea ...	Lamina membranacea ...	Lamina membranacea
Tunica mucosa	Tunica mucosa	Tunica mucosa
Glandulae mucosae ...	Glandulae mucosae ...	Glandulae tubariae
Noduli lymphatici tubarii	Lymphonoduli tubales .	.....
Ostium pharyngeum tubae	Ostium pharyngicum tubae pharyngotympanicae ...	Ostium pharyngeum tubae auditivae
AURIS EXTERNA°	*AURIS EXTERNA*	*AURIS EXTERNA*
MEATUS ACUSTICUS EXTERNUS	MEATUS ACUSTICUS EXTERNUS	MEATUS ACUSTICUS EXTERNUS
Porus acusticus externus .	Porus acusticus externus .	Porus acusticus externus
Incisura tympanica (Rivini)	Incisura tympanica	Incisura tympanica**

BNA	JNA	PNA
Meatus acusticus externus cartilagineus	Meatus acusticus externus cartilagineus	Meatus acusticus externus cartilagineus
Cartilago meatus acustici	Cartilago meatūs acustici externi	Cartilago meatus acustici
Incisura cartilaginis meatus acustici externi (Santorini)	Foramina cartilaginis meatūs acustici externi	Incisurae cartilaginis meatus acustici
Lamina tragi	Lamina tragi	Lamina tragi
AURICULA	AURICULA	AURICULA
Lobulus auriculae	Lobulus auriculae	Lobulus auriculae
Cartilago auriculae	Cartilago auriculae	Cartilago auriculae
Helix	Helix	Helix
Crus helicis	Crus helicis	Crus helicis
Spina helicis	Spina helicis	Spina helicis
Cauda helicis	Cauda helicis	Cauda helicis
Anthelix	Anthelix	Anthelix
Crura anthelicis	Crura anthelicis	Crura anthelicis
Fossa triangularis	Fossa triangularis	Fossa triangularis
Scapha	Scapha	Scapha
Concha auriculae	Concha auriculae	Concha auriculae
Cymba conchae	Cymba conchae	Cymba conchae
Cavum conchae	Cavum conchae	Cavum conchae
Antitragus	Antitragus	Antitragus
Tragus	Tragus	Tragus
Incisura anterior (auris) .	Sulcus helicotragicus	Incisura anterior (auris)
Incisura intertragica	Incisura intertragica	Incisura intertragica
(Tuberculum auriculae Darwini)	var. Tuberculum auriculae	(Tuberculum auriculae)
(Apex auriculae Darwini)	var. Apex auriculae	(Apex auriculae)
Sulcus auriculae posterior	.....	Sulcus auriculae posterior
(Tuberculum supratragicum)	var. Tuberculum supratragicum	(Tuberculum supratragicum)
Isthmus cartilaginis auris	Isthmus cartilaginis auris	Isthmus cartilaginis auris
Incisura terminalis auris .	Incisura terminalis auris .	Incisura terminalis auris
Fissura antitragohelicina .	Fissura antitragohelicina .	Fissura antitragohelicina*

BNA	JNA	PNA
Sulcus anthelicis transversus	Sulcus anthelicis transversus	Sulcus anthelicis transversus
Sulcus cruris helicis	Sulcus cruris helicis	Sulcus cruris helicis
Fossa anthelicis	Fossa anthelicis	Fossa anthelicis
Eminentia conchae	Eminentia conchae	Eminentia conchae
Eminentia scaphae	Eminentia scaphae	Eminentia scaphae
Eminentia fossae triangularis	Eminentia triangularis ...	Eminentia fossae triangularis
Ligg. auricularia (Valsalvae)	Ligg. auricularia	Ligg. auricularia
Lig. auriculare anterius	.....	Lig. auriculare ant.
Lig. auriculare superius	.....	Lig. auriculare superius
Lig. auriculare post.	.....	Lig. auriculare post.
M. helicis major	M. helicis major	M. helicis major
M. helicis minor	M. helicis minor	M. helicis minor
M. tragicus	M. tragicus	M. tragicus
(M. pyramidalis auriculae Jungi)	.....	M. pyramidalis auriculae
M. antitragicus	M. antitragicus	M. antitragicus
M. transversus auriculae .	M. transversus auriculae .	M. transversus auriculae
M. obliquus auriculae ..	M. obliquus auriculae ..	M. obliquus auriculae
(M. incisurae helicis Santorini)	var. M. incisurae helicis	(M. incisurae helicis)
ORGANON OLFACTUS	ORGANON OLFACTUS	ORGANUM OLFACTUS
.....	Regio olfactoria tunicae mucosae nasi	Regio olfactoria tunicae mucosae nasi
Glandulae olfactoriae	Glandulae olfactoriae	Glandulae olfactoriae
ORGANON GUSTUS	ORGANON GUSTUS	ORGANUM GUSTUS
Calyculi gustatorii	Caliculi gustatorii	Caliculus gustatorius Porus gustatorius

BNA	JNA	PNA
INTEGUMENTUM COMMUNE	INTEGUMENTUM COMMUNE	INTEGUMENTUM COMMUNE
CUTIS	*CUTIS*	*CUTIS*
Sulci cutis	Sulci cutis	Sulci cutis
Cristae cutis	Cristae cutis	Cristae cutis
Retinacula cutis	Retinacula cutis	Retinacula cutis
	Stratum fibrosum (cutis)	
Toruli tactiles	Toruli tactiles	Toruli tactiles
Foveola coccygea	Foveola coccygica	(Foveola coccygea)
Lig. caudale	Retinaculum caudale cutis	Retinaculum caudale
Epidermis	*Epidermis*	*Epidermis*
Stratum corneum	Stratum corneum	Stratum corneum
Stratum germinativum (Malpighii)	Stratum germinativum	
		Stratum basale (cylindricum)*
		Stratum granulosum
		Stratum lucidum
		Stratum spinosum
Corium	*Corium*	*Corium (dermis)**
Tunica propria	Stratum reticulare	Stratum reticulare*
Corpus papillare	Stratum papillare	Stratum papillare*
Papillae	Papillae	Papillae
		Menisci tactus
Tela subcutanea	*Tela subcutanea*	*Tela subcutanea*
Panniculus adiposus	Panniculus adiposus	Panniculus adiposus
Corpuscula nervorum terminalia	*Corpuscula nervorum terminalia*	*Corpuscula nervosa terminalia*
Corpuscula bulboidea (Krausei)	Corpuscula bulboidea	Corpuscula bulboidea
Corpuscula lamellosa (Vateri, Pacini)	Corpuscula lamellosa	Corpuscula lamellosa
Corpuscula tactus (Meissneri)	Corpuscula tactus	Corpuscula tactus

BNA	JNA	PNA
Corpuscula nervorum genitalia	Corpuscula nervorum genitalium	Corpuscula genitalia*
Corpuscula nervorum articularia	Corpuscula nervorum articularium	Corpuscula articularia*
PILI	*PILI*	*PILI*
Lanugo	Lanugo	Lanugo
Capilli	Capilli	Capilli
Supercilia	Supercilia	Supercilia
Cilia	Cilia	Cilia
Barba	Barba	Barba
Tragi	Tragi	Tragi
Vibrissae	Vibrissae	Vibrissae
Hirci	Hirci	Hirci
Pubes	Pubes	Pubes
Folliculus pili	Folliculus pili	Folliculus pili
Fundus folliculi pili		
Collum folliculi pili		
Papilla pili	Papilla pili	Papilla pili
Scapus pili	Scapus pili	Scapus pili
Radix pili	Radix pili	Radix pili
Bulbus pili	Bulbus pili	Bulbus pili
Mm. arrectores pilorum	Mm. arrectores pilorum	Mm. arrectores pilorum
Flumina pilorum	Flumina pilorum	Flumina pilorum
	Cruces pilorum	Cruces pilorum
Vortices pilorum	Vortices pilorum	Vortices pilorum
(Vortex coccygeus)		
UNGUES	*UNGUES*	*UNGUIS*
Matrix unguis	Lectulus unguis	Matrix unguis
Cristae matricis unguis	Cristae lectuli unguis	Cristae matricis unguis
Sulcus matricis unguis	Sulcus lectuli unguis	Sulcus matricis unguis
	Sinus unguis	Sinus unguis
Vallum unguis	Vallum unguis	Vallum unguis
Corpus unguis	Corpus unguis	Corpus unguis
Radix unguis	Radix unguis	Radix unguis
Lunula	Lunula	Lunula
		Retinacula unguis

BNA	JNA	PNA
Margo occultus	Margo occultus	Margo occultus
Margo liber	Margo liber	Margo liber
Margo lateralis	Margo lateralis	Margo lateralis
.....	.....	Perionyx**
.....	.....	Hyponychium
.....	.....	Eponychium
Stratum corneum	Stratum corneum unguis .	Stratum corneum unguis
Stratum germinativum unguis	Stratum germinativum unguis	Stratum germinativum unguis
GLANDULAE CUTIS	*GLANDULAE CUTIS*	*GLANDULAE CUTIS*
GLANDULAE GLOMIFORMES	GLANDULAE GLOMIFORMES	GLANDULAE GLOMIFORMES
Glandulae sudoriferae ...	Glandulae sudoriferae ...	Glandulae sudoriferae
.....	Glandulae sudoriferae majores	.....
.....	Glandulae sudoriferae minores	.....
Corpus gl. sudoriferae .	Corpus glandulae sudoriferae	Corpus gl. sudoriferae
Ductus sudoriferus ...	Ductus sudorifer	Ductus sudoriferus
Porus sudoriferus	Porus sudorifer	Porus sudoriferus
Sudor	.....	.....
.....	Glandulae sudoriferae axillares	.....
.....	Glandulae sudoriferae nasales	.....
Glandulae circumanales ..	Glandulae circumanales ..	Glandulae circumanales
Glandulae ceruminosae ..	Glandulae ceruminosae ..	Glandulae ceruminosae
Cerumen	.....	.....
GLANDULAE SEBACEAE	GLANDULAE SEBACEAE	GLANDULAE SEBACEAE
Sebum cutaneum	.....	.....
MAMMA	*MAMMA*	*MAMMA*
Papilla mammae	Papilla mammae	Papilla mammae
Corpus mammae	Corpus mammae	Corpus mammae
.....	.....	Glandula mammaria
Lobi mammae	Lobi mammae	Lobi glandulae mammariae

BNA	JNA	PNA
Lobuli mammae	Lobuli mammae	Lobuli glandulae mammariae
Ductus lactiferi	Ductus lactiferi	Ductus lactiferi
Sinus lactiferi	Sinus lactiferi	Sinus lactiferi
Lac femininum	.....	.....
Colostrum	.....	.....
Areola mammae	Areola mammae	Areola mammae
Glandulae sebaceae ...	.....	.....
Glandulae areolares (Montgomerii)	Gll. areolares mammae	Glandulae areolares
Mamma virilis	*Mamma masculina*	*Mamma masculina*
(Mammae accessoriae [muliebres et viriles]) ..	var. Mammae accessoriae (masculinae et femininae)	(Mammae accessoriae) (femininae et masculinae)
.....	.....	Ligg. suspensoria mammae*

REGIONES CORPORIS

Linea mediana anterior ..	Linea mediana ventralis .	Linea mediana anterior
Linea mediana posterior .	Linea mediana dorsalis .	Linea mediana posterior
Linea sternalis	Linea sternalis	.....
Linea parasternalis	Linea parasternalis	.....
Linea mamillaris	Linea mamillaris	Linea mamillaris (Linea medioclavicularis)
Linea axillaris	Linea axillaris	Linea axillaris
Linea scapularis	Linea scapularis	Linea scapularis
REGIONES CAPITIS	*REGIONES CAPITIS*	*REGIONES CAPITIS*
Regio frontalis	Regio frontalis	Regio frontalis
Regio supraorbitalis	.....	.....
Regio parietalis	Regio parietalis	Regio parietalis
Regio occipitalis	Regio occipitalis	Regio occipitalis
Regio temporalis	Regio temporalis	Regio temporalis
.....	.....	Regio infratemporalis*
Regio auricularis	Regio auricularis	.....
Regio mastoidea	Regio mastoidea	.....
REGIONES FACIEI	*REGIONES FACIEI*	*REGIONES FACIEI*
Regio nasalis	Regio nasalis	Regio nasalis
Regio oralis	Regio oralis	Regio oralis
Regio labialis superior ..	Regio labialis maxillaris .	.....
Regio labialis inferior ...	Regio labialis mandibularis	.....
Regio mentalis	Regio mentalis	Regio mentalis
Regio orbitalis	Regio orbitalis	Regio orbitalis
Regio palpebralis superior	Regio palpebralis superior	.....
Regio palpebralis inferior	Regio palpebralis inferior	.....
Regio infraorbitalis	Regio infraorbitalis	Regio infraorbitalis
Regio buccalis	Regio buccalis	Regio buccalis
Regio zygomatica	Regio zygomatica	Regio zygomatica

BNA	JNA	PNA
Regio parotideomasseterica	Regio parotideomasseterica	Regio parotideomasseterica
Fossa retromandibularis	Regio retromandibularis	.....
REGIONES COLLI	*REGIONES COLLI*	*REGIONES COLLI*
Regio colli anterior	Regio colli ventralis	Regio colli anterior
Regio submentalis	Regio submentalis	.....
Regio hyoidea	Regio hyoidea	.....
Regio subhyoidea	Regio subhyoidea	.....
Regio laryngea	Regio laryngica	.....
Regio thyreoidea	Regio thyreoidea	.....
Regio suprasternalis ...	.....	.....
Fossa jugularis	Fossa jugularis	.....
Regio submaxillaris ...	Regio submandibularis .	Trigonum submandibulare
Fossa carotica	Trigonum caroticum ..	Trigonum caroticum
Regio sternocleidomastoidea	Regio sternocleidomastoidea	Regio sternocleidomastoidea
Fossa supraclavicularis minor	Fossa supraclavicularis minor	Fossa supraclavicularis minor
Regio colli lateralis	Trigonum colli laterale ...	Regio colli lateralis
Fossa supraclavicularis major	Trigonum omoclaviculare = Fossa supraclavicularis major ..	Trigonum omoclaviculare (Fossa supraclavicularis major)
Trigonum omoclaviculare	Trigonum omoclaviculare = Fossa supraclavicularis major ..	
Regio colli posterior	Regio colli dorsalis	Regio colli posterior
Regio nuchae	Regio nuchae	.....
Fovea nuchae	.....	.....

BNA	JNA	PNA
REGIONES PECTORIS	*REGIONES PECTORIS*	*REGIONES PECTORIS*
Regio pectoris anterior ..	.....	.....
Regio sternalis	Regio sternalis	.....
Regio clavicularis	Regio clavicularis	.....
Regio infraclavicularis	Regio infraclavicularis	Regio infraclavicularis
Trigonum deltoideo-pectorale	Trigonum deltoideo-pectorale	.....
Regio mammalis	Regio mammalis	Regio mammaria**
Regio inframammalis ..	Regio inframammalis ..	.....
Regio pectoris lateralis ..	Regio thoracica lateralis	.....
Regio axillaris	Regio axillaris	Regio axillaris
Fossa axillaris	Fossa axillaris	Fossa axillaris
Regio costalis lateralis .	.....	.....
REGIONES ABDOMINIS	*REGIONES ABDOMINIS*	*REGIONES ABDOMINIS*
Regio epigastrica	Pars medialis = Regio mesogastrica	Regio epigastrica
Regio hypochondriaca ...	Pars lateralis = Regio hypochondrica	Regio hypochondriaca (dext. et sin.)
Regio mesogastrica	Regio abdominis media .	.....
Regio umbilicalis	Pars (Regio) umbilicalis	Regio umbilicalis
Regio abdominalis lat.	Pars lateralis	Regio lateralis (dext. et sin.)
Regio hypogastrica	Regio abdominis caudalis = Regio hypogastrica	.....
Regio pubica	Regio pubica	Regio pubica
Regio inguinalis	Regio inguinalis	Regio inguinalis (dext. et sin.)
REGIONES DORSI	*REGIONES DORSI*	*REGIONES DORSI*
Regio mediana dorsi	Regio vertebralis	Regio vertebralis
Regio interscapularis	Regio interscapularis	.....
Regio scapularis	Regio scapularis	Regio scapularis
Regio suprascapularis ...	Regio suprascapularis ...	.....
Regio infrascapularis	Regio infrascapularis	Regio infrascapularis
Regio lumbalis	Regio lumbalis	Regio lumbalis
Regio coxae	Regio coxae	.....
Regio sacralis	Regio sacralis	Regio sacralis

BNA	JNA	PNA
REGIO PERINEALIS	*REGIO PERINEALIS*	*REGIO PERINEALIS*
Perineum	Perineum	
Regio analis	Regio analis	Regio analis
Regio urogenitalis		Regio urogenitalis*
Regio pudendalis	Regio pudendalis	
REGIONES EXTREMITATIS SUPERIORIS	*REGIONES EXTREMITATIS THORACICAE*	*REGIONES MEMBRI SUPERIORIS*
Regio acromialis	Regio acromialis	
Regio deltoidea	Regio deltoidea	Regio deltoidea
Regio brachii lateralis		
Regio brachii medialis		
Regio brachii posterior	Regio brachii dorsalis	Regio brachii posterior
Regio brachii anterior	Regio brachii volaris	Regio brachii anterior
Regio cubiti anterior	Regio cubiti volaris	Regio cubiti anterior
Fossa cubitalis	Fossa cubiti	Fossa cubitalis
Regio cubiti posterior	Regio cubiti dorsalis	Regio cubiti posterior
Regio olecrani	Regio olecrani	
Regio cubiti lateralis		
Regio cubiti medialis		
Regio antibrachii volaris	Regio antebrachii volaris	Regio antebrachii anterior
Regio antibrachii dorsalis	Regio antebrachii dorsalis	Regio antebrachii posterior
Regio antibrachii radialis		
Regio antibrachii ulnaris		
Regio dorsalis manus		Dorsum manus
Regio volaris manus		Palma manus
Regiones digitales (manus)		
Regiones dorsales digitorum	Regiones dorsales digitorum manus	
Regiones unguiculares	Regiones unguiculares	
Regiones volares digitorum	Regiones volares digitorum manus	
REGIONES EXTREMITATIS INFERIORIS	*REGIONES EXTREMITATIS PELVINAE*	*REGIONES MEMBRI INFERIORIS*
Regio glutaea	Regio glutaea	Regio glutea

BNA	JNA	PNA
Regio femoris anterior	Regio femoris ventralis	Regio femoris anterior
Fossa subinguinalis	Fossa subinguinalis	.....
Trigonum femorale (Fossa Scarpae major)	Trigonum femorale	Trigonum femorale
Regio femoris lateralis	.....	.....
Regio trochanterica	.....	.....
Regio femoris posterior	Regio femoris dorsalis	Regio femoris posterior
Regio femoris medialis	.....	.....
Regio genu anterior	Regio genus anterior	Regio genus anterior*
Regio patellaris	Regio patellaris	.....
Regio genu posterior	Regio genus posterior	Regio genus posterior*
Fossa poplitea	Fossa poplitea	Fossa poplitea
Regio cruris anterior	Regio cruris anterior	Regio cruris anterior
Regio cruris posterior	Regio cruris posterior	Regio cruris posterior
Regio suralis	(Regio suralis)	.....
Regio cruris lateralis	.....	.....
Regio cruris medialis	.....	.....
Regio malleolaris lateralis	Regio malleolaris fibularis	.....
Regio malleolaris medialis	Regio malleolaris tibialis	.....
Regio retromalleolaris lateralis	Regio retromalleolaris fibularis	.....
Regio retromalleolaris medialis	Regio retromalleolaris tibialis	.....
Regio calcanea	Regio calcanearis	Regio calcanea
Regio dorsalis pedis	.....	Dorsum pedis
Regio plantaris pedis	Planta pedis	Planta pedis
Regiones digitales pedis	.....	.....
Regiones dorsales digitorum pedis	Regiones dorsales digitorum pedis	.....
Regiones unguiculares pedis	Regiones unguiculares	.....
Regiones plantares digitorum pedis	Regiones plantares digitorum pedis	.....

ADDITIONAL PNA TERMS

(The following terms supplement those which are listed in the foregoing PNA section and are marked with three asterisks)

A. cerebri anterior
A. communicans anterior
Rami corticales
Rami orbitales
Rami frontales
Rami parietales
Rami centrales

A. cerebri media
Rami corticales
Rami orbitales
Rami frontales
Rami parietales
Rami temporales
Rami centrales
Rami striati

A. cerebri posterior
Rami corticales
Rami temporales
Rami occipitales
Ramus parietooccipitalis*
Rami centrales
Ramus choroideus (rami choroidei post.)*

Segmenta bronchopulmonalia
(Pulmo dexter, Lobus superior)
Segmentum apicale
Segmentum posterius
Segmentum anterius
(Pulmo dexter, Lobus medius)
Segmentum laterale
Segmentum mediale
(Pulmo dexter, Lobus inferior)
Segmentum apicale (superius)
(Segmentum subapicale [subsuperius])
Segmentum basale mediale (cardiacum)
Segmentum basale anterius
Segmentum basale laterale
Segmentum basale posterius
(Pulmo sinister, Lobus superior)
Segmentum apicoposterius
Segmentum anterius
Segmentum lingulare superius
Segmentum lingulare inferius
(Pulmo sinister, Lobus inferior)
Segmentum apicale (superius)
(Segmentum subapicale [subsuperius])
(Segmentum basale mediale [cardiacum])
Segmentum basale anterius
Segmentum basale laterale
Segmentum basale posterius

Bronchi lobares et segmentales
Bronchus lobaris superior dexter
Bronchus segmentalis apicalis
Bronchus segmentalis posterior
Bronchus segmentalis anterior
Bronchus lobaris medius dexter
Bronchus segmentalis lateralis
Bronchus segmentalis medialis
Bronchus lobaris inferior dexter

Bronchus segmentalis apicalis (superior)
(Bronchus segmentalis subapicalis [subsuperior])
Bronchus segmentalis basalis medialis (cardiacus)
Bronchus segmentalis basalis anterior
Bronchus segmentalis basalis lateralis
Bronchus segmentalis basalis posterior
Bronchus lobaris superior sinister
Bronchus segmentalis apicoposterior
Bronchus segmentalis anterior
Bronchus lingularis superior
Bronchus lingularis inferior
Bronchus lobaris inferior sinister
Bronchus segmentalis apicalis (superior)
(Bronchus segmentalis subapicalis [subsuperior])
(Bronchus segmentalis basalis medialis [cardiacus])
Bronchus segmentalis basalis anterior
Bronchus segmentalis basalis lateralis
Bronchus segmentalis basalis posterior
Rami bronchiales segmentorum

A. pulmonalis dextra
Ramus apicalis
Ramus anterior descendens*
Ramus anterior ascendens*
Ramus posterior descendens*
Ramus posterior ascendens*
Ramus lobi medii
Ramus lateralis
Ramus medialis
Ramus apicalis (superior) lobi inferioris
Pars basalis
(Ramus subapicalis [subsuperior])
Ramus basalis medialis (cardiacus)
Ramus basalis anterior
Ramus basalis lateralis
Ramus basalis posterior

A. pulmonalis sinistra
Ramus apicalis
Ramus anterior descendens
Ramus posterior
Ramus anterior ascendens
Ramus lingularis
Ramus lingularis superior
Ramus lingularis inferior
Ramus apicalis (superior) lobi inferioris
Pars basalis
(Ramus subapicalis [subsuperior])
Ramus basalis medialis
Ramus basalis anterior
Ramus basalis lateralis
Ramus basalis posterior

(Vv. pulmonales dextrae)**
V. pulmonalis superior dextra
Ramus apicalis
Pars intrasegmentalis
Pars infrasegmentalis (intersegmentalis)
Ramus anterior
Pars intrasegmentalis
Pars infrasegmentalis (intersegmentalis)
Ramus posterior
Pars infralobaris
Pars intralobaris (intersegmentalis)
Ramus lobi medii
Pars lateralis
Pars medialis
V. pulmonalis inferior dextra
Ramus apicalis (superior)
Pars intrasegmentalis
Pars infrasegmentalis (intersegmentalis)
V. basalis communis
V. basalis superior
Ramus basalis anterior

Pars intrasegmentalis
Pars infrasegmentalis
(intersegmentalis)
V. basalis inferior

(Vv. pulmonales sinistrae)**
V. pulmonalis superior sinistra
Ramus apicoposterior
Pars intrasegmentalis
Pars infrasegmentalis
(intersegmentalis)
Ramus anterior
Pars intrasegmentalis
Pars infrasegmentalis
(intersegmentalis)
Ramus lingularis
Pars superior
Pars inferior
V. pulmonalis inferior sinistra
Ramus apicalis superior
Pars intrasegmentalis
Pars infrasegmentalis
(intersegmentalis)
V. basalis communis
V. basalis superior
Ramus basalis anterior
Pars intrasegmentalis
Pars infrasegmentalis
(intersegmentalis)
V. basalis inferior

NUCLEI SYSTEMATIS NERVOSI CENTRALIS

NUCLEI NERVORUM CRANIALIUM

Nucl. n. oculomotorii
Nucl. dorsolateralis
Nucl. ventromedialis
Nucl. caudalis centralis
Nucl. accessorius (autonomicus)
Nucl. n. trochlearis
Nucl. n. trigemini
Nucl. motorius n. trigemini
Nucl. sensorius principalis n. trigemini**
Nucl. tractus mesencephalici n. trigemini
Nucl. tractus spinalis n. trigemini
Nucl. n. abducentis
Nucl. n. facialis
Nucl. salivatorius superior
Nucl. tractus solitarii
Nucl. n. vestibulocochlearis*
Nucl. cochlearis ventralis
Nucl. cochlearis dorsalis
Nucl. vestibularis medialis
Nucl. vestibularis lateralis
Nucl. vestibularis superior
Nucl. vestibularis inferior
Nucl. n. glossopharyngei
Nucl. salivatorius inferior
Nucl. ambiguus
Nucl. tractus solitarii
Nucl. dorsalis n. glossopharyngei
Nucl. n. vagi
Nucl. dorsalis n. vagi**
Nucl. ambiguus
Nucl. tractus solitarii
Nucl. n. accessorii
Nucl. spinalis n. accessorii
Nucl. ambiguus
Nucl. n. hypoglossi

DIENCEPHALON

CORPUS STRIATUM

Thalamus
Stratum zonale**
Nuclei anteriores thalami**
Nucleus anterodorsalis**

Nucleus anteroventralis**
Nucleus anteromedialis**
Nucleus medialis thalami
Nuclei laterales thalami**
Nucleus ventralis anterolateralis**
Nucleus ventralis intermedius**
Nucleus ventralis posteromedialis**
Nucleus ventralis posterolateralis**
Nucleus lateralis dorsalis**
Nucleus posterior (Pulvinar thalami)**
Nucleus reticularis thalami**
Laminae medullares thalami**
Nuclei intralaminares**
Nucleus medialis centralis (centromedianus)**
Nucleus corporis geniculati medialis
Nuclei corporis geniculati laterales**
Nuclei habenulae medialis et lateralis**
Fasciculus retroflexus**
Zona incerta**
Ansa lenticularis**
Ansa peduncularis**
Pedunculus thalami inferior**
Corpus striatum
Nucl. lentiformis
Putamen
Globus pallidus
Nucl. caudatus
Corpus amygdaloideum
Claustrum
Hypothalamus
Nucl. supraopticus
Nucl. paraventricularis
Nucl. ventromedialis
Nucl. dorsomedialis
Nucl. posterior
Nucl. tuberales
Nuclei corporis mamillaris
Nucl. subthalamicus
Nucl. interpeduncularis

MESENCEPHALON

Nucl. ruber
Substantia nigra
Substantia grisea centralis
Formatio reticularis*
Nucl. tegmenti
Nucl. interstitialis
Stratum griseum colliculi superioris
Nucl. pretectalis
Nucl. colliculi inferioris
Nucl. n. oculomotorii (vide supra)
Nucl. n. trochlearis (vide supra)
Nucl. tractus mesencephalici n. trigemini (vide supra)

PONS

Nucl. n. trigemini (vide supra)
Nucl. n. abducentis (vide supra)
Nucl. n. facialis (vide supra)
Nucl. n. vestibulocochlearis* (vide supra)
Nuclei corporis trapezoidei
Nucl. dorsalis corporis trapezoidei*
Nucl. ventralis corporis trapezoidei*
Nucl. lemnisci lateralis
Nucl. pontis
Formatio reticularis*
Substantia ferruginea

MEDULLA OBLONGATA

Nucl. gracilis
Nucl. cuneatus
Nucl. cuneatus accessorius
Nuclei laterales
Nucl. arcuati
Nucl. olivaris
Nucl. olivaris accessorius medialis
Nucl. olivaris accessorius dorsalis

Substantia grisea centralis
Formatio reticularis
Nucl. tractus spinalis n. trigemini (vide supra)
Nucl. n. glossopharyngei (vide supra)
Nucl. n. vagi (vide supra)
Nucl. n. accessorii (vide supra)
Nucl. n. hypoglossi (vide supra)

CEREBELLUM

Nucl. dentatus
Nucl. emboliformis
Nucl. globosus
Nucl. fastigii

MEDULLA SPINALIS

Substantia grisea
Nucl. thoracicus*
Nucl. intermediolateralis (lateralis)**
Nucl. intermediomedialis (medialis)**
Substantia gelatinosa
Substantia alba*
Commissura alba*

EXPLANATORY DICTIONARY

(originally based on the BNA)

A

a, preposition (with ablative), L.: from

a. abbreviation, L. for arteria: artery

a-, prefix signifying the lack of the suffix (e.g. a-cardius: lacking a heart)

abdomen, -inis, n. L.: the belly: the part of the body situated between the thorax and the pelvis

cavum abdominis: abdominal cavity

abdominalis, -e: pertaining to the abdomen

aorta abdominalis: the abdominal part of the aorta

ganglion abdominale: the celiac ganglion

pars abdominalis oesophagei: the abdominal part of the oesophagus

abducens, -entis, L.: abducting; drawing away (abducere: to draw away)

nervus abducens: abducent nerve, the 6th cranial nerve

abductio, -onis, f. L.: abduction; drawing away or moving some part of the body from the median line. Refers usually to articular or muscular movements

abductor, -oris, m. L.: that which abducts

aberratio, -onis, f. L.: aberration; deviating from the usual (or normal) course

acardius, Gr.: lacking a heart (acardiac), developmental anomaly

accelerans, -antis, L.: stimulating, hastening, quickening (accelerare: to haste)

nervus accelerans: a nerve stimulating the heart. Term which has been applied to cervical and thoracic sympathetic branches to the heart

accessorius, -a, -um, L.: accessory; supplementary (accedere: approaching)

nervus accessorius: spinal accessory nerve; the 11th cranial nerve

accommodatio, -onis, f. L.: accommodation, adjustment

muscle of accommodation: the ciliary muscle for the adjustment of the focus of the eye for various distances

acephalus, Gr.: acephalous, without a head; developmental anomaly

acervulus, -i, m. L.: brainsand, a gritty material found in the pineal body of adults

acetabulum, -i, n. L.: the cup-shaped concavity on the os coxae, which accommodates the head of the femur

Achilles tendon: tendo calcaneus: the common tendon of insertion of the superficial flexor muscles, soleus and gastrocnemius, of the calf of the leg. (Achilles: a Greek hero in Homer's *Iliad,* who was invulnerable except at the heel)

acinus, -i, m. L.: grape; small terminal secretory sac of certain compound glands; in another sense, e.g. pulmonary acinus, the functional respiratory unit of the lung

acinaer: acinar; pertaining to an acinus

centro-acinar cells: cells of the wall of an excretory duct which are invaginated into the centre of a glandular acinus

acranius, Gr.: developmental anomaly characterized by the absence of the skull

acromion, -i, n. Gr.: the bone of the shoulder, formed by the lateral extension of the spine of the scapula

acromialis, -e: acromial; pertaining to the acromion

acusticus, -a, -um, Gr.: serving the sense of hearing

nervus acusticus: the auditory or 8th cranial nerve

meatus acusticus internus: the internal auditory meatus

meatus acusticus externus: the external auditory meatus

ad, preposition, L. (with accusative): to

adamantinus, -a, -um, L. from Gr.: adamant; impenetrably hard; used in Gr. of the hardest metal

substantia adamantina: the enamel substance on the crown of the tooth; the tooth enamel

adaptatio, -onis, f. L.: adaptation; the process by which an organism becomes fit for its environment; the ability of the eye to adjust itself to different intensities of light

adductio, -onis, f. L.: adduction; the act of drawing toward a centre, referring usually to articular and muscular movements (adducere: to draw toward)

adductor, -oris, m. L.: that which adducts, a term applied to muscles, e.g. m. adductor magnus: the large adductor of the thigh

canalis adductorius: s. canalis adductorius (Hunteri)

hiatus adductoris: s. hiatus adductoris (tendineus)

adenohypophysis, -is, Gr.: the anterior lobe of the hypophysis cerebri (Gr. aden: gland)

adiposus, -a, -um, L.: adipose; fat, fatty (adeps: fat)

corpus adiposum buccae Bichati: a pad of fat between the masseter and buccinator muscles

corpus adiposum infrapatellare: the infrapatellar pad of fat which lies between the ligamentum patellae and the front of the upper part of the tibia

corpus adiposum orbitae: the fat surrounding the eyeball in the orbit

adipositas, -atis, f. L.: adiposity; fatness

aditus, -us, m. L.: entrance (adire: approach)

aditus ad antrum: the opening between the mastoid antrum and the tympanic cavity

aditus laryngis: the opening into the larynx

aditus orbitae: the opening of the orbit in the skull

adminiculum, -i, n. L.: a support

adminiculum lineae albae: triangular broadening of the inferior end of the linea alba attached behind the rectus abdominis muscles to the posterior part of the pubic crest

adnex, -icis, f. L.: appendage (annectare: to tie on), e.g. the uterine adnexa: the ovaries, oviducts, etc.

adolfactorius, -a, -um, L.: pertaining to the olfactory lobe

area adolfactoria: s. area subcallosa

sulcus adolfactorius ant. et post.: anterior and posterior adolfactory or parolfactory sulci bounding the subcallosal area

adrenalis, -e, L.: adrenal; adrenal gland (ad: near; ren: kidney)

adrenal system: includes the chromaffine cells of the medullary substance of the adrenal glands and the paraganglia

adrenergic nerves: mostly postganglionic sympathetic fibres at the termination of which an adrenalin-like substance is liberated

adventitius, -a, -um, L.: adventitious; coming from without (advenire: to come)

adventitia, -ae, f. L.: the external coat of the blood vessels

adventitia cells: pericytes, the fibroblast-like cells situated in the external coat of the capillaries

aequator, -oris, m. L.: equator

aequator bulbi: the equator of the eye ball: an imaginary line dividing the eye into anterior and posterior hemispheres

afferens, -entis, L.: afferent; conveying, or carrying towards a centre (afferre: to carry)

vasa afferentia: the vessels conveying blood to the lymph nodes and renal glomeruli

affixus, -a, -um, L.: fixed (affigere: to affix)

pars affixa hepatis: the bare area of the liver attached to the diaphragm and not covered by peritoneum

agger, -eris, n. L.: embankment

agger nasi, L.: a slight ridge at the anterior margin of the middle concha above the atrium of the nose

agger perpendicularis: eminentia fossae triangularis: the protuberance on the upper part of the cranial surface of the auricle produced by the triangular fossa

aggregatus, -a, -um, L.: aggregated; crowded or clustered together (aggregare: to assemble)

folliculi aggregati Peyeri: Peyer's patches: aggregations of lymph nodules mainly in the submucosa of the ileum

folliculi aggregati processus vermiformis: the groups of lymph follicles of the vermiform appendix

ala, -ae, f. L.: wing; wing-like structure

ala cinerea: trigonum n. vagi: (grey wing): the area covering the dorsal nucleus of the vagus in the floor of the 4th ventricle

ala lobuli centralis: that part of the hemisphere of the cerebellum continuous with the central lobule of the vermis

ala magna ossis sphenoidalis: the greater wing of the sphenoid bone

ala nasi: the wing of the nostril
ala ossis ilei: the expanded wing-like part of the upper end of the ileum
ala parva ossis sphenoidalis: the lesser wing of the sphenoid bone
ala vomeris: the bifurcating expansions on the superior border of the vomer
alaris, -e, L.: alar; pertaining to a wing, wing-like

albus, -a, -um, L.: white
linea alba: the white line; a tendinous raphe in the midline of the anterior abdominal wall, formed by the insertions of the aponeuroses of the flat abdominal muscles
albicans, -ntis: whitish
albugineus, -a, -um: whitish
tunica albuginea: a covering of white fibrous tissue (of the testis, ovary, eye, penis)

Alcock's canal: the pudendal canal: a duct in the fascia of the obturator internus muscle on the lateral wall of the ischiorectal fossa

allantois, f. Gr.: initially, in man, a diverticulum from the yolk sac into the body stalk. Later it extends from the hind gut into the umbilical cord. Eventually it retrogresses to form the median umbilical ligament

alveolus, -i, m. L.: small cavity; pit
alveoli pulmonum (alveolis pulmonis): pulmonary alveolus; an air sac of the lungs
alveolus dentalis: dental alveolus: bony socket for the root of a tooth
alveolaris, -e, L.: alveolar; pertaining to an alveolus
juga alveolaria: ridges on the anterior surface of the maxillary or mandibular alveolar processes formed by the roots of the incisor and canine teeth
limbus alveolaris: the edge of the alveolar process
processus alveolaris maxillae et mandibulae: the alveolar process of the maxilla and of mandible, which gives attachment to the teeth
septum interalveolare: interalveolar septum: partition separating the sockets of neighbouring teeth

ambi-: a prefix signifying on both sides
ambiens: ambient: surrounding
cisterna ambiens: this part of the subarachnoid space bends laterally around the cerebral peduncles and is the continuation of the cisterna interpeduncularis. Ascending on the dorsal part of the midbrain, it continues into the space between the splenium of the corpus callosum and the upper part of the cerebellum as the cisterna venae magnae cerebri
ambiguus, -a, -um, L.: doubtful (ambigere: to drive in two directions)
nucleus ambiguus: a motor nucleus of the vagus and glossopharyngeal nerves in the reticular formation of the medulla oblongata innervating bronchial muscles

Ammon, -onis, m.: Egyptian God, represented by a ram's head with horns

cornu Ammonis: horn of Ammon: an eminence in the inferior horn of the lateral ventricle of the brain formed by the pes hippocampi

amnion, -ii, n. Gr.: the innermost membrane surrounding the foetus before birth and containing the amniotic fluid

amphiarthrosis, -is, f. Gr.: an articulation permitting little movement and with the bone surfaces joined by fibrous tissue (syndesmosis) or covered by cartilage and joined by fibrous tissue (symphysis)

ampulla, -ae, f. L.: a flask-shaped dilatation of a canal

ampulla seu pars ampullaris recti: rectal ampulla: the dilated portion of the rectum above the anal canal

ampulla ductus deferentis: ampulla of the ductus deferens: the dilated terminal retrovesical part of the ductus deferens

ampulla canaliculi lacrimalis: ampulla of the lacrimal canaliculus: the dilated parts of the lacrimal canaliculi where they change their direction

ampulla hepatopancreatica: hepatopancreatic ampulla of Vater: the dilatation of the common bile and pancreatic duct just before it opens into the duodenum

ampullae membranaceae et osseae: the dilated parts of the membranous semicircular ducts or bony semicircular canals of the internal ear

ampulla tubae uterinae: ampulla of the uterine tube: the dilated part medial to the infundibulum

ampullaris, -e: ampullary; pertaining to an ampulla

Amussat's valve: 1. an unusual fold of mucous membrane below the prostatic sinuses; 2. uvula vesicae: eminence of the mucous membrane of the bladder due to median lobe of prostate

amygdala, -ae, f. Gr.: almond; the tonsil

corpus amygdaloideum: the amygdaloid body or nucleus of the temporal lobe of the brain, which lies in the anterior end of the roof of the inferior horn of the lateral ventricle

amygdalinus, -a, -um, L.: amygdaline; like an almond; pertaining to the tonsil

anaphasis, -is, f. Gr.: anaphase; a stage in mitosis when the chromosomes are passing towards the pole of the spindle

anastomosis, -is, f. Gr.: communication; the communication between vessels or nerves. Clinically: artificial or pathological communication, e.g. intestinal or arteriovenous anastomosis

portocaval anastomosis: communication between the portal (v. portae) and systemic (v. cava inferior) circulation

anatomia, -ae, f. Gr.: anatomy; dissection (anatemnein: to cut); the science of the form and structure of organisms based on dissection

ancon, -onis, f. Gr.: the bend of the elbow

anconaeus, -a, -um: pertaining to the elbow

musculus anconaeus: a small extensor muscle of the elbow

Andersch's ganglion: ganglion inferius (n.IX): the inferior ganglion of the glossopharyngeal nerve which lies in the notch in the lower border of the petrous part of the temporal bone at the lowest part of the jugular foramen

anencephal: anencephalic: congenital absence of the brain

angiologia, -ae, f. Gr.: angiology (angeion: vessel); the study of the (blood and lymph) vessels

angulus, -i, m. L.: angle

angulus costae: the angle of the rib

angulus infrasternalis thoracis: s. incisura thoracica

angulus Ludovici: angulus sterni: sternal angle: the angle marking the junction between the body of the sternum and the manubrium

angulus mandibulae: angle of the mandible: the angle formed by the junction of the body and ramus of the mandible

angulus pubis: angulus subpubicus: pubic angle; the angle under the symphysis between the inferior rami of the pubic bones

angulus scapulae: angle of the scapula: the inferior, medial or lateral angles of the scapula

angulus venosus: venous angle: the angle between the junction of the internal jugular and subclavian veins

angularis, -e: angular

angustia, -ae, f. L.: narrowing, constriction

angustia aortica oesophagei: constriction of the oesophagus where crossed by the aorta at the level of the 3rd–4th thoracic vertebrae

angustia bronchialis oesophagei: constriction of the oesophagus as it is crossed by the left bronchus

angustia cricoidalis oesophagei: the narrowing of the oesophagus at the level of the cricoid cartilage

angustia diaphragmatica oesophagei: constriction of the oesophagus as it pierces the diaphragm

annulus (anulus-PNA), -i, m. L.: ring

annulus conjunctivae: the slightly prominent ring of conjunctiva at the periphery of the cornea

annulus femoralis: femoral ring: the space between the femoral vein and the lacunar ligament of Gimbernat, which is closed by condensed extraperitoneal tissue (septum femorale)

annulus fibrocartilagineus membranae tympani: the fibrocartilaginous ring by which the tympanic membrane is fixed to the tympanic sulcus

annulus fibrosus: the peripheral ring of fibrocartilage of the intervertebral disc

annuli fibrosi cordis: the fibrous rings of the heart surrounding the atrioventricular openings

annulus haemorrhoidalis: a ring-shaped elevation of the mucous membrane containing the anastomoses between the veins of the anal columns

annulus inguinalis abdominalis et subcutaneus: abdominal (deep) and subcutaneous (superficial) inguinal rings: tendinous rings around the deep and superficial openings of the inguinal canal

annulus iridis major et minor: the small inner ring of the iris (pupillary zone) and the large outer ring (ciliary zone). On the anterior surface of the iris these are seen to be separated from each other by the attachment (collarette) of the pupillary membrane

annulus tendineus communis (Zinni): the common tendinous ring giving origin to the rectus muscles of the eye and situated at the medial end of the superior orbital fissure and surrounding the optic foramen

annulus tympanicus: tympanic ring: the semicircle of bone surrounding the tympanic membrane of the new-born. It develops into the tympanic part of the temporal bone

annulus urethralis: urethral ring: a thickening around the internal urethral opening

annulus Vieussensii: s. limbus fossae ovalis (Vieussensii)

annularis, -e, L.: annular; shaped like a ring

anonymus, -a, -um, Gr.: anonymous; nameless, innominate (onoma: name)

ansa, -ae, f. L.: handle, loop

ansa cervicalis superficialis: the anastomosis of the transverse cervical nerve with the cervical branch of the facial nerve

ansa hypoglossi: ansa cervicalis profunda: a loop formed by the junction of a superior branch, containing C_1 and C_2 fibres, from the hypoglossal and an inferior branch consisting of C_2 and C_3 fibres. The loop innervates the infrahyoid muscles

ansa lenticularis: a bundle of efferent fibres, arising in the globus pallidus, and passing medially and partly round the ventral aspect of the internal capsule. Some of the fibres go to the anterior ventral nucleus of the thalamus, others to the subthalamus, hypothalamus and red nucleus and thence to the reticular formation

ansa sacralis: a loop of nerve fibres connecting the last bilateral sacral sympathetic ganglia

ansa subclavia (Vieussensi): ansa subsclavia of Vieussens: a loop connecting the middle and inferior cervical ganglia around the subclavian artery

anserinus, -a, -um, L.: anserine; pertaining to, or like, a goose (anser: goose)

pes anserinus: 1. the common insertion of the sartorius, semitendinosus and gracilis muscles at the upper medial aspect of the tibia; 2. the plexus of the facial nerve in the parotid gland. Clinically: "flat foot"

antagonism, -i, Gr.: opposition, e.g. the opposing function of some muscle groups, acting as antagonists to others

ante: preposition (with accusative), L.: before (in time or place)

antebrachium, -ii, n. L.: antibrachium, forearm

anteflexio, -onis, f. L.: anteflexion; a forward curvature

anteflexio uteri: anteflexion of the uterus: the normal forward curvature of the body of the uterus on the cervix

anterior, -ius, L.: situated in the forward part of, or in front of

anteversio, -onis, f. L.: anteversion; bending forwards

anteversio uteri: anteversion of the uterus: the normal forward bending of the uterus relative to the vagina

anthelix, -icis, m. Gr.: the inner curved ridge of the auricle

anticus: s. anterior

antitragus, -i, m. Gr.: a prominence at the inferior part of the auricle opposite the tragus

antrum, -i, m. L.: a cavity or chamber

antrum Highmorii: antrum of Highmore: s. sinus maxillaris

antrum pyloricum (Willisii): pyloric antrum: the dilated pyloric part of the stomach between the incisura angularis and the sulcus intermedius, which marks the beginning of the pyloric canal

antrum tympanicum: antrum mastoideum: tympanic antrum; a backward extension of the cavity of the middle ear in the temporal bone into which open the mastoid air cells

antrum Valsalvae: s. antrum tympanicum

anulus s. **annulus**

anus, -i, m. L.: ring; the opening of the anal canal on the surface of the body

analis, -e: anal: pertaining to the anus

aorta, -ae, f. Gr.: the largest artery of the body, which arises from the left ventricle of the heart; literal sense of the Greek word: something hung or suspended

arcus aortae: arch of the aorta

aorta ascendens: the ascending part of the aorta, which passes up from the heart to its arch

aorta thoracalis et abdominalis: the thoracic and abdominal parts of the descending aorta

aorticus, -a, -um: aortic: pertaining to the aorta

apertura, -ae, f. L.: aperture, opening (aperire: open)

apertura lateralis ventriculi quarti: lateral apertures of the 4th ventricle: Luschka's foramen: lateral apertures in the inferior part of the roof of the 4th ventricle leading into the subarachnoid space

apertura medialis ventriculi quarti: median aperture of the 4th ventricle: Magendi's foramen: aperture in the thin inferior part of the roof of the 4th ventricle leading into the subarachnoid space

apertura pelvis (minoris), superior et inferior: the superior opening or inlet of the pelvis bounded by the linea terminalis; the inferior opening or outlet of the pelvis bounded by the coccyx, sacrotuberous ligaments, inferior end of ischium and pubic arch

apertura piriformis: the nasal aperture in the skull bounded by the nasal bones and maxillae

apex, -icis, m. L.: the top, peak, summit, tip

apex cordis: the apex of the heart

apex dentis epistrophei: apex of odontoid process of 2nd cervical vertebra or axis

apex nasi: the tip of the nose

apex patellae: the pointed inferior apex of the patella

apex pulmonis: the summit of the lung

apex pyramidis ossis temporalis: the apex of the pyramid of the middle ear

apex radicis dentis: the terminal apex of the root of a tooth

apicalis, -e: apical: pertaining to the apex

apicatus, -a, -um: pointed

aplasia, -ae, Gr.: incomplete or defective development of tissue or organ

apocrin, Gr.: apocrine; secreting

apocrine gland: a gland in which part of the cytoplasm is extruded from the cell during secretion

aponeurosis, -is, f. Gr.: a flattened sheet of dense connective tissue serving as a tendon, e.g. the aponeurosis of the external oblique muscle, or as the investment on the sole of the foot and on the palm of the hand: the plantar and palmar aponeuroses

aponeurosis palmaris: palmar aponeurosis

aponeurosis plantaris: plantar aponeurosis

aponeuroticus, -a, -um: aponeurotic; pertaining to or of the nature of an aponeurosis

apophysis, Gr.: an outgrowth or process usually of bone which may be due to pull of muscle

apparatus, -us, m. L.: parts (organs) concerned in the performance of special functions

apparatus ligamentosus sinus tarsi: s. ligamentum talocalcaneum interosseum

apparatus ligamentosus Weitbrechti: membrane tectoria: a fibrous membrane covering the odontoid process and its ligaments posteriorly. It is continuous below with the posterior longitudinal ligament and above it is attached to the occipital bone

apparatus suspensorius lentis: zonula ciliaris: ciliary zonule (of Zinn); the fibrous thickening of the vitreous body forming a ring behind the ciliary body. It includes the suspensory ligament of the lens

appendix, -icis, f. L.: an appendage

appendix epididymidis: a small pear-shaped appendage of the head of the epididymis being the remnant of the mesonephric duct

appendices epiploicae: fatty pouches projecting beneath the serosa of the colon

appendix fibrosa hepatis: an occasional fibrous appendix of the liver in the left triangular ligament connecting the left lobe and the diaphragm

appendix testis (Morgagnii): appendix of the testis, a small sessile body on the

superior pole of the testis, near the head of the epididymis being a remnant of the paramesonephric (müllerian) duct

appendix ventriculi laryngis: succulus laryngis: saccule of the larynx; the small recess passing upwards from the ventricle

appendix vermiformis: processus vermiformis: vermiform appendix: the worm-like diverticulum of the caecum

appendices vesiculosi epoophori (Morgagnii): small pedunculated vesicles attached to the fimbria of the uterine tube

appendicularis, -e: appendicular; pertaining to an appendage

aqua, -ae, f. L.: water

humor aquaeus: aqueous humour of the eye; fluid occupying the space of the anterior and posterior chamber between the lens and cornea

aquaeductus, -us, m. L.: aqueduct; a passage or canal for conveyance of liquid

aquaeductus cerebri (Sylvii): cerebral aqueduct: the canal traversing the mid-brain and conveying cerebrospinal fluid from the 3rd to the 4th ventricle

aquaeductus cochleae: s. ductus perilymphaticus

aquaeductus vestibuli: aqueduct of the vestibule: the canal arising from the elliptical recess and leading to the posterior surface of the petrous part of the temporal; it contains the endolymphatic duct and a vein

aquula Cotunnii, L.: endolymph contained within the membranous labyrinth

arachnoidea, -ae, f. Gr.: the arachnoid, a delicate membrane (resembling a spider's web) enveloping the brain and the spinal cord and surrounding the underlying sub-arachnoid space

Aranzio's band: lig. venosum (Arantii): fibrous cord being the remnant of the ductus venosus of the fetus on the inferior surface of the liver at the left border of the caudate lobe

Aranzio's bodies: noduli valvularum semilunarium: corpora Arantii: nodules of the semilunar valves: small nodules in the middle of the free margins of the semilunar cusps of the aortic and pulmonary valves

Aranzio's duct: ductus venosus (Arantii): the connection between the umbilical vein and the inferior vena cava in embryonic life

arbor, -oris, f. L.: tree; a tree-like structure

arbor vitae: tree of life; the tree-like formation of the white substance in a median sagittal section of the cerebellum

arciformis, -e, L.: arciform; bow-shaped

arcus, -us, m. L.: arch

arcus aortae: arch of aorta

arcus cartilaginis cricoideae: arch of the cricoid cartilage

arcus cruralis: lig. inguinale: the inguinal ligament of the groin, running from the anterior superior iliac spine to the pubic tubercle

arcus glossopalatinus: arcus palatoglossus: the palatoglossal arch forming the anterior boundary of the tonsillar fossa

arcus lumbocostalis lateralis (Halleri): the lateral arcuate ligament or lumbocostal arch between the transverse process of the 2nd lumbar vertebra and the tip of the 12th rib stretching over quadratus lumborum and giving origin to part of the diaphragm

arcus lumbocostalis medialis (Halleri): the medial arcuate ligament or lumbocostal arch between the bodies of the 1st and 2nd lumbar vertebrae and the 1st lumbar transverse process stretching over psoas major and giving origin to part of the diaphragm

arcus palatinus anterior: s. arcus glossopalatinus

arcus palatinus posterior: s. arcus palatopharyngeus

arcus palatopharyngeus: the palatopharyngeal arch forming the posterior border of the tonsillar fossa

arcus pubis: the pubic arch formed by the inferior rami of the pubic bones

arcus superciliaris: superciliary arch; a ridge of the frontal bone above the supraorbital margin

arcus venosus juguli: the jugular venous arch connecting the anterior jugular veins across the suprasternal space

arcus volaris profundus: arcus palmaris profundus: the deep palmar arch formed by the radial artery and the deep branch of the ulnar artery in the hand

arcus volaris superficialis: and superficial palmar arch formed by the superficial branch of the radial artery and of the ulnar artery in the hand

arcus zygomaticus: the zygomatic arch formed by the zygomatic processes of the zygomatic and temporal bones

arcuatus, -a, -um, L.: arcuate; shaped like an arch

area, -ae, f. L.: area, surface

area acustica: the acoustic or vestibular area of the floor of the rhomboid fossa, beneath it being the vestibular nuclei and crossing part of it, the striae medullares

area cochleae: cochlear area: the anterior part, below the transverse crest, of the lateral end of the internal auditory meatus: pierced by the fibres of the cochlear nerve

area cribrosa papillae renalis: cribriform area of renal papilla: the surface of the renal papillae perforated by the renal tubules as they open into the renal calyces

area subcallosa: the subcallosal area situated anteroinferior to the paraterminal gyrus. Formerly termed the adolfactory area

area vestibularis sup. et inf.: the superior and inferior vestibular areas above and below the transverse crest at the posterior part of the lateral end of the internal auditory meatus: pierced by the vestibular nerve fibres

areola, -ae, f. L.: a small space or area

areola mammae: areola of the breast: the pigmented ring-shaped area surrounding the nipple

areolaris, -e: areolar; pertaining to areolae

argyrophil, Gr.: attracted to silver: tissues easily stained with silver

Arlt's line: a vertical line corresponding to the projection of the nasolacrimal duct and extending from the medial palpebral ligament to the start of the nasolabial fold

Arnold's area: s. ala cinerea fossae rhomboideae: trigonum n. vagi

Arnold's ganglion: s. ganglion oticum

Arnold's substance: substantia reticularis alba: formatio reticularis: reticular formation of the medulla oblongata

Arnold's tract: s. tractus frontopontinus

arrector, -oris, m. L.: that which raises (arrigere: to raise)

arrectores pilorum: the smooth muscles of the cutaneous hair follicles

arteria, -ae, f. Gr.: an artery, a vessel by which blood is conveyed from heart to the tissues

arteriosus, -a, -um: arterious: arterial: pertaining to the arteries, rich in arteries

arteriola, -ae, f.: arteriole; a very small artery of less than 200 μ diameter with a high ratio of wall thickness to lumen diameter

arthrodia, -ae, f. Gr.: a freely moving joint

articulatio, -onis, f. L.: an articulation, or joint

articularis, -e: articular; pertaining to a joint

arytaenoideus, -a, -um, Gr.: arytenoid; shaped like a pitcher

cartilago arytaenoidea: arytenoid cartilage: the pitcher-shaped cartilages of the larynx, which articulate with the cricoid cartilage and give attachment to laryngeal ligaments and muscles

ascendens, -entis, L.: ascending; having an upward course (ascendere: to ascend)

Aschoff–Tawara's node: nodus atrioventricularis: atrioventricular node: a node of specialized conducting tissue in the atrial septum of the heart which continues as the atrioventricular bundle

Aschoff's ducts: small diverticuli extending through the mucosa into the muscle-layer of the gall bladder: perhaps pathological

Aselli's vessels: vasa chylifera: lacteals: the lymph vessels of the small intestines transporting special lymph or chyle

asper, -a, -um, L.: rough

linea aspera: a rough line on the posterior aspect of the shaft of the femur giving attachment to muscles

asperitas, -atis, f. L.: roughness

associatio, -onis, f. L.: association, connection, co-ordination (e.g. of the function of similar organs)

association tracts: tracts interconnecting analogous parts (e.g. ipsilateral cortical areas), serving association in the central nervous system

atlas, -antis, m. Gr.: that which supports; in mythology the giant, who bears up the vault of Heaven; anat. sense: the name of the first cervical vertebra supporting the head

atrium, -ii, n. L.: hall; a cavity, e.g. chamber of the heart
atrium cordis dextrum et sinistrum: the right and the left atria of the heart
atrium meatus nasi medii: the dilated part or atrium of the middle meatus of the nose
atticus, Gr.: s. recessus epitympanicus
auditivus, -a, -um, L.: pertaining to the ear
auditus, -us, m. L.: the sense of hearing
Auerbach's plexus: plexus myentericus: myenteric plexus; the plexus of autonomic nerves between the longitudinal and circular muscle layers of the gut
auricula, -ae, f. L.: auricle: the expanded part of the external ear outside the skull
auricula cordis: auricula atrii: auricle of the heart, a prolongation from the upper anterior part of each atrium
auricularis, -e: auricular: pertaining to the ear or auricle
auris, -is, f. L.: the ear
auris externa: the external ear, including the auricle and external acoustic meatus
auris interna: the internal ear, including the cochlea and semicircular canals
auris media: the middle ear, or tympanic cavity, which contains the three ossicles
axilla, -ae, f. L.: the axillary fossa, or armpit
axillaris, -e: axillary: pertaining to the axillary fossa
axis, -is, m. L.: axis; a line about which there is symmetry, e.g. a straight line end-to-end through the body
axolemma, Gr.: axilemma; the sheath of an axon
axon, -onos, m. Gr.: the axis-cylinder or nerve-fibre process
azygos, Gr.: azygous; unpaired (zygon: yoke; azygos: without yoke)
vena azygos: azygos vein: a vein draining much of the thoracic wall, which passes up on the right side of the thoracic vertebrae and empties into the superior vena cava
vena hemiazygos: s. hemiazygos

B

barba, -ae, f. L.: beard
Bartholin's duct: s. ductus sublingualis major
Bartholin's gland: glandula vestibularis major: greater vestibular gland: the gland beside the lower end of the vagina whose duct opens between the labium minus and the hymen
basilicus, -a, -um, Gr.: basilic; important, prominent
vena basilica: basilic vein: a superficial vein which starts in the dorsal plexus of the hand runs up the medial side of the forearm and arm and continues as the axillary vein
basis, -eos, f. Gr.: ground, base, basic part

basis cartilaginis arytaenoidis: base of the arytenoid cartilage
basis cerebri: base of the cerebrum
basis cochleae: base of the cochlea
basis cordis: base of the heart whence the great vessels emerge
basis cranii: base of the skull
basis modioli: base of the modiolus or cochlear axis at the lateral end of the internal acoustic meatus
basis ossis metacarpalis: base or proximal part of the metacarpal bones
basis ossis metatarsalis: the base or proximal part of the metatarsal bones
basis patellae: the base or proximal broad part of the patella
basis pedunculi cerebri: crus cerebri: the ventral or anterior part of the cerebral peduncle, transmitting efferent tracts including corticospinal and corticopontine fibres
basis phalangis: the base or proximal part of the phalanges of the fingers or toes
basis prostatae: facies vesicalis prostatae: the base of the prostate, which faces the bladder
basis pulmonis: the base of the lung, which lies on the diaphragm
basis pyramidis renalis: the base of the renal pyramid, which is directed toward the surface of the kidney
basis stapedis: the base of the stapes
basalis, -e: pertaining to the base
basal cells: Sertoli's cells: sustentacular cells; the supporting cells within the seminiferous tubules of the testis with the various cell forms of spermatogenesis among them
basal ganglia: basal nuclei: the three central masses of grey matter within the cerebrum: the amygdaloid body, claustrum and corpus striatum including the caudate and lentiform nuclei
basal membrane: membrane, separating in some places the epithelium from the underlying tissue
basilaris, -e: basilar; pertaining to a base, or basal part
membrana basilaris: basilar membrane: the inferior boundary of the cochlear duct extending from the bony spiral lamina to the outer wall of the cochlea

Baudeloque's diameter: conjugata externa: external conjugate diameter: the distance between the superior margin of the symphysis pubis and the groove on the surface of the body situated below the spinous process of the 5th lumbar vertebra

Bauhin's valve: valvula coli: valva ileocecalis: the ileocaecal valve at the junction of the ileum and caecum

Bechterew's bundle: s. tractus spinoolivaris

Bechterew's nucleus: the superior nucleus of the vestibular nerve

Béclard's anastomosis: arcus raninus

Béclard's triangle: the space bounded by the posterior border of hyoglossus, the poste-

rior belly of the digastric muscle and the greater horn of the hyoid bone. Here the hypoglossal nerve lies superficial to the lingual artery

Bellini's tubules: tubuli renales recti: the straight uriniferous collecting tubules of the kidney

Bertin's column: columnae renales: renal columns: extensions of the cortical tissue of the kidney into the medullary substance between the pyramids

Bertin's ligament: lig. iliofemorale: Bigelow's ligament: the iliofemoral ligament of the hip joint extending from the lower part of the anterior inferior iliac spine to the intertrochanteric line

Betz cells: giant pyramidal cells of the motor cortex

bi-, L.: prefix meaning two or twice

biceps, -itis, L.: having two heads (caput: head)

m. biceps brachii: biceps: the flexor muscle of the arm with two heads of origin

bicipitalis, -e: pertaining to biceps

Bichat's fat-pad: the sucking pad superficial to buccinator

Bichat's foramen: a canal of doubtful existence which had been described as affording communication between the subarachnoid space and the third ventricle

biconvex, L.: having two convex surfaces

bicornis, L.: bicornuate; having two horns (cornu: horn)

bicuspidalis, -e, L.: bicuspid; having two cusps

valvula bicuspidalis: the mitral valve of the left atrioventricular orifice

bicuspidatus, -a, -um: bicuspidate, having two points or cusps

bifurcatio, -onis, f. L.: bifurcation; fork; division into two branches (furca: fork)

bifurcatio aortae: terminal bifurcation of the aorta into the common iliac arteries at the level of the 4th lumbar vertebrae

bifurcatio tracheae: the bifurcation of the trachea at the level of the 4th or 5th thoracic vertebra

Bigelow's ligament: ligamentum iliofemorale: s. Bertin's ligament

bigeminus, -a, -um, L.: bigeminal: paired or double; double twins (geminus: twin)

bilateralis, -e, L.: bilateral: pertaining to both sides

bilis, -is, f. L.: the bile

bilifer, -era, -erum: conveying bile (ferre: to convey)

biliosus, -a, -um: bilious; as a lay term meaning nausea, headache, etc., through liver dysfunction

bipartitus, -a, -um, L.: bipartite; having two parts or divisions (partire: divide)

bipolaris, -e, L.: bipolar; having two poles (polus: pole)

bipolar nerve-cells: an embryonic form of the nerve-cell with two processes. The type persists in the vestibular and spiral ganglia

bis, L.: twice

biventer, -era, -erum, L.: having two bellies, especially applied to muscles

m. biventer mandibulae (JNA): m. digastricus (BNA): the digastric muscle

blast, Gr.: a primitive stage in the development of a cell before its definitive form

is attained (e.g. erythroblast, later erythrocyte; neuroblast, later neurocyte) (blast: germ)

blastocoel, Gr.: blastocoele; the cavity of the blastula

blastula, -ae, f. Gr.: an early form of the embryo of many animals, corresponding approximately to the human blastocyst

blepharon, -ontis, n. Gr.: eyelid; s. palpebra

Bochdalek's bouquet: the extensions of the choroid plexus of the 4th ventricle between the cerebellar flocculus and the cerebellar hemispheres

Bochdalek's ganglion: a ganglion said to be present on the superior dental plexus above the canines

Bochdalek's gland-tubules: lateral branches of the thyroglossal duct

Bochdalek's triangle: vertebrocostal trigone: a triangular space usually present between the costal and lumbar parts of the diaphragm at the site of the pleuroperitoneal canal of the embryo

Bogros's space: spatium retroinguinale: the retroinguinal space between the peritoneum and fascia transversalis giving access to the external iliac artery

Bonnet's capsule: capsula bulbi: the anterior part of the vagina bulbi or Tenon's capsule

Botallo's bundle: s. ligamentum arteriosum

Botallo's duct: ductus arteriosus: fetal connection between the aortic arch and the left pulmonary artery, which becomes obliterated at birth to form the ligamentum arteriosum

Böttcher—Cotugno's duct or pouch: s. ductus, or saccus endolymphaticus

Bowman's capsule: capsula glomeruli: glomerular capsule surrounding the tuft of capillary blood vessels, which invaginates the commencement of the uriniferous tubule in the cortex of the kidney

Bowman's glands: tubuloalveolar glands in the olfactory mucosa of the nose

Bowman's membrane: lamina elastica anterior corneae: anterior elastic lamina of the cornea: the strong acellular membrane separating the anterior epithelium from the substantia propria

brachium, -ii, n. Gr.: the arm, the upper arm above the elbow

brachia colliculorum: 1. brachium colliculi superioris: brachium of the superior colliculus: one of the two white tracts connecting the superior colliculi of the corpora quadrigemina with the lateral geniculate bodies; 2. brachium colliculi inferioris: one of the two auditory tracts passing from the inferior colliculi to the medial geniculate bodies

brachium conjunctivum: pedunculus cerebellaris superior: superior cerebellar peduncle: bundle of afferent and efferent fibres passing between the midbrain and cerebellum

brachium (pedunculus) cerebellaris inferior: corpus restiforme: the inferior cerebellar peduncle or restiform body: a prominent tract consisting mainly of afferent fibres to the cerebellum from the medulla oblongata and spinal cord

brachium pontis: pedunculus cerebellaris medius: middle cerebellar peduncle:

tract of fibres almost all of which are passing from the pontine nuclei to the cerebellar cortex

brachialis, -e: brachial: pertaining to the arm

brachycephalus, -i, m. Gr.: brachycephalic: being relatively shortheaded (brachys: short, kephale: head)

branchial arches: the structures bearing the gills of fishes (branchia: gills); anat. sense: the branchial arches in the human fetus

Breschet's canals: s. canales diploici

Breschet's veins: venae diploicae: the diploic veins within the flat bones of the skull

brevis, -e, L.: short

Broca's gyrus: speech centre in the left inferior frontal gyrus

bronchus, -i, m. Gr.: the passages through which the inspired air travels from the trachea to the bronchioles

bronchial tree: the branch-like subdivisions of the bronchi

bronchial lymph glands: the nodes situated alongside the bronchi

bronchialis, -e: bronchial: pertaining to the bronchi

bronchiolus, -i, m. L.: bronchiole; branches of the bronchi which are less than 1 mm in diameter and with no cartilage in their walls

Bruch's membrane: lamina basalis chorioideae: basal lamina of the choroid: the hyaline inner layer of the choroid in the eye, which consists of the choroidal elastic and the retinal cuticular layers

Brücke's muscle: the meridional fibres of the ciliary muscle

Brunn's membrane: membrana limitans olfactoria: external limiting membrane: the membrane said to cover the epithelium in the olfactory region

Brunner's glands: digestive glands in the submucosa of the duodenum

bucca, -ae, f. L.: the cheek

buccalis, -e: buccal; pertaining to the cheek

buccinatorius, -a, -um: pertaining to the cheek or to the buccinator muscle

musculus buccinator: a broad muscle lying in the lateral wall of the oral cavity

bulbus, -i, m. Gr.: a bulb or swelling

bulbus aortae seu arteriosus: aortic bulb: the dilated part of the aorta just above its origin

bulbus medullae seu rachidicus seu spinalis: s. medulla oblongata

bulbus oculi: the eyeball

bulbus olfactorius: the olfactory bulb: the anterior expanded portion of the olfactory tract

bulbus penis: bulb of the penis: the expanded posterior part of the corpus spongiosum

bulbus venae jugularis internae sup. et inf.: superior and inferior bulbs of the internal jugular vein: dilatations of the beginning of the vein below the floor of the tympanic cavity and at its end just before it unites with the subclavian vein

bulbus vestibuli: bulb of the vestibule comprising two masses of erectile tissue on the inferior aspect of the perineal membrane one on either side of the vaginal orifice. They are covered by bulbospongiosus and lie deep to the labia

bulbiformis, -e: bulbiform; bulb-shaped

bulla, -ae, f. L.: blister, vesicle

Burdach's column: funiculus cuneatus: tract of the lateral part of the posterior white column of the spinal cord above the midthoracic level which conveys epicritical pressure and proprioceptive impulses from the cranial half of the body

Burow's veins: renal veins

bursa, -ae, f. Gr.: 1. a sac in the connective tissue lined by a synovial membrane, containing synovial fluid and being interposed between two structures, e.g. muscle and bone, which rub against each other; 2. a pouch of the peritoneum

bursa articularis: articular bursa: a bursa which communicates with, or lies in the immediate neighbourhood of a joint

bursa omentalis: omental bursa: the lesser sac of the peritoneum, which is related anteriorly to the stomach, the inferior surface of the liver and the lesser omentum, and posteriorly to the transverse mesocolon and the posterior abdominal wall

bursa testicularis: sinus epididymidis: a lateral slit-like invagination of the tunica vaginalis between the testis and epididymis

C

caecum, -i, n. L.: cecum: the blind ending pouch at the proximal end of the large intestine

caecus, -a, -um, L.: blind

caecalis, -e, L.: pertaining to the cecum

caeruleus, -a, -um: blueish

Cajal's horizontal cells: irregular cells in the molecular layer of the cerebral cortex with axon and dendrites running parallel to its surface

Cajal's nucleus: nucleus interstitialis Cajali: interstitial nucleus of Cajal: a reticular nucleus at the rostral end of the medial longitudinal fasciculus, which receives impulses from vestibular nuclei and projects to motor centres of the brain stem and spinal cord

calamus, -i, m. L.: reed, writer's pen

calamus scriptorius: an area of the floor of the 4th ventricle shaped like a pen nib and including the hypoglossal and vagal trigones

calcaneus, -i, m. L.: the tarsal bone, which forms the heel

calcar, -aris, n. L.: spur

calcar avis: an elevation caused by the calcarine sulcus and resembling a bird's spur in the posterior horn of the lateral ventricle

calcarinus, -a, -um: calcarine: spur-like

calix, -icis, m. L.: calyx; cup

calix renalis: renal calyx: one of the two or three major, or of the twelve minor calyces, which are subdivisions of the pelvis of the ureter, into which the apices of the renal pyramids project

callus, -i, m. L.: 1. the new bone formed around the fragments of bone following its fracture; 2. thickened hard skin

callosus, -a, -um: callous; scarred, indurated, e.g. corpus callosum

calvaria, -ae, f. L.: the skull-cap forming the vault of the skull (calva: the skull)

calx, -cis, f. L.: the heel

camera, -ae, f. Gr.: chamber

camera anterior bulbi: the anterior chamber of the eye: the cavity between the cornea and the iris containing aqueous humour

camera posterior bulbi: the posterior chamber of the eye: the space between the posterior surface of the iris and the lens containing aqueous humour

Camper's facial angle: the angle formed by the profile of the face and the horizontal plane at the intersection of two lines joining respectively the external auditory meatus to the lower border of the nasal septum, and the most prominent part of the forehead to the incisor teeth

canaliculus, -i, m. L.: a small canal or channel

canaliculi caroticotympanici: caroticotympanic canaliculi: minute canals, which transmit branches of the internal carotid artery and sympathetic fibres from the carotid canal to the tympanic cavity

canaliculi chordae tympani: canaliculi for the chordae tympani: the posterior canaliculus conveys the chorda tympani from the canal of the facial nerve to the tympanic cavity and the anterior canaliculus carries it from the tympanic cavity to the medial end of the petrotympanic fissure

canaliculus cochleae: the cochlear canaliculus: a small bony canal running from the cochlea to the upper boundary of the jugular foramen. It transmits a small vein and the perylymphatic duct

canaliculus dentalis: a dental canal

canaliculus lacrimalis: the lacrimal canaliculus which carries the lacrimal fluid from the puncti lacrimalia to the lacrimal sac

canaliculus mastoideus: mastoid canaliculus: a small canal from the jugular fossa to the tympanomastoid fissure conveying the auricular branch of the vagus nerve and crossing the descending portion of the facial canal

canaliculus tympanicus: tympanic canaliculus: a small canal conveying the tympanic branch of the glossopharyngeal nerve from the anterior wall of the jugular foramen to the tympanic cavity

canaliculus vestibuli: aqueduct or canaliculus of vestibule: a small canal passing from the elliptical recess of the vestibule to the posterior surface of the petrous part of the temporal bone and containingthe ductus endolymphaticus

canalis, -is, m. L.: canal or passage

canalis adductorius (Hunteri): adductor or subsartorial canal in the thigh between adductor magnus, vastus medialis and sartorius. The lamina vastoadductoria forms part of its anterior wall

canalis caroticus: the carotid canal in the petrous part of the temporal bone for the internal carotid artery

canalis carpi: the carpal canal between the palmar surface of the carpal bones and the flexor retinaculum

canalis Cloqueti: hyaloid canal: an embryonic passage in the vitreous body of the eye, which transmits the hyaloid artery. It becomes obliterated after birth

canalis cochlearis: s. ductus cochlearis

canales diploici (Brescheti): diploic canals: small canals within the diploe for the diploic veins

canalis facialis (Falloppii): facial canal: the passage for the facial nerve from the internal auditory meatus through the temporal bone to the stylomastoid foramen

canalis femoralis: femoral canal: the passage on the medial side of the femoral vein, its upper end forming the femoral ring. It lies deep to the saphenous opening and affords passage to a femoral hernia

canalis incisivus: incisive canal: a canal through the bony palate close to the midline behind the incisor teeth. It transmits the terminal part of the long sphenopalatine nerve and of the greater palatine artery

canalis infraorbitalis: the infraorbital canal which passes from the infraorbital sulcus through the maxilla and opens at the infraorbital foramen. It transmits the infraorbital vessels and nerves

canalis inguinalis: the inguinal canal about 4 – 5 cm length starts at the deep inguinal ring, passes obliquely through the anterior abdominal wall just above the inguinal ligament and ends at the superficial inguinal ring. It transmits the spermatic cord or the round ligament of the uterus and affords passage for inguinal hernias

canalis mandibulae: mandibular canal: the passage in the ramus and body of the mandible between the mandibular and mental foramina, which transmits the inferior alveolar nerves and vessels

canalis musculotubarius: the musculotubal canal which starts from the tympanic cavity and opens into the pharynx. A thin bony septum divides it into a lower half, the pharyngotympanic tube, and an upper which transmits tensor tympani

canalis nasolacrimalis: nasolacrimal canal: the bony passage between the orbit and the nose, which transmits the nasolacrimal duct

canalis nasopalatinus: s. canalis incisivus

canalis obturatorius: obturator canal: the canal bounded above by the superior ramus of the pubis and below by the superior free edge of the obturator

membrane and obturator internus and externus. It transmits the obturator nerve and blood vessels

canalis pterygoideus (Vidii): pterygoid canal: the canal piercing the root of the pterygoid process of the sphenoid bone in a posteroanterior direction. It transmits the pterygoid nerve and vessels from the foramen lacerum to the pterygopalatine fossa

canalis pterygopalatinus (canalis palatinus major): greater palatine canal: a passage bounded anteriorly by the maxilla and posteriorly by the vertical plate of the palatine bone. It transmits the greater and lesser palatine nerves and vessels from the pterygopalatine fossa to its openings, the greater and lesser palatine foramina, on the hard palate

canalis sacralis: sacral canal: the inferior part of the vertebral canal in the sacrum

canales semicirculares ossei: the bony semicircular canals in the petrous part of the temporal bone

canalis spiralis cochleae: the bony spiral canal of the cochlea within which lies the cochlear duct

canalis vertebralis: the vertebral canal containing the spinal medulla

caninus, -a, -um, L.: canine; pertaining to a dog (canis: dog)

dens caninus: canine tooth

canthus, -i, m. Gr.: the angle formed between the upper and lower eyelid; angulus oculi medialis et lateralis: the inner or nasal and the outer or temporal canthus of the eye

capillus, -i, m. L.: pilus capitis: hair (of the head)

capillaris, -e, L.: pertaining to a hair, hair-like

capillaris, -is, f. L.: capillary descriptive of the smallest branches of the blood and lymph vessels and of the bile ducts

capitulum, -i, n. L.: a little head; anatomical sense: a small articular eminence on the end of a bone

capitulum costae: caput costae: the head of a rib

capitulum humeri: capitulum of the humerus: the distal eminence, which articulates with the head of the radius

capitulum processus condyloidei mandibulae: caput mandibulae: the articular head of the mandible on its condyloid process

capitulum radii: caput radii: the head or proximal end of the radius

capitulum ulnae: caput ulnae: the head or distal end of the ulna

capsula, -ae, f. L.: capsule; a little box (capsa: capsule) a sheath enclosing a structure

capsula adiposa renis: adipose capsule of kidney: fatty tissue surrounded by the renal fascia and within which the kidney is embedded

capsula bulbi: Tenon's capsule; fascial sheath of the eye ball separating it from the surrounding fat

capsula externa: external capsule: the layer of white fibres between the lateral surface of the lentiform nucleus and the claustrum

capsula interna: internal capsule: fibre tracts covering the internal aspect of the lentiform nucleus and separating it from the caudate nucleus and thalamus, and passing to and from the cortex

capsula lentis: the thin transparent membrane surrounding and forming the capsule of the lens

capsularis, -e: pertaining to a capsule

caput, -itis, n. L.: head

caput angulare musculi quadrati labii superioris: musculus levator labii superioris alaeque nasi (PNA)

caput epididymidis: the head of the epididymis at the upper pole of the testis

caput femoris: the head (proximal end) of the femur articulating with the acetabulum

caput humeri: the head (proximal end) of the humerus articulating with the glenoid cavity of the scapula

caput infraorbitale musculi quadrati labii superioris: musculus levator labii superioris (PNA)

caput medusae: cirsomphalos: periumbilical enlargement of the anastomoses between the epigastric systemic veins and those passing along the falciform ligament to the liver; caused by portal obstruction

caput nuclei caudati: the head or anterior end of the caudate nucleus

caput pancreatis: the head of the pancreas being the portion lying within the concavity of the duodenum

caput tali: the head or anterior part of the talus, which participates in the talocalcaneonavicular joint

capitatus, -a, -um: having a head

os capitatum: the capitate bone of the carpus

Carabelli's tubercle: the small tubercle occasionally seen on the lingual surface of the superior first molar tooth

cardia, -ae, f. Gr.: 1. the heart; 2. cardia ventriculi: the cardiac orifice between the oesophagus and the stomach

cardiacus, -a, -um: cardiac; pertaining to 1. the heart, or 2. the stomach

plexus cardiacus: cardiac plexus: a nerve-plexus sending branches to the heart and formed by fibres from the vagus and the sympathetic trunk

cardiographia: cardiography; the recording of the heart's action

cardiovascularis: cardiovascular; pertaining to the heart and blood vessels

carina, -ae, f. L.: a keel-like ridge

carina tracheae: a prominent ridge at the bifurcation of the trachea between the orifices of the two bronchi

carina urethralis vaginae: urethral carina of the vagina: a prominent ridge on the anterior vaginal wall at the lower end of the anterior columna rugarum and occasionally visible on the external orifice of the urethra

caro, -nis, f. L.: flesh; a term which has been used instead of "muscle" (musculus), e.g. caro quadrata: musculus quadratus plantae

carnalis, -e: carneus, -a, -um: carnal: fleshy

carotis, -idis, f. Gr.: common carotid artery which supplies both the neck and the head, being on the right side a branch of the innominate and on the left springing from the aorta. Both give rise to the external and internal carotids

caroticus, -a, -um: pertaining to the carotid

carpus, -i, m. Gr.: 1. the wrist; 2. the eight carpal bones collectively

carpalis, -e: carpal; pertaining to the carpus, or wrist (hybrid word and linguistically: carpeus, -a, -um; carpicus, -a, -um more correct)

cartilago, -inis, f. L.: cartilage; a connective tissue forming a somewhat elastic flexible substance and consisting of cells enclosed within a matrix composed of collagen and elastic fibres and mucopolysaccharide

cartilago articularis: articular cartilage covering the bony surface of a joint

cartilagineus, -a, -um: cartilaginous; of the nature of, or composed of, cartilage

caruncula, -ae, f. L.: caruncle; a small fleshy eminence (caro: flesh)

carunculae hymenales (carunculae myrtiformes): caruncles of the hymen: remnants of the hymen forming small elevations around the opening of the vagina

caruncula lacrimalis: lacrimal caruncle; a small reddish eminence in the lacus lacrimalis at the medial angle of the eye

caruncula sublingualis: papilla salivaria sublingualis: sublingual caruncle or papilla: the small elevation where the submandibular duct opens into the oral cavity beneath the tongue

caseosus, -a, -um, L.: caseous; resembling cheese (caseus: cheese)

Casserio's muscle: m. perforatus; m. coracobrachialis: a flexor and adductor muscle of the upper arm

Casserio's nerve: n. musculocutaneus: n. perforans Casseri: the musculocutaneous nerve which originates from the lateral fasciculus of the brachial plexus and innervates the flexor muscles of the upper arm and the skin of the lateral aspect of the forearm

castratio, -onis, f. L.: castration; removal of the two testes or ovaries (castrare: castrate)

cauda, -ae, f. L.: tail, or tail-shaped appendage

cauda epididymidis: the inferior tail-like part of the epididymis

cauda equina: horse's tail; lumbar, sacral and coccygeal nerve-roots, arising from and passing below the level of the spinal medulla within the vertebral canal towards the intervertebral foramina. They resemble a horse's tail

cauda helicis: the inferior, pointed part of the helix of the ear

cauda nuclei caudati: tail of the caudate nucleus: the narrow tail-like inferior extremity of the caudate nucleus lying below the thalamus in the roof of the inferior horn of the lateral ventricle

cauda pancreatis: the tail of the pancreas: the terminal part of the pancreas directed towards the spleen

caudalis, -e: caudal; denoting a direction in anatomy: situated inferior to the centre and towards the tail end of the body (opposite to cranial)

caudatus, -a, -um: caudate; having a tail

caverna, -ae, f. L.: cavern, pathological sense, e.g. the cavity occurring in the lung in tuberculosis

cavernosus, -a, -um: cavernous; containing cavities

corpora cavernosa penis: s. corpus

cavum, -i, n. L.: cavity, cave

cavum abdominis: abdominal cavity

cavum articulare: the cavity of a joint

cavum axillare: the axilla or armpit

cavum conchae: the cavity of the concha, into which the external auditory meatus opens

cavum corporis uteri: the cavity of the body of the uterus

cavum dentis: the cavity within a tooth

cavum Douglasi: excavatio rectouterina: the rectouterine pouch of Douglas: a fold of the peritoneum dipping down between the rectum and uterus

cavum extradurale seu epidurale: the epidural cavity; the space between the dura mater of the spinal medulla and the bone forming the wall of the vertebral canal

cavum Meckeli: Meckel's cave: cavum trigeminale: a recess of the dura around the roots and ganglion of the trigeminal nerve on the superior surface of the petrous part of the temporal bone

cavum medullare ossium: the medullary or marrow cavity of a bone

cavum oris: the oral cavity

cavum pericardii: the pericardial cavity: the space between the parietal and visceral layers of the pericardium

cavum pleurae: pleural cavity: the space between the visceral and parietal pleurae

cavum tympani: auris media: the tympanic cavity of the middle ear, which contains the ossicles

cavus, -a, -um: hollow, excavated

cavitas, -atis, f. L.: cavity

cella, -ae, f. L.: a compartment, like the cell of a honeycomb; anat. sense: the cell

cella media: pars centralis ventriculi lateralis: the central part of the lateral ventricle of the brain

cellulae axiramificantes: Golgi's cells of type II: multipolar nerve-cells with numerous branched dendrites and a short axon. They are mainly found in the cortex of the cerebrum and cerebellum

cellulae coli: s. haustra coli

cellulae ethmoidales: sinus ethmoidalis: the air cells within the ethmoid

cellulae mastoideae: mastoid air cells in the mastoid process of the temporal bone, which open into the mastoid antrum and thence into the tympanic cavity

cellulae tympanicae: tympanic air cells having the form of depressions in the wall of the tympanic cavity

cellularis, -e: cellular; made up of cells

cellular pathology: according to the 19th century theory of Virchow all physiological and pathological changes occur in the cells and no life could exist apart from them Omnis cellulae e cellula: every cell descends from some pre-existing cell

centrum, -i, n. Gr.: 1. centre; middle point; 2. the body of a vertebra excluding the part developed from the neural arch

centrum nervosum Willisi: ganglion solare: s. ganglion coeliacum

centrum semiovale: the white matter of the cerebral hemisphere seen in a horizontal section at the level of the upper border of the corpus callosum. It is continuous inferiorly with the internal capsule

centrum tendineum (diaphragmatis): the central tendon of the diaphragm: the middle, tendinous part of the diaphragm

centralis, -e: central, situated at the centre

cephalicus, -a, -um, Gr.: cephalic; pertaining to, or towards the head (kefale: the head)

vena cephalica: the cephalic vein which passes up superficially on the lateral side of the upper arm

cerebellum, -i, n. L.: the part of the hindbrain, which lies inferior to the cerebrum and posterior to the pons and 4th ventricle

cerebellaris, -e: pertaining to the cerebellum

cerebrum, -i, n. L.: the major, superior portion of the brain; the forebrain

cerebralis, -e: pertaining to the cerebrum

cerumen, -inis, n. L.: ear wax (cera: wax)

ceruminosus: ceruminous; pertaining to, or rich in cerumen

cervix, -icis, f. L.: neck

cervix uteri: the inferior narrow part of the uterus which projects and opens into the vagina

cervicalis, -e: pertaining to the neck

Chassaignac's tubercle: tuberculum caroticum vertebrae cervicalis VI: the strongly developed anterior tubercle of the transverse process of the 6th cervical vertebra against which pulsation of the common carotid artery may be felt

chiasma, -atis, n. Gr.: chiasm, a crossing or decussation

chiasma opticum: optic chiasm: the site, at which the optic nerve fibres derived from the nasal half of the retina cross the midline to reach the opposite optic tract

chiasma tendinum digitorum manus: the passage of the tendons of flexor digitorum profundus through those of sublimis opposite the proximal phalanges

choana, -ae, f. Gr.: a funnel-shaped opening; the posterior opening of the nasal cavity leading to the pharynx

choledochus, -i, m. Gr.: the bile duct; (cholé: bile; dochos: containing) s. ductus choledochus

chondrin, Gr.: glue; a gelatinous substance including mucopolysaccharide and protein obtained from cartilage

chondroblast, Gr.: a cartilage-producing cell

chondropharyngeus, -i, m. Gr.: the part of the middle constrictor of the pharynx, which arises from the lesser horn of the hyoid and the adjoining part of the stylohyoid ligament (JNA)

chondrosis, Gr.: the formation of cartilaginous tissue

chondralis, -e: chondral; pertaining to cartilage

chondrinus, -a, -um: containing cartilage

Chopart's articulation: articulatio tarsi transversa (Choparti): the transverse joint of the tarsus (of Chopart) between the calcaneus and talus proximally and the cuboid and navicular distally

chorda, -ae, f. Gr.: a structure resembling a cord, e.g. a tendon or nerve

chorda dorsalis: the notochord

chordae tendineae cordis: the fine tendinous cords, which attach the free margins and ventricular surfaces of the cusps of the tricuspid and mitral valves to the papillary muscles and thence to the wall of the ventricles

chorda tympani: a branch of the facial nerve with its fibres originating from the n. intermedius. It passes to the lingual nerve carrying secretomotor fibres to the sublingual, and submaxillary glands and taste fibres to the anterior two thirds of the tongue

chorion, -i, n. Gr.: the outermost envelope of the ovum which consists of a layer of trophoblast and one of extra embryonic mesoderm and surrounds the embryo, yolk sac and amniotic cavity

chorion frondosum: the placental part of the chorion, which is in contact with the decidua basalis, and where the villi increase greatly in size and complexity

chorion laeve: the smooth part of the chorion towards the decidua capsularis, whose villi retrogress

choroidea, -ae, f. Gr.: choroid, the vascular membrane of the eye, which intervenes between the sclera and retina and is continuous anteriorly with the ciliary body and iris

choroideus, -a, -um: choroidal; pertaining to the choroid

lamina choroidocapillaris: the inner of the two vascular layers of the choroid, which contains the close capillary network

plexus choroideus: choroid plexus: vascular invaginations of the ependyma into the cavities of the lateral 3rd and 4th ventricles of the brain. They contribute to the formation of the cerebrospinal fluid

chromaffin. Gr.: descriptive of cells of the chromaffin system, which are coloured a yellowish brown by certain chrome salts

chromaffin system: organs or structures related to the sympathetic nervous system including the medulla of the suprarenal gland, the paraganglia and the para-

aortic bodies. They probably have a common origin in the embryo from neural crest and their tissue includes chromaffin cells, which are also scattered irregularly among the sympathetic plexuses

chromophil, Gr.: chromophile; an easily stainable cell or tissue component

chromophob, Gr.: chromophobe; a cell not staining readily (phob: fear)

chromosoma, -tos, n. Gr.: chromosomes: the bodies in the cell nucleus, which carry the genes or factors responsible ultimately for the inherited structure of the organism. There are 24 pairs in man including the X and Y sex chromosomes of the male and the paired X chromosomes of the female; *see also* mitosis

chylus, -i, m. Gr.: chyle; the lymph-fluid in the lymph vessels from the small intestine after a meal, which is milk-like owing to its content of absorbed fat

chylifer, -era, -erum: chyliferous; conveying chyle (ferre: to bear)

chymus, -i, m. Gr.: chyme; the semifluid gruel-like material, produced by initial digestion of food in the stomach

cilium, -ii, n. L.: 1. the eyelash; originally: the eyelid; 2. the mobile hair-like processes of certain cells *ciliaris*, -e: ciliary; pertaining to the eyelashes, eyelids or cilia

cinereus, -a, -um, L.: cinereal, cinerous; ashen-grey, e.g. grey matter of the central nervous system (cinis: ash)

cingulum, -i, n. L.: belt: a tract of cortical association fibres, which starts in the frontal lobe below the rostrum of the corpus callosum, passes back, lying deeply in the gyrus cinguli, and ends by extending forwards to the tip of the temporal lobe (cingere: to girdle)

gyrus cinguli: a belt-like convolution on the medial surface of the brain above the corpus callosum

circulus, -i, m. Gr.: circle, ring (circulus: circle). In anatomy: a part of the body which is round or circular

circulus arteriosus Halleri: s. circulus vasculosus n. optici

circulus arteriosus iridis major et minor: the greater and lesser arterial circles of the iris, lying respectively near its periphery and pupillary border

circulus arteriosus Willisi: the circle of Willis: the arterial ring at the base of the brain in the interpeduncular cistern formed by the internal carotid, anterior and posterior cerebral and the anterior and posterior communicating arteries

circulus vasculosus n. optici: a circle of arteries formed by branches of the short ciliary arteries around the entrance of the optic nerve into the eyeball

circulus venosus Halleri: a circle of veins around the base of the nipple on the mammary gland

circularis, -e: circular

circum, preposition, L. (with accusative): round, around

circumanalis, -e, L.: circumanal; situated around the anus

circumductio, -onis, f. L.: circumduction: 1. circular movement of a limb; 2. in anatomy: the motion exhibited by a bone describing a cone with the articular cavity as apex

circumferentia, -ae, f. L.: circumference (circumferre: to carry round)

circumferentia articularis: articular circumference covered with cartilage

circumflexus, -a, -um, L.: circumflex; bent or winding around. In anatomy: a. circumflexa humeri: artery winding around the humerus (circumflectere: bend about)

circumscriptus, -a, -um, L.: circumscribed; confined to a limited space

cisterna, -ae, f. L.: cistern, a closed space containing fluid

cisternae subarachnoideales: enlargements of the subarachnoid spaces between the arachnoid and the pia mater containing cerebrospinal fluid; e.g. cisterna cerebellomedullaris: subarachnoid space between the posterior surface of the medulla oblongata and the cerebellum; clinically: the site for cisternal puncture

cisterna chyli (Pecqueti): receptaculum chyli: a sac-like dilatation of the lower end of the thoracic duct, situated in front of the bodies of the 1st and 2nd lumbar vertebrae. Into it drain the lumbar and intestinal lymph ducts

Civinini's orifice: foramen pterygospinosum: the occasional pterygospinous foramen formed by ossification of the pterygospinous ligament which connects the spine of the sphenoid with the upper part of the lateral pterygoid plate. This foramen transmits the vessels and nerves to the medial pterygoid muscle

Civinini's process: processus pterygospinosus (Civinini): pterygospinous process; an occasional bony process resulting from partial ossification of the pterygospinous ligament

Clarke's column of spinal cord: nucleus thoracicus (dorsalis) medullae spinalis: thoracic nucleus or nucleus dorsalis of the thoracic part of the spinal medulla: a group of cells on the medial edge of the base of the dorsal horn, which receives collaterals from the posterior root and gives rise to the fibres of the posterior spinocerebellar tract (Syn.: Stilling's column, or nucleus)

Claudius' cells: columnar cells covering the basilar lamina of the cochlea peripheral to Hensen's cell

claustrum, -i, n. L.: bar (claudere: to shut, lock) a thin layer of grey substance on the lateral surface of the external capsule, separating the insula from the lentiform nucleus

claustrum virginale: the hymen

clava, -ae, f. L.: club: the gracile tubercle: a small swelling on the dorsal aspect of the medulla oblongata, which contains the gracile nucleus

clavicula, -ae, f. L.: small key, the clavicle, or collar bone (clavis: key)

clavicularis, -e: clavicular; pertaining to the clavicle

cleido, Gr.: a term only used in combination: pertaining to the clavicle

climacterium, -ii, n. Gr.: a critical period in human life: the termination of the reproductive period in the female (cessation of menstruation: menopause) usually between the age of 45—50; sometimes applied to the diminution of sexual activity in the male occurring in later life

clinoideus, -a, -um, Gr.: clinoid; sloping, inclining (klinein: to incline)

clitoris, -idis, f. Gr.: a small erectile body in the anterior part of the vulva homologous to the penis in the male

clivus, -i, m. L.: a slope

clivus Blumenbachii: the internal slope formed by the superior surfaces of the basilar parts of the occipital and sphenoid bones, which terminates above at the dorsum sellae. It supports the pons and the medulla oblongata

cloaca, -ae, f. L.: the canal for the common outlet of the rectum and the genital and urinary ducts in some lower vertebral species, e.g. birds; a homologous transitory structure occurs in the human embryo

Cloquet's canal: canalis hyaloideus: the central hyaloid canal of the vitreous body; a remnant of the canal traversed by the hyaloid artery in the embryo

Cloquet's ganglion: nasopalatine or incisive ganglion: a ganglion, whose existence is doubtful, but it has been said to be associated with the nasopalatine nerve in the incisive canal

Cloquet's membrane: septum femorale: femoral septum: the thin membrane closing the femoral ring, which is perforated by lymphatic vessels

clunis, -is, m. L.: the buttock

coccygeus, -a, -um, Gr.: coccygeal; pertaining to the coccyx (kokkyx: cuckoo)

cochlea, -ae, f. Gr.: snail shell: the spiral conical bony tube forming part of the inner ear and containing the cochlear duct

cochlearis: cochlear; pertaining to the cochlea

coecus: s. caecus

coeliacus, -a, -um, Gr.: celiac; pertaining to the abdomen (koilia: belly)

coeloma, -atos, n. Gr.: coelom; the extra- and intraembryonic body cavities of the embryo. The latter gives rise to the pericardial, pleural and peritoneal cavities

cohabitatio, -onis, f. L.: sexual intercourse; coitus

Cohnheim's areas: areas of relatively densely packed myofibrils described in transverse sections of certain voluntary muscle fibres

coitus, -us, m. L.: sexual union (coire: to meet)

collagen, Gr.: giving glue; a scleroprotein, characterized by its hydroxyproline content, which occurs as white fibres in connective tissue including bone and cartilage

collateralis, -e, L.: collateral: pertaining to the side; secondary or accessory (latus: side)

Colles' ligament: ligamentum inguinale reflexum: reflected part of the inguinal ligament: fibres reflected from the pectineal attachment of the lacunar part of the inguinal ligament towards the linea alba

colliculus, -i, m. L.: a small elevation (collis: mound)

colliculus facialis: facial colliculus: an eminence of the floor of the 4th ventricle caused by the facial nerve passing around the abducent nucleus

colliculus seminalis: seminal colliculus: an enlargement of the urethral crest in the prostatic portion of the male urethra where the ejaculatory ducts and prostatic utricle open

collum, -i, n. L.: neck: thinner part joining the head to the shaft of a bone or to the body of an organ

collum anatomicum humeri: the anatomical neck of the humerus joining the head to the shaft

collum chirurgicum humeri: the surgical neck of the humerus: the constricted portion of the shaft immediately inferior to the tuberosities where the bone is not uncommonly fractured

collum dentis: the neck of the tooth joining the crown to the root

collum mandibulae: neck of the mandible: the constriction joining the condyle to the ramus

collum scapulae: neck of the scapula: an ill-defined constricted portion which joins the head and its glenoid fossa to the rest of the scapula

collum uteri: cervix uteri: the neck of the uterus: the lower constricted segment which projects into the vagina

colon, -i, n. Gr.: the large intestine

colicus, -a, -um: colic; pertaining to the colon

colon ascendens: the ascending colon on the right side of the abdominal cavity, which starts at the ileocolic junction

colon descendens: the descending colon on the left side of the abdominal cavity, which terminates at the sigmoid colon

colon sigmoideum seu pelvinum: sigmoid or pelvic colon: the S-shaped part of the colon extending from the pelvic brim to the third piece of the sacrum, where it continues into the rectum

colon transversum: the transverse colon which extends from the end of the ascending to the beginning of the descending colon

colostrum, -i, n. Gr.: the first milk secreted by the mammary glands a few days before or just after parturition

colpo-, Gr.: a prefix denoting relationship to the vagina (kolpos: vagina)

columna, -ae, f. L.: column

columnae anales (Morgagnii): anal or rectal columns: the longitudinal folds of the mucous membrane of the anal canal above the zona haemorrhoidalis and anal valves

columnae Bertini: renal columns of Bertin; cortical tissue extending between the renal pyramids towards the sinus of the kidney

columnae rugarum anterior et posterior vaginae: two longitudinal folds of the mucosa on the anterior and posterior wall of the vagina

columna vertebralis: vertebral column

columella, -ae, f. L.: a little column

comitans, -antis, L.: accompanying (comitare: to accompany)

commissura, -ae, f. L.: connection (committere: to connect) 1. term applied to bands of fibres or commissural tracts connecting bilateral centres in the nervous system; 2. bars of tissue connecting two similar structures

commissura anterior alba medullae spinalis: anterior white commissure connecting the anterior funiculi in front of the central canal of the spinal medulla and containing decussating spinothalamic fibres

commissura anterior cerebri: the band of fibres on the anterior wall of the 3rd ventricle at the upper end of the lamina terminalis, connecting the right and left olfactory bulbs (anterior part) and the temporal lobes (posterior part)

commissura habenularum: habenular commissure: the band of fibres connecting the two habenulae above the pineal stalk

commissura hippocampi: commissure of hippocampus or fornix: interchange of fibres between the two fornices beneath the corpus callosum, whereby the right and left hippocampi become interconnected

commissura magna cerebri: corpus callosum: the great commissure of the brain lying above the roof of the 3rd ventricle being made up of transverse fibres connecting the cerebral hemispheres

commissura media cerebri: massa intermedia: interthalamic adhesion or connexus which often connects the medial surfaces of the two thalami across the cavity of the 3rd ventricle. Syn.: commissura mollis

commissura posterior cerebri: posterior commissure: tract of fibres, which cross the midline inferior to the pineal and interconnect nuclei of the two sides of the midbrain

commissura posterior medullae spinalis: the grey matter of the spinal cord behind the central canal

commissural tracts: s. commissura

communicans, -tis, L.: communicating, connecting (communicare: being in connection)

arteria communicans anterior et posterior: anterior and posterior communicating arteries, which complete the circle of Willis, the former by joining the two anterior cerebral arteries and the latter by joining the posterior cerebral and internal carotids

communis, -e, L.: common

compactus, -a, -um, L.: compact, dense (compingere: to assemble, to couple)

substantia compacta: the outer dense part of bones

comparative anatomy: the science comparing the structure of different species

complexus, -a, -um, L.: complex; the sum or combination of various components (complectere: to summarize)

compositus, -a, -um, L.: compound; the union of several parts, or materials (componere: to place together)

conarium, -ii, n. Gr.: epiphysis cerebri; the pineal body

concavus, -a, -um, L.: concave; having a depressed or hollow surface

conceptio, -onis, f. L.: conception, fertilization of the ovum (concipere: to conceive)

concha, -ae, f. Gr.: shell

concha auriculae: the hollow of the outer aspect of the auricle

concha nasalis superior, media et inferior: the superior, middle and inferior nasal

conchae are thin plates of the ethmoid, which project downwards and medially into the nasal cavity from its lateral wall. The inferior concha is a separate bone similarly situated and articulating laterally with the maxilla and palatine

concha nasalis suprema Santorini: uppermost nasal concha: an occasional extra concha above the superior concha

conchae sphenoidales: the thin plates of bone of the anterior surface of the body of the sphenoid bone

conchalis, -e: shaped like a shell

condylus, -i, m. Gr.: condyle; a rounded cartilage covered eminence on a bone for articulation with another bone

condylus humeri: condyle of humerus: the distal end of the bone including the trochlea and capitulum

condylus lateralis et medialis femoris: the medial and lateral condyles of the femur: the medially and laterally placed inferior articular masses of the femur

condylus lateralis et medialis tibiae: the lateral and medial condyles of the tibia: the lateral and medial articular prominences of the superior end of the tibia

condylus mandibulae: s. processus condylaris mandibulae

condylus occipitalis: occipital condyles: the eminence of the occipital bone lateral of the foramen magnum for articulation with the atlas

condylus scapulae: s. angulus scapulae

condyloides, Gr.: condyloid; resembling or pertaining to a condyle

condyloideus, -a, -um: condyloid: pertaining to the condyle

confluens, -entis, m. L.: confluence (confluere: running together)

confluens sinuum: the confluence of the sinuses where the superior sagittal, straight, occipital and transverse sinuses meet by the internal occipital protuberance; Syn.: torcular Herophili

congenitalis, -e, L.: congenital; present at birth, born with

conjugatus, -a, -um, L.: conjugate; coupled, paired together (conjugare: to yoke together)

conjugata diagonalis: the diagonal conjugate diameter between the inferior edge of the symphysis pubis and the sacral promontory

conjugata vera: diameter medianus: the true conjugate diameter of the pelvic inlet between the superior edge of the symphysis pubis and the sacral promontory

conjunctiva, -ae, f. L.: tunica conjunctiva: the mucous membrane which lines the inner surface of the eyelids and is reflected thence onto the eye-ball to cover its anterior aspect (conjugere: to connect)

conjunctivalis, -e: conjunctival: pertaining to the conjunctiva

constitutio, -onis, f. L.: constitution; the physical and mental make-up and functional habit of the body (constituere: constitute)

constrictor, -oris, m. L.: that which constricts (constringere: to draw together)

m. constrictor pharyngis, superior, medius et inferior: the superior, middle and inferior constrictor muscles which participate in the formation of the lateral and posterior walls of the pharynx

contortus, -a, -um, L.: contorted, twisted (contorquere: screw together)

tubuli renales contorti: the proximal and distal convoluted tubules of the kidney, which lead respectively from the renal corpuscle to the descending loop of Henle and from the ascending loop to the collecting tubule

contra-, L.: a prefix (with accusative), signifying: against, opposed to

contractio, -onis, f. L.: contraction; shortening (contrahere: to draw together)

contractilis, -e: contractile; having the power to contract

conus, -i, m. Gr.: cone

conus arteriosus (infundibulum): the cone-shaped part of the right ventricle of the heart from which the pulmonary trunk arises

conus elasticus laryngis: a conical elastic membrane attached below to the upper border of the cricoid cartilage and above to the arytenoid and thyroid cartilages, its upper free margin forming the vocal ligament

conus medullaris: the conical end of the spinal cord at the level of the lower part of the first lumbar vertebra

coni vasculosi: the conical lobules of the epididymis, each being formed by the convoluted part of the efferent ductules from the testis

Cooper's fascia: s. fascia cremasterica

Cooper's ligament: 1. the transverse band of the ulnar collateral ligament, which stretches between the medial borders of the olecranon and coronoid processes; 2. the pectineal ligament extending laterally along the pectineal line from the lacunar ligament

cor, -dis, n. L.: the heart

coraco-, Gr.: in combination denotes relationship to the coracoid process (korax: raven)

coracoides: like a raven's beak

coracoideus, -a, -um: pertaining to the coracoid process, the curved piece of bone arising from the superior aspect of the neck of the scapula

corium, -ii, n. Gr.: the true dermis or layer beneath the epidermis, which consists of dense connective tissue

cornea, -ae, f. L.: the transparent layer of tissue forming the anterior part of the external coat of the eye in front of the anterior chamber, and continuous posteriorly with the sclera

cornealis, -e: corneal: pertaining to the cornea

corneus, -a, -um: horny

corniculum, -i, L.: a small horn

corniculatus, -a, -um: corniculate; having or being shaped like a small horn

cornu, -us, n. L.: horn

cornu Ammonis: horn of Ammon; the hippocampus

cornu inferius ventriculi lateralis: the inferior horn of the lateral ventricle, which lies in the temporal lobe of the brain

cornu posterius ventriculi lateralis: the posterior horn of the lateral ventricle, which extends into the occipital lobe of the brain

corona, -ae, f. Gr.: crown; wreath

corona ciliaris: the anterior part of the ciliary body, which includes the ciliary processes

corona glandis penis: the raised ring-shaped posterior margin of the glans penis

corona mortis: the abnormal obturator artery passing around the femoral ring, where its section in femoral herniotomy may cause fatal hemorrhage

corona radiata: 1. a layer of radially arranged cells surrounding the zona pellucida of the mature ovum, some of which remain attached to it after ovulation; 2. the fibres which pass between the internal capsule and the cerebral cortex and intervene between the caudate and lentiform nuclei

coronalis, -e: coronal: pertaining to a crown

coronarius, -a -um: coronary; encircling like a crown

arteriae coronariae cordis: the right and left coronary arteries of the heart, which vascularize the myocardium

sutura coronalis: coronal suture between the frontal and parietal bones

coronoides, Gr.: coronoid: shaped like 1. a crown, 2. a crow's beak

coronoideus, -a, -um: pertaining to a coronoid process

corpus, -oris, n. L.: body

corpus albicans: the fibrous scar tissue that replaces the degenerated corpus luteum

corpus callosum: the great commissure of the brain, consisting of transversely running fibres connecting the cortex of the two cerebral hemispheres. *see also* forceps major and minor

corpus cavernosum penis: one of the two columns of cavernous or erectile tissue, which form the greater part of the bulk of the penis. Erection is caused by their becoming engorged with blood from the helicine arteries

corpus ciliare: the ciliary body of the eye, which connects the iris with the choroid and includes the ciliary ring, processes, muscles and corona

corpus geniculatum laterale: the lateral geniculate body beneath the posterior pole of the thalamus, which relays impulses from the optic tract to the visual cortex

corpus geniculatum mediale: medial geniculate body, which lies inferior to the posterior part of the thalamus lateral to the midbrain and relays auditory impulses from the lateral lemniscus via the inferior colliculus to the auditory cortex

corpus luteum: a yellowish body of the ovary, which develops from the granulosa and theca cells of the graafian follicle after the ovum has been released, and secretes the hormone progesterone

corpus mamillare: the mamillary bodies of the hypothalamus, situated in the interpeduncular fossa on the base of the brain

corpus pineale: the pineal body; s. epiphysis

corpus restiforme: s. brachium cerebellaris inferior

corpus striatum: the striate body, one of the basal nuclei of the forebrain, which includes the caudate and lentiform nuclei, the latter consisting of the putamen and globus pallidus. The striate effect is produced by bands of grey matter passing between the caudate nucleus and putamen through the white matter of the internal capsule

corpus vitreum: the vitreous substance of the eyeball occupying the space between the lens and the retina. A protein gel containing hyaluronic acid

corpusculum, -i, n. L.: corpuscle; a small body

corrugator, -oris, m. L.: that which wrinkles (corrugare: to wrinkle)

m. corrugator supercilii: the muscle which moves the eyebrows downwards and medially and wrinkles the forehead as in frowning

cortex, -icis, m. f. L.: bark; the outer layer of an organ

corticalis, -e, L.: cortical: pertaining to the cortex

cortifugalis, -e: cortifugal: conveying from the cerebral cortex towards the periphery of the body

Corti's cells: the auditory hair cells in the organ of Corti, which are situated by sound waves

Corti's membrane: s. membrana tectoria

Corti's organ: organum spirale: the spiral organ of Corti, which lies on the basilar membrane in the duct of the cochlea and includes supporting and hair cells, the latter responding to auditory stimuli

Corti's rods: the pillars on the basilar lamina of the cochlea, which bound the tunnel of Corti and support the hair cells

costa, -ae, f. L.: rib

costalis, -e: costal; pertaining to the rib

Coste's cell: s. ovum

cotyledo, -onis, f. Gr.: pan or cup; in anatomy: the 15 to 20 lobes of the placenta, which are bounded by septa

cotylicus, -a, -um: cup-shaped

cotyloideus, -a, -um: cotyloid; pertaining to the cotyloid cavity or acetabulum

Cowper's gland: s. glandula bulbourethralis

coxa, -ae, n. L.: the hip

craniologia, -ae, f. Gr.: craniology, the scientific study of skulls

cranium, -ii, Gr.: the skull

cranialis, -e: cranial: 1. pertaining to the skull; 2. denoting direction towards the superior end of the body, opposite to caudal

crassus, -a, -um, L.: thick

cremaster, -eris, m. Gr.: the thin muscular and connective tissue, which forms the inter-

mediate layer of the wall of the spermatic cord and by contraction raises the testis

cribrum, -i, n. L.: sieve

cribriformis: cribriform: resembling a sieve

lamina cribrosa ossis ethmoidalis: the horizontal plate of the ethmoid bone, which is perforated like a sieve by the olfactory nerve fibres

crico-, Gr.: (krikos: circle, ring) in combination denotes relationship to the cricoid cartilage

ligamentum cricothyreoideum (medium): the cricothyroid ligament, an anterior midline thickening of the conus elasticus passing between the thyroid and the cricoid cartilages

cricoides: cricoid; resembling a ring

cricoideus, -a, -um: pertaining to the cricoid cartilage

crista, -ae, f. L.: crest, ridge

crista acustica: crista ampullaris: the ampullary crest in the ampullary portion of the semicircular ducts which contain innervated hair cells responsive to movement of the endolymph

crista galli: the cork's comb: a prominent bony ridge on the upper surface of the ethmoid in the anterior cranial fossa, to which adheres the anterior end of the falx cerebri

crista iliaca: the iliac crest, the superior free edge of the wing of the ilium. It has an internal and external lip and an intermediate area

crista infratemporalis: infratemporal crest of the greater wing of the sphenoid, which separates the temporal from the pterygoid part of the facies temporalis

crista interossea: the interosseous crest: margo interosseus

crista pectinea: s. linea pectinea femoris

crista terminalis atrii dextri: crista terminalis of the right atrium: a prominent ridge of the lateral wall of the right atrium, which separates the smooth posterior wall derived from the sinus venosus from the rough wall of the atrium proper. It is derived from the right venous valve in the embryo

cruciatus, -a, -um, L.: cruciate; crossed (crux: cross)

cruciformis, -e: cruciform; shaped like a cross

crus, -ris, n. L.: leg, or leg-like structure

crura cerebelli ad corporam quadrigeminum: s. brachium conjunctivum (cerebelli)

crura cerebelli ad medullam oblongatam: s. brachium cerebellaris inferior

crura cerebelli ad pontem: s. brachium pontis

crus posterius stapedis: the curved posterior crus or limb of the stapes

cruralis, -e: crural; pertaining to the leg

crypta, -ae, f. Gr.: crypt, underground vault

cubitus, -i, m. L.: the elbow

cubitalis, -e: cubital: pertaining to the elbow

cuboideus, -a, -um, Gr.: cuboid, cuboidal; cube-shaped (cubus: cube)

os cuboideum: the cuboid bone of the tarsus

cucullaris, -e, L.: pertaining to a hood, hood-shaped (cucullus: hood)

culmen, -inis, n. L.: top, summit; in anatomy: the part of the cerebellar vermis which lies between the fissura prima and the postcentral fissure

cum, preposition (with ablative): with, together with

cumulus, -i, m. L.: heap, mound

cumulus oophorus: ovarian cumulus: the ovum and granulosa cells surrounding it in the graafian follicle

cuneus, -i, m. L.: wedge: the area of cortex between the parieto-occipital and calcarine sulci on the medial surface of the cerebral hemisphere (also wedge-shaped bones)

cunealis, -e: cuneal: pertaining to a wedge, or wedge-shaped bone

cuneatus, -a, -um: cuneate; wedge-shaped

cuneiformis, -e: cuneiform, shaped like a wedge

os cuneiforme mediale, intermedium, laterale: the medial, intermediate and lateral cuneiform bones: the wedge-shaped bones lying distal to the navicular in the tarsus

cunnus, -i, m. L.: the vulva

cupula, -ae, f. L.: cupola (cupa L.: barrel or cup)

cupula cochleae: the cupola or apex of the bony cochlea

cupula pleurae: the dome or upper cervical part of the parietal pleura

cupularis, -e: cupular: pertaining to a cupola

curvatura, -ae, f. L.: curvature (curvare: to curve)

curvatura ventriculi major: the greater convex curvature of the stomach, which forms its left and inferior border

curvatura ventriculi minor: the lesser concave curvature of the stomach, which forms its superior border

curvilineus, -a, -um: curvilinear

crus curvilineum: s. *crus posterius*

cuspis, -idis, f. L.: cusp, pointed elevation; cusp of a tooth, one of the projections on the crown of a tooth

cuspidalis, -e: cuspidate: having a cusp

cuspidate valve: the atrioventricular valves of the heart, which possess cusps

cuticula, -ae, f. L.: the cuticle, the superficial layer of the skin

cutis, -is, f. L.: the skin

cutaneus, -a, -um: cutaneous: pertaining to the skin

cylinder, -i, m. Gr.: a body with a circular transverse and a rectangular longitudinal section

cylindricus, -a, -um: cylindrical; shaped like a cylinder

cymba, -ae, f. Gr.: boat

cymba conchae: the upper part of the concha above the crus helicis

cysticus, -a, -um, Gr.: cystic; 1. pertaining to the urinary or gall bladder; 2. referring to a cyst (kystis: bladder)

cyto-, Gr.: in combination denoting relationship to a cell (kytos: cell)

cytologia: cytology: the scientific study of cells

cytoplasma: the cytoplasm; the protoplasm included within the cell membrane but excluding the nuclear contents

D

d. (abbreviation) L. for dexter: the right (side), the right one

dacryocysta, -ae, f. Gr.: dacryocyst: the lacrimal sac (dacryon: tear); s. saccus lacrimalis

dactylus, -i, m. Gr.: finger or toe; s. digitus

dartos, Gr.: flayed

tunica dartos: dartos muscle; a thin layer of non-striped muscular fibres, continuous around the base of the scrotum with the deep layer of the superficial fascia of the abdomen and perineum

de, preposition (with ablative), L.: from

decidua, -ae, f. L.: Hunter's membrane: the endometrium or uterine mucosa after it has hypertrophied preparatory to the implantation of the ovum (decidere: to fall off)

decidua basalis: the part of the decidua between the blastula and the myometrium

decidua capsularis: the part of the decidua covering the blastula and separating it from the lumen of the uterus

decidua parietalis: the decidua lining the uterus apart from the decidua basalis and capsularis

decidualis, -e: decidual; pertaining to the decidua

deciduus, -a, -um: deciduous; impermanent; term applied to the teeth of the first dentition

declive, -is, n. L.: slope (declive: hill)

declive cerebelli: the anterior part of the vermis of the middle lobe of the cerebellum bounded anteriorly by the fissura prima and posteriorly by the postclival fissure

decussatio, -onis, f. L.: decussation, crossing, often of the midline (decussare: to cross in the form of an X); the crossing of nerve-tracts

decussatio brachii conjunctivi: decussatio pedunculorum cerebellarium superiorum: the crossing of the superior cerebellar peduncles in the tegmentum of the midbrain. The constituent fibres are largely proceeding from cerebellar nuclei to the red nucleus and thalamus

decussatio lemniscorum: the decussation of the lemnisci: sensory decussation: the crossing of fibres from the gracile and cuneate nuclei in the medulla oblongata before they pass into the medial lemniscus

decussatio nervorum trochlearium: the crossing of the trochlear nerves in the superior medullary velum

decussatio pyramidum: pyramidal decussation: the crossing of the majority of the motor corticospinal fibres on the anterior aspect of the lower part of the medulla oblongata

decussationes tegmenti: the decussations of the tegmentum; decussating fibres in the mesencephalon including 1. the ventral tegmental decussation (decussatio tegmentalis ventralis) of the rubrospinal and of the rubroreticular tracts, and 2. the dorsal tegmental decussation (decussatio tegmentalis dorsalis) of the tectospinal tracts

decussatus, -a, -um: decussated; crossed

defaecatio, -onis, f. L.: defaecation; the discharge of faeces (defaecare: to clean)

deferens, -ntis, f. L.: deferent; conveying away from (deferre: to carry away)

ductus deferens: vas deferens; the thin muscular tube which is a continuation of the duct of the epididymis and conveys the spermatozoa through the inguinal canal to the ejaculatory duct

deferentialis, -e: pertaining to the ductus deferens

defloratio, -onis, f. L.: defloration; the rupturing of the hymen (deflorare: to pick flowers)

degeneratio, -onis, f. L.: degeneration, deterioration; change of cells, tissues or whole organs to a lower functional level including complete breakdown

dehiscentia, -ae, f. L.: dehiscence; slit or gap (dehiscere: to gape)

dehiscentia pyramidis: a term which has been applied to a bony deficiency of the tegmen tympani, through which the mucous membrane of the tympanic cavity may communicate with the meninges

Deiters' cells: 1. supporting cells which alternate with the outer hair cells of the organ of Corti; 2. nerve-cells with long processes (Golgi cells of type I)

Deiters' nucleus: nucleus vestibularis lateralis: the lateral vestibular nucleus

deltoideus, -a, -um, Gr.: deltoid; triangular (resembling the Greek letter delta)

m. deltoideus: the deltoid muscle which abducts the arm

dendrite, Gr.: a protoplasmic process of a nerve-cell, which conducts impulses towards the cell body. Often multiple and branched (dendron: tree)

Denonvilliers' fascia: septum rectovesicale: the rectovesical septum which intervenes between the rectum posteriorly and the prostate and the urinary bladder anteriorly

Denonvilliers' ligament: lig. puboprostaticum: the puboprostatic ligaments: a pair of ligaments between the prostate and pubis formed by condensation of the pelvic fascia

dens, -tis, m. L.: tooth

dens epistrophei: the dens or odontoid process of the 2nd cervical vertebra or axis

dentes canini: dentes angulares: the canine teeth interposed between the incisors and premolars. There is one on each side of the upper and lower jaw

dentes decidui: the milk teeth of the first dentition

dentes emboliformes: supernumerary teeth between the normal ones

dentes incisivi: the incisor teeth: there are two on each side of the midline of the upper and lower jaw

dentes molares: dentes multicuspidati: the molar teeth, of which there are two on each side in the deciduous and three on each side in the permanent dentition in the upper and lower jaw

dentes permanentes: the permanent teeth of the adult

dentes praemolares: dentes bicuspidati: the premolar teeth of the permanent dentition interposed between the canines and molars. There are two on each side of the upper and lower jaw

dentes serotini seu sapientiae: the wisdom teeth or 3rd permanent molars

dentalis, -e: dental: pertaining to the teeth

dentatio, -onis, f. L.: dentition; 1. the eruption of the teeth through the gum; 2. the sets of deciduous and permanent teeth (dentire: to teethe)

dentatus, -a, -um: dentate; having teeth

nucleus dentatus: the dentate nucleus in the white substance of the cerebellum, which projects largely to the red nucleus and thalamus

denticulus, -i, m. L.: denticle; a small tooth, or tooth-like process

denticulatus, -a, -um: denticulated; in anatomy: having closely arranged very small teeth or tooth-like processes

ligamentum denticulatum: a scalloped band which extends laterally from the pia and is attached to the dura mater between the spinal nerve roots, thus suspending the spinal medulla within the subarachnoid space

dentinum, L.: dentine: the bone-like substance (substantia eburnea: ivory), which forms most of the hard substance of the tooth and is covered with enamel on the crown and with cement on the root

depressor, -oris, m. L.: that which depresses (muscle) (deprimere: to press down)

n. depressor cordis: a term which has been applied to the inhibiting fibres of the vagus nerve to the heart

derma, -atis, n. Gr.: the skin

dermatologia: dermatology; the branch of medicine dealing with diseases of the skin

Descemet's membrane: s. lamina limitans posterior

descendens, -ntis, L.: descending (descendere: to descend)

aorta descendens: the descending aorta

descensus, -us, m. L.: descent

descensus testis: the descent of the testes from the abdominal cavity into the scrotum. The final part of this descent through the inguinal canal usually occurs in the last fetal month

descriptive anatomy: systematic anatomy, which describes the organs of the normal body (describere: to describe)

detritus, -us, m. L.: the product of deterioration or wearing away; in anatomy the remains of broken-down cells and tissues (deterere: to rub away)

detrusio, -onis, f. L.: pushing down (detrudere: to push down)

m. detrusor urinae: the muscle of the wall of the bladder which expels the urine

m. detrusor ventriculi: a term which has been applied to the muscle fibres bending over the cardiac notch of the stomach to extend over its anterior and posterior walls

deviatio, -onis, f. L.: deviation; turning away from the regular course

deviatio septi nasi: deviation of the nasal septum to the right or left of the midline

dexter, -a, -um, L.: situated on, or pertaining to the right side

di-, Gr.: in combination: twice, or two

dia-, Gr.: in combination: through, across

diameter biparietalis: biparietal diameter; the distance between the two parietal eminences

diameter bitemporalis: bitemporal diameter: the distance between the stephanion or the end of the coronal suture on either side

diameter costalis: a costal diameter

diameter fronto-occipitalis: occipitofrontal diameter: the distance between the glabella and the most prominent point on the occipital bone

diameter mento-occipitalis: occipitomental diameter: the distance between the most prominent point on the occipital bone and the midpoint of the chin

diameter suboccipitobregmatica: suboccipitobregmatic diameter: the distance between the centre of the anterior fontanelle and the inion

diaphragma, -atis, n. Gr.: fence, partition; diaphragm; in anatomy: the musculotendinous partition which separates the abdomen from the thorax

diaphragma oris: the oral diaphragm: formed by the mylohyoid muscle which supports the floor of the mouth

diaphragma pelvis: pelvic diaphragm: the floor of the pelvic cavity formed mainly by the levatores ani and coccygei muscles

diaphragma sellae: a disk-like fold of dura mater roofing over the pituitary fossa and surrounding the stalk of the hypophysis

diaphragma urogenitale: urogenital diaphragm: a two-layered membrane which almost fills in the pubic arch stretching between the conjoint rami and the ischial tuberosities. It consists of the superior and inferior (perineal membrane) fasciae which enclose the deep perineal pouch

diaphragmaticus, -a, -um: diaphragmatic; pertaining to a diaphragm

diaphysis, -is, f. Gr.: the shaft of a long bone (diaphysis: growing through)

diarthrosis, -is, f. Gr.: a synovial articulation allowing considerable movement (Gr. sense: articulated)

diastole, -es, f. Gr.: dilatation; the stage of relaxation of the myocardium when the heart cavities dilate and fill with blood

dicephalus, -i, m. Gr.: dicephalous, having two heads

diencephalon, -i, n. Gr.: the part of the forebrain, which form the walls of the 3rd ventricle including the epi-, hypo-, sub- and metathalamus, as well as the thalamus proper but excluding the lamina terminalis

digastricus, -a, -um, L.: having two bellies (L.: biventer)
m. digastricus: m. biventer mandibulae: the digastric muscle of the neck
digestorius, -a, -um, L.: serving digestion; digesting (digerere: to distribute, to digest)
apparatus digestorius: the digestive system
canalis digestorius: digestive canal, the alimentary canal
digitus, -i, m. L.: digit; a finger or toe
digitus annularis (IV): the ring or fourth finger
digitus index (II): the second or forefinger
digitus medius (III): the middle or third finger
digitus minimus (V): the little or fifth finger or little toe
digitalis, -e: digital; pertaining to a finger or a toe
digitatus, -a, -um: digitate; having fingers (or finger-shaped processes)
impressiones digitatae: digital impressions; impressions on the inner surface of the neurocranium due to cerebral convolutions
digitatio, -onis, f. L.: digitation; a finger-like process especially of muscle
dilatatio, -onis, f. L.: dilatation; the enlargement of a hollow structure or its cavity (e.g. heart, stomach, bladder, etc.) (dilatare: to broaden, to extend)
dilatator, -oris, m.: that which dilates
m. dilatator naris: a very small muscle which helps to widen the anterior nasal aperture
m. dilatator pupillae: radiating muscle fibres which supposedly dilate the iris; their presence is denied by some
diploë, -es, f. Gr.: the spongy, osseous tissue between the two compact tables of the flat cranial bones (diploë: double)
diploicus, -a, -um: pertaining to the diploë
diplopia, -ae, f. Gr.: double vision; seeing single objects as double
directio, -onis, f. L.: direction, trend (dirigere: to put straight, arrange)
dis-, L.: in combination, separation or reversal, denoting a sense opposite to that of the second part of the word (e.g. dis-similatio: dissimilar)
discus, -i, m. Gr.: disk
discus articularis: articular disk: a fibrocartilaginous stucture between the articular surfaces of the bones of some synovial joints
discus intervertebralis: fibrocartilagines intervertebrales (BNA): intervertebral disk; a fibrocartilaginous disk between, and uniting the bodies of adjacent vertebrae. Its central part is the nucleus pulposus and its periphery the anulus fibrosus
discus ovigerus: s. cumulus oophorus
disfunctio, -onis, f. L.: dysfunction; disturbed or abnormal function
dispositio, -onis, f. L.: disposition; 1. a tendency toward certain diseases; 2. temperament (disponere: to distribute)
disseminatio, -onis, f. L.: dissemination; extension, distribution (semen: seed; disseminare: to sow); e.g. the spreading of a pathological process

dissimilatio, -onis, f. L.: dissimilation; destructive metabolism (catabolism): decomposition of organic substances eventually into waste material, the reverse of constructive metabolism (anabolism): the assimilation of food derivatives into living cells, where they participate in the building up of their protoplasm (similis: alike, assimilatio: to make like: dissimilatio: to make unlike)

distalis, -e, L.: distal; denotes something as being further away from the centre of the body as opposed to a structure which is proximal or nearer its centre. Often used with reference to structures in the limbs as being further away from the trunk (distare: standing apart)

distantia, -ae, f. L.: distance, interval

distantia cristarum: intercristal diameter: the distance between the outer lips of the right and left iliac crests where they are farthest apart

distantia intertrochanterica: intertrochanteric distance: the distance between the two points of the right and left greater trochanters, which are farthest apart

distantia spinarum: interspinous distance: the distance between the tips of adjacent vertebral spines

divergens, -entis, L.: divergent; spreading or tending apart, deviating (divergere: to tend apart)

divergatio, -onis, f.: divergence; a spreading or tending apart

divergentia, -ae, f.: divergence. In ophthalmology: the simultaneous abduction or lateral rotation of both eyes. The reverse of convergence, in which the visual axes tend toward a common point by medial rotation of the two eyes as occurs when looking from a distant to a near object

diverticulum, -i, n. L.: a recess, sacculation, or blind pouch of a hollow organ (stomach, intestines, urinary bladder, etc.) (divertere: to turn aside)

diverticulum Heisteri: bulbus venae jugularis superior: the superior bulb of the internal jugular vein, a slight dilatation at its commencement in the jugular foramen

diverticulum ilei verum: Meckel's diverticulum from the ileum, which occurs about three feet from the ileocoecal valve in about 2% of subjects. It may be attached to, or open onto the umbilicus and it is a remnant of the vitellointestinal duct

diverticulum pituitarium: pituitary diverticulum: 1. Rathke's pouch; an ectodermal diverticulum, which grows up from the dorsal wall of the embryonic buccal cavity, and develops into the anterior lobe of the pituitary body; 2. the term has also been applied to the down-growth from the floor of the diencephalon, which gives rise to the posterior lobe of the pituitary

diverticulum Vateri: s. ampulla hepatopancreatica

dolichocephalus, -i, m. Gr.: dolichocephalic: long headed, the transverse diameter of the head being less than 75% of the anteroposterior. The reverse of brachiocephalus: short-headed (dolichos: long)

dorsum, -i, n. L.: back

dorsum linguae: the upper surface of the tongue

dorsum manus: the back or dorsal surface of the hand

dorsum nasi: the anterior part, at which the two lateral surfaces of the external nose unite

dorsum penis: the superior, dorsal surface of the penis, opposite to the urethral surface

dorsum sellae: the square plate of bone, forming the posterior wall of the sella turcica or pituitary fossa of the sphenoid

dorsalis, -e: dorsal; pertaining to the back. Denoting also direction: towards the back. Opposite to ventral

dorsalflexio: dorsalflexion; bending backwards; bending of the hand or foot towards the dorsum of the forearm or leg

Douglas' cul-de-sac, or pouch: s. excavatio rectouterina

Douglas' fold: s. plica rectouterina

Douglas' line: s. linea arcuata; linea semicircularis

ductulus, -i, m. L.: ductule; a minute duct

ductuli aberrantes: the blind ending ductules, which occur at the upper and lower end of the epididymis. They are vestiges of the collecting tubules of the mesonephros

ductuli biliferi: the biliferous ductules; small channels which lead from the interlobular bile ductules of the liver to the right and left hepatic ducts

ductuli interlobulares: the interlobular bile ductules which convey the bile from the intralobular canaliculi to the biliferous ductules

ductuli prostatici: the excretory ductules of the prostate. There are about 20, most of which open into the prostatic sinus

ductus, -us, m. L.: a duct, a tube for the passage of fluid including excretions, glandular secretions, lymph or occasionally blood or air (ducere: to lead)

ductus alveolares: alveolar duct; passages leading from the respiratory bronchioles of the lungs into the alveolae

ductus arteriosus (Botalli): ductus arteriosus of Botallo: the embryonic connection between the left pulmonary artery and the aortic arch, which develops from the distal part of the left sixth branchial arch artery. It may persist as a congenital abnormality

ductus Bartholinianus: s. ductus sublingualis major

ductus choledochus: the bile duct, formed by the union of the common hepatic and the cystic ducts. It usually joins the pancreatic duct before opening into the second part of the duodenum

ductus chyliferus: s. ductus thoracicus

ductus cochlearis: the membranous cochlear duct of the internal ear, which contains the spiral organ of Corti

ductus cysticus: cystic duct; the excretory passage of the gall bladder, which unites with the common hepatic duct to form the bile duct

ductus deferens: vas deferens: the duct of the testis, which conveys spermatozoa from the epididymis through the inguinal canal to the ejaculatory duct

ductus efferentes testis: 9–17 minute ductules which convey the spermatozoa from the rete testis into the duct of the epididymis

ductus ejaculatorius: ejaculatory duct; the common duct formed by the junction of the excretory duct of the seminal vesicle and the ductus deferens. It opens into the prostatic urethra on the seminal colliculus

ductus endolymphaticus: endolymphatic duct: a blind diverticulum leading from the utriculosaccular duct through the aqueduct of the vestibule to end beneath the dura as the dilated endolymphatic sac

ductus epididymis: the duct of the epididymis: the convoluted tube which forms the bulk of the epididymis and conveys the spermatozoa from the ductuli efferentes to the ductus deferens

ductus epoophori longitudinales: (s. epoophoron): the longitudinal duct or straight tube of the epoophoron: the remnant part of the mesonephric duct, which may extend from the epoophoron into the broad ligament

ductus excretorius vesiculae seminalis: the excretory duct of the seminal vesicle

ductus hepaticus communis: the common hepatic duct which is formed by the union of the right and left hepatic ducts and joins the cystic duct to form the bile duct

ductus incisivus: incisive duct; the duct connecting the nasal cavity with the incisive papilla and thence with the oral cavity in the embryo. This is normally a transitory structure but epithelial remnants may persist

ductus lacrimalis: s. canaliculus lacrimalis

ductus lactiferi mammae: the lactiferous ducts of the mammary gland 15-20 in number and opening separately on the nipple

ductus lingualis: the lingual duct, a term which has been applied to the remnant of the thyreoglossal duct

ductus lymphaticus dexter: the right lymphatic duct: an inconstant vessel, which may be formed by the union of the right jugular, subclavian and bronchomediastinal trunks. If present it is about $^1/_2$ inch long and usually opens into the right brachiocephalic vein at its commencement

ductus nasolacrimalis: the naso-lacrimal duct, which drains the lacrimal fluid from the lacrimal sac to the inferior meatus of the nose

ductus omphaloentericus: s. diverticulum ilei verum

ductus pancreaticus (Wirsungi): the pancreatic duct: the main excretory duct of the pancreas, which usually unites with the bile duct to open into the second part of the duodenum

ductus pancreaticus accessorius (Santorini): the accessory pancreatic duct (of Santorini) which is often present draining the lower part of the head of

the pancreas and opening into the duodenum about 1 inch above the opening of the bile duct

ductus paraurethrales: paraurethral duct which drains a group of small glands lying alongside the lower end of the female urethra (Skene's paraurethral glands) and opens beside the external urethral orifice. The term has also been applied to a duct in the male, which drains some of the urethral glands near the external urethral orifice

ductus parotideus (Stenoni): the parotid duct, the excretory duct of the parotid gland, which traverses the cheek to open into the mouth opposite the second upper molar tooth

ductus perilymphaticus: the perilymphatic duct which lies in the cochlear canaliculus and connects the perilymphatic space of the scala tympani with the subarachnoid space

ductus reuniens (Henseni): the duct connecting the saccule and cochlear duct

ductus semicircularis anterior, posterior et lateralis: the three membranous semicircular ducts which lie within the semicircular canals

ductus sublingualis major: major sublingual duct (of Bartholin): ductus Bartholinianus; the largest, although inconstant duct of the sublingual gland, which opens with, or close to, the submandibular duct

ductus sublingualis minor (Rivini): minor sublingual ducts of Rivinus: 10 to 20 small ducts which pass from the sublingual gland to open into the submandibular duct or directly into the mouth on the sublingual fold

ductus submaxillaris (Whartoni): ductus submandibularis: the submandibular duct (Wharton's duct) which drains the submandibular gland and opens onto the floor of the mouth at the sublingual papilla

ductus sudoriferus: the excretory duct of a sudoriferous or sweat gland

ductus thoracicus: the thoracic duct: the main lymph duct of the body, which starts at the cisterna chyli, ascends through the posterior mediastinum to the root of the neck, where it opens usually into the beginning of the left innominate vein. It generally receives lymph from the whole of the body except the right side of the head, neck and thorax and the right arm

ductus thyreoglossus: thyroglossal duct: the duct which grows down from the floor of the mouth in the embryo and gives rise in the neck to the thyroid gland. It normally disappears but may persist as a cyst, fistula or cord of cells

ductus utriculosaccularis: the utriculosaccular duct which connects the utricle to the origin of the endolymphatic duct and thence to the saccule

ductus venosus (Arantii): the fetal connection between umbilical vein and inferior vena cava which bypasses the liver. It becomes obliterated at birth; the remnants forming the ligamentum venosum

ductus Wirsungi: Wirsung's duct: s. ductus pancreaticus

duodenum, -i, n. L.: the first portion of the small intestine leading from the stomach

to the jejunum, so named because its length is about equal to the breadth of twelve fingers (duodeni: twelve)

duodenalis, -e: pertaining to the duodenum

duplicatus, -a, -um, L.: double, duplicated (duplicare: to fold in two)

durus, -a, -um, L.: hard

dura mater: the outermost toughest and most fibrous of the membranes surrounding the brain and spinal cord

Duverney's gland: glandula vestibularis major: s. Bartholin's gland

E

Ebner's fibrils: delicate collagen fibres in the dentine and cementum of a tooth

Ebner's gland: serous or albuminous secreting glands of the tongue, whose ducts open into the bottom of the furrow, which surrounds the vallate papillae

Ebner's pillar: stuctures which Ebner has described as regulating the blood flow through arteries of the penis

Ebner's reticulum: a term which has been applied to the network of Sertoli cell processes within the semiferous tubules

ebur, -oris, n. L.: ivory, of the nature of ivory

eburneus, -a, -um: eburneous; resembling ivory

substantia eburnea: s. dentinum

ectoblast, Gr.: s. ectoderma

ectoderma, -atis, f. Gr.: ectoderm; the outermost germ layer of the embryo (ektos: outward; derma: skin). The term is due to the epidermis being of ectodermal origin

ectoplasma, -atis, f. Gr.: ectoplasm: a term applied to the outer condensed layer of protoplasm which has been described in certain cells

Edinger's tract or bundle: tractus spinothalamicus: the spinothalamic fibres of the lateral part of the medial lemniscus in the brain stem, which are the upward continuation of the spinothalamic tracts in the antero-lateral fasciculus of the spinal medulla, transmitting sensory impulses including those of pain and temperature

Edinger–Westphal's nucleus: the parasympathetic nucleus of the oculomotor nerve in the midbrain, which gives rise to the fibres innervating the ciliary and sphincter pupillae muscles of the eye

Ehrenritter's ganglion: s. ganglion superius (n. IX)

efferens, -entis, L.: efferent, conveying away from (efferre: leading away). 1. A blood or lymphatic vessel conveying away from an organ or part; 2. a nerve carrying impulses away from a nerve centre to another nucleus, or to a structure outside the central nervous system (centrifugal); opposite to afferent

ejaculatio, -onis, f. L.: ejaculation, expulsion: e.g. the expulsion of the semen at orgasm (ejaculare: to expel)

ejaculatorius, -a, -um: ejaculatory; serving ejaculation

ductus ejaculatorius: s. ductus

elasticus, -a, -um, Gr.: elastic

lamina elastica externa et interna: the external and internal elastic membranes in the walls of the arteries

elevator, -oris, m. L.: that which lifts (elevare: to lift)

m. elevator testis: s. cremaster

ellipticus. -a. -um, Gr.: elliptical

ellipsoideus, -a, -um: ellipsoid

embolus, -i, m. Gr.: wedge, plug; a foreign substance such as a blood-clot obstructing a vessel

emboliformis, -e: emboliform; like an embolus

nucleus emboliformis: small, almost spherical nucleus, which lies medial to the dentate nucleus in the cerebellum

embryo, -onis, f. Gr.: the early antenatal stage in the development of the organism; the term fetus is usually applied to the later, and embryo to the earlier stages of the organism before the third month of intrauterine development (embryon)

embryonalis, -e: embryonal; pertaining to the embryo

embryologia: embryology: the science dealing with the development of the embryo

eminentia, -ae, f. L.: eminence, protuberance (eminere: to stand out, project)

eminentia arcuata: the arcuate prominence on the intracranial, anterior surface of the petrous part of the temporal bone, beneath which lies the anterior semicircular canal

eminentia carpi radialis: radial carpal eminence: a lateral prominence on the anterior aspect of the wrist formed by the tubercles of the scaphoid and trapezium

eminentia carpi ulnaris: ulnar carpal eminence: a medial prominence on the anterior aspect of the wrist formed by the pisiform bone

eminentia collateralis: collateral eminence of lateral ventricle: an elongated prominence lateral to the hippocampus and in front of the collateral trigone, in the floor of the lateral ventricle of the brain. It is formed by the collateral sulcus

eminentia conchae: the conchal eminence: the large prominence on the cranial surface of the auricle produced by the concha

eminentia cruciformis: eminentia cruciata: the cruciform eminence: the four ridges which radiate superiorly, inferiorly and laterally from the internal occipital protuberance on the inner surface of the occipital bone

eminentia iliopubica: eminentia iliopectinea: iliopubic eminence: a protuberance just above the brim of the true pelvis, marking the junction of the ilium with the superior ramus of the pubis

eminentia intercondyloidea: the intercondylar eminence on the superior surface of the tibia between the medial and lateral articular surfaces. It includes the medial and lateral intercondylar tubercles

eminentia medialis fossae rhomboideae: medial eminence: an elevation of the floor of the 4th ventricle extending throughout its length on either side of the midline, and bounded laterally by the sulcus limitans. It includes the facial colliculus, the area postrema and the vagal and hypoglossal trigones

eminentia pyramidalis: pyramidal eminence: a small pyramid of bone on the posterior wall of the tympanic cavity, which contains the stapedius muscle belly

eminentia scaphae: the scaphoid eminence on the medial aspect of the auricle produced by the scaphoid fossa

emissarium, -ii, n. L.: an emissary structure (emittere: to send out)

emissarium condyloideum: the condylar emissary vein which passes through the condylar canal to connect the sigmoid sinus to suboccipital veins

emissarium mastoideum: mastoid emissary vein passing through the mastoid foramen to join the sigmoid sinus to the posterior auricular or occipital vein

emissarium occipitale: the occipital emissary vein which occasionally passes through the occipital bone to connect the confluence of the sinuses with an occipital vein

emissarium parietale (Santorini): the small emissary vein passing through the parietal foramen of the skull, connecting the superior sagittal sinus with the superficial temporal veins

enarthrosis, -is, f. Gr.: a ball and socket joint, in which the articular socket of one bone accommodates more than half of the convex articular head of the other (e.g. hip joint)

encephalon, -i, n. Gr.: the brain

endo-, Gr.: in combination denotes an inward situation, within

endoabdominalis, -e: s. intraabdominalis

endoangialis, -e: intravasalis: within a vessel or vessels

endocardium, -ii, Gr.: the endothelial lining of the heart, which also covers the valves

endocranialis: s. intracranialis

endocrin, Gr.: endocrine, secreting internally; endocrine gland, which secretes directly into the bloodstream (krienin: to separate)

endoderma, Gr.: endoderm, entoderm; the innermost of the three germ layers of the embryo

endogen, Gr.: endogenic, endogenous; developing or originating within the organism; opposite to exogenous

endolympha, -ae, f. Gr.: endolymph; the fluid filling the membranous labyrinth of the ear

endometrium, -ii, n. Gr.: the mucous membrane of the uterus (tunica mucosa uteri)

endomysium, -ii, n. Gr.: perimysium internum: the fine connective tissue surrounding the individual muscle fibres

endoneurium, -ii, n. Gr.: perineurium internum: the delicate connective tissue surrounding the individual peripheral nerve fibres

endopelvicus, -a, -um: endopelvic; situated within the pelvis

endoplasma, -atos, Gr.: endoplasm; a term which has been applied to such cytoplasm as is surrounded by ectoplasm

endosteum, -ii, n. Gr.: the tissue lining the medullary or marrow cavity of bone. The term has also been applied to the lining of the Haversian canal

endothelium, -ii, n. Gr.: (mesothelium) the single layer of flattened pavement cells, which lines the heart, blood-vessels, lymphatics and covers the serous membranes

endothoracicus, -a, -um: endothoracic: lining or within the thorax

ensiformis, -e, L.: ensiform; shaped like a sword (ensis: sword)

processus ensiformis: proc. xiphoideus: the xiphoid process of the sternum

entericus, -a. -um, Gr.: enteric; pertaining to the intestines

ento-, Gr.: within, or inner (s. endo-) (only in combination)

entoderma: s. endoderma

eosinophil cells: cells whose cytoplasm or cytoplasmic granules are readily stained by eosin (philein: to love)

eosinophil leucocytes: the white blood cells whose cytoplasm contains eosin-staining granules

ependyma, -atis, n. Gr.: (upper garment): the single cell layer of columnar epithelium, which lines the ventricles of the brain and the central canal of the spinal medulla

ephippium, -i, n. Gr.: s. sella turcica (hippos: horse)

epi-, Gr.: in combination: on or upon

epiarterialis, seu eparterialis, -e, L.: lying upon an artery

epiblast, Gr.: ectoderma; the outermost germ layer of the embryo

epibulbaris, -e: epibulbar: situated upon, or above the eyeball or any bulb-like structure

epicanthus: plica palpebronasalis

epicapitulum, -i, n. L.: epicondylus lateralis humeri

epicardium, -ii, n. Gr.: pericardium serosum, lamina visceralis: the visceral layer of the serous pericardium. It covers the heart and the origin of the great vessels

epicerebralis, -e, L.: epicerebral: situated above or on the brain

epicondylus, -i, m. Gr.: a bony projection above a condyle of a bone, which does not take part in the articulation and serves for the attachment of muscles

epicranium, -ii, n. Gr.: the scalp; the soft parts covering the neurocranium

epidermis, -is, n. Gr.: the outermost stratified squamous epithelial and non-vascular layer of the skin

epididymis, -idis, f. Gr.: the structure which lies on the upper and posterior aspect of the testis and consists mainly of a coiled duct. The spermatozoa pass from the efferent ductules of the testis through the duct of the epididymis to the ductus deferens (didymos: double, testes) (verbatim: situated upon the testicles)

epiduralis, -e, L.: seu supraduralis: epidural: situated upon or outside the dura mater

cavum epidurale: epi- or extradural space or cavity: the space lying between the dura mater of the spinal medulla and the wall of the vertebral canal, which is occupied by veins and fatty areolar tissue

epifascialis, -e, L.: epifascial; situated upon or outside fascia

epigastrium, -ii, n. Gr.: s. regio epigastrica
epigastricus, -a, -um: epigastric; related to the epigastrium
epiglottis, -idis, f. Gr.: the leaf-shaped piece of elastic cartilage at the entrance to the larynx
epinephros, Gr.: the suprarenal gland
epineurium, -ii, n. Gr.: the connective tissue sheath covering the surface of peripheral nerves
epipharynx, -gis, f. Gr.: pars nasalis pharyngis: the nasal part of the pharynx above and behind the soft palate
epiphysis, -is, f. Gr.: growing upon; 1. a secondary centre of ossification at the end of a long bone, which is joined to the shaft during growth by the epiphyseal cartilage; 2. corpus pineale: the pineal body
epiploon, -i, n. Gr.: net; in anatomy: omentum majus
epiploicus, -a, -um: pertaining to the omentum
episclera, -ae, f. Gr.: s. lamina episcleralis
episcleralis, -e, L.: episcleral; pertaining to the episclera
episternalis, -e, L.: episternal; situated over the sternum
epithalamus, -i, m. Gr.: the part of the diencephalon that includes the pineal body, habenula, habenular commissure and striae medullares
epithelialis, -e: epithelial; pertaining to epithelium
epitrochlea, Gr.: epicondylus medialis humeri
epitympanicus, -a, -um, Gr.: epitympanic; situated over or above the tympanic cavity
epoophoron, -i, n. Gr.: a few rudimentary tubules between the ovary and the uterine tube, the remains of the embryonic mesonephros
equinus, -a, -um, L.: resembling or pertaining to a horse (equus: horse)
Erbs's point: a term, which has been applied to the site of emergence of the upper part of the brachial plexus at the posterior border of sternomastoid about 3 cm above the clavicle
erectio, -onis, f. L.: erection, caused by the increased volume of blood in the cavernous tissues, especially of the penis, but also in the clitoris and nipple (erigere: to erect)
erectilis, -e: erectile; capable of erection
erector, -oris, m. L.: that which erects. Term used in myology
erythrocyta, Gr.: erythrocyte; red blood corpuscle (erythros: red)
ethmoides, Gr.: ethmoid: cribriform; sieve-like (ethmos: sieve)
os ethmoidale: the ethmoid bone
ethmoideus, -a, -um: ethmoidal: pertaining to the ethmoid bone
Eustachian amygdalae: s. tonsilla tubaria
Eustachian muscle: m. tensor tympani which tenses the tympanic membrane
Eustachian tube: s. tuba auditiva (Eustachii)
Eustachian valve: s. valvula venae cavae inferioris (Eustachii)
eversio, -onis, f. L.: eversion: turning outward: movement of the foot so that its sole tends to face laterally (evertere: to turn out)

evisceratio, -onis, f. L.: evisceration; removal of the viscera (viscera: entrails)

evolutio, -onis, f. L.: evolution; a continuous and progressive developmental change

ex, preposition (with ablative): from, out

excavatio, -onis, f. L.: a depression or hollow

excavatio papillae nervi optici: the depression on the papilla of the optic nerve (physiological cup): the normal depression which occurs in the centre of the optic disc where the optic nerve enters the retina

excavatio rectouterina: rectouterine pouch of Douglas: a pouch situated between the rectum and uterus, formed by a fold of the peritoneum

excavatio rectovesicalis: rectovesical pouch: a peritoneal pouch between the urinary bladder and rectum in the male

excavatio vesicouterina: vesicouterine pouch: a peritoneal pouch between the urinary bladder and uterus

excretio, -onis, f. L.: excretion; the function of excreting; the elimination of waste products from the body

excretorius, -a, -um, L.: excretory; serving excretion; eliminating waste products (excernere: to sift out, discharge)

excretum, -i, n. L.: excretion or waste product

exfoliatio, -onis, f. L.: exfoliation; the falling off of surface layers, e.g. of the skin or tongue

exitus, -us, m. L.: outlet (exite: to go out)

exitus pelvis: s. apertura pelvis inferior

Exner's nerve: a small nerve arising from the pharyngeal plexus, which divides to supply cricothyroid muscle and then perforates the cricothyroid membrane to supply branches to the mucous membrane of the larynx. Its fibres may be derived from the vagus

Exner's plexus: the plexus of nerve fibres parallel to, and immediately below, the surface of the cerebral cortex in the molecular layer (lamina zonalis)

exo-, Gr.: outside, outward (a prefix used in combination)

exocrin, Gr.: exocrine; glands whose secretions are carried by ducts

exogen: exogenous (exogenic); originating outside the organism

exophthalmos, Gr.: pathological protrusion of the eyeball

exoplasma, Gr.: s. ectoplasma

exostosis, -is, m. Gr.: a bony outgrowth

exspiratio, -onis, f. L.: expiration; breathing air out from the lungs (exspirare: to breathe out)

exstirpatio, -onis, f. L.: the eradication, or complete removal of a pathological structure (exstirpare: to root out)

extensio, -onis, f. L.: extension; prolongation; enlargement

extensor, -oris, m. L.: any muscle that extends a joint (opposite to a flexor muscle)

externus, -a, -um, L.: external; situated on the outside

extra (prep. with accusative), L.: outward, outside of
extrabuccalis, -e: extrabuccal; outside the mouth
extracardialis, -e: extracardial; outside the heart
extracysticus, -a, -um: extracystic; outside the urinary or gall bladder (or a cyst)
extraduralis, -e: extradural; situated outside the dura mater
extrahepaticus, -a, -um: extrahepatic; outside the liver
extramedullaris, -e: extramedullary; outside the medulla oblongata, spinal medulla or bone marrow
extramuralis, -e: extramural; outside the wall of a structure (murus: wall)
extrapulmonalis, -e: extrapulmonary; outside the lungs
extrapyramidal system: the system of motor pathways, apart from the pyramidal system, which is concerned with the more automatic movements. The cerebral cortex can influence the latter by pathways involving the striatum, pallidum, red nucleus, reticular formation, tectum, cerebellum, etc.
extractio, -onis, f. L.: extraction; drawing out (extrahere: to draw out)
extrauterin, L.: extrauterine; situated outside the uterus
extremitas, -atis, f. L.: extremity; terminal portion; in anatomy: a limb

F

fabella, -ae, f. L.: little bean; in anatomy: the small sesamoid bone sometimes found in the lateral head of the gastrocnemius muscle
facies, -ei, f. L.: face; outer surface
facies anterior dentium premolarium et molarium: the anterior contact surfaces of the premolar and molar teeth
facies anterior pyramidis ossis temporalis: facies ant. partis petrosae: the anterior, or cerebral surface of the petrous part of the temporal bone
facies articularis: articular surface
facies buccalis dentis: the buccal surfaces of the molar and premolar teeth
facies cerebellaris pyramidis: s. facies posterior pyramidis ossis temporalis
facies cerebralis pyramidis: s. facies anterior pyramidis ossis temporalis
facies contactus dentis: the contact surface of the tooth where it touches its neighbour
facies contactus loborum pulmonis: s. facies interlobares pulmonis
facies interlobares: interlobar surfaces of the lung
facies labialis dentis: the labial surface of a tooth
facies lateralis: lateral surface (general term)
facies lingualis dentis: the lingual surface of a tooth
facies masticatoria dentis: the occlusal or chewing surface of a tooth
facies medialis: medial surface
facies posterior: posterior surface

facies posterior dentium premolarium et molarium: the posterior contact surface of the premolar and molar teeth

facies posterior pyramidis ossis temporalis: facies posterior partis petrosae ossis temporalis: the posterior or cerebellar surface of the petrous part of the temporal bone

facies proximalis: proximal surface

facies symphyseos ossis pubis: facies symphysialis: the articular surface of the pubis

facialis, -e: pertaining to the face

n. facialis: the 7th cranial or facial nerve

faeces, -um, f. L.: the excreta, which are discharged from the bowel (faex, -cis, f.: refuse)

Fallopian band or ligament: s. lig. inguinale

Fallopian canal: s. canalis facialis

Fallopian tube: s. tuba uterina (Fallopii)

Fallopian valve: s. valva ileocoecalis

falx, -cis, f. L.: sickle

falx aponeurotica (inguinalis): s. falx inguinalis

falx cerebelli: the small sickle-shaped fold of dura mater, which extends between the cerebellar hemispheres from the internal occipital crest

falx cerebri: the sickle-shaped fold of dura mater between the hemispheres of the cerebrum in the longitudinal fissure, which is attached to the whole length of the vault of the skull in the midline

falx inguinalis (tendo conjunctivus): the conjoint tendon: the lower part of the conjoined aponeuroses of the internal oblique and transversus, which is inserted into the pubic crest and pectineal line

falciformis, -e: falciform: sickle-shaped

lig. falciforme hepatis: the falciform ligament of the liver: a sickle-shaped fold of peritoneum attached to the anterior surface of the liver between the right and left lobes, and to the diaphragm and anterior wall of the abdomen as far down as the umbilicus

Farabeuf's triangle: the triangular space bounded by the internal jugular vein, the common facial vein and the hypoglossal nerve

Farre's white line: the line of attachment of the mesovarium to the ovary

fascia, -ae, f. L.: band or bandage; in anatomy: the thin sheet of connective tissue investing and separating muscle-groups and individual muscles and also covering other structures

fascia cinerea: s. gyrus fasciolaris

fasciculus, -i, m. L.: a bundle or cluster generally of muscle or nerve fibres (fascis, -is, m.: bundle)

fascicularis, -e, *fasciculatus*, -a, -um: clustered together in a bundle; comprising a fasciculus

fasciola, -ae, f. L.: small bandage

fastigium, -ii, n. L.: peak, summit, ridge

fastigium ventriculi quarti: the peak of the roof of the 4th ventricle

nucleus fastigii: a small nucleus in the white substance of the cerebellum near the midline

fastigatus, -a, -um: having a peak

faux, -cis, f. L.: the throat (used in plural: fauces, -ium)

isthmus faucium: isthmus of the fauces: the constricted entrance to the pharynx, which is bounded by the arch of the palatoglossal folds

fecundatio, -onis, f. L.: fecundation; fertilization

fel, fellis, n. L.: bile

felleus, -a, -um: pertaining to bile, or the gall bladder

vesica fellea: the gall bladder

femininus, -a, -um: feminine (femina, -ae: woman)

femur, -oris, n. L.: the thigh-bone; in anatomy: the bone extending from the pelvis to the knee

femoralis, -e: femoral, pertaining to the femur

canalis femoralis: femoral canal: s. canalis

trigonum femorale: s. trigonum

fenestra, -ae, f. L.: window; a window-like opening

fenestra cochleae: a small opening in the medial wall of the middle ear, which leads from the tympanic cavity into the scala tympani of the bony cochlea. It is closed by the secondary tympanic membrane

fenestra vestibuli: an oval opening on the medial wall of the tympanic cavity, which leads into the vestibule. It is occupied by the base of the stapes

Ferrein's canal: rivus lacrimalis: a channel said to be formed during sleep between the borders of the closed lids and the eyeball, which conducts the lacrimal fluid to the punctae lacrimales

Ferrein's ligament: 1. the thick external part of the capsule of the temporomandibular joint; 2. the vocal cord

Ferrein's pyramids: pars radiata: striae medullares: the radiating intracortical medullary rays, which are prolongations from the renal pyramids

fertilis, -e, L.: fertile, fruitful

fetus, -us, m. L.: term applied to the embryo from the beginning of the third month of intrauterine life onwards

fetalis, -e: fetal; pertaining to a fetus

fibra, -ae, f. L.: fibre, thread

fibrae ansatae: a nerve-fibre bundle passing in front of the lamina terminalis and bending back to the tuber cinereum

fibrae arcuatae cerebri: arcuate association of fibres in the cortex of the cerebrum, which connect adjacent convolutions

fibrae arcuatae externae: external arcuate fibres which arise from the arcuate nuclei and cross the surface of the olive to enter the cerebellum by the inferior

cerebellar peduncle. They can be regarded as aberrant pontocerebellar fibres

fibrae arcuatae internae: internal arcuate fibres: the fibres arising from the gracile and cuneate nuclei, which pass ventrally in the medulla, decussate and then form the medial lemniscus

fibrae cerebelloolivares: cerebelloolivary fibres, which have been described passing from the cerebellum, including the dentate nucleus, to the olive by the superior and inferior cerebellar peduncles

fibrae circulares musculi ciliaris (Mülleri): the circular muscle fibres of the ciliary body of the eye, running parallel with the margin of the cornea

fibrae intercrurales: intercrural fibres connecting the medial and lateral crura of the superficial inguinal ring

fibrae lentis: fibres forming the substance of the lens of the eye

fibrae meridionales (Brueckei): the meridional or radial fibres of the ciliary muscle of the eye

fibrae obliquae ventriculi: oblique muscle fibres, forming the innermost layer of the tunica muscularis of the stomach

fibrae pontis superficiales et profundae: superficial and deep transverse fibres of the pons, which arise from the pontine nuclei, cross the midline lying either superficial to, or among and dorsal to the longitudinal fasciculi and then form the middle cerebellar peduncle to enter the cerebellum

fibrae zonulares: zonular fibres which pass from the ciliary zonule, where they lie posterior to the ciliary body, forwards to the lens, where the anterior fibres form the suspensory ligament of the lens and the posterior the floor of the hyaloid fossa

fibrilla, -ae, f. L.: a small fibre, a fibril, e.g. components of the muscle and nerve fibres

fibrillaris, -e: fibrillar; pertaining to fibrils

fibrin: the fine protein fibres formed from "fibrinogen" by the action of thrombin in the clotting of blood

fibrocartilago, -inis, f. L.: fibrocartilage: cartilage in which there is a large number of collagen fibres, which often form parallel bundles lying between rows of cartilage cells

fibrocartilago basalis: disks of fibrocartilage, closing the foramen lacerum and other intervals of the base of the skull

fibrocartilago interarticularis: s. discus articularis

fibrocartilago intervertebralis: s. discus intervertebralis

fibrocartilago navicularis: a term which has been applied to the plantar calcaneonavicular ligament after it has undergone cartilaginous change in old age

fibrosus, -a, -um: fibrous: rich in, or composed of fibres

fibula, -ae, f. L.: the slender bone of the leg which lies lateral to the tibia

fibularis, -e: pertaining to the fibula

filum, -i, n. L.: thread; a thread-like structure

fila olfactoria: nervi olfactorii: the olfactory nerves

fila radicularia nervorum spinalium: the root filaments which emerge from the spinal medulla, and by their union form the dorsal and ventral roots of the spinal nerves

filum durae matris spinalis: the filum of the spinal dura mater: the thin sheath of tissue covering the filum terminale and continues above with the dura

filum terminale: the thread-like prolongation of the spinal medulla with its covering of pia mater, which extends from the level of the second lumbar vertebra to the coccyx

filiformis, -e: filiform; thread-like

papillae filiformes: the numerous pointed filiform papillae of the anterior two thirds of the dorsal mucosa of the tongue

fimbria, -ae, f. L.: fringe

fimbria hippocampi: fimbria of the hippocampus: the bundle of nerve fibres derived from the pyramidal cells of the hippocampus, which lie between the latter and the choroid fissure and continue as the crus of the fornix

fimbria ovarica: ovarian fimbria: an enlarged thread-like fimbria of the uterine tube, which is connected to the tubal pole of the ovary

fimbriae tubae uterinae: fimbriae of the uterine tube: the fringe of slender processes extending from, and surrounding the abdominal outlet of the uterine tube

fimbriatus, -a, -um: fimbriated: fringed

fissura, -ae, f. L.: fissure

fissura antitragohelicina: the fissure of the auricle between the tail of the helix and the antitragus

fissura calcarina: the calcarine fissure which extends on the medial surface of the cerebral hemisphere from below the splenium of the corpus callosum to the occipital pole and sometimes ends on the lateral aspect of the latter

fissura cerebri lateralis (Sylvii): the lateral fissure which starts on the basal surface of the brain lateral to the anterior perforated substance, and then extends on its lateral surface between the temporal and frontal lobes. Its posterior branch enters the parietal lobe

fissura collateralis: the colateral fissure on the inferior surface of the brain, running parallel with the calcarine fissure and forming the lateral boundary of the parahippocampal and lingual gyri

fissura hippocampi: the hippocampal fissure, starting from the sulcus of the corpus callosum below the splenium, and extending toward the temporal pole medial to the parahippocampal gyrus

fissura longitudinalis cerebri: the longitudinal cerebral fissure in the sagittal plane separating the cerebral hemispheres

fissura mediana anterior medullae spinalis seu oblongatae: anterior median fis-

sure: the longitudinal midline fissure, running along the anterior surface of the spinal medulla and medulla oblongata

fissura orbitalis inferior: the inferior orbital fissure between the greater wing of the sphenoid and the orbital surface of the maxilla, in the posterior part of the inferolateral border of the orbit. It gives passage to the infraorbital artery and nerve, and to the zygomatic nerve

fissura orbitalis superior: the superior orbital fissure between the greater and lesser wings of the sphenoid bone, separating the superior and lateral walls of the orbit posteriorly. It communicates with the middle cranial fossa and transmits the III, IV, VI and the V/1 cranial nerves, and the superior ophthalmic vein

fissura palpebrarum: rima palpebrarum: the palpebral fissure between the eyelids

fissura parietooccipitalis: the parietooccipital fissure on the medial surface of the cerebral hemispheres, between the cuneus and the precuneus, joining the calcarine fissure inferiorly

fissura petrooccipitalis: the petrooccipital fissure on the base of the skull, extending backwards and laterally from the foramen lacerum, between the petrous part of the temporal and the basal part of the occipital bones

fissura petrosquamosa: the petrosquamous fissure on the base of the skull, separating the tegmen tympani and squamous portions of the temporal bone and comprising the anterior subdivision of the squamotympanic fissure

fissura petrotympanica: the petrotympanic fissure running between the tegmen tympani and the tympanic portions of the temporal bone and comprising the posterior subdivision of the squamotympanic fissure. It transmits the chorda tympani and the anterior tympanic artery and vein

fissura pterygoidea: the pterygoid fissure between the anterior borders of the medial and lateral lamellae of the pterygoid processes of the sphenoid bone

fissura sphenopetrosa: the narrow sphenopetrous fissure between the greater wing of the sphenoid and the petrous part of the temporal bone

fissura transversa cerebri: the transverse cerebral fissure between the splenium of the corpus callosum and the roof of the 3rd ventricle. Through it pass the posterior choroid arteries and the great cerebral vein

fissura tympanomastoidea: the tympanomastoid fissure of the temporal bone, separating the tympanic plate and mastoid process

fistula, -ae, f. L.: an abnormal canal joining the cavities of two hollow organs or the cavity of an organ and the surface of the body

fixatio, -onis, f. L.: fixation; a fixed state

fixus, -a, -um: fixed

fixator, -oris, f., *fixor,* -oris, m.: fixating

flaccidus, -a, -um, L.: flaccid; weak, lax (flaccus: lax)

flagellum, -i, n. L.: whip; a mobile, whip-like cell process

flavus, -a, -um, L.: yellow

ligamenta flava: ligg. interarcualia: ligamentous bands between the laminae of the vertebral arches consisting of yellow elastic fibres (yellow bands)

Flechsig's areas: an anterior, lateral and posterior area seen in transverse section of the medulla oblongata, which are separated from each other by the fibres of the hypoglossal and vagus nerves

Flechsig's incision: the oblique incision extending from the ridge of the corpus callosum to the beginning of the lateral cerebral sulcus to expose the basel ganglia in dissection of the brain

Flechsig's tract: s. tractus spinocerebellaris posterior

Fleischmann's bursa: the sublingual synovial bursa, said to occur occasionally between the anterior end of genioglossus and the septum of the tongue

flexio, -onis, f. L.: flexion: bending a joint, so that the angle between its two limbs becomes more acute. Opposite to extension

flexor, -oris, m.: a muscle that flexes (flectere: to flex)

flexorius, -a, -um: serving flexion

flexura, -ae, f.: flexure; a bend or curve

flexura coli dextra: flexura coli hepatica: the right colic flexure at the junction of the ascending and transverse colon

flexura coli sinistra: flexura coli lienalis: the left colic flexure at the junction of the transverse and descending colon

flexura duodenojejunalis: duodenojejunal flexure: the sharp bend where the duodenum leads into the jejunum

flexura perinealis recti: the anteroposterior perineal flexure of the rectum at its junction with the anal canal. Its convexity is directed forwards, and in the male it is at the level of the apex of the prostate

flexura sacralis recti: the sacral flexure of the rectum, in the anteroposterior plane with its concavity directed forwards and corresponding to the curvature of the sacrum

flexura sigmoidea: the sigmoid flexure: the curvature of the sigmoid colon

flocculus, -i, m. L.: small tuft (floccus: tuft). In anatomy: the small lobule of the posterior lobe of the cerebellum, which adjoins the middle cerebellar peduncle and is connected to the nodule

fluctuatio, -onis, f. L.: fluctuation (fluctuare: undulate, fluctuate)

flumen, -inis, n. L.: stream

flumina pilorum: hair tracts due to the direction of the hairs, especially in the fetus

foetus: s. fetus

Folian process: processus anterior mallei (Folii): the anterior process of the malleus

folium, -ii, n. L.: leaf; a leaf-like formation

folium vermis: the part of the vermis on the superior surface of the cerebellum, which lies behind the declive

foliatus, -a, -um: foliate: having folia

folliculus, -i, m. L.: follicle, a small sac or pouch often secretory

Fontana's spaces: s. spatia anguli iridocornealis

fonticulus, -i, m. L.: small spring; fontanelle (fons: source); the unossified membranous intervals at the junction of the angles of the parietal, with the surrounding bones of the skull in young infants. All are usually ossified and closed 18 months after birth

fonticulus anterior: anterior fontanelle: the diamond-shaped membranous interval at the junction of the coronal, sagittal and frontal sutures. Normally closed at about 18 months

fonticulus mastoideus: (f. posterolateralis) mastoid fontanelle at the junction of the temporal, parietal and occipital bones. Normally closed at about 12 months

fonticulus posterior: the posterior fontanelle: the membranous triangular interval at the junction of the sagittal and lambdoid sutures. Normally closed at about 3 months after birth

fonticulus sphenoidalis: (f. anterolateralis) the sphenoidal fontanelle situated at the junction of the frontal, parietal and temporal bones, and at the greater wing of the sphenoid. Normally closed at about 3 months after birth

foramen, -inis, n. L.: a hole, or opening (forare: to pierce)

foramina papillares: papillary foramina: the openings of the collecting tubules on the apex of the renal papilla

foraminosus, -a, -um: pierced with holes, foraminous

forceps, -ipis, f. L.: forceps, pincers; in anatomy: forceps major or occipital part of the radiation of the corpus callosum, consisting of fibres from the splenium proceeding to the occipital lobe. Forceps minor or frontal part of the radiation of the corpus callosum, consisting of fibres of the genu proceeding to the frontal lobe

Forel's commissure: s. decussatio tegmentalis ventralis (decussationes tegmenti)

formatio, -onis, f. L.: formation (formare: to form)

formatio reticularis: the reticular formation: a somewhat ill-defined system of scattered neurons intermingled with nerve-fibres running mainly longitudinally. In the midbrain it lies centrally in each half of the tegmentum, in the pons between the lemnisci and the 4th ventricle and in the medulla oblongata dorsal to the olive, whence it extends into the medial part of the lateral funiculus of the upper spinal medulla. Its connections include afferents from the spinothalamic tracts, cerebellum, cerebral cortex and vestibular and red nuclei and efferents, which ascend to the thalamus and descend to the spinal medulla

fornix, -icis, m. L.: arch or vault

fornices conjunctivae superior et inferior: conjunctival fornices: the lines of reflection of the conjunctiva of the upper and lower eyelids onto the eyeball

fornix cranii: cranial fornix: calvaria; the vault of the neurocranium

fornix pharyngis: pharyngeal fornix: the vault-like roof of the nasal portion of the pharynx, where the pharyngeal tonsils lie

fornix sacci lacrimalis: the fornix of the lacrimal sac: the part of the lacrimal sac lying above the inlet of the lacrimal canaliculi

fornix uteri: s. fundus uteri

fornix vaginae: fornix of vagina: the part of the vaginal cavity which forms the vault-like space between the anterior, posterior or lateral wall of the vagina and the cervix uteri (anterior, posterior or lateral fornix)

fornix ventriculi: fornix of the stomach: a term occasionally applied to the arch of the cardiac part or fundus of the stomach

fornicatus, -a, -um: having a vault

Forssell's sinuses: recess situated between folds of the gastric mucosa, which has been demonstrated radiologically

fossa, -ae, f. L.: pit, depression

fossa incisiva: incisive fossa: the median depression on the anterior part of the inferior surface of the bony palate, where the incisive canals open

fossula, -ae, f. L.: a small fossa

fossula fenestrae cochleae: the small fossa on the medial wall of the tympanic cavity where the fenestra cochleae is situated

fossula fenestrae vestibuli: the small fossa on the medial wall of the tympanic cavity where the fenestra vestibuli is situated

fossula petrosa: petrous fossula: the small depression between the external opening of the carotid canal, the jugular fossa and the external opening of the cochlear canaliculus. It lodges the inferior ganglion of the glossopharyngeal nerve

fossulae tonsillares: the pit-like invaginations of the surface epithelium into the substance of the tonsil

fovea, -ae, f. L.: pit, depression

foveola, -ae, f. L.: small depression

foveola coccygea: foveola of the coccyx: a small dimple often present in the skin over the tip of the coccyx

foveolae gastricae: gastric foveolae or pits: the minute pits in the gastric mucosa into the base of which open the gastric glands

foveolae granulares (Pacchioni): the granular foveolae or pits (of Pacchini): depressions in the bone of the inner surface of the cranial cavity which are occupied by the arachnoid granulations

foveolaris, -e: foveolar: pertaining to a small pit, or depression

fractura, -ae, f. L.: break; fracture of a bone (frangere: to break)

Frankenhäuser's ganglion: s. ganglion cervicale uteri

Frankenhäuser's plexus: plexus uterovaginalis: the part of the autonomic pelvic plexus lying in the base of the broad ligament along the upper part of the vagina and the cervix uteri

frenulum, -i, n. L.: small bridle: a fold of tissue joining two structures (fraenum: bridle)

frenulum clitoridis: frenulum of the clitoris: the junction of the lower of the

anterior terminations of the labia minora below the clitoris, to whose inferior surface they are attached

frenulum labii superioris et f. labii inferioris: frenula of the upper and lower lips: the folds of mucous membrane of the upper and lower lips connecting them with the gum in the midline

frenulum linguae: frenulum of the tongue: the vertical fold of mucous membrane in the midline connecting the inferior surface of the tongue to the floor of the mouth

frenulum preputii penis: the frenulum of the prepuce of the penis: the fold of skin in the midline connecting the inferior surface of the glans penis with the prepuce

frenulum valvulae coli: frenulum valvae ileocecalis: the frenulum of the ileocecal valve: the mucous fold formed by the fusion of the two lips of the ileocecal valve, which continues onto the wall of the colon

frenulum veli medullaris anterioris (superioris): frenulum of the superior medullary velum: a median ridge, running downwards from between the inferior colliculi onto the upper part of the superior medullary velum

frondosus, -a, -um, L.: frondose; bearing fronds, or villi (frons: leaf)

chorion frondosum: the part of the chorion with persistent villi, which becomes concerned in the development of the placenta

frons, -tis, f. L.: the forehead

frontalis, -e: pertaining to the forehead

functio, -onis, f. L.: function

fundus, -i, m. L.: base, bottom

fundus meatus acustici interni: the fundus or base of the internal auditory meatus

fundus oculi: the fundus or back of the eye

fundus uteri: fundus of the uterus: the part of the uterus above the entrance of the uterine tubes

fundus ventriculi: fundus of the stomach: the part of the stomach above the level of the cardiac orifice

fundus vesicae felleae: fundus of the gall bladder: the anterior expanded part of the gall bladder

fundus vesicae urinariae: fundus of the urinary bladder: the base or posterior surface of the urinary bladder

fungiformis, -e, L.: fungiform: shaped like a fungus (fungus: mushroom)

papillae fungiformes: the broad fungiform papillae of the mucosa of the anterior two thirds of the dorsum of the tongue. They are scattered amongst the filiform papillae and most of them are provided with taste-buds

funiculus, -i, m. L.: cord, bundle (funis: cord)

funiculus anterior medullae spinalis: anterior funiculus: the anterior white column of the spinal medulla

funiculus cuneatus: s. Burdach's column

funiculus gracilis: (Goll's column) the part of the posterior funiculus, which lies medial to the fasciculus cuneatus above the midthoracic level. It conveys epicritical, proprioceptive and pressure impulses from the lower half of the body

funiculus lateralis medullae spinalis: lateral funiculus: the lateral white column of the spinal medulla

funiculi medullae spinalis: funiculi of the spinal medulla: the anterior, lateral and posterior white columns of the spinal medulla

funiculus posterior medullae spinalis: posterior funiculus: the posterior white column of the spinal medulla

funiculus spermaticus: the spermatic cord which contains the ductus deferens and the blood, and lymphatic vessels and nerves to the testis. It passes from the testis through the inguinal canal to the deep inguinal ring and is surrounded by the spermatic fasciae and cremaster

funiculus umbilicalis: the umbilical cord passing from the fetus to the placenta and transmitting the umbilical blood vessels

fusiformis, -e, L.: fusiform: spindle-shaped (fusus: spindle)

papillae fusiformes: a term which has been applied to the bulbi gustatorii or taste-buds

G

galactophorus, -a, -um, Gr.: galactophorous; lactiferous: conveying milk (galaktos: milk; phorus: carrying)

galea, -ae, f. L.: helmet

galea aponeurotica: (aponeurosis epicranialis): the epicranial aponeurosis, which unites the frontal and occipital bellies of epicranius and caps the vault of the skull. Fibres bind it to the skin of the scalp

Galeati's glands: s. the crypts of Lieberkühn

Galen, anastomosis of: *ramus communicans (n. laryngei superioris) cum n. laryngeo inferiore:* the communicating nerve which joins the internal branch of the superior laryngeal to the recurrent laryngeal nerve

Galen, great vein of: v. cerebri magna (Galeni): the great cerebral vein formed by the union of the two internal cerebral veins and emptying into the straight sinus

gallus, -i, m.: cock

crista galli: s. crista

Galton's delta: the central triangular pattern of the lines of a fingerprint

ganglion, -ii, n. Gr.: knot; a group of nerve-cells outside the central nervous system

ganglia cardiaca: the autonomic cardiac ganglia of the cardiac plexus, situated below the arch of the aorta to the right of the ligamentum arteriosum

ganglia phrenica: phrenic ganglia: nerve-cells in the phrenic branches of the celiac plexus, which may be grouped to form the phrenic ganglion, where the plexus is joined by the right phrenic nerve

ganglia plexuum sympathicorum: g. plexuum autonomicorum; aggregations of the cell bodies of postganglionic sympathetic efferent fibres occurring in the sympathetic plexuses

ganglia sacralia: the ganglia of the pelvic part of the sympathetic trunk

ganglia thoracalia: the thoracic ganglia of the thoracic part of the sympathetic chain

ganglion acusticofaciale: the acousticofacial ganglion of the embryo, which later divides to give rise to the geniculate ganglion of the facial and the vestibular and spiral ganglia of the vestibulocochlear nerves

ganglion Anderschi: s. ganglion inferius nervi glossopharyngei

ganglion aorticorenale: the aorticorenal autonomic ganglion in front of the aorta below the celiac ganglion at the level of the renal arteries

ganglion Arnoldi: ganglion oticum: the otic ganglion medial to the mandibular nerve after its passage through the foramen ovale. Parasympathetic impulses from the glossopharyngeal, via the lesser superficial petrosal, relay here before gaining the parotid gland via the auriculotemporal nerve

ganglion caroticum: autonomic nerve-cells in the plexus caroticus

ganglion cell: a nerve-cell whose body is grouped with those of other neurones to form a ganglion

ganglion cervicale medium: the small middle cervical sympathetic ganglion probably formed usually by the fusion of the 5th and 6th cervical ganglia. It is usually close to the inferior thyroid artery at the level of the 6th cervical vertebra

ganglion cervicale superius: the superior cervical sympathetic ganglion, formed by the fusion of the upper four cervical ganglia and lying at the level of the 2nd and 3rd cervical vertebrae

ganglion cervicale uteri: uterine cervical ganglion: an autonomic ganglion or group of small ganglia beside the cervix of the uterus

ganglion cervicothoracicum (stellatum): the cervicothoracic or stellate ganglion; in the majority of persons the 7th and 8th cervical and 1st thoracic ganglia of the sympathetic chain fuse to form this ganglion, which lies behind the vertebral artery, on the neck of the 1st rib. The 7th and 8th cervical ganglia, which sometimes fuse with each other, but not with the 1st thoracic form the inferior cervical ganglion

ganglion ciliare: the ciliary ganglion lying just lateral to the optic nerve in the orbit. Parasympathetic impulses from the oculomotor nerve are relayed there before passing to the ciliary muscles and sphincter pupillae via the short ciliary nerves

ganglion coccygeum: the median sympathetic ganglion in front of the coccyx where the two sympathetic chains terminate

ganglion coeliacum: the celiac sympathetic ganglion, whose two halves lie on either side of the aorta, at the level of the celiac artery. It is closely connected with the celiac plexus

ganglion Gasseri: gasserian ganglion: s. ganglion trigeminale

ganglion geniculi nervi facialis: geniculate ganglion: the sensory ganglion of the facial nerve situated at the geniculum. It contains the cell bodies of the taste fibres

ganglion habenulae: nucleus habenulae: the habenular ganglion or nucleus, situated in the habenular trigone and receiving fibres through the stria medullaris. It projects to the opposite side through the habenular commissure and to the interpeduncular ganglion through the fasciculus retroflexus

ganglion impar: s. ganglion coccygeum

ganglion inferius nervi glossopharyngei: the inferior ganglion of the glossopharyngeal nerve, which contains cell bodies of sensory nerve fibres and lies in the fossula petrosa, where it gives off the tympanic nerve

ganglion interpedunculare: nucleus interpedunculare: the interpeduncular ganglion situated in the posterior part of the posterior perforated substance. It receives fibres from the habenular ganglion through the fasciculus retroflexus

ganglion intervertebrale: s. ganglion spinale

ganglion jugulare: s. ganglion superius nervi vagi

ganglion lumbale: lumbar ganglion: one of the four ganglia of the lumbar part of the sympathetic trunk

ganglion Meckeli maius: s. ganglion pterygopalatinum

ganglion Meckeli minus: s. ganglion submaxillare

ganglion mesentericum superius: the superior mesenteric sympathetic ganglion situated immediately in front of the aorta at the origin of the superior mesenteric artery

ganglion nodosum (g. inferius nervi vagi): the inferior ganglion of the vagus situated just below the jugular foramen and containing the cell bodies of the sensory nerve fibres

ganglion pterygopalatinum: the pterygopalatine ganglion in the pterygopalatine fossa, where preganglionic parasympathetic fibres from the greater petrosal branch of the facial nerve terminate and postganglionic fibres arise to be distributed to the lacrimal gland, nose, palate and pharynx

ganglion Scarpae: s. ganglion vestibulare

ganglion spinale: ganglion intervertebrale: the spinal ganglion on the dorsal sensory root of each spinal nerve, which the containscell bodies of the pseudounipolar (modified bipolar) sensory nerve-cells

ganglion spirale cochleae: the spiral ganglion of the cochlea in the spiral canal, consisting of the cell bodies of the bipolar neurones of the cochlear nerve

ganglion stellatum: s. ganglion cervicothoracicum

ganglion submaxillare: (submandibulare): the submandibular ganglion below the lingual nerve where parasympathetic fibres from the facial nerve via the chorda tympani and lingual nerve terminate, and postganglionic fibres arise to be distributed to the submandibular and sublingual glands

ganglion superius nervi glossopharyngei: the small superior ganglion of the glossopharyngeal nerve, which lies in the groove of the jugular foramen and consists of the cell bodies of the sensory neurones

ganglion superius nervi vagi: the superior ganglion of the vagus nerve in the jugular foramen. It contains the cell bodies of sensory nerve fibres

ganglion trigeminale (Gasseri): trigeminal ganglion: the ganglion of the trigeminal nerve, which consists of the cell bodies of its sensory nerve fibres. It lies in the cavum trigeminale on the anterior surface of the petrous part of the temporal bone and gives rise to the ophthalamic, maxillary and mandibular divisions

ganglion vestibulare: the vestibular ganglion consisting of the bipolar cell bodies of the vestibular nerve-fibres. It is situated at the bottom of the internal auditory meatus and is usually divided into a superior and inferior part

ganglion Wrisbergi: s. cardiac ganglion

Gartner's ducts: s. ductus epoophori longitudinales

Gasser's ganglion: s. ganglion trigeminale

gaster, -tris, f. Gr.: the stomach (syn.: ventriculus)

gastricus, -a, -um: gastric: pertaining to the stomach

gastro-, Gr.: pertaining to the stomach (only used in combination)

gastrocolicus, -a, -um: gastrocolic: pertaining to the stomach and colon

gastroduodenalis, -e: gastroduodenal: pertaining to the stomach and duodenum

gastrointestinalis, -e: gastrointestinal: pertaining to the stomach and intestine

gastroknemion, Gr.: calf

gastrocnemialis, -e: pertaining to the gastrocnemius muscle (kneme: leg)

m. gastrocnemius: the superficial muscle of the calf, which arises by a medial and lateral head from the medial and lateral condyles of the femur and is inserted by the tendo calcaneus into the calcaneum. It is a flexor of the knee and ankle

gastrula, -ae, f. Gr.: the early stage in the development of the embryo, which results from the invagination of parts of the blastula at the blastopore to form endoderm, mesoderm and notochord

gastrulatio, -onis, f. Gr.: gastrulation; the development of the gastrula from the blastula. In the human embryo the formation of the notochord and mesoderm has been compared with the process of gastrulation in lower forms

Gavard's muscle: s. fibrae obliquae ventriculi

gelatina, -ae, f. L.: (gelare: to freeze) gelatin; jelly

gelatinosus, -a, -um: gelatinous: resembling jelly or gelatin

substantia gelatinosa (Rolandi): the gelatinous layer of cells covering the posterior horn of the spinal medulla, into which fibres of the dorsolateral tract enter

gemellus, -a, -um, L.: one of two twins, double

mm. gemelli: two small muscles arising from the bone forming the upper and

lower boundaries of the lesser sciatic notch and being inserted with the tendon of obturator internus

generatio, -onis, f. L.: generation; reproduction

genesis, -is, f. Gr.: generation; origin

geniculum, -i, m. L.: small knee, a knot-like bend in a small structure (genu: knee)

geniculum nervi facialis: the backward bend of the horizontal portion of the facial nerve above the promontory of the middle ear in the temporal bone

geniculatus, -a, -um, L.: geniculate; bent like the knee

corpus geniculatum laterale et mediale: s. corpus

genioglossus, Gr. (musculus): the muscle arising from the upper part of the spina mentalis and fanning out to be inserted into the tongue and hyoid bone (geneion: chin, glossa: tongue)

geniohyoideus, Gr. (musculus): the muscle arising from the lower part of the spina mentalis and inserting into the body of the hyoid bone (hyoides: shaped like a Greek Y)

genitalis, -e, L.: genital; pertaining to the organs of reproduction

Gennari's line: the well-developed outer band of Baillarger in layer 4 of the visual cortex. It is visible to the naked eye

genu, -us, n. L.: knee

genu capsulae internae: genu of the internal capsule: the angle between the anterior and posterior limbs of the internal capsule

genu corporis callosi: genu of the corpus callosum: the bend at the anterior end of the corpus callosum, between its trunk and rostrum

Gerdy's fibres: the superficial transverse metacarpal ligament crossing the most distal part of the palm and the flexor tendons of the fingers

Gerdy's hyoid fossa: Malgaigne's fossa: s. trigonum caroticum

Gerdy's ligament: the suspensory ligament of the axilla

Gerlach's valve: s. valvula processus vermiformis

germinatio, -onis, f. L.: germination (germinare: to germinate)

germinativus, -a, -um: germinative; pertaining to the germ or germination

Gerota's fascia: the renal fascia and its layers in front of, and behind the kidney

Giacomini's band: the anterior end of the dentate gyrus lying on the inferior surface of the uncus

Gianuzzi's crescents: crescent-shaped serous cells or demilunes in the periphery of the acini of mixed salivary glands such as the submandibular

Gierke's respiratory bundle: the tractus solitarius

Gimbernat's ligament: the lacunar ligament, a triangular extension from the medial end of the inguinal ligament to the pectineal line of the pubis

gingiva, -ae, f. L.: gum: the connective tissue covering the alveolar processes of the upper and lower jaws

gingivalis, -e: gingival: pertaining to the gum

ginglymus, -i, m. Gr.: a hinged joint where movement is confined to one plane

Giraldés' organ: s. paradidymis

glabella, -ae, f. L.: the eminence of the frontal bone in the midline above the root of the nose and between the superciliary arches

glandula, -ae, f. L.: gland (glans: acorn), also a small gland

glandulae areolares (Montgomerii): areolar glands (of Montgomery), glands of the areola of the breast, their form tending to be intermediate to that of sweat and mammary glands

glandulae bulbourethrales (Cowperi): bulbourethral glands: glandulae Cowperi seu Mery: two pea-shaped glands in the deep perineal pouch whose ducts open into the floor of the posterior part of the spongy urethra

glandula carotica: s. glomus caroticum

glandulae lactiferae: the mammary glands

glandula lingualis anterior Blandini: the anterior lingual glands (of Blandin): small glands situated on the underside of the tip of the tongue

glandularis, -e: glandular, pertaining to a gland

glans, -dis, f. L.: gland; the distal part of the penis or clitoris

Glaser's fissure: the petrotympanic fissure between the downturned tegmen tympani and the petrous part of the temporal bone giving passage to the chorda tympani and the anterior tympanic artery

glenoidalis, -e, Gr.: glenoid; pertaining to a shallow socket, e.g. glenoid cavity

cavitas glenoidalis: the glenoid cavity of the scapula, with which the head of the humerus articulates

glia-tissue: the neuroglia; the supporting tissue of the central nervous system. It includes the astrocytes, oligodendrocytes and microglia (glia, Gr.: glue)

Glisson's capsule: capsula fibrosa perivascularis hepatis: the fibrous perivascular capsule of the liver, especially distinct in the porta hepatis and extending between the lobules

globus, -i, m. L.: globe, sphere

globus major: the head of the epididymis

globus minor: the tail of the epididymis

globus pallidus: the medial pale part of the lentiform nucleus

globiformis, -e: globe-shaped, resembling a globe

globosus, -a, -um: globular; globe-shaped

nucleus globosus: the spherical nucleus, which lies medial to the emboliform nucleus in the cerebellum

glomerulus, -i, m. L.: a small tuft; the tuft of capillaries in the renal corpuscle, where the glomerular filtrate originates

glomus, -eris, n. L.: a tuft of blood vessels, which may include an arteriovenous anastomosis as in the skin

glomus caroticum: carotid body: the clump of epithelioid cells at the angle of bifurcation of the common carotid, which is richly innervated and vascularized and is stimulated by chemical changes resulting from low blood pressure

glomus chorioideum: the tuft formed by the enlarged choroid plexus at the junction of the inferior horn with the central part of the lateral ventricle

glomus coccygeum: coccygeal body: a small clump of polyhedral cells and sinusoidal vessels in front of the tip of the coccyx

glossa, -ae, f. Gr.: the tongue (only used in combination)

glossoepiglotticus, -a, -um: glossoepiglottic: pertaining to the tongue and epiglottis

plicae glossoepiglotticae: the median and lateral glossoepiglottic folds extending from the root of the tongue to the epiglottis and bounding the valleculae

glossopalatinus, -a, -um: glossopalatine: pertaining to the tongue and the palate

arcus palatoglossus: the palatoglossal arch: a fold of mucous membrane covering palatoglossus and passing downwards and forwards from the soft palate to the back of the tongue in front of the tonsil

glossopharyngeus, -a, -um: glossopharyngeal: pertaining to the tongue and pharynx

n. glossopharyngeus: the glossopharyngeal or 9th cranial nerve, which supplies sensory fibres to the tongue and pharynx, visceromotor fibres to the parotid gland, motor fibres to stylopharyngeus, etc.

glottis, -idis, f. Gr.: the narrow part of the larynx at the level of the vocal folds

glottis respiratoria: a term which has been applied to the posterior or intercartilaginous part of the rima glottidis, between the arytenoid cartilages

glottis vocalis: a term which has been applied to the anterior or intermembranous part of the rima glottidis between the vocal cords

glotticus, -a, -um: glottic; pertaining to the glottis

glutaeus, -a, -um, Gr.: the buttock: the muscles of the buttock; pertaining to the gluteal muscle

Golgi—Mazzoni's corpuscles (Krause's end bulbs): sensory encapsulated nerve-endings similar to, but smaller and simpler than Vater–Pacini corpuscules. Present in superficial and deep connective tissues

Golgi's cells: type I, neurons with long axon projecting at a distance from the cell body; type II, neurons with short processes ending nearby

Goll's column: fasciculus gracilis

Goll's nucleus: nucleus gracilis

gomphosis, -is, f. Gr.: a type of fibrous joint, in which a peg-like structure e.g. a tooth, articulates in a socket (gomphos: bolt)

Gowers-tract: s, tractus spinocerebellaris anterior

Graafian follicle: an ovarian follicle containing an ovum and follicular fluid and being lined with granulosa cells

gracilis, -e, L.: gracile; slender, delicate, thin

m. gracilis: one of the flexors of the femur

granularis, -e: granular; pertaining to granules (granum: grain)

granulatio, -onis, f. L.: granulation

granulationes arachnoideales (Pacchionii): arachnoid granulations: large arach-

noid villi, especially in the superior sagittal sinus, which are more evident in the elderly and may erode into the bone

granulocyt: any cell, but especially a leukocyte, which contains granules

granulosus, -a, -um: marked by granules

Gratiolet's radiation: s. radiatio optica

graviditas, -atis, f. L.: pregnancy (gravis, -e: heavy)

gravidus, -a, -um: gravid; pregnant

griseus, -a, -um: grey

substantia grisea centralis: the central grey substance surrounding the aqueduct of the midbrain

gubernaculum, -i, n. L.: guide (rudder)

gubernaculum dentis: the epithelial strand connecting the apex of the dental sac to the gum

gubernaculum testis (Hunteri): the cord consisting of fibrous tissue and smooth muscle, which passes in the embryo from the testis to the scrotal swelling and has been described as guiding the descent of the testis

Gudden's commissure: the ventral supraoptic fibres posterodorsal to the decussating optic fibres, which have been described as connecting the medial geniculate bodies or tegmentum of the two sides or extending to the spinal cord in mammals

Gudden's tract: s. mamillotegmental tract

Guérin's fold: valvula fossae navicularis: valve of the navicular fossa: the transverse fold of mucous membrane at the posterior border of the navicular fossa of the male urethra

gustus, -us, m. L.: tasting, the sense of taste

gustatorius, -a, -um: gustatory; pertaining to the sense of taste (gustare: to taste)

gemma gustatoria: taste-bud

Guthrie's muscle: m. sphincter urethrae membranaceae

gutta, -ae, f. L.: drop

gyrus, -i, m. Gr.: circle, convolution (of the brain)

gyrus angularis: the angular gyrus of the parietal lobe surrounding the posterior end of the superior temporal sulcus

gyrus cinguli: the cingulate gyrus which lies above and in front of the corpus callosum and is continuous posteriorly with the isthmus. It forms part of the fornicate lobe

gyrus fasciolaris: the transitional area between the dentate gyrus and the indusium griseum (fasciola cinerea (BNA))

gyrus lingualis: the lingual gyrus forming the posterior part of the parahippocampal gyrus on the inferomedial surface of the occipital lobe between the calcarine and collateral sulci

gyrus occipitotemporalis lateralis: gyrus fusiformis (BNA): the lateral occipitotemporal gyrus; the most lateral gyrus on the inferior aspect of the occipital and temporal lobes

gyrus supramarginalis: the supramarginal gyrus of the inferior parietal lobule, which curves around the posterior end of the lateral sulcus

gyrus uncinatus: s. uncus gyri parahippocampalis

gyratus, -a, -um: gyrate; convoluted; tortuous

H

habenula, -ae, f. L.: small rein, thong; in anatomy: rein-, or thong-like structure (habena: rein)

habenula corporis pinealis: habenula of the pineal body: the fibres which pass between the habenular commissure and the habenular triangle

habenula hypophyseos: habenula of the hypophysis: a term which has been applied to the infundibulum

trigonum habenulae: the habenular triangle which is situated on the postero-medial aspect of the thalamus and is connected with the stria medullaris, the habenular commissure and the fasciculus retroflexus

habitus, -us, m. L.: the external appearance suggesting the constitution of the body

haemocyta, Gr.: hemocyte; an erythrocyte or any type of blood cell

haemorrhagia, -ae, Gr.: hemorrhage; bleeding (rhegnumi: burst)

haemorrhoidalis, -e, Gr.: hemorrhoidal; pertaining to hemorrhoids or dilated veins of the anal canal, hence in anatomy: belonging to the rectum or anal canal (e.g. vessels, nerves)

Haller's ansa: 1. the occasional anastomosis between the facial and glossopharyngeal nerves anterior to the internal jugular vein; 2. the anastomosis between the glossopharyngeal nerve and the auricular branch of the vagus

Haller's arch: ligg. arcuata mediale et laterale: the medial and lateral arcuate ligaments of the diaphragm

Haller's circle: circulus arteriosus Halleri: the circle of arteries in the sclera surrounding the optic nerve

Haller's cone: coni vasculosi: the vascular cones formed by the convolutions of the efferent ductules and their blood vessels in the head of the epididymis

Haller's habenula: the fibrous cord remaining after obliteration of the upper part of the processus vaginalis of the peritoneum

Haller's layer: lamina vasculosa: the layer of large vessels of the vascular layer of the choroid

Haller's network: s. rete testis

hallux, -icis, m. L.: the big toe (allex, L.: big toe or thumb)

hamulus, -i, m.: little hook; a hook-shaped process

hamulus laminae spiralis: hamulus of the spiral lamina: the hook-like upper end of the osseous spiral lamina in the cochlea

hamulus ossis hamati: hamulus or hook of the hamate
hamulus ossis lacrimalis: the hamulus of the lacrimal bone
hamulus pterygoideus: the pterygoid hamulus on the inferior aspect of the medial plate of the pterygoid process of the sphenoid

hamus, -i, m. L.: hook
hamatus, -a, -um: supplied with a hook
os hamatum: the hamate in the distal row of the carpal bones

harmonia, -ae, f. Gr.: harmony; has been applied in anatomy to the articulation of bones by almost smooth surfaces
sutura harmonia: a term which has been applied to the apposition of two smooth margins of contiguous bones (e.g. sutura lacrimomaxillaris)

Hasner's valve: plica lacrimalis

Hassal's corpuscles: (Virchow–Hassal's corpuscles): small structures in the medulla of the thymus gland consisting of concentrically arranged epithelial cells

haustrum, -i, n. L.: device for drawing water; the sacculations on the wall of the colon (haurire: to dip)
haustra coli: the sacculations of the colon

haversian canals: the vascular canals of bone

haversian lamellae: the concentric layers of bone around the haversian canals

Heidenhain's crescents or demilunes, Gianuzzi's crescents: crescent-shaped serous cells, peripheral to the mucous cells in the alveoli of mixed salivary glands

Heister's valve: s. plica spiralis

helix, -icis, f. Gr.: coil, the inturned rim of the auricle of the ear
helicinus, -a, -um: helicine or coiled; pertaining to the helix
helicotrema, -atis, n.: the opening at the apex of the cochlea, through which the scala vestibuli and scala tympani communicate (trema: hole)

Helweg's bundle: tractus olivospinalis; the olivospinal tract in the anterolateral funiculus of the spinal cord

hemi-, Gr. (hémi: half): a prefix signifying one half
hemidecussatio: s. semidecussatio
hemisphaerium, -ii, n.: hemisphere, the cerebral hemisphere
vena hemiazygos: the hemiazygos vein which lies on the left side of the lower thoracic vertebrae and empties into the azygos vein

Henle's bundle: s. falx inguinalis

Henle's glands: the "tubular glands" in the palpebral conjunctiva, which are probably, in fact, gland-like folds of mucous membrane

Henle's layer: the outer layer of the internal root sheath of the hair

Henle's loop: the U-shaped part of the nephron connecting the proximal and distal convoluted tubules

Henle's sheath: the endoneurium; the thin connective tissue sheath surrounding individual peripheral nerve-fibres

Hensen's canal: s. ductus reuniens

Hensen's cells: the outer supporting cells in the organ of Corti, which are situated lateral to the cells of Deiters

hepar, -atis, n. Gr.: the liver

hepaticus, -a, -um: hepatic; pertaining to the liver

hernia, -ae, f. Gr.: herniation; an internal structure e.g. intestine, protruding through an abnormal opening of the wall of the cavity within which it lies or into a subdivision of the cavity

herniosus, -a, -um: hernial; pertaining to a hernia

lacuna herniosa: s. lacuna lymphatica

Heschl's convolution: gyri temporales transversi: the transverse temporal gyri: the cortical centre of hearing

Hesselbach's band or ligament: s. lig. interfoveolare

hiatus, -us, m. L.: opening, cleft (hiare: gape)

hiatus adductorius (tendineus): the opening between the tendon of adductor magnus and the distal end of the femur, through which the femoral artery passes to gain the popliteal fossa

hiatus aorticus: the aortic opening in the diaphragm giving passage to the aorta and the thoracic duct

hiatus basilicus: the basilic opening in the medial part of the brachial fascia for the basilic vein and the medial cutaneous nerve of the forearm

hiatus canalis n. petrosi majoris: the opening of the canal for the greater petrosal nerve on the anterior surface of the petrous part of the temporal bone

hiatus genitalis: genital opening: a term which has been applied to the passage between the levatores ani for the vagina and the urethra

hiatus maxillaris: maxillary opening: the entrance into the maxillary sinus on the nasal surface of the maxilla

hiatus oesophagei: the oesophageal opening in the diaphragm for the passage of the oesophagus and the vagus nerves

hiatus sacralis: the opening of the inferior end of the sacral canal

hiatus semilunaris: the sickle-shaped groove on the wall of the middle meatus, between the uncinate process and the ethmoidal bulla

Highmore's antrum: s. sinus maxillaris

Highmore's body: s. mediastinum testis

hilus, -i, m. L.: hilum: a little thing: the place where the vessels, nerves, etc. enter an organ

hilus lienis: the hilum of the spleen

hilus nuclei dentati: the hilum of the dentate nucleus of the cerebellum

hilus nuclei olivaris: the hilum of the olivary nucleus

hilus pulmonis: the hilum of the lung

hilus renalis: the hilum of the kidney

hippocampus, -i, m. Gr.: a mythical sea-monster: the part of the cortex of the telencephalon, which is invaginated as a rounded elevation into the inferior horn of the lateral ventricle by the hippocampal sulcus

hirci, -orum, m. L.: the axillary hairs; the term has also been applied to the hairs in the external auditory meatus and the tragus (hircus: he-goat)

His' bundle: fasciculus atrioventricularis: the atrioventricular bundle which conducts the heart impulse from the sinu-atrial node to the ventricular muscle. It divides into a right and a left limb

His' canal: s. ductus thyreoglossus

His' spaces: the perivascular spaces in the central nervous system continuous with the subarachnoid space

histologia, -ae, f. Gr.: histology, the science dealing with the microscopic structure, and function of the tissues

homolateralis, -e, L.: situated on the same side (Gr. homos: same)

homologia, -ae, f.: homology, structural resemblance between organs or parts of animals (homoios: resembling)

horizontalis, -e, L.: horizontal, parallel to horizon (denoting direction)

hormon, -nis, Gr.: hormone; the secretion of an endocrine gland, which passes into the blood

Horner's muscle: pars lacrimalis m. orbicularis oculi: the lacrimal part of orbicularis oculi muscle arising from the lacrimal crest

Hortega's cells: a microglial cell (microglia) of mesenchymal origin, which can be phagocytic

Houston's valve: plicae transversales recti: the transverse folds of the rectum, the eponym referring usually to the middle one of the three

Howship's lacunae: the small grooves or recesses in bones, excavated and occupied by osteoclasts during resorption

humerus, -i, m. L.: shoulder: the bone of the upper arm extending from the shoulder to the elbow

humeralis, -e: humeral; pertaining to the humerus

humor, -oris, m. L.: humour: liquid, various fluids of the body

humor aquaeus: aqueous humour: the fluid filling the anterior and posterior chambers of the eye

humor crystallinus: the lens of the eye (crystalline lens)

humor ocularis: the aqueous or vitreous humour or the lens of the eye

humor vitreum: the vitreous body

humoralis, -e: humoral; pertaining to humour

regulatio humoralis: the chemical or humoral regulation of the organism

Hunter's bundle: s. gubernaculum testis

Hunter's canal: s. canalis adductorius

Hunter's ligament: ligamentum teres uteri, s. teres

Hunter's membrane: s. decidua

Hunter's point: the place where the femoral artery can be compressed in the femoral triangle

Huschke's auditory teeth: the tooth-like projections on the upper surface of the limbus of the spiral lamina of the cochlea

Huschke's cartilage: the vomeronasal cartilage

Huschke's valve: fold of mucous membrane forming the lower lip of the entrance of the lacrimal canaliculi into the lacrimal sac

Huxley's layer: the inner layer of the internal root sheath of the hair

hyaline, Gr.: glass-like (hyalos, Gr.: glass)

hyaloideus, -a, -um, Gr.: hyaloid; resembling glass

cartilago hyaloidea: hyaloid-cartilage

membrana hyaloidea: the hyaloid membrane which was formerly held to bound the vitreous body externally, but is now considered to be no more than a condensation of the surface fibrils of the vitreous body if it exists at all

hymen, -enis, m. Gr.: the membrane which partially closes the lower end of the vagina in the virgin

hymen annularis: circular or annular hymen with a small round foramen

hymen cribriformis: cribriform hymen with a number of perforations

hymen dentatus: hymen with dentate or serrated edges

hymen falciformis: sickle-shaped hymen

hymen imperforatus: imperforate hymen without an opening

hymen semilunaris: crescent-shaped hymen

hymenalis, -e: hymenal; pertaining to the hymen

carunculae hymenales: the shrunken remnants of the hymen after parturition

hyoglossus, -a, -um, Gr.: hyoglossal: extending from the hyoid bone to the tongue

hyoideus, -a, -um, Gr.: hyoid; Y- or U-shaped; pertaining to the hyoid bone

hyparterialis: hyparterial; situated beneath or below an artery, opposite to "eparterial"

hyper-, Gr.: above, excessive, (used as prefix to denote an excess of the succeeding term)

hyperextensio, -onis, f. L.: hyperextension; extreme extension

hyperflexio, -onis, f. L.: hyperflexion; extreme flexion

hypertensio, -onis, f. L.: hypertension: abnormally high blood pressure

hypo-, Gr.: beneath, deficient

hypochondrium, -ii, n. Gr.: the upper lateral subcostal region of the abdomen, covered by the ribs

hypogastricus, -a, -um: hypogastric; situated below the stomach; pertaining to the lower median region of the abdomen

hypoglossus, -a, -um: hypoglossal; situated under or below the tongue

n. hypoglossus: the hypoglossal or 12th cranial nerve which passes below the tongue to supply its muscles

hypopharynx, -gis, m. L.: the lowest part of the pharynx situated behind the epiglottis

hypophysis, -is, m. Gr.: the pituitary body or gland (s. glandula pituitaria)

hypophyseos: hypophyseal; pertaining to the pituitary gland

hypothalamus, -i, m. Gr.: the part of the brain forming the floor and side walls of the diencephalon below the thalamus

hypothalamicus, -a, -um: hypothalamic: pertaining to the hypothalamus
sulcus hypothalamicus: the groove on the lateral wall of the 3rd ventricle which separates the hypothalamus from the thalamus, and extends from the interventricular foramen to the aditus of the cerebral aqueduct

hypothenar, -aris, n. Gr.: pertaining to the hypothenar eminence on the medial aspect of the palm

hypotympanum, -i, n. Gr.: the lowest part of the tympanic cavity

Hyrtl's canal: canalis musculoperonaeus: the musculoperoneal canal between flexor hallucis longus and the fibula containing the peroneal artery

Hyrtl's muscle: m. iliopsoas, s. ilio-,

Hyrtl's plexus: a venous plexus beneath the isthmus of the thyroid gland

I

ileum, -i, n. Gr.: the distal part of the small intestine
ileo-: pertaining to the ileum (used in combination)
ileocaecalis, -e: ileocecalis, -e: ileocecal; pertaining to the ileum and cecum
ileocolicus, -a, -um: ileocolic; pertaining to the ileum and colon

ilia, -ium, m. L. plur.: the flanks; hence os ilium: the iliac bone or ilium of the pelvis
iliacus, -a, -um: iliac; pertaining to the ilium
bursa iliaca: the iliac bursa under the insertion of the iliopsoas muscle
crista iliaca: the iliac crest forming the upper border of the ilium
fascia iliaca: the fascia covering iliacus and psoas muscles. It is continuous with the transversalis fascia
fossa iliaca: the iliac fossa at the inner surface of the ala of the ilium
spina iliaca: the anterior and posterior, superior and inferior spines of the iliac bone
ilio-: pertaining to the ilium or flank (used in combination)
m. iliocapsularis: the lateral fibres of iliacus muscle, which insert into the capsule of the hip joint
iliocostalis, -e: iliocostal; pertaining to the ilium and ribs
n. iliohypogastricus: iliohypogastric nerve: a predominantly cutaneous nerve of the lumbar plexus
n. ilioinguinalis: ilioinguinal nerve: a predominantly cutaneous nerve of the lumbar plexus
a. iliolumbalis: the iliolumbar branch of the internal iliac artery, which supplies iliacus, psoas and quadratus lumborum
iliopectineus, -a, -um: iliopectineal; pertaining to the ilium and pubis
m. iliopsoas: a compound muscle, formed by the union of the iliacus and psoas major beneath the inguinal ligament
iliosacralis, -e: iliosacral; pertaining to the ilium and sacrum

imbibitio, -onis, f. L.: absorption of liquid (imbibere: to drink)
imperforatio, -onis, f. L.: imperforate: congenital lack of a natural opening, "atresia"
impotentia, -ae, f. L.: impotence (usually denoting lack of virility)
impregnatio, -onis, f. L.: impregnation; rendering pregnant
impressio, -onis, f. L.: impression, groove (imprimere: to press into)
impressio cardiaca: cardiac impression: the deep impression of the heart on the medial surface of the right and left lungs
impressio carotica: the impression at the anterior end of the carotid sulcus on the body of the sphenoid
impressio colica: the colic impression on the visceral surface of the right lobe of the liver, which is related to the right colic flexure
impressiones digitatae: the digital impressions on the inner surface of the cranium, due to the cerebral convolutions
impressio duodenalis: the duodenal impression on the right side of the gall bladder on the visceral surface of the right lobe of the liver
impressio gastrica: the gastric impression of the stomach on the visceral surface of the left lobe of the liver
impressio renalis: the renal impression of the kidney on the visceral surface of the right lobe of the liver
impressio suprarenalis: the suprarenal impression of the right adrenal gland on the visceral surface of the right lobe of the liver
impressio trigemini: the trigeminal impression of the semilunar ganglion on the anterior surface of the petrous part of the temporal bone, near its apex
inactivitas, -atis, f. L.: inactivity
inaequalis, -e, L.: unequal
incipiens, -ntis, L.: incipient, beginning (incipiere: to begin)
incisio, -onis, f. L.: incision (incidere: to make a cut)
incisivus, -a, -um: incisive; having the quality of cutting; pertaining to the incisor teeth
dens incisivus: incisor tooth
incisura, -ae, f. L.: incisure; notch
incisura cardiaca: the cardiac notch on the anterior border of the left lung corresponding to the pericardium
incisurae cartilaginis meatus acustici: notches of the cartilagenous part of the acustic meatus: these fissures are in the anterior part of the cartilage
incisura frontalis lateralis: incisura sive foramen supraorbitale: the supraorbital notch or foramen on the squama frontalis for the supraorbital vessels and nerve
incisura frontalis medialis: incisura sive foramen frontalis: the frontal notch or foramen on the squama frontalis for the supratrochlear vessels and nerve
incisura pallii: fissura longitudinalis cerebri: the longitudinal cerebral fissure separating the two cerebral hemispheres

incisura pterygoidea: the notch between the lower ends of the medial and lateral pterygoid plates of the sphenoid bone

incisura Rivini: s. incisura tympanica

incisura Santorini: s. incisurae cartilaginis meatus acustici

incisura tentorii: the tentorial notch which is bounded by the free border of the tentorium cerebelli. It gives passage to the midbrain

incisura thoracica: thoracic notch: the infrasternal angle between the two subcostal margins

incisura tympanica: the deficiency in the upper part of the tympanic ring

inclinatio, -onis, f. L.: inclination, bend, slope (inclinare: to bend)

inclinatio pelvis: the inclination of the pelvis: the plane of the pelvic inlet encloses an angle of about 55° with the horizontal plane

incompletus, -a, -um, L.: incomplete, partial (complere: to complete)

incus, -udis, f. L.: anvil: the intermediate ossicle of the middle ear, which articulates with the malleus and stapes

incudo-mallearis: incudomalleal; pertaining to the incus and malleus

incudo-stapedicus: incudostapedial; pertaining to the incus and stapes

index, -icis, m. L.: pointer, hence the forefinger

indicans, -antis, L.: indicating (indicare: showing, announce)

individuum, -i, n. L.: individual; that which is indivisible (dividere: to divide)

indifferens, -ntis, L.: indifferent; neutral

cellulae indifferentes: undifferentiated cells: e.g. of the embryo

infantilis, -e, L.: infantile; hence retarded (infans: not speaking)

infectio, -onis, f. L.: infection; the invasion of the body by living pathogenic and reproductive animal or plant organisms, esp. microorganisms (inficere: to infect)

inferior, -ius, L.: situated below (inferus: lower)

inflammatio, -onis, f. L.: inflammation (inflammare: to inflame)

infra- (prep. with accusative), L.: below, under (used in combination)

infraclavicularis, -e: infraclavicular; inferior to or below the clavicle

infracorticalis, -e: subcorticalis: infracortical: inferior to or below the cortex (of the brain)

infraglenoidalis, -e: infraglenoid; inferior to or below the fossa of the glenoid cavity

inframammalis, -e: inframammary; inferior to or below the mammary gland

inframandibularis, -e: submandibularis; inframandibular; under the lower jaw

infraorbitalis, -e: infraorbital; inferior to or below the orbit

infrapatellaris, -e: infrapatellar; inferior to or below the patella

infrascapularis, -e: infrascapular; inferior to or below the scapula

infraspinatus, -a, -um: inferior to or below the spine of the scapula

infratemporalis, -e: inferior to or below the temporal region

infratrochlearis, -e: inferior to or below the trochlea

infraumbilicalis, -e: infraumbilical; inferior to or below the umbilicus

infundibulum, -i, n. L.: funnel (infundere: to fill)

infundibulum cochleae: scyphus Vieussensi: the termination of the spiral cochlear canal at the cupula where the helicotrema is situated

infundibulum crurale: canalis femoralis: the femoral canal

infundibulum ethmoidale: the funnel-shaped passage of the ethmoid connecting the frontal sinus and anterior ethmoidal air cells with the middle meatus of the nasal cavity

infundibulum hypothalami: the funnel-shaped downward extension of the floor of the 3rd ventricle, which continues as the stalk of the pituitary body

infundibulum tubae uterinae: infundibulum of the uterine tube: the funnel-shaped lateral part of the tube

Ingrassia's process: the lesser wings of the sphenoid bone

inguen, -inis, f. L.: the groin

inguinalis, -e: inguinal; pertaining to the groin

canalis inguinalis: inguinal canal; the oblique passage just superior to the medial half of the inguinal ligament which starts at the deep, and terminates at the superficial inguinal ring and transmits the spermatic cord, or the round ligament through the anterior abdominal wall

fossa inguinalis (medialis et lateralis): the small depressions lying respectively medial and lateral to the lateral umbilical fold and underlying the deep and superficial inguinal rings

lig. inguinale (Pouparti): the inguinal ligament (Poupart's ligament): the fibrous thickening of the border of the external oblique muscle, which extends from the anterior superior spine of the ilium to the pubic tubercle

trigonum inguinale: inguinal triangle: (Hesselbach's triangle): the triangle bounded by the inferior epigastric artery, the inguinal ligament and the lateral border of the rectus abdominis

inion, Gr.: the most prominent point on the external occipital protuberance

innervatio, -onis, f. L.: innervation; the nerve supply of a structure

innominatus, -a, -um, L.: innominate, nameless

a. innominata

foramen innominatum: canaliculus innominatus: the occasional small canal on the medial side of the foramen spinosum, through which the lesser petrosal nerve may pass

linea innominata: innominate line: a term which has been applied to the sacral part of the linea terminalis separating the true from the false pelvis

inscriptio, -onis, f. L.: inscription (inscribere: to write)

inscriptio tendinea: s. intersectio tendinea

insertio, -onis, f. L.: insertion; the more mobile and usually the more distal or lateral attachment of a muscle to the bone (inserere: to insert)

insufficientia, -ae, f. L.: insufficiency; inadequate functioning of an organ

insula, -ae, f. L.: island

insula Langerhansi: the islets of Langerhans: the endocrine cell groups in the substance of the pancreas

insula Reilii: the island of Reil, or insula: the part of the cortex lying deeply in the lateral sulcus and being bounded by the circular sulcus and covered by the opercula

integumentum, -i, n. L.: integument, cover

inter-, prep. (with accusative) L.: situated between (used in combination)

interalveolaris, -e: interalveolar; between the alveoli

interarticularis, -e: interarticular; situated between two joints or two joint surfaces

interarytenoideus, -a, -um: interarytenoid; between the arytenoid cartilages

interatrialis, -e: interatrial; situated between the atria

intercalaris, -e: intercalary; interposed, inserted between (intercalare: to insert)

intercarpeus, -a, -um: intercarpal; between the carpal bones

intercavernosus, -a, -um: intercavernous; situated between two cavities or between the cavernous sinuses

intercellularis, -e: intercellular; situated between the cells of a tissue

intercilium, -ii: the glabella or the area between the eyebrows

intercolumnaris, -e: intercolumnar; situated between columns

intercondylaris, -e: (intercondyloideus), intercondylar; situated between two condyles

intercostalis, -e: intercostal; situated between the ribs

intercruralis, -e: intercrural situated between two crura

interdigitatio, -onis, f. L.: interdigitation; interposition of finger-like processes

interfoveolaris, -e: interfoveolar; situated between foveolae

interganglionaris, -e: interganglionic; situated between ganglia

intergyralis, -e: intergyral; situated between the cerebral convolutions

interhemisphaericus, -a, -um: interhemispheric; situated between the (cerebral) hemispheres

interlobaris, -e: interlobar; situated between lobes

interlobularis, -e: interlobular; situated between lobules

intermedius, -a, -um: intermediate

intermeningealis, -e: intermeningeal; situated between the meninges

intermuscularis, -e: intermuscular; situated between muscles

internuntialis, -e: internuncial; neurone situated in series between two other neurons, thus acting as intermediate transmitter of the nerve-impulse

interosseus, -a, -um: interosseous; situated between bones

interpeduncularis, -e: interpeduncular; situated between two peduncles

interpolaris, -e: interpolar; situated between poles

intersectio tendinea: tendinous intersection: a fibrous partition, which passes across and interrupts the belly of a muscle such as rectus abdominis

intersegmentalis, -e: intersegmental; situated between segments

interstitialis, -e: interstitial; situated between cells, or in spaces within tissues

intertransversarius, -a, -um: intertransverse; situated between the transverse processes of vertebrae

intertubercularis, -e: intertubercular; situated between two tubercules, e.g. of the humerus

intervertebralis, -e: intervertebral; situated between vertebrae

intervillosus, -a, -um: intervillous; situated between villi

interior, -ius, L.: situated inside

internus, -a, -um, L.: situated inside, within

intestinum, -i, n. L.: intestine

intestinum caecum: cecum; the blind pouch forming the beginning of the large intestine

intestinum crassum: the large intestine

intestinum ileum: the ileum (the distal part of the small intestine)

intestinum jejunum: the jejunum: the proximal part of the small intestine (jejunus, L.: empty)

intestinum rectum: rectum; the distal part of the large intestine, which ends at the anal canal (rectus, L.: straight)

intestinum tenue: the small intestine

intestinum tenue mesenteriale: the freely movable part of the small intestine including the jejunum and ileum, which is attached by a common mesentery to the posterior abdominal wall

intestinalis, -e: intestinal; pertaining to the intestine

intima, -ae, f. L.: the innermost layer of the wall of a blood vessel consisting of endothelium and a delicate connective tissue underlying it (intimus: innermost)

intra-, prep. (with accusative), L.: within (used in combination)

intraabdominalis, -e: intra-abdominal; situated within the abdomen

intraarachnoidalis, -e: intra-arachnoid; situated within or beneath the arachnoid

intraarterialis, -e: intra-arterial; situated within an artery or arteries

intraarticularis, -e: intra-articular; situated within a joint

intraatrialis, -e: intra-atrial; situated within the atrium

intrabronchialis, -e: intrabronchial; situated within the bronchus

intracapsularis, -e: intracapsular; situated within a capsule

intracardialis, -e: intracardiac; situated within the heart

intracarpalis, -e: intracarpal; situated within the carpus

intracellularis, -e: intracellular; situated within the cell

intracerebellaris, -e: intracerebellar; situated within the cerebellum

intracerebralis, -e: intracerebral; situated within the cerebrum

intracranialis, -e: intracranial; situated within the skull

intracutaneus, -a, -um: intracutaneous; situated within layers of the skin

intraduralis, -e: intradural; situated within the dura mater

intrafascicularis, -e: intrafascicular; situated within fasciculi

intraglandularis, -e: intraglandular; situated within a gland

intrajugularis, -e: intrajugular; situated within the jugular notch or foramen
intralaryngealis, -e: intralaryngeal; situated within the larynx
intralobularis, -e: intralobular; situated within a lobule
intramedullaris, -e: intramedullary; within the spinal cord, medulla oblongata or bone marrow
intrameningealis, -e: intrameningeal; within the meninges
intramuralis, -e: intramural; within the wall of an organ
intraocularis, -e: intraocular; within the eyeball
intraperitonealis, -e: intraperitoneal; within the peritoneal cavity
intrapleuralis, -e: intrapleural; within the pleural cavity
intrathecalis, -e: within a sheath, or within the spinal meninges
intrathoracalis, -e: intrathoracic; situated within the thorax
intrauterinalis, -e: intrauterine; situated within the uterus
intravenosus, -a, -um: intravenous; situated within a vein
intraventricularis, -e: intraventricular; situated within a ventricle
intravitalis, -e: intravital; occurring during life

introitus, -us, m. L.: entrance
introitus pelvis: the pelvic inlet
introitus vaginae: the entrance of the vagina

intumescentia, -ae, f. L.: intumescence, swelling (intumescere: to swell)
intumescentia cervicalis et lumbalis: the cervical and lumbar enlargements of the spinal cord
intumescentia gangliformis: ganglion geniculi: a term formerly denoting the sensory geniculate ganglion of the facial nerve (geniculum n. facialis)
intumescentia tympanica: ganglion tympanicum: tympanic ganglion: groups of nerve-cells associated with the tympanic branch of the glossopharyngeal nerve

inversus, -a, -um, L.: inverted, opposite, contrary (invertere: to turn in)

involucrum, -i, n. L.: cover, sheath (involvere: to wrap)
involutio uteri: the involution of decrease in size of the uterus after parturition

iris, -idis, f. Gr.: rainbow; the membrane of the eye, situated behind the cornea and forming the boundary of the pupil. It contains the sphincter and dilator pupillar muscles and pigment-cells
iridicus, -a, -um: iridic (iridial); pertaining to the iris

ischaemia, -ae, f. Gr.: ischemia; localized lack or deficiency of blood
os ischii: ischium: the lower posterior component of the hip bone
ischiadicus, -a, -um: ischial; sciatic; pertaining to the ischium
n. ischiadicus: the sciatic nerve, the thickest nerve of the human body. A branch of the lumbosacral plexus; it supplies directly—or by its branches — the hamstrings and the muscles of the leg (crus)
tuber ischiadicum: the ischial tuberosity or tuber

isthmus, -i, m. Gr.: a narrow part of a structure connecting two larger parts

isthmus aortae: the slightly narrowed part of the aorta between the left subclavian artery and the ligamentum arteriosum

isthmus cartilaginis auris: the isthmus of the cartilage of the ear: the narrow piece of cartilage connecting the cartilage of the auricle with that of the external auditory meatus

isthmus faucium: oropharyngeal isthmus: the aperture, by which the mouth communicates with the pharynx. It is surrounded by the arch of the palatoglossal folds

isthmus glandulae thyreoideae: the isthmus of the thyroid gland: the narrow median portion connecting the two lateral lobes of the thyroid gland

isthmus gyri cinguli: the posterior narrowed connection between the parahippocampal and cingulate gyrus

isthmus rhombencephali: the constricted region connecting the rhombencephalon with the mesencephalon in the embryo

isthmus tubae auditivae: the isthmus of the auditory tube: the narrowest part of the tube at the junction of the bony and cartilaginous parts

isthmus tubae uterinae: the isthmus of the uterine tube: the narrow medial part of the tube, which joins the lateral angle of the uterus

isthmus urethrae: isthmus of the urethra: a term which has been applied to the junction of the cavernous with the membranous urethra

isthmus uteri: the isthmus of the uterus: the lowest constricted part of the body which corresponds to the "lower uterine segment" of the obstetrician. It is about 1 cm in length

isthmus ventriculi Aschoffi: a term which has been applied to the physiological narrowing between the body and pyloric part of the stomach

isthmus Vieussensi: limbus fossae ovalis; the ring of Vieussens or margin of the fossa ovalis

isthmicus, -a, -um: isthmian, isthmic; pertaining to an isthmus

J

Jackson's membrane: peritoneal bands or folds passing from the cecum or ascending colon to the abdominal wall

Jacob's membrane: the layer of rods and cones in the retina

Jacobson's anastomosis: the communication between the inferior ganglion of the glossopharyngeal and the otic ganglion via the tympanic nerve and plexus and the lesser petrosal nerve

Jacobson's cartilage: cartilago vomeronasalis: the narrow vomeronasal cartilage wedged between the septal cartilage and the vomer

Jacobson's groove: sulcus promontorii: a groove on the promontory of the middle ear for the tympanic nerve

Jacobson's organ: organon vomeronasale: the rudimentary vomeronasal organ of the lower part of the nasal septum anterosuperior to the incisive canals (in many lower animals it is well developed and lined with olfactory epithelium)

Jacobson's plexus: plexus tympanicus: the tympanic plexus on the promontory of the middle ear

jejunum, -i, n. L.: the proximal part of the small intestine (jejunum: empty, famished)

jejunalis, -e: jejunal; pertaining to the jejunum

Jonnesco's fossa: the shallow duodenojejunal fossa between the superior and inferior duodenal folds

jugulum, -i, n. L.: 1. the neck, or throat; 2. the jugular fossa (situated between the lower ends of the two sternocleidomastoids and above the manubrium sterni)

jugularis, -e: jugular; pertaining to the neck, or to the jugular fossa

foramen jugulare: jugular foramen: the opening on the base of the skull bounded by the occipital and temporal bones, and giving passage to the termination of the sigmoid and inferior petrosal sinuses and the beginning of the internal jugular vein and the 9th, 10th, 11th cranial nerves

fossa jugularis: jugular fossa: the deep oval depression on the inferior surface of the temporal bone medial to the styloid process, which lodges the superior bulb of the internal jugular vein

incisura jugularis: the jugular notches of the temporal and occipital bones, bounding the jugular foramen

processus intrajugularis: the intrajugular process of the occipital and temporal bones, which sometimes divides the jugular foramen into two parts (foramen jugulare verum et foramen jugulare spurium)

processus jugularis: the jugular process of the occipital bone, which forms the posterior border of the jugular foramen

tuberculum jugulare: jugular tubercle: the oval elevation on the superior surface of the condylar part of the occipital bone on either side of the foramen magnum above the condylar canal

vena jugularis anterior, externa, interna: the anterior, external, internal jugular vein

jugum, -i, n. L.: yoke

juga alveolaria: the ridges on the anterior surface of the alveolar processes of the maxilla and mandible, which are raised by the roots of the incisors and canines

juga cerebralia: the cerebral ridges on the inner surface of the cranial bones corresponding to the fissures of the brain

jugum petrosum: eminentia arcuata: the arcuate eminence on the anterior surface of the petrous part of the temporal bone formed by the superior semicircular canal

jugum sphenoidale: the smooth anterior part of the upper surface of the sphenoid bone connecting the lesser wings and supporting the gyri recti

junctura, -ae, f. L.: junction (jungere: to connect)
junctura ossium: bony junction
junctura tendineum: tendinous junction

Jung's muscle: m. pyramidalis auriculae: the fibres of tragicus, which may be prolonged to the spine of the helix

juxta, prep. (with accusative), L.: near (used in combination)
juxtaauricularis, -e: juxtaauricular; situated near the auricle
sulcus juxtaauricularis: the juxtaauricular groove on the internal aspect of the ilium situated just in front of the auricular surface
juxtamedullaris, -e: juxtamedullary; situated near the medulla of the kidney
juxtamuralis, -e: juxtamural; situated near the wall of a structure

K

karyo-, Gr.: a term denoting relationship to a nucleus (used only in combination) (karyon: nut)
karyokinesis: mitotic cell division (kinesis: motion)
karyolysis: the final disappearance of the nucleus of a dead cell
karyoplasma: karyoplasm: the nucleoplasm
karyorrhexis: disintegration of the nucleus of the degenerating cell

Keith and Flack's node: nodus sinuatrialis: the sinuatrial node at the upper end of the sulcus terminalis in the wall of the right atrium, where the impulse initiating systole starts

Kent's bundle: the bundle of Paladino and Kent: s. His' bundle

keratin: the scleroprotein of the hair and nails and of the horny layer of the epidermis (keras, Gr.: horn)
kerato-, Gr.: in combination denotes relationship to keratin and formerly to the horn of the hyoid bone
m. keratoglossus, JNA: those fibres of hyoglossus arising from the greater horn of the hyoid bone
m. keratopharyngeus, JNA: m. constrictor pharyngis medius: the middle constrictor of the pharynx
keratoid: resembling horn
stratum keratoideum: stratum corneum: the outermost, horny layer of the epidermis

Kerckring's folds: plicae circulares intestini tenuis: the circular mucous folds of the small intestines, which are especially distinct in the duodenum and the jejunum

Kiernan's space: spatium interlobulare hepatis: the interlobular connective tissue spaces in the liver

Kiesselbach's area: the area on the anterior part of the nasal septum, which is commonly the site of bleeding as a result of its rich blood supply

Killian's line: the transverse line of the promontory of the sacrum, which is continuous laterally with the linea terminalis

Killian's muscle: m. fundiformis pharyngis: the most inferior part of the inferior constrictor of the pharynx

Kiss, the funnel-valved veins of: the veins of the corpora cavernosa described as playing an important role in the mechanism of erection of the penis

klasmatocyta, -ae, Gr.: clasmatocyte: histiocyte, resting wandering cell, etc.; cell of the connective tissue, which is characterized by its phagocytic properties. It is similar to the tissue macrophages derived from monocytes but seems to be less mobile

Klumpke's paralysis: the birth palsy involving the C. 8. and T. 1. roots of the brachial plexus

Kohlrausch's folds: plicae transversales recti: the term usually refers to the three constant transverse folds of the mucous membrane of the rectum, but sometimes only to the lowest of the three

Kölliker's cells: spermatoblasts: obsolete term which has been applied to the spermatids

Kölliker's layer: the middle, connective tissue layer or stroma of the iris

Koyter's muscle: m. corrugator supercilii: the muscle which wrinkles the forehead in drawing the eyebrows downwards and medially as in frowning

Krause's glands: glandulae conjunctivales: the conjunctival glands which can be regarded as accessory lacrimal glands

Krause's terminal club: the sensory nerve-endings with the form of bulbous corpuscles in the conjunctiva, tongue, epidermis of the external genitalia, etc. They have been supposed to be concerned with the sensation of cold

Krause's valve: valvula sacci lacrimalis inferior: the fold of mucous membrane at the inferior end of the lacrimal sac and at the commencement of the nasolacrimal duct

Krönig's fields: a band of resonance to percussion over the apices of the lungs

Kupffer's cells: the phagocitic reticulo-endothelial cells lining the liver sinusoids

Kupressoff's centre: a centre at the level of the 3rd–5th lumbar spinal cord segments, which has been described as being concerned with the innervation of the sphincter of the urinary bladder

kyphoscoliosis, Gr.: pathological forward and lateral curvature of the vertebral column (skoliosis: curvature)

kyphosis, Gr.: pathological forward curvature of the vertebral column (kyphos: bent, hunch-backed)

L

L.: an abbreviation for lumbar; pertaining to the loins

vertebra, L.: the lumbar vertebra

L_3*:* the 3rd lumbar segment of the spinal cord, or the 3rd lumbar spinal nerve

Labbé's triangle: the triangular area bounded by a horizontal line, passing through the

tip or lowest part of the 9th rib by the left subcostal margin and by the inferior border of the liver

Labbé's vein: the inferior anastomotic vein between the superficial middle cerebral vein and the transverse sinus

labium, -ii, n. L.: lip

labia oris: the lips

labia pudendi majora: the two large folds of skin bounding the cleft of the vulva on either side

labia pudendi minora: the two small folds of skin situated within the labia majora and bounding the vestibule

labium anterius et posterius orificii externi uteri: the anterior and posterior lips of the vaginal orifice of the uterus

labium articulare: labrum glenoidale: the fibrocartilaginous lip attached to the edge of the glenoid cavity

labium inferius oris: the lower lip

labium limbi tympanicum laminae spiralis: the tympanic, or the lower border of the two outer lips of the limbus of the bony spiral lamina

labium limbi vestibulare laminae spiralis: the vestibular or upper of the two outer lips of the limbus of the bony spiral lamina

labium superius oris: the upper lip

labium urethrae: the small lips which bound either side of the sagittally placed external urethral orifice

labium vocale: plica vocalis

labialis, -e: labial; pertaining to a lip

labiodentalis, -e: labiodental; pertaining to the labial surface of the teeth

labrum, -i, n. L.: edge, lip

labrum acetabulare: the fibrocartilaginous lip attached to the edge of the acetabulum, thus increasing its depth

labrum cartilagineum: the lip at the border of an articular cartilage

labrum glenoidale: the fibrocartilaginous lip attached to the edge of the glenoid cavity and increasing its depth

labyrinthus, -i, m. Gr.: labyrinth; a structure consisting of intercommunicating passages

labyrinthus ethmoidalis: the labyrinth of ethmoidal cells in the lateral part of the ethmoid bone

labyrinthus membranaceus: the membranous labyrinth of the internal ear including the membranous structures lying within the bony labyrinth

labyrinthus osseus: the bony labyrinth of the internal ear including the vestibule and cochlea

lac, -tis, n. L.: milk

lactatio, -nis, f. L.: lactation or secretion of milk; suckling

lactifer, -a, -um: lactiferous; giving or conveying milk (ferre: to bear)

lacer, -era, -erum, L.: lacerated, torn

foramen lacerum: the opening on the base of the skull between the petrous part of the temporal, the sphenoid and the occipital bone, which has an irregular edge and is closed by a cartilaginous plate

lacertus, -i, m. L.: the upper arm, muscle (a term used by the Romans)

lacertus cordis: s. trabeculae carneae

lacertus fibrosus: the bicipital aponeurosis

lacertus medius Weitbrechtii: the continuation of the anterior longitudinal ligament, which strengthens the median part of the anterior atlantooccipital membrane

laciniatus, -a, -um, L.: fringed, jagged

lig. laciniatum: the flexor retinaculum of the ankle

lacrima, -ae, f. L.: tear

lacrimalis, -e: lacrimal; pertaining to tears and hence the lacrimal apparatus

lacuna, -ae, f. L.: small depression or hollow

lacunae cerebri: the perivascular spaces around the arterioles in the cerebral substance

lacuna Howshipi: s. Howship's lacunae

lacunae intervillosae: the intervillous lacunae; the blood-spaces between the villi of the placenta

lacunae laterales: the lateral lacunae of the superior sagittal sinus into which arachnoid granulations project

lacuna lymphatica: lacuna herniosa: lymphatic or hernial space: surgical terms which have been applied to the internal opening of the femoral canal

lacuna magna: the depression in the roof of the fossa navicularis of the penile urethra brought about by Guérin's fold

lacuna pharyngis: a term which has been applied to the expanded pharyngeal opening of the eustachian tube

lacunae tonsillares: cryptae tonsillares: the narrow slits on the surface of the tonsils extending into the organ

lacunae urethrales (Morgagnii): the small blind recesses in the mucosa of the urethra

lacuna vasorum: the passage deep to the inguinal ligament, which accomodates the femoral artery and vein

lacunaris, -e: lacunar; pertaining to a lacuna

lacus, -us, m. L.: lake

lacus lacrimalis: the space filled with lacrimal fluid between the medial margins of the eyelids at the inner angle. The caruncle lies in its floor

laevus, -a, -um, L.: pertaining to the left side

Lallemand's bodies: concretions in the seminal vesicles

Lallouette's pyramids: s. lobus pyramidalis glandulae thyreoideae

lambdoideus, -a, -um: shaped like lambda (*Λ λ*) the Greek letter L

sutura lambdoidea: the lambdoid suture between the occipital and parietal bones

lamella, -ae, f. L.: a thin plate

lamellosus, -a, -um: lamellated: composed of, or arranged as plates

lamina, -ae, f. L.: plate

lamina affixa: the ependyma of the lateral ventricle, which is contiguous with the superior surface of the thalamus

laminae arcus vertebrae: the two laminae which pass from the pedicles of a vertebra and by their fusion posteriorly in the midline complete the vertebral arch

lamina basalis chorioideae: the basal lamina of the choroid between the vascular lamina of the choroid and the pigmented layer of the retina

lamina cartilaginis cricoideae: the posterior expanded lamina of the cricoid cartilage

lamina choriocapillaris (Ruyschi): the capillary lamina of the choroid lying within the vascular lamina

lamina chorioidea: chorioidea: the choroid of the eyeball

lamina chorioidea epithelialis: the epithelial ependymal layer forming the covering of the choroid plexuses of the 3rd and 4th and lateral ventricles

lamina cinerea: s. lamina terminalis (cerebri)

lamina cribrosa ossis ethmoidalis: the cribriform plate of the ethmoid bone, which forms part of the roof of the nasal cavity and is pierced by the filaments of the olfactory nerve

lamina cribrosa sclerae: the posterior pole of the sclera perforated by the optic nerve

lamina dentalis: the ectodermal thickenings of the jaws, from which the enamel organs develop

lamina dura: the dura mater or the dense bone seen radiologically to form the innermost part of the wall of the dental alveolus

lamina elastica anterior (Bowmani, lamina limitans anterior: the anterior limiting layer of the cornea between the anterior epithelium and the substantia propria

lamina elastica posterior (Descemeti seu Demoursi), lamina limitans posterior: the posterior limiting layer of the cornea between the substantia propria and the endothelium of the anterior chamber

lamina externa cranii: the outer plate of the cranial bones forming the calvarium

lamina fibrocartilaginea interpubica: discus interpubicus: the fibrocartilaginous disc uniting the articular surfaces of the pubic bones in the sympyhsis pubis

lamina fusca sclerae: the inner pigmented part of the sclera

lamina interna cranii: tabula vitrea: the inner plate of the cranial bones forming the calvarium

lamina lateralis et medialis processus pterygoidei: the lateral and medial plates of the pterygoid process of the sphenoid bone

laminae medullares thalami: medullary laminae of the thalamus: the two layers of white matter between the nuclei of the thalamus. The medial one separates

the medial from the lateral and ventral nuclei and the lateral lamina lies between the lateral and reticular nuclei

lamina modioli: the terminal plate-like part of the modiolus extending toward the cupula

lamina orbitalis: (lamina papyracea): the orbital plate of the ethmoid, which takes part in the formation of the medial wall of the orbit and the lateral wall of the ethmoidal labyrinth

lamina perpendicularis ossis ethmoidalis: the perpendicular plate of the ethmoid bone, which forms part of the bony nasal septum

lamina perpendicularis ossis palatini: the perpendicular plate of the palatine bone, which forms part of the posterior part of the lateral wall of the nasal cavity

lamina quadrigemina (lamina tecti mesencephali): the tectal plate of the mid-brain, formed by the superior and inferior colliculi

lamina rostralis: the thin terminal continuation of the rostrum of the corpus callosum, which passes to the anterior commissure

lamina spiralis membranacea: lamina basilaris: the basilar lamina which extends from the bony spiral lamina to the outer wall of the cochlea

lamina spiralis ossea: the bony spiral lamina winding round and projecting from the modiolus into the spiral canal of the cochlea

lamina spiralis secundaria: the secondary spiral lamina: the bony plate which projects from the outer wall of the lower part of the basal coil of the cochlea towards the bony spiral lamina

lamina suprachorioidea: the pigmented layer of the outer surface of the choroid, which separates the vascular layer from the sclera

lamina terminalis: the anterior wall of the 3rd ventricle of the brain

lamina tragi: the cartilaginous plate forming the beginning of the cartilage of the external auditory meatus

lamina vasculosa: the vascular layer of the choroid containing the larger vessels

lamina vitrea: s. lamina interna cranii

Lancisi's striae: striae longitudinales: the longitudinal strands of nerve-fibres on the upper surface of the corpus callosum

Landolt's bodies: branches of bipolar cells of amphibia, reptiles and birds, which end near the external limiting membrane among the rods and cones cells of the retina

Landström's muscle: the smooth muscle fibres in the anterior part of the sheath of the eye ball, some of which are attached to the upper and lower tarsi

Langenbeck's triangle: the space between the anterior superior spine of the ilium, the greater trochanter and the anatomical neck of the femur

Langer's arch or muscle: an occasional slip from latissimus dorsi, which inserts with pectoralis major having crossed the axillary vessels

Langerhans' cells: stellate cells, which have been demonstrated in the epidermis by treatment with gold chloride. They may be pigmented

Langerhans' islands: the clumps of endocrine cells in the pancreas, which produce insulin

Langerhans' layer: s. stratum granulosum of the skin

Langhans' cells: the cytotrophoblastic cells of the chorion

Langhans' layer: the cytotrophoblast layer of the chorion

Lanterman's clefts or incisures (Schmidt–Lanterman): the oblique clefts, which have been described as interrupting the continuity of the myelin between the nodes of Ranvier in peripheral nerve-fibres

lanugo, -inis, f. L.: the fine hair of the skin of the foetus or the down on the cheeks

Lanz's point: the point at the junction of the right and median thirds of a line joining the two anterior superior iliac spines

laquear vaginae: s. fornix vaginae

Larrey's point: the femoral point, where the femoral artery passes beneath the inguinal ligament half way between the anterior superior iliac spine and the symphysis pubis and can there be compressed

Larrey's triangle: trigonum sternocostale diaphragmatis: sternocostal triangle of the diaphragm: the triangular interval between the sternal and costal parts of the diaphragm

larynx, -gis, m. Gr.: the larynx, which is situated at, and guards the entrance to the trachea and is concerned with production of the voice

laryngealis, -e, *laryngeus*, -a, -um: laryngeal; pertaining to the larynx

lateralis, -e, L.: lateral; pertaining to the side, more distant from the mid line

latero-: (used in combination: lateral)

latitudo, -inis, f. L.: latitude, extension, dimension

latus, -eris, n. L.: the side

m. latissimus colli: platysma, the muscle of the skin of the neck

m. latissimus dorsi: the broad flat triangular muscle of the back

Laumonier's ganglion: s. ganglion caroticum

Lauth's canal: s. sinus venosus sclerae

Leber's plexus: Hovius' plexus: the small venous plexus situated between Schlemm's canal and spaces of Fontana

Lecat's gulf: the dilated part of the urethra lying within the bulb of the penis

Lee's ganglion: a group of small autonomic ganglia lateral to the neck of the uterus

lemniscus, -i, m. L.: band

lemniscus lateralis: the tract of auditory fibres passing through the pons from the corpus trapezoidum to the inferior colliculus

lemniscus medialis: the tract of fibres conveying epicritic and proprioceptive sensory impulses from the gracile and cuneate nuclei to the posterior part of the ventral nucleus of the thalamus

lemniscus trigeminalis: the fibres which pass from the sensory nuclei of the trigeminal nerve to the posterior part of the ventral nucleus of the thalamus

lens, -tis, f. L.: lentil: hence lens, the lens of the eye

lens crystallina: the lens of the eye

lenticula, -ae, f. L.: a small lens or lens-like structure

lenticularis, -e: lenticular; shaped like a lentil or lens; pertaining to the lens

lenticuloopticus, -a, -um: lenticulo-optic; denoting relationship to the lentiform nucleus and the optic pathways (topographical term)

lenticulostriatus, -a, -um: lenticulostriate; pertaining to the lentiform nucleus and the corpus striatum

lentiformis, -e: lentiform; shaped like a lens

Lenzman's point: s. McBurney's point

leptomeninx, -gis, f. Gr.: the pia mater and arachnoid together (lepto: thin, fine; meninx: membrane)

Lesshaft's triangle: the triangle of Grynfelt and Lesshaft, bounded by the anterior border of quadratus lumborum, the posterior border of the internal oblique and the 12th rib

leucocyta, Gr.: leucocyte; white blood corpuscle (leuko: white; kytos: the cell)

levator, -oris, m. L.: that which raises or lifts up (levare: to raise)

m. levator ani: the main muscle of the pelvic floor

levis, -e, L.: smooth

Leyden's duct: mesonephric duct

Leydig's cells: the interstitial cells of the testes, which produce testosterone

liber, -a, -um, L.: free

lien, -is, m. L.: the spleen

lien accessorius seu succenturiatus: accessory spleen, which usually occurs on the gastrolienal ligament

lienalis, -e: lienal; pertaining to the spleen

flexura lienalis: the splenic or left colic flexure of the transverse colon where it is related to the spleen

Lieberkühn's glands or crypts: glandulae intestinales: the straight tubular intestinal glands, situated in the wall of the small and large intestine

Lieutaud's triangle: trigonum vesicae (Lieutaudi): the triangle of the base of the bladder, whose apices are the orifices of the ureter and the internal orifice of the urethra

ligamentum, -i, n. L.: ligament, band (ligare: to bind)

ligamentum apicis dentis: the apical ligament of the odontoid process of the axis, which extends from its tip to the anterior margin of the foramen magnum

ligamentum inguinale: s. inguen

ligamentum interfoveolare: the interfoveolar ligament which consists of a thickening of the transversalis fascia medial to the deep inguinal ring and connected above to the transversus abdominis and below to the inguinal ligament

ligamentosus, -a, -um: supplied with a band, ligamentous

limbus, -i, m. L.: border, edge

limbus alveolaris: the edge of the alveolar process of the jaw

limbus angularis: s. linea obliqua cartilaginis thyreoideae

limbus articularis: s. labrum glenoidale

limbus conjunctivae: the edge of the conjunctiva at the corneoscleral junction
limbus corneae: the edge of the cornea adjoining the sclera
limbus fossae ovalis Vieussensii: the prominent anterior and superior ridge bounding the fossa ovalis
limbus luteus: the margin of the macula lutea
limbus palpebralis: the margin of the eyelid

limbosus, -a, -um: supplied with a fringed, lobated edge

limen, -inis, n. L.: border, threshold
limen insulae: the part of the cortex of the insula in the stem of the lateral sulcus extending to the anterior perforated substance. It receives fibres from the lateral olfactory stria
limen nasi: the curved ridge which forms the superior and posterior boundary of the vestibule of the nose, where the skin is replaced by mucous membrane

limitans, -tis: limiting (limitare: to confine)
membrana limitans externa et interna: the external and internal limiting membranes of the retina, which separate the layer of rods and cones from the outer nuclear layer, and the layer of nerve-fibres from the vitreous body respectively

linea, -ae, f. L.: line
linea alba: the median fibrous band extending down the anterior abdominal wall from the xiphoid process to the symphysis pubis. It is formed by the insertions of the aponeuroses of the internal and external obliques and transversus abdominis
lineae albicantes: the white lines on the skin of the abdominal wall after pregnancy or less commonly after other forms of abdominal distension
linea arcuata: the arcuate line of the sheath of rectus abdominis, at about the level of the anterior superior iliac spines. Below the line the aponeuroses of the internal oblique and transversus pass anterior to the rectus abdominis to insert into the linea alba
linea aspera: the rough ridge running downwards on the posterior surface of the shaft of the femur and giving attachment to various muscles
lineae gluteae: the anterior, posterior and inferior gluteal lines on the gluteal surface of the ala of the ilium, which delimit the origins of the gluteus muscles
linea intercondyloidea femoris: the intercondylar line passing between the medial and lateral condyles of the femur and separating the intercondylar fossa from the popliteal surface
linea intermedia cristae iliacae: the rough intermediate line between the outer and inner lips of the crest of the ilium
linea intertrochanterica: the intertrochanteric line which, on the anterior surface of the femur between the neck and the shaft, passes between the greater and lesser trochanters

linea mediana: sulcus medianus ventriculi quarti: the median sulcus of the 4th ventricle: the groove between the right and left halves of the rhomboid fossa

linea mylohyoidea mandibulae: the oblique ridge on the inner surface of the body of the mandible, which passes from the alveolus of the 3rd molar towards the anterior part of the inferior border

linea nigra: the pigmented black line of the skin of the abdomen in pregnancy in front of the lower part of the linea alba

linea nuchae inferior: the curved inferior nuchal line running on the nuchal surface of the squamous part of the occipital bone half way between the superior nuchal line and the foramen magnum

linea nuchae superior: the ridge on the squama occipitalis passing laterally from the external occipital protuberance and separating the nuchal from the occipital surface

linea nuchae suprema: the slight and inconstant highest nuchal line passing laterally from the external occipital protuberance, just above the superior nuchal line on the squamous part of the occipital bone

linea obliqua cartilaginis thyreoideae: the oblique line of the thyroid cartilage which runs downwards and forwards from the superior tubercle on the lateral aspect of the lamina

linea obliqua (Sylvii): a term which has been applied to the projection of the lateral sulcus on the surface of the head

linea pectinea femoris: the pectineal line on the posterior surface of the femur below the lesser trochanter giving insertion to the pectineus muscle

linea poplitea tibiae (linea musculi solei): the rough soleal line running downwards and medially from the fibular facet on the posterior surface of the tibia and giving origin to the soleus

linea semicircularis: s. linea arcuata

linea semilunaris (Spigeli): the shallow groove on the skin of the anterior abdominal wall corresponding to the lateral border of the rectus abdominis

linea temporalis inferior et superior ossis parietalis: the semicircular inferior and superior temporal lines, which run on the side of the calvaria from the zygomatic process of the frontal across the parietal towards the mastoid region. The superior line gives attachment to the temporal fascia and the inferior one bounds the origin of temporalis muscle

linea terminalis pelvis: this consists of the crest of the pubis, the pecten pubis, the arcuate line of the ilium, and the promontory of the sacrum. It separates the true from the false pelvis

linea transversa: s. intersectio tendinea

linearis, -e: linear

lingua, -ae, f. L.: the tongue

lingua cerebelli: s. lingula cerebelli

lingualis, -e: lingual: pertaining to the tongue

a. lingualis: the lingual artery of the tongue, which is a branch of the external carotid

n. lingualis: the lingual nerve which is a branch of the mandibular and carries sensory fibres to the anterior two thirds of the tongue

lingula, -ae, f. L.: small tongue

lingula cerebelli: the most anterior lobule of the superior vermis of the cerebellum

lingula mandibulae: the small bony projection supermedial to the mandibular foramen and giving attachment to the sphenomandibular ligament

lingula pulmonis sinistri: the tongue-shaped part of the superior lobe of the left lung between the cardiac notch and the oblique fissure

lingula sphenoidalis: the lingula of the sphenoid: the small bony process, forming the lateral boundary of the posterior part of the carotid sulcus and overhanging the entrance to the pterygoid canal

liquor, -oris, m. L.: fluid, liquid

liquor amnii: the amniotic fluid filling the amniotic sac

liquor cerebrospinalis: the cerebrospinal fluid occupying the subarachnoid space and the cerebral ventricles

liquor chorii: the fluid occupying the extraembryonic coelom within the chorion of the early embryo

liquor Cotunnii: s. perilympha

liquor folliculi: the fluid in the graafian follicle

liquor Morgagni: fluid appearing between the fibres and epithelium of the crystalline lens after death

liquor pericardii: the small amount of fluid normally within the pericardial cavity

liquor Scarpae: s. endolympha

Lisfranc's joint: articulatio tarsometatarsea: the tarsometatarsal joints in the foot, through which Lisfranc's amputation is performed

Lisfranc's tubercle: tuberculum musculi scaleni anterioris: the tubercle on the 1st rib giving insertion to the scalenus ant. muscle

Lissauer's tract: tractus dorsolateralis: the dorsolateral tract of the spinal cord situated over the tip of the posterior horn. It receives fine sensory fibres from the posterior roots and sends collaterals into the substantia gelatinosa and posterior horn

Lissauer's zone: zona terminalis medullae spinalis: the layer of white substance, connecting the tip of the posterior horn and the surface of the spinal cord

Littré's glands: glandulae urethrales: the glands situated in the urethral mucous membrane

lobulus, -i, m. L.: lobule, small lobe

lobulus auriculae: the lobule or lowest part of the auricle

lobulus biventer: a lobule of the inferior hemisphere of the cerebellum, which is continuous medially with the pyramid of the vermis

lobulus centralis cerebelli: the central lobule forming the intermediate part of the vermis of the anterior lobe of the cerebellum

lobulus fusiformis: s. gyrus occipitotemporalis lateralis

lobulus gracilis: the small gracile or paramedian lobule, which forms the anterior part of the inferior semilunar lobule and is connected medially with the tuber vermis

lobulus paracentralis: the horseshoe-shaped convolution on the medial surface of the cerebrum surrounding the end of the central sulcus and being bounded by the paracentral sulcus, the cingulate sulcus and its marginal ramus

lobulus parietalis superior et inferior: the superior and inferior parietal lobules: the upper and lower parts of the parietal lobe on the lateral surface of the cerebral hemisphere, which are separated from each other by the intraparietal sulcus

lobulus quadrangularis cerebelli: quadrangular lobule: the posterior part of the hemisphere of the anterior lobe of the cerebellum, which is continuous medially with the culmen of the vermis

lobulus semilunaris superior et inferior: the superior and inferior semilunar lobules: the most posterior lobules of the superior and inferior surfaces of the cerebellar hemisphere

lobularis, -e: lobular; pertaining to a lobule

lobus, -i, m. L.: a lobe

lobus appendicularis: s. Riedel's lobe

lobus azygos: the occasional triangular lobe on the mediastinal surface of the apex of the right lung, which is delimited by the arch of the azygos vein embedded in the lung substance

lobus cacuminis: s. folium vermis

lobus caudatus (Spigeli): the caudate lobe of the visceral surface of the liver bounded anteriorly by the porta hepatis, to the right by the inferior vena cava and to the left by the fissure for the ligamentum venosum

lobus centralis: s. insula

lobus clivi: clivus monticuli: s. declive cerebelli

lobus cuneiformis: lobus biventer

lobus falciformis: a collective term which has been used to include gyrus fornicatus, lamina septi pellucidi, dentate gyrus and fornix

lobus frontalis: the frontal lobe of the cerebrum bounded behind by the central and below by the lateral sulci

lobus hepatis dexter et sinister: the right and left lobes of the liver, which are separated from each other by the falciform ligament, the fissure for the ligamentum venosum and the fissure for the ligamentum teres

lobus limbicus: a collective term which usually includes the gyrus fornicatus together with the olfactory bulb and stalk, the anterior and posterior parolfactory and the medial and lateral olfactory gyri

lobus occipitalis: the occipital lobe of the posterior part of the cerebrum, which is bounded anteriorly by the parietooccipital sulcus and the line joining it to the preoccipital notch

lobus olfactorius: the olfactory lobe of the cerebrum: a collective term which has been used to include the olfactory bulb, tract and trigone and the anterior perforated substance

lobus parietalis: the parietal lobe of the cerebrum, which is bounded by the central sulcus, a line joining the parietooccipital sulcus to the preoccipital notch and the continuation of the lateral sulcus backward until it intersects the latter line

lobus pyramidalis glandulae thyreoideae: the pyramidal lobe of the thyroid gland, which occurs in rather less than 50% of cases and extends upwards from the isthmus in front of the cricoid and thyroid cartilages

lobus quadratus hepatis: the quadrate lobe of the liver situated in front of the porta hepatis between the gall bladder and the fissure for the ligamentum teres

lobus renalis: reniculus: a renal lobe, which is formed by a pyramid capped by cortical substance

lobus Spigelii: s. lobus caudatus

lobus temporalis: the temporal lobe of the cerebrum, which is bounded by the lateral sulcus and its extension backward, until it intersects the line joining the parietooccipital sulcus to the preoccipital notch. The latter line forms its posterior boundary

lobaris, -e: lobar; pertaining to a lobe

localisatio, -onis, f. L.: localization; the site or situation of a structure

locus, -i, m. L.: place, site

locus caeruleus: a shallow groove on the floor of the rhomboid fossa extending rostrally from the superior fovea to the cerebral aqueduct. Its faint blue colour is due to the underlying pigmented nerve-cells, the substantia ferruginea

locus cinereus: s. locus caeruleus

locus ferrugineus: s. substantia ferruginea

locus Kiesselbachi: Kiesselbach's area; the area above the limen nasi, whose mucosa is richly supplied with vascular plexuses, and is fairly often the site of haemorrhage

localis, -e: pertaining to a certain place

locularis, -e: locular; provided with loculi (loculus: a small compartment or cavity)

Loewenberg's canal: the part of the cochlear duct above the membrana tectoria

longitudo, -inis, f. L.: length

longitudinalis, -e: longitudinal; running lengthwise

longus, -a, -um, L.: long

lordosis, -is, f. Gr.: excessive forward curvature of the vertebral column (lordosis: forward curvature)

Louis' angle: angulus sterni (Ludovici): the angle formed at the junction of the manubrium and the body of the sternum

Lower's rings: annuli fibrosi cordis

Lower's tubercle: s. tuberculum intervenosum

lucidus, -a, -um, L.: lucid; clear; transparent

Ludwig's ganglion: diffuse groups of autonomic nerve-cells in the interatrial septum

lumbricalis, -e, L.: lumbrical: resembling a worm (lumbricus, L.: earthworm)

m. lumbricalis: lumbrical muscle; the four slender muscles of the palm and sole of the foot, which arise from flexor digitorum profundus and flexor digitorum longus respectively and are inserted into the extensor expansions of the fingers and toes

lumbus, -i, m. L.: the loin

lumbalis, -e, L.: lumbar; pertaining to the loin

plexus lumbalis: the lumbar nerve-plexus

lumboiliacalis: lumboiliac; pertaining to the loin and ilium (denoting direction)

lumboinguinalis: lumboinguinal; pertaining to the loin and inguinal region (denoting direction)

n. lumboinguinalis: the femoral branch of the genitofemoral nerve, running beneath the inguinal ligament and supplying the skin of the lateral part of the femoral triangle

lumbosacralis: lumbosacral; pertaining to the loin and sacrum

plexus lumbosacralis: a comprehensive term including the lumbar, sacral, and coccygeal plexuses

lumen, -inis, n. L.: light; the cavity, or light part within a tube

luna, -ae, f. L.: moon

lunaris, -e: lunar; moon-shaped

lunula, -ae, f. L.: small moon

lunula unguis: the white, semilunar area of the proximal part of the nail

lunulae valvularum semilunarium: the crescenteric free edge of the semilunar valves of the heart on either side of the nodules

Luschka's ducts: tubular structures which sometimes branch from the bile ducts into the wall of the gall bladder. They have been considered to be aberrant bile ducts

Luschka's foramen: s. apertura lateralis ventriculi quarti

Luschka's gland: s. glomus coccygeum

Luschka's tonsil: s. tonsilla pharyngea

luteus, -a, -um, L.: yellow

corpus luteum: (yellow body) s. corpus

luxatio, -onis, f. L.: dislocation

Luys' median centre: the nucleus medialis centralis of the thalamus

Luys' nucleus: nucleus subthalamicus: the subthalamic nucleus in the lateral part of the hypothalamus. It projects to the subthalamic tegmental area and red nucleus

lympha, -ae, f. Gr.: water, lymph; the transparent liquid contained in the lymphatic vessels

lymphaticus, -a, -um: lymphatic; pertaining to lymph

lymphoblast: the precursor of the lymphocyte

lymphocyta: lymphocyte; a type of non-granular leukocyte, which is formed in lymphatic tissue including the lymph glands and circulates in the blood

lymphoglandula, -ae: lymph gland, or lymph node

lymphonodus: lymph node

lyra, -ae, f. Gr.: lyre

lyra Davidis (commissura fornicis): the lyre or psalter of David: the triangular formation bounded by the diverging crura of the fornix

lyra uterina: arbor vitae: plicae palmatae: palmate folds: the mucosal folds which extend obliquely from the two longitudinal ridges situated on the anterior and posterior walls of the canal of the uterine cervix

M

m. (abbreviation) for musculus: muscle

maceration, -onis, f. L.: maceration, softening; e.g. maceration of the soft parts from the skeleton (macerare: softening)

McBurney's point: the surface marking of the appendix; a point lying at the junction of the middle and lateral thirds of a line joining the umbilicus and anterior superior iliac spine

McDowell's frenulum: an offshoot from the tendon of the pectoralis major muscle, which crosses the bicipital groove

macro-, Gr.: in combination: large or excessive size or length (macro: large)

macrocyta: an abnormally large blood cell such as occurs in macrocytic anaemias

macrophag: macrophage; a phagocytic cell in connective tissue, which is probably derived from the monocytes of the blood

macroscopia: macroscopy; the examination of objects with the naked eye (opposite to microscopy)

macula, -ae, f. L.: spot

maculae acusticae: the maculae of the saccule and the utricle. These specialized areas of epithelium include hair cells which are sensitive to the position of the statoconia lying on their surface

macula cribrosa superior, media et inferior: the superior, middle and inferior maculae cribrosae: areas on the wall of the vestibule of the bony labyrinth of the internal ear, which are perforated to give passage to the nerve-fibres of the vestibular part of the vestibulocochlear nerve

macula flava laryngis: a small yellow cartilaginous nodule in the anterior part of the vocal ligament

macula germinativa: the germinal area or blastodisc in eggs containing much yolk

macula lutea retinae: the small yellow spot of the retina just lateral to the posterior pole, where vision is most acute

macularis, -e: macular; pertaining to a macula

maculatus, -a, -um: maculate; spotted

maculosus, -a, -um: spotted

Magendie's foramen: apertura mediana ventriculi quarti

Magendie's spaces: spaces between the pia and arachnoid

magnus, -a, -um, L.: great

Maissiat's band: s. tractus iliotibialis

major, majus, L.: greater (comparative of "magnus")

mala, -ae, f. L.: the cheek bone or cheek

malaris, -e: malar; pertaining to the cheek or zygomatic bone

facies malaris (ossis zygomatici): facies lateralis: the lateral surface of the zygomatic bone

os malare: os zygomaticum; the zygomatic bone

Malacarne's pyramid: the pyramids of the vermis cerebelli

Malacarne's space: s. substantia perforata posterior

Malgaigne's (triangle) fossa: s. trigonum caroticum

malleolus, -i, m. L.: a bony prominence (malleus: hammer)

malleolus lateralis: the distal end of the fibula, which forms the lateral malleolus of the ankle

malleolus medialis: the distal end of the tibia, which forms the medial malleolus of the ankle

malleus, -i, m. L.: hammer, club; the auditory ossicle, which is attached laterally to the tympanic membrane and articulates medially with the incus

Malpighi's capsule: s. Bowman's capsule

Malpighi's corpuscles: 1. the lymph-follicles of the spleen; 2. the renal corpuscles at the commencement of the renal tubules. They consist of the tuft of capillary vessels invaginating the glomerular capsule

Malpighi's layer: stratum germinativum

Malpighi's pyramids: s. pyramides renales

Malpighi's rete: s. rete mirabile

Malpighi's saccules: s. alveoli pulmonum

mamilla, -ae, f. L.: papilla mammae: the nipple

mamillaris, -e: mamillary; pertaining to, or like a nipple

corpus mamillare: either one of the two small pea-shaped mamillary bodies of the hypothalamus, lying in front of the posterior perforated substance and behind the infundibulum. They receive fibres from the fornix and project to the anterior thalamic nuclei

mamma, -ae, f. L.: the breast, including the mammary gland

mammae accessoriae: the occasional supernumerary mammary glands

mammarius, -a, -um: mammary; pertaining to the breast

mandibula, -ae, f. L.: the mandible or lower jaw (mandere: to chew)

mandibularis, -e: mandibular; pertaining to the mandible

labium mandibulare: labium inferius oris: the lower lip

manus, -us, f. L.: the hand

manualis, -e: manual; pertaining to the hand

manubrium, -ii, n. L.: handle

manubrium mallei: the handle or inferior process of the malleus situated on the internal surface of the tympanic membrane

manubrium sterni: the most superior component of the sternum

Manz's glands: these occur at the limbus of the conjunctiva in various animals but probably not in man

Marchand's adrenals: (glandulae suprarenales accessoriae): accessory suprarenal glands in the broad ligament

Marchand's cells: adventitial cells: cellulae peritheliales; the phagocytes in the adventitia of blood vessels

Marchi's bundle: as a result of cerebellar lesions Marchi described a cerebellospinal tract lying in the ventrolateral funiculus. Degeneration in this area, however, probably resulted from involvement of Deiters nucleus

margo, -inis, m. L.: edge, border, margin

marginalis, -e: marginal; pertaining to a margin

marginatus, -a, -um: having a margin, mound-like

Mariotte's spot: discus nervi optici: the "blind spot" or optic disk of the retina, where the optic nerve and the central retinal vessels enter

Marshall's oblique vein: vena obliqua atrii sinistri cordis; the small oblique vein running on the posterior surface of the left atrium. It is derived from the lateral part of the left common cardinal vein

Marshall's vestigial fold: ligamentum venae cavae sinistrae: the ligament of the left vena cava: the fibrous cord and its covering of serous pericardium, which connects the oblique vein of the left atrium to the left superior intercostal vein. It is the vertige of the lateral part of the left common cardinal vein in the embryo

masculinus, -a, -um, L.: masculine; pertaining to the male (mas: man)

massa, -ae, f. L.: mass

massa intermedia: adhesio interthalamica: the interthalamic adhesion: a bridge of grey matter commonly interconnecting the medial surfaces of the two thalami

masseter, -eris, m. Gr.: m. masseter; one of the muscles of mastication, which arises from the zygomatic arch and inserts into the lateral aspect of the ramus of the mandible (maseter: chewer)

massetericus, -a, -um: masseteric; pertaining to the masseter muscle

tuberositas masseterica: the masseteric tuberosity sometimes present on the outer surface of the angle of the mandible for part of the insertion of the masseter muscle

masticatorius, -a, -um, L.: masticatory; serving mastication (masticare: to chew)

facies masticatoria: the masticatory, occlusal, or chewing surface of the tooth

n. masticatorius: the motor branch of the mandibular nerve to the masticatory muscles

nucleus masticatorius: a term which has been applied to the motor nucleus of the trigeminal nerve

mastoideus, -a, -um, Gr.: mastoid; breast-shaped (mastos: the breast)

angulus mastoideus ossis parietalis: the mastoid or posterior inferior angle of the parietal bone

antrum mastoideum: the mastoid antrum, which communicates with the mastoid air-cells and with the epitympanic recess through the aditus

cellulae mastoideae: the mastoid air-cells (cavities) within the mastoid part of the temporal bone

foramen mastoideum: the mastoid foramen: the opening in the posterior part of the mastoid portion of the temporal bone, giving passage to an emissary vein from the sigmoid sinus

fossa mastoidea ossis temporalis: mastoid or supramastoid fossa: the small depression behind the suprameatal spine

incisura mastoidea ossis temporalis: the mastoid notch medial to the mastoid process

os mastoideum: the mastoid portion of the petrous part of the temporal bone

pars mastoidea ossis temporalis: the posterior mastoid part of the petrous part of the temporal bone

processus mastoideus ossis temporalis: the conical mastoid process of the temporal bone, behind and below its tympanic part

mater, -tris, f. L.: mother; in anatomy: a covering

dura mater: the outermost and most dense of the three membranes or meninges enveloping the brain and spinal cord

maternus, -a, -um: maternal; pertaining to the mother

matrix, -icis, f. L.: womb: uterus

matrix unguis: the nail bed

maturatio, -onis, f. L.: maturation

maturus, -a, -um: mature; fully developed; ripe

Mauchart's ligaments: ligamenta alaria: the two ligaments, which pass from the sides of the dens (odontoid process) of the axis vertebra to the medial aspects of the occipital condyles

Mauthner's sheath: (axolemma) it has been described as intervening between the axis cylinder and the myelin sheath of a nerve fibre

maxilla, -ae, f. L.: the bone forming the upper jaw

sinus maxillaris: maxillary sinus: antrum of Highmore; the large air-sinus within the maxilla

maxillaris, -e: maxillary; pertaining to the upper jaw

maximus, -a, -um, L.: greatest (superlative of "magnus")

Mazzoni's corpuscles: sensory nerve endings which have been described in tendons and in the subcutaneous tissue of the finger. Their form appears to be between that of Krause's end bulbs and Pacinian corpuscles

meatus, -us, m. L.: passage, channel (meare: to go)

meatus acusticus externus: the external acoustic meatus, which leads from the outer surface of the ear down to the tympanic membrane

meatus acusticus internus: the internal acoustic meatus in the petrous part of the temporal bone, which conveys the facial and vestibulocochlear nerves towards the internal ear

meatus nasi communis: the common meatus of the nose between the nasal septum and conchae

meatus nasi inf., med., sup., supremus: the inferior, middle and superior nasal meati beneath the inferior, middle and superior conchae respectively. There is often a small supreme meatus below a supreme concha

meatus nasopharyngeus: part of the nasal cavity that opens into the nasopharynx and is situated just in front of the choana

meatus urinarius: ostium urethrae externum: the external orifice of the urethra

Meckel's cartilage: the cartilage of the mandibular part of the first branchial arch in the embryo

Meckel's cavity: cavum trigeminale: the space walled by dura mater on the anterior aspect of the apex of the petrous part of the temporal bone, which encloses the trigeminal ganglion

Meckel's diverticulum: the diverticulum from the ileum about two feet from the ileocecal junction, which sometimes occurs as a congenital abnormality. It represents the persistent vitello-intestinal duct

Meckel's ganglion: ganglion pterygopalatinum; the pterygopalatine ganglion, situated in the pterygopalatine fossa. It receives preganglionic parasympathetic fibres from the greater petrosal branch of the facial nerve, and its postganglionic fibres are distributed with the neighbouring branches of the maxillary nerve

Meckel's groove: impressio trigemini: the trigeminal impression on the anterior surface of the petrous part of the temporal bone, where the trigeminal ganglion is situated

Meckel's vein: marginal or circular sinus: the large venous sinus, which was described as lying in the periphery of the placenta and draining away most of the venous blood from it. Although veins may occur in this situation their role is now held to be relatively unimportant

meconium, -ii, n. L.: the excreta of the bowel of a new-born infant

medialis, -e, L.: medial: situated closer to the median line of the body, denoting direction (opposite to lateral)

mediastinum, -i, n. L.: a septum in the middle, hence the central segment of the thoracic cavity between the pleural cavities

mediastinum anterius: the anterior mediastinum; part of the mediastinum, which lies between the pleural cavities in front of the pericardium

mediastinum cerebelli: s. falx cerebelli

mediastinum cerebri: s. falx cerebri

mediastinum posterius: the posterior mediastinum; the part of the mediastinum which lies between the pleural cavities posterior to the pericardium

mediastinum superius: the superior mediastinum, which lies between the pleural cavities above the plane passing between the 4th and 5th thoracic vertebrae and the manubriosternal joint

mediastinum testis: body of Highmore: the fibrous tissue-mass of the posterior aspect of the testis, which is continuous with the tunica albuginea and contains the rete testis

mediastinalis, -e: mediastinal; pertaining to the mediastinum

medius, -a, -um, L.: middle

medianus, -a, -um: median; situated in the midline (medium, -ii: the middle of an object)

n. medianus: median nerve: a large nerve arising from the medial and lateral fasciculi of the brachial plexus, supplying muscular and cutaneous branches to the arm and forearm

medulla, -ae, f. L.: marrow: the inmost part of a structure

medulla oblongata: the caudal part of the hindbrain, continuous above with the pons and below with the spinal medulla, or spinal cord

medulla ossium: the bone marrow

medulla spinalis: the spinal cord

medullaris, -e: medullary; pertaining to the marrow, or medulla

medullatus, -a, -um: medullated; provided with, or containing a medullary substance or surrounded by a medullary sheath

Méglin's point: the point at which the greater palatine nerve emerges from the greater palatine foramen

Meibom's glands: glandulae tarsales: tarsal glands: the sebaceous Meibomian glands in the tarsi of the eyelids

Meig's capillaries: capillares cordis terminales: the capillary blood vessels supplying the myocardium

Meissner's corpuscles: Wagner's corpuscles; the tactile corpuscles found in the corium, conjunctiva, lips, etc.

Meissner's plexus: plexus submucosus: an autonomic nerve-plexus in the submucosa of the gut

membrana, -ae, f. L.: membrane

membrana abdominis: peritoneum: the serous membrane lining the abdominal cavity and covering its viscera

membrana adamantina: Nasmyth's membrane; the thin membrane which covers the enamel of the newly erupted tooth and is the remnant of the enamel organ

membrana atlantooccipitalis anterior, posterior: the anterior and posterior atlantooccipital membranes extending from the border of the foramen magnum to the anterior and posterior arches of the atlas

membrana basilaris ductus cochlearis: the basilar membrane forming the floor of the cochlear duct

membrana carnosa: tunica dartos: s. dartos

membrana choriocapillaris: s. lamina choriocapillaris

membrana decidua: decidual membrane, or decidua: the endometrium which has become hypertrophied to receive the embryo

membrana eboris: a term which has been applied to the cells lining the dental pulp

membrana fibroelastica laryngis: the fibroelastic membrane, forming part of the wall of the larynx and including the quadrangular membrane and the conus elasticus

membrana flaccida: the thin upper flaccid part of the tympanic membrane, lying between the mallear folds and the tympanic notch

membrana granulosa: the cell-layer surrounding the follicular fluid in the graafian follicle

membrana hyaloidea: membrana vitrea: the vitreous or hyaloid membrane which has been described as bounding the vitreous body. It is probably confined to the anterior part of the vitreous body being formed by a condensation of its surface layer

membrana hyothyreoidea: s. membrana thyrohyoidea

membrana interossea antibrachii: the fibrous interosseous membrane of the forearm, connecting the shafts of the radius and ulna

membrana interossea cruris: the fibrous interosseous membrane of the leg connecting the shafts of the tibia and fibula

membrana ligamentosa (Weitbrechti): s. membrana tectoria

membrana limitans externa et interna: the external and internal limiting membranes of the retina, which intervene between the rods and cones and their nuclei, and between the layer of nerve-fibres and the vitreous body respectively

membrana nictitans: the nictitating membrane or third eyelid of lower animals, which is probably represented by the semilunar conjunctival fold of the medial canthus in man

membrana obturatoria: the membrane filling in the obturator foramen

membrana propria: the delicate connective tissue layer which supports the epithelium of a mucous membrane

membrana pupillaris: the vascular membrane on the anterior surface of the pupil. It normally atrophies shortly before birth

membrana quadrangularis: the quadrangular membrane extending between the

arytenoid cartilages and the epiglottic cartilage. Its lower border is thickened to form the vestibular ligament

membrana Reissneri: membrana vestibularis: the delicate vestibular membrane separating the cochlear duct and the scala vestibuli

membrana sterni: the sternal membrane on the anterior surface of the sternum, formed by the interweaving fibres of the anterior sternocostal ligaments

membrana tectoria: 1. the broad fibrous tectorial membrane posterior to the cruciform ligament. It is continuous below with the posterior longitudinal ligament, and is attached above to the occipital bone; 2. the membrane overhanging the spiral organ of Corti: Corti's membrane

membrana thyrohyoidea: the fibroelastic thyrohyoid membrane extending between the hyoid bone and the upper margin of the thyroid cartilage

membrana tympani: the tympanic membrane which separates the external acoustic meatus from the tympanic cavity

membrana tympani secundaria: the thin membrane closing the fenestra cochleae

membrana versicolor: Fielding's membrane (s. tapetum)

membrana vestibularis: s. membrana Reissneri

membrana vitellina: the vitelline membrane; the surface layer of the cytoplasm of the ovum

membranosus, -a, -um: seu *membranaceus*, -a, -um: membranous; provided with, or having the nature of, a membrane

membrum, -i, n. L.: member, extremity, limb

meninx, -ingis, f. Gr.: one of the membranes or meninges surrounding the brain or spinal cord (meninx: skin, membrane)

meninx fibrosa: dura mater; s. durus

meninx serosa: s. arachnoidea

meninx vasculosa: pia mater: s. pius

meningicus seu meningeus, -a, -um: meningeal; pertaining to the meninx

meniscus, -i, m. Gr.: small half-moon or crescent (mene: moon; meniskos: small moon) in anatomy: the crescentic intraarticular cartilages of the knee joint

mens, -tis, f. L.: intellect, mind

menstruatio, -nis, f. L.: menstruation; the cyclic uterine bleeding occurring at about monthly intervals (mensis: month)

mentum, -i, n. L.: chin

mentalis, -e: mental; pertaining to 1. the chin; 2. the mind

spina mentalis: spina mandibularis: the upper and lower mental spines on the inner surface of the mandible on either side of the midline. They give attachment to genioglossus and geniohyoid muscles

tuberculum mentale: mental tubercle: the prominence of the chin

trigonum mentale: trigonum mandibulae: the triangular mental protuberance of the mandible corresponding to the chin

Mercier's bar: plica interureterica

Merkel's corpuscles: tactile corpuscles in the deep layer of the epidermis

Merkel's muscle: m. ceratocricoideus

merulatio, -nis, f. L.: bipartite (meros: part)

Méry's glands: glandulae bulbourethrales: s. Cowper's glands

mesaraicus, -a, -um, L.: mesaraic; mesenteric; pertaining to the mesentery (messarion, Gr.: mesentery)

mesencephalon, -i, n. Gr.: midbrain

mesenchyma, -tis, f. Gr.: the mesenchyme, or non-epithelial cells of the embryo between the ecto- and entoderm, from which are formed the vascular and lymphoid tissues, the smooth muscle and myocardium (mesos: middle; enkleo: to pour in)

mesenteriolum, -i, n. L.: small mesentery; e.g. mesoappendix

mesenterium, -ii, n. L.: mesentery (mesenterion, Gr.: mesentery)

radix mesenterii: the root of the mesentery. The attachment of the mesentery of the small intestine to the posterior abdominal wall

mesenterialis, -e; *mesentericus,* -a, -um: mesenteric; pertaining to the mesentery

meso-, Gr.: middle, intermediate (a prefix used only in combination)

mesoappendix, -cis, f.: mesenteriolum; mesentery of the appendix: the small, double-layered fold of peritoneum, which passes from the appendix to the mesentery of the ileum

mesoblast: mesoderm: the middle of the three germ layers

mesocaecum, -i, m.: the occasional mesentery of the cecum

mesocolon transversum: transverse mesocolon: the layers of peritoneum, which connect the transverse colon to the posterior abdominal wall and form part of the inferoposterior wall of the lesser sac

mesoderma, -atis, n.: mesoderm: s. mesoblast

mesogastrium, -ii, n.: the dorsal and ventral mesogastria, which in the embryo connect the stomach to the posterior abdominal wall and liver respectively

mesometrium, -ii, n.: the part of the broad ligament below the mesosalpinx and lateral to the uterus

mesonephros, -i, m.: the intermediate kidney of the human embryo, which is associated with the development of the gonads

mesorchium, -ii, n.: the mesentery, which attaches the testis to the mesonephros at a certain stage in the embryo

mesorectum, -i, n.: the short peritoneal fold of the rectum

mesosalpinx, -gis, f.: the part of the broad ligament, which lies between the uterine tube, the ovary and round ligament of the ovary

mesotenon, -ontis, m.: the line of reflection of the parietal, onto the visceral layer of the tendon sheath. It affords passage to vessels and nerves to the tendon

mesovarium, -ii, n.: the peritoneal attachment of the ovary to the posterosuperior surface of the broad ligament

meta-, Gr.: in combination a prefix denoting with, after

metacarpus, -i, m.: the part of the hand between the carpus and the fingers

metacarpalis, -e: metacarpal: pertaining to the metacarpus

metacarpophalangealis, -e: metacarpophalangeal: pertaining to the metacarpus and phalanges

metaphysis, -is, m.: the part of the shaft of a long bone adjacent to the epiphysis

metatarsus, -i, m.: the part of the foot between the tarsus and the toes

metatarsalis, -e: metatarsal: pertaining to the metatarsus

metatarsophalangealis, -e: metatarsophalangeal: pertaining to the metatarsus and phalanges

metathalamus: the part of the thalamencephalon which includes the medial and lateral geniculate bodies

metencephalon, -i, n.: the cephalic part of the hindbrain which includes the pons and cerebellum

Meyer's sinus: the small depression on the floor of the external acoustic meatus in front of the tympanic membrane

Meynert's bundle: fasciculus retroflexus

Meynert's commissure: the term usually refers to the ventral supraoptic commissure, but may be taken to include part of the dorsal one as well

Meynert's decussation: s. decussatio tegmentalis dorsalis

Michaelis' rhomboid: the rhomboid shaped depression in the female which is bounded by lines joining the 5th lumbar spinous process to the dimples over the posterior superior iliac spines, and by lines joining the latter to the point at which the medial borders of the gluteus maximus muscles are approximated

micro-, Gr.: a prefix denoting small

microglia, -ae, f.: neuroglial cells of the central nervous system which are derived from mesoderm in the embryo. They are potentially phagocytic

minimus, -a, -um, L.: smallest, least (superlative of "parvus")

digitus minimus: the 5th or little finger of the hand, the 5th toe of the foot

minor, minus, L.: smaller, lesser (comparative of "parvus")

mirabilis, -e, L.: wonderful (mirare: to wonder at)

rete mirabile: the splitting of an artery into small branches, which then unite again to form a single vessel. An example of this in man is the renal glomeru-lus

mitosis, -is, f. Gr.: the division of a nucleus into two. During the process each chromosome splits into two and one member of each pair, thus formed, goes to one of the daughter nuclei

mitralis, -e, n. L.: mitral; shaped like a mitre, hence a bicuspid valve (mitra, Gr.: turban)

valvula mitralis: valvula atrioventricularis sinistra: the left atrioventricular or mitral valve

mobilis, -e, L.: mobile (movere: to move)

modiolus, -i, m. L.: measure of corni borer or trepan; in anatomy: the central bony axis of the cochlea

modulatio, -nis, f. L.: modulation, e.g. of the tone of the voice

Mohrenheim's fossa: fossa infraclavicularis: the infraclavicular fossa between the deltoid and pectoralis major muscles

molaris, -e, L.: molar; grinder (mola: mill)

dentes molares: the molar teeth. There are two deciduous and three permanent ones on each side of the upper and lower jaws

Moll's glands: glandulae ciliares: the ciliary glands: modified sweat glands of the eyelids, which open near the roots of the eyelashes

Monakow's bundle: tractus rubrospinalis: the rubrospinal tract, which arises from the red nucleus, decussates in the ventral tegmental decussation and passes in the lateral funiculus of the spinal cord to end in relation to cells of the anterior grey column

monos, Gr.: a prefix denoting sole, single

monaster: the star-shaped equatorial arrangement of chromosomes on the spindle in the metaphase of mitosis

monocyta: monocyte; relatively large mononuclear agranular leukocytes which constitute about 6% of the white cells of the blood

Monro's foramen: foramen interventriculare: the interventricular foramen connecting the 3rd and lateral ventricles

Monro's gland: pars palpebralis glandulae lacrimalis: the palpebral part of the lacrimal gland, which extends into the lateral part of the upper eyelid

Monro's groove: sulcus hypothalamicus: the shallow hypothalamic sulcus on the lateral wall of the 3rd ventricle extending from the interventricular foramen to the cerebral aqueduct of the midbrain

mons, -tis, m. L.: mountain, eminence

mons pubis: mons veneris: an eminence due to a deposit of fat above the symphysis pubis of sexually mature women

mons ureteris: the slight eminence at the entrance of the ureter into the bladder

Montgomery's glands: glandulae areolares mammae: areolar glands of the breast: modified sweat glands, situated beneath the areola

monticulus, -i, m. L.: a small hill or eminence

Morand's foramen: the foramen caecum which is situated in the anterior cranial fossa, between the crista galli and frontal crest. It usually ends blindly, but may be patent and transmit a small vein from the nose

Morgagni's appendix: s. appendix testis

Morgagni's columns: s. columnae Morgagni

Morgagni's concha: s. concha nasalis sup.

Morgagni's foramen: foramen caecum linguae: the small pit situated in the midline of the upper surface of the tongue at the apex of the V-shaped sulcus terminalis, separating the anterior two thirds from the posterior third. It marks the original site of down-growth of the thyroglossal duct

Morgagni's lacunae: s. lacunae urethrales

Morgagni's pouch: ventriculus laryngis (Morgagni): s. ventriculus laryngis

Morgagni's sinuses: sinus anales; the longitudinal grooves situated between the anal columns of Morgagni

Morgagni's spheres or tubercles: s. bulbus olfactorius

motoricus seu motorius, -a, -um, L.: motor: subserving movement (movere: to move)

radix motoricus: radix anterius: the anterior or ventral motor roots of the spinal nerves

mucus, -i, m. L.: the slimy viscous liquid secreted by mucous membranes. It owes its characteristic physical properties to the presence of mucopolysaccharides

mucosus, -a, -um: mucous, pertaining to mucus

stratum mucosum: a term which has been used to refer to the stratum germinativum of the skin

mulier, -eris, f. L.: woman

muliebris, -e: pertaining to a woman, or the female sex

organa genitalia muliebria: muliebria; the female reproductive organs

Müller's capsule: s. Bowman's capsule, capsula glomeruli

Müller's ducts: the paramesonephric ducts of the embryo, which give rise to the uterine tubes, uterus and most of the vagina. Their vestige in the male forms the appendix of the testis and perhaps the prostatic utricle

Müller's ganglion: s. ganglion superius nervi glossopharyngei

Müller's muscle: 1. fibrae circulares musculi ciliaris the circular fibres of the ciliary muscle; 2. m. orbitalis: the smooth muscle extending above the inferior orbital fissure

multangulus, -a, -um, L.: multangular; provided with many angles (multus: many; angulus: angle)

os multangulum majus et minus: the trapezium and trapezoid bones of the carpus respectively

multifidus, -a, -um, L.: multifid; cleft into many, or subdivided into many parts (findere: to split)

multiplex, -icis, L.: multiple; manifold

musculus, -i, m. L.: muscle (little mouse; mus, L.: mouse)

musculus tensor chorioideae: a term which has been applied to the meridional fibres of the ciliary muscle

muscularis, -e: muscular

muscularis mucosae: the outermost smooth-muscle layer of the mucous membrane of the gut

myel-, Gr.: in combination denoting relationship to marrow or to brain or spinal medulla (myelos: marrow)

myelencephalon, -i, n.: the caudal part of the hindbrain, the medulla oblongata

myelin: the fatty sheath surrounding the axon of medullated nerve fibres

myentericus, -a, -um: myenteric; pertaining to the muscle of the intestine (mys, Gr.: mouse, muscle; enteron: gut)

myo-, Gr.: in combination denoting relationship to muscle

myocardium, -ii, n.: the heart muscle
myofibrillum, -i, n.: myofibril; the contractile fibrils of muscle
myolemma: sarcolemma: the membrane bounding the striated muscle fibre
myologia: myology; the anatomy of muscles
myometrium, -ii, n.: the muscular coat of the uterus (metra: uterus)

N

n.: abbreviation for nervus: nerve
Naboth's glands: the mucous glands of the uterine cervix. These may give rise to Naboth's retention cysts
Nägele's pelvis: a contracted deformation of the pelvis due to defective development of one of the alae
naevus, -i, m. L.: a birthmark
nanismus, -i, m.: nanism; dwarfishness (nanos: dwarf)
naris, -is, f. L.: the anterior aperture of the nasal cavity; the nostril
Nasmyth's membrane: cuticula dentis
nasus, -i, m. L.: nose
nasalis, -e: pertaining to the nose
nates, -ium, f. L. pl.: the buttocks
nativus, -a, -um, L.: native, normal
naturalis, -e, L.: natural
Naunyn's centre: the reading centre in the left angular gyrus where lesions cause inability to understand written or printed words
navicular, -e, L.: navicular; boat-shaped (navicula: boat)
fossa navicularis: navicular fossa: the terminal dilated part of the male urethra within the glans penis
os naviculare: the bone of the tarsus, which lies distal to the talus. Former name of scaphoid of carpus
nebula, -ae, f. L.: fog, mist
necro- Gr.: in combination pertaining to death (necros: dead, the cadaver)
necrosis, -is, f.: the death of living tissue
Nélaton's line: a line joining the anterior superior iliac spine and the ischial tuberosity
Nélaton's sphincter: an inconstant circular band of muscle in the ampulla of the rectum
neo-, Gr.: in combination meaning new, young (neos: new, young)
neocerebellum, -i, n.: the part of the cerebellum which, in the course of phylogeny, developed latest. The term usually refers to the middle lobe, but is sometimes taken to include the whole of the hemispheres except the flocculi
neocytosis, -is, f.: the appearance of immature leukocytes in the blood
neoformatio, -onis, f.: neoformation; new growth

neonatus, -a, -um: neonate; newborn

nephron: the developmental and functional unit of the kidney, consisting of a renal corpuscle and straight and convoluted tubules

nephros, Gr.: in combination denoting relationship to the kidney

nervus, -i, m. L.: nerve; originally applied to fibrous or string-like structures, e.g. tendon

Neubauer's artery: a. thyroidea ima: an inconstant artery to the thyroid gland, which usually arises from the brachiocephalic trunk

Neumann's cells: the nucleated red cells of the bone marrow, which develop into erythrocytes

neuron, Gr.: the functional cellular unit of the nervous system; originally the term indicated a tendon, or string-like structure

neurilemma or neurolemma: a term applied to the membrane which is to be seen with light microscopy to surround the myelin sheath of peripheral nerves. It is the outermost part of the cell membranes of the Schwann cell as seen with the electron microscope

neurit, neurite: former term for the axon of a nerve-cell

neuroblast: the immature cell which develops into the neurone

neurocyta: neurocyte; the mature nerve-cell or neurone

neuroepithelium: sensory epithelium, such as that subserving olfaction or taste, or that occurring in the cochlear duct or the ampullae of the semicircular ducts

neurofibrillum: the extremely fine fibrils in the nerve-cells and their processes

neuroglia: the supporting cells of the central nervous system including astrocytes, oligodendrocytes and microglia

neutralis, -e, L.: neutral, chemically indifferent (neuter: neither of two)

neutrophil: stainable by neutral dyes

nidatio, -onis, f. L.: nidation: the implantation of the fertilized ovum in the endometrium of the uterus

nidus, -us, m. L.: nest

nidus avis: nidus hirundinis: the depression on the cerebellum, which accommodates the tonsil

nidus lienis: the nest or bed of the spleen, being formed by part of the phrenicocolic ligament

nidus tonsillaris: s. fossulae tonsillares

niger, -a, -um, L.: black, dark

Nissl's bodies: tigroid bodies; the clumps of basophilic material which are found in the cytoplasm of nerve-cells. They have a high ribonucleic acid content

nodulus, -i, m. L.: nodule

noduli lymphatici: lymphatic nodules consisting of closely packed lymphocytes. The centre may consist of larger lymphocytes or lymphoblasts forming the germinal centre

noduli lymphatici aggregati: s. Peyer's patches

noduli lymphatici lienales (Malpighii): lymphatic nodules or malpighian corpuscles of the spleen

noduli lymphatici solitarii: solitary lymphatic nodules of small size which occur in the mucosa of the intestines

noduli valvularum semilunarium (Arantii): corpora Arantii: the nodules found on the middle of the free edge of the semilunar valvules of the pulmonary and aortic valves

nodulus vermis: the nodule or most caudal part of the vermis of the cerebellum, which connects the flocculi of either side

nodus, -i, m. L.: node

nodi aggregati processus vermiformis: the lymphatic nodules of the mucosa of the vermiform appendix

nodus atrioventricularis: s. Aschoff–Tawara's node

nodus caroticum: s. glomus caroticum

nodus cerebri: s. pons

nodus cordis: s. trigona fibrosa

nodus cursorius: a term which has been applied to the anterior part of the caudate nucleus, where lesions can cause compulsive movements

nodus lymphaticus tubarius: s. tonsilla tubaria

nodus sinuatrialis: s. Keith and Flack's node

nodosus, -a, -um: nodose; having nodes

nomen, -inis, n. L.: name

nomenclatura, -ae, f.: nomenclature; terminology; the system of specific terms, used in any field of science

anatomical nomenclature: nomina anatomica: the official lists of anatomical terms compiled at Basle (1895), Jena (1935) and Paris (1955) and modified in New York (1960) and Wiesbaden (1965)

normalis, -e, L.: normal, regular (norma: rule)

normoblast: the stage in the development of the erythrocyte, when the nucleus is darkly staining and pyknotic and the cytoplasm acidophilic

normocyta: an erythrocyte of normal morphology and staining reactions

nubecula, -ae, f. L.: small cloud (nubes: cloud)

nucha, -ae, f.: the back or nape of the neck (a word of Arab origin)

nuchalis, -e: nuchal; pertaining to the nucha

planum nuchale: the plane of the inferior surface of the squamous part of the occipital bone below the superior nuchal line

Nuck's canal: that part of the processus vaginalis peritonei in the female which extends into the inguinal canal. It is normally obliterated but may persist as a diverticulum which can give passage to an oblique inguinal hernia

nucleus, -i, m. L.: the central part of a structure; the centre of a cell which contains the chromosomes and is surrounded by the nuclear membrane (originally kernel of nut) (nux: nut)

nucleus pulposus: the central softer gelatinous part of the intervertebral disk, which becomes fibrocartilaginous in old age

nuc earis, -e: nuclear; pertaining to a nucleus

nucleolus, -i, m.: a small body within the nucleus, which contains ribonucleic acid

Nuel's space: the space between the outer rods of Corti and the innermost of the outer hair-cells of the spiral organ

Nuhn's glands: Blandin and Nuhn's glands: glandulae linguales anteriores: the mixed mucous and serous apical anterior lingual glands which extend between the muscles lying on either side of the frenulum

Nussbaum's cells: the granular cells of the pyloric glands of the stomach which are especially darkened by osmic acid

nutricius, -a, -um, L.: nutrient; nourishing (nutrix: wet nurse)

canalis nutricius: the canal entering a bone to give passage to its nutrient artery

nympha, -ae, f. Gr.: nymph; in anatomy: the labia minora of the female pudendum

O

O'Beirne's sphincter: a thickening of the circular muscle of the uppermost part of the rectum, which has been described as forming a sphincter

obelion, Gr.: the sagittal point where the sagittal suture crosses the line, joining the two parietal foramina

obex, -icis, m. L.: bolt, barrier; the small triangular lamina at the caudal end of the roof of the 4th ventricle where the two taeniae come together

objectus, -a, -um, L.: objective; the lens complex of the microscope nearest the object to be viewed

obliquus, -a, -um, L.: oblique

linea obliqua: the oblique line on the lateral aspect of the lamina of the thyroid cartilage

m. obliquus abdominis externus: the external oblique muscle of the abdomen, which forms the outermost layer of its muscular wall

m. obliquus abdominis internus: the internal oblique muscle of the abdomen, which forms the intermediate layer of its muscular wall

obliteratio, -onis, f. L.: obliteration

oblongus, oblongatus, -a, -um, L.: oblong, of elongated form

medulla oblongata: the part of the hindbrain situated between the pons and the spinal cord

obturator, -oris, L.: obturatorius, -a, -um: closing (obturare: to stop up, or close)

m. obturator externus et internus: the two muscles arising from the outer and inner aspects of the obturator membrane respectively and inserting into the trochanteric fossa and greater trochanter of the femur

obturatorium, -ii, n. L.: cover, stopper

canalis obturatorius: the obturator canal, between the freean terosuperior edge of the obturator membrane and the margin of the obturator foramen. It gives passage to the obturator nerves and vessels

foramen obturatorium: the obturator foramen, which is bounded by the bodies and rami of the ischium and pubis

membrana obturatoria: the obturator membrane, which is attached to the margins of, and closes the obturator foramen except for the obturator canal

n. obturatorius: the obturator nerve which arises from the 2nd, 3rd, 4th lumbar segments of the spinal cord and passes through the obturator canal to supply mainly the adductor muscles of the thigh

obturatus, -a, -um: closed

obtusus, -a, -um, L.: obtuse, blunt

occiput, -itis, n. L.: the back part of the head (ob: opposite; caput: the head)

occipitalis, -e: occipital; pertaining to the occiput

planum occipitale: the plane of the squamous part of the occipital bone above the superior nuchal line

Ochsner's ring: a circular fold of mucous membrane, which has been described as narrowing of the pancreatic duct at its entrance to the hepatopancreatic ampulla

ocular: the lenses of the microscope nearest to the eye of the observer

oculus, -i, m. L.: eye

ocularis, -e: ocular: pertaining to the eye

oculomotor: concerning movements of the eye (motor: mover)

oculomotorius, -a, -um, L.: 1. n. oculomotorius: the oculomotor or 3rd cranial nerve; 2. pertaining to the oculomotor nerve (motorius: mover, neologism)

Oddi's sphincter: the sphincteric ring of circular muscle surrounding the termination of the bile duct and the hepatopancreatic ampulla

odontoblast, Gr.: the cell associated with the formation of dentine and lining the pulp cavity of the tooth (odonto: tooth; blastos: germ)

odor, -is, m. L.: smell, odour

Oehl's layer: stratum lucidum: the thin, clear layer between the stratum granulosum and the stratum corneum of the epidermis

oesophagus, -i, m. Gr.: the esophagus or gullet which extends from the pharynx to the cardiac opening of the stomach (ois: carry; phagein: to eat)

oesophageus, -a, -um: esophageal: pertaining to the esophagus

oestrus, -i, m. Gr.: estrus: the phase of the sexual cycle of many mammals when the female will receive the male (oestrus: gadfly; hence vehement sexual impulse)

olecranon, -i, n. Gr.: the curved proximal part of the ulna, which articulates with the trochlea of the humerus (olené: elbow; kranion: head)

olfactorius, -a, -um, L.: olfactory; subserving the sense of smell (olfacere: to smell)

area olfactoria: 1. the olfactory area of the cerebral cortex including the uncus

and adjacent part of parahippocampal gyrus and amygdala and anterior perforated substance; 2. the olfactory epithelium in the mucous membrane of the nose

bulbus olfactorius: the anterior expanded termination of the olfactory tract, where the olfactory nerve fibres end

glomerulus olfactorius: olfactory glomerulus: the complex synapse between the axons of the olfactory nerves and the dendrites of the mitral cells in the olfactory bulb

lobus olfactorius: see under lobus

nn. olfactorii: the olfactory nerves; the first cranial nerves

striae olfactoriae: the medial and lateral olfactory striae, which are formed by the proximal bifurcation of the olfactory tract. They enclose between them the olfactory tubercle and they project to the olfactory area

sulcus olfactorius: the olfactory sulcus on the inferior aspect of the frontal lobe, which forms the lateral boundary of the gyrus rectus and is occupied by the olfactory tract

tractus olfactorius: the olfactory tract situated in the olfactory sulcus. It starts at the olfactory bulb and terminates as the olfactory striae

trigonum olfactorium: olfactory trigone: the thickened proximal end of the olfactory tract anterior to the anterior perforated substance and bounded by the medial and lateral olfactory striae

oligodendroglia, -ae, f. Gr.: neuroglial cells of the central nervous system with few, and small processes. They are concerned with the formation of myelin in the central nervous system (oligo: few; dendron: tree; glia: glue)

oliva, -ae, f. L.: olive; the oval elevation of the medulla oblongata between the pyramid and the inferior cerebellar peduncle, i.e. corpus restiforme. It is caused by the olivary nucleus

olivaris, -e: olivary: pertaining to the olive

omentum, -i, n. L.: double layers of peritoneum which may contain considerable quantities of fat and connect various viscera with each other, or with the abdominal wall (probably originating from operimentum: a cover)

omentum lienale: lig. gastrolienale: gastrosplenic ligament: the part of the greater omentum, extending from the greater curvature of the stomach to the hilus of the spleen

omentum majus: greater omentum: the apron-like fold of peritoneum which passes downwards from the greater curvature of the stomach and encloses the transverse colon

omentum minus: the lesser omentum, which extends from the fissure of the ligamentum teres to the lesser curvature of the stomach

omentalis, -e, m.: omental; pertaining to the omentum

omo-, Gr.: in combination denotes relationship to the shoulder (omos: shoulder)

m. omohyoideus: the omohyoid muscle, whose inferior and superior bellies are

attached respectively to the superior border of the scapula and the superior transverse scapular ligament and to the hyoid bone

ontogenesis, -is, f. Gr.: ontogeny; the development and growth of an individual (ont-: existing)

onyx, onychos, m. Gr.: nail (of a finger or a toe)

oogenesis, -is, f. Gr.: the growth and differentiation of the ovum (oon: egg)

oogonium, -i, n. Gr.: the primordial germ-cell containing the diploid number of chromosomes. It gives rise to the primary oocyte (gonein: to generate)

oolemma, -tis, n. Gr.: s. zona pellucida (lemma: sheath)

oophoron, -i, n. Gr.: ovary (ferein: to bear)

opalescens, -entis, m. L.: opalescent; semi-transparent, opal-like (opallios, Gr.: opal)

operculum, -i, n. L.: a cover (operire: to cover) in anatomy: the parts of the cerebrum, which overhang and cover the insula

opercularis, -e: opercular; pertaining to the operculum

ophthalmicus, -a, -um, Gr.: ophthalmic; pertaining to the eye

a. ophthalmica: the ophthalmic artery, which arises from the internal carotid artery and supplies the eyeball and other structures in the orbit

n. ophthalmicus: the ophthalmic or first division of the trigeminal nerve

opponens, -entis, L.: opposing (opponere: to oppose)

oppositio, -onis, f. L.: opposition, resistance; in anatomy: the movement by which the thumb is opposed to the other fingers

opticus, -a, -um, Gr : optic, optical; pertaining to sight

n. opticus: the optic or second cranial nerve

ora, -ae, f. L.: border, boundary

ora serrata: the serrated anterior boundary of the optic part of the retina, which then continues forward as the ciliary part

oralis, -e, L.: oral; pertaining to the mouth (os, oris: mouth)

orbiculus, -i, m. L.: small wheel, circle or ring (orbis: circle)

orbicularis, -e: orbicular, circular

m. orbicularis oculi: the oval muscle surrounding and occupying the eyelids. It consists of palpebral, orbital and lacrimal parts

m. orbicularis oris: the circular muscle occupying the lips and surrounding the opening of the mouth

orbiculus ciliaris: annulus ciliaris: ciliary ring: the part of the ciliary body lying between the ora serrata and the posterior ends of the ciliary processes

orbita, -ae, f. L.: the orbit

orbitalis, -e: orbital; pertaining to the orbit

orchis, -is, m. Gr.: testis

organum, -i, n. L.: structure, organ

organa genitalia: genital or reproductive organs

organum gustus: organ of taste

organa oculi accessoria: the accessory organs of the eye, including the eyelids, muscles, conjunctiva and lacrimal apparatus
organum olfactus: organ of smell
organum spirale: s. Corti's organ
organum tactus: organ of touch
organa uropoetica: the uropoetic organs including the kidney, ureter and bladder
organum vestibulocochleare: the ear, or organ of hearing
organum visus: the organ of sight, including the eye
organum vomeronasale: s. Jacobson's organ
organismus, -i, m.: organism; the living body as a structural and functional unit
orificium, -ii, n. L.: orifice, opening (os, oris: mouth; facere: to make)
orificium externum uteri: ostium uteri: the external orifice of the cervix of the uterus, which opens into the vagina (the external os of the uterus)
orificium internum uteri: a term formerly used to indicate an internal orifice of the cervix uteri opening into the cavity of the uterus. It has been made redundant by the introduction of the term isthmus uteri (the internal os of the uterus)
orificium ureteris: ostium ureteris: the opening of the ureter into the bladder
orificium urethrae ext.: ostium urethrae ext.: the external opening of the urethra in the male or female
orificium urethrae int.: ostium urethrae int.: the internal opening of the urethra at the apex of the trigone of the bladder
orificium vaginae: ostium vaginae: the orifice of the vagina
origo, -inis, f. L.: origin; beginning (oriri: originate)
os, oris, n. L.: mouth; orifice
os, ossis, n. L.: bone
osseus, -a, -um: osseous; bony
ossificatio, -nis, f. L.: ossification: formation of bone
ossificatio enchondralis: enchondral ossification, where the bone is initially formed of cartilage, which is subsequently replaced by bone
ossificatio endesmalis: intramembranous ossification, where bone is formed initially without a cartilaginous precursor
ossificatio perichondralis: perichondral ossification occurring around, or on the surface of a piece of cartilage
ossiculum, -i, m.: ossicle; a small bone
ossicula auditus: ossicula tympani: the auditory ossicles, including the malleus, incus and stapes
osteoblast, Gr.: the cell concerned with the formation of bone (osteon: bone; blastos: germ, bud)
osteoclast, Gr.: the cell concerned with the resorption of bone (klast: to break)
osteocranium, Gr.: the bony skull
osteologia: osteology; the study of bones
osteoid: resembling bone

osteon, -i, n.: Haversian system: the cylindrical unit of bone, consisting of a central vascular canal surrounded by bony lamellae with lacunae containing osteocytes

ostium, -ii, n. L.: opening, orifice

ostium abdominale tubae uterinae: the abdominal opening of the uterine tube

ostium arteriosum dextrum cordis: ostium trunci pulmonalis: the opening from the heart into the pulmonary trunk

ostium arteriosum sinistrum cordis: ostium aortae: the aortic opening from the left ventricle into the aorta

ostium atrioventriculare dextrum et sinistrum: the right and left atrioventricular openings

ostium ileocolicum: the ileocolic opening of the ileum into the colon

ostium pharyngeum tubae auditivae: the pharyngeal opening of the auditory or eustachian tube

ostium tympanicum tubae auditivae: the opening of the auditory or eustachian tube into the tympanic cavity of the middle-ear

ostium uterinum tubae: the opening of the uterine tube into the cavity of the uterus

ostium vaginae: the external orifice of the vagina

ostium venosum: s. ostium atrioventriculare

oticus, -a, -um, Gr.: otic; pertaining to the ear (ous, Gr.: the ear)

otolith: statoconia: small calcium carbonate crystals lying in the statoconial membrane, which is situated on the maculae of the saccule and utricle of the internal ear (lithos : stone)

ovalis, -e, L.: oval; egg-shaped

ovarium, -ii, n. L.: the ovary

ovarialis, -e: *ovaricus*, -a, -um: ovarian; pertaining to the ovary

oviductus, -us, m. L.: uterine or fallopian tube (oviduct)

ovulatio, -nis, f. L.: ovulation, the monthly discharge of an ovum from a vesicular ovarian follicle (graafian follicle)

ovum, -i, n. L.: egg; the female germ-cell

ovulum, -i, n. L.: ovum, small egg

P

Pacchioni's foramen: s. incisura tentorii

Pacchioni's foveolae: s. foveolae granulares

Pacchioni's granulations: s. granulationes arachnoideales

pachymeninx, -gis, f. Gr.: the dura mater (pakhys: hard)

Pacini's corpuscles: s. Vater–Pacini's corpuscles

palatum, -i, n. L.: palate

palatum durum: the hard or anterior part of the palate, formed by the palatine processes of the maxillae and the horizontal plates of the palatine bones

palatum molle: the soft or posterior part of the palate

palatinus, -a, -um: palatine; pertaining to the palate

arcus palatini: the palatine arch including the palatoglossal and palatopharyngeal arches

pallidus, -a, -um, L.: pale

globus pallidus: the medial component of the lentiform nucleus. It lies lateral to the internal capsule and medial to the putamen, and is one of the nuclei of the extrapyramidal system

pallium, -ii, f. L.: cloak; in anatomy: the cerebral cortex

palma, -ae, f. L.: palm; in anatomy: the palm of the hand

palmaris, -e, L.: palmar; pertaining to the palm

arcus palmaris profundus: the deep palmar arch, formed by the junction of the terminal part of the radial with the deep palmar branch of the ulnar artery

arcus palmaris superficialis: the superficial palmar arch, formed by the junction of the terminal part of the ulnar with the superficial palmar branch of the radial artery

m. palmaris brevis: a superficial muscle in the hypothenar eminence, which helps to maintain the form of the latter during gripping

m. palmaris longus: a slender inconstant superficial muscle of the forearm, arising from the common flexor origin of the humerus and inserting into the palmar aponeurosis

palmatus, -a, -um, L.: palmate: palm-shaped

plicae palmatae: palm-like mucosal folds of the anterior and posterior walls of the canal of the uterine cervix

palpebra, -ae, f. L.: eyelid

palpebra inferior: the lower eyelid

palpebra superior: the upper eyelid

palpebra tertia: s. membrana nictitans

palpebralis, -e, L.: palpebral; pertaining to the eyelid

pampiniformis, -e, L.: pampiniform; of tangled shape, like vine tendrils (pampinus: vine tendril)

plexus pampiniformis: the pampiniform venous plexus of the spermatic cord, which drains the testis and continues as the testicular vein

pancreas, -atis, n. Gr.: a gland, situated on the posterior abdominal wall behind the stomach, which consists of endocrine islets of Langerhans producing insulin and exocrine cells producing various digestive enzymes, which pass by the pancreatic duct into the duodenum

pancreas accessorium: small amounts of accessory pancreatic tissue, which may occur in the wall of the stomach, duodenum or jejunum

pancreas or glands of Aselli: an assemblage of mesenteric lymph nodes below the pancreas of the dog

pancreas minus: pancreas Winslowi: the uncinate process when, as occasionally occurs, this is separate from the rest of the pancreas

pancreaticus, -a, -um: pancreatic; pertaining to the pancreas

ductus pancreaticus: the pancreatic or main excretory duct of the pancreas, which unites with the bile duct before entering the second part of the duodenum

ductus pancreaticus accessorius: the accessory pancreatic duct, which usually drains part of the head of the pancreas and opens into the duodenum about 2 cm above the opening of the hepatopancreatic ampulla

Paneth's cells: the cells at the base of the crypts of Lieberkühn, which are characterized by the presence of eosinophilic granules in their cytoplasm

panniculus, -i, m. L.: a piece of cloth (pannus: cloth)

panniculus adiposus: the fat-containing superficial fascia

papilla, -ae, f. L.: nipple-shaped structure (papilla, L.: nipple)

papilla acustica: s. Corti's organ

papilla dentis: dental papilla: the mesoderm which invaginates the enamel organ of the developing tooth, and whose odontoblasts lay down dentine

papilla duodeni major (Santorini seu Vateri): duodenal papilla: the greater papilla projects slightly into the cavity of the descending part of the duodenum and is the opening of the hepatopancreatic ampulla. The lesser papilla is the usual opening of the accessory pancreatic duct and lies about 2 cm above the greater ampulla

papillae filiformes: the conical filiform papillae which are scattered over the dorsal surface of the anterior two thirds of the tongue

papillae fungiformes: the fungiform papillae, which have expanded tops and occur scattered on the dorsal surface of the anterior two thirds of the tongue, especially at the tip. They contain taste-buds

papilla incisiva: the small incisive papilla behind the upper median incisor teeth at the anterior end of the palatine raphe. It covers the incisive fossa

papillae lacrimales: the small lacrimal papillae at the median end of the edge of each eyelid. The punctum lacrimale occurs on its summit

papillae lenticulares: lenticular papillae: a term which has been applied to the smaller type of fungiform papillae of the dorsum of the tongue

papillae linguales: the common term applied to the different types of papillae (fungiform, filiform, vallate) on the dorsal surface of the tongue

papilla mammae: the nipple

papilla nervi optici: discus nervi optici: the optic disk: the site at which the optic nerve enters the retina

papilla palatina: s. papilla incisiva

papilla pili: the hair papilla of vascular corium, which invaginates the bulb of the hair

papilla renalis: renal papilla: the apex of a renal pyramid, which projects into a minor calyx. The excretory tubules open on its surface

papilla Santorini: s. papilla duodeni

papilla urethralis: the small papilla in the vestibule of the vagina, formed by the external orifice of the urethra

papillae vallatae: vallate papillae: the large papillae of the dorsal surface of the tongue, just in front of the sulcus terminalis. Each is surrounded by a fossa and contains taste-buds

papilla Vateri: s. papilla duodeni major

papillaris, -e: papillary; pertaining to a papilla

mm. papillares: the papillary muscles of the heart, arising from the walls of the ventricles and inserting into the chordae tendineae of the cusps of the atrio-ventricular valves

para-, Gr.: in combination meaning beside

paraaquaeductus, -us, m. L.: the slightly dilated part of the cerebral aqueduct at about the level of Perlia's nucleus

paracentralis, -e: paracentral; near the centre

paradidymis, -idis, f. Gr.: organ of Giraldes: a small collection of tubules just above the head of the epididymis, which is probably derived from mesonephric tubules in the embryo

paraganglia, Gr.: the chromaffin tissue, situated in relation to sympathetic ganglia or plexuses

parahepaticus, -a, -um: parahepatic; situated beside the liver

paramastoidalis, -e: paramastoid; situated near the mastoid process

processus paramastoidalis: the paramastoid process, which sometimes projects downwards from the jugular process of the occipital bone. It may articulate with the transverse process of the atlas

paramedian: situated near the median plain

parametrium, -ii. n.: the connective tissue within the broad ligament of the uterus

paranephros, -i, m. Gr.: the suprarenal gland

paraneuralis, -e: paraneural; situated beside nervous tissue

parapancreaticus, -a, -um: parapancreatic; situated beside the pancreas

parapharyngealis, -e: parapharyngeal; situated near the pharynx

spatium parapharyngeale: a term which has been applied to the connective tissue space surrounding the wall of the pharynx

paraphysis, -is, f.: a gland-like structure in the roof of the telencephalon impar of certain lower vertebrates. In man it is a transitory embryonic structure of the roof of the 3rd ventricle just rostral to the telen-diencephalic junction

parapinealis, -e: parapineal; situated near the pineal body

paraplexus, -us, m.: the choroid plexus of the lateral ventricle

pararectalis, -e: pararectal; situated beside the rectum

parasacralis, -e: parasacral; situated near the sacrum

parasternalis, -e: parasternal; situated beside the sternum

parasympathetic nervous system: the part of the autonomic nervous system which emerges in the 3rd, 7th, 9th and 10th cranial nerves and in the 2nd, 3rd and 4th sacral nerve roots. It is antagonistic in action to the sympathetic system and has been described as being concerned with the "conservation and building up of energy". In the periphery it consists of pre- and postganglionic fibres, the latter usually being short and arising near the structure they innervate

paratarsium, -ii, n.: the tissues associated with the tarsal bones

paratestis, -is, m.: the epididymis

parathyreoidea, -ae, f.: parathyroid; situated near the thyroid gland, e.g. the parathyroid glands

paraumbilicalis, -e: paraumbilical; situated near the umbilicus

venae paraumbilicales: the small paraumbilical veins which go with the round ligament from the veins around the umbilicus to the left branch of the portal vein, thus connecting the systemic and portal circulation

paraurethralis, -e: paraurethral; situated near the urethra

ductus paraurethrales: the paraurethral ducts which drain small glands at the lower end of the female urethra and open just lateral to the external urethral orifice

paravaginalis, -e: paravaginal; situated near the vagina

paravertebralis, -e: paravertebral; situated beside the vertebral column

parenchyma, Gr.: the specific functional cells of an organ or gland as opposed to its connective tissue components

parenchymatosus, -a, -um: parenchymatous; pertaining to the parenchyma, rich in parenchyma

paries, -etis, m. L.: wall

paries caroticus cavi tympani: the carotid or anterior wall of the tympanic cavity

paries jugularis cavi tympani: the jugular wall or floor of the tympanic cavity

paries labyrinthicus cavi tympani: the labyrinthine or medial wall of the tympanic cavity

paries mastoideus cavi tympani: the mastoid or posterior wall of the tympanic cavity

paries membranaceus cavi tympani: the membranous or lateral wall of the tympanic cavity

paries tegmentalis cavi tympani: the tegmental wall or roof of the tympanic cavity

parietalis, -e: parietal; pertaining to a wall

parodontium, -ii, n. L.: the supporting structures of the teeth including the alveolar process, the periodontal membrane and the neighbouring gum

parolfactorius, -a, -um: parolfactory: pertaining to olfactory structures

parolivarius, -a, -um: parolivary; situated near the olivary body

sulcus parolivarius medialis et lateralis: the anterolateral and posterolateral sulci in front of, and behind the olive, where the fibres of the hypoglossal and the glossopharyngeal, vagus and accessory nerves respectively emerge

paroophoron, -ii, m. Gr.: the parovarium; a few rudimentary tubules in the broad ligament between the epoophoron and the uterus, being a remnant of part of the embryonic mesonephros

parotis, -idis, f. Gr.: parotid, situated near the ear

glandula parotis: the parotid gland: the serous salivary gland which lies on the side of the face, in front of the ear and between the ramus of the mandible and the external acoustic meatus

parotideus, -a, -um: parotid; pertaining to the parotid gland

pars, -tis, f. L.: part

partialis, -e: partial

parturitio: parturition: act of giving birth (parturire: be in labour)

parvus, -a, -um, L.: small

Passavant's ridge: the horizontal ridge in the wall of the pharynx at the level of the hard palate, caused by contraction of the upper fibres of palatopharyngeus muscle

patella, -ae, f. L.: pan; in anatomy: the knee cap or bone of the front of the knee joint

patellaris, -e: patellar; pertaining to the patella

fossa patellaris: fossa hyaloidea: the hyaloid fossa on the anterior surface of the vitreous body, which accommodates the lens

Pawlik's triangle: the triangular area of the anterior wall of the vagina, adjacent to the bladder and characterized by the absence of rugae

Pecquet's cistern: s. cisterna chyli

Pecquet's duct: s. ductus thoracicus

pecten, -inis, m. L.: comb

pecten ossis pubis: the pectineal line: the sharp anterosuperior edge of the superior ramus of the pubis, which passes laterally from the pubic tubercle to the iliopubic eminence

pectinatus, -a, -um: pectinate; shaped like a comb

pectineus, -a, -um: pectineal: pertaining to a comb-like structure, e.g. pecten ossis pubis

m. pectineus: the pectineus muscle, which arises mainly from the pectineal line and the bone in front and inserts into a line below the lesser trochanter of the femur

pectiniformis: pectiniform; comb-shaped

pectus, -oris, n. L.: breast

pectoralis, -e: pectoral; pertaining to the breast or the neighbouring part of the chest

m. pectoralis major et minor: the pectoralis major and pectoralis minor muscles

pedunculus, -i, m. L.: peduncle, stalk-like structure (pes: foot)

pedunculus cerebri: the cerebral peduncle: the part of the midbrain ventral to the cerebral aqueduct and composed of the tegmentum and crus cerebri

pedunculus corporis mamillaris: fasciculus pedunculomamillaris: the mamillary peduncle, which includes fibres passing from the medial lemniscus and reticular formation to end in relation to the mamillary body

pedunculus corporis pinealis: s. habenula corp. pinealis

pedunculus flocculi: the peduncle of the flocculus, which connects the latter with the nodule of the cerebellum

pedunculi thalami: the fibres passing between the thalamus and cerebral cortex. They have been subdivided into anterior, posterior, superior and inferior peduncles

peduncularis, -e: peduncular; pertaining to a peduncle

pedunculatus, -a, -um: pedunculated; provided with a peduncle

pellicula, -ae, f. L.: a thin membrane or skin. The term has been applied to the epidermis (pellis: skin)

pellucidus, -a, -um, L.: pellucid; translucent, transparent (perlucere: transilluminate)

septum pellucidum: the part of the original marginal cortex, which, after the development of the corpus callosum, extends between the latter, its genu and the fornix as a thin sheet of tissue usually containing a cavity

zona pellucida: the transparent membrane surrounding the ovum

pelvis, -is, f. L.: basin

pelvis major: the greater or false pelvis: the part of the pelvis above the linea terminalis, which is formed mainly by the iliac fossae but also by the body of the 5th and part of the 4th lumbar vertebrae and the base of the sacrum

pelvis minor: lesser or true pelvis: the part of the pelvis below the linea terminalis, whose bony wall is formed by sacrum, coccyx, pubis, ischium and part of the ilium

pelvis renalis: the pelvis of the kidney: the expanded commencement of the ureter, which starts within the sinus of the kidney and then extends medial to it, and finally narrows to form the tubular part of the ureter

pelvicus, -a, -um; *pelvinus*, -a, -um: pelvic; pertaining to the pelvis

penicillum, -i, n. L.: paint-brush

aa. penicilli: the brush-like branches which the follicular arteries of the spleen give off on entering the red pulp

penis, -is, m. L.: the male phallus or organ of copulation

penna, -ae, f. L.: feather

pennatus, -a, -um: pennate; shaped like a feather

m. bipennatus: bipennate muscle, in which the fibres arise or insert on both sides of a tendon at an angle to the long axis of the muscle belly, like the barbs of a feather

m. unipennatus: unipennate muscle, in which the fibres pass obliquely from their origin to be attached to one side of their tendon of insertion

per (prep. with accusative): through

perforans, -ntis, L.: perforating (perforare: to pierce through)

aa. perforantes: the perforating branches of the profunda femoris artery, which pierce adductor magnus at its insertion and then supply vastus lateralis

n. perforans Casserii: nervus musculocutaneus; the musculocutaneous nerve, which arises from the lateral cord of the brachial plexus, supplies biceps, brachialis and coracobrachialis and ends as the lateral cutaneous nerve of the forearm

peri, Gr.: a prefix signifying around, e.g. perianal; located around the anus: periauricular; situated around an auricle of the heart or the ear

pericardium, -ii, n. Gr.: the sac which surrounds the heart. It consists of an outer fibrous part which surrounds the serous part. The latter is a sac, which is invaginated by the heart and thus consists of an outer parietal layer which lines the fibrous pericardium, and an inner visceral layer (epicardium) which is reflected onto, and covers the heart itself. Between the parietal and visceral layers is the pericardial cavity

perichondrium, -ii, n.: the membrane which covers a cartilage and contributes to its formation

pericranium, -ii, n.: the periosteum covering the outside of the cranial bones

peridesmium, -ii, n.: the connective tissue covering of a ligament

perididymis, -idis: tunica albuginea testis: the layer of white fibrous tissue enclosing the testis

perilympha, -ae, f.: perilymph; the fluid contained in the space between the membranous labyrinth and the wall of the bony labyrinth of the ear

perimetrium, -ii, n.: the peritoneal covering of the uterus

perimysium, -ii, n.: the connective tissue around a fasciculus or bundle of muscle fibres

perineum, -ei, n.: the anatomical region bounded by the pubic arch and ischial tuberosities, the coccyx and the sacrotuberous ligaments

perinealis, -e: perineal; pertaining to the perineum

perineurium, -ii, n.: the connective tissue sheath surrounding a fasciculus or bundle of nerve-fibres

periodontium, -ii, n.: the connective tissue periodontal membrane surrounding the root of a tooth

periorbita, -ae, f.: periorbital; the periosteum lining the orbit

periosteum, -ii, n.: the connective tissue membrane surrounding a bone

periostealis, -e: periosteal; pertaining to the periosteum

periphericus, -a, -um; peripherialis, -e: peripheral: pertaining to the periphery

peristalticus, -a, -um: peristaltic; pertaining to, or of the nature of peristalsis, the waves of muscular contraction, which travel down the gut driving its contents before them (peristaltica: a slow worm-like movement)

peritenon, -i, n. Gr.: the sheath surrounding a tendon

peritoneum, -i, n. Gr.: the serous membrane which lines the abdominal walls (parietal portion) and is reflected over the contained viscera (visceral portion). It encloses the peritoneal cavity (periteinein: to stretch)

perivascularis, -e: perivascular; situated around a blood vessel

periventricularis, -e: periventricular; situated around a ventricle

Perlia's nucleus: the median unpaired part of the oculomotor nerve-nuclei

permanens, -ntis, L.: permanent, constant (permanere: to remain)

permeabilis, -e, L.: permeable (permeare: to pass through)

permeabilitas, -tis, f. L.: permeability

peronaeus, -a, -um, L.: peroneal; pertaining to the fibula (perone Gr.: pin)

perpendicularis, -e, L.: perpendicular; vertical (perpendiculum: plumbline)

lamina perpendicularis ossis ethmoidalis: the median perpendicular plate of the ethmoid bone, which forms part of the nasal septum

Pertik's diverticulum: an occasional diverticulum-like extension of the pharyngeal recess (of Rosenmüller)

pes, -dis, m. L.: foot

pes anserinus: plexus parotideus: the plexiform branching of the facial nerve in, and in front of the parotid gland. The term has also been applied to the combined insertions of the gracilis, sartorius and semitendinosus muscles (pes, L.: foot; anser, L.: goose)

pes hippocampi major: cornu Ammonis: the expanded anterior end of the hippocampus in the inferior horn of the lateral ventricle

Peter's line: the horizontal line drawn at the level of the upper border of the symphysis pubis, which normally intersects the tips of the greater trochanters

petiolus, -i, m. L.: (pediolus) petiole; a small pedicle or stalk

petiolus epiglottis: the pedicle of the inferior end of the epiglottis

Petit's canal: spatia zonularia: the spaces between the fibres of the ciliary zonule

Petits's triangle: trigonum lumbale: the lumbar triangle bounded by latissimus dorsi and the external oblique muscles and the iliac crest

Pétrequin's ligament: a term which has been applied to the anterior part of the temporomandibular joint-capsule

petrosus, -a, -um, Gr.: petrous; stony, resembling a rock (petros: rock)

ganglion petrosum: ganglion inferius (N IX): the inferior ganglion of the glossopharyngeal nerve

n. petrosus major: the greater petrosal nerve, which traverses the petrous part of the temporal bone, conveying fibres from the facial nerve to the pterygopalatine ganglion

n. petrosus minor: the lesser petrosal nerve, which penetrates the petrous part of the temporal bone, conveying fibres from the glossopharyngeal nerve to the otic ganglion

pars petrosa (ossis temporalis): the petrous part of the temporal bone which contains the structures of the internal and middle ear

sinus petrosus sup. et inf.: the superior petrosal sinus runs along the superior margin of the petrous part of the temporal bone, connecting the cavernous with the transverse sinus. The inferior petrosal sinus runs down-

wards from the cavernous sinus and joins the commencement of the internal jugular vein

Peyer's patches: folliculi lymphatici aggregati: aggregations of lymphatic follicles in the wall of the small intestine, mainly in the distal part of the ileum

Pflüger's tubes: the columns of cells which grow from the germinal epithelium on the surface of the developing ovary down into its stroma where they give rise to the primitive follicles

phagocyta, -ae, f. Gr.: phagocyte; any cell which ingests foreign particles (phagen: to eat)

phalanx, -gis, f. Gr.: an array of soldiers; in anatomy: the bones of the fingers or toes

phallus, -i, m. Gr.: penis

pharynx, -gis, m. Gr.: the part of the alimentary canal, situated behind the nasal cavities, the mouth and the larynx. It becomes the esophagus at the level of the 6th cervical vertebra

pars laryngea pharyngis: (laryngopharynx): the laryngeal part of the pharynx which lies behind the larynx

pars nasalis pharyngis: (nasopharynx): the part of the pharynx situated behind the choanae

pars oralis pharyngis: (oropharynx): the oral part of the pharynx situated behind the mouth and extending from the level of the soft palate to the laryngeal inlet

pharyngeus, -a, -um: pharyngeal; pertaining to the pharynx

philtrum, -i, n. Gr.: the vertical groove in the midline of the anterior surface of the upper lip (philtron, Gr.: love potion; or perhaps from filtrum, L.: filter)

phonatio, -onis, f. L.: phonation; the production of sounds by the larynx

phrenicus, -a, -um: phrenic; pertaining to the diaphragm (phrenos, Gr.: diaphragm)

phylogenesis, Gr.: phylogeny; the history of the evolution of species or race of animals (phylon: tribe, race)

Piersol's point: a small eminence which has been described at the beginning of the urethral crest

pigmentum, -i, n. L.: pigment (pingere: to paint)

pilosus, -a, -um: pilose; hairy

pilus, -i, m. L.: hair

pinealis, -e, L.: pineal; shaped like a pine cone; pertaining to the pineal body (pinea: pine cone)

piriformis, -e, L.: piriform; pear-shaped

apertura piriformis: piriform aperture: the anterior opening of the bony part of the nose

Pirogoff's angle: the angle formed by the junction of the internal jugular and subclavian veins

pisiformis, -e: pisiform; pea-shaped (pisum: pea)

os pisiforme: the pisiform bone of the carpus which articulates with the triquetrum

Pitres' sections: a series of defined coronal sections of the brain

pituita, -ae, f. L.: slime, mucus

pituitarius, -a, -um: pituitary; originally secreting mucus

glandula pituitaria: hypophysis; the pituitary gland of the base of the brain. It consists of a posterior lobe, which develops from the floor of the diencephalon and is attached to the tuber cinereum by the infundibulum, and an anterior lobe which develops from Rathke's pouch, an ectodermal up-growth from the roof of the stomatodaeum. The anterior lobe consists of cords of cells, chromophobe and acido- and basophil, and its blood supply is derived from portal vessels originating mainly in the infundibulum. The posterior lobe includes neuroglial-like cells and receives nerve-fibres from the paraventricular and supraoptic nuclei

pius, -a, -um, L.: soft, tender

pia mater: the innermost of the three (cerebral) meninges. It consists of a delicate vascular connective tissue, closely investing brain and spinal cord (mater, L.: mother)

placenta: the disk-shaped organ which connects the foetus to the uterine wall and which mediates respiratory, nutritive and excretory exchange between fetal and maternal blood (placenta, L.: cake)

placentalis, -e: placental; pertaining to the placenta

planta, -ae, f. L.: the sole of the foot

plantaris, -e: plantar; pertaining to the sole of the foot

planum, -i, n. L.: plane

planum nuchale: s. nucha, planum nuchale

planum occipitale: s. occiput, planum occipitale

planum orbitale: the orbital plane; 1. the orbital surface of the maxilla, forming the base of the orbit; 2. a vertical plane dropped from the orbitale, or lowest point on the inferior margin of the orbit

planum popliteum femoris: facies poplitea: the popliteal plane or surface of the posterior aspect of the inferior part of the shaft of the femur

planum sternale: the sternal plane of the anterior surface of the sternum

planum temporale: the temporal plane, or surface of the skull below the inferior temporal line

planus, -a, -um: plain, even

plaque (Fr.): a circumscribed area or patch

plasma, -tis, n. Gr.: the fluid part of the blood, excluding the cells. The term has also been applied to the protoplasm

plasma sanguis: blood plasma; the liquid part of the blood in which the corpuscles are suspended

platysma, -ates, n. Gr.: the thin subcutaneous sheet of muscle of the neck (platysma, Gr.: plate)

pleura, -ae, f. Gr.: the serous membrane which covers the lungs and lines the thoracic cavity

pleura cervicalis: cupula pleurae: the dome of the pleura which ascends in the neck as far as the neck of the 1st rib. It is related laterally to the scalene muscles

pleura costalis: costal pleura: the part of the pleura which lines the chest walls

pleura diaphragmatica: diaphragmatic pleura: that part of the pleura which covers the thoracic surface of the diaphragm

pleura mediastinalis: mediastinal pleura: the part of the pleura which covers the wall of the mediastinum

pleura parietalis: parietal pleura: the part of the pleura, which lines the thoracic cavity. It includes the cupula and the costal, mediastinal and diaphragmatic pleurae

pleura pericardiaca: pericardiac pleura: the part of the mediastinal pleura covering the fibrous pericardium

pleura pulmonalis: pulmonary pleura: the part of the pleura investing the lungs

pleura visceralis: s. pleura pulmonalis

pleuralis, -e: pleural; pertaining to the pleura

plexus, -us, m. L.: network (plectere: to plait)

plexus uterovaginalis: s. Frankenhäuser's plexus

plexiformis, -e: plexiform; resembling a plexus

plica, -ae, f. L.: fold (plicare: to fold)

plica rectouterina (Douglasi): the rectouterine folds of peritoneum which pass posteriorly from the cervix uteri on either side of the rectum to the posterior wall of the pelvis

plica spiralis: valvula spiralis (Heisteri); the spiral fold of mucous membrane which extends from the neck of the gall bladder into the first part of cystic duct

plicatus, -a, -um: plicate; folded

pluralis, -e, L.: plural, multiple (plus: more)

pneumaticus, -a, -um, Gr.: pneumatic; 1. containing air; 2. pertaining to respiration (pneuma: air)

ossa pneumatica: bones containing air cells

Poirier's gland: lymph gland, situated at the crossing of the ureter by the uterine artery

Poisseuille's space: the peripheral part of the cavity of a blood vessel where the flow of blood, and hence the movement of the blood cells, is reduced in comparison with that in the more central part of the lumen

pollex, -icis, m. L.: thumb

polus, -i, m. L.: pole or end of an axis

polus frontalis hemispherii cerebri: the frontal pole or anterior extremity of the frontal lobe of the brain

polus occipitalis hemispherii cerebri: the occipital pole or posterior extremity of the occipital lobe of the brain

polus temporalis hemispherii cerebri: the temporal pole or anterior extremity of the temporal lobe of the brain

polaris, -e: polar; pertaining to a pole

polocyta, -ae, f.: polocyte; the 1st and 2nd polar bodies which are formed during the meiotic division of the ovum. Each contains the haploid number of chromosomes

poly-, Gr.: a prefix meaning many (polys: many)

polydactylia: polydactylism: the occurrence of supernumerary digits on the hands or feet

polynuclearis: polynuclear; multinucleate: cells having several nuclei

pomum, -i, n. L.: fruit, including the apple

pomum Adami: prominentia laryngea: the prominence of the larynx in the adult man: "Adam's apple"

Ponfick's shadows: ghost or phantom erythrocytes, remaining after removal of their haemoglobin

pons, -tis, m. L.: bridge; in anatomy: the part of the rhombencephalon, which connects the medulla oblongata with the mesencephalon. It has the appearance of a bridge between the two cerebellar hemispheres

ponticulus, -i, m.: a small bridge

ponticulus promontorii: subiculum promontorii: the small process of bone, which passes downwards and backwards from the promontory towards the base of the pyramid. It bounds the fenestra cochleae posteriorly

poples, -itis, f. L.: the ham or knee

popliteus, -a, -um: popliteal; pertaining to the region of the posterior aspect of the knee

fossa poplitea: popliteal fossa; the hollow at the back of the knee

porosus, -a, -um, L.: porous; containing, or behaving as though containing pores

porta, -ae, f. L.: gate, hilum

porta hepatis: the hilum of the inferior aspect of the liver where the portal vein, hepatic artery and bile ducts enter

porta lienis: the hilum of the spleen where the splenic vessels enter

porta pulmonis: the hilum of the lung where the bronchi and pulmonary vessels enter

porta renis: hilus renalis: the hilum or fissure of the medial border of the kidney where the pelvis of the ureter lies and the renal vessels enter the kidney

v. portae: the portal vein, which lies in the free border of the lesser omentum and is formed by the union of the splenic and superior mesenteric veins. It conveys the blood from the unpaired abdominal viscera to the liver

portalis, -e: portal; pertaining to, or situated in a porta

portio, -onis, f. L.: part, division

portio intermedia nervi facialis (Wrisbergi): n. intermedius: the root of the facial nerve, which contains taste and parasympathetic fibres. It emerges from the brain between the facial and vestibulocochlear nerves

portio major nervi trigemini: radix sensoria: the sensory root of the trigeminal nerve

portio minor nervi trigemini: radix motoria: the motor root of the trigeminal nerve

portio supravaginalis cervicis: the part of the uterine cervix situated above the vagina

portio vaginalis cervicis: the part of the uterine cervix which projects into the upper part of the cavity of the vagina

porus, -i, m. Gr.: opening, passage, pore

porus acusticus externus: the opening of the external acoustic meatus on the surface of the skull

porus acusticus internus: the opening of the internal acoustic meatus on the inside of the cranial cavity

porus ejaculatorius: the opening of the ejaculatory duct on the seminal colliculus

porus sudoriferus: the opening of a sweat gland on the surface of the skin

poralis, -e: porous; penetrated by pores

positio, -onis, f. L.: position (ponere: to place)

post: (prep. with accusative) L.: after

posterior, -ius, L.: situated behind

posticus, -a, -um: posterior

Poupart's ligament: ligamentum inguinale (Pouparti): the inguinal ligament, which passes from the anterior superior iliac spine to the pubic tubercle

Poupart's line: perpendicular line passing through the midpoint of the inguinal ligament

prae- (pre-): (with accusative) a prefix signifying before

precuneus, -i, m.: the quadrilateral area on the medial surface of the cerebral hemisphere, which is bounded by the marginal ramus of the cingulate sulcus, the subparietal sulcus and the parietooccipital sulcus

praemolaris, -e: premolar; situated in front of the molar teeth; for premolar tooth s. dentes praemolares

praeparatio, -nis, f. L.: preparation

praeparatum, -i, n. L.: a preparation

praeputium, -ii, n. L.: prepuce

praeputium clitoridis: the prepuce of the clitoris, formed by the junction of the labia minora over the clitoris

praeputium penis: the fold of skin which covers the glans penis

pressor, -oris, f. L.: that which presses (premere: to press)

nn. pressores: the nerve-fibres mediating vasoconstriction

pressoceptor, -oris, f.: the receptors, sensitive to pressure in the bulb and arch of the aorta and in the carotid sinus

primarius, -a, -um, L.: primary; first in order, principal (primus: first)

primata: primates: the highest order of the mammalia, which includes the lemurs, monkeys and man

primitivus, -a, -um, L.: primitive; of earliest origin

primordium, -ii, n. L.: beginning, origin; the first form of an organ or structure; also called "Anlage"

primordialis, -e: primordial: pertaining to the beginning or primordium

primus, -a, -um, L.: first

princeps, -ipis, L.: chief, main

a. princeps pollicis: the main artery supplying the thumb, which branches from the radial artery as it enters the palm

prisma, -atis, n. Gr.: prism

pro-,: (prep. with ablative) before

procerus, -a, -um: long, extended

m. procerus nasi: the muscle which arises from the nasal bone and passes upwards to insert into the skin between the eyebrows

processus, -us, m. L.: process (procedere: to procede)

projectio, -onis, f. L.: projection; outward extension (projicere: to project)

prominentia, -ae, f. L.: prominence; protuberance (prominere: to project)

prominentia laryngea: s. pomum Adami

prominentia mallearis membranae tympani: the mallear prominence at the upper extremity of the stria mallearis, formed by the lateral process of the malleus

prominentia spiralis: the spiral prominence of the cochlea, which bounds the stria vascularis inferiorly. It contains the vas prominens

prominentia styloidea: the styloid prominence on the inferior part of the posterior wall of the tympanic cavity

prominens, -ntis: prominent; projecting

promontorium, -ii, n. L.: promontory; 1. the anteriorly projecting edge formed by the upper border of the body of the first sacral vertebra; 2. the prominence on the medial wall of the tympanic cavity formed by the first coil of the cochlea

pronatio, -onis, f. L.: pronation; in a prone position (pronare: to face downwards)

pronatio manus: pronation of the hand, in which position its dorsum is directed forwards or upwards and the bones of the forearm cross each other

pronatio pedis: pronation of the foot: the movement of the foot combining eversion and dorsi-flexion

pronator, -oris, m.: that which causes pronation (muscle)

pronephros, -i, m. Gr.: the precursor of the meso- and metanephros, or definitive kidney, in the human embryo. It is a transitory structure

prophasis, -is, f. Gr.: prophase; the first stage in mitosis, in which the chromosomes become visible

proprius, -a, -um, L.: proper; particular

prosencephalon, -i, n. Gr.: the forebrain including the telen- and diencephalon

prostata, -ae, f. Gr.: the prostate gland consisting partly of glandular and partly of muscular tissue, which in the male lies immediately inferior to the bladder and surrounds the first part of the urethra (prostates: one who stands before)

prostaticus, -a, -um: prostatic: pertaining to the prostate

protoplasma, -atos, n. Gr.: protoplasm: the ground substance of the cell outside the nucleus (protos: first)

protuberantia, -ae, f. L.: protuberance

protuberantia mentalis: the mental protuberance or prominence of the chin

protuberantia occipitalis externa: the external occipital protuberance: the median prominence on the outer surface of the squamous part of the occipital bone where the superior nuchal lines meet

protuberantia occipitalis interna: the internal occipital protuberance: the median prominence on the inner surface of the squamous part of the occipital bone where the confluence of the sinuses occurs

proximus, -a, -um, L.: proximal; nearest

proximalis, -e: proximal; situated nearer the centre of the body (opposite to distal)

Prussak's fibres: the connective tissue fibres bounding the pars flaccida of the tympanic membrane

Prussak's space: recessus membranae tympani sup.: superior recess of the tympanic membrane: the narrow space situated between the neck of the malleus, the lateral ligament of the malleus and the pars flaccida of the tympanic membrane

pseudo-, Gr.: in combination signifying false or spurious

psoas, f. Gr.: the region of the loin

m. psoas major: the muscle which arises from the sides of the lumbar intervertebral disks and the adjoining part of the bodies and transverse processes of the lumbar vertebrae and inserts into the lesser trochanter of the femur

pterygoideus, -a, -um: pterygoid; shaped like a wing

canalis pterygoideus: the canal which passes in a posteroanterior direction through the root of the pterygoid process of the sphenoid bone

fossa pterygoidea: the pterygoid fossa between the medial and lateral pterygoid plates of the sphenoid

lamina lateralis et medialis processus pterygoidei: the lateral and medial pterygoid plates of the pterygoid process of the sphenoid

processus pterygoideus: the pterygoid process of the sphenoid

pteryon, Gr.: the region on the skull where the parietal, frontal, squamous part of the temporal and the greater wing of the sphenoid bone come together (pteron: wing)

pubes, -is, f. L.: the region of the os pubis

pubicus, -a, -um: pubic; pertaining to the pubes

pudendum muliebre, L.: the female external genitalia (pudere: to be ashamed)

pudendus, -a, -um; *pudendalis*, -e: pudendal; pertaining to the pudendum

pulmo, -onis, m. L.: lung

hilus pulmonis: the hilus of the lung

pulmonalis, -e: pulmonary; pertaining to the lung

pulpa, -ae, f. L.: pulp; any soft content of a structure

canalis pulpae: the canal of the root of the tooth

pulpa dentis: the dental pulp: the connective tissue, nerves and blood vessels contained within the dental cavity

pulpa digitalis: the digital pulp; the pad of fibro-fatty tissue, forming the bulk of the palmar or plantar surface of the distal phalanx of the fingers or toes

pulpa lienis: the soft contents of the spleen

pulposus, -a, -um: pulpous: soft

pulsatio, -onis, f. L.: pulsation; pulse, or rhythmical beat (pulsare: to pulsate)

pulvinar, -aris, n. L.: a cushioned couch

pulvinar acetabuli: a term which has been applied to the acetabulum and its contents

pulvinar thalami: the posterior part of the thalamus, which overhangs the superior colliculi

punctum, -i, n. L.: point

punctum caecum: the blind spot of the retina at the entrance of the optic nerve

punctum coxale: the highest point of the crest of the ilium

punctum lacrimale: the opening of the lacrimal canalicus on the lacrimal papilla of the eyelid

punctum luteum: s. macula lutea

punctum ossificationis: the ossification centre of a bone where bone first appears

puncta vasculosa: the minute red spots on the cut surface of the white substance of the brain, produced by blood exuded from damaged vessels

punctatus, -a, -um: punctate

pupilla, -ae, f. L.: pupil of the eye

pupillaris, -e: pupillary; pertaining to the pupil

Purkinje's cells: (stratum gangliosum): the nerve-cells in the deepest part of the molecular layer of the cerebellar cortex. They project to the cerebellar nuclei

Purkinje's fibres: the large specialized muscle fibres, which form the terminal ramifications of the conducting system of the heart

Purkinje's network: the subendocardial network of Purkinje's fibres

Purkinje's vesicle: the nucleus of the ovum

putamen, -inis, n. L.: shell, husk

putamen lentis: capsula lentis: the capsule of the lens

putamen nuclei lentiformis: the outer component of the lentiform nucleus of the cerebrum. It lies lateral to the globus pallidus and is one of the nuclei of the extrapyramidal system

pylorus, -i, n. Gr.: gate-keeper; in anatomy: the pyloric orifice of the stomach, which opens into the duodenum

pyloricus, -a, -um: pyloric; pertaining to the pylorus

pyramis, -idis, f. Gr.: pyramid

os pyramidale: os triquetrum

pyramidal pathway: fasciculus corticospinalis: the main pathway of the voluntary motor impulses in the mesencephalon, pons, medulla oblongata and spinal medulla. It includes the corticospinal and corticonuclear fibres

pyramidal cells: the pyramidal cells of the cerebral cortex, whose main dendrite projects towards the surface of the cortex, and whose axon goes towards the underlying white matter

pyramides renales (Malpighii): the pyramids formed by the medullary substance of the lobes of the kidney. Their apices or papillar project into the minor calyces

processus pyramidalis: 1. pyramidal lobe of the thyroid gland; 2. the projection of the palatine bone, which is directed downwards and laterally from the junction of the horizontal and vertical plates

pyramis ossis temporalis: pars petrosa ossis temporalis; s. petrosus

pyramis vermis: the pyramid of the vermis, which lies on the inferior surface of the cerebellum between the uvula and tuber

Q

quadrangularis, -e, L.: quadrangular (angulus: angle)

lobus quadrangularis: the quadrangular lobe of the hemisphere of the cerebellum which forms the posterior part of the anterior lobe

quadratus, -a, -um, L.: quadrate; squared

m. quadratus labii inf.: m. depressor labii inferioris

m. quadratus labii sup.: the superior quadrate muscle of the BNA, which includes levator labii superioris, levator labii superioris alaeque nasi and zygomaticus minor

quadriceps, -itis, m. L.: four-headed

m. quadriceps femoris: the quadriceps muscle of the thigh, which includes vastus lateralis, intermedius and medialis and rectus femoris

quadrigeminus, -a, -um: quadrigeminal: fourfold

corpora quadrigemina: the superior and inferior colliculi of the tectum of the mesencephalon, which are concerned with visual reflexes and the auditory pathways respectively

lamina quadrigemina: the dorsal part of the mesencephalon, which includes the superior and inferior colliculi

quartus, -a, -um: fourth

Quatrefage's angle: angulus parietalis: the parietal angle between lines tangential to the most prominent lateral point of the zygomatic arch and to the frontoparietal suture

quattuor, L.: four

quinque, L.: five

quinquetubercularis, -e, L.: quinquetubercular; having five cusps or tubercles as on the first lower molar tooth

R

radiatio, -onis, f. L.: radiation

radiatio corporis callosi: the radiation of the fibres of the corpus callosum towards the cerebral cortex

radiatio corporis striati: the radiation of the corpus striatum, which consists of fibres passing from the thalamus and hypothalamus to the corpus striatum

radiatio optica: Gratiolet's radiation: the optic radiation consisting of fibres passing from the lateral geniculate body to the visual or striate cortex of the occipital lobe

radiatio tegmentalis: the tegmental radiation extending lateral to the red nucleus and including corticorubral fibres

radiatio thalamica: fasciculi corticothalamici et thalamocorticales: the thalamic radiation consisting of thalamocortical and corticothalamic fibres, leaving the lateral aspect of the thalamus to pass between the latter and the cortex in the internal capsule

radius, -ii, m. L.: staff, spoke; in anatomy: the lateral of the two bones of the forearm

radialis, -e: radial; pertaining to the radius

a. radialis: radial artery: one of the two terminal branches of the brachial artery. It passes down the anterolateral aspect of the forearm to gain the hand

n. radialis: the radial nerve, which arises from the posterior fasciculus of the brachial plexus. It supplies muscles of the posterior aspect of the arm and forearm

radiatus, -a, -um: radiate; emitting rays or ray-like structures

lig. carpi radiatum: the radiate ligament of the corpus, which connects the head of the capitate with the neighbouring carpal bones

radix, -icis, f. L.: root

radix anterior (ventralis) nervorum spinalium: the motor, anterior or ventral root of a spinal nerve

radix arcus vertebrae: pediculus arcus vertebrae: the pedicle or root of the vertebral arch which connects the lamina to the body of the vertebra

radix dentis: the root of a tooth, which is contained in the bony socket of the jaw

radix dorsalis nervorum spinalium: the dorsal, posterior or sensory root of a spinal nerve

radix linguae: the posterior attached part of the tongue

radix longa ganglii ciliaris: ramus communicans (n. nasociliaris) cum ganglio ciliari: the communicating branch of the nasociliary nerve to the ciliary ganglion. This conveys sensory fibres to the ganglion

radix mesenterii: the root of the mesentery where it is attached to the posterior abdominal wall

radix nasi: the root of the nose where it joins the face

radix oculomotoria ganglii ciliaris: the oculomotor root of the ciliary ganglion, which conveys preganglionic parasympathetic fibres from the oculomotor nerve to the ciliary ganglion

radix penis: the root of the penis: the posterior part of the corpora cavernosa and spongiosum which are attached respectively to the pubic arch and perineal membrane

radix pili: the root of a hair; that part of the hair which is embedded in the follicle

radix pulmonis: the root of the lung: the bronchi and the pulmonary and bronchial vessels and nerves entering the lungs at the hilus

radix sympathica ganglii ciliaris: the sympathetic fibres originating from the internal carotid plexus which pass through the ciliary ganglion

radix unguis: the proximal part of a nail, which is overlapped by a fold of skin (vallum unguis)

Ramón y Cajal's cells: Cajal's cells; the nerve-cells of the molecular layer of the cerebral cortex, whose processes lie parallel to the surface

Ramón y Cajal's nucleus: nucleus interstitialis; the interstitial nucleus, which lies dorsomedial to the rostral end of the red nucleus and gives rise to fibres of the medial longitudinal bundle

ramulus, -i, m. L.: a small branch

ramus, -i, m. L.: branch; in anatomy: a term applied to the primary division of a blood vessel, or nerve

ramificatio, -onis, f.: ramification; distribution in branches

Ranvier's constrictions: the ring-like constrictions, which occur at intervals along the length of the medullary sheath of a nerve-fibre

Ranvier's crosses: the small crosses seen in silver preparations where the axon traverses the nodes of Ranvier

Ranvier's motor points: a term which has been applied to the endings of motor-nerves of muscle fibres and especially to their minute terminal enlargements

Ranvier's nodes: s. Ranvier's constrictions

Ranvier's segments: the segments of medullary sheath between Ranvier's constrictions

raphe, -ae, f. Gr.: a line of union; in anatomy: a line marking a junction (raphe: suture)

raphe anococcygea: ligamentum anococcygeum: the anococcygeal ligament or

body: a fibromuscular structure which intervenes between the anal canal and the coccyx

raphe corporis callosi: a term which has been applied to the groove on the dorsal surface of the corpus callosum between the medial longitudinal striae

raphe medullae oblongatae: raphe of the medulla oblongata: the median plane of union of the two halves of the medulla oblongata. Decussating fibres intersect it

raphe palati: the palatine raphe: the slight ridge in the midline on the oral surface of the palate which extends posteriorly from the incisive papilla

raphe palpebralis lateralis: lateral palpebral raphe: the raphe formed by the interlacing of the upper and lower parts of the palpebral part of orbicularis oculi at the lateral angle of the eyelids

raphe perinei: the slight ridge in the midline on the skin of the perineum. It is continuous anteriorly with the raphe of the scrotum

raphe pharyngis: the tendinous line on the posterior wall of the pharynx in the midline to which muscles of the pharynx are attached

raphe pterygomandibularis: pterygomandibular raphe: a fibrous band extending between the posterior end of the mylohyoid line of the mandible and the pterygoid hamulus

raphe scroti: the slight midline ridge on the surface of the scrotum. It is continuous with the raphe perinei posteriorly

Rathke's bundles: a term which has been applied to the trabeculae carneae

Rathke's pouch: the ectodermal diverticulum which grows upwards from the roof of the stomatodeum in the embryo to form the anterior lobe of the pituitary

Rathke's trabeculae: trabeculae cranii; the trabecular and hypophyseal cartilages in the embryo, situated at the anterior end of the notochord. They contribute to the formation of the sphenoid

Rau's process: processus anterior mallei; the anterior process of the malleus

receptor, -oris, f. L.: that which receives, e.g. nerve endings responding to sensory stimuli (recipere: to receive)

recessus, -us, m. L.: recess, depression, pouch (recedere: to recede)

recessus anterior fossae interpeduncularis (Tarini): the depression of the interpeduncular fossa near the mamillary bodies

recessus cochlearis vestibuli: the cochlear recess at the lower end of the vestibular crest of the vestibule of the bony labyrinth of the internal ear

recessus duodenalis superior et inferior: the superior and inferior duodenal recesses, bounded by the superior and inferior duodenal peritoneal folds on the left of the 4th part of the duodenum

recessus ellipticus vestibuli: the elliptical recess: the depression on the medial wall of the vestibule of the bony labyrinth of the inner ear. It lodges the utricle

recessus epitympanicus: the epitympanic recess: the part of the tympanic cavity above the level of the tympanic membrane

recessus ileocaecalis inferior: the inferior ileocaecal recess between the ileocaecal fold and the mesoappendix

recessus ileocaecalis superior: the superior ileocaecal recess between the vascular fold of the caecum and the mesentery of the ileum

recessus inferior omentalis: the part of the omental bursa which passes below the level of the vestibule between the stomach and the pancreas

recessus infundibuli: the recess formed by the extension of the cavity of the 3rd ventricle into the upper part of the infundibulum

recessus infundibuliformis: s. r. pharyngeus

recessus intersigmoideus: the intersigmoid recess which lies behind the apex of the attachment of the sigmoid mesocolon in front of the bifurcation of the left common iliac artery

recessus lateralis ventriculi quarti: the lateral recess of the 4th ventricle: the narrow lateral prolongation of the cavity of the 4th ventricle, dorsal to the inferior cerebellar peduncle

recessus lienalis: the splenic recess: that part of the omental bursa which extends towards the hilum of the spleen

recessus membranae tympani anterior: the anterior recess of the tympanic membrane between the latter and the anterior malleolar fold. It opens inferiorly

recessus membranae tympani superior: Prussak's space: the superior recess of the tympanic membrane between the inner surface of the pars flaccida and the neck of the malleus

recessus opticus: the optic recess of the 3rd ventricle of the brain, which extends between the optic chiasma and the lamina terminalis

recessus paracolici: sulci paracolici: paracolic sulci; the inconstant peritoneal pockets situated at the left border of the descending colon

recessus pharyngeus (Rosenmülleri): pharyngeal recess: Rosenmüller's fossa: the narrow depression on the wall of the pharynx, behind the tubal elevation and the salpyngopharyngeal fold

recessus pinealis: pineal recess: the small extension of the cavity of the 3rd ventricle between the posterior and habenular commissures

recessus piriformis: the piriform recess or fossa of the laryngeal part of the pharynx between the aryepiglottic fold and the lamina of the thyroid cartilage and thyrohyoid membrane

recessus posterior fossae interpeduncularis (Tarini): posterior recess: the deeper part of the interpeduncular fossa in front of the anterior margin of the pons

recessus retrocaecalis: the retrocecal peritoneal recess, which is of variable size and extends upwards behind the cecum

recessus sacciformis: 1. the synovial pouch of the distal radioulnar joint, which extends proximally for a short distance between the radius and ulna; 2. the term has also been applied to the extension of the synovia of the elbow joint deep to the anular ligament

recessus sphaericus vestibuli: spherical recess: a circular depression of the anterior part of the medial wall of the vestibule of the bony labyrinth of the ear. It lodges the saccule

recessus sphenoethmoidalis: the sphenoethmoidal recess above and behind the superior concha and forming the posterior superior angle of the nasal cavity. The sphenoidal sinus opens into it

recessus superior omentalis: the superior recess of the omental bursa, which extends above the level of the vestibule posterior to the caudate lobe of the liver

recessus suprapinealis: the extension of the 3rd ventricle of the brain between the pineal body and the corpus callosum

recessus triangularis: the recess of the 3rd ventricle of the brain which may occur between the anterior columns of the fornix and the anterior commissure

rectum, -i, n. L.: the distal part of the large intestine extending from the sigmoid colon to the anal canal (intestinum rectum)

rectalis, -e: rectal; pertaining to the rectum

rectus, -a, -um, L.: straight

m. rectus abdominis: the rectus abdominous muscle, which arises from the pubic crest and ligaments, and inserts into the anterior surface of the xiphoid process and 5th to 7th costal cartilages

m. rectus femoris: the part of m. quadriceps femoris, which arises from the anterior inferior iliac spine and the ilium, just above the acetabulum and inserts into the patella. It lies superficial to vastus intermedius

recurrens, -ntis, L.: recurrent; returning, running back (recurrere: to return)

n. laryngeus recurrens: the recurrent laryngeal branch of the vagus-nerve, which innervates the intrinsic muscles of the larynx with the exception of cricothyroid. It also supplies sensory fibres to the lower part of the laryngeal mucosa

reflex, -us, m. L.: the involuntary response of the organism to a stimulus (reflectere: to turn back)

regeneratio, -onis, f. L.: regeneration; renewal (generare: to beget)

regio, -onis, f. L.: region

Reichert's cartilage: the cartilage of the second branchial arch in the embryo. It is the precursor of the stapes styloid process, stylohyoid ligament and upper part of the hyoid bone

Reichert's membrane: lamina limitans anterior: the anterior limiting layer of the cornea

Reichert's recess: s. recessus cochlearis

Reichert's substance: the posterior part of the anterior perforated substance

Reid's base line: the line of the base of the skull, passing between the lower margin of the opening of the orbit and the centre of the opening of the external acoustic meatus

Reil's ansa: ansa peduncularis

Reil's band: trabecula septomarginalis: the moderator band of the right ventricle

Reil's insula: s. insula Reilii

Reil's ribbon: s. lemniscus medialis

Reil's sulcus: sulcus circularis insulae; the circular sulcus, which bounds the insula

Reil's triangle: s. trigonum lemnisci

Reisseisen's muscles: the smooth muscle fibres in the wall of the bronchioles

Reissner's canal: s. ductus cochlearis

Reissner's membrane: membrana vestibularis: the vestibular membrane, which separates the scala vestibuli from the duct of the cochlea

Remak's band: axon; the axial filament of the nerve-fibre

Remak's fibres: the nonmedullated nerve-fibres

Remak's ganglion: autonomic ganglion at the opening of the inferior vena cava into the heart

Remak's nuclear division: amitosis

Remak's plexus: s. Meissner's submucous plexus

ren, renis, m. L.: the kidney

ren arcuatus: the horseshoe-shaped kidney, where the two kidneys are united by kidney tissue, which lies anterior to the aorta and caudal to the inferior mesenteric artery

ren succenturiatus: the suprarenal gland

renalis, -e: renal; pertaining to the kidney

a. renalis: renal artery: the branches of the abdominal aorta at the level of the second lumbar vertebra, which supply the kidneys

v. renalis: the renal veins draining the kidneys and emptying into the inferior v. cava

reniculus, -i, m. L.: small kidney: the term has been applied to the lobes of the kidney

respiratorius, -a, -um, L.: respiratory: subserving respiration (respirare: to respire)

apparatus respiratorius: the respiratory system

mm. respiratorii: the muscles which effect respiration

mm. respiratorii supplementarii: the supplementary muscles which help effect deep, or forced, respiration

restiformis, -e, L.: restiform; shaped like a rope (restis: rope)

corpus restiforme: pedunculus cerebellaris inferior: the inferior cerebellar peduncle, connecting the cerebellum and medulla oblongata (the rope-like body)

rete, -tis, n. L.: net

rete acromiale: the anastomotic arterial network around the acromion, formed by branches of the suprascapular and thoracoacromial arteries

rete articulare cubiti: the anastomotic vascular network around the elbow joint, formed by branches of the brachial, ulnar and radial arteries

rete articulare genu: the anastomotic vascular network especially in front of, and beside, the knee joint, which is formed by branches from the anterior and posterior tibial and genicular arteries

rete articulare vasculosum: the vascular anastomosing networks commonly present around joints

rete calcaneum: the anastomosing vascular network around the calcaneus, formed by branches of the peroneal and posterior tibial arteries

rete canalis hypoglossi: the venous network surrounding the hypoglossal nerve in the hypoglossal canal, which establishes connection between the occipital sinus, the inferior petrosal sinus and the internal jugular vein

rete carpi dorsale: the vascular network or arch on the dorsal surface of the carpus, which is formed by the dorsal carpal branches of the ulnar and radial arteries and gives rise to the dorsal metacarpal arteries

rete dorsale pedis: the vascular network on the dorsal aspect of the distal tarsal bones, formed by branches of the lateral tarsal and arcuate arteries

rete foraminis ovalis: plexus venosus foraminis ovalis: the venous plexus of the foramen ovale around the mandibular nerve, which connects the cavernous sinus with the pterygoid plexus

rete malleolare laterale: the vascular network around the lateral malleolus, formed by branches from the peroneal and anterior tibial arteries

rete malleolare mediale: the vascular network around the medial malleolus, formed by branches from the anterior and posterior tibial arteries

rete Malpighi: s. mirabilis

rete patellae: the superficial vascular network around the patella, which is formed by branches from the genicular arteries

rete testis (Halleri): the network of tubules in the mediastinum testis into which open the straight seminiferous tubules

rete venosum dorsale manus: the superficial venous network of the dorsum of the hand, which empties into the cephalic and the basilic veins

rete venosum dorsale pedis: the superficial venous plexus of the dorsum of the foot, which empties into the great and small saphenous veins

rete venosum plantare: the subcutaneous plantar venous network of the sole of the foot, which drains into the saphenous veins

retia venosa vertebrarum: the venous network of the internal vertebral venous plexus, between the dura and vertebrae

reticularis, -e, L.: reticular; pertaining to a network

reticulatus, -a, -um: reticulated; reticular

reticulocyta: reticulocyte; immature polychromatophil erythrocytes with basophilic material in the cytoplasm, which can be precipitated to form a network (substantia granulofilamentosa)

reticulum, -i, n. L.: small net

reticuloendothelial system: the system is characterized by the presence of phago-

cytic cells which can be readily stained by vital dyes such as trypan blue. Such cells line sinuses in the liver, spleen, bone marrow, adrenal and lymph nodes and are also present in the connective tissue as macrophages or histiocytes

retina, -ae, f. L.: the inner membrane of the eye, which is sensitive to light. It includes an outer pigmented layer and an inner nervous layer, which contains the rods and cones

retinaculum, -i, n. L.: a band of dense connective tissue which holds structures and especially tendons in their correct position (retinere: to retain)

retinaculum capsulae articularis coxae: the retinaculum of the hip joint: the bundles of fibres which are reflected from the capsule of the hip joint, onto the neck of the femur

retinacula cutis: the bands of connective tissue which attach the dermis to the underlying superficial fascia

retinacula musculorum peroneorum superius et inferius: the superior and inferior peroneal retinacula which retain the tendons of the peroneus longus and brevis, as they pass behind the lateral malleolus and across the surface of the calcaneus

retinaculum patellae med. et lat.: fibrous expansions from the medial and lateral vastus muscles, which pass beside and gain attachment to the patella and insert into the front of the condyles of the tibia

retro-, L.: a prefix signifying backward, behind

retroauricularis, -e: retroauricular; situated behind the auricle

retrobuccalis, -e: retrobuccal; situated in the posterior part of, or behind, the cheek

retrobulbar space: the space in the orbit behind the eyeball, which is occupied by adipose tissue

retrocaecalis, -e: retrocecal; situated behind the cecum

retrocardiac space: Holzknecht's space: a term which has been applied to the space between the dorsal surface of the heart and the ventral surface of the vertebral column in a right anterior oblique radiograph

retrocervicalis, -e: retrocervical; situated behind the cervix uteri

retroflexio, -onis, f. L.: retroflexion; the bending backwards of an organ, especially the uterus

retroflexus, -a, -um: retroflexed; bent backwards

retrolingualis, -e: situated behind the tongue

retromammalis, -e: retromammary; situated behind the mammary gland

retromandibularis, -e: retromandibular; situated behind the mandible

retromastoidalis, -e: retromastoid; situated behind the mastoid process

retronasalis, -e: retronasal; situated behind the nose

retrooocularis, -e: retrobulbar; situated behind the eye

retrooesophagealis, -e: retroesophageal; situated behind the esophagus

retroperitonealis, -e: retroperitoneal; situated behind the peritoneum

retropharyngealis, -e: retropharyngeal; situated behind the pharynx

retrosternalis, -e: retrosternal; situated behind the sternum

retroversio, -onis, f. L.: retroversion; the turning backward of a structure

retroversio uteri: retroversion of the uterus: the condition in which the uterus is bent backwards on the vagina

Retzius' band: lig. fundiforme penis

Retzius' gyrus: gyrus intralimbicus: the posterior tip of the uncus

Retzius' space: spatium retropubicum: the retropubic space between the bodies of the pubic bones, the puboprostatic ligaments and the apex of the bladder. It is filled with loose connective tissue

Retzius' striae: brown, concentric, incremental, growth lines visible in the enamel in transverse sections of the tooth

Retzius' veins: the small anastomosing veins which connect the intestinal veins with the retroperitoneal branches of the inferior vena cava

reunient, -ntis, f. L.: reunient; uniting, joining (reunire: to unite)

ductus reuniens: a short narrow canal connecting the inferior part of the saccule and the vestibular end of the cochlear duct

rhaphe: s. raphe

rhinencephalon, -i, n. Gr.: the part of the brain concerned with olfaction. It consists of the olfactory bulb and those sites which receive fibres from the latter, including the anterior perforated substance (olfactory tubercle), the uncus (piriform cortex) and part of the amygdala. It remains uncertain whether the entorhinal area (parahippocampal gyrus) and the hippocampus itself should be included (rhin: the nose)

rhombencephalon, -i, n. Gr.: the hindbrain including the pons, cerebellum and medulla oblongata (rhombos: rhomboid)

rhomboideus, -a, -um, Gr.: rhomboid; rhomb-shaped, like the ace of diamonds on a playing card

fossa rhomboidea: the rhomboid fossa, which forms the floor of the 4th ventricle of the brain

lig. rhomboideum: lig. radiocarpeum dorsale

m. rhomboideus major et minor: the rhomboideus major and minor muscles, which arise from the lower part of the ligamentum nuchae and spines of the 7th cervical and upper 5 thoracic vertebrae, and insert into the medial border of the scapula opposite to, and below, the root of its spine

Ribes' ganglion: a very small sympathetic ganglion, which Ribes described as sometimes occurring on the anterior communicating artery of the brain

Ridley's sinus: sinus circularis: the venous circle formed by the bilateral cavernous and the anterior and posterior intercavernous sinuses

Riedel's lobe: lobus appendicularis seu linguiformis: an occasional small accessory lobe of the liver projecting downwards, in front of the gall bladder

rigidus, -a, -um, L.: rigid, stiff

rima, -ae, f. L.: slit, cleft, fissure
rima cornealis: the anterior margin of the sclera where it joins the cornea
rima glottidis: the gap between the vocal folds
rima oris: the opening of the mouth
rima palpebrarum: the slit between the eyelids
rima pudendi: the pudendal (vulvar) cleft
rima vestibuli: the fissure between the vestibular folds of the larynx

Rindfleisch's cells: the eosinophil granular leukocytes

Rindfleisch's fold: folds of the serous pericardium around the initial part of the aorta

Riolan's arch: the arcade in the transverse mesocolon, formed by the colic arteries

Riolan's bones: small isolated bones, sometimes found in the petrooccipital synchondrosis

Riolan's bouquet: the collective term which has been applied to the muscles and ligaments which take their origin from the styloid process of the temporal bone

Riolan's muscle: the ciliary part of the orbicularis oculi muscle, whose fibres run near the margin of the eyelid

risorius, -a, -um, L.: subserving laughter (ridere: to laugh)
m. risorius: the muscle which arises from the parotid fascia and is inserted into the angle of the mouth. It pulls the latter sideways as in grinning

Rivinus' ducts: ductus sublinguales: the excretory ducts of the sublingual glands which open along the top of the sublingual folds

Rivinus' foramen: Bochdalek's canal: a small orifice, sometimes present in the pars flaccida of the tympanic membrane

Rivinus' gland: the sublingual gland. A mainly mucous salivary gland which lies beneath the sublingual fold

Rivinus' membrane: the pars flaccida of the tympanic membrane

Robert's ligament: the anterior and posterior meniscofemoral ligaments which extend from the posterior part of the lateral meniscus of the knee to the anterior and posterior surfaces of the posterior cruciate ligament

Robin's space: lymphatic spaces in the walls of arteries, especially between the media and adventitia

Robinson's circle: anastomoses between the uterine and ovarian arteries

Rolando's fissure: sulcus centralis: the central sulcus between the parietal and frontal lobes of the cerebrum

Rolando's lobe: s. operculum

Rolando's points: the points on the head, corresponding to the upper and lower ends of the central sulcus. The upper one is about half way between the glabella and external occipital condyle and the lower about two inches above the preauricular point

Rolando's substance: s. substantia gelatinosa

Roller's nucleus: a small nucleus ventral to the hypoglossal nucleus. It is probably

a component of the reticular formation. The eponym has also been applied to part of the nucleus of the accessory nerve

Rosenmüller's gland: the lymph node in the femoral ring

Rosenmüller's organ: s. epoophoron

Rosenmüller's recess: s. recessus pharyngeus

Rosenmüller's valve: a fold of mucous membrane at the opening of the lacrimal canaliculi into the lacrimal sac

Rosenthal's vein: vena basalis: the basal vein formed by the union of the anterior and deep middle cerebral veins. It drains into the great cerebral vein

Roser–Nélaton's line: s. Nélaton's line

rostrum, -i, n. L.: beak

rostrum corporis callosi: the part of the corpus callosum passing from the genu towards the anterior commissure

rostrum sphenoidale: the spine on the lower surface of the body of the sphenoid bone, which articulates with the alae of the vomer

rostralis, -e: rostral; pertaining to, or resembling a rostrum; towards the cephalic end of the body

rotator, -oris, m. L.: a muscle which causes rotation (rotare: to rotate)

Roth's vas aberrans: a diverticulum of the upper end of the epididymis, connected with the rete testis. It is to be distinguished from Haller's vas aberrans

rotundus, -a, -um, L.: round

foramen rotundum: the foramen which pierces the greater wing of the sphenoid bone, and transmits the maxillary nerve from the middle cranial fossa to the pterygopalatine fossa

Rouget's cells: contractile cells or pericytes, which have been described in the wall of capillaries

Rouget's muscle: the circular fibres of the ciliary muscle of the eye

Rouget's veins: the dilated and tortuous veins of the hilum of the ovary and mesovarium

ruber, -bra, -brum, L.: red

nucleus ruber: the red nucleus of the tegmentum of the midbrain at the level of the superior colliculus. It forms part of the extrapyramidal system

rubor, -oris, m. L.: redness

rubor labii: the redness of the lips

rudimentum, -i, n. L.: rudiment or in a rudimentary condition, an imperfectly developed structure (rudis: crude, rudimentary)

rudimentum processus vaginalis peritonei: s. Nuck's canal

Ruffini's corpuscles: sensory nerve endings (tactile corpuscles) in the corium, especially of the digital pulp. They are described as lying within a connective tissue bundle

ruga, -ae, f. L.: wrinkle; hence folds of a mucous membrane

rugae gastricae: the folds on the mucous membrane of the stomach

rugae iridis: plicae iridis

rugae palatinae: plicae palatinae transversae: the transverse folds of the mucous membrane of the hard palate

rugae vaginales: the transverse folds of the mucous membrane of the vaginal wall

Russel's bodies: acidophil hyaline bodies, readily staining with carbolfuchsin, and found in the plasma cells and in other cells of inflammatory tissue. They are probably degeneration products

Ruysch's duct: a small diverticulum in the foetal nasal septum associated with the vomeronasal organ

Ruysch's membrane: lamina choriocapillaris: the inner choriocapillary lamina of the choroid of the eye. It contains a rich capillary plexus

Ruysch's muscle: muscular bundles of the fundus uteri

Ruysch's veins: 1. vv. vorticosae, s. vorticosa; 2. Retzius' veins, s. Retzius

S

s.: abbreviation for sacralis, sacral; pertaining to the sacrum (sacral nerve or segment)

s.: abbreviation for sinister, L.: left

sabulum conarii: s. acervulus

sabulosus, -a, -um, L.: sabulous; sandy

saccus, -i, m. L.: sac, pouch

saccus caecus: the fundus of the stomach

saccus endolymphaticus: endolymphatic sac: the terminal blind pouch of the endolymphatic duct situated in the aqueduct of the vestibule

saccus epiploicus: s. bursa omentalis

saccus herniosus: the hernial sac or pouch of peritoneum containing a hernia

saccus lacrimalis: the lacrimal sac: the upper slightly dilated part of the naso-lacrimal duct situated in the lacrimal fossa. It receives the lacrimal canaliculi

saccus lienalis: recessus lienalis: the splenic recess of the omental bursa towards the hilum of the spleen

sacciformis, -e: sacciform; shaped like a sac

saccularis, -e, L.: saccular; shaped like a small sac; in anatomy: pertaining to the sacculus of the labyrinth

sacculus, -i, m. L.: a small sac; a part of the membranous labyrinth of the internal ear, which lies in the spherical recess of the vestibule and is connected to the cochlear duct by the ductus reuniens. It gives off the endolymphatic duct

sacculi alveolares: alveolar saccules of the lung: the dilatations of the alveolar ductules. They give off the alveoli

sacculus ellipticus: s. utriculus

sacculus laryngis: s. appendix ventriculi laryngis (BNA)

sacer, -a, -um, L.: sacred

sacrococcygeus, -a, -um, L.: sacrococcygeal; pertaining to the sacrum and coccyx

sacroiliacus, -a, -um, L.: sacroiliac; pertaining to the sacrum and ilium; the term is applied to the articulation between the sacrum and ilium and its ligaments

sacrolumbalis, -e, L.: sacrolumbar; pertaining to the sacrum and the lumbar region

sacrum, -i, n. L.: os sacrum: the large triangular bone formed by the fusion of the five sacral vertebrae, and situated between the two hip-bones. Big objects were called "sacred" by the Greeks, which may account for the application of the term to the largest bone of the vertebral column. Alternatively it may have been the "sacrificial bone"

sacral nucleus: the cell group in the 2nd, 3rd and 4th segments of the sacral spinal cord, which give rise to parasympathetic fibres. They lie in the grey matter between the dorsal and ventral grey columns

sacralis, -e: sacral: pertaining to the sacrum

sacralisatio, -onis, f. L.: sacralization: the incorporation of the 5th lumbar vertebrae into the sacrum. It may be unilateral or otherwise incomplete

sagitta, -ae, f. L.: arrow

sagittalis, -e: sagittal; denoting direction parallel with the plane of the sagittal suture (e.g. sagittal plane) (sagitta: arrow)

sutura sagittalis: the sagittal suture of the skull between the right and left parietal bones

saliva, -ae, f. L.: the secretion of the various salivary and smaller mucous glands of the mouth

salivaris, -e: salivary; pertaining to the saliva

glandulae salivares: the salivary glands including the sublingual, submandibular and parotid glands

salivarius, -a, -um: salivary

salivatorius, -a, -um: salivatory; secreting saliva

salpinx, -gis, f. Gr.: trumpet; in anatomy: 1. the uterine tube; 2. the auditory tube

Sandström's bodies: glandulae parathyreoideae; the two pairs of superior and inferior parathyroid endocrine glands found usually posterior to the lobes of the thyroid gland within its capsule

sanguis, -inis, m. L.: blood

sanguiferus, -a, -um: sanguiferous; conveying or containing blood (ferre: to bear)

sanguineus, -a, -um: sanguineous; pertaining to blood

Santorini's cartilage: cartilago corniculata: corniculate cartilage: a small nodule of cartilage situated just above the arytenoid cartilage of the larynx in the aryepiglottic fold

Santorini's concha: s. concha nasalis suprema

Santorini's duct: s. ductus pancreaticus accessorius

Santorini's muscles: 1. m. procerus nasi; 2. m. risorius; 3. m. incisurae helicis: one of the rudimentary muscles of the auricle

Santorini's sulcus: s. incisura cartilaginis meatus acustici

Santorini's tubercle: the elevation in the aryepiglottic fold due to the corniculate cartilage

Santorini's veins: vena emissaria parietalis: the parietal emissary veins, which connect the superior sagittal sinus with the occipital veins by traversing the parietal foramina

saphena, -us (vena, nervous): the great or small saphenous vein or the saphenous cutaneous nerve of the leg (probably from saphin: hidden, Arabic term)

Sappey's fibres: smooth-muscle fibres, which Sappey describes as occurring in the check ligaments of the eye

Sappey's ligament: the posterior, thickened part of the temporomandibular joint

Sappey's nerve: a branch of the nerve to mylohyoid, which Sappey describes as piercing mylohyoid muscle to join the lingual nerve

Sappey's veins: venae paraumbilicales: the small veins which pass from the umbilicus to the left branch of the portal vein beside the round ligament of the liver. They form a communication between the epigastric veins and the portal circulation

sarcolemma, -atis, n. Gr.: the cell membrane bounding the muscle-fibre (sarx: flesh; lemma: sheath)

sarcoplasma, -atis, n. Gr.: sarcoplasm; the cytoplasm of the muscle cell, within which the myofibrils and other inclusions lie

sartor, -oris, m. L.: tailor

m. sartorius: the tailor's muscle; the long muscle crossing the upper and anterior parts of the thigh, which helps to flex, abduct and laterally rotate the thigh. Its name is based on the custom of tailors to sit cross-legged

scala, -ae, f. L.: staircase, ladder

scala tympani: the inferior compartment of the bony cochlea, which is bounded superiorly by the spiral and basilar laminae. It contains perilymph

scala vestibuli: the superior compartment of the bony cochlea above the spiral lamina. It contains perilymph

scalenus, -a, -um, Gr.: irregular, uneven

fossa scalenotrachealis: a term which has been applied to the interval between the scalene muscles and the trachea and esophagus

hiatus scaleni: the interval between the scalenus anterior and medius muscles

m. scalenus anterior, medius et posterior: the scalene muscles, which arise from the transverse processes of cervical vertebrae and insert onto the shaft of the 1st or 2nd rib

tuberculum m. scaleni anterioris: Lisfranc's tubercle: the scalene tubercle on the upper surface of the 1st rib, which gives insertion to the scalenus anterior muscle

scapha, -ae, f. Gr.: skiff, small boat or scooped out structure; in anatomy: the curved depression on the outer aspect of the auricle of the ear, between the helix and anthelix

scaphoideus, -a, -um: scaphoid; shaped like a boat

fossa scaphoidea: the small, oval, shallow depression on the inferior surface of the pterygoid process of the sphenoid bone, which is bounded by the division of the upper posterior part of the medial pterygoid plate

scapula, -ae, f. L.: the shoulder-blade: the flat triangular bone which articulates with the clavicle and humerus

scapularis, -e: scapular; pertaining to the scapula

scapus, -i, m. L.: shaft, stem

scapus pili: the shaft of a hair

Scarpa's fascia: the membranous layer of the superficial fascia of the lower part of the anterior abdominal wall. It forms the inferior boundary of the superficial perineal pouch and it fuses with the deep fascia of the thigh just below the inguinal ligament

Scarpa's foramina: the two inferior openings of the incisive canals from which the nasopalatine nerves emerge

Scarpa's ganglion: s. ganglion vestibulare

Scarpa's liquid: s. endolymph

Scarpa's membrane: the connective tissue membrane closing the fenestra rotunda of the middle ear

Scarpa's nerve: nervus nasopalatinus: the nasopalatine nerve, which originates from the maxillary branch of the trigeminal, traverses the pterygopalatine ganglion and sphenopalatine foramen and passes downwards and forwards on the nasal septum to pass through the median incisive foramen. It innervates the roof and septum of the nose and the mucosa of the hard palate

Scarpa's orifice: helicotrema: the aperture connecting the scala tympani with the scala vestibuli at the apex of the cochlea

Scarpa's triangle: s. trigonum femorale

sceletum, -i, n. Gr.: the skeleton (skeletos: dried-up)

Schachowa's tubes: the proximal convoluted tubules of the kidney

Schlemm's canal: s. sinus venosus sclerae

Schlemm's ligament: a term which has been applied to fibrous bands, which Schlemm described as strengthening the capsule of the shoulder joint medially

Schmidel's anastomosis: abnormal anastomoses between the inferior vena cava and the portal system; e.g. between the right and left gastric and the azygos veins

Schmidt–Lantermann's clefts: s. Lantermann's clefts

schneiderian membrane: tunica mucosa nasi: the mucous membrane of the nose

Schultze's cells: the olfactory cells of the nasal mucosa

Schultze's fascicle: fasciculus semilunaris: the semilunar tract between the gracile and cuneate tracts of the spinal medulla. It consists of descending fibres derived from the cuneate tract

Schütz's fascicle: the dorsal longitudinal fasciculus: an association pathway in the floor of the aqueduct, which has connections with the superior colliculus, the dorsal tegmental nucleus and the solitary tract

Schwalbe's corpuscles: taste-buds of the tongue

Schwalbe's nucleus: the medial vestibular nucleus

Schwalbe's space: spatium episclerale: the space between the fascial sheath of the eye-ball and the sclera

Schwann's sheath: s. neurilemma

Schwann's substance: the myelin around nerve-fibres

sclera, -ae, f. Gr.: tunica oculi: the tough, opaque outer fibrous tunic of the eyeball

scleromeninx: s. dura mater

scoliosis, Gr.: a lateral curvature of the vertebral column

scriptor, -oris, m. L.: writer

scriptorius, -a, -um: pertaining to a writer, or writing

calamus scriptorius: s. calamus

scrobiculus, -i, m. L.: a small ditch

scrobiculus cordis: the epigastric fossa: the slight depression of the surface of the epigastrium just below the xiphosternum

scrobis, -is, m. L.: ditch, trench

scrotum, -i, n. L.: the pouch of skin containing the testes

scrotalis, -e: scrotal; pertaining to the scrotum

scutiformis, -e, L.: scutiform; shaped like a shield (scutum: shield)

scyphus Vieussensi: s. infundibulum cochleae

sebum, -i, n. L.: tallow; the secretion of the sebaceous glands

sebaceus, -a, -um: sebaceous; pertaining to, or consisting of sebum

glandulae sebaceae: the sebaceous glands, which discharge their secretion into the hair follicles

secretio, -onis, f. L.: secretion; a substance which is separated and elaborated by cells or glands (secernere: to separate)

secretum, -i, n. L.: secreted substance (e.g. of a gland)

secretorius, -a, -um: secretory; effecting secretion

sectio, -onis, f. L.: section (secare: to cut)

secundus, -a, -um, L.: second

digitus secundus: the index, second or forefinger

segmentatio, -onis, f. L.: segmentation; cleavage of the egg

segmentum, -i, n. L.: segment

segmentum bronchopulmonale: bronchopulmonary segment; the largest independent subdivisions of the lungs, each with its own bronchi and branches of the pulmonary vessels

segmentum interannulare: interannular segment; part of a nerve-fibre between adjacent nodes of Ranvier

segmentum spinale: spinal segment: that part or segment of the spinal medulla which gives origin to a pair of spinal nerves

sella, -ae, f. L.: chair, saddle

sella turcica: Turkish saddle; the concavity on the dorsal aspect of the sphenoid, which accommodates the hypophysis and includes the tuberculum and dorsum sellae and the posterior clinoid process

semen, -inis, n. L.: seed; the fluid ejaculate, which contains the spermatozoa

seminalis, -e: seminal; containing, or pertaining to semen

colliculus seminalis: caput gallinaginis: seminal colliculus: the elevation of the urethral crest on the posterior aspect of the prostatic urethra, on whose apex opens the prostatic utricle and the ejaculatory ducts

vesicula seminalis: the seminal vesicle: the hollow sacculated viscera at the base of the bladder, which join the vasa deferentia to form the ejaculatory ducts

seminifer, -era, -erum: seminiferous; conveying semen (ferre: to bear)

tubuli seminiferi contorti: the convoluted seminiferous tubules of the testis, within which the spermatozoa develop

semi-, L.: in combination signifying half (Gr. synonym: hemi-)

semicanalis, -e: semicanal; a half canal

semicanalis m. tensoris tympani: the upper of the two semicanals of the musculotubal canal. It contains the tensor tympani muscle

semicanalis tubae auditivae: the semicanal or bony part of the auditory tube. It forms the lower part of the musculotubal canal

semicircularis, -e: semicircular; shaped like a half circle

canalis semicircularis: one of the three semicircular canals of the internal ear. They are disposed in planes at right angles to each other and contain the semicircular ducts of the membranous labyrinth

semidecussatio: a partial decussation or crossing

semidecussatio nervi optici: s. chiasma opticum

semidecussatio pyramidalis: s. decussatio pyramidum

semilunaris, -e: semilunar; resembling a half moon

valvulae semilunares: the semilunar valvules or segments forming the aortic and pulmonary valves

semimembranaceus, -a, -um: semimembraneus; semimembranous, partially membranous

m. semimembranaceus: one of the flexor hamstring muscles of the thigh, which arises from the ischial tuberosity and inserts into the medial condyle of the tibia

semiovalis, -e: semioval; partly egg-shaped

centrum semiovale: the semioval centre. The large mass of white substance seen in the cerebral hemisphere, sectioned horizontally at the level of the upper border of the corpus callosum

semispinalis, -e: partly pertaining to, or partly provided with spines

mm. semispinales: a part of transversospinalis. It is subdivided into semispinalis thoracis, cervicis and capitis and its fibres arise mainly from the transverse processes of the vertebrae and insert into their spines at a higher level. The uppermost part of the muscle gains attachment to the base of the skull

semitendinosus, -a, -um: half-tendinous

m. semitendinosus: one of the hamstring flexor muscles of the thigh, which arises from the ischial tuberosity and inserts into the medial aspect of the upper part of the shaft of the tibia

sensatio, -onis, f. L.: sensation

sensitivus, -a, -um: sensitive, sensory; pertaining to, or subserving sensation

sensus, -us, m. L.: sense, perception (sentire: to feel)

organa sensuum: the sense organs including the eye, ear and structures subserving olfaction and taste

septula, -ae, f. L.: a small septum

septula testis: the small septa forming the boundaries of the lobules of the testis

septum, -i, n. L.: partition, fence, dividing wall

septum alveoli: one of the small plates of bone which intervene between the dental alveoli

septum atriorum cordis: septum interatriale: the interatrial septum separating the atria of the heart

septum atrioventriculare cordis: pars membranacea septi atriorum (BNA): the atrioventricular septum: that part of the membranous septum which lies between the right atrium and left ventricle

septum bulbi urethrae: the septum of the bulb of the penis: a median, vertical, thin, fibrous partition which tends to divide the bulb into two halves

septum canalis musculotubarii: the thin lamella of bone which intervenes between the semicanal of the tensor tympani and that of the auditory tube

septum cartilagineum nasi: the cartilaginous part of the nasal septum

septum cervicale intermedium: the intermediate cervical septum: a longitudinal median septum, which passes from the arachnoid to the pia mater, covering the posterior median septum of the spinal medulla. It is most complete in the thoracic region

septum corporum cavernosorum clitoridis: the median fibrous septum intervening between the right and left corpora cavernosa of the clitoris

septum femorale (Cloqueti): the thin fibrous septum which closes the femoral ring

septum interalveolare: a bony septum between adjacent dental alveoli

septum intermusculare: a fibrous intermuscular septum separating adjacent muscles

septum interradiculare: the interradicular bony septum which intervenes between the roots of a molar, or premolar tooth

septum linguae: the thin, vertical, median, fibrous septum of the tongue, which divides it into a right and left half

septum mediastinalis: the mediastinum: the partition between the right and left pleural cavities

septum membranaceum nasi: the membranous anteroinferior part of the nasal septum

septum membranaceum ventriculorum cordis: the membranous part of the interventricular septum which forms the thin fibrous superposterior part of the latter

septum mobile nasi: the anterior, cartilaginous mobile part of the nasal septum

septum nasi osseum: the bony part of the nasal septum formed mainly by the vomer and perpendicular plate of the ethmoid

septum orbitale: the fibrous septum which passes from the margin of the orbit to blend with the aponeurosis of levator palpebrae superioris in the upper lid and with the tarsus of the lower eyelid

septum pectiniforme: s. septum penis

septum pellucidum: s. pellucidus

septum penis: the median fibrous septum intervening between the right and left corpora cavernosa of the penis

septum scroti: the median fibromuscular septum dividing the scrotum into a right and left part

septum sinuum frontalium: the thin lamella of bone between the right and left frontal sinuses

septum sinuum sphenoidalium: the bony partition intervening between the right and left sphenoidal sinuses

septum tubae: s. septum canalis musculotubarii

septum ventriculorum cordis: septum interventriculare; the interventricular septum of the heart. It is divided into a muscular and membranous part

serratus, -a, -um, L.: serrated; having a saw-like edge, dentated (serra: saw)

mm. serrati: the serratus anterior, posterior superior and posterior inferior muscles of the thorax

sutura serrata: a serrated suture where the bones interdigitate deeply with each other as in the interparietal suture

Serres' metafacial angle: the angle between the pterygoid process and the base of the skull

Sertoli's cells: the sustenticular or supporting cells which extend from the basement membrane of the seminiferous tubules towards their lumen. They probably help supply nutrients to the cells undergoing spermatogenesis

serum, -i, n. L.: whey; in anatomy: blood serum: the clear, defibrinated liquid of the blood, devoid of its cells. The term has also been applied to the fluid, which moistens serous membranes such as the peritoneum

serosus, -a, -um: serous; pertaining to, or resembling serum

tunica serosa: the serous membrane covering a viscus

sesamoideus, -a, -um, Gr.: resembling the seed of the sesame plant (sesamen: the sesame plant)

sesamoid bones: the small bones which tend to occur in tendons, which move over a bony surface or joint

sexus, -us, m. L.: sex

sexualis, -e: sexual; pertaining to sex, or to the sexual organs

Sharpey's fibres: collagen fibres which pass from periosteum into the underlying bone and attach the two together

Shenton's line: the continuous curved line seen in the normal radiograph, formed by the upper border of the obturator foramen and the inferomedial border of the neck of the femur

Shrapnell's membrane: the pars flaccida of the tympanic membrane: s. membrana flaccida

Sibson's fascia: membrana suprapleuralis: suprapleural membrane: a thickening of the endothoracic fascia, which is attached anteriorly to the inner aspect of the 1st rib. It arches posteriorly to be attached to the 7th cervical transverse process

Sibson's groove: the furrow sometimes occurring on the outer surface of the thorax and corresponding to the lower border of the pectoralis major muscle

sigma, -atis, n. Gr.: the Greek letter "S"; in anatomy: colon sigmoideum, the sigmoid colon, which joins the descending colon to the rectum and is somewhat S-shaped

sigmoides seu sigmoideus, -a, -um: S-shaped

flexura sigmoidea: the flexure of the sigmoid colon

simplex, -icis, L.: simple

sinciput, -itis, m. L.: the upper anterior part of the head, including the forehead as far back as the crown. The term has also been applied to the bregma (semi-caput: half of the head)

sine (prep. with ablative), L.: without

singularis, -e, L.: singular; sole, single

sinister, -tra, -trum, L.: left

sinistralis, -e, L.: sinistral; pertaining to the left

sinus, -us, m. L.: curved surface, bay

sinus aortae: sinus Valsalvae: the three slight dilatations of the aorta between the aortic semilunar valvules and the wall of the aorta

sinus cavernosus: the cavernous venous sinuses of the dura mater, situated on either side of the sella turcica. They drain by the superior and inferior petrosal sinuses into the end of the transverse sinus and the internal jugular vein. They give passage to the internal carotid arteries and abducent nerves and in their lateral wall lie the maxillary, oculomotor, ophthalmic and trochlear nerves

sinus circularis: s. Ridley's sinus

sinus coronarius: the short venous sinus which lies in the posterior part of the coronary sulcus and opens into the right atrium. Most of the veins of the heart open into it

sinus durae matris: the venous sinuses in the dura mater

sinus epididymidis: sinus of the epididymis: the invagination of the visceral layer of the tunica vaginalis, to form a recess between the posterolateral aspect of the testis and the epididymis

sinus ethmoidalis: cellulae ethmoidales: the ethmoidal air-cells

sinus falciformis major et minor: s. sinus sagittalis sup. et inf.

sinus frontalis: the right and left frontal sinuses in the inferior part of the squama

of the frontal bone. Each opens by the infundibulum into the middle meatus of the nose

sinus intercavernosus ant. et post.: the venous sinuses connecting the right and left cavernous sinuses in front of, and behind the infundibulum of the hypophysis

sinus jugularis: s. bulbus venae jugularis internae

sinus lactiferus: the dilated part of a lactiferous duct of the mammary gland, just before it enters the nipple

sinus maxillaris: the maxillary sinus: the air cavities in the bodies of the maxillae, which open into the hiatus semilunaris of the middle meatus of the nose

sinus Morgagni: sinus anales: the longitudinal mucosal recesses between the anal columns

sinus occipitalis: the venous sinus extending from the border of the foramen magnum, where it communicates with the termination of the sigmoid sinus and the internal vertebral plexuses, to the confluence of the sinuses. It lies in the attached border of the falx cerebelli and is usually unpaired

sinus paranasales: one of the air sinuses (ethmoidal, frontal, maxillary, sphenoidal) which open into the cavity of the nose

sinus pleurae: recessus costodiaphragmaticus: the costodiaphragmatic recess; the recess of the pleural cavity between the diaphragm and chest wall

sinus rectalis: s. sinus Morgagni

sinus rectus: straight sinus: the venous sinus situated in the line of union of the falx cerebri and tentorium cerebelli. It is formed by the union of the great cerebral vein and the inferior sagittal sinus and it usually drains into the left transverse sinus

sinus renalis: renal sinus: the concavity of the kidney containing the renal pelvis and calyces

sinus sagittalis sup. et inf.: the superior and inferior sagittal sinuses: the venous sinuses which lie in the free and attached borders of the falx cerebri

sinus sigmoideus: the sigmoid sinus which is the continuation of the transverse sinus. It lies on the inner surface of the mastoid part of the temporal bone and traverses the jugular foramen to become continuous with the internal jugular vein

sinus sphenoidalis: the sphenoid sinus; one of the paired air sinuses of the nose which occupy the body of the sphenoid and opens into the sphenoethmoidal recess

sinus sphenoparietalis: the sphenoparietal dural venous sinus which runs along the posterior free border of the lesser wing of the sphenoid bone to drain into the cavernous sinus

sinus tarsi: the oblique canal between the sulci of the talus and calcaneus. It is occupied by the interrosseous talocalcanean ligament

sinus tonsillaris: fossa tonsillaris: the tonsillar fossa between the palatoglossal and palatopharyngeal arches

sinus transversus: one of the paired transverse venous sinuses lying in the groove on the inner surface of the occipital bone at the attached border of the tentorium cerebelli. They extend from the confluence of the sinuses to the sigmoid sinuses

sinus trunci pulmonalis: the sinuses of the pulmonary trunk: the three slight dilatations of the pulmonary trunk between its semilunar valvules and wall

sinus tympani: the small depression on the medial wall of the tympanic cavity posterior to the promontory between the fenestra vestibuli and cochleae

sinus venarum cavarum: the sinus of the vena cava: the posterior part of the right atrium, into which enter the superior and inferior venae cavae

sinus venosus sclerae: Schlemm's canal; the small canal in the coreoscleral junction, which transmits aqueous humour from the anterior chamber to the anterior ciliary veins

sinus vertebrales longitudinales: an anterior and posterior pair of venous sinuses, which run longitudinally beside the posterior longitudinal ligament and along the internal aspect of the vertebral arches

sinuatrial (sinuauricular) node: s. Keith and Flack's node

sinusoid: resembling a sinus; the vascular canals in certain organs, such as the liver, spleen and bone marrow, which are lined by reticuloendothelial cells

situs, -us, m. L.: site, position

situs inversus: a developmental anomaly involving transposition of the viscera of the right and left sides of the body

Skene's glands: a few small urethral glands near the lower end of the female urethra, which drain by the paraurethral duct and may be homologous with the prostatic glands

smegma, -atis, n. Gr.: soap (*see also* sebum)

smegma praeputii: the product of glands of the prepuce and of epithelial breakdown of the surface of the glans and prepuce

Soemmering's foramen: fovea centralis retinae: a depression in the middle of the macula of the retina, where vision is most acute

Soemmering's ligament: the suspensory ligament of the lacrimal gland, which passes to the lacrimal fossa

Soemmering's substance: s. substantia nigra

solaris, -e, L.: solar; pertaining to the sun (sol: sun)

ganglion solare: s. ganglion coeliacum

plexus solaris: plexus coeliacus: the celiac plexus of autonomic nerve-fibres, which is distributed with the branches of the celiac artery

soleus, -a, -um, L.: resembling a sandal (solea: sandal)

m. soleus: the soleus muscle, which, arising from the soleal line of the tibia and the posterior aspect of the upper end of the fibula and inserting into the tendo calcaneus, acts as a flexor of the foot

solitarius, -a, -um, L.: solitary

tractus solitarius: the tract in the medulla oblongata concerned with the sense of taste. It receives fibres from the facial, glossopharyngeal and vagus nerves

solum, -i, n. L.: floor, lowest part, bottom

solum tympani: paries jugularis: the jugular or inferior wall of the tympanic cavity

soma, -atis, n. Gr. body

somaticus, -a, -um: somatic; pertaining to the body or somite

somatic nervous system: the voluntary, as opposed to the autonomic part of the nervous system

somita, -ae, f. L.: somite; one of about 44 paired metameric masses of mesoderm, which form beside the notochord in the embryo. They form skeletal, dermal and striated muscular tissues

spatium, -ii, n. L.: space

spatia anguli iridocornealis: iridocorneal, or Fontana's spaces: the spaces between the fibres of the pectinate ligament in the iridocorneal angle through which aqueous humour can pass into the sinus venosus sclerae

spatium epidurale: s. cavum epidurale

spatium episclerale: Tenon's space: the space between the fascial sheath of the eyeball and the sclera

spatia intercostalia: the intercostal spaces between the ribs

spatia interossea metacarpi et metatarsi: the four spaces between the metacarpal, or metatarsal bones

spatia intervaginalia: the spaces between the vaginal sheaths of the optic nerve

spatium perilymphaticum: the space between the osseous and membranous labyrinth. It includes the scala tympani and vestibuli

spatium retroinguinale: Bogros' space: the space between the peritoneum and the fascia transversalis, in which the external iliac artery is situated

spatium retroperitoneale: the retroperitoneal space between the peritoneum and the muscles of the posterior abdominal wall

spatia zonularia: Petit's spaces: the zonular spaces between the anterior and posterior fibres of the ciliary zonule around the margin of the lens of the eye

sperma, -atis, n. Gr.: spermatozoa

spermaticus, -a, -um: spermatic; pertaining to spermatozoa

funiculus spermaticus: the spermatic cord which starts at the upper pole of the testis and ends at the deep inguinal ring having traversed the scrotum and inguinal canal. It contains the ductus deferens and the testicular vessels, nerves and lymph vessels, and its walls are formed by cremaster muscle and the internal and external spermatic fascia

spermatid: the cell which develops into the spermatozoa without further division

spermatogenesis, -is, n.: the process of formation of spermatozoa, including the development and division of the spermatogonia and spermatocytes and the development of the spermatid into the spermatozoa (spermiogenesis)

spermatogonium, -ii, n.: the cell which undergoes mitotic division and eventually forms the primary spermatocyte

spermatozoon, -ntis, n.: the male reproductive cell, consisting of head, middle piece and tail

spermium, -ii, n.: the spermatozoon

spermiocyta, -ae, f.: the primary and secondary spermatocytes, which divide by meiosis to form the spermatid

sphenoidalis, -e, Gr.: sphenoid; wedge-shaped (sphen: wedge)

sphenoideus, -a, -um: sphenoidal; pertaining to the sphenoid bone

sphera, -ae, f. Gr.: sphere

sphaericus, -a, -um: spherical, globular

sphaeroideus, -a, -um: spheroid; resembling a sphere

sphincter, -eris, n. Gr.: a ring-like muscle which constricts an orifice

sphincter iridis: the circular smooth muscle-fibres around the iris, which by their contraction diminish the size of the pupil

spigelian lobe: s. lobus caudatus hepatis

Spigelius' line: s. linea semilunaris

spina, -ae, f. Gr.: thorn; the vertebral column

spina helicis: the cartilaginous process of the helix, which projects forwards near the crus

spina iliaca: iliac spine; the anterior and posterior, superior and inferior spines of the iliac bone

spina ischiadica: the ischial spine, which projects posteromedially from the body of the ischium and separates the greater from the lesser sciatic notch

spina mentalis: s. mentalis

spina nasalis anterior: the anterior nasal spine of the maxilla, which articulates with its fellow of the opposite side in the midline, projecting upwards from the inferior border of the piriform aperture of the nose

spina nasalis ossis frontalis: the nasal spine of the frontal bone. It projects down behind the nasal bones and forms part of the nasal septum

spina nasalis posterior: the posterior nasal spine of the horizontal lamina of the palatine bone, which articulates with its fellow in the midline and contributes to the posteroinferior part of the nasal septum

spina ossis sphenoidalis: the spine of the greater wing of the sphenoid bone, which projects downwards from the triangular part of the bone, between the petrous and squamous parts of the temporal

spinae palatinae: the longitudinal ridges on the inferior surface of the palatal process of the maxilla, which terminate posteriorly as small spines

spina scapulae: the spine of the scapula, whose lateral continuation is the acromion

spina suprameatum: the small suprameatal spine of the squamous part of the

temporal bone, situated on the posterosuperior border of the external acoustic meatus, just in front of the suprameatal triangle

spina trochlearis: the small trochlear spine at the medial end of the orbital surface of the frontal bone, which gives attachment to the trochlea of the superior oblique muscle

spina tympanica major et minor: the small greater and lesser tympanic spines, situated at the anterior and posterior ends of the tympanic notch

spinalis, -e: spinal; pertaining 1. to a spine; 2. to the vertebral column

ganglion spinale: one of the spinal ganglia of the dorsal roots of the spinal nerves, which contain the cell bodies of the afferent fibres

n. spinalis: spinal nerve: one of the paired nerves which emerge from each segment of the spinal medulla

spinatus, -a, -um: spinate: spined, having spines

spinosus, -a, -um: spinous; pertaining to a spine

spiralis, -e, Gr.: spiral (spira: that which is coiled)

Spitzka's bundle: the term has been variously applied to the fibres running from the cortex to the oculomotor nerve-nuclei, to fibres of the dorsolateral tract of the spinal cord, to the medial fibres of the medial lemniscus and to fibres connecting the oculomotor and abducent nuclei

Spitzka's nucleus: s. Perlia's nucleus

splanchnicus, -a, -um, Gr.: splanchnic; pertaining to the viscera (splanchnon: viscus)

splanchnocranium, -ii, n.: the skeleton of the face

splanchnologia, -ae, f.: splanchnology; knowledge of the viscera

splen, -nis, m. Gr.: spleen (L.: lien)

splenicus, -a, -um: splenic; pertaining to the spleen

splenium, -ii, n. Gr.: bandage, compress, fern

splenius, -a, -um: resembling bandage or fern leaf

mm. splenii capitis et cervicis: the splenius muscles, which arise from the lower part of the ligamentum nuchae and the spines of the upper six thoracic vertebrae, and insert into the mastoid process, superior nuchal line and transverse processes of upper cervical vertebrae

splenium corporis callosi: the posterior thickened part of the corpus callosum

spondylos, -i, n. Gr.: a vertebra

spongiosus, -a, -um, Gr.: spongy; of a sponge-like structure

substantia spongiosa: the spongy substance of bones, consisting of bony trabeculae disposed in a sponge-like way

spongiformis, -e: spongiform; resembling a sponge

spongioblast: 1. cells which are initially attached to the internal and external limiting membranes of the neural tube, but later separate from them to form neuroglia; 2. the diffuse amacrine cells of the retina, whose bodies are next the inner molecular layer, and whose processes end in it

spontaneus, -a, -um, L.: spontaneous (sponte: spontaneous)

spurius, -a, -um: spurious; simulated; false

costae spuriae: the false ribs: the five lower ribs, which do not articulate directly with the sternum

vertebrae spuriae: the false vertebrae: one of the fused vertebrae of the sacrum or coccyx

squama, -ae, f. L.: scale

squama frontalis: the squamous part of the frontal bone, which forms the anterior wall of the neurocranium

squama occipitalis: the squamous part of the occipital bone posterior and superior to the foramen magnum

squama temporalis: the squamous part of the temporal bone. The relatively thin plate of bone forming part of the lateral wall of the neurocranium

squamiformis, -e: squamiform: resembling a scale

squamatus, -a, -um; *squamosus*, -a, -um: squamous; scaly

sutura squamosa: the squamous suture formed by the articulation of the squama temporalis with the parietal bone

stabilitas, -tis, f. L.: stability, constancy (stare: to stand)

stapes, -edis, m. L.: stirrup (L. neologism: stare: to stand; pes: foot); in anatomy: the ossicle of the ear, which articulates with the incus, and whose base lies in the fenestra vestibuli

stapedius, -a, -um: pertaining to the stapes

m. stapedius: the stapedius muscle which arises from the pyramid and inserts into the neck of the stapes. It retracts the head of the latter and tilts the anterior part of its base from the fenestra vestibuli

staphylinus, -a, -um, Gr.: staphyline; shaped like a bunch of grapes; in anatomy: the uvula, pertaining to the uvula (staphyle: bunch of grapes)

staticus, -a, -um, L.: static; constant

statoconia, -ae, f. Gr.: (neologism) minute granules containing calcium carbonate, which rest on the macules of the utricle and saccule (statos: standing; konia: dust, lime-dust. Also called otoconia, or ear dust)

status, -us, m. L.: state, condition

stella, -ae, f. L.: star

stellatus, -a, -um: stellate; star-shaped

stellulae Verheynii: venae stellatae: the star-shaped arrangement of small veins on the surface of the kidney

stelliformis, -e: s. stellatus

Stenon's (Stensen's) canal: s. canalis incisivus

Stenon's (Stensen's) duct: s. ductus parotideus

Stenon's (Stensen's) foramen: foramen incisivum: one of the inferior openings of the incisive canals

stenosis, -is, f. Gr.: narrowing, constriction

sterilis, -e, L.: sterile; not fertile

sterilitas, -atis, f.: sterility, asepsis

sternum, -i, n. Gr.: the breast bone, including the manubrium and body of the sternum and the xiphoid process. It articulates with the clavicles and the costal cartilages of the upper seven ribs (sternon: breast)

sternalis, -e: sternal; pertaining to the sternum

sternoclavicularis, -e: sternoclavicular; pertaining to the sternum and clavicle

sternocostalis, -e: sternocostal; pertaining to the sternum and ribs

m. sternocleidomastoideus: the sternomastoid muscle which arises from the front of the manubrium sterni and the upper surface of the medial third of the clavicle, and inserts into the mastoid process and lateral part of the superior nuchal line. It turns the face to the opposite side

m. sternohyoideus: the sternohyoid muscle, which arises from the manubrium sterni and the medial end of the clavicle and inserts into the body of the hyoid bone

m. sternothyreoideus: the sternothyroid muscle, which arises from the manubrium sterni and first costal cartilage and inserts into the oblique line of the thyroid cartilage

Stieda's process: processus posterior tali: the posterior process of the body of the talus, which includes the medial and lateral tubercles and the groove for flexor hallucis longus

stigma, -atis, n. Gr.: mark, impression on the skin

Stilling's column: s. Clarke's column

stoma, -atis, n.: mouth: an opening of a cavity onto a surface or into another cavity (pl.: stomata)

stomachus, -i, m. Gr.: stomach (gaster)

stomadeum: stomodaeum; stomatodaeum: the ectodermal pit in the embryo, which is bounded by the mandibular, maxillary and frontonasal processes. Later it forms part of the mouth

stratum, -i, n. L.: layer, cover (sternere: to lay out)

stratum album profundum: the layer of white matter separating the colliculi from the central grey substance around the cerebral aqueduct of the midbrain

stratum bacillare retinae: the neuroepithelial layer of rods and cones in the retina

stratum cinereum: substantia grisea centralis; the central grey substance of the spinal cord or medulla

stratum circulare: a circular layer e.g. the circular layer of muscle around the gut

stratum corneum: the superficial horny keratinized layer of the epidermis

stratum cylindricum: s. stratum germinativum

stratum fibrosum capsulae articularis: the outer fibrous layer of an articular capsule

stratum gangliosum: the layer of Purkinje cells in the cerebellum

stratum germinativum: the deep layer of the epidermis, consisting of columnar epithelial cells lying against the dermis. By their proliferation these cells contribute to the more superficial layers

stratum griseum centrale: s. substantia grisea centralis

stratum germinativum unguis: the stratum germinativum of the nail matrix and bed

stratum granulosum: 1. the granular or innermost layer of the cerebellar cortex, which consists of small granule-cells. The mossy fibres synapse with the latter, which project to the molecular layer; 2. the innermost cellular layer of the ovarian follicle. It is continuous with the cumulus oophorus

stratum griseum colliculi superioris: the grey layer of the superior colliculus, situated beneath the stratum zonale and superficial to the stratum opticum. Many fibres from the optic tract end in this layer

stratum interolivare lemnisci: the fibres passing from the decussation of the lemnisci into the medial lemnisci between the olives

stratum lucidum: the transparent layer beneath the stratum corneum of the epidermis, which is believed to contain eleidin

stratum moleculare: the most superficial, molecular layer of the cerebellar cortex, in which there are synapses between Purkinje-, basket- and granule-cells, and in which the climbing fibres end

stratum pigmenti retinae: the outermost, pigmented layer of the retina

stratum reticulare: tunica corii: the deeper layer of the dermis, in which these is a net-like interlacing of collagen fibres

stratum spongiosum: the intermediate layer of the endometrium in the progestational phase, in which the glands are wide and tortuous

stratum synoviale: membrana synovialis: the synovial membrane which lines the capsule of synovial joints and contributes to the formation of the synovial fluid

stratum zonale: 1. the superficial white layer of the superior colliculus; 2. the thin layer of white matter covering the dorsal surface of the thalamus

stria, -ae, f. L.: streak, furrow

striae acusticae: striae medullares ventriculi quarti: the medullary striae of the 4th ventricle which, having arisen from the arcuate nuclei, pass dorsally and then laterally across the floor of the 4th ventricle to enter the cerebellum by the inferior cerebellar peduncle

stria longitudinalis: the medial and lateral longitudinal striae formed by longitudinally running nerve-fibres on the dorsal surface of the corpus callosum

stria mallearis: the streak visible on the lateral aspect of the tympanic membrane, corresponding to the attachment of the manubrium of the malleus

striae olfactoriae: the medial and lateral olfactory striae, which contain fibres passing from the olfactory trigone towards the paraterminal gyrus and limen insulae respectively

stria terminalis: the band of fibres which passes in the roof of the inferior horn of the lateral ventricle and then between the thalamus and the body of the caudate nucleus in the central part of the lateral ventricle. It connects the amygdaloid nucleus with the preoptic region and hypothalamus

striae transversae: the transverse streaks on the upper surface of the corpus callosum caused by its transversely running fibres

stria vascularis: the vascular mucous membrane of the lateral wall of the cochlear duct above the spiral prominence

striatus, -a, -um: striated

striatum: the caudate nucleus and putamen, whose similarity of structure and interconnections enable them to be considered together

corpus striatum: the caudate and lentiform nuclei considered together

stroma, -atis, n. Gr.: a covering; in anatomy: the connective tissue framework of a structure

stroma vitreum: the very fine fibrillar framework of the vitreous body of the eye

structura, -ae, f. L.: structure (struere: to build)

styloides, Gr.: styloid: resembling a style (stylos: style: small pointed rod used by the ancients for writing)

styloideus, -a, -um: styloid: resembling or pertaining to a style

processus styloideus: the styloid process extending downward from the lower surface of the temporal bone between the tympanic plate and the petrous part

sub- (prep. with abl.), L.: under

subacromialis, -e: subacromial; situated beneath the acromion

bursa subacromialis: the subacromial bursa between the acromion and the deltoid and the shoulder joint

subarachnoidalis, -e: subarachnoid; situated beneath the arachnoid

cavum subarachnoidale: the subarachnoid space between the pia mater and the arachnoid

subarcuatus, -a, -um: subarcuate; situated beneath an arch, e.g. beneath one of the arcuate ligaments

subchondralis, -e: subchondral; situated beneath a cartilage

subchordalis, -e: subchordal; situated beneath the notochord or vocal folds

subclavius, -a, -um: situated under the clavicle

subconjunctivalis, -e: subconjunctival; situated beneath the conjunctiva

subcorticalis, -e: subcortical; situated beneath the cortex

subcostalis, -e: subcostal; situated beneath a rib

subcutanaeus, -a, -um: subcutaneous; situated beneath the skin

subcutis, -is, f. L.: the subcutaneous tissue: the term has also been applied to the corium

subdeltoideus, -a, -um: subdeltoid; situated beneath the deltoid muscle

subdiaphragmaticus, -a, -um: subdiaphragmatic; situated beneath the diaphragm

subduralis, -e: subdural; situated beneath the dura mater

subhyoideus, -a, -um: subhyoid (subhyoidean); situated beneath the hyoid bone

sublingualis, -e: sublingual; situated under the tongue
submammalis, -e: submammary; situated beneath the mammary gland
submandibularis, -e: submandibular; situated beneath the mandible
submaxillaris, -e: submaxillary; situated beneath the maxilla
submentalis, -e: submental; situated below the chin
submicroscopicus, -a, -um: submicroscopic; too small to be visible with the microscope
submucosus, -a, -um: submucous; situated beneath a mucous membrane
suboccipitalis, -e: suboccipital; situated under the occiput
subpatelaris, -e: subpatellar; situated beneath the patella
subperitonaealis, -e: subperitoneal; situated beneath the peritoneum
subscapularis, -e: subscapular; situated beneath the scapula
subscleralis, -e: subscleral; situated beneath the sclera
subserosus, -a, -um: subserous; situated beneath a serous membrane
subiculum, -i, n. L.: an underlayer or support

subiculum cornu Ammonis: the part of the parahippocampal gyrus, which adjoins the hippocampus

substantia, -ae, f. L.: substance

substantia adamantina: the enamel which covers the crown of a tooth
substantia alba: the white substance, consisting of the nerve-fibres of the central nervous system
substantia compacta ossium: the compact substance or dense outer part of a bone
substantia corticalis: the cortical substance or outer layer of a structure
substantia eburnea: the dentin of a tooth; s. dentinum
substantia ferruginea: the deeply pigmented nerve-cells in the locus ceruleus
substantia gelatinosa (Rolandi): the gelatinous substance (of Rolando): the layer of grey substance which caps the posterior grey column of the spinal cord. It does not readily take neurological stains
substantia grisea centralis: the grey substance surrounding the cerebral aqueduct of the midbrain
substantia lentis: the substance of the lens of the eye, excluding its capsule and anterior layer of epithelium
substantia medullaris ossium: the medullary substance, marrow or soft inner part of a bone
substantia nigra: the grey substance, which lies between the crus cerebri and tegmentum of the cerebral peduncle of the midbrain. It contains markedly pigmented nerve-cells
substantia ossea: the cementum or bone-like substance which covers the root of the tooth
substantia perforata anterior: the anterior perforated substance between the olfactory trigone and the optic tract, which is pierced by numerous small blood vessels

substantia perforata posterior: the posterior perforated substance in the caudal part of the interpeduncular fossa. It is pierced by numerous small blood vessels

substantia reticularis alba: substantia Arnoldi: a thin layer of white matter on the medial surface of the parahippocampal gyrus

substantia reticularis grisea: the grey reticular substance: the part of the reticular formation of the medulla oblongata which lies dorsal to the olive and lateral to the root of the hypoglossal nerve

substantia reticulo-filamentosa: the basophilic network which can be shown by supravitally staining immature erythrocytes

substantia spongiosa: the spongy or canellous substance of a bone, which consists of a mesh of fine bony trabeculae

substantia vitrea: s. substantia adamantina

substitutio, -onis, f. L.: substitution, replacement

succenturiatus, -a, -um: succenturiate; accessory, additional

lien succenturiatus: an accessory or supernumerary spleen

succus, -i, m. L.: juice

sudor, -oris, n. L.: sweat

sulcus, -i, m. L.: groove, furrow

super (prep. with accusative) L.: above, over

supercilium, -i, m. L.: eyebrow

superciliaris, -e: superciliary; pertaining to the eyebrow

arcus superciliaris: the slightly elevated superciliary arch of the frontal bone, which extends laterally from the glabella above the margin of the orbit

superficialis, -e: superficial; situated on, or towards the surface

superior, -ius: situated further above, higher (comparative of super); can also denote direction

superus, -a, -um: that which is superior

supinatio, -onis, f. L.: the turning, or rotating of a structure, so that it lies on its back (supinare: to turn back)

supinatio manus: supination of the hand, in which position the palm is directed upward or forward and the back of the hand downward or backward, and the radius and ulna are parallel with each other

supinatio pedis: supination of the foot, which combines the movements of plantar-flexion and inversion

supinator, -oris, m. L.: that which supinates

m. supinator: the supinator muscle, which arises mainly from the lateral epicondyle of the humerus and the supinator crest of the ulna, and inserts into the lateral and anterior aspects of the upper part of the shaft of the radius

canalis supinatorius: the passage between the superficial and deep layers of supinator muscle by which the posterior interosseous branch of the radial nerve gains the back of the forearm

supra (prep. with accusative) L.: a prefix signifying above, over

supraacromialis, -e: supraacromial; situated above the acromion
suprachorioideus, -a, -um: suprachoroid; situated outside the choroid of the eye
supraclavicularis, -e: supraclavicular; situated above the clavicle
supracondyloideus, -a, -um: supracondylar; situated above a condyle
supradiaphragmaticus, -a, -um: supradiaphragmatic; situated above the diaphragm
supraduralis, -e: supradural; situated above, or outside the dura mater
supraglenoidalis, -e: supraglenoid; situated above the glenoid cavity
tuberculum supraglenoidale: the tubercle at the upper border of the glenoid cavity, from which arises the long head of the biceps brachii
suprahyoideus, -a, -um: suprahyoid; situated above the hyoid bone
suprainguinalis, -e: suprainguinal; situated above the inguinal region or inguinal ligament
supramalleolaris, -e: supramalleolar; situated above a malleolus
supramarginalis, -e: supramarginal; situated above a margin or border
supramastoidalis, -e: supramastoid; situated above the mastoid part of the temporal bone
supranuclearis, -e: supranuclear; situated above the nucleus of a nerve
supraorbitalis, -e: supraorbital; situated above the orbit
suprapatellaris, -e: suprapatellar; situated above the patella
suprapubicus, -a, -um: suprapubic; situated above the pubic bone
suprarenalis, -e: suprarenal; situated above the kidney
glandula suprarenalis: the suprarenal or adrenal gland
supraspinalis, -e: supraspinal; situated above a spine
suprasternalis, -e: suprasternal; situated above the sternum
supratrochlearis, -e: supratrochlear; situated above a trochlea
supravitalis, -e: supravital; surviving, e.g. supravital staining: the staining of living cells

supremus, -a, -um, L.: supreme: uppermost (superlative of superius)

sura, -ae, f. L.: the calf of the leg
suralis, -e: sural; pertaining to the calf of the leg

suspensorius, -a, -um, L.: suspensory; serving to suspend (suspendere: to hang up)

sustentaculum, -i, n. L.: support (sustentare: to support)
sustentaculum tali: the process which projects medially from the anterior end of the calcaneus, and supports the head of the talus

sutura, -ae, f. L.: suture; an articulation in which two contiguous bones of the skull are united by intervening periosteum
sutura coronalis: the coronal suture between the frontal and parietal bones
sutura dentata: dentate or serrated sutures, in which the bones interlock by tooth-like processes
sutura ethmoidomaxillaris: the ethmoidomaxillary suture between the orbital surfaces of the maxilla and ethmoid

sutura frontalis: the suture between the two halves of the frontal bones, which normally persists in part until about the eighth year, but may persist into adult life when it is usually termed the metopic suture

sutura frontoethmoidalis: the frontoethmoidal suture between the orbital surfaces of the frontal and ethmoid bones

sutura frontomaxillaris: the frontomaxillary suture between the frontal bone and the frontal process of the maxilla

sutura harmonia: a harmonic or plane suture between two plane surfaces of bone

sutura incisiva: the suture which may persist between the palatine parts of the maxilla and premaxilla. It runs from the incisive fossa to the interval between the lateral incisor and canine tooth

sutura infraorbitalis: an occasional infraorbital suture extending from the inferior orbital fissure to the infraorbital foramen

sutura intermaxillaris: the intermaxillary suture in the midline of the hard palate between the two maxillae

sutura internasalis: the internasal suture between the two nasal bones

sutura interparietalis: s. sutura sagittalis

sutura lacrimoconchalis: the lacrimoconchal suture between the lacrimal bone and the inferior nasal concha

sutura lacrimomaxillaris: the lacrimomaxillary suture between the lacrimal bone and the frontal process of the maxilla

sutura lambdoidea: the lambdoid suture between the parietal bones and the squamous part of the occipital bone

sutura limbosa: a serrated suture in which there is overlapping of the two bones

sutura mendosa: the suture occasionally persisting and separating the interparietal bone from the lower part of the squamous portion of the occipital bone

sutura metopica: a persistent sutura frontalis

sutura nasofrontalis: the frontonasal suture between the nasal and frontal bones

sutura nasomaxillaris: the nasomaxillary suture between the nasal bone and the frontal process of the maxilla

sutura notha: false sutures: irregular bony lines which appear on one surface of the bone but do not extend throughout its depth

sutura occipitomastoidea: the suture between the occipital bone and the mastoid part of the temporal bone. It is continuous with the lambdoid suture

sutura palatina mediana: the median palatine suture between the horizontal laminae of the two palatine bones

sutura palatina transversa: the transverse palatine suture between the palatine processes of the maxillae and the horizontal laminae of the palatine bones

sutura palatomaxillaris: the suture between the palatine bone and the maxilla. It may refer specifically to the suture between the orbital process of the palatine bone and the maxilla in the floor of the orbit

sutura parietomastoidea: the parietomastoid suture where the mastoid angle of the parietal bone articulates with the mastoid part of the temporal bone

sutura petrosquamosa: the petrosquamous suture, visible as a thin line in the middle cranial fossa between the petrous and squamous parts of the temporal bone

sutura sagittalis: the sagittal suture between the two parietal bones

sutura serrata: serrated suture: s. sutura dentata

sutura sphenoethmoidalis: the sphenoethmoidal suture between the sphenoid and ethmoid bones

sutura sphenofrontalis: the sphenofrontal suture between the greater and lesser wings of the sphenoid and the frontal bone

sutura sphenomaxillaris: the occasional sphenomaxillary suture between the pterygoid process of the sphenoid bone and the body of the maxilla

sutura sphenoorbitalis: the sphenoorbital suture between the orbital process of the palatine bone and the sphenoidal concha

sutura sphenoparietalis: the sphenoparietal suture between the greater wing of the sphenoid and the parietal bone

sutura sphenosquamosa: the sphenosquamous suture between the greater wing of the sphenoid and the squamous part of the temporal bone

sutura sphenozygomatica: the sphenozygomatic suture between the greater wing of the sphenoid and the zygomatic bone

sutura squamomastoidea: the squamomastoid suture between the squamous and mastoid parts of the temporal bone. The semiobliterated suture may be seen on the lateral aspect of the mastoid process of the adult skull

sutura zygomaticofrontalis: the frontozygomatic suture between the zygomatic process of the frontal and the frontal process of the zygomatic bones

sutura zygomaticomaxillaris: the zygomaticomaxillary suture between the zygomatic bone and the zygomatic process of the maxilla

sutura zygomaticotemporalis: the temporozygomatic suture between the zygomatic bone and the zygomatic process of the temporal bone

Suzanne's gland: a small median mucous gland in the floor of the mouth

sylvian artery: a. cerebri media: the middle cerebral artery, which branches from the internal carotid and passes into the lateral cerebral sulcus

Sylvius' aqueduct: s. aqueductus cerebri Sylvii

Sylvius' fissure: s. fissura cerebri lateralis (Sylvii)

Sylvius' substance: s. substantia grisea centralis

Sylvius' valve: s. valvula venae cavae inferioris

Sylvius' vein: a term which has been applied to the middle cerebral veins

symmetria, -ae, f. Gr.: symmetry: the similarity of structures on each side of, or around an axis

sympathicus, -i, m. Gr.: sympathetic; in anatomy: the sympathetic part of the autonomic nervous system

symphysis, -is, f. Gr.: a joint, such as the symphysis pubis, where the adjoining bones are united by fibrocartilage

syn-, Gr.: prefix signifying with, together

synapsis, -is, f. Gr.: synapse; the region of contact between axon and neuron, or axon and dendrite, where the nerve impulse is transmitted from one neuron to another (synaptein: join)

synarthrosis, -is, f. Gr.: junctura fibrosa; a joint in which the bones are joined together by fibrous tissue, which allows but little movement

synchondrosis: a joint where the bones are united by cartilage

synchronos: synchronous; occurring at the same time

syncytium, -ii, n. Gr.: a mass of protoplasm containing many nuclei which do not appear to be separated from each other by cell membranes. Sometimes supposed to be formed by the fusing of adjacent cells (syn: together; cytos: cell; Gr.)

syndesmologia, -ae, f. Gr.: syndesmology; the branch of anatomy which is concerned with joints and ligaments

synergia, -ae, f. Gr.: synergy; working together, e.g. a muscle, which assists another one

synergist: a structure co-operating with another, especially muscles

synostosis, -is, f. L.: bony union of two bones initially separate

synovia, -ae, f. Gr.: the synovial fluid contained in, and lubricating synovial joints

synovialis, -e: synovial; pertaining to synovia

systema, -atis, n. Gr.: system

systema lymphaticum: the lymphatic system

systema nervosum: the nervous system

systema nervosum autonomicum: the autonomic nervous system: the part of the nervous system which innervates smooth and cardiac muscle and glands, or those structures, largely under involuntary control. It includes both efferent and afferent fibres and is divided into the sympathetic and parasympathetic systems. Commonly a viscus is innervated by both, their action being mutually antagonistic

systema nervosum centrale: the central nervous system including the brain and spinal cord

systema nervosum parasympathicum: s. parasympathetic nervous system

systema nervosum periphericum: the peripheral nervous system, which includes all nervous tissue apart from the brain and spinal cord

systema nervosum sympathicum: the sympathetic nervous system: the part of the autonomic nervous system which originates from the first thoracic down to the second lumbar segment of the spinal cord. It consists generally of pre- and postganglionic fibres, the synapses between them being in the sympathetic chain or in more peripheral ganglia. It is antagonistic in action to the parasympathetic system. It has been described as preparing the body to cope with an emergency in the external environment

systema nervosum vegetativum: s. systema nervosum autonomicum

systema organorum viscerale: the visceral nervous system: s. systema nervosum autonomicum

systema sceleti: the skeletal system

systole, -es, f. Gr.: contraction; the contraction phase of the heart beat

T

tabatière, Fr.: snuff-box

fossa tabatière (fossa anatomique): foveola radialis: the anatomical snuff-box: the depression on the dorsolateral aspect of the corpus between the tendons of abductor pollicis longus, extensor pollicis brevis and extensor pollicis longus

tabula, -ae, f. L.: table

tabula vitrea: s. lamina interna cranii

tactilis, -e, L.: tactile; pertaining to touch

tactus, -us, m. L.: touch, contact, the sense of touch

taenia, -ae, f. L.: band, ribbon

taenia acustica: stria medullaris

taenia chorioidea (ventriculi lateralis): the line along which the ependyma of the lamina affixa and the pia are reflected from the dorsal surface of the thalamus onto the choroid plexus of the lateral ventricle

taenia coli: the three bands of longitudinal muscle on the wall of the colon, which are named the taenia mesocolica: corresponding to the attachment of the transverse mesocolon; the taenia libera: opposite to the latter and the taenia omentalis: the band found in the line of attachment of the greater omentum in the case of the transverse colon

taenia fimbriae: a term which has been applied to the line of attachment of the choroid plexus of the lateral ventricle's inferior horn to the lateral border of the fimbria

taenia fornicis: the line of attachment of the choroid plexus on the fornix

taenia pylori: thickened bands of longitudinal muscle which have been described on the anterior and posterior walls of the pylorus

taenia terminalis: s. crista terminalis

taenia thalami: the line at the dorsomedial border of the thalamus, marking the reflection of the ependyma of the 3rd ventricle, and the pia on the dorsal surface of the thalamus onto the tela choroidea of the 3rd ventricle

talus, -i, m. L.: the ankle bone: the bone of the tarsus, which articulates with the tibia and fibula at the ankle joint

talaris, -e: talar: pertaining to the talus

tangentialis, -e, L.: tangential; corresponding to the direction of a tangent (tangere: to touch)

tapetum, -i, n. Gr.: carpet

tapetum alveoli: s. periodontium

tapetum chorioideae: membrana versicolor of Fielding: tapetum lucidum: the layer of iridescent cells outside the choriocapillary lamina of the choroid, which causes the eyes of certain animals, especially carnivores, to shine in the dark. In other animals the tapetum is a fibrous layer

tapetum corporis callosi: the fibres from the temporal and inferior parts of the occipital lobes, passing to the posterior part of the corpus callosum above the lateral ventricle

tapetum opticum: a term which has been applied to the optic radiation as it passes superior to the inferior, and lateral to the posterior horn of the lateral ventricle

Tarin's fossa: fossa interpeduncularis: the depressed interpeduncular fossa between the cerebral peduncles. Its floor consists of the posterior, perforated substance, in front of which are the mammillary bodies, tuber cinereum and infundibulum

Tarin's hole, s. hiatus canalis n. petrosi major

Tarin's plate: s. velum medullare inferius

Tarin's space: s. substantia perforata posterior

tarsus, -i, m. Gr.: 1. the instep; the posterior part of the foot which includes the talus, calcaneus, navicular, cuboid, and three cuneiform bones; 2. the dense fibrous plates which form the framework of the eyelids

glandulae tarsales: s. meibomian glands

tarsalis, -e; *tarseus,* -a, -um: tarsal; pertaining to the tarsus of the foot, or eyelid

Tawara's node: s. Aschoff–Tawara's node

Tawara's stalk: the atrioventricular bundle and its right and left crurae

tectorius, -a, -um, L.: tectorial; of the nature of a covering (tegere: to cover)

membrana tectoria: s. membrana

tectum, -i, n. L.: roof, cover

tectum mesencephali: the part of the midbrain dorsal to the cerebral aqueduct. It includes the superior and inferior colliculi, their brachii and the tectal lamina

tegmen, -inis, m. L.: cover

tegmen tympani: the thin plate of the petrous part of the temporal bone, which forms the roof of the tympanic cavity and the lateral wall of the bony part of the pharyngotympanic tube

tegmen ventriculi quarti: the roof of the 4th ventricle, which is formed by the superior cerebellar peduncles, the superior and inferior medullary vela, the upper surface of the nodule and the tela choroidea

tegmentalis, -e: tegmental; pertaining to a tegmen or cover

tegmentum, -i, m. L.: tegmen, cover

tegmentum pedunculi: the dorsal part of the cerebral peduncle between the substantia nigra and the cerebral aqueduct

Teichmann's plexus: the lymphatic plexuses in the wall of the stomach

tela, -ae, f. L.: web or woven tissue

tela chorioidea ventriculi: the part of the pia mater which comes in contact with the ependyma to form the roof of the 3rd and part of the 4th ventricles

tela conjunctiva: connective tissue

tela subcutanea: the subcutaneous connective tissue which forms the superficial fascia

tela submucosa pharyngis: the fibrous layer of the pharynx between the mucosa and the muscular layer. It is continuous above with the pharyngobasilar fascia which forms the superficial fascia

tela subserosa: the connective tissue layer beneath a serous membrane

tela vasculosa: s. plexus chorioideus, s. chorioideus

telencephalon, -i, n. Gr.: endbrain (telos: end), the part of the forebrain which is composed of the cerebral hemispheres and the lamina terminalis

telodendron, -i, n. Gr.: the terminations of a dendrite

telolemma, -atis, n.: the part of the axolemma covering the motor end-plates

telophasis, -es, f. Gr.: telophase; the final phase of mitosis, when the two sets of chromosomes have separated from each other and the two daughter nuclei form their membranes

tempora, -um, n. plur. L.: the temples: the region of the temporal fossae at the sides of the head

temporalis, -e: temporal; pertaining to the temple

tendo, -inis, f. L.: tendon

tendineus, -a, -um; *tendinosus,* -a, -um: tendinous; resembling or pertaining to a tendon

Tenon's capsule: s. vagina bulbi

Tenon's space: s. spatium episclerale

tensor, -oris, m. L.: any muscle that stretches or makes more tense

tendus, -a, -um: stretched

tentorium, -ii, n. L.: tent

tentorium cerebelli: the fold of the dura mater which forms the roof of the posterior cranial fossa and thus covers the upper surface of the cerebellum

tentorium hypophyseos: s. diaphragma sellae

tenuis, -e, m. L.: thin, delicate

intestinum tenue: the small intestine, including the duodenum, jejunum and ileum

tenus, (prep with abl.) L.: reaching up to, as far as

teres, -etis, L.: round, rounded off, well-turned (terere: to rub)

lig. teres uteri (Hunteri): lig. rotundum: the round ligament which is attached to the uterus, just below the entrance of the uterine tube. It passes through the broad ligament and inguinal canal to end in the labium majus

m. pronator teres: the pronator teres muscle of the forearm, which arises from

the lower part of the medial supracondylar ridge and medial epicondyle of the humerus and from the coronoid process of the ulna and inserts into the middle of the lateral aspect of the shaft of the radius

m. teres major: the teres major muscle, which arises from the lower third of the lateral border of the scapula, and inserts into the lesser tubercular crest of the humerus

m. teres minor: the teres minor muscle, which arises from the upper two thirds of the lateral border of the scapula, and inserts into the greater tubercle of the humerus

terminus, -i, m. L.: term; 1. boundary; 2. scientific expression or name

terminus technicus: technical term

terminalis, -e: terminal; pertaining to a boundary, or end

alveolus terminalis: terminal or pulmonary alveolus; an air sac of the lungs in the form of terminal dilatations of bronchioles

a. terminalis: a terminal branch of an artery, having no further ramifications

conus terminalis: conus medullaris, the inferior conical extremity of the spinal cord

filum terminale: the thread-like prolongation of the pia mater below the conus medullaris. It extends down as far as the coccyx

linea terminalis: s. linea

tertius, -a, -um, L.: third

testiculus, -i, m.: testis

testicularis, -e: testicular; pertaining to the testis

testiculatus, -a, -um: testiculate; shaped like the testis

testis, -is, m. L.: the male gonad

thalamus, -i, n. Gr.: room or chamber

thalamus: (thalamus opticus) the ovoid ganglionic mass in the lateral wall of the 3rd ventricle of the brain. Amongst other functions it relays sensory impulses to the cortex

thalamicus, -a, -um: thalamic: pertaining to the thalamus

Thebesius' foramina: foramina venarum minimarum cordis: the entrances of the small veins into the right atrium

Thebesius' valve: s. valvula sinus coronarii

Thebesius' veins: venae cordis minimae; the smallest veins which drain the wall of the heart and open directly into its cavities—mainly the atria

theca, -ae, f. Gr.: capsule, sheath

theca folliculi: the external and internal tunicae or capsules, which consist of connective tissue stroma and enclose the vesicular ovarian follicles

Theile's canal: the transverse sinus of the pericardium, which is situated behind the pulmonary trunk and aorta and in front of the atria. The passage is lined with pericardium and is formed in the embryo by the breakdown of the dorsal mesocardium

Theile's glands: mucous glands in the wall of the cystic duct and neck of the gall bladder

thenar, -aris, n. Gr.: the palm of the hand; in anatomy: the fleshy mound at the base of the thumb: the ball of the thumb

Thomson's fascia: the iliopectineal fascia: the fascia below the level of the inguinal ligament, which separates the femoral vessels from the iliopsoas and the femoral nerve. Medially it is attached to the pectineal line and is continuous with the pectineal fascia. Laterally it covers iliopsoas and superiorly is continuous with the psoas and iliacus fascia

thorax, -acis, m. Gr.: the chest

thoracalis, -e; *thoracicus*, -a, -um: thoracic; pertaining to the chest

Thorel's bundle: a bundle of myocardial fibres which has formerly been described as connecting the sinuatrial and atrioventricular nodes

thrombocyta, -ae, f. Gr.: thrombocyte: blood platelet; the small disk-shaped bodies of the blood, which are concerned with blood clotting (thrombos: a clot formed by coagulation of the blood)

thymus, -i, m. Gr.: the thymus gland; a lymphoid gland situated in the lower cervical and the anterior part of the superior mediastinal regions. It is relatively large in the new-born child but retrogresses gradually after the second year

thymicus, -a, -um: thymic; pertaining to the thymus gland

thyreoidea, -ae, f. Gr.: glandula thyreoidea: the thyroid ductless gland which consists of an isthmus lying in front of the upper part of the trachea and two lobes on either side of the latter. It produces the hormone thyroxin (thyreos: shield)

cartilago thyreoidea: the thyroid cartilage of the larynx, which consists of a right and left flat lamina each of these giving rise to superior and inferior horns from their posterior borders. They unite together at their anterior borders

thyreoideus, -a, -um: thyroid; resembling a shield, pertaining to the thyroid gland or cartilage

tibia, -ae, f.: a musical wind instrument of tubular form; in anatomy: the shin-bone, which articulates above with the femur and below with the talus. The fibula lies lateral to it

tibialis, -e: tibial; pertaining to the tibia

Tiedemann's glands: s. Bartholin's glands

Tiedemann's nerve: a plexus of sympathetic nerve-fibres, which have been described as accompanying the central artery of the retina

tigroid bodies: s. Nissl's bodies

Tomes' fibres: the dentinal processes of the odontoblasts extending into the dentinal tubules

Tomes' layer: the granular layer of dentin, which may be seen in ground sections near the dentin-cement boundary

Tomes' processes: the homogenous part of the ameloblast, which is being transformed into, or giving rise to enamel

tonsilla, -ae, f. L.: a pointed stake: the palatine tonsil or a similarly shaped structure

tonsilla cerebelli: the rounded lobule situated on the anterior part of the inferior surface of the cerebellum. Medially it is continuous with the uvula

tonsilla intestinalis: s. Peyer's patches

tonsilla lingualis: the lingual tonsil: the aggregation of lymph follicles in the submucosa of the pharyngeal part of the tongue

tonsilla palatina: the palatine tonsil, which consists of aggregations of lymphoid tissue in the fauces between the palatoglossal and palatopharyngeal arches

tonsilla pharyngea: the pharyngeal tonsil consisting of lymphoid tissue, situated in the roof of the pharynx posterosuperior to the opening of the auditory tube

tonsilla tubaria: tubal tonsil: the aggregation of lymphoid tissue, situated beside the opening of the auditory tube in the pharynx. It includes Gerlach's tonsil

tonsillaris, -e: tonsillar; pertaining to the tonsil

tonus, -i, m. Gr.: tone; the tension in muscles which are not engaged in active movement; the sound of the voice

tonicus, -a, -um: tonic, tense, e.g. as a muscle undergoing contraction

Topinard's angle: angulus facialis: the facial angle of Topinard between a line joining the glabella and the anterior nasal spine and the one joining the latter point and the external auditory meatus

torsio, -onis, f. L.: rotation, twisting (torquere: to twist)

torus, -i, m. L.: protuberance, swelling

torus frontalis: the median protuberance of the frontal bone or glabella between the eyebrows

torus occipitalis: an occasional ridge on the occipital bone, just above the superior nuchal line

torus palatinus: an occasional bony protuberance in the median line on the inferior surface of the hard palate

torus tubarius: the tubal elevation lying dorsal and posterior to the pharyngeal opening of the auditory tube. It is raised by the base of the cartilage of the auditory tube

torus uretericus: plica interureterica: the interureteric fold on the internal surface of the bladder passing between the openings of the ureters

torus uterinus: a term which has been applied to the slight horizontal ridge on the posterior aspect of the cervix of the uterus, which is formed by the union of the right and left rectouterine folds

totalis, -e: total (totus: complete, total)

trabecula, -ae, f.: small beam (trabs: beam)

trabeculae carneae: the muscular trabeculae which project into the cavities of the ventricles of the heart as ridges or bundles. They include the papillary muscles

trabeculae cinereae: s. massa intermedia

trabeculae corporum cavernosum: the fibrous trabeculae, which form the spongy framework of the corpora cavernosa of the penis

trabeculae lienis: the fibrous trabeculae which pass into the interior of the spleen from its capsule and form the framework which supports the splenic pulp

trabecularis, -e: trabecular; pertaining to trabeculae

trabs, -bis, f. L.: beam

trabs cerebri: s. splenium corporis callosi

trachea, -ae, f. Gr.: the windpipe, which extends from the larynx until it bifurcates to give rise to the two bronchi (trachys: rough)

trachealis, -e: tracheal; pertaining to the trachea

tractus, -us, m. L.: wool pulled out for spinning, hence tract, or that which is drawn out; in anatomy: that which connects different structures, e.g. a nervous pathway of the central nervous system (trahere: to draw)

tractus digestorius: the digestive or alimentary tract including the mouth, pharynx, esophagus and gut

tractus iliotibialis (Maissiati): the thickened lateral part of the fascia lata of the thigh, extending from the iliac crest to the lateral condyle of the tibia and giving insertion to much of gluteus maximus

tractus olfactorius: the olfactory tract, which extends from the olfactory bulb to the trigone, where it divides into the medial and lateral striae

tractus opticus: the optic tract, which extends from the optic chiasm to the lateral geniculate body

tractus spinocerebellaris anterior: fasciculus anterolateralis superficialis (Gowersi): the anterior spinocerebellar tract, which lies in the lateral funiculus of the spinal cord and probably conveys impulses derived from collaterals of the posterior funiculi to the cerebellum by the superior cerebellar peduncle

tractus spinocerebellaris posterior: fasciculus spinocerebellaris dorsalis: (Flechsig's tract) the posterior spinocerebellar tract, which lies in the lateral funiculus of the spinal cord and conveys fibres from the thoracic nucleus to the cerebellum by the inferior cerebellar peduncle

tragus, -i, m. L.: goat; in anatomy: the projection of the front of the auricle, which extends backwards over the opening of the external auditory meatus (from the supposed resemblance of the hairs there, to the goat's beard)

tragi: the hairs in the external auditory meatus

tragicus, -a, -um: tragic; pertaining to the tragus

transparens, -entis, L.: transparent, translucent

transversus, -a, -um, L.: transverse, placed crosswise at right angles to the long axis of a structure (transvertere: to turn)

transversalis, -e; *transversarius*, -a, -um: s. transversus

processus transversarius: the transverse process of the vertebrae, which generally projects laterally from the junction of the pedicle and lamina

trapezion, -i, n. Gr.: table

trapezialis, -e: trapezial; pertaining to a trapezium

corpus trapezoideum: the fibres from the cochlear nuclei, which are crossing to the opposite side to form the lateral lemniscus in the pons

os trapezoideum: the most lateral bone of the distal row of the carpus

m. trapezius: the muscle which arises mainly from the ligamentum nuchae and spines of the thoracic vertebrae and inserts into the lateral third of the clavicle, the acromion and the spine of the scapule. It rotates the scapula, and draws it backwards

trapezoid: trapeziform; having the shape of a trapezium, which is a quadrilateral, with two sides parallel to each other

Treitz's fascia: a layer of fascia immediately behind the head of the pancreas

Treitz's fossa: recessus duodenojejunalis: s. recessus duodenallis sup. et inf.

Treitz's muscle: m. suspensorius duodeni: the suspensory muscle of the duodenum: a band of smooth muscle and collagen fibres which passes from the right crus of the diaphragm to the upper part of the duodenojejunal flexure

Treves' bloodless fold : plica ileocecalis: the ileocecal fold of peritoneum, which passes from the front of the terminal part of the ileum to the mesentery of the appendix

tri-, L.: (tres, tria) prefix meaning three

triangularis, -e, L.: triangular

triceps, -ipitis, L.: having three heads

m. triceps brachii: triceps muscle which arises by three heads from the lower lip of the glenoid cavity and from the posterior aspect of the humerus, above and below the sulcus for the radial nerve. It inserts into the olecranon process of the ulna

tricuspidalis, -e, L.: tricuspid; having three cusps or pointed projections

trigeminis, -a, -um, L.: trigeminal, triple, divided into three parts

nervus trigeminus: the trigeminal or 5th cranial nerve which divides into three nerves, namely the ophthalmic, maxillary and mandibular

trigonum, -i, n. L.: triangle

trigonum acustici: s. area acustica

trigonum caroticum: Malgaigne's fossa: fossa carotica; Gerdy's fossa; the muscular triangle in the neck bounded by the anterior border of sternocleidomastoid, the superior belly of omohyoid and stylohyoid and the posterior belly of the digastric

trigonum cervicale: cervical triangle: one of the triangular areas into which the neck may be divided

trigonum deltoideopectorale: infraclavicular fossa: Mohrenheim's triangle: the depressed triangle or fossa bounded by the superior edge of pectoralis major, the anterior margin of deltoid and the clavicle. It gives passage to the cephalic vein and to the deltoid branch of the thoracoacromial artery

trigonum femorale: Scarpa's triangle: the femoral triangle in the upper part of

the front of the thigh, which is bounded by the sartorius, the medial border of adductor longus and the inguinal ligament

trigona fibrosa cordis: fibrous trigones: the two roughly triangular masses of fibrous tissue which lie between the aortic arterial ring and the right and left atrioventricular rings

trigonum lemnisci: the triangular area between the inferior colliculus, the superior cerebellar peduncle and the midline, where the lateral lemniscus approaches the surface of the tegmentum

trigonum lumbale (Petiti): Petit's triangle: the lumbar triangle of the loin, which is bounded by the external oblique and inferior margin of the latissimus dorsi muscles, and by the iliac crest

trigonum nervi vagi: s. ala cinerea

trigonum vesicae (Lieutaudi): Lieutaud's triangle: a triangular area of the mucous membrane of the bladder, whose apices are the openings of the ureters and the internal urethral orifice. The mucosa here is smooth and closely adherent to the muscular layer

trigonalis, -e: trigonal; pertaining to a triangle

trigonus, -a, -um; *triquetrus*, -a, -um: triangular

triticum, -i, n. L.: wheat

triticeus, -a, -um: triticeous; resembling a grain of wheat

trochanter, -eris, n. Gr.: runner

trochanter major: the greater trochanter: the bony projection from the lateral part of the upper end of the shaft of the femur, which gives insertion to various muscles

trochanter minor: the lesser trochanter: the bony projection on the posteromedial aspect of the shaft of the femur, just below the neck. It gives insertion to iliopsoas

trochanter tertius: the occasional projection of the gluteal tuberosity of the femur

trochantericus, -a, -um: trochanteric; pertaining to a trochanter

trochlea, -ae, f. Gr.: pulley

trochlea femoris: the patellar surface of the femur: the shallow groove on the anterior aspect of the articular surface of the condyles which lodges the patella

trochlea humeri: the pulley-shaped body of the distal end of the humerus, which articulates with the ulna

trochlea m. obliqui oculi superioris: the fibrocartilaginous pulley at the anterior end of the junction of the medial and superior walls of the roof of the orbit, through which passes the superior oblique muscle

trochlea phalangis: the articular surface at the distal end of the proximal and middle phalanges of the fingers and toes

trochlea tali: the pulley-shaped part of the body of the talus which articulates with the tibia and fibula

trochoides, -es, m. Gr.: trochoid; resembling a wheel

articulatio trochoidea: trochoginglymus: a pivot-like joint in which the cylinder-like part of one bone rotates within the concavity of another, e.g. the proximal radioulnar joint

Trolard's plexus: s. rete canalis hypoglossi

Trolard's vein: an anastomotic vein between the superficial middle cerebral vein and the superior sagittal sinus

Tröltsch's recess: s. recessus membranae tympani anterior et posterior

trophoblast, -os, n. Gr.: the outer wall of the blastocyst which differentiates into two layers—the syncytio- and cytotrophoblast—when the embryo becomes embedded in the uterine wall. These form the outer layer of the chorion and its villi and help form the placenta (trophos: feeding)

truncus, -i, m. L.: trunk; in anatomy: the body apart from the head and extremities; the main stem of a vessel or nerve

truncus bronchomediastinalis: the right or left bronchomediastinal lymph ducts, which collect the lymph from the lung, heart and mediastinum and usually open into the right lymphatic duct and the terminal part of the thoracic duct respectively

truncus corporis callosi: the main intermediate part of the corpus callosum between the genu and splenium

truncus costocervicalis: the costocervical trunk which arises as a branch of the subclavian artery and gives off the deep cervical and supreme intercostal arteries

truncus intestinalis: the intestinal lymph trunk, which drains lymph from the celiac and superior mesenteric lymph nodes and empties into the cisterna chyli

truncus lumbalis: the right or left lumbar lymph trunk, which drain the lumbar lymph glands and open into the cisterna chyli

truncus lumbosacralis: the lumbosacral trunk which is formed by the union of part of the anterior primary ramus of the 4th with the anterior primary ramus of the 5th lumbar nerve. It joins the 1st sacral nerve to help form the sacral plexus

truncus lymphaticus: lymphatic trunk: one of the larger collecting lymph ducts

truncus subclavius: the right and left subclavian lymphatic trunks which usually convey lymph from the right and left upper extremities to the right lymphatic duct or termination of the thoracic duct respectively

truncus sympathicus: sympathetic trunk: the double chain of sympathetic ganglia, which extends on either side of the vertebral column from the base of the skull to the coccyx. It receives preganglionic fibres from the first thoracic down to the second lumbar segments of the spinal cord by white rami communicantes. It gives off grey rami communicantes, which convey postganglionic fibres to all of the spinal nerves. Fibres also pass from it to the smooth and cardiac muscle and viscera of the trunk

truncus thyreocervicalis: the thyrocervical trunk which is a branch of the sub-

clavian artery. It gives off the inferior thyroid, transverse cervical and suprascapular arteries

tuba, -ae, f. L.: trumpet, tube

tuba auditiva: eustachian tube: the auditory tube which leads from the tympanic cavity to the nasopharynx

tuba uterina (Falloppii): the uterine or Fallopian tube: the oviduct which lies in the upper border of the broad ligament. Its lateral end opens near the ovary and its medial into the upper lateral angle of the uterine cavity

tubalis, -e; *tubarius,* -a, -um: tubal; pertaining to a tube

tuber, -eris, n. L.: swelling, tubercle

tuber calcanei: the posterior end of the calcaneus

tuber cinereum: the slightly elevated area of grey matter in the floor of the 3rd ventricle between the mammillary bodies and optic chiasm. The infundibulum of the hypophysis passes downwards from it

tuber frontale: one of the bilateral rounded prominences of the frontal bone above the superciliary arches

tuber iliopubicum: s. eminentia iliopubica

tuber ischiadicum: the ischial tuberosity on the inferior and posterior aspects of the body of the ischium

tuber maxillare: maxillary tuberosity: the prominence of the inferior part of the infratemporal surface of the body of the maxilla behind the 3rd molar tooth

tuber olfactorium: trigonum olfactorium; s. olfactorius

tuber parietale: the parietal tuber or eminence: the most prominent part of the parietal bone

tuber vermis: the most posterior part of the inferior surface of the vermis of the cerebellum. It is continuous laterally with the inferior semilunar lobule

tuberalis, -e: tuberal; pertaining to a tuber

tuberosus, -a, -um: tuberous; provided with one or more tubers

tuberculum, -i, n. L.: tubercle or small tuber

tuberculum intervenosum: the intervenous tubercle: a rather indefinite protuberance on the internal aspect of the posterior wall of the right atrium between the openings of the superior and inferior vena cava

tuberositas, -atis, f. L.: tuberosity or tuber

tuberositas coracoidea: coracoid tuberosity: this includes the conoid tubercle and trapezoid line on the inferior aspect of the lateral part of the clavicle, which give attachment to the conoid and trapezoid parts of the coracoclavicular ligament

tuberositas costae secundae: the rough eminence at about the middle of the outer surface of the 2nd rib giving insertion to the scalenus posterior muscle

tuberositas costalis: impressio lig. costoclavicularis: impression of the costoclavicular ligament: a rough area on the lower surface of the medial end of the clavicle giving attachment to the costoclavicular ligament

tuberositas deltoidea: deltoid tuberosity: the rough eminence at about the middle of the lateral surface of the shaft of the humerus for insertion of the deltoid muscle

tuberositas glutea: gluteal tuberosity: a rough linear elevation on the posterior aspect of the femur between the greater trochanter and linea aspera giving insertion to gluteus maximus

tuberositas infraglenoidalis: tuberculum infraglenoidale: the infraglenoid tubercle at the lower part of the glenoid margin of the scapula, which gives origin to the long head of the triceps muscle

tuberositas masseterica: the roughened area on the outer surface of the angle of the mandible which gives insertion to part of the masseter muscle

tuberositas ossis metatarsalis primi: the tuberosity of the 1st metatarsal: the rough elevation on the lateral side of the base of the 1st metatarsal bone for insertion of part of tibialis anterior and peroneus longus

tuberositas ossis metatarsalis quinti: the tuberosity of the 5th metatarsal: the rough projection on the lateral aspect of the base of the 5th metatarsal bone for insertion of the peroneus brevis muscle

tuberositas ossis navicularis: the tuberosity of the navicular bone: the rough eminence on the medial aspect of the navicular bone giving insertion to the tibialis posterior muscle

tuberositas pterygoidea: the pterygoid tuberosity: the rough elevation on the inner side of the angle of the mandible for the insertion of fibres of the medial pterygoid muscle

tuberositas radii: the tuberosity of the radius: the roughened projection on the medial aspect of the upper end of the shaft of the radius giving insertion to the tendon of the biceps muscle

tuberositas sacralis: the sacral tuberosity above and behind the auricular surface of the sacrum, which gives attachment to the interosseous sacroiliac ligaments

tuberositas supraglenoidalis: tuberculum supraglenoidale: the supraglenoid tubercle of the superior margin of the glenoid cavity of the scapula, which gives origin to the long head of the biceps brachii muscle

tuberositas tibiae: the tuberosity of the tibia on the anterior aspect of the upper end of its shaft, which gives attachment to the ligamentum patellae

tuberositas ulnae: ulnar tuberosity: the rough eminence on the inferior part of the anterior aspect of the coronoid process of the ulna giving insertion to the brachialis muscle

tuberositas unguicularis: tuberositas phalangis distalis: tuberosity of the distal phalanx: the roughened area on the palmar aspect of the distal phalanges of the fingers or toes

tubulus, -i, m. L.: tubule, small canal

tubuli renales: the renal (uriniferous) tubules including those of the nephron and the collecting tubules

tubuli renales contorti: the convoluted renal tubules of the nephron. The proximal one leads from the glomerular capsule to the descending loop of Henle and the distal from the ascending part of the loop into a collecting tubule

tubuli renales recti: the straight (collecting) as opposed to the convoluted tubules of the kidney

tubuli seminiferi: the seminiferous tubules: s. seminifer

tubuli uriniferi: the minute uriniferous canals in the kidney, including the convoluted tubules, the loop of Henle and the collecting tubules

tubulosus, -a, -um: tubular; containing or pertaining to tubules

tubus, -i, m. L.: tube

Tulp's valve: s. valva ileocaecalis

tunica, -ae, f. L.: tunic; in anatomy: the tissue covering or forming the coat of a structure

tunica albuginea: a white fibrous layer covering a structure

tunica dartos: s. dartos

tunica elastica: the tunica media or intermediate layer in the wall of a blood vessel, which contains a variable amount of elastic tissue and smooth muscle

tunica externa: s. adventitia

tunica interna: s. intima

tunica mucosa: mucous membrane

tunica muscularis: muscular layer

tunica muscularis propria mucosae: muscularis mucosae: the smooth muscle forming the deepest layer of a mucous membrane

tunica vaginalis communis: fascia spermatica interna: the internal spermatic fascia which forms the inner layer of the wall of the spermatic cord and scrotum and is continuous above with the transversalis fascia of the abdomen

tunica vaginalis testis: the tunica vaginalis of the testis: a serous sac which is invaginated by the testis from behind. It, thus, consists of an outer parietal and inner visceral layer, the latter covering the testis except for its superior and posterior aspect

turbinalis, -e, L.: turbinal; turbinated, curled (turbo: a whirl)

turcicus, -a, -um, L.: Turkish

sella turcica: s. sella

Türck's tract: tractus temporopontinus: the temporopontine tract which passes from the temporal cortex to the lateral part of the cerebral peduncle and thence to the pontine nuclei

tympanum, -i, n. Gr.: tambourine or drum

cavum tympani: the tympanic cavity in the petrous part of the temporal bone. It contains the auditory ossicles and from it anteriorly opens the auditory tube, and posteriorly the tympanic additus, antrum and mastoid air-cells

membrana tympani: s. membrana

tympanicus, -a, -um: tympanic; pertaining to the tympanic cavity

Tyrrel's fascia: septum rectovesicale: the rectovesical septum or fascia between the rectum and prostate gland

Tyson's glands: glandulae preputiales: the preputial glands of the corona and neck of the penis, which are of a sebaceous nature and secrete smegma

U

ulna, -ae, f. L.: the medial of the two bones of the forearm

ulnaris, -e: ulnar; pertaining to the ulna

a. ulnaris: the ulnar artery, which arises from the brachial artery in the cubital fossa. It proceeds along the medial aspect of the front of the forearm and finally contributes to the formation of the superficial and deep palmar arches

n. ulnaris: the ulnar nerve: a branch of the medial cord of the brachial plexus. It supplies branches to flexor carpi ulnaris and flexor digitorum profundus and in the hand innervates the hypothenar muscles, the interossei, the medial two lumbricals and adductor pollicis. It also gives off cutaneous branches

ultimus, -a, -um: final, ultimate

umbilicus, -i, m. L.: the navel

umbilicalis, -e: umbilical; pertaining to the navel

ductus umbilicalis: ductus omphalomesentericus: the vitellointestinal duct, which connects the mid gut with the yolk sac in the embryo

funiculus umbilicalis: the umbilical cord, which extends from the placenta to the foetus and transmits the umbilical blood vessels

umbo, -onis, m. L.: boss, or elevation, e.g. the boss in the centre of a shield

umbo membranae tympani: the convexity in the middle of the tympanic membrane where the lower end of the handle of the malleus is attached

uncus, -i, m. L.: hook

uncus gyri fornicati: uncus gyri parahippocampalis: the anterior curved hook-like part of the parahippocampal gyrus of the temporal lobe of the brain

uncus ossis hamati: hamulus ossis hamati: the hamulus, a hook-like process projecting anteriorly from the hamate

unciformis, -e; *uncinatus*, -a, -um: unciform (uncinate); hooked; shaped like a hook

unguiculus, -i, m. L.: a small nail; the term has been applied to the nail of the 5th (little) toe

unguis, -is, f. L.: nail (of a finger or toe)

unguis Halleri: s. calcar avis

unguicularis, -e: ungual, unguinal; pertaining to the nail

unguiculatus, -a, -um: unguiculate; provided with nails

unicellularis, -e: unicellular; made of a single cell

unilateralis, -e: unilateral; pertaining or confined to one side

unilocularis, -e, L.: unilocular; having a single compartment

unipennatus, -a, -um, L.: unipennate: s. pennatus

unus, -a, -um, L.: one

urachus, -i, m. Gr.: the canal, which in the foetus connects the apex of the bladder with the umbilicus. It is derived from the allantois and normally its lumen is obliterated, the remainder forming a fibrous cord, the median umbilical ligament (urakhos: urinary duct; uron: urine; cheein: to pour)

ureter, -eris, f. Gr.: the urinary tube which conveys the urine from the kidney to the bladder

uretericus, -a, -um: ureteric, ureteral; pertaining to the ureter

urethra, -ae, f. Gr.: the urinary canal, which conveys urine from the bladder to the exterior

urethra masculina: the male urethra, which traverses the prostate gland, the sphincter urethrae and the penis

urethra muliebra: the female urethra, which traverses the sphincter urethrae to open on the surface of the vestibule in front of the vaginal orifice

urethralis, -e: urethral; pertaining to the urethra

urina, -ae, f. L.: urine

urogenitalis, -e: urogenital; pertaining to the urinary and genital organs

apparatus urogenitalis: the urogenital system

uropoeticus, -a, -um: uropoetic; concerned in the formation and excretion of the urine

apparatus uropoeticus: the uropoetic system including the kidney ureter and bladder (poiein: to make)

uterus, -i, m. L.: the womb: the hollow somewhat pear-shaped organ with thick muscular wall, within which the foetus develops. It consists of a main part or body, the lower third or cervix, which joins the body at the isthmus and opens inferiorly into the vagina, and an upper part or fundus which lies above the openings of the uterine tubes into the upper lateral angle of the uterus

uterus masculinus: utriculus prostaticus: the small diverticulum, which passes posterosuperiorly from the seminal colliculus of the prostatic part of the urethra. It is believed to be formed from the fused caudal ends of the paramesonephric ducts and thus to be the homologue of the uterus

uterinus, -a, -um: uterine; pertaining to the uterus

utriculus, -i, m. L.: utricle; literally, a small uterus; in anatomy: the sac of the membranous labyrinth of the internal ear, which lies in the vestibule. The semicircular canals open into it and it communicates with the saccule by the utriculosaccular duct

utriculus prostaticus: the prostatic utricle, s. uterus masculinus

utricularis, -e: utricular; pertaining to the utricle

uvea, -ae, f. L.: tunica vasculosa bulbi: the vascular layer of the eyeball, which includes the iris, ciliary body and choroid (uva: a bunch of grapes)

uvula, -ae, f. L.: (diminutive of uva)

uvula bifida: a bifid uvula of the soft palate, which is split in two. It can be regarded as the mildest form of a cleft palate

uvula cerebelli: uvula vermis: that part of the vermis of the cerebellum which links the two tonsils

uvula palatina: the conical structure which projects backwards in the midline from the soft palate

uvula vesicae: uvula of Lieutaud: the median elevation of the mucosa of the bladder just behind the internal urethral orifice, which is caused by the median lobe of the prostate

V

v. (abbreviation) vena: vein: a blood vessel which conveys blood back towards the heart

vacuola, -ae, f. L.: vacuole: a small cavity containing fluid within the cytoplasm of a cell

vacuus, -a, -um, L.: empty

vagina, -ae, f. L.: sheath; the female genital passage whose lower end opens to the exterior at the vulva and whose upper end communicates with the uterus

vagina bulbi: the fascial sheath which invests the eyeball, being attached to the sclera near the cornea and posteriorly fusing with the sheath of the optic nerve. It is pierced by the muscles, vessels and nerves of the eye

vagina fibrosa tendinis: the fibrous sheath which generally surrounds a tendon

vagina musculi recti abdominis: the sheath of the rectus abdominis muscle. Above the linea semilunaris the anterior layer is formed by the aponeuroses of the external oblique and the anterior layer of the internal oblique, and posteriorly by the posterior layer of the latter and by transversus. Below the linea semilunaris, all the aponeuroses pass anteriorly and the posterior layer of the sheath is formed by the transversal fascia

vaginae nervi optici: the external and internal sheaths of the optic nerve, which are forward prolongations of the dura mater and arachnoid

vagina processus styloidei: the bony sheath enclosing the root of the styloid process, which is formed by the tympanic part of the temporal bone splitting into two layers laterally

vagina septi: a developmental anomaly in which a median sagittal septum more or less separates the vagina into two halves

vagina synovialis tendinis: the synovial sheath of a tendon, which occurs in situations, where the tendon has to be held in place by a retinaculum. The sheath consists of a parietal layer which is reflected onto the tendon at the mesotenon to form the visceral layer

vagina vasorum: the connective tissue ensheathing blood vessels

vaginalis, -e: vaginal; pertaining to the vagina or to a sheath

vagus, -a, -um, L.: wandering, roaming

area nervi vagi: s. ala cinerea

n. vagus: the 10th cranial nerve (the wandering nerve): the nerve emerges from the medulla oblongata and traverses the neck and thorax to gain the abdomen. It gives off parasympathetic fibres to innervate the viscera of the neck, thorax and most of the abdomen and it also supplies the intrinsic muscles of the larynx

Valentin's corpuscles: small amyloid bodies which have been described in nervous tissue

valgus, -a, -um, L.: bow-legged

vallatus, -a, -um: vallate; surrounded by a rampart: having a rim (vallum: rampart)

vallecula, -ae, f. L.: small fossa, or depression (vallis: valley)

vallecula cerebelli Reili: the median depression on the inferior surface of the cerebellum in which the vermis lies

vallecula epiglottica: the depressions between the root of the tongue and the epiglottis, which are bounded by the median and lateral glossoepiglottic folds

vallecula fossae Sylvii: vallecula cerebri lateralis: the cleft where the lateral cerebral sulcus opens out towards the anterior perforated substance

vallecula unguis: sulcus matricis unguis: the sulcus of the matrix of the nail, which lodges the root of the nail

vallum, -i, n. L.: an earthen wall or rampart

vallum unguis: the fold of skin covering the sides and proximal end of the nail

Valsalva's antrum: s. antrum tympanicum

Valsalva's sinus: s. sinus aortae

Valva, -ae, f. L.: valve

valva atrioventricularis sinistra: valvula mitralis: the left atrioventricular or mitral valve, which guards the orifice between the left atrium and left ventricle. It has an anterior and posterior cusp

valva ileocaecalis: ileocaecal valve: two mucosal folds situated at the opening of the ileum into the caecum

valva tricuspidalis: valva atrioventricularis dextra: the tricuspid or right atrioventricular valve, which guards the right atrioventricular orifice. It has an anterior, posterior and septal cusp

valvula, -ae, f. L.: valve (valva: door-leaf)

valvula coli: valvula Bauhini: s. valva ileocaecalis

valvula foraminis ovalis (falx septi): valvule of the foramen ovale: the sickle-shaped fold which may be seen in the left atrium on the interatrial septum. It represents the upper border of the embryonic septum primum

valvula fossae navicularis: s. Guérin's fold

valvula processus vermiformis: valvula Gerlachi: a semilunar valve-like fold of mucous membrane which sometimes occurs at the orifice of the vermiform appendix

valvula prostatica: Mercier's dam: the valve-like ridge of mucous membrane on the inner surface of the bladder behind the urethral orifice, which may be formed by enlargement of the median lobe of the prostate

valvula pylori: the fold of mucous membrane at the pyloric orifice of the stomach caused by the pyloric sphincter

valvula Rosenmülleri: s. Rosenmüller's valve

valvulae semilunares: s. semilunaris

valvula semilunaris Tarini: s. velum medullare inferius

valvula sinus coronarii: valvula Thebesii: the valve of the coronary sinus: a semilunar endocardial fold at the right margin of the opening of the coronary sinus into the right atrium

valvula spiralis: s. plica spiralis

valvula Tulpii: s. valva ileocaecalis

valvula venae cavae inferioris: valvula Eustachii: valvula Sylvii: valve of the inferior vena cava: an endocardial fold which bounds the opening of the inferior vena cava into the right atrium anteriorly and in the foetus directs the flow of blood towards the left atrium

valvula Vieussensi: the valve-like structure which may occur at the opening of the great cardiac vein into the coronary sinus

valvulae venarum: the valves of veins

valvularis, -e: valvular; pertaining to, or provided with valves

van Helmont's mirror: speculum Helmontii: s. centrum tendineum diaphragmatis

van Horne's canal: s. ductus thoracicus

variabilis, -e, L.: variable; varying

variatio, -onis, f. L.: variation; change, modification (variare: to change)

Varolius' pons: pons varolii: s. pons

vas, -is, n. L.: vessel; in anatomy: blood vessel, lymphatic vessel, etc.

vas aberrans Halleri: s. ductulus aberrans inferius: s. ductuli aberrantes

vas aberrans hepatis: any of the blind ending bile ducts or associated blood vessels which occur in the coronary ligament, capsule or fibrous appendix of the liver

vasa afferentia: vessels leading toward, or entering a structure, e.g. lymph-nodes, renal glomeruli, etc.

vas anastomoticum: an anastomosing vessel

vasa capillaria: the capillary or smallest type of blood vessel; capillaries

vasa efferentia: the vessels leaving a structure, e.g. lymph-nodes, renal glomeruli, etc.

vas lymphaticum: lymphatic vessel

vasa nutricia: the nutrient artery, supplying a bone

vasa publica: aa. et vv. pulmonales: pulmonary arteries and veins

vasa sanguinae: blood vessels

vasa vasorum: the small nutrient blood vessels in the walls of the larger arteries and veins

vascularisatio, -nis, f. L.: vascularization, the formation of vessels in a tissue

vasculosus, -a, -um: vascular; pertaining to, or rich in vessels

vasculum, -i, n. L.: a small vessel, a small blood vessel

vasoconstrictor, -is, m. L.: nerves or chemical agents which cause constriction of blood vessels (constringere: to compress)

vasodilator, -is, m. L.: nerves or chemical agents which cause dilatation of blood vessels (dilatere: to widen)

vasomotor, -is, m. L.: vasomotor nerves which effect changes in the width of blood vessels and thus regulate the blood flow and affect the blood pressure

vastus, -a, -um, L.: great, vast

mm. vasti: extensor muscles of the thigh including vastus medialis, intermedius and lateralis. They arise from the shaft of the femur and insert by the patella and ligamentum patellae into the tibial tuberosity

Vater's ampulla: s. ampulla hepatopancreatica

Vater's papilla: s. papilla duodeni major

Vater–Pacini's corpuscles: corpuscula lamellosa: the ovoid sensory nerve-endings, just visible with the naked eye, which occur in the dermis, including that of the hand and foot, tendons, the mesentery, the external genitalia, etc. Their capsule consists of layers of connective tissue concentrically arranged around the central core with its endings of nerve fibrils

vegetatio, -onis, f. L.: vegetation, growth

vegetative nervous system: s. systema nervosum autonomicum

velamentum, -i, n. L.: a covering, a membranous covering (velare: to cover)

velamentum abdominale: s. peritoneum

velamentum cerebrale: any of the meninges including the dura or pia mater or the arachnoid

velamentosus, -a, -um: velamentous: pertaining to, or provided with a velamentum

insertio velamentosa: a velamentous insertion of the blood vessels into the placenta when they separate from each other before reaching the placenta, and are conveyed to it from the umbilical cord in folds of amniotic membrane

velum, -i, n. L.: covering, veil, sail

velum interpositum: s. tela chorioidea ventriculi

velum medullare inferius: the inferior medullary velum: the thin layer of white substance forming the roof of some of the inferior part of the 4th ventricle

velum medullare superius: the superior medullary velum: the thin layer of white substance which forms the roof of the upper part of the 4th ventricle stretching between the superior cerebellar peduncles

velum palatinum: s. palatum molle

velum terminale: s. lamina terminalis

velum triangulare: s. tela chorioidea of 3rd ventricle

vena, -ae, f. L.: vein, a vessel which conveys the blood towards the heart

vena emissaria: s. emissarium

venosus, -a, -um: venous; pertaining to the veins

angulus venosus: Pirogov's angle: the angle at the junction of the internal jugular and subclavian veins into which, on the left, the thoracic duct and, on the right side, right lymphatic duct usually open

calculus venosus: venous calculus; a phlebolith or calcified concretion of old coagulated blood in a vein

venter, -tris, m. L.: belly

ventralis, -e, L.: ventral; pertaining to the belly. Denoting direction or position: e.g. situated nearer to the anterior surface of the trunk or on the opposite side of the body to the spinal cord

ventriculus, -i, m. L.: stomach, ventricle

ventriculus Arantii: ventricle of Aranzio: the small depression on the anterior margin of the calamus scriptorius in the caudal part of the floor of the 4th ventricle

ventriculus cerebri: s. ventriculus lateralis (cerebri)

ventriculus cordis: the right or left ventricle of the heart

ventriculus dexter: the right ventricle of the heart, which receives the venous blood from the right atrium and expels it into the pulmonary artery

ventriculus laryngis: ventricle of the larynx: the recess which opens between the vestibular and vocal folds and extends superolaterally between the quadrangular membrane and the lamina of the thyroid cartilage

ventriculus lateralis cerebri: the lateral ventricle of the cerebrum: the cavity which lies within the cerebral hemisphere. It communicates with the 3rd ventricle by the interventricular foramen and it is subdivided into a central part and an anterior and posterior horn and a lateral horn, which extends into the temporal lobe

ventriculus Morgagni: s. ventriculus laryngis

ventriculus quartus cerebri: 4th ventricle: the rhomboid-shaped cavity of the hindbrain, whose side walls are formed mainly by the cerebellar peduncles, its roof by the superior cerebellar peduncle, superior and inferior medullary vela, nodule and tela choroidea, and its floor by the posterior surfaces of the pons and medulla

ventriculus septi pellucidi: cavum septi pellucidi: a narrow cavity which is usually present within the septum pellucidum

ventriculus sinister: the left ventricle of the heart, which receives the arterial blood from the left atrium and expels it into the aorta

ventriculus terminalis: the dilated, terminal, inferior part of the central canal in the spinal cord

ventriculus tertius cerebri: the 3rd ventricle of the forebrain: a slit-like cavity between the thalami. It is bounded anteriorly by the lamina terminalis, inferiorly by structures of the hypothalamus and superiorly by an ependymal roof. It communicates with the lateral ventricles and caudally with the cerebral aqueduct

ventriculus Vergae: the space which may occur between the commissure of the fornix (lyre of David) and the inferior surface of the corpus callosum

ventricularis, -e, L.: ventricular; pertaining to a ventricle e.g. of the heart, or brain

plica ventricularis: plica vestibularis: the vestibular or false vocal folds, which lie above the vocal folds passing from the anterolateral aspect of the arytenoid cartilages to the posterior aspect of the thyroid lamina by its anterior border

septum interventriculare: the interventricular septum forming the partition between the ventricles of the heart

Verga's ventricle: s. ventriculus Vergae

Verheyen's stars: venae stellatae renis: the star-shaped arrangement of small veins on the surface of the kidney

vermis, -is, m. L.: worm

vermis cerebelli: the narrow median part of the cerebellum, which connects the cerebellar hemispheres

vermiformis, -e, *vermicularis*, -e: vermiform, vermicular; shaped like a worm

processus vermiformis: s. appendix vermiformis

versio, -onis, f. L.: version, rotation

versio uteri: s. anteversio uteri

vertebra, -ae, f. L.: any one of the 33 bones which compose the vertebral column

vertebra basilaris: the 5th or lowest lumbar vertebra

vertebrae cervicales: the seven cervical vertebrae of the neck

vertebrae coccygeae: the four coccygeal vertebrae which more or less fuse together to form the coccyx bone

vertebrae lumbales: the five lumbar vertebrae of the loin

vertebra prominens: the 7th cervical vertebra, which has a prominent easily palpable spine

vertebrae sacrales: the five sacral vertebrae which fuse together to form the sacrum

vertebrae spuriae: the "false" sacral and coccygeal vertebrae which fuse together to form the sacrum and coccyx

vertebrae thoracales: the twelve thoracic vertebrae

vertebrae verae: the true vertebrae including all apart from the sacral and coccygeal

vertebralis, -e: vertebral; pertaining to a vertebra

vertebratus, -a, -um: vertebrate; having vertebrae

vertebrata: the vertebrates (animals having a vertebral column)

vertex, -icis, m. L.: top, summit, whirl

vertex cranii: the top or crown of the head: the highest point of the skull

verticalis, -e, L.: denoting direction: vertical, perpendicular

verus, -a, -um, L.: true, real

Vesalius' bones (vesalian bones): 1. a term which has been applied to the sesamoid bone, which may be present near the origin of the lateral head of the gastrocnemius

muscle; 2. the tuberosity of the base of the 5th metatarsal bone when it occurs as a separate sesamoid bone

Vesalius' foramen (vesalian foramen): the small inconstant foramen in the sphenoid bone anteromedial to the foramen ovale, which gives passage to an emissary vein from the cavernous sinus

Vesalius' ligament (vesalian ligament): ligamentum inguinale, s. inguinalis

Vesalius' vein (vesalian vein): the emissary vein from the cavernous sinus which passes through the foramen of Vesalius

vesica, -ae, f. L.: bladder

vesica fellea: the gall bladder situated on the inferior surface of the liver. It stores bile which it receives by the hepatic and cystic ducts and discharges it through the cystic and bile ducts into the duodenum

vesica prostatica: s. uterus masculinus

vesica urinaria: the urinary bladder situated in the pelvis. It receives urine from the kidneys by the ureters and discharges it through the urethra

vesicalis, -e: vesical; pertaining to the bladder

vesicula, -ae, f. L.: vesicle; a small bladder-like structure

vesicula germinativa: the germinal vesicle or nucleus of the ovum

vesicula Graafi: s. graafian follicle

vesicula ophthalmica: the optic vesicle or cup; the expanded, distal, cup-like end of the optic stalk which grows from the wall of the diencephalon in the embryo. It forms the nervous and pigmented layers of the retina

vesicula prostatica: s. uterus masculinus

vesicula seminalis: seminal vesicle: the two glandular sacculated vesicles which lie posterior to the base of the urinary bladder. The duct of each joins the ductus deferens to form the ejaculatory duct which opens into the prostatic part of the urethra

vesicularis, -e: vesicular; pertaining to a vesicle

vestibulum, -i, n. L.: vestibule, entrance

vestibulum aortae: aortic vestibule: the part of the left ventricle just below, and leading into the aorta. Its walls consist mainly of fibrous tissue

vestibulum bursae omentalis: the vestibule of the omental bursa, which lies just to the left of the epiploic foramen below the caudate lobe of the liver. It leads into the upper and lower recesses

vestibulum labyrinthi: the dilated part of the bony labyrinth of the internal ear, which contains the saccule and utricle

vestibulum laryngis: the part of the larynx extending from the inlet down to the vestibular folds

vestibulum nasi: the vestibule of the nose: a slight dilatation within the nasal aperture, which extends towards the apex of the nose. It is continuous posteriorly with the atrium

vestibularis, -e: vestibular; pertaining to a vestibule

via, -ae, f. L.: way, passage

Vicq-d'Azyr's band: the line of Gennari: the conspicuous white band in the 4th layer of the striate area in the region of the calcarine fissure running parallel to the surface of the cerebral cortex. It is the same as the outer line of Baillarger elsewhere

Vicq-d'Azyr's bundle: fasciculus mamillothalamicus: the mamillothalamic tract extending from the mamillary body to the anterior nucleus of the thalamus

Vicq-d'Azyr's caecum: foramen caecum medullae oblongatae: foramen caecum posterius: the small pit in the midline, at the border between the pons and medulla oblongata on the ventral surface. It marks the upper end of the anterior median fissure

Vicq-d'Azyr's centre: s. centrum semiovale

Vidius' artery (vidian artery): the artery of the pterygoid canal which arises from the maxillary or greater palatine artery. It supplies branches to the upper part of the pharynx and the auditory tube

Vidius' canal (vidian canal): s. canalis pterygoideus

Vidius' nerve (vidian nerve): the nerve of the pterygoid canal formed by the union of the deep and superficial petrosal nerves. It conveys sympathetic and parasympathetic fibres to the pterygopalatine ganglion

Vidius' vein (vidian vein): the vein of the pterygoid canal, which accompanies the artery of the same name and drains into the pterygoid venous plexus

Vieussens' ansa: s. ansa subclavia

Vieussens' ring: s. limbus fossae ovalis

Vieussens' veins: vv. innominatae cordis: the minute superficial veins of the heart

villus, -i, f. L.: tuft of hair, shaggy hair

villi intestinales: the intestinal villi the small thread-like projections on the surface of the mucosa of the small intestine. They contain blood and lymph vessels

villi pleurales: the villi which may project from the pleura especially in the costomediastinal recess

villi synoviales: the thread-like projections from the synovia of joints, which contain many capillaries

villosus, -a, -um: villous; covered with villi

vinculum, -i, n. L.: band

vincula lingulae cerebelli: vincula of the lingula of the cerebellum: a small lateral projection from the lingula

vincula tendinum: the bands of fibrous tissue which pass from the long flexor tendons of the fingers and toes to the phalanges. They convey blood vessels to the tendons

Virchow–Hassal's corpuscles: s. Hassal's corpuscles

Virchow–Robin's spaces: the perivascular spaces which extend for a certain distance around the blood vessels into the brain tissue. They intervene between the pia and the wall of the vessel and they communicate with the subarachnoid space

virgo, -inis, f. L.: virgin

virginitas, -atis, f. L.: virginity

virilis, -e, L.: virile; masculine (vir: man)

organa genitalia virilia: the male genitalia

viscera, -um, n. L. plur.: the internal organs, especially those of the abdomen and thorax

visceralis, -e: visceral; pertaining to the viscera

visus, -us, m. L.: vision, sight

vitrum, -i, n. L.: glass

vitreus, -a, -um: vitreous, glass-like

corpus vitreum: the vitreous body of the eye: s. corpus

vola, -ae, f. L.: the palm of the hand or sole of the foot

volaris, -e: volar; pertaining to the palm or sole

Volkmann's canals: canals which pass into bones more or less at right angles to their surface and convey blood vessels to the haversian canals

vomer, -eris, m. L.: ploughshare; in anatomy: the bone which forms the postero inferior part of the septum of the nose

vortex, -icis, m. L.: whirl

vortex coccygeus: the whirl-like arrangement of hairs sometimes visible in the coccygeal region

vortex cordis: the whirl-like arrangement of muscle fibre bundles at the apex of the heart

vortex lentis: the whirl- or star-shaped pattern of white lines visible on the anterior and posterior surfaces of the lens of the eye

vorticosus, -a, -um: having vortices, whirl-like

venae vorticosae Ruyschi: the veins of the vascular layer of the choroid, which converge on four or five main veins situated on the equator of the eye. The latter pierce the sclera and drain into the ophthalmic veins

vox, -cis, f. L.: voice

vocalis, -e: vocal; pertaining to the voice

plica vocalis: the vocal folds of mucous membrane which stretch from the vocal processes of the arytenoid cartilages to the front of the posterior aspect of the laminae of the thyroid cartilage

vulva, -ae, f. L.: the external genitalia of the female

W

Wachendorf's membrane: s. membrana pupillaris

Wagner's corpuscles: corpuscula tactus: the tactile corpuscles: encapsulated sensory nerve-endings of moderate size which occur in the dermal papillae of the hand, foot, lips and in the conjunctiva, tongue, etc.

Wagner's spot: the nucleolus of the human ovum

Waldeyer's epithelium: this term has been applied to the germinal epithelium of the ovary

Waldeyer's fossa: s. recessus duodenalis

Waldeyer's layer: a term which has been applied to the vascular network of the ovary

Waldeyer's ring: the ring-like system of lymph-follicles surrounding the fauces and including the palatine, pharyngeal, tubal and lingual tonsils

Walther's duct: s. ductus sublingualis minor Rivini

Walther's ganglion: s. ganglion coccygeum

Weber's organ: s. uterus masculinus

Weitbrecht's cartilage: the fibrocartilaginous disk which usually occurs in the acromioclavicular joint partially dividing it into two

Weitbrecht's foramen: the opening in the capsule of the shoulder joint through which its synovial cavity communicates with the bursa deep to subscapularis tendon

Werneking's commissure: s. decussatio pedunculorum cerebellarium superiorum

Wernicke's centre: the centre concerned with speech in the posterior third of the superior temporal gyrus. It has also been taken as including the angular gyrus

Westphal's nucleus: s. Edinger—Westphal's nucleus

Wharton's duct: s. ductus submandibularis

Wharton's jelly: the jelly-like connective tissue of the umbilical cord. It is rich in mucopolysaccharides

Wilde's cord: transversely running fibres of the corpus callosum

Willis' circle: s. circulus arteriosus Willisi

Willis' nerve: n. accessorius, the accessory or 11th cranial nerve

Willis' vessels: the anterior and posterior communicating arteries of the circle of Willis

Wilson's muscle: the sphincter urethrae muscle which surrounds the urethra in the deep perineal pouch

Winslow's foramen: foramen epiploicum: the opening into the omental bursa. It lies behind the hepatoduodenal part of the lesser omentum, below the caudate process of the liver, in front of the inferior vena cava and above the first part of the duodenum

Winslow's ligament: lig. popliteum obliquum: the fibrous band extending from the insertion of the semimembranosus tendon upwards and laterally in the posterior part of the capsule of the knee joint to be attached to the lateral condyle of the femur

Winslow's pancreas: the uncinate or hook-shaped process of the head of the pancreas, which lies behind the superior mesenteric artery and vein

Winslow's stars: the vascular stars: the whirl-like arrangement of the capillaries and venules in the lamina choriocapillaris from which arise the venae vorticosae

Wirsung's duct: s. ductus pancreaticus

wolffian body: s. mesonephros

wolffian duct: the mesonephric duct which leads from the mesonephros to the cloaca in the embryo. In the male it forms the ductus deferens, whereas in the female it

largely disappears. In both sexes it contributes to the formation of the trigone of the bladder

Worm's bone (wormian bone): ossicula intercalaria: small bones in the sutures of the skull especially the lambdoid one

Wrisberg's anastomosis: the interconnection between the medial cutaneus nerve of the arm and the intercostobrachial nerve

Wrisberg's cardiac ganglion: ganglion cardiacum: the ganglion below the arch of the aorta to the right of the ligamentum arteriosum. It probably contains vagal synapses, the postganglionic fibres passing to the heart

Wrisberg's cartilage: cartilago cuneiformis: the small cuneiform cartilages in the aryepiglottic folds

Wrisberg's loop: the connection between the greater splanchnic and the vagus nerves of the right side

Wrisberg's nerve: nervus intermedius: the smaller of the two roots of the facial nerve, which lies between the main root and the eighth cranial nerve. It contains taste fibres from the anterior two thirds of the tongue and efferent parasympathetic fibres

Wrisberg's tuberculum: tuberculum cuneiforme: the protuberance in the inferior part of the aryepiglottic fold due to the cuneiform cartilage

X

X-chromosome: one of the two sex chromosomes. The human male has an X and a Y and the female two X chromosomes

xiphoides, Gr.: xiphoid; shaped like a sword (xiphos: sword)

xiphoideus, -a, -um: pertaining to the xiphoid process

processus xiphoideus: processus ensiformis: the xiphoid process: the small lowest component of the sternum, which is initially made of cartilage and only slowly becomes ossified

X-rays: Roentgen rays

Y

Y-bundle: lig. iliofemorale: the iliofemoral ligament which is attached above to the anterior inferior iliac spine and adjoining bone. Below the stronger bands of the inverted Y diverge to be attached to the upper and lower parts of the intertrochanteric line

Y-chromosome: one of the two sex chromosomes: s. X-chromosome

ypsiloideus, -a, -um: ypsiloid; ypsiliform

ypsiliformis, -e: ypsiliform; Y- or U-shaped

Z

Zaglas' band: the part of the posterior sacroiliac ligament which connects the posterior superior iliac spine with the 2nd transverse tubercle of the sacrum

Zang's space: fossa supraclavicularis minor: the lesser supraclavicular fossa: the triangular space between the sternal and clavicular heads of the sternocleidomastoid muscle

Zeis' gland (zeisian glands): the ciliary glands: modified sebaceous glands attached to the follicles of the eyelashes

Zeissl's layer: a homogeneous layer which has been described in the wall of the stomach of the cat between the submucosa and the muscularis mucosae

Zinn's annulus: s. annulus tendineus communis

Zinn's artery: a. centralis retinae: the central retinal branch of the ophthalmic artery which enters the optic nerve and gains the retina at the centre of the optic disk where it divides into an upper and lower branch. These give off further branches which supply the retina

Zinn's circle: s. circulus vasculosus nervi optici

Zinn's ligament: s. annulus tendineus communis

Zinn's zonule: s. zonula ciliaris

zona, -ae, f. Gr.: zone (zone: belt)

zona arcuata: arcuate zone: the inner part of the basilar membrane situated beneath the spiral organ of Corti in the internal ear

zona dermatica: the term has been applied to the thick skin around a meningocele or to the thickened skin which may occur above the patella and the ole-

zona fasciculata: the intermediate layer of the cortex of the suprarenal gland in which the cells are arranged in columns

zona glomerulosa: the outermost layer of the cortex of the suprarenal gland in which the cells form rounded clumps

zona incerta: the group of cells lying just below the thalamus and dorsal to the subthalamic nucleus. Fibres from the globus pallidus and probably the cortex project to it and efferent fibres pass from this region to the tegmentum of the midbrain

zona orbicularis (Weberi); fibres of the capsule of the hip joint, which pass circularly around the joint. They are most prominent in the posterior part of the capsule

zona pellucida: the relatively thick, transparent membrane which surrounds the ovum

zona radiata: s. corona radiata

zona reticularis: the inner layer of the cortex of the suprarenal gland in which the cells form an irregular network

zona spongiosa: a layer on the dorsal aspect of the substantia gelatinosa of the spinal cord, which contains elongated fusiform cells

zona tecta: s. zona arcuata

zona tendinosa: s. annulus fibrosus

zona terminalis: s. Lissauer's tract and zone

zona vasculosa: the vascular zone of the external acoustic meatus supplied with small blood vessels derived from the mastoid part of the temporal bone

zonalis, -e: zonal; pertaining to a zone

zonula, -ae, f. L.: zonule; small girdle, small zone

zonula Arnoldi: fibrae arcuatae externae: the dorsal external arcuate fibres which arise from the lateral cuneate nucleus and enter the cerebellum by the inferior cerebellar peduncle. They convey proprioceptive and tactile impulses from the neck and arm

zonula ciliaris: the ciliary zonule which consists of fibres passing from the orbiculus ciliaris and from the valleys between the ciliary processes forwards towards the lens where they are attached to either its anterior or posterior surfaces near the periphery. They thus form the suspensory ligament of the lens

zonularis, -e: zonular; pertaining to a zonule

Zuckerkandl's bodies: aggregations of chromaffin tissue beside the aorta

Zuckerkandl's convolution: gyrus paraterminalis: the gyrus in front of the lamina terminalis and below the rostrum of the corpus callosum, which probably receives connections from the medial olfactory tract

Zuckerkandl's glands: an accessory lobe of the thyroid gland in front of the hyoid bone

zygomaticus, -a, -um, Gr.: zygomatic; pertaining to the zygoma (zygoma: yoke)

os zygomaticum: the zygomatic or malar bone of the cheek

LIST OF AUTHORS WITH BIOGRAPHICAL DATA

A list of the authors named in eponyms, which were included in the BNA or which are generally recognized.

A

ALCOCK, B. (1801 – ?), Irish anatomist
Alcock's canal
AMUSSAT, J. Z. (1796 – 1856), French surgeon
Amussat's valve: uvula vesicae
ANDERSCH, C. S. (1732 – 1777), German physician
Andersch's ganglion: ganglion inferius (N. IX)
ARANZIO, G. C. (1530 – 1589), Italian physician and surgeon in Bologna
Aranzio's band: lig venosum (Arantii)
Aranzio's bodies: noduli valvularum semilunarium
Aranzio's duct: ductus venosus (Arantii)
ARLT, C. F. R. v. (1812 – 1887), ophthalmologist in Prague and Vienna
Arlt's line
ARNOLD, F. (1803 – 1890), anatomist in Heidelberg, etc.
Arnold's area: ala cinerea
Arnold's ganglion: ganglion oticum
Arnold's substance: substantia reticularis alba
Arnold's tract: tractus frontopontinus
ASCHOFF, L. (1866 – 1942), professor of pathological anatomy in Freiburg
Aschoff's ducts
Aschoff – Tawara's node: nodus atrioventricularis
ASELLI, G. (1581 – 1626), anatomist in Milan and Pavia
Aselli's vessels: vasa chylifera
AUERBACH, L. (1828 – 1897), physician and neuropathologist in Breslau
Auerbach's plexus: plexus myentericus

B

BARTHOLIN, C. (1655 – 1738), professor of anatomy in Copenhagen
Bartholin's duct: ductus sublingualis major
Bartholin's gland: glandula vestibularis major
BAUDELOCQUE, L. P. (1746 – 1810), gynecologist in Paris
Baudelocque's diameter: conjugata externa
BAUHIN, C. (1560 – 1624), anatomist in Basle

Bauhin's valve: valvula ileocaecalis

BECHTEREW, V. M. (1857–1927), neurologist in Leningrad
Bechterew's bundle: tractus spinoolivaris
Bechterew's nucleus: nucleus vestibularis superioris

BÉCLARD, P. A. (1785–1825), anatomist in Paris
Béclard's anastomosis: arcus raninus
Béclard's triangle

BELLINI, L. (1643–1704), professor of anatomy in Pisa
Bellini's tubules: tubuli renales recti

BERNARD, C. (1813–1878), physiologist in Paris
Bernard's canal: ductus pancreaticus accessorius Santorini

BERTIN, E. J. (1712–1781), anatomist in Paris
Bertin's column: columnae renales
Bertin's ligament: ligamentum iliofemorale

BETZ, V. A. (1834–1894), Russian anatomist
Betz cells

BICHAT, M. F. X. (1771–1802), anatomist in Paris
Bichat's fat-pad
Bichat's foramen

BIGELOW, H. J. (1818–1890), professor of surgery, Harvard University
Bigelow's ligament: ligamentum iliofemorale

BLUMENBACH, J. F. (1752–1840), Göttingen physician and biologist
Blumenbach's clivus: clivus

BOCHDALEK, V. A. (1801–1883), anatomist in Prague
Bochdalek's bouquet
Bochdalek's ganglion
Bochdalek's gland tubules
Bochdalek's triangle: trigonum vertebrocostale

BOGROS, A. J. (1786–1823), anatomist in Paris
Bogros' space: spatium retroinguinale

BOLL, F. C. (1849–1879), German physiologist
Boll's cells: basement cells of the lacrimal gland

BONNET, A. (1802–1858), Lyons surgeon
Bonnet's capsule: capsula bulbi

BOTALLO, L. (1530–?), Italian physician
Botallo's bundle: ligamentum arteriosum
Botallo's duct: ductus arteriosus

BOWMAN, W. (1816–1892), ophthalmic surgeon and anatomist in London
Bowman's capsule: capsula glomeruli
Bowman's glands: glandulae olfactoriae
Bowman's membrane: lamina elastica ant. corneae
Böttcher–Cotugno's duct or pouch: saccus endolymphaticus

BÖTTCHER, A. (1831–1889), pathologist and anatomist in Dorpart
BRESCHET, G. (1796–1860): anatomist in Paris
Breschet's canals: canales diploici
Breschet's veins: venae diploicae
BROCA, P. P. (1824–1880), Paris surgeon and anthropologist
Broca's gyrus or centre
BRUCH, K. W. L. (1819–1885), anatomist in Basle
Bruch's membrane: lamina basalis chorioideae
BRÜCKE, E. W. R. (1819–1892), Vienna physiologist
Brücke's muscle: musculus ciliaris (fibrae meridionales)
BRUNN, A. v. (1849–1895), anatomist in Göttingen
Brunn's membrane: membrana limitans olfactoria
BRUNNER, J. K. (1653–1727), Swiss anatomist in Paris and Heidelberg
Brunner's glands: glandulae duodenales
BURDACH, K. F. (1776–1847), anatomist and physiologist in Königsberg
Burdach's column: fasciculus cuneatus
BUROW, K. A. v. (1809–1874), anatomist and surgeon in Königsberg
Burow's veins

C

CAJAL s. Ramón y Cajal
CAMPER, P. (1722–1789), anatomist, physician, etc. in Amsterdam
Camper's facial angle
CARABELLI, G. (1787–1842), Vienna physician and dental surgeon born in Hungary
Carabelli's tubercle
CASSERIO, G. (c. 1556–1616), anatomist in Padua
Casserio's muscle: m. coracobrachialis
Casserio's nerve: n. musculocutaneus
CHARCOT, J. M. (1825–1893), neurologist in Paris
Charcot's artery: a. haemorrhagica: artery of cerebral haemorrhage
CHASSAIGNAC, CH. M. E. (1805–1879), Parisian surgeon
Chassaignac's tubercle: tuberculum caroticum
CHOPART, F. (1743–1795), surgeon in Paris
Chopart's articulation: articulatio tarsi transversa
CIVININI, F. (1805–1844), anatomist in Pistoia
Civinini's orifice: foramen pterygospinosum
Civinini's process: processus pterygospinosus
CLARKE, J. A. L. (1817–1880), neurologist in London
Clarke's column: nucleus thoracicus medullae spinalis

CLAUDIUS, F. M. (1822–1869), anatomist in Marburg
Claudius' cells
CLOQUET, J. G. (1790–1883), anatomist in Paris
Cloquet's canal: canalis hyaloideus
Cloquet's membrane: septum femorale
COHNHEIM, J. F. (1839–1884), pathologist in Breslau
Cohnheim's areas
COLLES, A. (1773–1843), anatomist and surgeon in Dublin
Colles' ligament: ligamentum reflexum
COOPER, A. P. (1768–1841), surgeon and anatomist in London
Cooper's fascia: fascia cremasterica
Cooper's ligaments
CORTI, A. (1822–1888), Italian anatomist
Corti's cells
Corti's membrane: membrana tectoria
Corti's organ: organum spirale
Corti's rods
COSTE, J. J. M. C. V. (1807–1873), French embryologist
Coste's cell: human ovum
COTUGNO, D. (1736–1822), anatomist in Naples
Cotugno–Böttcher's duct or pouch: saccus endolymphaticus
COTUNNIUS s. Cotugno
aquula externa Cotunnii: perilymph
COWPER, W. (1666–1709), anatomist and surgeon in London
Cowper's gland: glandula bulbourethralis

D

DEITERS, O. F. K. (1834–1863), histologist in Bonn
Deiters' cells
Deiters' nucleus: nucleus vestibularis lateralis
DENONVILLIERS, CH. P. (1808–1872), surgeon in Paris
Denonvilliers' fascia: septum rectovesicale
Denonvilliers' ligament: lig. puboprostaticum
DESCARTES, R. (1596–1650), French philosopher, mathematician and physiologist
Descartes' organ: corpus pineale
DESCEMET, J. (1732–1810), Paris anatomist
Descemet's membrane: lamina limitans posterior
DOUGLAS, J. (1675–1742), London physician and anatomist
Douglas' fold: plica rectouterina

Douglas' line: linea arcuata
Douglas' pouch: excavatio rectouterina
DUVERNEY, J. G. (1648–1730), anatomist in Paris
Duverney's gland: Bartholin's gland

E

EBNER, V. (1842–1925), Vienna anatomist
Ebner's fibrils
Ebner's glands
Ebner's pillar
Ebner's reticulum
EDINGER, L. (1855–1918), neurologist in Frankfurt
Edinger's tract: tractus spinothalamicus
Edinger–Westphal's nucleus
EHRENRITTER, J. (?–1790), anatomist in Vienna
Ehrenritter's ganglion: ganglion superius (n. IX)
ERB, W. H. (1840–1921), physician and neurologist in Heidelberg
Erb's point
EUSTACH (IO), B. (c. 1513–1574), professor of medicine in Rome, physician of the Pope
eustachian amygdalae: tonsilla tubaria
eustachian muscle: m. tensor tympani
eustachian tube: tuba auditiva (Eustachii)
eustachian valve: valvula venae cavae inferioris (Eustachii)
EXNER, S. (1846–1926), physiologist in Vienna
Exner's nerve
Exner's plexus

F

FALLOPIO, G. (1523–1563), professor of surgery at the Ferrara, Pisa and Padua universities
Fallopian band: lig. inguinale
Fallopian canal: canalis facialis
Fallopian tube: tuba uterina (Fallopii)
Fallopian valve: valva ileocaecalis
FARABEUF, L. H. (1841–1910), anatomist and surgeon in Paris
Farabeuf's triangle
FARRE, A. (1811–1887), obstetrician in London
Farre's line

FERREIN, A. (1693–1769), surgeon and anatomist in Paris
Ferrein's canal: rivus lacrimalis
Ferrein's ligaments
pyramids of Ferrein
FIELDING, G. H. (1801–1871), English anatomist and ophthalmologist
Fielding's membrane: membrana versicolor
FLECHSIG, P. E. (1847–1929), neurologist in Leipzig
Flechsig's areas
Flechsig's incision
Flechsig's tract: tractus spinocerebellaris posterior
FLEISCHMANN, G. (1777–1853), German anatomist and physician
Fleischmann's bursa
FOLLI, C. (Folius) (1615–1650), anatomist in Venice
process of Folius: processus anterior mallei (Folii)
FONTANA, A. F. (1732–1805), anatomist in Pisa, and later in Florence
Fontana's spaces: spatia anguli iridocornealis
FOREL, A. (1848–1931), neurologist in Zürich
Forel's commissure: decussatio tegmentalis ventralis
FORSSELL, G. (1876–1950), Swedish radiologist
Forssell's sinuses
FRANKENHÄUSER, F. (?–1894), obstetrician in Jena and Zürich
Frankenhäuser's ganglion: ganglion cervicale uteri
Frankenhäuser's plexus: plexus uterovaginalis

G

GALEATI, C. (1686–1775), physician in Bologna
Galeati's glands: the crypts of Lieberkühn
GALENUS, C. (Galen) (130–200 AD), born in Pergamum, practised medicine in Rome, physician to Marcus Aurelius
anastomosis of Galen
great vein of Galen: v. cerebri magna (Galeni)
GALTON, F. (1822–1911), English geneticist
Galton's delta
GARTNER, H. T. (1785–1827), Danish anatomist and surgeon
Gartner's ducts: ductus epoophori longitudinales
GASSER, J. L. (1723–1765), Vienna anatomist
Gasser's (Gasserian) ganglion: ganglion trigeminale
GAVARD, H. (1753–1802), French anatomist
Gavard's muscle: fibrae obliquae ventriculi
GENNARI, F. (c. 1750–1795?), Italian anatomist

Gennari's line

GERDY, P. N. (1797–1856), Paris surgeon, pathologist and anatomist
Gerdy's fibres
Gerdy's hyoid fossa: trigonum caroticum
Gerdy's ligament

GERLACH, J. (1820–1896), anatomist in Erlangen
Gerlach's valve: valvula processus vermiformis

GEROTA, D. (1867–1939), surgeon in Bucharest
Gerota's fascia: fascia renis

GIACOMINI, C. (1840–1898), anatomist in Turin
Giacomini's band

GIANUZZI, G. (1839–1876), physiologist in Siena
Gianuzzi's crescents

GIERKE, H. P. (1847–1886), German anatomist
Gierke's respiratory bundle: tractus solitarius

GIMBERNAT, M. L. A. (1734–1816), surgeon and anatomist in Spain
Gimbernat's ligament: lig. lacunare

GIRALDÉS, J. A. C. C. (1808–1875), Paris surgeon of Portuguese birth
Giraldés' organ: paradidymis

GLASER, J. H. (1629–1675), anatomist in Basle
Glaser's fissure: fissura petrotympanica

GLISSON, F. (1597–1677), physician in London
Glisson's capsule: capsula fibrosa perivascularis hepatis

GOLGI, C. (1844–1926), anatomist in Pavia and Siena
Golgi–Mazzoni's corpuscles
Golgi's cells

GOLL, F. (1829–1903), physiologist in Zürich
Goll's column: fasciculus gracilis
Goll's nucleus: nucleus gracilis

GOWERS, W. R. (1845–1915), neurologist in London
Gowers' tract: tractus spinocerebellaris anterior

GRAAF, R. (1641–1673), anatomist in Delft
Graafian follicles

GRATIOLET, L. P. (1815–1865), anatomist and zoologist in Paris
Gratiolet's radiation: radiatio optica

GUDDEN, J. B. A. (1824–1886), psychiatrist in Munich
Gudden's commissure
Gudden's tract: tractus mamillotegmentalis

GUÉRIN, A. F. M. (1817–1895), Paris surgeon
Guérin's fold: valvula fossae navicularis

GUTHRIE, G. J. (1785–1856), surgeon in London
Guthrie's muscle: m. sphincter urethrae membranaceae

H

HALLER, A. (1708–1777), Swiss anatomist and physiologist
- Haller's ansa
- Haller's arch: ligg. arcuata (lat. et med.)
- Haller's circle: circulus arteriosus Halleri
- Haller's cone: coni vasculosi
- Haller's habenula
- Haller's layer: lamina vasculosa
- Haller's network: rete testis

HARVEY, W. (1578–1657), English physician, the discoverer of blood circulation. The book on his discovery *(Exercitatio anatomica de motu cordis et sanguinis)* was published in 1628.

HASNER, J. R. A. (1819–1892), ophthalmologist in Prague
- Hasner's valve: plica lacrimalis

HASSAL, A. H. (1817–1894), English physician and histologist
- Hassal's corpuscles

HAVERS, C. (1657–1702), English physician
- haversian canals
- haversian lamellae

HEIDENHAIN, R. P. H. (1834–1897), physiologist in Breslau
- Heidenhain's crescents or demilunes

HEISTER, L. (1683–1758), anatomist and surgeon in Altdorf and Helmstadt
- Heister's valve: plica spiralis

HELWEG, H. K. S. (1847–1901), Danish psychiatrist
- Helweg's bundle: tractus olivospinalis

HENLE, F. G. J. (1809–1885), anatomist in Göttingen
- Henle's bundle: falx inguinalis
- Henle's glands
- Henle's layer
- Henle's loop
- Henle's sheath: the endoneurium

HENSEN, V. (1835–1924), physiologist in Kiel
- Hensen's canal: ductus reuniens
- Hensen's cells

HESCHL, R. L. (1824–1881), path. anatomist in Vienna
- Heschl's convolutions: gyri temporales transversi

HESSELBACH, F. K. (1759–1816), surgeon in Würzburg
- Hesselbach's band: lig. interfoveolare

HIGHMORE, N. (1613–1685), English physician
- Highmore's antrum: sinus maxillaris
- Highmore's body: mediastinum testis

His, W. jun. (1863–1934), anatomist in Göttingen and Berlin
His' bundle: fasciculus atrioventricularis
His, W. sen. (1831–1904), German anatomist
His' canal: ductus thyreoglossus
His' spaces
Horner, W. E. (1793–1853), anatomist in Pennsylvania
Horner's muscle: pars lacrimalis m. orbicularis oculi
Hortega del Rio (1882–1945), Spanish anatomist in Buenos Aires
Hortega's cells
Houston, J. (1802–1845), physician in Dublin
Houston's valve: plicae transversales recti
Howship, J. (1781–1841), surgeon in London
Howship's lacunae
Hunter, J. (1728–1793), English surgeon and anatomist
Hunter's bundle: gubernaculum testis
Hunter's canal: canalis adductorius
Hunter's ligament: lig. teres uteri
Hunter's point
Hunter, W. (1718–1783), English anatomist, brother of J. Hunter
Hunter's membrane: decidua (uterina)
Huschke, E. (1797–1858), anatomist in Jena
Huschke's auditory teeth
Huschke's cartilage
Huschke's valve
Huxley, T. H. (1825–1895), English biologist
Huxley's layer
Hyrtl, J. (1811–1894), Viennese anatomist of Hungarian birth
Hyrtl's canal: canalis musculoperonaeus
Hyrtl's muscle: m. iliopsoas
Hyrtl's plexus

I

Ingrassia, G. F. (1510–1580), Italian anatomist and physician
Ingrassia's process: ala minor ossis sphenoidalis

J

Jackson, J. N. (1868–1935), surgeon in Kansas City
Jackson's membrane
Jacob, A. (1790–1874), Irish surgeon and anatomist
Jacob's membrane

JACOBSON, L. L. (1783–1843), Danish physician and anatomist
Jacobson's anastomosis
Jacobson's groove: sulcus promontorii
Jacobson's cartilage: cartilago vomeronasalis
Jacobson's organ: organon vomeronasale
Jacobson's plexus: plexus tympanicus
JONNESCO, T. (1860–1926), surgeon in Bucharest
Jonnesco's fossa
JUNG, K. G. (1793–1864), anatomist in Basle
Jung's muscle: m. pyramidalis auriculae

K

KEITH, A. (1866–1955), London anatomist
Keith and Flack's node: nodus sinuatrialis
KENT, A. F. S. (1863–1958), English physiologist
Kent's bundle: His' bundle
KERCKRING, TH. (1640–1693), Dutch physician
Kerckring's folds: plicae circulares intestini tenuis
KIERNAN, F. (1800–1874), surgeon in London of Irish birth
Kiernan's space: spatium interlobulare hepatis
KIESSELBACH, W. (1839–1902), otolaryngologist in Erlangen
Kiesselbach's area
KILIAN, H. F. (1800–1863), German gynaecologist
Kilian's line
KILLIAN, G. (1860–1921), laryngologist in Berlin
Killian's muscle: m. fundiformis pharyngis
KLUMPKE, A. D. K. (1859–1927), Paris neurologist
Klumpke's paralysis
KOHLRAUSCH, O. L. B. (1811–1854), German physician
Kohlrausch's folds: plicae transversales recti terminalis
KÖLLIKER, H. T. A. (1817–1905), physiologist and surgeon in Würzburg and Leipzig
Kölliker's cells: spermatoblasts
Kölliker's layer
KOYTER (Coiter), V. (1534–1600), Dutch anatomist in Bologna
Koyter's muscle: m. corrugator supercilii
KRAUSE, K. F. T. (1797–1868), anatomist in Hanover
Krause's glands: glandulae conjunctivales
KRAUSE, W. (1833–1909), anatomist in Berlin
Krause's terminal clubs
Krause's valve: valvula sacci lacrimalis inferior

KRÖNIG, G. (1856–1911), physician in Berlin
Krönig's fields
KUPFFER, K. W. (1829–1902), anatomist in Munich
Kupffer's cells
KUPRESSOFF, J. (19th century), Russian physician
Kupressoff's center

L

LABBÉ, L. (1832–1916), French surgeon
Labbé's triangle
Labbé's vein
LALLEMAND, C. F. (1790–1853), French surgeon
Lallemand's bodies
LALLOUETTE, P. (1711–1792), physician in Paris
Lallouette's pyramid: lobus pyramidalis thyroideae
LANCISI, G. M. (1654–1720), Italian anatomist
Lancisi's streaks: striae longitudinales
LANDOLT, E. (1846–1926), ophthalmologist in Paris
Landolt's bodies
LANDSTRÖM, J. (1869–1910), Swedish surgeon
Landström's muscle
LANGENBECK, B. R. K. (1810–1887), German surgeon
Langenbeck's triangle
LANGER, K. (1819–1887), Viennese anatomist
Langer's arch
LANGERHANS, P. (1847–1888), German pathologist
Langerhans' cells
Langerhans' islands
Langerhans' layer: stratum granulosum cutis
LANGHANS, T. (1839–1915), pathologist in Bern
Langhans' cells
Langhans' layer
LANGLEY, J. N. (1852–1925), physiologist in Cambridge, who studied the sympathetic nervous system
LANTERMAN, A. J. (19th century), anatomist in Strasbourg
Lanterman's clefts
LANZ, O. (1865–1935), surgeon in Amsterdam
Lanz's point
LARREY, D. J. (1766–1842), surgeon in France
Larrey's point

Larrey's triangle: trigonum sternocostale diaphragmatis

LAUMONIER, J. B. P. N. R. (1749–1818), surgeon in France
Laumonier's ganglion: ganglion caroticum

LAUTH, E. A. (1803–1837), physiologist in Strasbourg
Lauth's canal: sinus venosus sclerae

LEBER, TH. (1840–1917), German ophthalmologist
Leber's plexus

LECAT, C. N. (1700–1768), French surgeon
Lecat's gulf: dilatation of the bulbous part of the urethra

LEE, R. (1793–1877), English physiologist and gynaecologist
Lee's ganglion

LENZMAN, R. (1856–1927), physician in Duisburg
Lenzman's point: McBurney's point

LESSHAFT, P. F. (1836–1909), Russian anatomist
Lesshaft's triangle: Grynfelt's triangle

LEYDEN, E. V. (1832–1910), physiologist and physician in Berlin
Leyden's duct: ductus mesonephricus

LEYDIG, F. (1821–1908), comp. histologist in Bonn
Leydig's cells

LIEBERKÜHN, J. N. (1711–1756), physician in Berlin
Lieberkühn's glands: glandulae intestinales

LIEUTAUD, J. (1703–1780), physician and anatomist in Paris
Lieutaud's triangle: trigonum vesicae (Lieutaudi)

LISFRANC, J. (1790–1847), Paris surgeon
Lisfranc's joint: articulatio tarsometatarsea
Lisfranc's tubercle: tuberculum musculi scaleni anterioris

LISSAUER, H. (1861–1891), neurologist in Breslau
Lissauer's zone: zona terminalis medullae spinalis

LITTRÉ, A. (1658–1726), anatomist and surgeon in Paris
Littré's glands: glandulae urethrales

LOEWENBERG, B. B. (1836–1905), Parisian otolaryngologist of German birth
Loewenberg's canal: ductus cochlearis

LOUIS, P. C. A. (1787–1872), physician in Paris
Louis angle: angulus sterni

LOWER, R. (1631–1691), physician in London
Lower's ring: annulus fibrosus cordis
Lower's tubercle: tuberculum intervenosum

LUDWIG, K. F. W. (1816–1895), physiologist in Leipzig
Ludwig's ganglion

LUSCHKA, H. (1820–1875), anatomist in Tübingen
Luschka's ducts
Luschka's foramen: apertura lateralis ventriculi quarti

Luschka's gland: glomus coccygeum
Luschka's tonsil: tonsilla pharyngea
LUYS, J. B. (1828–1897), Paris neurologist
Luys' median centre
Luys' nucleus: nucleus subthalamicus

M

MCBURNEY, CH. (1845–1913), surgeon in New York
McBurney's point
McDOWELL, B. G. (1829–1885), Irish anatomist and surgeon
McDowell's frenulum
MAGENDIE, F. (1783–1855), physiologist in Paris
Magendie's foramen: apertura mediana ventriculi quarti
Magendie's spaces: spatium subarachnoidale
MAISSIAT, J. H. (1805–1878), Paris anatomist
Maissiat's band: tractus iliotibialis fasciae latae
MALACARNE, M. V. G. (1744–1816), Italian surgeon and anatomist
Malacarne's pyramid
Malacarne's space: substantia perforata post.
MALGAIGNE, J. F. (1806–1865), Paris surgeon
Malgaigne's fossa or triangle: trigonum caroticum
MALPIGHI, M. (1628–1694), Italian anatomist, professor at Bologna, Pisa and Rome
Malpighi's capsule: Bowman's capsule
Malpighi's corpuscles: 1. the lymph follicles of the spleen; 2. renal corpuscles
Malpighi's layer: stratum germinativum
Malpighi's pyramids: pyramides renales
Malpighi's rete: rete mirabile
Malpighi's saccules: alveolus pulmonis
MANZ, W. (1833–1911), German ophthalmologist
Manz's utricular glands
MARCHAND, F. (1846–1928), pathologist in Leipzig, etc.
Marchand's adrenals
Marchand's cells: cellulae peritheliales
MARCHI, V. (1851–1908), Italian physiologist
Marchi's bundle
MARIOTTE, E. (1620–1684), French prior who performed experiments on vision
Mariotte's spot: discus nervi optici
MARSHALL, J. (1818–1891), anatomist and surgeon in London
Marshall's vein: vena obliqua atrii sinistri
Marshall's vestigial fold: ligamentum venae cavae sin.

MAUCHART, B. D. (1696–1751), German anatomist
Mauchart's ligament: lig. alare
MAUTHNER, L. (1840–1894), Austrian ophthalmologist
Mauthner's sheath
MAZZONI, V. (1880–1940), Italian physiologist
Mazzoni's corpuscles
MECKEL, J. F. (1724–1774), anatomist in Berlin
Meckel's cavity: cavum trigeminale
Meckel's ganglion: ganglion pterygopalatinum
Meckel's groove: impressio trigemini
Meckel's vein
MECKEL, J. F. (1781–1833), grandson of former, anatomist, later surgeon in Halle
Meckel's cartilage
Meckel's diverticulum
MÉGLIN, J. A. M. (1756–1824), French physician
Méglin's point
MEIBOM, H. (1638–1700), anatomist in Helmstadt
Meibom's glands: glandulae tarsales
MEIGS, A. V. (1850–1912), American physiologist
Meigs' capillaries: capillares cordis terminales
MEISSNER, G. (1829–1905), German anatomist and histologist
Meissner's corpuscles
Meissner's plexus: plexus submucosus
MERCIER, L. A. (1811–1882), French urologist
Mercier's bar: plica interureterica
MERKEL, F. S. (1845–1919), German anatomist
Merkel's corpuscles
MERKEL, K. L. (1812–1876), German anatomist
Merkel's muscle: musculus ceratocricoideus
MERY, J. (1645–1722), anatomist and surgeon in Paris
Mery's glands: glandulae bulbourethrales
MEYER, G. H. (1815–1892), German anatomist
Meyer's sinus
MEYNERT, T. H. (1833–1892), Viennese neurologist
Meynert's bundle: fasciculus retroflexus
Meynert's commissure
Meynert's decussation: decussatio tegmentalis dorsalis
MICHAELIS, G. A. (1798–1848), obstetrician in Kiel
Michaelis' rhomboid
MOHRENHEIM, J. J. (1759–1799), surgeon in Vienna and later in St. Petersburg
Mohrenheim's fossa: fossa infraclavicularis
MOLL, J. A. (1832–1914), ophthalmologist and anatomist in Utrecht

Moll's glands: glandulae ciliares
MONAKOW, K. (1853–1930), neurologist in Zürich
Monakow's bundle: tractus rubrospinalis
MONRO, A. (1733–1817), Edinburgh anatomist
Monro's foramen: foramen interventriculare
Monro's gland: pars palpebralis glandulae lacrimalis
Monro's groove: sulcus hypothalamicus
MONTGOMERY, W. F. (1797–1859), gynaecologist in Dublin
Montgomery's glands: glandulae areolares mammae
MORAND, S. F. (1697–1773), surgeon in Paris
Morand's foramen: foramen caecum
MORGAGNI, G. B. (1682–1771), anatomist in Padua
Morgagni's appendix: appendix testis
Morgagni's columns: columnae anales
Morgagni's concha: concha nasalis sup.
Morgagni's foramen: foramen caecum linguae
Morgagni's lacunae: lacunae urethrales
Morgagni's pouch: ventriculus laryngis (Morgagni)
Morgagni's sinuses: sinus anales
Morgagni's tubercles: bulbus olfactorius
MÜLLER, H. (1820–1864), anatomist in Würzburg
Müller's muscle: 1. fibrae circulares musculi ciliaris; 2. musculus orbitalis
MÜLLER, J. P. (1801–1858), anatomist and physiologist in Berlin
Müller's capsule: Bowman's capsule, capsula glomeruli
Müller's duct: paramesonephic duct
Müller's ganglion: ganglion superius nervi glossopharyngei

N

NABOTH, M. (1675–1721), anatomist and physician in Leipzig
Naboth's glands and retention cysts
NÄGELE, F. K. (1777–1851), German gynaecologist
Nägele's pelvis
NASMYTH, A. (died 1848), dentist in London
Nasmyth's membrane: cuticula dentis
NAUNYN, B. (1839–1925), German physician
Naunyn's centre
NÉLATON, A. (1807–1873), Paris surgeon
Nélaton's line
Nélaton's sphinctre
NEUBAUER, J. E. (1742–1777), anatomist in Jena

Neubauer's artery: a. thyreoidea ima
NEUMANN, E. F. C. (1834–1918), pathologist in Königsberg
Neumann's cells
NISSL, F. (1860–1919), neurologist in Heidelberg
Nissl's bodies: tigroid bodies
NUCK, A. (1650–1692), anatomist in Leyden
Nuck's canal
NUEL, J. P. (1847–1920), physiologist and otologist in Ghent and Liège
Nuel's space
NUHN, A. (1814–1889), anatomist in Heidelberg
Nuhn's glands: glandulae lingualis anterior
NUSSBAUM, M. (1850–1915), German histologist
Nussbaum's cells

O

O'BEIRNE, J. (1786–1862), Irish surgeon
O'Beirne's sphincter
OCHSNER, A. J. (1858–1925), surgeon in Chicago
Ochsner's ring
ODDI, R., Italian physiologist and physician of 19th century
Oddi's sphincter
OEHL, E. (1827–1903), Italian physiologist
Oehl's layer: stratum lucidum

P

PACCHIONI, A. (1665–1726), anatomist in Rome
Pacchioni's foramen: incisura tentorii
Pacchioni's foveolae: foveolae granulares
Pacchioni's granulations: granulationes arachnoideales
PACINI, F. (1812–1883), anatomist in Florence
Pacini's corpuscles: Vater–Pacini corpuscles
PANETH, J. (1857–1890), Austrian physiologist
Paneth's cells
PASSAVANT, PH. G. (1815–1893), surgeon in Frankfort
Passavant's ridge
PAWLIK-KAREL, K. (1849–1914), gynaecologist in Prague
Pawlik's triangle
PECQUET, J. (1622–1674), French anatomist and physician
Pecquet's cistern: cisterna chyli
Pecquet's duct: ductus thoracicus

PERLIA, R. (19th century), German ophthalmologist
Perlia's nucleus
PERTIK, O. (1852–1913), pathologist in Budapest
Pertik's diverticulum
PETER, K. (1870– ?), anatomist in Greifswald
Peter's line
PÉTERFI, T. (1883–1953), Hungarian histologist in Kolozsvár (Cluj), Istanbul and finally in Budapest
Péterfi's micromanipulator
PETIT, F. P. (1664–1741), French anatomist and surgeon
Petit's canal: spatia zonularia
PETIT, J. L. (1664–1750), surgeon in Paris
Petit's triangle: trigonum lumbale
PÉTREQUIN, T. J. E. (1810–1876), Lyons surgeon
Pétrequin's ligament
PEYER, J. K. (1653–1712), anatomist in Basle
Peyer's patches: folliculi lymphatici aggregati
PFLÜGER, E. F. W. (1829–1910), physiologist in Bonn
Pflüger's tubes
PIERSOL, G. A. (1856–1924), Philadelphia anatomist
Piersol's point
PIROGOFF, N. I. (1810–1881), surgeon in St. Petersburg
Pirogoff's angle: angulus venosus
PITRES, J. A. (1848–1927), physician in Bordeaux
Pitres sections
POIRIER, P. J. (1853–1907), surgeon and anatomist in Paris
Poirier's gland
POISEUILLE, J. M. (1799–1869), physiologist in Paris
Poiseuille's space
PONFICK, E. (1844–1913), pathologist in Breslau
Ponfick's shadows
POUPART, F. (1661–1708), anatomist and surgeon in Paris
Poupart's ligament: ligamentum inguinale
Poupart's line
PRUSSAK, A. (1839–1894), Russian otologist
Prussak's fibres
Prussak's space: recessus membranae tympani sup.
PURKINJE, J. E. (1787–1869), physiologist and anatomist in Breslau, later in Prague
Purkinje's cells
Purkinje's fibres
Purkinje's network
Purkinje's vesicle

Q

QUATREFAGE DE BRÉAU, J. L. A. (1810–1892), French naturalist and anthropologist
Quatrefage's angle: angulus parietalis

R

RAMÓN Y CAJAL, S. (1852–1934), anatomist in Madrid
Cajal's cells
Cajal's nucleus: nucleus interstitialis
RANVIER, L. A. (1835–1922), anatomist in Paris
Ranvier's constrictions
Ranvier's crosses
Ranvier's motor points
Ranvier's nodes
Ranvier's segments
RATHKE, M. H. (1793–1860), anatomist in Königsberg
Rathke's bundles: trabeculae carneae
Rathke's pouch
Rathke's trabeculae: trabeculae cranii
RAU, J. J. (1668–1719), Dutch anatomist
Rau's process: processus anterior mallei
RECKLINGHAUSEN, F. D. (1833–1910), pathologist in Strasbourg
Recklinghausen's canals: lymph canaliculi, tissue spaces
REICHERT, K. B. (1811–1883), anatomist in Berlin
Reichert's cartilage
Reichert's membrane: lamina limitans anterior
Reichert's recess: recessus cochlearis
Reichert's substance
REID, R. W. (1851–1939), Scotch anatomist
Reid's base line
REIL, J. CH. (1759–1813), anatomist in Halle, later in Berlin
Reil's ansa: ansa peduncularis
Reil's band: trabecula septomarginalis
Reil's insula: insula Reilii
Reil's ribbon: lemniscus medialis
Reil's sulcus: sulcus circularis insulae
Reil's triangle: trigonum lemnisci
REISSEISEN, F. D. (1773–1828), anatomist and physician in Strasbourg
Reisseisen's muscles
REISSNER, E. (1824–1878), anatomist in Dorpat

Reissner's canal: ductus cochlearis
Reissner's membrane: membrana vestibularis
REMAK, R. (1815–1865), neurologist in Berlin
Remak's band: axon
Remak's fibres
Remak's ganglion
Remak's nuclear division: amitosis
Remak's plexus: plexus submucosus Meissneri
RETZIUS, A. A. (1796–1860), anatomist in Stockholm, later in Lund
Retzius' band: lig. fundiforme penis
Retzius' space: spatium retropubicum
Retzius' veins
RETZIUS, G. M. (1842–1919), anatomist in Stockholm
Retzius' gyrus: gyrus intralimbicus
Retzius' striae
RIBES, F. (1765–1845), French surgeon
Ribes' ganglion
RIDLEY, H. (1653–1708), anatomist and physician in London
Ridley's sinus: sinus circularis
RIEDEL, B. M. C. L. (1846–1916), surgeon in Jena
Riedel's lobe: lobus appendicularis
RINDFLEISCH, G. E. (1836–1908), German physician
Rindfleisch's cells
Rindfleisch's fold
RIOLAN, J. (1577–1657), anatomist in Paris
Riolan's arch
Riolan's bones
Riolan's bouquet
Riolan's muscle
RIVINUS, A. Q. (Bachmann) (1652–1723) latinized name, anatomist and physiologist in Leipzig
Rivinus' ducts: ductus sublinguales
Rivinus' foramen: Bochdalek's canal
Rivinus' gland
Rivinus' membrane: pars flaccida membranae tympani
ROBERT, C. A. (1801–1862), surgeon in Paris
Robert's ligament: lig. menisci lat.
ROBIN, C. P. (1821–1885), physician and histologist in Paris
Robin's space: Virchow–Robin's space
ROBINSON, F. B. (1855–1910), anatomist and surgeon in Chicago
Robinson's circle
ROLANDO, L. (1773–1831), Turin anatomist

Rolando's fissure: sulcus centralis
Rolando's lobe: operculum
Rolando's points
Rolando's substance: substantia gelatinosa

ROLLER, CH. F. W. (1802–1878), German psychiatrist
Roller's nucleus

ROSENMÜLLER, J. CH. (1771–1820), anatomist in Leipzig
Rosenmüller's gland
Rosenmüller's organ: epoophoron
Rosenmüller's recess: recessus pharyngeus
Rosenmüller's valve: plica lacrimalis

ROSENTHAL, F. CH. (1780–1829), anatomist in Greifswald
Rosenthal's vein: vena basalis

ROSER, W. (1817–1888), surgeon in Marburg
Roser–Nélaton's line

ROTH, M. (1839–1915), pathologist in Basle
Roth's vas aberrans

ROUGET, CH. (1824–1904), French physiologist and anatomist
Rouget's cells: pericytes
Rouget's muscle
Rouget's veins

RUFFINI, A. (1874–1929), histologist in Bologna
Ruffini's corpuscles

RUSSEL, W. (1852–1940), physician in Edinburgh
Russel's bodies

RUYSCH, F. (1638–1731), anatomist in Amsterdam
Ruysch's duct
Ruysch's membrane: lamina choriocapillaris
Ruysch's muscle
Ruysch's veins: vv. vorticosae: Retzius' veins

S

SANDSTRÖM, I. V. (1852–1889), anatomist in Upsala
Sandström's bodies: glandulae parathyreoideae

SANTORINI, G. D. (1681–1737), anatomist in Venice
Santorini's cartilage: cartilago corniculata
Santorini's concha: concha nasalis suprema
Santorini's duct: ductus pancreaticus accessorius
Santorini's muscles
Santorini's papilla: papilla duodeni major

Santorini's sulcus: incisurae cartilaginis meatus acustici
Santorini's tubercle: tuberculum corniculatum
Santorini's veins: vv. emmissariae parietales
SAPPEY, M. PH. C. (1810–1896), anatomist in Paris
Sappey's fibres
Sappey's ligament
Sappey's nerve
Sappey's veins: venae paraumbilicales
SCARPA, A. (1747–1832), surgeon in Modena and Pavia
Scarpa's fascia
Scarpa's foramina
Scarpa's ganglion: ganglion vestibulare
Scarpa's liquid: endolympha
Scarpa's membrane
Scarpa's nerve: nervus nasopalatinus
Scarpa's orifice: helicotrema
Scarpa's triangle: trigonum femorale
SCHACHOWA, S. (19th century), Russian histologist
Schachowa's tubes: proximal convoluted tubules
SCHLEMM, F. (1795–1858), anatomist in Berlin
Schlemm's canal: sinus venosus sclerae
Schlemm's ligament
SCHMIDEL, K. CH. (1716–1792), anatomist in Erlangen
Schmidel's anastomosis
SCHMIDT, H. D. (1823–1888), pathologist in New Orleans
Schmidt–Lantermann's clefts
SCHNEIDER, C. V. (1610–1680), physician and anatomist in Wittenberg
schneiderian membrane: tunica mucosa nasi
SCHULTZE, M. J. S. (1825–1874), German anatomist
Schultze's cells
Schultze's fascicle
SCHWALBE, G. A. (1844–1916), anatomist in Königsberg, later in Strasbourg
Schwalbe's corpuscles: taste buds
Schwalbe's nucleus: nucleus medialis nervi vestibularis
Schwalbe's space: spatium episclerale
SCHWANN, F. TH. (1810–1882), anatomist in Lüttich, later in Berlin and Liège
Schwann's sheath: neurilemma
Schwann's substance
SERRES, A. E. R. A. (1786–1868), anatomist in Paris
Serres' metafacial angle
SERTOLI, E. (1842–1910), physiologist in Milan
Sertoli's cells

SHARPEY, W. (1802–1880), London anatomist
Sharpey's fibres
SHENTON, E. W. H. (1872–1955), London radiologist
Shenton's line
SHRAPNELL, H. J. English army surgeon in the early part of the 19th century
Shrapnell's membrane: pars flaccida membranae tympani
SIBSON, F. (1814–1876), physician in London
Sibson's fascia: membrana suprapleuralis
Sibson's groove
SKENE, A. J. C. (1838–1900), gynaecologist in Brooklyn
Skene's glands
SOEMMERING, S. TH. (1755–1830), physician in Frankfurt
Soemmering's foramen: fovea centralis retinae
Soemmering's ligament
Soemmering's substance: substantia nigra
SPIGELIUS (van den Spieghel), A. (1578–1625), anatomist in Venice and Padua
Spigelius' line: linea semilunaris
spigelian lobe: lobus caudatus hepatis
SPITZKA, E. CH. (1852–1914), neurologist in New York
Spitzka's bundle
Spitzka's nucleus: Perlia's nucleus
STENSEN, N. (Steno, or Stenoninus) (1638–1686), Danish anatomist, who worked in Hanover, Münster, Florence and later returned to Copenhagen
Stensen's canal: canalis incisivus
Stensen's duct: ductus parotideus
Stensen's foramen: foramen incisivum
STIEDA, L. (1837–1918), German anatomist
Stieda's process: processus posterior tali
STILLING, B. (1810–1879), anatomist and surgeon in Kassel, later in Vienna
Stilling's column: Clarke's column
SYLVIUS (de la Boe, F.) (1614–1672), physician in Amsterp am, later in Leyden
sylvian artery: a. cerebri media
Sylvius' aquaeduct: aquaeductus cerebri
Sylvius' fissure: fissura cerebri lateralis
Sylvius' substance: substantia grisea centralis
Sylvius' valve: valvula venae cavae inferioris
Sylvius' vein: v. cerebri media
SUZANNE, J. G. (1859–?), French physician
Suzanne's gland

T

TARIN (Tarinus), P. (1725–1761), French anatomist
Tarin's fossa: fossa interpeduncularis
Tarin's hole: hiatus canalis n. petrosi major
Tarin's plate: velum medullare inferius
Tarin's space: substantia perforata posterior
TAWARA, K. S. (1873–1938), Japanese pathologist
Tawara's node: Aschoff–Tawara's node: nodus atrioventricularis
Tawara's stalk
TEICHMANN, L. K. T-S. (1823–1895), anatomist in Krakau
Teichmann's plexus
TENON, J. R. (1724–1816), ophthalmologist in Paris
Tenon's capsule: vagina bulbi
Tenon's space: spatium episclerale
THEBESIUS, A. CH. (1686–1732), anatomist in Leyden
Thebesius' foramina: foramina venarum minimarum
Thebesius' valve: valvula sinus coronarii
Thebesius' veins: venae cordis minimae
THEILE, F. W. (1801–1879), German anatomist
Theile's canal
Theile's glands
THOMSON, A. (1809–1884), Scotch anatomist
Thomson's fascia
THOREL, CH. (1868–1935), pathologist in Nürnberg
Thorel's bundle
TIEDEMANN, F. (1781–1861), anatomist and zoologist in Heidelberg
Tiedemann's glands: Bartholin's glands
Tiedemann's nerve
TOMES, C. S. (1846–1928), London dental anatomist, son of J. Tomes
Tomes' processes
TOMES, J. (1815–1895), London dental surgeon
Tomes' fibres
Tomes' granular layer
TOPINARD, P. (1830–1912), French physical anthropologist
Topinard's angle: angulus facialis
TREITZ, W. (1819–1872), Austrian physician and pathologist
Treitz's fascia: fascia retropancreatica
Treitz's fossa: recessus duodenojejunalis
Treitz's muscle: m. suspensorius duodeni
TREVES, F. (1853–1923), English surgeon
Treves' bloodless fold

TROLARD, P. (1842–1910), anatomist in Algiers
Trolard's plexus: rete canalis hypoglossi
Trolard's vein
TRÖLTSCH, A. F. (1829–1890), otologist in Würzburg
Tröltsch's recess: recessus membranae tympani anterior et posterior
TULPIUS, N. (Tulp) (1593–1674), anatomist and physician in Amsterdam
Tulp's valve: valvula ileocaecalis
TÜRCK, L. (1810–1878), neurologist and laryngologist in Vienna
Türck's tract: tractus temporopontinus
TYRREL, F. (c. 1793–1843), English surgeon and anatomist
Tyrrel's fascia: septum rectovesicale
TYSON, E. (1649–1708), anatomist in London
Tyson's glands: glandulae preputiales

V

VALENTIN, G. G. (1810–1883), physiologist in Berne
Valentin's corpuscles
VALSALVA, A. M. (1666–1723), anatomist in Bologna
Valsalva's antrum: antrum tympanicum
Valsalva's sinus: sinus aortae
VAN HELMONT, J. B. (1577–1644), Dutch surgeon
van Helmont's mirror: centrum tendineum diaphragmatis
VAN HORNE, J. (1621–1670), Dutch anatomist and surgeon
van Horne's canal: ductus thoracicus
VAROLIO, C. (1543–1575), anatomist in Bologna, later in Rome
Varolius' pons: pons cerebri
VATER, A. (1684–1751), anatomist and botanist in Wittenberg
Vater's ampulla: ampulla hepatopancreatica
Vater's papilla: papilla duodeni major
Vater–Pacini's corpuscles: corpuscula lamellosa
VERGA, A. (1811–1895), Italian anatomist and psychiatrist
Verga's ventricle: ventriculus Vergae
VERHEYEN, PH. (1648–1710), Dutch anatomist and surgeon
Verheyen's stars: venae stellatae renis
VESALIUS, A. (1514–1564), professor of anatomy in Padua, Bologna and Pisa, the "father of anatomy"
Vesalius' bones
Vesalius' foramen
Vesalius' ligament: lig. inguinale
Vesalius' vein

VICQ D'AZYR, F. (1748–1794), Paris anatomist and physician
Vicq d'Azyr's band
Vicq d'Azyr's bundle: fasciculus mamillothalamicus
Vicq d'Azyr's caecum: foramen caecum medullae oblongatae
Vicq d'Azyr's centre: centrum semiovale
VIDIANUS, G. (Vidius); (Guido Guidi) (1500–1567), anatomist and physician in Paris, later in Pisa
vidian artery: a. canalis pterygoidei
vidian canal: canalis pterygoideus
vidian nerve: n. canalis pterygoidei
vidian vein: v. canalis pterygoidei
VIEUSSENS, R. DE (1641–1716), anatomist and physician in Montpellier, later in Paris
Vieussens' ansa: ansa subclavia
Vieussens' ring: limbus fossae ovalis
Vieussen's scyphus: infundibulum cochleae
Vieussens' veins: vv. innominatae cordis
VIRCHOW, R. L. K. (1821–1902), pathologist in Berlin
Virchow–Hassal's corpuscles
Virchow–Robin's spaces: spatium perivasculare
VOLKMANN, A. W. (1800–1877), physiologist in Halle
Volkmann's canals

W

WACHENDORFF, E. J. (1703–1758), Dutch surgeon
Wachendorff's membrane: membrana pupillaris
WAGNER, R. (1805–1864), physiologist in Göttingen
Wagner's corpuscles: corpuscula tactus
Wagner's spot
WALDEYER, H. W. G. (1836–1921), anatomist in Berlin
Waldeyer's epithelium
Waldeyer's fossa: recessus duodenalis
Waldeyer's layer
Waldeyer's ring
WALTHER, A. F. (1688–1746), German anatomist and surgeon
Walther's duct: ductus sublingualis minor Rivini
Walther's ganglion: ganglion impar
WEBER, M. I. (1795–1875), anatomist in Bonn
Weber's organ: utriculus prostaticus
WEITBRECHT, J. (1702–1747), German anatomist in St. Petersburg
Weitbrecht's cartilage

Weitbrecht's foramen

WERNEKING, F. C. G. (1798–1835), anatomist in Giessen
Werneking's commissura: decussatio pedunculorum cerebellarium superiorum

WERNICKE, K. (1848–1905), psychiatrist in Halle
Wernicke's centre

WESTPHAL, K. F. O. (1833–1890), neurologist in Berlin
Westphal's nucleus: Edinger–Westphal's nucleus

WHARTON, TH. (c. 1610–1673), physician and anatomist in London
Wharton's duct: ductus submandibularis
Wharton's jelly

WILDE, W. R. W. (1815–1876), ophthalmologist in Dublin
Wilde's cord: fibrae transversae corporis callosi

WILLIS, TH. (1621–1675), anatomist and physician in London
Willis' circle: circulus arteriosus cerebri
Willis' nerve: n. accessorius
Willis' vessels: arteria comm. ant. et post.

WILSON, J. (1765–1821), surgeon and anatomist in London
Wilson's muscle: m. sphincter urethrae membranaceus

WINSLOW, J. B. (1669–1760), anatomist in Paris
Winslow's foramen: foramen epiploicum
Winslow's ligament: lig. popliteum obliquum
Winslow's pancreas
Winslow's stars

WIRSUNG, J. G. (?–1643), anatomist in Padua
Wirsung's duct: ductus pancreaticus major

WOLFF, K. F. (1733–1794), anatomist in St. Petersburg
wolffian body: mesonephros
wolffian duct: mesonephric duct

WORM, O. (1588–1654), anatomist in Copenhagen
wormian bone: ossicula intercalaria

WRISBERG, H. A. (1739–1808), anatomist in Göttingen
Wrisberg's anastomosis
Wrisberg's cartilage: cartilago cuneiformis
Wrisberg's ganglion: ganglion cardiacum
Wrisberg's loop
Wrisberg's nerve: nervus intermedius nervi facialis
Wrisberg's tuberculum: tuberculum cuneiforme

Z

ZAGLAS, J. (19th century), surgeon in Boston
Zaglas' band
ZANG, CH. B. (1772–1835), Viennese surgeon
Zang's space: fossa supraclavicularis minor
ZEIS, ED. (1807–1868), German surgeon
Zeis' glands: ciliary glands
ZEISSL, M. (1853–1925), German dermatologist
Zeissl's layer
ZINN, J. G. (1727–1759), anatomist in Göttingen
Zinn's annulus: annulus tendineus communis
Zinn's artery: a. centralis retinae
Zinn's circle: circulus vasculosus nervi optici
Zinn's ligament: annulus tendineus communis
Zinn's zonule: zonula ciliaris
ZUCKERKANDL, E. (1849–1910), anatomist in Vienna
Zuckerkandl's bodies
Zuckerkandl's convolution: gyrus paraterminalis
Zuckerkandl's glands

INDEX

The index lists the whole of the BASLE nomenclature (normal type). Only those terms of the JNA (italics) and PNA (bold-face), which differ significantly from the BNA, are inserted. In cases where there is a merely grammatical difference (e.g. os sphenoidale – os sphenoides) only the BNA term it given. The same applies to differences in terms denoting direction, which are also referred to in the table on p. 11. The number by each term in the index shows the page on which it appears in the section listing the three nomenclatures.

Abdomen 18
Abdomen 38
Abducens 18
Abductor 18
Aberrans 18
Accessorius 18
Acervulus 252
Acetabulum 49
Acinus 18
Acromion 44
Acutus 18
Adductor 18
Adeps 18
Adhesio 18
Adhesio interthalamica 232
Aditus 18
Aditus ad aquaeductum cerebri 232
Aditus glottidis inf. 148
Aditus glottidis sup. 148
Aditus laryngis 148
Aditus orbitae 80
Aditus pelvis 51
Adminiculum 18
Adminiculum lineae albae 117
Adventicius 18
Aequator (bulbi oculi) 277
Aequator lentis 282
Afferens 18
Affixus 18
Agger 18
Agger nasi 142
Ala 18
Ala cinera 224
Ala cristae galli 73
Ala lobuli centralis 228
Ala magna 65
Ala major 65
Ala minor 65
Ala nasi 143
Ala ossis ilium 49
Ala parva 65
Ala vomeris 74
Albicans 18
Albugineus 18
Albus 18
Alimentarius 18
Alveoli dentales (mandibulae) 77
Alveoli dentales (maxillae) 75
Alveoli pulmonum 151
Alveolus 18
Alveus 18
Alveus hippocampi 241
Ambiguus 18
Amnion 166
Amphiarthrosis 81
Ampulla 18
Ampulla ductus deferentis 157
Ampulla ductus lacrimalis 285
Ampullae membranaceae 286
Ampulla membranacea lat. 286
Ampulla membranacea post. 286
Ampulla membranacea sup. 286
Ampullae osseae 289
Ampulla ossea lat. 289
Ampulla ossea post. 289
Ampulla ossea sup. 289
Ampulla recti 137
Ampulla tubae uterinae 161
Ampulla urethrae 160
Amygdala 18
Anastomosis 18
Anastomosis arteriovenosa 175
Anatomia 19
Ancon 19

Angiologia 175
Angulus 19
Angulus acromialis 44
Angulus ant. pyramidis 68
Angulus arcuum costarum 63
Angulus articularis (scapulae) 44
Angulus costae 62
Angulus cranialis (scapulae) 44
Angulus frontalis (ossis parietalis) 72
Angulus inf. (scapulae) 44
Angulus infrasternalis 63
Angulus iridis 281
Angulus lat. (scapulae) 44
Angulus mandibulae 77
Angulus mastoideus (ossis parietalis) 72
Angulus med. (scapulae) 44
Angulus occipitalis (ossis parietalis) 72
Angulus oculi lat. 283
Angulus oculi med. 283
Angulus oris 126
Angulus parietalis 66
Angulus post. pyramidis 68
Angulus pubis 51
Angulus sphenoidalis (ossis parietalis) 72
Angulus sterni 62
Angulus subpubicus 51
Angulus sup. pyramidis 68
Angulus sup. (scapulae) 44
Annulus conjunctivae 278
Annulus femoralis 109
Annulus fibrocartilagineus 292
Annulus fibrosus 92
Annuli fibrosi (cordis) 177
Annulus haemorrhoidalis 138
Annulus inguinalis abdominalis 117
Annulus inguinalis subcutaneus 117
Annulus iridis major 279
Annulus iridis minor 279
Annulus tendineus communis 282
Annulus tympanicus 70
Annulus umbilicalis 116
Annulus urethralis 155
Ansa 19
Ansa cervicalis 263
Ansa cervicalis superficialis (n. facialis) 259
Ansa cruralis 233
Ansa lenticularis 233
Ansa n. hypoglossi 263
Ansae (nn. spinalium) 262
Ansa peduncularis 233
Ansa sacrococcygica 275
Ansa subclavia 273
Anserinus 19
Anterior 17
Anthelix 296
Antibrachium 39
Antitragus 296
Antrum 19
Antrum cardiacum 133
Antrum mastoideum 291
Antrum pyloricum 134
Antrum tympanicum 291
Anulus 19
Anulus inguinalis praeperitonealis 117
Anulus inguinalis profundus 117
Anulus inguinalis superficialis 117
Anus 19
Anus 137
Aorta 19
Aorta 181
Aorta abdominalis 191
Aorta ascendens 181
Aorta caudalis 191
Aorta descendens 190
Aorta thoracalis 190
Apertura 19
Apertura ext. aquaeductus vestibuli 69
Apertura ext. canaliculi cochleae 69
Apertura ext. canaliculi tympanici 69
Apertura ext. canalis carotici 69
Apertura inf. canaliculi tympanici 69
Apertura int. canaliculi n. petrosi superficialis minoris 67
Apertura int. canaliculi vestibuli 69
Apertura int. canalis carotici 67
Apertura labyrinthica canaliculi cochleae 289
Apertura lat. rhombencephali 225
Apertura lat. ventriculi quarti 225
Apertura mediana rhombencephali 224
Apertura med. ventriculi quarti 225
Apertura pelvis (minoris) inf. 51
Apertura pelvis (minoris) sup. 51
Apertura piriformis 79
Apertura sinus frontalis 73
Apertura sinus sphenoidalis 65
Apertura sup. canaliculi tympanici 67
Apertura thoracis inf. 63
Apertura thoracis sup. 62
Apertura tympanica canaliculi chordae 292
Apertura tympanica canaliculi n. petrosi superficialis minoris 291
Apertura tympanica canaliculi tympanici 291

Apertura vestibularis canaliculi vestibuli 289
Apex 19
Apex auriculae Darwini 296
Apex capituli fibulae 53
Apex (cart. arytaenoideae) 145
Apex columnae post. (medullae spinalis) 219
Apex cordis 176
Apex cornus post. (medullae spinalis) 219
Apex cuspidis 128
Apex dentis 60
Apex linguae 129
Apex nasi 143
Apex ossis sacri 61
Apex patellae 54
Apex prostatae 158
Apex pulmonis 150
Apex pyramidis 67
Apex radicis dentis 129
Apex rami radicis 129
Apex suprarenalis (gl. dextrae) 173
Apex vesicae 154
Aponeurosis 19
Aponeurosis 99
Aponeurosis linguae 129
Aponeurosis lumbalis 118
Aponeurosis m. bicipitis brachii 100
Aponeurosis palmaris 104
Aponeurosis plantaris 112
Apophysis 19
Apophysis 43
Apparatus 19
Apparatus digestorius 126
Apparatus lacrimalis 284
Apparatus respiratorius 142
Apparatus suspensorius lentis 282
Apparatus urogenitalis 152
Appendix 19
Appendix epididymidis 156
Appendices epiploicae 136
Appendix fibrosa hepatis 139
Appendices testis 156
Appendix testis 156
Appendix ventriculi laryngis 148
Appendix vermiformis 136
Appendices vesiculosi 164
Appendix vesiculosa 161
Aquaeductus 19
Aquaeductus cerebri 230
Aquaeductus mesencephali 230
Aquaeductus vestibuli 68
Aquaeductus vestibuli 285
Aquosus 19
Arachne 19
Arachnoidea encephali 251
Arachnoidea spinalis 251
Arbor 19
Arbor vitae 228
Arcuatus 19
Arcus 19
Arcus alveolaris (mandibulae) 77
Arcus alveolaris (maxillae) 75
Arcus ant. (atlantis) 60
Arcus aortae 181
Arcus (cartilaginis cricoideae) 145
Arcus costarum 63
Arcus dentalis inf. 129
Arcus dentalis sup. 129
Arcus glossopalatinus 131
Arcus iliopectineus 117
Arcus lumbocostalis lat. 116
Arcus lumbocostalis med. 116
Arcus palatini 130
Arcus palatoglossus 131
Arcus palatopharyngeus 131
Arcus palpebralis inf. 185
Arcus palpebralis sup. 185
Arcus pedis longitudinalis 41
Arcus pedis transversalis 41
Arcus pharyngopalatinus 131
Arcus plantaris 198
Arcus post. (atlantis) 60
Arcus pubis 51
Arcus superciliaris 72
Arcus tarseus inf. 185
Arcus tarseus sup. 185
Arcus tendineus 99
Arcus tendineus faciae obturatoriae 166
Arcus tendineus fasciae pelvis 167
Arcus tendineus m. levatoris ani 166
Arcus tendineus m. solei 110
Arcus venosi digitales 203
Arcus venosus dorsalis pedis 210
Arcus venosus juguli 202
Arcus venosus plantaris 211
Arcus vertebrae 58
Arcus volaris profondus 189
Arcus volaris superficialis 189
Arcus volaris venosus profundus 203
Arcus volaris venosus superficialis 203
Arcus zygomaticus 79
Area 19
Area acustica 224

Area adolfactoria 242
Area cochleae 290
Areae cribriformes 288
Area cribriformis ampullaris 289
Area cribriformis saccularis 289
Area cribriformis sclerae 277
Area cribriformis utriculoampullaris 288
Area cribrosa 153
Areae gastricae 134
Area intercondylaris ant. 53
Area intercondylaris post. 53
Area n. facialis 290
Area nuda 139
Area olfactoria 242
Area parolfactoria 242
Area postrema 224
Area subcallosa 240
Area vestibularis 224
Area vestibularis inf. 290
Area vestibularis sup. 290
Areola 19
Areola mammae 301
Arrector 19
Arteria 19
Arteria 175
A. acetabuli 194
A. alveolaris inf. 183
Aa. alveolaris superiores anteriores 184
A. alveolaris sup. post. 184
A. analis 195
A. angularis 182
A. anonyma 181
A. appendicularis 193
Aa. arciformes (renis) 153
A. arcuata 197
A. ascendens 193
A. auditiva int. 186
A. auricularis post. 183
A. auricularis profunda 183
A. axillaris 188
A. basilaris 186
A. brachialis 188
A. brachialis superfic. 188
Aa. bronchiales 190
A. buccinatoria 184
A. bulbi penis 195
A. bulbi urethrae 195
A. bulbi vestibuli (vaginae) 195
A. canalis pterygoidei 184
A. carotis communis 181
A. carotis ext. 182
A. carotis int. 184
A. caudae pancreatis 192
A. cecalis ant. 193
A. cecalis post. 193
A. centralis retinae 185
A. cerebelli inf. ant. 186
A. cerebelli inf. post. 186
A. cerebelli sup. 186
Aa. cerebri 185
A. cerebri ant. 185
A. cerebri media 185
A. cerebri post. 186
A. cervicalis ascendens 187
A. cervicalis profunda 187
A. cervicalis superficialis 187
A. chordae uteroinguinalis 195
A. chorioidea 185
Aa. chorioideae 185
A. choroidea ant. 185
Aa. ciliares anteriores 185
Aa. ciliares posteriores breves 185
Aa. ciliares posteriores longae 185
A. circumflexa femoris lat. 196
A. circumflexa femoris med. 196
A. circumflexa humeri ant. 188
A. circumflexa humeri post. 188
A. circumflexa ilium profunda 195
A. circumflexa ilium superficialis 196
A. circumflexa scapulae 188
A. clitoridis 195
A. coeliaca 191
A. colica dextra 193
A. colica media 193
A. colica sinistra 193
A. collateralis media 188
A. collateralis radialis 188
A. collateralis ulnaris inf. 188
A. collateralis ulnaris sup. 188
A. comitans n. ischiadici 194
A. communicans ant. 185
A. communicans post. 186
Aa. conjunctivales anteriores 185
Aa. conjunctivales posteriores 185
A. coronaria (cordis) dextra 181
A. coronaria (cordis) sinistra 181
Aa. corticales radiatae (renis) 153
A. cystica 191
A. deferentialis 194
Aa. digitales dorsales (manus) 189
Aa. digitales dorsales (pedis) 197
Aa. digitales plantares 198

Aa. digitales volares communes 190
Aa. digitales volares propriae 190
A. dorsalis clitoridis 195
A. dorsalis nasi 185
A. dorsalis pedis 197
A. dorsalis penis 195
A. ductus deferentis 194
Aa. encephali 185
A. epigastrica inf. 195
A. epigastrica sup. 187
A. epigastrica superficialis 196
Aa. episclerales 185
A. ethmoidalis ant. 185
A. ethmoidalis post. 185
A. facialis 182
A. femoralis 196
A. fibularis 198
A. frontalis 185
A. frontalis lat. 185
Aa. gastricae breves 192
A. gastrica dextra 191
A. gastrica sinistra 191
A. gastroduodenalis 192
A. gastroepiploica dextra 192
A. gastroepiploica sinistra 192
A. genu inf. lat. 197
A. genu inf. med. 197
A. genu media 197
A. genu sup. lat. 197
A. genu sup. med. 197
A. genu suprema 196
A. genus descendens 196
A. glutaea inf. 194
A. glutaea sup. 194
A. haemorrhoidalis inf. 195
A. haemorrhoidalis media 195
A. haemorrhoidalis sup. 193
Aa. helicinae 159
A. hepatica 191
A. hepatica propria 191
A. hyaloidea 281
A. hypogastrica 194
Aa. ileae 193
A. ileocolica 193
A. iliaca communis 194
A. iliaca ext. 195
A. ilica int. 194
A. iliolumbalis 194
A. infraorbitalis 184
Aa. intercostales 190
Aa. intercostales post. 187
A. intercostalis suprema 187
Aa. interlobares renis 153
Aa. interlobulares (hepatis) 140
Aa. interlobulares (renis) 153
A. interossea communis 189
A. interossea dorsalis 189
A. interossea recurrens 189
A. interossea volaris 189
A. intestinales 192
Aa. iridis 185
A. iridis nasalis 185
A. iridis temporalis 185
Aa. jejunales 193
Aa. labiales anteriores 196
A. labialis inf. 182
Aa. labiales posteriores 195
A. labialis sup. 182
A. labyrinthi 186
A. lacrimalis 185
A. laryngea inf. 187
A. laryngea sup. 182
A. lienalis 192
A. lig. teretis uteri 195
A. lingualis 182
A. lobi caudati 191
Aa. lumbales 191
A. lumbalis ima 191
A. malleolaris ant. lat. 197
A. malleolaris ant. med. 197
A. malleolaris post. lat. 198
A. malleolaris post. med. 198
A. mammaria int. 186
A. masseterica 184
A. maxillaris ext. 182
A. maxillaris int. 183
A. mediana 189
Aa. mediastinales anteriores 186
A. meningea ant. 185
A. meningea media 183
A. meningea post. 182
A. mentalis 183
A. mesenterica inf. 193
A. mesenterica sup. 192
Aa. metacarpeae dorsales 189
Aa. metacarpeae volares 189
Aa. metatarseae dorsales 197
A. metatarsea perforans 197
Aa. metatarseae plantares 198
A. musculi cremasteris 195
A. musculophrenica 187
Aa. nasales posteriores laterales et septi 184

A. nutricia femoris inf. 196
A. nutricia femoris sup. 196
A. nutricia fibulae 198
A. nutricia humeri 188
Aa. nutriciae pelvis renalis 154
A. nutricia tibiae 198
A. obturatoria 194
A. obturatoria accessoria 195
A. occipitalis 182
Aa. oesophageae 190
A. ophthalmica 185
A. ovarica 194
A. palatina ascendens 182
A. palatina descendens 184
A. palatina major 184
Aa. palatinae minores 184
Aa. palpebrales laterales 185
Aa. palpebrales mediales 185
A. pancreatica dorsalis 192
A. pancreatica inferior 192
A. pancreatica magna 192
A. pancreaticoduodenalis inf. 193
A. pancreaticoduodenalis sup. 192
A. penis 195
Aa. perforantes 167
A. perforans prima 196
A. perforans secunda 196
A. perforans tertia 196
A. pericardiacophrenica 186
A. perinei 195
A. peronaea 198
A. pharyngea ascendens 182
A. phrenica abdominalis 191
A. phrenica inf. 191
Aa. phrenicae superiores 190
A. plantaris lat. 198
A. plantaris med. 198
A. poplitea 197
A. princeps pollicis 189
A. profunda brachii 188
A. profunda clitoridis 195
A. profunda femoris 196
A. profunda linguae 182
A. profunda penis 195
A. pterygopalatina 184
Aa. pudendae externae 196
A. pudenda int. 195
A. pulmonalis 181
A. pulmonalis dextra 181
A. pulmonalis sinistra 181
A. radialis 189
A. radialis indicis 189
A. rectalis caudalis 195
A. rectalis cranialis 193
A. rectalis inf. 195
A. recurrens radialis 189
A. recurrens tibialis ant. 197
A. recurrens tibialis post. 197
Aa. recurrentes ulnares 189
A. renalis 193
A. retroauricularis 183
Aa. retroduodenales 192
A. sacralis lat. 194
A. sacralis media 191
A. scapularis descendens (dorsalis) 187
Aa. scrotales anteriores 196
Aa. scrotales posteriores 195
A. segmenti ant. 192
A. segmenti lat. 192
A. segmenti med. 192
A. segmenti post. 192
Aa. sigmoideae 193
A. spermatica ext. 195
A. spermatica int. 193
A. sphenopalatina 184
A. spinalis ant. 186
A. spinalis post. 186
A. sternocleidomastoidea 182
A. stylomastoidea 183
A. subclavia 186
A. subcostalis 191
A. sublingualis 182
A. submentalis 182
A. subscapularis 188
Aa. supraduodenales superiores 192
A. supraorbitalis 185
A. suprarenalis inf. 193
A. suprarenalis media 193
A. suprascapularis 187
A. supratrochlearis 185
Aa. surales 197
A. tarsea lat. 197
Aa. tarseae mediales 197
A. temporalis media 183
Aa. temporales profundae 184
A. temporalis profunda ant. 184
A. temporalis profunda post. 184
A. temporalis superficialis 183
A. testicularis 193
A. thoracalis lat. 188
A. thoracalis suprema 188
A. thoracica int. 186

A. thoracoacromialis 188
A. thoracodorsalis 188
Aa. thymicae 186
A. thyreoidea ima 181
A. thyreoidea inf. 187
A. thyreoidea sup. 182
A. tibialis ant. 197
A. tibialis post. 197
A. transversa colli 187
A. transversa faciei 183
A. transversa scapulae 187
A. tympanica ant. 183
A. tympanica inf. 182
A. tympanica post. 183
A. tympanica sup. 184
A. ulnaris 189
A. umbilicalis 194
A. urethralis 195
A. uterina 195
A. vaginalis 195
Arteriae renis 153
A. vertebralis 186
A. vesicae felleae 191
Aa. vesicales inferiores 194
A. vesicalis sup. 194
A. volaris indicis radialis 189
A. zygomaticoorbitalis 183
Arteriola 19
Arteriola 175
Arteriola afferens 153
Arteriola efferens 153
Arteriolae rectae 153
Arteriola (Venula) macularis inf. 281
Arteriola (Venula) macularis sup. 281
Arteriola (Venula) nasalis retinae inf. 281
Arteriola (Venula) nasalis retinae sup. 280
Arteriola (Venula) retinae med. 281
Arteriola (Venula) temporalis retinae inf. 280
Arteriola (Venula) temporalis retinae sup. 280
Arthrodia 81
Articulatio 19
Articulatio 81
Articulatio acromioclavicularis 83
Articulatio atlantoaxialis lat. 94
Articulatio atlantoaxialis mediana 93
Articulatio atlantoepistrophica 93
Articulatio atlantooccipitalis 93
Articulatio calcaneocuboidea 89
Articulatio capitis costae 94
Articulationes capitulorum 94
Articulationes carpometacarpeae 84
Articulatio carpometacarpea pollicis 85
Articulatio cochlearis 81
Articulatio composita 81
Articulatio condylaris 81
Articulationes costochondrales 95
Articulationes costotransversariae 94
Articulationes costovertebrales 94
Articulatio coxae 87
Articulatio cricoarytaenoidea 147
Articulatio cricothyreoidea 146
Articulatio cubiti 83
Articulatio cuneonavicularis 89
Articulationes digitorum manus 85
Articulationes digitorum pedis 92
Articulatio ellipsoidea 81
Articulatio genu 87
Articulatio humeri 83
Articulatio humeroradialis 83
Articulatio humeroulnaris 83
Articulatio incudomalleolaris 294
Articulatio incudostapedia 294
Articulatio intercarpea 84
Articulationes interchondrales 95
Articulationes intermetacarpeae 85
Articulationes intermetatarseae 91
Articulationes interphalangeae manus 85
Articulationes interphalangeae pedis 92
Articulationes intertarseae 88
Articulationes (Juncturae ossium) 81
Articulatio mandibularis 95
Articulatio manus 84
Articulatio mediocarpea 84
Articulationes metacarpophalangeae 85
Articulationes metatarsophalangeae 92
Articulationes ossiculorum auditus 294
Articulatio ossis pisiformis 84
Articulationes pedis 88
Articulatio radiocarpea 84
Articulatio radioulnaris distalis 84
Articulatio radioulnaris proximalis 83
Articulatio sacroiliaca 86
Articulatio sellaris 81
Articulatio simplex 81
Articulatio sphaeroidea 81
Articulatio sternoclavicularis 82
Articulationes sternocostales 95
Articulatio subtalaris 88
Articulatio talocalcanea 88
Articulatio talocalcaneonavicularis 88
Articulatio talocruralis 88
Articulatio talonavicularis 89

Articulatio tarsi transversa 89
Articulationes tarsometatarseae 91
Articulatio temporomandibularis 95
Articulatio tibiofibularis 88
Articulatio trochoidea 81
Articulus 19
Articulus atlantodentalis dorsalis 93
Articulus atlantodentalis ventralis 94
Articuli atlantoepistrophici laterales 94
Articulus carpometacarpicus communis 84
Articulus carpometacarpicus primus 85
Articulus cuneocuboideus 89
Articuli intercartilaginei 95
Articulus intermetatarseus tertius 91
Articuli intervertebrales 92
Articulus naviculocuboideus 89
Articulus planus 81
Articuli tarsometatarsei et intermetatarsei 91
Articulus tarsometatarseus primus 91
Articulus tarsometatarseus quartus + quintus 91
Arytena 19
Ascendens 19
Asper 19
Associus 19
Atavus 19
Atlas 60
Atrium 19
Atrium cordis 177
Atrium dextrum 178
Atrium meatus medii (nasi) 142
Atrium sinistrum 179
Auditus 19
Auricula 19
Auricula 296
Auricula atrii 177
Auricula cordis 177
Auricula dextra 178
Auricula sinistra 179
Auris 19
Auris 37
Auris ext. 295
Auris int. 285
Auris media (Cavum tympani) 291
Autonomicus 19
Axilla 19
Axilla 39
Axis 19
Axis bulbi ext. 277
Axis bulbi int. 277
Axis lentis 282
Axis oculi ext. 277
Axis oculi int. 277
Axis optica 277
Axis pelvis 51
Axis (Vertebra cerv. II.) 60
Azygos 19
Barba 299
Basilicus 19
Basis 20
Basis (cart. arytaenoideae) 145
Basis cerebri 236
Basis cochleae 289
Basis cordis 176
Basis cranii 78
Basis cranii ext. 78
Basis cranii int. 78
Basis gl. suprarenalis 173
Basis mandibulae 77
Basis (metacarpi) 48
Basis modioli 289
Basis nasi 143
Basis ossis sacri 60
Basis (ossium metatarsalium) 57
Basis patellae 54
Basis pedunculi (cerebri) 229
Basis phalangis 48
Basis prostatae 158
Basis pulmonis 150
Basis pyramidis (renalis) 153
Basis stapedis 293
Biceps 20
Bicornis 20
Bifidus 20
Bifurcatio tracheae 149
Bifurcus 20
Brachium 20
Brachium 39
Brachium colliculi caudalis 230
Brachium colliculi rostralis 230
Brachium colliculi sup. 230
Brachium conjunctivum (cerebelli) 229
Brachium pontis 225
Brachium quadrigeminum inf. 230
Brachium quadrigeminum sup. 230
Branchia 20
Brevis 20
Bronchi lobares et segmentales 149
Bronchioli 151
Bronchioli respiratorii 151
Bronchiolus 20
Bronchus 20

Bronchus (dexter et sinister) 149
Bronchus principalis (dexter et sinister) 149
Bucca 20
Bucca (Mala) 38, 126
Buccina 20
Bulbus 20
Bulbus aortae 181
Bulbus cornu post. 241
Bulbus corporis cavernosi urethrae 159
Bulbus oculi 277
Bulbus olfactorius 241
Bulbus penis 159
Bulbus pili 299
Bulbus urethrae 159
Bulbus valvularis v. jugularis int. 200
Bulbus v. jugularis inf. 200
Bulbus v. jugularis sup. 200
Bulbus vestibuli 164
Bulla 20
Bulla ethmoidalis 73
Bursa 20
Bursa anserina 113
Bursa bicipitogastrocnemialis 113
Bursa bicipitoradialis 105
Bursa capitis tibialis m. gastrocnemii 113
Bursa coccygea 120
Bursa cubitalis interossea 105
Bursa gastrocnemiosemimembranacea 113
Bursae gluteofemorales 107
Bursa iliaca subtendinea 109
Bursa iliopectinea 109
Bursa infrahyoidea 121
Bursa infrapatellaris profunda 112
Bursa infrapatellaris subcutanea 112
Bursae intermetacarpophalangeae 106
Bursae intermetatarsophalangeae 115
Bursae intermusculares mm. gluteorum 107
Bursa intratendinea olecrani 105
Bursa ischiadica m. glutaei maximi 108
Bursa ischiadica m. obturatorii int. 107
Bursa mucosa 99
Bursa mucosa subcutanea 99
Bursa mucosa subfascialis 100
Bursa mucosa submuscularis 100
Bursa mucosa subtendinea 100
Bursa m. bicipitis femoris inf. 113
Bursa m. bicipitis femoris sup. 109
Bursa m. coracobrachialis 101
Bursa m. extensoris carpi radialis brevis 106
Bursa m. flexoris carpi radialis 106
Bursa m. flexoris carpi ulnaris 106
Bursa m. gastrocnemii lat. 113
Bursa m. gastrocnemii med. 113
Bursa m. infraspinati 101
Bursa m. latissimi dorsi 118
Bursae mm. lumbricalium pedis 115
Bursa m. obturatorii int. 107
Bursa m. pectinei 109
Bursa m. piriformis 107
Bursa m. poplitei 113
Bursa m. recti femoris 109
Bursa m. sartorii propria 113
Bursa m. semimembranacei tibialis 108
Bursa m. semimembranosi 113
Bursa m. sternohyoidei 121
Bursa m. subscapularis 101
Bursa m. tensoris veli palatini 124
Bursa m. teretis majoris 101
Bursa m. thyreohyoidei 121
Bursa m. trochlearis 124
Bursa omentalis 169
Bursa ovarica 171
Bursa pharyngea 132
Bursa praepatellaris subaponeurotica 112
Bursa praepatellaris subcutanea 112
Bursa praepatellaris subfascialis 112
Bursa praepatellaris subtendinea 112
Bursa retrohyoidea 121
Bursa sinus tarsi 114
Bursa subacromialis 101
Bursa subcoracoidea 100
Bursa subcutanea acromialis 101
Bursa subcutanea calcanea 114
Bursae subcutaneae digitorum dorsales 106
Bursa subcutanea epicondyli lat. 105
Bursa subcutanea epicondyli med. 105
Bursa subcutanea infrapatellaris 112
Bursa subcutanea malleoli lat. 113
Bursa subcutanea malleoli med. 113
Bursae subcutaneae metacarpophalangeae dorsales 106
Bursa subcutanea olecrani 104
Bursa subcutanea praementalis 124
Bursa subcutanea prepatellaris 112
Bursa subcutanea prominentiae laryngeae 121
Bursa subcutanea sacralis 120
Bursa subcutanea trochanterica 107
Bursa subcutanea tuberositatis tibiae 113
Bursa subdeltoidea 101
Bursa subfascialis prepatellaris 112
Bursa subtendinea iliaca 109
Bursa subtendinea m. bicipitis femoris inf. 113

Bursa subtendinea m. gastrocnemii lat. 113
Bursa subtendinea m. gastrocnemii med. 113
Bursa subtendinea m. infraspinati 101
Bursa subtendinea m. latissimi dorsi 118
Bursa subtendinea m. obturatorii int. 107
Bursae subtendineae m. sartorii 113
Bursa subtendinea m. subscapularis 101
Bursa subtendinea m. teretis majoris 101
Bursa subtendinea m. tibialis ant. 114
Bursa subtendinea m. tibialis post. 114
Bursa subtendinea m. trapezii 118
Bursa subtendinea m. tricipitis brachii 105
Bursa subtendinea olecrani 105
Bursa subtendinea prepatellaris 112
Bursa suprapatellaris 112
Bursa synovialis 99
Bursa synovialis subcutanea 99
Bursa synovialis subfascialis 100
Bursa synovialis submuscularis 100
Bursa synovialis subtendinea 100
Bursa synovialis tendinis m. tensoris veli palatini 124
Bursa tendinis calcanei 114
Bursa tendinis m. tricipitis surae 114
Bursa testicularis 157
Bursa trochanterica m. glutaei maximi 107
Bursa trochanterica m. glutaei medii ant. 107
Bursa trochanterica m. glutaei medii post. 107
Bursa trochanterica m. glutaei medii profunda 107
Bursa trochanterica m. glutaei medii superficialis 107
Bursa trochanterica m. glutaei minimi 107
Bursa trochanterica subcutanea 107

Caecum cupulare 287
Caecum vestibulare 287
Calamus scriptorius 224
Calamus scriptorius 225
Calcaneum 20
Calcaneus 55
Calcar 20
Calcar avis 241
Caliculus 20
Caliculus ophthalmicus 277
Calix 20
Callosus 20
Calvaria 20
Calvaria 78
Calx 20
Calx 41
Calyces renales 153
Calyces renales majores 153
Calyces renales minores 153
Calyculi gustatorii 297
Camera 20
Camera ant. bulbi 281
Camera oculi ant. 281
Camera oculi post. 281
Camera post. bulbi 281
Camera vitrea bulbi 281
Canaliculus 20
Canaliculi caroticotympanici 70
Canaliculus chordae tympani 70
Canaliculus cochleae 69
Canaliculi dentales 129
Canaliculus lacrimalis 285
Canaliculus mastoideus 69
Canaliculus n. petrosi superficialis minoris 67
Canaliculus tympanicus 69
Canaliculus vestibuli 68
Canalis 20
Canalis adductorius 109
Canalis alimentarius 133
Canales alveolares 74
Canalis analis 137
Canalis basipharyngeus 66
Canalis caroticus 69
Canalis carpi 84
Canalis centralis 218
Canalis cervicis uteri 162
Canalis condyloideus 63
Canales diploici 78
Canalis facialis 68
Canalis fasciculi optici 65
Canalis femoralis 109
Canalis hyaloideus 281
Canalis hypoglossi 63
Canalis incisivus 75
Canalis infraorbitalis 74
Canalis inguinalis 117
Canalis isthmi 162
Canales longitudinales modioli 290
Canalis mandibulae 78
Canalis musculotubarius 70
Canalis nasolacrimalis 75
Canalis nutricius 43
Canalis obturatorius 86
Canalis opticus 65
Canalis orbitocranialis 73
Canalis orbitoethmoideus 73
Canales palatini 76
Canalis palatinus major 79

Canales palatini minores 76
Canalis palatovaginalis 80
Canalis pharyngeus 66
Canalis pterygoideus 66
Canalis pterygopalatinus 79
Canalis pudendalis 168
Canalis pyloricus 134
Canalis radicis dentis 129
Canalis rami radicis 129
Canalis rotundus 65
Canalis sacralis 61
Canalis semicircularis lat. 289
Canales semicirculares ossei 289
Canalis semicircularis post. 289
Canalis semicircularis sup. 289
Canalis spinalis 38
Canalis spiralis cochleae 289
Canalis spiralis modioli 289
Canalis tendinis m. flexoris carpi radialis 102
Canalis ventriculi 134
Canalis vertebralis 58
Canalis vomerovaginalis 80
Cancellus 20
Capillaris 20
Capilli 299
Capillus 20
Capitalis 20
Capitatus 20
Capitulum 20
Capitulum costae 62
Capitulum fibulae 53
Capitulum humeri 46
Capitulum mallei 293
Capitulum (metacarpi) 48
Capitulum (ossium metatarsalium) 57
Capitulum (proc. condyl.) mandibulae 78
Capitulum radii 46
Capitulum stapedis 293
Capitulum ulnae 47
Capsula 20
Capsula adiposa 152
Capsula articularis 84
Capsula articularis cricoarytaenoidea 147
Capsula articularis cricothyreoidea 146
Capsula bulbi 283
Capsula ext. (nuclei lentiformis) 243
Capsula fibrosa 172
Capsula fibrosa (hepatis) 140
Capsula fibrosa perivascularis 140
Capsula gl. thyreoideae 172
Capsula glomeruli 153
Capsula int. (nuclei lentiformis) 243
Capsula lentis 281
Capsula lienis 141
Capsula nuclei dentati 229
Capsula ossea labyrinthi 288
Capsula prostatae 167
Caput 20
Caput angulare 123
Caput breve (m. bicipitis brachii) 100
Caput breve (m. bicipitis femoris) 108
Caput epididymidis 156
Caput femoris 51
Caput humerale (m. flexoris carpi ulnaris) 102
Caput humerale (m. flexoris digitorum sublimis) 102
Caput humerale m. flexoris pollicis longi 102
Caput humerale (m. pronatoris teretis) 102
Caput humeri 45
Caput infraorbitale 123
Caput lat. (m. gastrocnemii) 110
Caput lat. (m. tricipitis brachii) 101
Caput longum (m. bicipitis brachii) 100
Caput longum (m. bicipitis femoris) 108
Caput longum (m. tricipitis brachii) 101
Caput med. (m. gastrocnemii) 110
Caput med. (m. tricipitis brachii) 101
Caput nuclei caudati 241
Caput obliquum (m. adductoris hallucis) 111
Caput obliquum m. adductoris pollicis 103
Caput ossis capitati 48
Caput pancreatis 138
Caput phalangis 48
Caput profundum m. flexoris pollicis brevis 103
Caput radiale (m. flexoris digitorum sublimis) 102
Caput superficiale m. flexoris pollicis brevis 103
Caput tali 54
Caput transversum (m. adductoris hallucis) 111
Caput transversum m. adductoris pollicis 103
Caput ulnare (m. flexoris carpi ulnaris) 102
Caput ulnare (m. pronatoris teretis) 102
Caput zygomaticum 123
Cardia 20
Cardia 133
Cardiacus 20
Carina 20
Carina urethralis vaginae 163
Carneus 20
Carpus 20
Carpus 39

Cartilago 20
Cartilago alaris major 144
Cartilagines alares minores 144
Cartilago apicis nasi 144
Cartilago articularis 82
Cartilago arytaenoidea 145
Cartilago auriculae 296
Cartilago corniculata 146
Cartilago costalis 62
Cartilago cricoidea 145
Cartilago cuneiformis 146
Cartilago epiglottica 146
Cartilago epiphysialis 43
Cartilagines laryngis 144
Cartilago meatus acustici 296
Cartilagines nasales accessoriae 144
Cartilagines nasi 143
Cartilago nasi lat. 144
Cartilago septi nasi 143
Cartilago septodorsalis 143
Cartilago sesamoidea 147
Cartilagines sesamoideae nasi 144
Cartilago thyreoidea 144
Cartilagines tracheales 149
Cartilago triticea 145
Cartilago tubae auditivae 295
Cartilago tubae pharyngotympanicae 295
Cartilago vomeronasalis 144
Caruncula 20
Carunculae hymenales 163
Caruncula lacrimalis 284
Caruncula sublingualis 126
Carunculae sublinguales 126
Cauda 20
Cauda epididymidis 156
Cauda equina 262
Cauda helicis 296
Cauda nuclei caudati 241
Cauda pancreatis 138
Caudalis 17
Caverna 20
Cavernae corporum cavernosorum 159
Cavernae corporis spongiosi 159
Cavitas 21
Cavitas glenoidalis 44
Cavum 21
Cavum abdominis 38
Cavum abdominis 168
Cavum articulare 82
Cavum conchae 296
Cavum coronale 129
Cavum corporis uteri 162
Cavum dentis 129
Cavum epidurale 251
Cavum extradurale 251
Cavum infraglotticum 148
Cavum laryngis 148
Cavum leptomeningicum 251
Cavum mediastinale ant. 152
Cavum mediastinale post. 152
Cavum medullare 43
Cavum nasi 142
Cavum nasi ossei 79
Cavum oris 126
Cavum oris proprium 126
Cavum pelvis 39
Cavum pericardii 176
Cavum peritonaei 168
Cavum pharyngis 132
Cavum pleurae 151
Cavum septi pellucidi 240
Cavum subarachnoidale 251
Cavum subdurale 251
Cavum thoracis 62
Cavum thoracis et pleura 151
Cavum trigeminale 250
Cavum tympani 291
Cavum uteri 162
Cavus 21
Cecum 136
Cecus 21
Celiacus 21
Cella 21
Cellula 21
Cellulae anteriores (cavi nasi) 143
Cellulae ethmoidales (cavi nasi) 143
Cellulae ethmoidales (ossis ethmoidalis) 73
Cellulae mastoideae 292
Cellulae mediae (cavi nasi) 143
Cellulae pneumaticae tubariae 295
Cellulae posteriores (cavi nasi) 143
Cellulae tympanicae 292
Cementum 129
Centralis 21
Centrum 21
Centrum semiovale 242
Centrum tendineum 116
Centrum tendineum perinei 166
Cephalicus 21
Cerebellum 21
Cerebellum 227
Cerebrum 21

Cerebrum 236
Ceruleus 21
Cerumen 300
Cervix 21
Cervix 38
Cervix columnae post. (medullae spinalis) 219
Cervix uteri 162
Cervix vesicae 154
Chiasma 21
Chiasma fasciculorum opticorum 232
Chiasma opticum 232
Chiasma tendinum 104
Choanae 80
Choanae (nasi) 142
Chorda 21
Chorda a. umbilicalis 194
Chorda ductus arteriosi 181
Chorda ductus venosi 139
Chorda obliqua 83
Chordae sternopericardiacae 176
Chordae tendineae 177
Chorda tympani 259
Chorda urachi 154
Chorda uteroinguinalis (teres) 163
Chorda uteroovarica 161
Chorda v. umbilicalis 139
Chorioidea 278
Chorion 166
Choroidea 21
Chroma 21
Chylus 21
Chylus 135
Chymus 135
Cilia 283
Cilium 21
Cinereus 21
Cingulum 21
Cingulum 242
Cingulum extremitatis inf. 49
Cingulum extremitatis sup. 44
Cingulum membri inf. 49
Cingulum membri sup. 44
Circulus 21
Circulus arteriosus 186
Circulus arteriosus major (iridis) 279
Circulus arteriosus minor (iridis) 279
Circulus articularis vasculosus 175
Circulus vasculosus n. optici 280
Circumferentia 21
Circumferentia articularis (radii) 46
Circumferentia articularis (ulnae) 47
Circumflexus 21
Cisterna 21, 175
Cisterna ambiens 251
Cisterna cerebellomedullaris 251
Cisterna chiasmatis 251
Cisterna chyli 211
Cisterna corporis callosi 251
Cisterna fossae lat. cerebri 251
Cisterna intercruralis 251
Cisterna interpenduncularis 251
Cisternae leptomeningicae 251
Cisternae subarachnoidales 251
Cisterna valleculae lat. cerebri 251
Cisterna v. magnae cerebri 251
Claustrum 21
Claustrum 243
Clava 221
Clavicula 21
Clavicula 44
Clinoideus 21
Clitoris 21
Clitoris 165
Clivus 21
Clivus (cranii) 79
Clivus (ossis occipitalis) 63
Clivus (ossis sphenoidalis) 64
Clunis 21
Coccyx 21
Cochlea 21
Cochlea 289
Collateralis 21
Colliculus 21
Colliculus (cart. arytaenoideae) 146
Colliculus facialis 224
Colliculus inf. (corporum quadrigem.) 230
Colliculus rostralis (corporum quadrigem.) 229
Colliculus seminalis 160
Colliculus sup. (corporum quadrigem.) 229
Collum 21, 37
Collum anatomicum 45
Collum chirurgicum 45
Collum costae 62
Collum dentis 129
Collum femoris 52
Collum folliculi pili 299
Collum glandis (penis) 158
Collum mallei 293
Collum (proc. condyl.) mandibulae 78
Collum radii 46
Collum scapulae 44
Collum tali 54

Collum vesicae felleae 140
Colon 21
Colon 136
Colon ascendens 136
Colon descendens 136
Colon sigmoideum 136
Colon transversum 136
Colostrum 301
Columna 21
Columna ant. (medullae spinalis) 219
Columna fornicis 240
Columnae griseae (medullae spinalis) 219
Columna lat. (medullae spinalis) 219
Columna post. (medullae spinalis) 219
Columnae rectales 138
Columnae renales 153
Columnae rugarum 163
Columna rugarum ant. 163
Columna rugarum post. 163
Columna vertebralis 38
Comes 21
Commissura 21
Commissura alba 219
Commissura ant. alba 219
Commissura ant. (cerebri) 244
Commissura ant. grisea (medullae spinalis) 219
Commissura basialis 233
Commissura dorsalis 233
Commissura fornicis 240
Commissura grisea (medullae spinalis) 219
Commissura habenularum 234
Commissura hippocampi 241
Commissura inf. 233
Commissura labiorum 126
Commissura labiorum ant. (pudendi) 164
Commissura labiorum post. (pudendi) 164
Commissura palpebrarum lat. 283
Commissura palpebrarum med. 283
Commissura pinealis 245
Commissura post. (cerebri) 232
Commissura post. (medullae spinalis) 219
Commissura rostralis (cerebri) 244
Commissura sup. 233
Commissura supraopticae 233
Communis 21
Compactus 22
Compressor 22
Concha 22
Concha auriculae 296
Concha nasalis inf. 74
Concha nasalis media 73
Concha nasalis sup. 73
Concha nasalis suprema 73
Conchae sphenoidales 64
Condylus 22
Condylus humeri 46
Condylus lat. (femoris) 52
Condylus lat. (tibiae) 52
Condylus med. (femoris) 52
Condylus med. (tibiae) 52
Condylus occipitalis 63
Conexus 22
Confluens 22
Confluens sinuum 203
Congenitus 22
Conjugata 51
Conjugata vera 51
Conjugatio 22
Conjunctiva 284
Conjunctivus 22
Connexus intertendineus 103
Constrictor 22
Conus 22
Conus arteriosus 179
Conus elasticus 149
Conus medullaris 218
Coni vasculosi 156
Convexus 22
Convolutus 22
Cor 176
Corium 22
Corium 298
Cornea 22
Cornea 278
Corniculatus 22
Corniculum 22
Cornu 22
Cornu ant. (medullae spinalis) 219
Cornu ant. (ventriculi lat.) 241
Cornu coccygea 61
Cornu cricoideum 145
Cornu hyoideum 145
Cornu inf. (cart. thyreoideae) 145
Cornu inf. (fossae ovalis) 109
Cornu inf. (ventriculi lat.) 241
Cornu lat. (medullae spinalis) 219
Cornu majus 78
Cornu minus 78
Cornu ossis sacri 61
Cornu post. (medullae spinalis) 219
Cornu post. (ventriculi lat.) 241
Cornua sacralia 61

Cornu sup. (cart. thyreoideae) 145
Cornu sup. (fossae ovalis) 109
Corona 22
Corona ciliaris 278
Corona clinica 128
Corona dentis 128
Corona glandis (penis) 158
Corona radiata 243
Coronalis 17
Corpus 22
Corpus adiposum buccae 126
Corpus adiposum fossae ischiorectalis 168
Corpus adiposum genus 87
Corpus adiposum infrapatellare 87
Corpus adiposum orbitae 283
Corpus albicans 161
Corpus amygdaloideum 243
Corpus atreticum 161
Corpus calcanei 56
Corpus callosum 240
Corpus cavernosum 175
Corpus cavernosum clitoridis 165
Corpus cavernosum penis 159
Corpus cavernosum urethrae 159
Corpus ciliare 278
Corpus clitoridis 165
Corpus coccygeum 191
Corpus costae 62
Corpus epididymidis 156
Corpus femoris 52
Corpus fibulae 54
Corpus fornicis 240
Corpus geniculatum lat. 234
Corpus geniculatum med. 234
Corpus glandulare (prostatae) 158
Corpus gl. bulbourethralis 158
Corpus gl. sudoriferae 300
Corpus humeri 45
Corpus incudis 293
Corpora interrenalia accessoria 173
Corpus linguae 129
Corpus luteum 161
Corpus mamillare 232
Corpus mammae 300
Corpus mandibulae 77
Corpus maxillae 74
Corpus medullare (cerebelli) 228
Corpus (metacarpi) 48
Corpus nuclei caudati 241
Corpus (ossis hyoidei) 78
Corpus ossis ilium 49
Corpus ossis ischii 50
Corpus (ossium metatarsalium) 57
Corpus ossis pubis 50
Corpus (ossis sphenoidalis) 64
Corpus pancreatis 138
Corpus papillare (corii) 298
Corpora paraaortica 181
Corpus penis 158
Corpus phalangis 48
Corpus pineale 173
Corpora quadrigemina 229
Corpus radii 46
Corpus restiforme 221
Corpus spongiosum penis 159
Corpus spongiosum urethrae (muliebris) 165
Corpus sterni 62
Corpus striatum 243
Corpus suprarenale 173
Corpus tali 54
Corpus tibiae 53
Corpus trapezoideum 225
Corpus ulnae 47
Corpus unguis 299
Corpus uteri 162
Corpus ventriculi 134
Corpus vertebrae 58
Corpus vesicae 154
Corpus vesicae felleae 140
Corpus vesiculae seminalis 157
Corpus vitreum 281
Corpus Wolffi 165
Corpusculum 22
Corpuscula bulboidea 298
Corpuscula lamellosa 298
Corpuscula nervorum articularia 299
Corpuscula nervorum genitalia 299
Corpuscula nervorum terminalia 298
Corpuscula nervosa terminalia 218
Corpuscula renis 153
Corpuscula tactus 298
Corrugator 22
Cortex 22, 43
Cortex 173
Cortex cerebelli 229
Cortex cerebri 242
Cortex lentis 281
Cortex (nodi lymph.) 211
Cortex renis 153
Costa 22
Costae 61
Costae arcuariae 61

Costae arcuariae affixae 61
Costae arcuariae fluctuantes 61
Costae spuriae 61
Costae sternales 61
Costae verae 61
Cotyla 22
Coxa 22
Coxa 39
Cranialis 17
Cranium 22
Cranium 37
Cranium cerebrale 78
Cranium viscerale 78
Crassus 22
Crena 22
Crena ani 39
Cribriformis 22
Cribrosus 22
Cribrum 22
Cricoideus 22
Crista 22
Crista ampullaris 286
Crista ant. (fibulae) 54
Crista ant. (tibiae) 53
Crista arcuata (cart. arytaenoideae) 146
Crista basilaris 287
Crista buccinatoria 78
Crista capituli (costae) 62
Crista colli costae 62
Crista columnae dorsalis (medullae spinalis) 219
Crista conchalis (maxillae) 75
Crista conchalis (ossis palatini) 76
Cristae cutis 298
Crista ethmoidalis (maxillae) 75
Crista ethmoidalis (ossis palatini) 76
Crista femoris 52
Crista fenestrae cochleae 291
Crista frontalis 72
Crista galli 73
Crista iliaca 49
Crista infratemporalis 65
Crista infrazygomatica 74
Crista interossea (fibulae) 54
Crista interossea (radii) 46
Crista interossea (tibiae) 53
Crista interossea (ulnae) 47
Crista intertrochanterica 52
Crista lacrimalis ant. 75
Crista lacrimalis post. 74
Crista lat. (fibulae) 54
Crista marginalis 129
Cristae matricis unguis 299
Crista med. (fibulae) 54
Crista m. supinatoris 47
Crista nasalis (maxillae) 75
Crista nasalis (ossis palatini) 76
Crista obturatoria 50
Crista occipitalis ext. 64
Crista occipitalis int. 64
Crista palatina 76
Crista phallica 51
Crista pubica 50
Crista pyramidis 68
Cristae sacrales articulares 61
Crista sacralis intermedia 61
Cristae sacrales laterales 61
Crista sacralis media 61
Crista sphenoidalis 65
Crista supraventricularis 179
Crista tegmentalis 70
Crista terminalis (atrii dextri) 178
Crista transversa (fundus meatus acustici int.) 290
Crista transversalis 128
Crista triangularis 128
Crista tuberculi majoris 45
Crista tuberculi minoris 45
Crista tympanica 70
Crista urethralis (urethrae muliebris) 165
Crista urethralis (urethrae virilis) 160
Crista vestibuli 288
Cruces pilorum 299
Cruciatus 22
Crus 22, 40
Crura ampullaria 289
Crus ant. capsulae int. 243
Crus ant. (stapedis) 293
Crura anthelicis 296
Crus breve (incudis) 293
Crura cerebelli 228
Crus cerebellocerebrale 229
Crus cerebri 229
Crus cerebri + tegmentum 229
Crus clitoridis 165
Crus commune (labyrinthi ossei) 289
Crura corporis cavernosi penis 158
Crus curvilineum (stapedis) 293
Crus (dextrum et sinistrum) 177
Crura (fasciculi atrioventricularis) 177
Crus fornicis 240
Crus frontale (capsulae int.) 243
Crus helicis 296

Crus inf. (annuli inguinalis subcutanei) 117
Crus intermedium (diaphragmatis) 116
Crus lat. (anuli inguinalis subcutanei) 117
Crus lat. (cart. alaris majoris) 144
Crus lat. (diaphragmatis) 116
Crus longum (incudis) 293
Crus med. (anuli inguinalis subcutanei) 117
Crus med. (cart. alaris majoris) 144
Crus med. (diaphragmatis) 116
Crura membranacea 286
Crura membranacea ampullaria 286
Crus membranaceum commune 286
Crus membranaceum simplex 286
Crus occipitale (capsulae int.) 243
Crura ossea 289
Crura ossea ampullaria 289
Crus osseum commune 289
Crus osseum simplex 289
Crus penis 158
Crus post. capsulae int. 243
Crus post. (stapedis) 293
Crus rectilineum (stapedis) 293
Crus simplex (labyrinthi ossei) 289
Crus sup. (annuli inguinalis subcutanei) 117
Cryptae tonsillares (tonsillae palatinae et pharyngeae) 131
Cubitum 22
Cubitus 39
Culmen 22
Culmen 228
Cumulus 22
Cumulus oophorus 161
Cumulus oviger 161
Cuneus 22
Cuneus 240
Cupula 22
Cupula 286
Cupula (cochleae) 289
Cupula pericardii 176
Cupula pleurae 151
Curvatura 22
Curvatura ventriculi major 133
Curvatura ventriculi minor 133
Cuspis 22
Cuspis ant. (valvulae bicuspidalis) 180
Cuspis ant. (valvulae tricuspidalis) 179
Cuspis (coronae) dentis 128
Cuspis med. (valvulae tricuspidalis) 179
Cuspis post. (valvulae bicuspidalis) 180
Cuspis post. (valvulae tricuspidalis) 179
Cuspis septalis (valvulae tricuspidalis) 179
Cuticula 23
Cuticula dentis 129
Cutis 23
Cutis 298
Cymba conchae 296
Decidua basalis 166
Decidua capsularis 166
Decidua parietalis 166
Decidua vera 166
Deciduus 23
Declive 23
Declive 228
Decursus fibrarum cerebralium 242
Decussatio 23
Decussatio brachii conjunctivi 231
Decussatio crurum cerebellocerebralium 231
Decussatio lemniscorum 223
Decussatio nervorum trochlearium 253
Decussatio pedunculorum cerebellarium sup. 231
Decussatio pyramidum 221
Decussationes tegmentorum 231
Deferens 23
Delta 23
Dens 23
Densus 23
Dentes 128
Dentes acustici (ductus cochlearis) 287
Dentes canini 129
Dentes decidui 128
Dens (epistrophei) 60
Dentes incisivi 129
Dentes molares 129
Dentes permanentes 128
Dentes praemolares 129
Dens serotinus 129
Denticulatus 22
Dentinum 23, 129
Depressor 23
Dermis 23
Descendens 23
Descensus testis 157
Detrusor 23
Dexter 17
Diameter diagonalis 51
Diameter mediana 51
Diameter obliqua 51
Diameter transversa 51
Diaphragma 23
Diaphragma 115
Diaphragma pelvis 166

Diaphragma sellae 250
Diaphragma urogenitale 167
Diaphysis 23
Diaphysis 43
Diarthrosis 81
Diastema 23
Diencephalon 23
Diencephalon 232
Digastricus 23
Digitalis 23
Digitationes hippocampi 241
Digitus 23
Digitus annularis 48
Digiti manus 40
Digitus medius 49
Digitus minimus (manus) 49
Digitus minimus (pedis) 58
Digiti pedis 41
Digiti II.—IV. (pedis) 58
Dilator 23
Diploë 78
Diplois 23
Discus 23
Discus articularis 82
Discus articularis (art. acromioclavicularis) 83
Discus articularis (art. mandibularis) 95
Discus articularis (art. radioulnaris distalis) 84
Discus articularis (art. sternoclavicularis) 83
Discus interpubicus 86
Disci intervertebrales 92
Discus n. optici 280
Distalis 18
Diverticulum 23
Diverticula ampullae (ductus deferentis) 157
Dorsalis 17
Dorsum 23, 38
Dorsum linguae 129
Dorsum manus 40
Dorsum nasi 143
Dorsum pedis 41
Dorsum penis 158
Dorsum sellae 65
Ductulus 23
Ductuli aberrantes 156
Ductulus aberrans sup. 156
Ductuli alveolares (pulmonis) 151
Ductuli efferentes testis 156
Ductuli excretorii (gl. lacrimalis) 285
Ductuli transversi (epoophori) 164
Ductus 23
Ductus arteriosus 181
Ductus biliferi 140
Ductus biliferi interlobulares 140
Ductus choledochus 141
Ductus cochlearis 287
Ductus cysticus 141
Ductus deferens 156
Ductus ejaculatorius 157
Ductus endolymphaticus 285
Ductus epididymidis 156
Ductus epoophori longitudinalis 164
Ductus excretorius (gl. bulbourethralis) 158
Ductus excretorius (vesiculae seminalis) 157
Ductus g. bulbourethralis 158
Ductus hepaticus 140
Ductus incisivus 143
Ductus interlobulares (hepatis) 140
Ductus lacrimales 285
Ductus lactiferi 301
Ductus lingualis 130
Ductus lymphaticus dexter 211
Ductus mesonephricus 166
Ductus Mülleri 166
Ductus nasolacrimalis 285
Ductus pancreaticus 138
Ductus pancreaticus accessorius 138
Ductus pancreaticus major 138
Ductus pancreaticus minor 138
Ductus paramesonephricus 166
Ductus paraurethrales 165
Ductus parotideus 127
Ductus perilymphatici 287
Ductus prostatici 158
Ductus reuniens 287
Ductus semicirculares 285
Ductus semicircularis lat. 286
Ductus semicircularis post. 286
Ductus semicircularis sup. 286
Ductus sublingualis major 127
Ductus sublinguales minores 127
Ductus submandibularis 127
Ductus submaxillaris 127
Ductus sudoriferus 300
Ductus thoracicus 211
Ductus thyreoglossus 130
Ductus utriculosaccularis 285
Ductus venosus 207
Ductus Wolffi 166
Duodeni 23
Duodenum 135
Dura mater encephali 250

Dura mater spinalis 251
Durus 23

Efferens 23
Ejaculatorius 23
Elasticus 23
Ellipsoideus 23
Embryo 23
Eminentia 23
Eminentia arcuata 68
Eminentia carpi radialis 48
Eminentia carpi ulnaris 48
Eminentia collateralis 241
Eminentia conchae 297
Eminentia cruciata 64
Eminentia fossae triangularis 297
Eminentia iliopectinea 50
Eminentia iliopubica 50
Eminentia intercondyloidea 52
Eminentia med. 224
Eminentia pyramidalis 292
Eminentia scaphae 297
Eminentia triangularis 297
Emissarium 175
Emissarium condyloideum 204
Emissarium mastoideum 204
Emissarium occipitale 204
Emissarium parietale 204
Emissarius 23
Enamelum 129
Enarthrosis 81
Encephalon 23
Encephalon 221
Endocardium 177
Endolympha 287
Endometrium 163
Endosteum 43
Endothelium 23, 125
Endothelium camerae ant. 278
Entericus 23
Ependyma 23
Ependyma ventriculorum 217
Epicardium 177
Epicondylus 24
Epicondylus lat. (femoris) 52
Epicondylus lat. (humeri) 46
Epicondylus med. (femoris) 52
Epicondylus med. (humeri) 46
Epidermis 24
Epidermis 298
Epididymis 24
Epididymis 156
Epigastrium 24
Epiglottis 146
Epiorchium 157
Epiphysis 24
Epiphysis 43
Epistropheus 60
Epithalamus 234
Epithelium 24, 125
Epithelium corneae 278
Epithelium ductus semicircularis 285
Epithelium lentis 281
Eponychium 300
Epoophoron 164
Equator 24
Equinus 24
Erector 24
Esophagus 24
Excavatio 24
Excavatio disci 280
Excavatio papillae n. optici 280
Excavatio rectouterina 171
Excavatio rectovesicalis 172
Excavatio vesicouterina 171
Exitus pelvis 51
Extensor 24
Externus 17
Extremitas 24
Extremitates 37
Extremitas acromialis (claviculae) 45
Extremitas ant. (lienis) 141
Extremitas capitalis (testis) 155
Extremitas inf. (corporis) 40
Extremitas inf. (lienis) 141
Extremitas inf. (renis) 152
Extremitas inf. (testis) 155
Extremitas pelvina 40
Extremitas post. (lienis) 141
Extremitas sternalis (claviculae) 44
Extremitas sup. (corporis) 39
Extremitas sup. (lienis) 141
Extremitas sup. (renis) 152
Extremitas sup. (testis) 155
Extremitas thoracica 39
Extremitas tubaria (ovarii) 160
Extremitas uterina (ovarii) 161
Extremitas ventralis (lienis) 141
Extremitas vertebralis (lienis) 141

Facies 24, 37
Facies ant. (brachii) 39

Facies ant. (corneae) 278
Facies ant. (cruris) 40
Facies ant. (dentium praemolarium et molarium) 128
Facies ant. (femoris) 40
Facies ant. (gl. suprarenalis) 173
Facies ant. (iridis) 279
Facies ant. lat. (humeri) 45
Facies ant. (lentis) 282
Facies ant. (maxillae) 74
Facies ant. med. (humeri) 45
Facies ant. palpebrarum 283
Facies ant. (pancreatis) 138
Facies ant. (patellae) 54
Facies ant. (prostatae) 158
Facies ant. pyramidis 67
Facies ant. (renis) 152
Facies anterolat. (cart. arytenoideae) 145
Facies articularis 43
Facies articularis acromialis (claviculae) 45
Facies articularis acromii 44
Facies articularis ant. (calcanei) 56
Facies articularis ant. (epistrophei) 60
Facies articularis arytaenoidea 145
Facies articularis calcanea ant. (tali) 55
Facies articularis calcanea media (tali) 55
Facies articularis calcanea post. (tali) 55
Facies articularis calcanearis dist. 55
Facies articularis calcanearis dist. bipartita 55
Facies articularis calcanearis proximalis 55
Facies articularis capituli costae 62
Facies articularis capituli (fibulae) 54
Facies articularis carpea 46
Facies articularis (cart. arytaenoideae) 145
Facies articularis cuboidea 56
Facies articularis dentalis 60
Facies articularis fibularis tibiae 53
Facies articulares inferiores (atlantis) 60
Facies articularis inf. (tibiae) 53
Facies articulares inferiores (vertebrae) 59
Facies articularis lat. (epistrophei) 60
Facies articularis malleolaris (fibulae) 54
Facies articularis malleolaris (tibiae) 53
Facies articularis media (calcanei) 56
Facies articularis (metatarsi) 57
Facies articularis navicularis (tali) 54
Facies articularis (patellae) 54
Facies articularis (phalangis) 57
Facies articularis post. (calcanei) 56
Facies articularis post. (epistrophei) 60
Facies articularis pro ligamento calcaneonaviculari 55
Facies articularis sternalis (claviculae) 45
Facies articularis sup. (tibiae) 52
Facies articulares superiores (vertebrae) 58
Facies articularis talaris dist. bipartita 56
Facies articularis talaris dist. (calcanei) 56
Facies articularis talaris proximalis (calcanei) 56
Facies articularis (temporalis) 67
Facies articularis thyreoidea 145
Facies articularis tuberculi costae 62
Facies auricularis (ossis ilium) 50
Facies auricularis (ossis sacri) 61
Facies basialis cerebri 236
Facies basialis pyramidis 69
Facies caudalis (vertebrae) 58
Facies cerebellaris (post. int.) pyramidis 68
Facies cerebralis (alae magnae) 65
Facies cerebralis (ant. int.) pyramidis 67
Facies cerebralis (ossis frontalis) 72
Facies cerebralis (ossis parietalis) 71
Facies cerebralis (ossis sphenoidalis) 65
Facies cerebralis (squamae temporalis) 67
Facies colica 141
Facies conjunctivalis palpebrae 283
Facies contactus (dentis) 128
Facies contactus loborum (pulmonis) 150
Facies convexa cerebri 236
Facies costalis processus transversi vertebrae thoracicae 59
Facies costalis (pulmonis) 150
Facies costalis (scapulae) 44
Facies cranialis (vertebrae) 58
Facies cutanea palpebrae 283
Facies diaphragmatica (cordis) 176
Facies diaphragmatica (hepatis) 139
Facies diaphragmatica (lienis) 141
Facies diaphragmatica (pulmonis) 150
Facies distalis 128
Facies dorsalis (antibrachii) 39
Facies dorsalis (ossis sacri) 61
Facies dorsalis (radii) 46
Facies dorsalis (scapulae) 44
Facies dorsalis (ulnae) 47
Facies ext. (baseos cranii) 78
Facies ext. (ossis frontalis) 72
Facies frontalis (ossis frontalis) 72
Facies gastrica (lienis) 141
Facies glutea 50
Facies inf. cerebri 236
Facies inf. (hemisphaerii cerebelli) 228

Facies inf. (hepatis) 139
Facies inf. (linguae) 130
Facies inf. (mesencephali) 229
Facies inf. (pancreatis) 138
Facies inf. pyramidis 69
Facies inferolateralis (prostatae) 158
Facies infratemporalis 66
Facies infratemporalis 74
Facies interlobares (pulmonis) 150
Facies int. (baseos cranii) 78
Facies int. (ossis frontalis) 72
Facies int. (ossis parietalis) 71
Facies intestinalis uteri 162
Facies labialis (buccalis) (dentis) 128
Facies lat. (brachii) 39
Facies lat. (dentium incisivorum et caninorum) 128
Facies lat. (digiti pedis) 41
Facies lat. (femoris) 40
Facies lat. (fibulae) 54
Facies lat. (fibularis) (crusis) 40
Facies lat. (ossis zygomatici) 76
Facies lat. (ovarii) 166
Facies laterales (radiales) (digiti manus) 49
Facies lat. (radii) 46
Facies lat. (testis) 155
Facies lat. (tibiae) 53
Facies lingualis (dentis) 128
Facies lunata 49
Facies malaris (ossis zygomatici) 76
Facies malleolaris lat. (tali) 55
Facies malleolaris med. (tali) 55
Facies masticatoria (dentis) 128
Facies maxillaris (ossis palatini) 75
Facies med. (brachii) 39
Facies med. (cart. arytenoideae) 145
Facies med. (cerebri) 236
Facies med. (dentium incisivorum et caninorum) 128
Facies med. (digiti pedis) 41
Facies med. (femoris) 40
Facies med. (fibulae) 54
Facies med. (hemisphaerii cerebri) 239
Facies med. (ovarii) 160
Facies med. (testis) 155
Facies med. (tibiae) 53
Facies med. (tibialis) (cruris) 41
Facies med. (ulnae) 47
Facies mediales (ulnares) (digiti manus) 49
Facies mediastinalis (pulmonis) 150
Facies mesialis 128
Facies mylohyoidea linguae 130
Facies nasalis (maxillae) 74
Facies nasalis (ossis palatini) 76
Facies occlusalis 128
Facies orbitalis (maxillae) 74
Facies orbitalis (ossis frontalis) 72
Facies orbitalis (ossis sphenoidalis) 66
Facies orbitalis (ossis zygomatici) 76
Facies (ossium cranii) 78
Facies palatina 76
Facies parietalis 71
Facies patellaris 52
Facies pelvina 61
Facies post. (brachii) 39
Facies post. (cart. arytenoideae) 145
Facies post. (corneae) 278
Facies post. (cruris) 40
Facies post. (dentium praemolarium et molarium) 128
Facies post. (femoris) 40
Facies post. (fibulae) 54
Facies post. (gl. suprarenalis) 173
Facies post. (hepatis) 139
Facies post. (humeri) 45
Facies post. (iridis) 279
Facies post. (lentis) 282
Facies post. palpebrarum 283
Facies post. (pancreatis) 138
Facies post. (prostatae) 158
Facies post. pyramidis 68
Facies post. (renis) 152
Facies post. (tibiae) 53
Facies pubica (prostatae) 158
Facies pulmonalis (cordis) 176
Facies rectalis (prostatae) 158
Facies rectalis (uteri) 162
Facies renalis 173
Facies renalis (lienis) 141
Facies sacropelvina 50
Facies sphenomaxillaris 65
Facies sternocostalis (cordis) 176
Facies sup. (hemisphaerii cerebelli) 228
Facies sup. (hepatis) 139
Facies sup. (tali) 55
Facies superolat. cerebri 236
Facies symphyseos 51
Facies temporalis (ossis frontalis) 72
Facies temporalis (ossis sphenoidalis) 65
Facies temporalis (ossis zygomatici) 76
Facies temporalis (squamae temporalis) 66
Facies terminalis caudalis (ossis sacri) 61

Facies terminalis cranialis (ossis sacri) 60
Facies terminalis sacralis (ossis coccygis) 61
Facies tympanica pyramidis 70
Facies ulnaris (antibrachii) 39
Facies urethralis penis 158
Facies vesicalis (prostatae) 158
Facies vesicalis uteri 162
Facies vestibularis (facialis) 128
Facies visceralis (hepatis) 139
Facies visceralis (lienis) 141
Facies volaris (antibrachii) 39
Facies volaris (radii) 46
Facies volaris (ulnae) 47
Falx 24
Falx (aponeurotica) inguinalis 117
Falx cerebelli 250
Falx cerebri 250
Falx septi 179
Fascia 24, 99
Fascia antibrachii 103
Fascia axillaris 100
Fascia brachii 101
Fascia buccopharyngea 123
Fascia bulbi 283
Fascia cervicalis 121
Fascia clavipectoralis 116
Fascia clitoridis 165
Fascia colli 121
Fascia colli media 121
Fascia colli profunda (praevertebralis) 121
Fascia colli superficialis 121
Fascia coracoclavicularis 116
Fascia coracocleidopectoralis 116
Fascia cremasterica 157
Fascia cribrosa 109
Fascia cruris 110
Fascia dentata hippocampi 241
Fascia diaphragmatis pelvis ext. 167
Fascia diaphragmatis pelvis inf. 167
Fascia diaphragmatis pelvis int. 167
Fascia diaphragmatis pelvis sup. 167
Fascia diaphragmatis urogenitalis ext. 167
Fascia diaphragmatis urogenitalis inf. 167
Fascia diaphragmatis urogenitalis int. 167
Fascia diaphragmatis urogenitalis sup. 167
Fascia dorsalis manus 104
Fascia dorsalis pedis 111
Fascia endopelvina 167
Fascia endothoracica 152
Fascia iliaca 109
Fascia iliopectinea 109
Fascia infraspinata 100
Fascia intrapelvina 167
Fascia lata 108
Fascia lumbodorsalis 118
Fascia masseterica 123
Fasciae musculares (m. oculi) 283
Fascia m. obturatoris int. 166
Fascia nuchae 120
Fascia obturatoria 166
Fascia parotideomasseterica 123
Fascia pectinea 109
Fascia pectoralis 116
Fascia pelvis 166
Fascia pelvis parietalis 166
Fascia pelvis visceralis 167
Fascia penis 159
Fascia penis profunda 159
Fascia penis superficialis 159
Fascia pharyngobasilaris 132
Fascia pharyngobuccinatoria 123
Fascia phrenicopleuralis 152
Fascia praevertebralis 121
Fascia prostatae 167
Fascia psoica 108
Fascia spermatica ext. 157
Fascia spermatica int. 157
Fascia subperitonealis 168
Fascia subscapularis 100
Fascia superficialis 99
Fascia superficialis perinei 168
Fascia supraspinata 100
Fascia temporalis 124
Fascia thoracolumbalis 118
Fascia transversalis 117
Fasciculus 217
Fasciculus 24
Fasciculus ant. proprius 220
Fasciculus anterolateralis superficialis 220
Fasciculus atrioventricularis 177
Fasciculus cerebellospinalis 220
Fasciculus cerebrospinalis ant. (pyradmidalis ant.) 219
Fasciculus cerebrospinalis lat. (pyramidalis lat.) 220
Fasciculi corporis restiformis 223
Fasciculi corticothalamici 245
Fasciculus cuneatus (medullae oblongatae) 221
Fasciculus cuneatus (medullae spinalis) 220
Fasciculus dorsalis (medullae oblongatae) 220
Fasciculus dorsalis (medullae spinalis) 218
Fasciculus dorsolateralis 248

Fasciculus frontooccipitalis 242
Fasciculus gracilis (medullae oblongatae) 221
Fasciculus gracilis (medullae spinalis) 220
Fasciculus interfascicularis 248
Fasciculi intersegmentales 244
Fasciculus labialis (m. orbicularis oculi) 122
Fasciculus lat. (medullae oblongatae) 220
Fasciculus lat. (medullae spinalis) 218
Fasciculus lat. (plexus brachialis) 264
Fasciculus lat. proprius (medullae spinalis) 220
Fasciculus longitudinalis dorsalis 223
Fasciculus longitudinalis dorsalis 227
Fasciculus longitudinalis inf. 242
Fasciculus longitudinalis med. 223
Fasciculi longitudinales (junct. columnae vert.) 94
Fasciculi longitudinales (pyramidales) 227
Fasciculus longitudinalis sup. 242
Fasciculus mamillotegmentalis 246
Fasciculi mamillotendinei 119
Fasciculus mamillothalamicus 233
Fasciculus med. (plexus brachialis) 264
Fasciculi medullae spinalis 218
Fasciculus mentalis (m. buccinatorii) 123
Fasciculi (musculares) periostales mandibulae 123
Fasciculi (musculares) periostales maxillae 123
Fasciculus obliquus (pontis) 225
Fasciculus opticus 252
Fasciculi pedunculomamillares 233
Fasciculus post. (plexus brachialis) 264
Fasciculi proprii medullae spinalis 220
Fasciculi pyramidales 223
Fasciculus retroflexus 235
Fasciculi rubroreticulares 248
Fasciculus semilunaris 248
Fasciculus septomarginalis 248
Fasciculus solitarius 222
Fasciculus subcallosus 250
Fasciculus temporooccipitalis 242
Fasciculi thalamocorticales 245
Fasciculus thalamomamillaris 233
Fasciculi transversi (aponeurosis palmaris) 104
Fasciculi transversi (aponeurosis plantaris) 112
Fasciculus triangularis 248
Fasciculus uncinatus 242
Fasciculus ventralis (medullae spinalis) 218
Fasciola cinerea 240
Fastigium 225
Fauces 24
Fauces 38, 130
Fel (Bilis) 140
Femur 51
Fenestra 24
Fenestra cochleae 291
Fenestra vestibuli 291
Fetus 24
Fibra 24
Fibra 217
Fibrae arcuatae cerebri 242
Fibrae arcuatae externae 221
Fibrae arcuatae externae dorsales 223
Fibrae arcuatae externae ventrales 223
Fibrae arcuatae internae 223
Fibrae cerebelloolivares 223
Fibrae circulares 279
Fibrae corticonucleares 246
Fibrae corticopontinae 223
Fibrae corticoreticulares 246
Fibrae corticospinales 223
Fibrae intercrurales 117
Fibrae lentis 281
Fibrae meridionales 278
Fibrae obliquae (ventriculi) 134
Fibrae periventriculares 249
Fibrae periventriculares (hypothalami) 233
Fibrae pontis profundae 227
Fibrae pontis superficiales 227
Fibrae pontis transversae 249
Fibrae striarum medullarium 250
Fibrae striarum medullarium (thalami) 234
Fibrae suspensioriae (lentis) 282
Fibrae zonulares 282
Fibrocartilago 24
Fibrocartilago basalis 79
Fibrocartilagines intervertebrales 92
Fibrocartilago navicularis 90
Fibula 53
Fibularis 18
Filamentum 24
Filum 24
Filum 218
Fila anastomotica (n. acustici) 259
Filum durae matris spinalis 251
Fila lateralia pontis 225
Fila olfactoria 252
Fila radicularia (nn. spinalium) 262
Filum terminale 218
Fimbria 24
Fimbria hippocampi 241
Fimbria ovarica 161

Fimbriae tubae 161
Fissura 24
Fissura accessoria pulmonis dextri 150
Fissura antitragohelicina 296
Fissura calcarina 240
Fissurae cerebelli 227
Fissura cerebri lat. 236
Fissura cerebrocerebellaris 227
Fissura choroidea 241
Fissura collateralis 239
Fissura hippocampi 239
Fissura horizontalis cerebelli 227
Fissura horizontalis (pulmonis dext.) 150
Fissura interhemisphaerica 236
Fissura interlobaris (pulmonis) 150
Fissura lig. teretis 139
Fissura lig. venosi 139
Fissura longitudinalis cerebri 236
Fissura mediana ant. 218
Fissura mediana ant. (medullae oblongatae) 221
Fissura mediana post. (medullae oblongatae) 221
Fissura obliqua (pulmonis) 150
Fissura orbitalis cerebralis 65
Fissura orbitalis inf. 80
Fissura orbitalis sphenomaxillaris 80
Fissura orbitalis sup. 65, 80
Fissura parietooccipitalis 240
Fissura petrooccipitalis 79
Fissura petrosquamosa 70
Fissura petrotympanica 70
Fissura posterolat. (cerebelli) 228
Fissura prima (cerebelli) 227
Fissura pterygoidea 66
Fissura pterygomaxillaris 79
Fissura sagittalis (sin.) 139
Fissura secunda 227
Fissura sphenooccipitalis 79
Fissura sphenopetrosa 79
Fissura telodiencephalica 236
Fissura transversa cerebelli 227
Fissura transversa cerebri 236
Fissura tympanomastoidea 71
Fissura tympanosquamosa 71
Flavus 24
Flexor 24
Flexura 24
Flexura coli dextra 136
Flexura coli hepatica 136
Flexura coli lienalis 136
Flexura coli sinistra 136
Flexura duodeni inf. 135
Flexura duodeni sup. 135
Flexura duodenojejunalis 135
Flexura perinealis recti 137
Flexura sacralis recti 137
Flocculus 228
Flocculi secundarii 228
Flumina pilorum 299
Folium 24
Folia cerebelli 227
Folium vermis 228
Folliculus 24
Folliculi gl. thyroideae 172
Folliculi linguales 130
Folliculus lymphaticus 212
Folliculi lymphatici aggregati appendicis vermiformis 136
Folliculi lymphatici aggregati (intestini tenuis) 135
Folliculi lymphatici gastrici 134
Folliculi lymphatici (intestini recti) 137
Folliculi lymphatici laryngei 149
Folliculi lymphatici lienales 142
Folliculi lymphatici solitarii (intestini crassi) 137
Folliculi oophori primarii 161
Folliculi oophori vesiculosi 161
Folliculi ovarii 161
Folliculi ovarii primarii 161
Folliculi ovarii secundarii 161
Folliculi ovarii vesiculosi 161
Folliculus pili 299
Fonticulus 24
Fonticulus ant. 98
Fonticuli cranii 98
Fonticulus frontalis (major) 98
Fonticulus major 98
Fonticulus mastoideus 98
Fonticulus minor 98
Fonticulus occipitalis (minor) 98
Fonticulus post. 98
Fonticulus sphenoidalis 98
Foramen 24
Foramina alveolaria 74
Foramen apicis dentis 129
Foramen apicis rami radicis 129
Foramen caecum 72
Foramen caecum linguae 130
Foramen caecum (medullae oblongatae) 221
Foramina cartilaginis meatus acustici ext. 296
Foramen costotransversarium 95
Foramen costotransversarium vertebrae cervicalis 59

Foramen diaphragmatis (sellae) 250
Foramen epiploicum 169
Foramina ethmoidalia 73
Foramen ethmoidale ant. 73
Foramen ethmoidale post. 73
Foramen incisivum 75
Foramen infraorbitale 74
Foramen interventriculare 232
Foramen intervertebrale 59
Foramina intervertebralia 61
Foramen ischiadicum majus 86
Foramen ischiadicum minus 86
Foramen jugulare 79
Foramen lacerum 79
Foramen magnum (ossis occipitalis) 63
Foramen mandibulare 78
Foramen mastoideum 71
Foramen mentale 77
Foramina nasalia 74
Foramina nervosa 288
Foramen nutricium 43
Foramen obturatum 49
Foramen occipitale magnum 63
Foramen oesophagicum 116
Foramen opticum 65
Foramen ovale 65
Foramen ovale (septi atriorum) 178
Foramen palatinum majus 76
Foramina palatina minora 76
Foramina papillaria 153
Foramen parietale 71
Foramen pterygopalatinum 79
Foramen rotundum 65
Foramina sacralia anteriora 61
Foramina sacralia pelvina 61
Foramina sacralia posteriora 61
Foramen singulare 290
Foramen sive Incisura supraorbitalis 72
Foramen sphenopalatinum 79
Foramen sphenopalatinum 79
Foramen spinosum 65
Foramen stylomastoideum 69
Foramen supraorbitale 72
Foramen thyreoideum 145
Foramen transversarium 59
Foramen venae cavae 116
Foramina venarum minimarum 178
Foramen vertebrale 58
Foramen zygomaticofaciale 76
Foramen zygomaticoorbitale 76
Foramen zygomaticotemporale 77
Forceps 24
Forceps major 245
Forceps minor 245
Formatio 24
Formatio reticularis (medullae oblongatae) 223
Formatio reticularis (medullae spinalis) 219
Formatio reticularis (mesencephali) 230
Formatio reticularis (pontis) 225
Fornix 20
Fornix 24, 240
Fornix conjunctivae inf. 284
Fornix conjunctivae sup. 284
Fornix pharyngis 131
Fornix sacci lacrimalis 285
Fornix vaginae 163
Fossa 24
Fossa acetabuli 49
Fossa anthelicis 297
Fossa articularis (scapulae) 44
Fossa axillaris 305
Fossa caecalis 171
Fossa canina 74
Fossa carotica 304
Fossa cerebri lat. 236
Fossa commissurae caudalis (cerebri) 232
Fossa condyloidea 63
Fossa coronoidea (humeri) 46
Fossa cranii ant. 78
Fossa cranii media 79
Fossa cranii occipitalis 79
Fossa cranii post. 79
Fossa cubitalis 306
Fossa digastrica 77
Fossa ductus venosi 139
Fossa epigastrica 38
Fossa gl. lacrimalis 72
Fossa hyaloidea 281
Fossa hypophyseos 65
Fossa iliaca 50
Fossa iliacosubfascialis 171
Fossa iliopectinea 109
Fossa incisiva 109
Fossa incisiva (palati ossei) 80
Fossa incudis 292
Fossa infraspinata 44
Fossa infratemporalis 79
Fossa inguinalis lat. 171
Fossa inguinalis med. 171
Fossa intercondyloidea 52
Fossa intercondyloidea ant. 53
Fossa intercondyloidea post. 53

Fossa intercruralis 229
Fossa interpeduncularis 229
Fossa ischiorectalis 168
Fossa jugularis (ossis temporalis) 69
Fossa jugularis (regionis colli anterioris) 304
Fossa lat. cerebri 236
Fossa malleoli fibulae 54
Fossa malleoli lat. 54
Fossa mandibularis 67
Fossa m. biventeris 77
Fossa navicularis urethrae 160
Fossa navicularis (vestibuli vaginae) 164
Fossa occipitalis cerebellaris 64
Fossa occipitalis cerebralis 64
Fossa olecrani (humeri) 46
Fossa ovalis (fasciae latae) 109
Fossa ovalis (septi atriorum) 178
Fossa poplitea 307
Fossa praenasalis 74
Fossa pterygoidea 66
Fossa pterygopalatina 79
Fossa radialis (humeri) 46
Fossa retromandibularis 304
Fossa rhomboidea 223
Fossa sacci lacrimalis 74
Fossae sagittales dextrae (hepatis) 139
Fossa sagittalis sinistra (hepatis) 139
Fossa scaphoidea 66
Fossa subarcuata 68
Fossa subinguinalis 307
Fossa subscapularis 44
Fossa supraclavicularis major 304
Fossa supraclavicularis minor 304
Fossa supraspinata 44
Fossa supratonsillaris 131
Fossa supravesicalis 171
Fossa temporalis 79
Fossa tonsillaris 131
Fossa triangularis 296
Fossa trochanterica 52
Fossa venae cavae 139
Fossa venae umbilicalis 139
Fossa vesicae felleae 139
Fossa vestibuli vaginae 164
Fossula 24
Fossula fenestrae cochleae 291
Fossula fenestrae vestibuli 291
Fossula petrosa 69
Fossulae tonsillares (tonsillae palatinae) 131
Fossulae tonsillares (tonsillae pharyngeae) 131
Fovea 24
Fovea articularis inf. (atlantis) 60
Foveae articulares superiores (atlantis) 60
Fovea capitis femoris 51
Fovea capituli radii 46
Fovea centralis 280
Fovea costalis inf. 59
Fovea costalis sup. 59
Fovea costalis transversalis 59
Fovea dentis (atlantis) 60
Fovea inf. (fossae rhomboideae) 224
Fovea inguinalis lat. 171
Fovea inguinalis med. 171
Fovea nuchae 304
Fovea oblonga (cart. arytaenoideae) 146
Fovea pterygoidea (proc. condyloidei) 78
Fovea rostralis (fossae rhomboideae) 224
Fovea sublingualis 77
Fovea submandibularis 77
Fovea submaxillaris 77
Fovea sup. (fossae rhomboideae) 224
Fovea supravesicalis 171
Fovea triangularis (cart. arytaenoideae) 146
Fovea trochlearis 72
Foveola 24
Foveola coccygea 298
Foveolae ethmoideae 72
Foveolae gastricae 134
Foveolae granulares (Pacchioni) 71
Frenulum 24
Frenulum clitoridis 165
Frenulum labii inf. 126
Frenulum labii sup. 126
Frenulum labiorum pudendi 164
Frenulum linguae 130
Frenulum praeputii 159
Frenulum valvulae coli 136
Frenulum veli medullaris ant. 224
Frenulum veli medullaris sup. 224
Frons 24
Frons 78
Frontalis 17
Funda 25
Fundus 25
Fundus folliculi pili 299
Fundus meatus acustici int. 290
Fundus uteri 162
Fundus ventriculi 133
Fundus vesicae 154
Fundus vesicae felleae 140
Funiculus 25
Funiculus ant. (medullae spinalis) 218

Funiculus cuneatus (medullae oblongatae) 221
Funiculus gracilis (medullae oblongatae) 221
Funiculus lat. (medullae oblongatae) 221
Funiculus lat. (medullae spinalis) 218
Funiculi medullae spinalis 218
Funiculus post. (medullae spinalis) 218
Funiculus sclerae 277
Funiculus spermaticus et tunicae testis et funiculi spermatici 157
Funiculus umbilicalis 165
Fuscus 25
Fusiformis 25

Galea 25
Galea aponeurotica 122
Gallus 25
Ganglion 25
Ganglion 217
Ganglion aorticorenale 274
Ganglion cardiacum 273
Ganglion cervicale inf. 273
Ganglion cervicale medium 273
Ganglion cervicale superius 272
Ganglion cervicothoracicum (stellatum) 273
Ganglion ciliare 254
Ganglia coeliaca (syst. sympathici) 274
Ganglion extracraniale (n. glossopharyngici) 260
Ganglion geniculi 259
Ganglion impar 274
Ganglion inf. (n. glossopharyngei) 260
Ganglion inf. (n. vagi) 261
Ganglion intercrurale 230
Ganglia intermedia (trunci sympathici) 271
Ganglion interpeduncular 230
Ganglion intracraniale (n. glossopharyngici) 260
Ganglion jugulare (n. vagi) 261
Ganglia lumbalia (syst. sympathici) 274
Ganglion mesentericum inf. 275
Ganglion mesentericum sup. 274
Ganglion n. laryngici cranialis 261
Ganglion nodosum (n. vagi) 261
Ganglion oticum 258
Ganglia pelvica 275
Ganglion petrosum (n. glossopharyngei) 260
Ganglia phrenica 274
Ganglia plexuum autonomicorum 271
Ganglia plexuum sympathicorum 271
Ganglion pterygopalatinum 255
Ganglia renalia 274
Ganglia sacralia (syst. sympathici) 274
Ganglion semilunare 253
Ganglion sphenopalatinum 255
Ganglion spinale 262
Ganglion spirale 260
Ganglion spirale cochleae 288
Ganglion splanchnicum 273
Ganglion sublinguale 258
Ganglion submandibulare 258
Ganglion submaxillare 258
Ganglion sup. (n. glossopharyngei) 260
Ganglion sup. (n. vagi) 261
Ganglion terminale 271
Ganglia thoracalia 273
Ganglion trigeminale 253
Ganglia trunci sympathici 271
Ganglion tympanicum 260
Ganglion vertebrale (trunci sympathici) 273
Ganglion vestibulare 260
Gaster 25
Gelatinosus 25
Genesis 25
Geniculum 25
Geniculum canalis facialis 68
Geniculum n. facialis 258
Genitalis 25
Genu 25, 40
Genu capsulae int. 243
Genu corporis callosi 240
Genu (internum) (radicis n. facialis) 225
Genu n. facialis 225
Germen 25
Germinativus 25
Gingiva 25
Gingiva 126
Ginglymus 25
Ginglymus 81
Glabella 72
Glandula 25, 125
Gl. apicis linguae 127
Gll. areolares 301
Gll. bronchiales 150
Gll. buccales 127
Gl. bulbourethralis 158
Gll. ceruminosae 300
Gll. cervicales (uteri) 163
Gll. ciliares 284
Gll. circumanales 300
Gll. conjunctivales 284
Gll. cutis 300
Gll. duodenales 135
Gll. gastricae (propriae) 134
Gll. glomiformes 300

Gll. intestinales (intestini tenuis, crassi) 135
Gll. labiales 127
Gll. lacrimales accessoriae 285
Gl. lacrimalis inf. 284
Gl. lacrimalis sup. 284
Gll. laryngeae 149
Gll. laryngeae anteriores 149
Gll. laryngeae mediae 149
Gll. laryngeae posteriores 149
Gll. linguales 127
Gl. lingualis ant. 127
Gl. mammaria 300
Gll. molares 127
Gl. mucosa 125
Gll. mucosae biliosae 141
Gll. mucosae (tubae auditivae) 295
Gll. mucosae (tunicae conjunctivae) 284
Gll. mucosae ureteris 154
Gll. nasales 143
Gll. oesophageae 133
Gll. olfactoriae 143
Gll. oris 127
Gll. palatinae 127
Gll. parathyreoideae craniales et caudales 173
Gll. paraurethrales (urethrae femininae) 165
Gll. paraurethrales (urethrae masculinae) 160
Gl. parotis 127
Gl. parotis accessoria 127
Gl. pelvis renalis 153
Gll. pharyngeae 132
Gl. pituitaria 173
Gll. praeputiales 159
Gll. pyloricae 134
Gll. retromolares 127
Gl. sebaceae 284
Gll. sebaceae (areolae mammae) 300
Gll. sebaceae (labiorum pudendi) 164
Gl. seromucosa 125
Gl. serosa 125
Gl. sine ductibus 172
Gl. sublingualis 127
Gll. sublinguales minores 127
Gl. submandibularis 127
Gl. submaxillaris 127
Gll. sudoriferae 300
Gll. sudoriferae axillares 300
Gll. sudoriferae ciliares 284
Gll. sudoriferae majores 300
Gll. sudoriferae minores 300
Gll. sudoriferae nasales 300
Gl. suprarenalis 173
Gll. suprarenales accessoriae 173
Gll. tarsales 284
Gl. thyreoidea 172
Gll. thyreoideae accessoriae 172
Gl. thyreoidea accessoria suprahyoidea 172
Gll. tracheales 149
Gll. trigonales 155
Gl. tubariae 295
Gll. tympanicae 294
Gll. urethrales 160
Gll. urethrales (urethrae muliebris) 165
Gll. uterinae 163
Gll. vesicales 155
Gl. vesiculosa 157
Gl. vestibularis major 165
Gll. vestibulares minores 164
Glans 25
Glans clitoridis 165
Glans penis 158
Globus 25
Globus pallidus 243
Glomerulus 25
Glomeruli 153
Glomeruli arteriosi cochleae 288
Glomus 25
Glomus caroticum 181
Glomus chorioideum 252
Glomus coccygeum 191
Glottis 148
Gluteus 25
Gomphosis 25
Gomphosis 81
Gracilis 25
Granula meningica 251
Granulatio 25
Granulationes arachnoidales 251
Granulosa folliculi 161
Griseus 25
Gubernaculum testis 157
Gyrus 25
Gyrus angularis 239
Gyri breves insulae 237
Gyrus centralis ant. 237
Gyrus centralis post. 238
Gyri cerebelli 227
Gyri cerebri 236
Gyrus cinguli 239
Gyrus circumflexus 239
Gyrus dentatus 241
Gyrus fasciolaris 240
Gyrus fornicatus 239

Gyrus frontalis inf. 237
Gyrus frontalis medialis 239
Gyrus frontalis medius 237
Gyrus frontalis sup. 237
Gyrus fusiformis 239
Gyrus hippocampi 239
Gyri insulae 236
Gyrus lingualis 239
Gyrus longus insulae 237
Gyri occipitales laterales 238
Gyri occipitales superiores 238
Gyrus occipitotemporalis lat. 239
Gyrus occipitotemporalis med. 239
Gyri orbitales 237
Gyrus parahippocampalis 239
Gyrus paraterminalis 240
Gyrus postcentralis 238
Gyrus praecentralis 237
Gyri profundi (cerebri) 236
Gyrus rectus 237
Gyrus subcallosus (Pedunculus corporis callosi) 242
Gyrus supramarginalis 239
Gyrus (systematis nervorum) 217
Gyrus temporalis inf. 238
Gyrus temporalis medius 238
Gyrus temporalis sup. 238
Gyri temporales transversi 237
Gyri transitivi (cerebri) 236

Habenula 234
Haemolymphonodus 212
Hallux 25
Hallux 58
Hamatus 25
Hamulus 25
Hamulus lacrimalis 74
Hamulus laminae spiralis 290
Hamulus ossis hamati 48
Hamulus pterygoideus 66
Haustra coli 136
Haustrum 25
Helicotrema 290
Helix 25
Helix 296
Hemisphaerium 236
Hemisphaeria bulbi urethrae 159
Hemisphaerium cerebelli 228
Hemispherium 25
Hepar 25
Hepar 138
Hiatus 25
Hiatus aorticus 116
Hiatus canalis adductorii 109
Hiatus canalis facialis 68
Hiatus canalis n. petrosi majoris 68
Hiatus canalis n. petrosi minoris 68
Hiatus canalis sacralis 61
Hiatus maxillaris 75
Hiatus oesophageus 116
Hiatus sacralis 61
Hiatus saphenus 109
Hiatus semilunaris 73, 143
Hiatus subarcuatus 68
Hiatus tendineus 109
Hilus 25
Hilus 173
Hilus corporis suprarenalis 173
Hilus gl. suprarenalis 173
Hilus lienis 141
Hilus (lgl.) 212
Hilus nuclei dentati 229
Hilus nuclei olivaris 222
Hilus ovarii 161
Hilus pulmonis 150
Hilus renalis 152
Hippocampus 25
Hippocampus 241
Hirci 299
Homo 25
Horizontalis 17
Humerus 45
Humor 25
Humor aqueus 281
Humor vitreus 281
Hyalinus 25
Hybrida 26
Hymen 26
Hymen 163
Hyoideus 26
Hypogastrium 26
Hypoglossus 26
Hyponchium 300
Hypophysis 173
Hypothalamus 232
Hypothenar 40

Ileum 26, 136
Ilia 26
Iliacus 26
Impar 26
Impressio 26

Impressio cardiaca (hepatis) 139
Impressio cardiaca (pulmonis) 150
Impressio colica (hepatis) 139
Impressio costae primae (pulmonis) 150
Impressiones digitatae 79
Impressio duodenalis (hepatis) 139
Impressio gastrica (hepatis) 139
Impressio gastrica (renis) 152
Impressiones gyrorum 79
Impressio hepatica (renis) 152
Impressio lig. costoclavicularis 45
Impressio muscularis (renis) 152
Impressio oesophagea (hepatis) 139
Impressio petrosa (cerebri) 236
Impressio renalis (hepatis) 139
Impressio suprarenalis (hepatis) 139
Impressio trigemini 67
Imus 26
Incisura 26
Incisura acetabuli 49
Incisura angularis 133
Incisura ant. (auris) 296
Incisura (apicis) cordis 176
Incisura cardiaca 133
Incisura cardiaca (pulmonis) 150
Incisurae cartilaginis meatus acustici ext. 296
Incisura cerebelli ant. 227
Incisura cerebelli post. 227
Incisura clavicularis (sterni) 62
Incisurae costales 62
Incisura ethmoidalis 72
Incisura fibularis 53
Incisura frontalis 72
Incisura frontalis lat. 72
Incisura hepatis 138
Incisura interarytaenoidea 149
Incisura interlobaris (pulmonis) 150
Incisura intertragica 296
Incisura ischiadica major 50
Incisura ischiadica minor 50
Incisura jugularis (ossis occipitalis) 63
Incisura jugularis (ossis temporalis) 69
Incisura jugularis (sterni) 62
Incisura lacrimalis 75
Incisura lig. teretis 138
Incisura mandibulae 78
Incisura mastoidea 71
Incisura nasalis 74
Incisura pancreatis 138
Incisura parietalis 67
Incisura preoccipitalis 238
Incisura pterygoidea 66
Incisura pterygopalatina 76
Incisura radialis (ulnae) 47
Incisura scapulae 44
Incisura semilunaris 47
Incisura sive Foramen frontale 72
Incisura sphenopalatina 76
Incisura tentorii 250
Incisura terminalis auris 296
Incisura thyreoidea inf. 144
Incisura thyreoidea sup. 144
Incisura trochlearis 47
Incisura tympanica 70
Incisura tympanica 295
Incisura ulnaris (radii) 46
Incisura umbilicalis (hepatis) 138
Incisura vertebralis inf. 58
Incisura vertebralis sup. 58
Incisus 26
Inclinatio pelvis 51
Incus 293
Index 26
Index 49
Indusium griseum 240
Inferior 17
Infundibulum 26, 232
Infundibulum ethmoidale (nasi) 143
Infundibulum ethmoidale (ossis ethmoidalis) 73
Infundibulum tubae uterinae 161
Inguen 26
Inguen 39
Inscriptio tendinea 99
Inscriptiones tendineae 116
Insula 26
Insula 236
Integumentum 26
Integumentum commune 298
Intercalatus 26
Intermedius 17
Internus 17
Intersectio 26
Interstitium 26
Intestinum 26
Intestinum caecum 136
Intestinum colon 136
Intestinum crassum 136
Intestinum duodenum 135
Intestinum ileum 136
Intestinum jejunum 136
Intestinum rectum 137

Intestinum tenue 134
Intestinum tenue mesenteriale 168
Intestinum tenue mesosteniale 168
Intima 26
Introitus 26
Introitus canalis nervi facialis 290
Intumescentia 26
Intumescentia cervicalis 218
Intumescentia lumbalis 218
Intumescentia tympanica 260
Iris 26
Iris 279
Ischiadicus 26
Ischium 26
Isthmus 26
Isthmus aortae 181
Isthmus cartilaginis auris 296
Isthmus columnae dorsalis (medullae spinalis) 219
Isthmus faucium 130
Isthmus gl. thyreoideae 172
Isthmus gyri cinguli 239
Isthmus gyri fornicati 239
Isthmus prostatae 158
Isthmus rhombencephali 229
Isthmus tubae auditivae 295
Isthmus tubae pharyngotympanicae 295
Isthmus tubae uterinae 161
Isthmus uteri 162

Jejunum 26, 136
Juga alveolaria (mandibulae) 77
Juga alveolaria (maxillae) 75
Juga cerebralia 65
Jugulum 26
Jugum 26
Jugum sphenoidale 65
Junctura 26
Junctura cartilaginea 81
Juncturae cinguli membri inf. 86
Juncturae cinguli membri sup. 82
Juncturae columnae vertebralis thoracis et cranii 92
Junctura fibrosa 81
Junctura lumbosacralis 93
Juncturae membri inferioris liberi 87
Juncturae membri superioris liberi 83
Juncturae ossiculorum tympani 294
Junctura ossium 81
Juncturae ossium cinguli extremitatum pelvinarum 86
Juncturae ossium cinguli extremitatum thoracicarum 82
Juncturae ossium extremitatis pelvinae 87
Juncturae ossium extremitatis pelvinae liberae 87
Juncturae ossium extremitatis thoracicae 82
Juncturae ossium extremitatis thoracicae liberae 83
Junctura sacrococcygea 93
Junctura synovialis 81
Juncturae tendinum 99
Juncturae zygapophiseales 92

Labium 26
Labium ant. (portionis vaginalis uteri) 162
Labium ant. (tubae auditivae) 131
Labium articulare 82
Labium articulare (art. coxae) 87
Labium articulare (art. humeri) 83
Labium externum 49
Labium inf. (oris) 126
Labium inf. (valvulae coli) 136
Labium internum 49
Labium lat. (lineae asperae) 52
Labium limbi tympanicum 288
Labium limbi vestibulare 288
Labium majus pudendi 164
Labium med. (lineae asperae) 52
Labium minus pudendi 164
Labia oris 126
Labium post. (portionis vaginalis uteri) 162
Labium post. (tubae auditivae) 131
Labium sup. (oris) 126
Labium sup. (valvulae coli) 136
Labium tympanicum 288
Labium vestibulare 288
Labium vocale 148
Labrum 26
Labrum acetabulare (art. coxae) 87
Labrum glenoidale 82
Labrum glenoidale (art. coxae) 87
Labrum glenoidale (art. humeri) 83
Labyrinthus 26
Labyrinthus ethmoidalis 73
Labyrinthus membranaceus 285
Labyrinthus osseus 288
Lac 26
Lac femininum 301
Lacerus 26
Lacertus 26
Lacertus fibrosus 100
Lacertus m. recti lat. (oculi) 282

Lacrima 26
Lacrimae 285
Lacuna 26
Lacunae laterales 203
Lacunae laterales sinuum 203
Lacuna musculorum 109
Lacunae urethrales (fem.) 165
Lacunae urethrales (masc.) 160
Lacuna vasorum 109
Lacus lacrimalis 285
Lamina 26
Lamina affixa 241
Lamina alaris (nervorum) 217
Laminae albae (cerebelli) 228
Lamina ant. 117
Lamina arcus vertebrae 58
Lamina basalis (cerebelli) 229
Lamina basalis (chorioideae) 278
Lamina basalis (nervorum) 217
Lamina basalis (corporis ciliaris) 278
Lamina basilaris (cochleae) 287
Lamina capillarium 278
Lamina (cart. cricoideae) 145
Lamina (cartilaginis) lat. 295
Lamina (cartilaginis) med. 295
Lamina choriocapillaris 278
Lamina choriodea epithelialis 224
Lamina choriodea epithelialis (ventriculi lat.) 241
Lamina chorioidea epithelialis (thalamencephali) 234
Lamina circularis (corporis ciliaris) 278
Lamina cribriformis fossae ovalis 109
Lamina cribrosa 73
Lamina cribrosa sclerae 277
Lamina (dextra et sinistra) (cart. thyreoideae) 144
Lamina dorsi nasi (cartilago septodorsalis) 144
Lamina elastica ant. 278
Lamina elastica post. 278
Lamina episcleralis 277
Lamina epithelialis 217
Lamina ext. (ossium cranii) 78
Lamina fibrocartilaginea interpubica 86
Lamina fusca 277
Lamina int. (ossium cranii) 78
Lamina lat. processus pterygoidei 66
Lamina limitans ext. 278
Lamina limitans int. 278
Lamina maxillaris (ossis palatini) 75
Lamina med. processus pterygoidei 66
Lamina mediana (ossis ethmoidalis) 73
Laminae mediastinales (pleurae mediastinalis) 151
Laminae medullares (cerebelli) 228
Laminae medullares (nuclei lentiformis) 243
Laminae medullares (thalami) 235
Lamina membranacea (tubae auditivae) 295
Lamina mesenteri propria 168
Lamina modioli 289
Lamina muscularis mucosae 125
Lamina muscularis mucosae (intestini crassi) 137
Lamina muscularis mucosae (intestini recti) 137
Lamina muscularis mucosae (intestini tenuis) 135
Lamina muscularis mucosae (oesophagi) 133
Lamina muscularis mucosae (ventriculi) 134
Lamina orbitalis 73
Lamina palatina 76
Lamina papyracea 73
Lamina parietalis (tunicae vag. prop. testis) 157
Lamina perpendicularis 73
Lamina pharyngobasilaris 132
Lamina post. 117
Lamina pretrachealis 121
Lamina prevertebralis 121
Lamina profunda (fasciae temporalis) 124
Lamina profunda (m. levatoris palpebrae sup.) 282
Lamina propria mucosae 125
Lamina quadrigemina 229
Lamina rostralis (corporis callosi) 240
Lamina septi (cartilago septodorsalis) 143
Lamina septi pellucidi 240
Lamina spiralis ossea 290
Lamina spiralis secundaria 290
Lamina superficialis 121
Lamina superficialis (fasciae temporalis) 124
Lamina superficialis (m. levatoris palpebrae sup.) 282
Lamina suprachorioidea 278
Lamina tecti 229
Lamina tectoria ventriculi quarti 224
Lamina tectoria ventriculi tertii (thalamencephali) 234
Lamina terminalis (cerebri) 233
Lamina tragi 296
Lamina vasculosa (chorioideae) 278
Lamina vastoadductoria 109
Lamina viscelaris (epicardium) 177

Lamina visceralis (tunicae vaginalis propriae testis) 157
Lanugo 27
Lanugo 299
Laryngeus 27
Larynx 38
Lateralis 17
Latissimus 27
Latus 27, 39
Lectulus unguis 300
Lemniscus 27
Lemniscus 225
Lemniscus lat. (acusticus) 225
Lemniscus med. (medullae oblongatae) 223
Lemniscus med. (sensitivus) 225
Lemniscus spinalis 225
Lemniscus trigeminalis 225
Lens 27
Lens crystallina 281
Leptomeninx 251
Levator 27
Liber 27
Lien 27
Lien 141
Lien accessorius 142
Ligamenta 82
Ligamentum 27
Ligg. accessoria plantaria 92
Ligg. accessoria volaria 85
Lig. acromioclaviculare 83
Ligg. alaria 94
Lig. anococcygeum 166
Lig. annulare baseos stapedis 293
Ligg. annularia digitorum manus 104
Ligg. annularia (digitorum pedis) 112
Lig. annulare radii 83
Ligg. annularia (trachealia) 149
Lig. apicis dentis (epistrophei) 94
Lig. arcuatum carpi dorsale 84
Lig. arcuatum laterale 116
Lig. arcuatum mediale 116
Lig. arcuatum medianum 116
Lig. arcuatum pubis 86
Lig. arteriosum 181
Ligg. articuli cricothyreoidei 146
Ligg. auricularia 297
Lig. auriculare ant. 297
Lig. auriculare post. 297
Lig. auriculare sup. 297
Ligg. basium (ossium metacarp.) dorsalia 85
Ligg. basium (ossium metacarp.) interossea 85
Ligg. basium (ossium metacarp.) volaria 85
Ligg. basium (ossium metatars.) dorsalia 91
Ligg. basium (ossium metatars.) interossea 91
Ligg. basium (ossium metatars.) plantaria 92
Lig. bifurcatum 90
Lig. bipartitum 90
Lig. calcaneocuboideum 90
Lig. calcaneocuboideum dorsale 90
Lig. calcaneocuboideum plantare 90
Lig. calcaneocuboideum plantare obliquum 91
Lig. calcaneocuboideum plantare transversum 91
Lig. calcaneofibulare 88
Lig. calcaneonaviculare 90
Lig. calcaneonaviculare dorsale 90
Lig. calcaneonaviculare plantare 90
Lig. calcaneotibiale 88
Lig. capitis femoris 87
Lig. capitis fibulae ant. 88
Lig. capitis fibulae post. 88
Lig. capituli costae interarticulare 94
Lig. capituli costae radiatum 94
Ligg. capituli fibulae 88
Lig. capituli mallei superius 293
Ligg. capitulorum (ossium metacarp.) transversa 85
Ligg. capitulorum (ossium metatars.) transversa 92
Lig. carpi dorsale 103
Lig. carpi radiatum 84
Lig. carpi transversum 104
Lig. carpi volare 103
Lig. carpi volare radiatum 84
Ligg. carpometacarpea dorsalia 85
Ligg. carpometacarpea palmaria 85
Ligg. carpometacarpea volaria 85
Lig. caudale 298
Ligg. ceratocricoidea lateralia 146
Ligg. ceratocricoidea posteriora 146
Lig. ceratocricoideum anteriora 146
Ligg. cinguli extremitatis inf. 86
Ligg. cinguli extremitatis sup. 82
Ligg. collateralia (art. digitorum manus) 86
Ligg. collateralia (art. digitorum pedis) 92
Ligg. collateralia (art. metacarpophalang.) 85
Ligg. collateralia (art. metatarsophalang.) 92
Lig. collaterale carpi radiale 84
Lig. collaterale carpi ulnare 84
Lig. collaterale fibulare 87
Lig. collaterale radiale (art. cubiti) 83
Lig. collaterale tibiale 87
Lig. collaterale ulnare (art. cubiti) 83

Lig. colli costae 94
Lig. conoideum 83
Lig. coracoacromiale 82
Lig. coracoclaviculare 83
Lig. coracohumerale 83
Lig. corniculopharyngeum 147
Lig. coronarium hepatis 170
Lig. costoclaviculare 82
Ligg. costoensiformia 95
Lig. costotransversarium 94
Lig. costotransversarium ant. 94
Lig. costotransversarium ext. 94
Lig. costotransversarium int. 94
Lig. costotransversarium lat. 94
Lig. costotransversarium post. 94
Lig. costotransversarium sup. 94
Ligg. costoxiphoidea 95
Lig. cricoarytaenoideum post. 147
Lig. cricopharyngeum 147
Lig. cricothyreoideum (medium) 147
Lig. cricotracheale 147
Lig. cruciatum ant. 87
Lig. cruciatum atlantis 94
Lig. cruciatum cruris 111
Ligg. cruciata digitorum manus 104
Ligg. cruciata (digitorum pedis) 112
Ligg. cruciata genu 87
Lig. cruciatum post. 87
Lig. cuboideonaviculare dorsale 90
Lig. cuboideonaviculare plantare 90
Lig. cubonaviculare obliquum 90
Lig. cuneocuboideum dorsale 90
Lig. cuneocuboideum interosseum 89
Lig. cuneocuboideum plantare 91
Ligg. cuneometatarsea interossea 91
Ligg. cuneonavicularia dorsalia 91
Ligg. cuneonavicularia plantaria 91
Lig. decussatum ant. 87
Ligg. decussata genus 87
Lig. decussatum post. 87
Lig. deltoideum 88
Lig. denticulatum 251
Lig. duodenorenale 170
Lig. epididymidis inf. 157
Lig. epididymidis sup. 157
Ligg. extracapsularia 82
Lig. falciforme hepatis 170
Lig. fibulocalcaneare 88
Lig. fibulotalare ant. 88
Lig. fibulotalare post. 88
Ligg. flava 92
Lig. fundiforme 111
Lig. fundiforme penis 117
Lig. gastrocolicum 169
Lig. gastrolienale 169
Lig. gastrophrenicum 169
Lig. genitoinguinale 157
Ligg. glenohumeralia 83
Lig. hepatocolicum 169
Lig. hepatoduodenale 169
Lig. hepatogastricum 169
Lig. hepatorenale 170
Lig. hyoepiglotticum 147
Lig. hyothyreoideum lat. 146
Lig. hyothyreoideum medium 146
Lig. iliofemorale 86
Lig. iliolumbale 86
Lig. incudis posterius 293
Lig. incudis superius 293
Lig. inguinale 117
Lig. inguinale reflexum 117
Ligg. interarcualia 92
Ligg. intercarpea dorsalia 84
Ligg. intercarpea interossea 84
Ligg. intercarpea palmaria 84
Ligg. intercarpea volaria 84
Lig. interclaviculare 83
Ligg. intercostalia 95
Ligg. intercostalia externa 95
Ligg. intercostalia interna 95
Ligg. intercuneiformia dorsalia 90
Ligg. intercuneiformia interossea 89
Ligg. intercuneiformia plantaria 90
Lig. interfoveolare 117
Ligg. interspinalia 92
Ligg. intertransversaria 92
Ligg. intracapsularia 82
Lig. ischiocapsulare 87
Lig. ischiofemorale 87
Ligg. labiohumeralia 83
Lig. laciniatum 111
Lig. lacunare 117
Lig. laterale (art. temporomandibularis) 95
Lig. latum uteri 171
Lig. longitudinale ant. 93
Lig. longitudinale commune dorsale 93
Lig. longitudinale commune ventrale 93
Lig. longitudinale post. 93
Lig. lumbocostale 95
Lig. mallei anterius 293
Lig. mallei laterale 293
Lig. mallei superius 293

Lig. malleoli lat. ant. 88
Lig. malleoli lat. post. 88
Lig. mediale (deltoideum) 88
Lig. menisci fibularis 87
Lig. meniscofemorale ant. 87
Lig. meniscofemorale post. 87
Ligg. metacarpea dorsalia 85
Ligg. metacarpea interossea 85
Ligg. metacarpea palmaria 85
Lig. metacarpeum transversum profondum 85
Lig. metacarpeum transversum superficiale 104
Ligg. metatarsea dorsalia 91
Ligg. metatarsea interossea 91
Ligg. metatarsea plantaria 92
Lig. metatarseum transversum profundum 92
Lig. metatarseum transversum superficiale 112
Ligg. navicularicuneiformia dorsalia 90
Ligg. navicularicuneiformia plantaria 90
Lig. nuchae 93
Ligg. ossiculorum auditus 293
Ligg. ossiculorum tympani 293
Lig. ovarii proprium 161
Ligg. palmaria 86
Lig. palmare transversum subcutaneum 104
Lig. palpebrale med. 283
Lig. palpebrale temporale 283
Lig. patellae 87
Lig. pectinatum iridis 279
Lig. pectineale 117
Lig. phrenicocolicum 170
Lig. phrenicolienale 170
Lig. pisohamatum 84
Lig. pisometacarpeum 84
Ligg. plantaria 92
Lig. plantare longum 90
Lig. popliteum arcuatum 87
Lig. popliteum obliquum 87
Lig. praeurethrale 167
Lig. processus longi mallei 293
Lig. pterygospinosum 96
Lig. pubicum superius 86
Lig. pubocapsulare 87
Lig. pubofemorale 87
Lig. puboprostaticum (pubovesicale) laterale 167
Lig. puboprostaticum (pubovesicale) mediale 167
Ligg. pubovesicalia 167
Lig. pulmonale 151
Lig. pylori 134
Lig. quadratum (art. cubiti) 83
Lig. radiocarpeum dorsale 84
Lig. radiocarpeum palmare 84
Lig. radiocarpeum volare 84
Lig. reflexum 117
Lig. sacrococcygeum ant. 93
Lig. sacrococcygeum lat. 93
Lig. sacrococcygeum post. profundum 93
Lig. sacrococcygeum post. superficiale 93
Ligg. sacroiliaca anteriora 86
Ligg. sacroiliaca dorsalia 86
Ligg. sacroiliaca interossea 86
Lig. sacroiliacum post. breve 86
Lig. sacroiliacum post. longum 86
Lig. sacrospinosum 86
Lig. sacrotuberosum 86
Lig. serosum 125
Lig. sphenomandibulare 95
Lig. spirale cochleae 287
Lig. sternoclaviculare 82
Lig. sternocostale interarticulare 95
Ligg. sternocostalia radiata 95
Ligg. sternopericardiaca 176
Lig. stylohyoideum 96
Lig. stylomandibulare 95
Lig. supraspinale 92
Ligg. suspensiora mammae 301
Lig. suspensorum clitoridis 165
Lig. suspensorium ovarii 171
Lig. suspensorium penis 159
Lig. suspensorium penis s. clitoridis 117
Lig. talocalcaneum ant. 88
Lig. talocalcaneum interosseum 89
Lig. talocalcaneum lat. 89
Lig. talocalcaneum med. 89
Lig. talocalcaneum post. 89
Lig. talofibulare ant. 88
Lig. talofibulare post. 88
Lig. talonaviculare (dorsale) 89
Lig. talotibiale ant. 88
Lig. talotibiale post. 88
Ligg. tarsi dorsalia 89
Ligg. tarsi interossea 89
Ligg. tarsi plantaria 90
Ligg. tarsi profunda 90
Ligg. tarsometatarsea dorsalia 91
Ligg. tarsometatarsea interossea 91
Ligg. tarsometatarsea plantaria 91
Ligg. temporomandibulare 95
Lig. teres femoris 87
Lig. teres hepatis 139
Lig. teres hepatis (v. portae) 207
Lig. teres uteri 163

Lig. thyreoepiglotticum 147
Lig. thyrohyoideum 146
Lig. thyrohyoideum medianum 146
Lig. tibiofibulare ant. 88
Lig. tibiofibulare post. 88
Lig. tibionaviculare 88
Lig. transversum acetabuli 87
Lig. transversum atlantis 94
Lig. transversum cruris 110
Lig. transversum genu 87
Lig. transversum pelvis 167
Lig. transversum scapulae inf. 82
Lig. transversum scapulae sup. 82
Lig. trapezoideum 83
Lig. triangulare dextrum 170
Lig. triangulare sinistrum 170
Lig. tuberculi costae 94
Lig. ulnocarpeum palmare 84
Lig. ulnocarpicum volare 84
Lig. umbilicale lat. 194
Lig. umbilicale mediale 194
Lig. umbilicale medium 154
Lig. vaginale 99
Ligg. vaginalia digitorum manus 104
Ligg. vaginalia (digitorum pedis) 112
Lig. venosum 139
Lig. venosum (v. portae) 207
Lig. ventriculare 147
Lig. vestibulare 147
Lig. vocale 147
Limbus 27
Limbus alveolaris (mandibulae) 77
Limbus alveolaris (maxillae) 75
Limbus corneae 278
Limbus fossae ovalis (septi atriorum) 178
Limbus laminae spiralis osseae 288
Limbus membranae tympani 292
Limbi palpebrales anteriores 283
Limbi paplpebrales conjunctivales 283
Limbi palpebrales cutanei 283
Limbi palpebrales posteriores 283
Limbus sphenoideus 65
Limen 27
Limen insulae 242
Limen nasi 142
Limitaneus 27
Linea 27
Linea alba 116
Linea arcuata 50
Linea arcuata 117
Linea aspera 52
Linea axillaris 303
Linea glutaea ant. 50
Linea glutaea cranialis 50
Linea glutaea inf. 50
Linea glutaea post. 50
Linea glutaea supraacetabularis 50
Linea intercondyloidea 52
Linea intermedia 49
Linea intertrochanterica 52
Linea mamillaris 303
Linea mediana ant. 303
Linea mediana post. 303
Linea musculares 44
Linea m. solei 53
Linea mylohyoidea 77
Linea nuchae inf. 64
Linea nuchae sup. 64
Linea nuchae suprema 64
Linea nuchalis supraterminalis 64
Linea nuchalis terminalis 64
Linea obliqua (mandibulae) 77
Linea obliqua (cart. thyreoideae) 145
Linea parasternalis 303
Linea pectinea 52
Linea plani nuchalis 64
Linea poplitea 53
Linea scapularis 303
Linea semicircularis 117
Linea semilunaris 39
Linea sternalis 303
Linea temporalis 67
Linea temporalis 72
Linea temporalis 67
Linea temporalis fascialis 71
Linea temporalis inf. 71
Linea temporalis sup. 71
Linea terminalis (pelvis) 51
Lineae transversae (ossis sacri) 61
Linea trapezoidea 45
Linea visus 277
Lingua 27
Lingua 129
Lingula 27
Lingula cerebelli 227
Lingula mandibulae 78
Lingula pulmonis sinistri 150
Lingula sphenoidalis 65
Liquor 27
Liquor cerebrospinalis 251
Liquor folliculi 161
Liquor pericardii 176

Lobulus 27, 125
Lobulus auriculae 296
Lobulus biventer 228
Lobulus centralis 228
Lobuli corticales (renis) 153
Lobuli epididymidis 156
Lobuli gl. thyreoideae 172
Lobuli hepatis 140
Lobuli mammae 301
Lobulus paracentralis 240
Lobulus parietalis inf. 239
Lobulus parietalis sup. 239
Lobuli pulmonum 150
Lobulus quadrangularis 228
Lobulus semilunaris inf. 228
Lobulus semilunaris sup. 228
Lobulus simplex 228
Lobuli testis 155
Lobuli thymi 173
Lobus 27, 125
Lobus ant. (hypophyseos) 173
Lobus caudatus 139
Lobi cerebri 236
Lobus (dexter et sinister) (prostatae) 158
Lobus (dexter et sinister) (thymi) 173
Lobus (dexter et sinister) (thyreoideae) 172
Lobus dorsocaudalis (pulmonis) 150
Lobus frontalis (cerebri) 237
Lobus glandularis (hypophyseos) 173
Lobus hepatis dexter 138
Lobus hepatis sinister 138
Lobus inf. (pulmonis) 150
Lobi mammae 300
Lobus medius (prostatae) 158
Lobus medius (pulmonis) 150
Lobus nervosus (hypophyseos) 173
Lobus occipitalis (cerebri) 238
Lobus olfactorius 241
Lobus parietalis (cerebri) 238
Lobus post. (hypophyseos) 173
Lobus pyramidalis 172
Lobus quadratus 139
Lobi renales 153
Lobus sup. (pulmonis) 150
Lobus temporalis (cerebri) 237
Lobus ventrocranialis (pulmonis) 150
Locus 27
Locus caeruleus 224
Longissimus 27
Longitudinalis 17
Longus 27
Lucidus 27
Lumbricus 27
Lumbus 27
Lumbus 39
Lunatus 27
Lunula 27
Lunula (ungius) 299
Lunulae valvularum semilunarium 179
Lunulae velorum semilunarium 179
Luteus 27
Lympha 27
Lympha 176
Lymphaticus 27
Lymphocentrum 212
Lymphoglandula 175
Lgll. auriculares anteriores 212
Lgll. auriculares posteriores 212
Lgll. axillares 213
Lgll. bronchiales 213
Lgll. cervicales profundae inferiores 212
Lgll. cervicales profundae superiores 212
Lgll. cervicales superficiales 212
Lgll. coeliacae 214
Lgll. cubitales profundae 213
Lgll. cubitales superficiales 213
Lgll. epigastricae 213
Lgll. faciales profundae 212
Lgll. gastricae inferiores 214
Lgll. gastricae superiores 214
Lgll. hepaticae 215
Lgll. hypogastricae 215
Lgll. iliacae 214
Lgll. inguinales 215
Lgll. intercostales 214
Lgll. linguales 213
Lgll. lumbales 214
Lgll. mediastinales anteriores 214
Lgll. mediastinales posteriores 214
Lgll. mesentericae 215
Lgll. mesocolicae 215
Lgll. occipitales 212
Lgll. pancreaticolienales 215
Lgll. parotideae 212
Lgll. pectorales 213
Lgll. popliteae 216
Lgll. pulmonales 214
Lgll. sacrales 215
Lgll. sternales 214
Lgll. subinguinales profundae 216
Lgll. subinguinales superficiales 216
Lgll. submaxillares 212

Lgll. subscapulares 213
Lgl. tibialis ant. 216
Lgll. tracheales 213
Lymphonodulus 211
Lymphonoduli aggregati (intestini coli) 137
Lymphonoduli aggregati processus vermiformis 136
Lymphonoduli bronchales 214
Lymphonoduli gastrici 134
Lymphonodu'i (intestini recti) 137
Lymphonoduli laryngici 149
Lymphonoduli lienales 142
Lymphonoduli solitarii (intestini crassi) 137
Lymphonoduli solitarii (intestini tenuis) 135
Lymphonoduli tubales 295
Lymphonoduli vaginales 163
Lymphonoduli vesicae 155
Lymphonodus vide: Lymphoglandula 211
Lymphonodi anorectales 215
Lymphonodi bronchales 213
Lymphonodi bronchopulmonales 213
Lymphonodi ilici interni 215
Lymphonodi mesosteniales 215
Lymphonodi praelaryngici 214
Lymphonodi pulmonales 214
Lymphonodi retroauriculares 212
Lymphonodi retropharyngici 213
Lymphonodi submentales 212
Lymphonodi tracheobronchales caudales 213
Lymphonodi tracheobronchales craniales 214

Macula 27
Maculae 287
Maculae acusticae 287
Maculae cribrosae 288
Macula cribrosa inf. 289
Macula cribrosa media 289
Macula cribrosa sup. 288
Macula flava 148
Macula lutea 280
Macula sacculi 287
Maculae staticae 287
Macula utriculi 287
Magnus 27
Major 27
Mala 27
Malleolus 27
Malleolus lat. 41
Malleolus med. 41
Malleus 27
Malleus 293
Mamilla 27
Mamma 27
Mamma 300
Mammae accessoriae (muliebres et viriles) 301
Mamma masculina 301
Mamma virilis 301
Mandibula 27
Mandibula 77
Manubrium 27
Manubrium mallei 293
Manubrium sterni 62
Manus 27
Manus 39
Margo 27
Margo acutus (lienis) 141
Margo aditus (ossis frontalis) 72
Margo aditus (maxillae) 74
Margo aditus (ossium cranii) 80
Margo alveolaris (mandibulae) 77
Margo alveolaris (maxillae) 75
Margo ant. (fibulae) 54
Margo ant. (hepatis) 139
Margo ant. (lienis) 141
Margo ant. (pancreatis) 138
Margo ant. (pulmonis) 150
Margo ant. (testis) 155
Margo ant. (tibiae) 53
Margo axillaris (scapulae) 44
Margo ciliaris (iridis) 279
Margo cranialis 44
Margo dexter (cordis) 176
Margo diaphragmaticus (pulmonis) 150
Margo dorsalis (radii) 46
Margo dorsalis (ulnae) 47
Margo falciformis (fasciae latae) 109
Margo frontalis (ossis parietalis) 72
Margo frontalis (ossis sphenoidalis) 65
Margo incisalis 129
Margo inf. (hepatis) 139
Margo inf. (inferolateralis) 236
Margo inf. (lienis) 141
Margo inf. (pancreatis) 138
Margo inf. (pulmonis) 150
Margo infraglenoidalis 53
Margo infraorbitalis (maxillae) 74
Margo interosseus (fibulae) 54
Margo interosseus (radii) 46
Margo interosseus (tibiae) 53
Margo lacrimalis (maxillae) 74
Margo lambdoideus 64

Margines laterales (digiti pedis) 58
Margo lat. (fibularis) (pedis) 41
Margo lat. (humeri) 45
Margo lat. (linguae) 129
Margo lat. (renis) 152
Margo lat. (scapulae) 44
Margo lat. (unguis) 300
Margo lat. (uteri) 162
Margo liber (ovarii) 161
Margo liber (testis) 155
Margo liber (unguis) 300
Margo mastoideus 64
Margines mediales (digiti pedis) 58
Margo med. (gl. suprarenalis) 173
Margo med. (humeri) 45
Margo med. (inferomedialis) 236
Margo med. (renis) 152
Margo med. (scapulae) 44
Margo med. (tibiae) 53
Margo mesorchicus (testis) 155
Margo mesovaricus 161
Margo nasalis (ossis frontalis) 73
Margo nasi 143
Margo obtusus (lienis) 141
Margo occipitalis (ossis parietalis) 71
Margo occipitalis (ossis temporalis) 71
Margo occultus 300
Margo orbitalis 72
Margo orbitalis (maxillae) 74
Margines palpebrales 283
Margo parietalis 66
Margo parietalis (ossis frontalis) 72
Margo parietalis (temporalis) 67
Margo pedis lat. 41
Margo pedis med. 41
Margo post. (fibulae) 54
Margo post. (lienis) 141
Margo post. (pancreatis) 138
Margo post. (partis petrosae) 68
Margo post. (testis) 155
Margo pupillaris (iridis) 279
Margo radialis (antibrachii) 39
Margines radiales (digiti manus) 49
Margo sagittalis (ossis parietalis) 72
Margo sphenoidalis 67
Margo sphenoides 72
Margo sphenoideus (ossis frontalis) 72
Margo squamosus (ossis parietalis) 71
Margo squamosus (ossis sphenoidalis) 66
Margo sternalis (pulmonis) 150
Margo sup. (gl. suprarenalis) 173
Margo sup. (lienis) 141
Margo sup. (pancreatis) 138
Margo sup. (partis petrosae) 68
Margo sup. (scapulae) 44
Margo sup. (superomedialis) 236
Margo supraorbitalis 72
Margo ulnaris (antibrachii) 39
Margines ulnares (digiti manus) 49
Margo uteri (dexter et sinister) 162
Margo vertebralis (scapulae) 44
Margo volaris (radii) 46
Margo volaris (ulnae) 47
Margo zygomaticus (ossis sphenoidalis) 66
Massa 28
Massa intermedia 232
Massa lat. (atlantis) 60
Masticatus 28
Mastoideus 28
Mater 28
Matrix 28
Matrix unguis 299
Maxilla 74
Maximus 28
Meatus 28
Meatus acusticus ext. 70
Meatus acusticus ext. cartilagineus 296
Meatus acusticus int. 68
Meatus nasi 142
Meatus nasi communis 143
Meatus nasi inf. 143
Meatus nasi medius 142
Meatus nasi sup. 142
Meatus nasopharyngeus 143
Medialis 17
Medianum 28
Medianus 17
Mediastinum 28
Mediastinum 152
Mediastinum ant. 152
Mediastinum medium 152
Mediastinum post. 152
Mediastinum sup. 152
Mediastinum testis 156
Medius 17
Medulla 28
Medulla 173
Medulla (nodi lymph.) 211
Medulla oblongata 221
Medulla ossium 43
Medulla ossium flava 43
Medulla ossium gelatinosa 43

Medulla ossium rubra 43
Medulla renis 153
Medulla spinalis 218
Melania 28
Membra 39
Membrana 28
Membrana atlantoepistrophica dorsalis 93
Membrana atlantoepistrophica ventralis 93
Membrana atlantooccipitalis ant. 93
Membrana atlantooccipitalis post. 93
Membrana basalis ductus semicircularis 285
Membranae deciduae 166
Membrana elastica laryngis 149
Membrana fibroelastica laryngis 149
Membrana fibrosa 82
Membrana hyaloidea 281
Membrana hyothyreoidea 146
Membrana intercostalis ext. 95
Membrana intercostalis int. 95
Membrana interossea antibrachii 83
Membrana interossea cruris 88
Membrana mucosa nasi 143
Membrana obturatoria 86
Membrana obturatoria (stapedis) 293
Membrana propria ductus semicircularis 285
Membrana pupillaris 279
Membrana quadrangularis 149
Membrana reticularis (ductus cochlearis) 287
Membrana stapedis 293
Membrana statoconorium 287
Membrana sterni 95
Membrana suprapleuralis 152
Membrana synovialis 82
Membrana tectoria (art. atlantoepistrophicae) 94
Membrana tectoria (ductus cochlearis) 287
Membrana thyrohyoidea 146
Membrana tympani 292
Membrana tympani secundaria 291
Membrana vestibularis 287
Membrum 28
Membrum inferius 40
Membrum superius 39
Meninges 250
Meninx 28
Meniscus 28
Meniscus articularis 82
Meniscus lat. (art. genu) 87
Meniscus med. (art. genu) 87
Menisci tactus 298
Mentum 28
Mentum 38
Meridiani 277
Mesencephalon 229
Mesenteria 168
Mesenteriolum processus vermiformis 169
Mesenterium 168
Mesenterium commune 172
Mesoappendix 169
Mesocolon 168
Mesocolon ascendens 168
Mesocolon descendens 169
Mesocolon sigmoideum 169
Mesocolon transversum 168
Mesogastrium 172
Mesogastrium dorsale 169
Mesohepaticum lat. dextrum 170
Mesohepaticum lat. sinistrum 170
Mesohepaticum ventrale 170
Mesometrium 171
Mesonephros 165
Mesopneumonium 151
Mesorchium 172
Mesorectum 169
Mesosalpinx 171
Mesosigmoideum 169
Mesostenium 168
Mesotendineum 99
Mesothelium 28
Mesovarium 171
Metacarpus 28
Metacarpus 39
Metaphysis 28
Metatarsus 28
Metatarsus 41
Metathalamus 234
Metencephalon 225
Minimus 28
Minor 28
Mitra 28
Modiolus 28
Modiolus 289
Mola 28
Molecularis 28
Mollis 28
Mons 28
Mons pubis 164
Monticulus 28
Monticulus 228
Motor 28
Mucosus 28
Mucus 28, 125

Multifidus 28
Musculus 28, 99
Mm. abdominis 116
M. abductor digiti minimi (manus) 104
M. abductor digiti minimi (pedis) 111
M. abductor digiti quinti (manus) 104
M. abductor digiti quinti (pedis) 111
M. abductor hallucis 111
M. abductor pollicis brevis 103
M. abductor pollicis longus 103
M. adductor brevis 108
M. adductor hallucis 111
M. adductor longus 108
M. adductor magnus 108
M. adductor minimus 108
M. adductor pollicis 103
M. anconaeus 101
M. antitragicus 297
Mm. arrectores pilorum 299
M. articularis 99
M. articularis cubiti 101
M. articularis genu 108
M. aryepiglotticus 148
M. arytaenoideus 148
M. arytaenoideus obliquus 148
M. arytaenoideus transversus 148
M. auricularis ant. 122
M. auricularis nuchalis 122
M. auricularis post. 122
M. auricularis sup. 122
M. auricularis temporalis 122
M. biceps brachii 100
M. biceps femoris 108
M. bipennatus 99
M. biventer 99
M. biventer mandibulae 120
M. brachialis 101
M. brachioradialis 102
M. bronchooesophageus 133
M. buccinator 123
M. buccopharyngeus 132
Mm. bulbi 282
M. bulbocavernosus 168
M. bulbospongiosus 168
M. caninus 123
Mm. capitis 121
M. cephalopharyngicus 132
M. ceratocricoideus 148
M. ceratopharyngeus 133
M. chondroglossus 130
M. chondropharyngeus 132
M. ciliaris 278
M. coccygeus 120
Mm. colli 120
M. constrictor pharyngis inf. 133
M. constrictor pharyngis medius 132
M. constrictor pharyngis sup. 132
M. coracobrachialis 101
M. corrugator glabellae 122
M. corrugator supercilii 122
M. cremaster 116
M. cricoarytaenoideus lat. 147
M. cricoarytaenoideus post. 147
M. cricopharyngeus 133
M. cricothyreoideus 147
M. cutaneus 99
M. deltoideus 100
M. depressor anguli oris 123
M. depressor capitis supercilii 122
M. depressor glabellae 122
M. depressor labii inf. 123
M. depressor septi 122
M. depressor supercilii 122
M. digastricus 120
M. dilatator pupillae 279
Mm. dorsi 118
M. epicranius 122
M. epicranius temporoparietalis 122
M. epitrochleoanconaeus 101
M. erector spinae 118
M. extensor carpi radialis brevis 102
M. extensor carpi radialis longus 102
M. extensor carpi ulnaris 103
M. extensor digiti minimi 103
M. extensor digiti quinti proprius 103
M. extensor digitorum brevis 111
M. extensor digitorum communis 103
M. extensor digitorum longus 110
M. extensor hallucis brevis 111
M. extensor hallucis longus 111
M. extensor indicis proprius 103
M. extensor pollicis brevis 103
M. extensor pollicis longus 103
Mm. extremitatis inf. 106
Mm. extremitatis pelvinae 106
Mm. extremitatis sup. 100
Mm. extremitatis thoracicae 100
M. fibularis brevis 110
M. fibularis longus 110
M. fibularis tertius 110
M. fixator baseos stapedis 293
M. flexor carpi radialis 102

M. flexor carpi ulnaris 102
M. flexor digitorum brevis 112
M. flexor digitorum longus 110
M. flexor digiti minimi brevis (manus) 104
M. flexor digiti minimi brevis (pedis) 111
M. flexor digitorum profundus 102
M. flexor digiti quinti brevis (manus) 104
M. flexor digiti quinti brevis (pedis) 111
M. flexor digitorum sublimis 102
M. flexor digitorum superficialis 102
M. flexor hallucis brevis 111
M. flexor hallucis longus 110
M. flexor pollicis brevis 103
M. flexor pollicis longus 102
M. frontalis 122
M. fusiformis 99
M. gastrocnemius 110
M. gemellus inf. 107
M. gemellus sup. 107
M. genioglossus 130
M. geniohyoideus 121
M. glossopalatinus 131
M. glossopharyngeus 132
M. glutaeus maximus 107
M. glutaeus medius 107
M. glutaeus minimus 107
M. gracilis 108
M. helicis major 297
M. helicis minor 297
M. hyoglossus 130
M. hypopharyngicus 132
M. iliacus 107
M. iliocostalis 118
M. iliocostalis cervicis 118
M. iliocostalis dorsi 118
M. iliocostalis lumborum 118
M. iliocostalis thoracis 118
M. iliopsoas 106
Mm. incisivi labii inf. 122
Mm. incisivi labii sup. 122
M. incisurae helicis Santorini 297
Mm. infrahyoidei 121
M. infraspinatus 100
Mm. intercostales externae 115
Mm. intercostales internae 115
Mm. intercostales intimi 115
Mm. intercostales lumbales 119
Mm. intercostotransversarii cervicales 119
Mm. intercostotransversarii ventrales 119
M. interfoveolaris 117
Mm. interossei dorsales (manus) 104
Mm. interossei dorsales (pedis) 112
Mm. interossei palmares 104
Mm. interossei plantares 112
Mm. interossei volares 104
Mm. interspinales 119
Mm. intertransversarii 119
Mm. intertransversarii anteriores 119
Mm. intertransversarii laterales 119
Mm. intertransversarii mediales 119
Mm. intertransversarii posteriores 119
Mm. intertransversarii thoracis 119
M. intervaginalis testis 157
M. ischiocavernosus 168
Mm. laryngis 147
M. laryngopharyngicus 133
M. latissimus dorsi 118
M. levator anguli oris 123
M. levator ani 166
M. levator glandulae thyreoideae 121, 172
M. levator labii sup. 123
M. levator labii sup. aleque nasi 123
M. levator nasi et labii maxillaris lat. 123
M. levator nasi et labii maxillaris med. 123
M. levator palpebrae sup. 282
M. levator scapulae 118
M. levator veli palatini 131
Mm. levatores costarum 115
Mm. levatores costarum breves 115
Mm. levatores costarum longi 115
Mm. linguae 130
M. longissimus 118
M. longissimus capitis 118
M. longissimus cervicis 118
M. longissimus dorsi 118
M. longissimus thoracis 118
M. longitudinalis inf. 130
M. longitudinalis profundus 130
M. longitudinalis superficialis 130
M. longitudinalis sup. 130
M. longus capitis 121
M. longus colli 121
Mm. lumbricales (manus) 104
Mm. lumbricales (pedis) 112
M. masseter 123
Mm. membri inf. 106
Mm. membri sup. 100
M. mentalis 123
M. multifidus 119
M. mylohyoideus 121
M. mylopharyngeus 132
M. nasalis 122

M. obliquus atlantis 120
M. obliquus auriculae 297
M. obliquus bulbi inf. 282
M. obliquus bulbi sup. 282
M. obliquus capitis inf. 120
M. obliquus capitis sup. 120
M. obliquus ext. abdominis 116
M. obliquus inf. (oculi) 282
M. obliquus int. abdominis 116
M. obliquus sup. (oculi) 282
M. obturator ext. 107
M. obturator int. 107
M. occipitalis 122
M. occipitofrontalis 122
Mm. oculi, fasciae orbitales 282
M. omohyoideus 121
M. opponens digiti minimi 104
M. opponens digiti quinti (manus) 104
M. opponens digiti quinti (pedis) 111
M. opponens pollicis 103
M. orbicularis 99
M. orbicularis oculi 122
M. orbicularis oris 122
M. orbitalis 282
Mm. ossiculorum auditus 294
Mm. ossiculorum tympani 294
Mm. ossis hyoidei 120
Mm. palati et faucium 131
M. palatoglossus 131
M. palatopharyngeus 131
M. palmaris brevis 104
M. palmaris longus 102
Mm. papillares 177
M. papillaris ant. (valvulae bicuspidalis) 180
M. papillaris dexter (valvulae bicuspidalis) 180
Mm. papillares parvi 179
M. papillaris post. 179
M. papillaris post. (valvulae bicuspidalis) 180
Mm. papillares septales 179
M. papillaris sinister (valvulae bicuspidalis) 180
M. papillaris ventralis 179
M. pectinati 178, 180
M. pectineus 108
M. pectoralis major 115
M. pectoralis minor 115
Mm. perinei 166
M. peronaeus brevis 110
M. peronaeus longus 110
M. peronaeus tertius 110
M. pharyngopalatinus 131
M. pharyngotubalis 132
M. piriformis 107
M. plantaris 110
M. pleurooesophageus 133
M. popliteus 110
M. procerus 122
M. pronator quadratus 102
M. pronator teres 102
M. prostaticus 158
M. psoas major 107
M. psoas minor 107
M. pterygoideus ext. 123
M. ptreygoideus int. 123
M. pterygoideus lat. 123
M. pterygoideus med. 123
M. pterygopharyngeus 132
M. puboprostaticus 158
M. pubovesicalis 154
M. pyramidalis 116
M. pyramidalis auriculae Jungi 297
M. quadratus femoris 107
M. quadratus labii inf. 123
M. quadratus labii sup. 123
M. quadratus lumborum 116
M. quadratus plantae 112
M. quadriceps femoris 108
M. rectococcygeus 137
M. rectourethralis 137
M. rectouterinus 163
M. rectovesicalis 137
M. rectovesicalis 154
M. rectus abdominis 116
M. rectus bulbi inf. 282
M. rectus bulbi nasalis 282
M. rectus bulbi sup. 282
M. rectus bulbi temporalis 282
M. rectus capitis ant. 121
M. rectus capitis lat. 120
M. rectus capitis post. major 120
M. rectus capitis post. minor 120
M. rectus femoris 108
M. rectus inf. (oculi) 282
M. rectus lat. (oculi) 282
M. rectus med. (oculi) 282
M. rectus sup. (oculi) 282
M. rhomboideus major 118
M. rhomboideus minor 118
M. risorius 123
Mm. rotatores 119
Mm. rotatores breves 119
Mm. rotatores longi 119
M. sacrococcygeus ant. 120

M. sacrococcygeus post. 120
M. sacrospinalis 118
M. salpingopharyngeus 132
M. sartorius 108
M. scalenus ant. 121
M. scalenus medius 121
M. scalenus min. 121
M. scalenus post. 121
M. semimembranosus 108
M. semispinalis 119
M. semispinalis capitis 119
M. semispinalis cervicis 119
M. semispinalis dorsi 119
M. semispinalis thoracis 119
M. semitendinosus 108
M. serratus ant. 115
M. serratus post. inf. 118
M. serratus post. sup. 118
M. skeleti 99
M. soleus 110
M. sphincter 99
M. sphincter ampullae hepatopancreaticae 141
M. sphincter ani ext. 166
M. sphincter ani int. 137
M. sphincter ductus choledochi 141
M. sphincter pupillae 279
M. sphincter pylori 134
M. sphincter urethrae diaphragmaticae 167
M. sphincter urethrae membranaceae 167
M. sphincter vesicae 154
M. spinalis 119
M. spinalis capitis 119
M. spinalis cervicis 119
M. spinalis dorsi 119
M. spinalis thoracis 119
M. splenius 118
M. splenius capitis 118
M. splenius cervicis 118
M. stapedius 294
M. sternalis 115
M. sternocleidomastoideus 120
M. sternohyoideus 121
M. sternothyreoideus 121
M. styloglossus 130
M. stylohyoideus 121
M. stylopharyngeus 132
M. subclavius 115
Mm. subcostales 115
M. subscapularis 100
M. supinator 103
Mm. suprahyoidei 120
M. supraspinatus 100
M. suspensorius duodeni 135
M. tarsalis inf. 284
M. tarsalis sup. 284
M. temporalis 123
M. temporoparietalis 122
M. tensor faciale latae 107
M. tensor tympani 294
M. tensor veli palatini 131
M. teres major 100
M. teres minor 100
Mm. thoracis 115
M. thyreoarytaenoideus 148
M. thyreoarytaenoideus (ext.) 148
M. thyreoepiglotticus 148
M. thyreohyoideus 121
M. thyreopharyngeus 133
M. tibialis ant. 109
M. tibialis post. 110
M. trachealis 149
M. tragicus 297
Mm. transversocostales breves et longi 115
M. transversooccipitalis 119
M. transversospinalis 119
M. transversus abdominis 116
M. transversus auriculae 297
M. transversus linguae 130
M. transversus menti 123
M. transversus nuchae 118
M. transversus perinei profundus 167
M. transversus perinei superficialis 168
M. transversus thoracis 115
M. trapezius 118
M. triangularis 123
M. triceps brachii 101
M. triceps surae 110
M. unipennatus 99
M. uvulae 131
M. vastus intermedius 108
M. vastus lat. 108
M. vastus med. 108
M. ventricularis 148
M. verticalis linguae 130
M. viscerum 125
M. vocalis 148
M. zygomaticus 123
M. zygomaticus major 123
M. zygomaticus minor 123
Myelencephalon 221
Myocardium 177

Myologia 99
Myometrium 163

Nares 142
Naris 28
Nasus 28
Nasus 142
Nasus externus 143
Nates 28
Nates (Clunes) 39
Natus 28
Navicula 28
Nephritis 28
Nervus 28, 217
N. abducens 258
N. accessorius 262
N. acusticus 259
N. alveolaris inf. 257
Nn. alveolares superiores 254
N. ampullae post. 260
N. ampullaris inf. 260
N. ampullaris lat. 260
N. ampullaris post. 260
N. ampullaris sup. 260
Nn. anales 271
Nn. anococcygei 271
N. articularis 217
Nn. auriculares anteriores 257
N. auricularis magnus 263
N. auricularis post. 259
N. auriculotemporalis 256
N. axillaris 266
N. buccinatorius 256
N. canalis pterygoidei 255
Nn. capitales 252
N. cardiacus inf. 273
N. cardiacus medius 273
N. cardiacus sup. 273
Nn. cardiaci thoracici 273
N. caroticotympanicus inf. 260
N. caroticotympanicus sup. 260
N. carotici externi 272
N. caroticus int. 272
N. cavernosus clitoridis major 276
Nn. cavernosi clitoridis minores 276
N. cavernosus penis major 275
Nn. cavernosi penis minores 275
Nn. cerebrales 252
Nn. cervicales 263
N. cervicalis descendens 263
Nn. ciliares breves 254
Nn. ciliares longi 253
Nn. clunium inferiores 269
Nn. clunium medii 267
Nn. clunium superiores 267
N. coccygeus 271
N. cochleae 260
Nn. craniales 252
N. cutaneus 217
N. cutaneus antibrachii dorsalis 265
N. cutaneus antibrachii lat. 264
N. cutaneus antibrachii med. 264
N. cutaneus brachii lat. 266
N. cutaneus brachii lat. inf. 265
N. cutaneus brachii lat. sup. 266
N. cutaneus brachii med. 264
N. cutaneus brachii post. 265
N. cutaneus colli 263
N. cutaneus dorsalis intermedius 269
N. cutaneus dorsalis lat. 270
N. cutaneous dorsalis med. 269
N. cutaneus femoris lat. 268
N. cutaneus femoris post. 269
N. cutaneus surae lat. 269
N. cutaneus surae med. 270
N. depressor 261
Nn. digitales dorsales (n. radialis) 266
Nn. digitales dorsales (n. ulnaris) 265
Nn. digitales dorsales, hallucis lat. et digiti secundi med. 270
Nn. digitales dorsales pedis 269
Nn. digitales palmares communes 265
Nn. digitales palmares proprii 265
Nn. digitales plantares communes 270
Nn. digitales plantares proprii 270
Nn. digitales volares communes (n. mediani) 265
Nn. digitales volares communes (n. ulnaris) 265
Nn. digitales volares proprii (n. mediani) 265
Nn. digitales volares proprii (n. ulnaris) 265
N. dorsalis clitoridis 271
N. dorsalis penis 271
N. dorsalis scapulae 264
N. ethmoidalis ant. 253
N. ethmoidalis post. 253
N. facialis 258
N. femoralis 268
N. fibularis communis 269
N. fibularis profundus 269
N. fibularis superficialis 269
N. frontalis 253
N. genitofemoralis 268

N. glossopharyngeus 260
N. glutaeus inf. 269
N. glutaeus sup. 269
Nn. haemorrhoidales inferiores 271
Nn. haemorrhoidales medii 271
Nn. haemorrhoidales superiores 275
N. hypogastricus (dexter et sinister) 275
N. hypoglossus 262
N. infraorbitalis 254
N. infratrochlearis 254
N. iliohypogastricus 268
N. ilioinguinalis 268
Nn. intercostobrachiales 267
N. intermedius 259
N. interosseus (antibrachii) dorsalis 266
N. interosseus (antibrachii) volaris 264
N. interosseus cruris 270
N. ischiadicus 269
N. jugularis 272
Nn. labiales anteriores 268
Nn. labiales posteriores 271
N. lacrimalis 253
N. laryngeus inf. 261
N. laryngeus recurrens 261
N. laryngeus sup. 261
N. lingualis 257
Nn. lumbales 267
N. lumboinguinalis 268
N. mandibularis 256
N. massetericus 256
N. masticatorius 256
N. maxillaris 254
N. meatus acustici ext. 256
N. meatus auditorii ext. 256
N. medianus 264
N. meningeus (medius) 254
N. mentalis 257
N. m. coccygici 271
N. m. levatoris ani 271
N. musculocutaneus 264
N. mylohyoideus 257
N. nasociliaris 253
N. nasopalatinus 256
N. obturatorius 268
N. occipitalis major 263
N. occipitalis minor 263
N. occipitalis tertius 263
N. oculomotorius 252
Nn. olfactorii 252
N. ophthalmicus 253
N. opticus 252
Nn. palatini 256
N. palatinus ant. 256
N. palatinus major 256
N. palatinus medius 256
N. palatinus minor 256
N. palatinus post. 256
N. pectoralis med. 264
N. pectoralis lat. 264
Nn. perinei 271
N. peronaeus communis 269
N. peronaeus profundus 269
N. peronaeus superficialis 269
N. petrosus minor 260
N. petrosus profundus 255
N. petrosus superficialis major 255
N. petrosus superficialis minor 258
N. phrenicus 263
Nn. phrenici accessorii 263
N. plantaris lat. 270
N. plantaris med. 270
N. pterygoideus ext. 256
N. pterygoideus int. 256
N. pterygoideus lat. 256
N. pterygoideus med. 256
N. pterygopalatini 254
N. pudendus 271
N. radialis 265
Nn. rectales caudales 271
Nn. rectales craniales 275
Nn. rectales inferiores 271
N. recurrens 261
N. retroauricularis 259
N. saccularis 260
Nn. sacrales 267
Nn. sacrales et n. coccygeus 267
N. saphenus 268
Nn. scrotales anteriores 268
Nn. scrotales posteriores 271
N. spermaticus ext. 268
Nn. sphenopalatini 254
Nn. spinales 262
N. spinosus 256
N. splanchnicus imus 273
Nn. splanchnici lumbales 274
N. splanchnicus major 273
N. splanchnicus minor 273
Nn. splanchnici pelvini (nn. erigentes) 275
Nn. splanchnici sacrales 275
N. stapedius 259
N. statoacusticus 259
N. subclavius 264

N. subcostalis 267
N. sublingualis 257
N. suboccipitalis 263
Nn. subscapulares 264
N. subscapularis 266
Nn. supraclaviculares 263
Nn. supraclaviculares anteriores 263
Nn. supraclavicularis intermedii 263
Nn. supraclaviculares mediales 263
Nn. supraclaviculares medii 263
Nn. supraclaviculares posteriores 263
N. supraorbitalis 253
N. suprascapularis 264
N. supratrochlearis 253
N. suralis 270
Nn. temporales profundi 256
N. temporalis profundus ant. 256
N. temporalis profundus post. 256
N. tensoris tympani 258
N. tensoris veli palatini 258
N. tentorii 253
N. terminalis 271
Nn. thoracici 266
Nn. thoracales anteriores 264
N. thoracalis longus 264
Nn. thoracales posteriores 264
N. thoracodorsalis 264
N. thoracodorsalis 266
N. tibialis 270
N. transversus colli 263
N. trigeminus 253
N. trochlearis 253
N. tympanicus 260
N. ulnaris 265
N. utricularis 260
N. utriculoampullaris 260
Nn. vaginales 275
N. vagus 261
N. vascularis 217
N. vertebralis 273
Nn. vesicales inferiores (plexus pudendi) 271
Nn. vesicales inferiores (syst. sympathici) 275
Nn. vesicales superiores 275
N. vestibuli 260
N. vestibulocochlearis 259
N. zygomaticofacialis 254
N. zygomaticotemporalis 254
N. zygomaticus 254·
Neuras 28
Neuroepithelium 286
Neurologia 217
Nidus avis 228
Niger 29
Nodulus 29, 228
Noduli aggregati processus vermiformis 136
Nodulus lymphaticus 212
Noduli lymphatici aggregati (Peyeri) 135
Noduli lymphatici bronchiales 214
Noduli lymphatici conjunctivales 284
Noduli lymphatici gastrici 134
Noduli lymphatici (intestini recti) 137
Noduli lymphatici laryngei 149
Noduli lymphatici lienales 142
Noduli lymphatici solitarii (intestini crassi) 137
Noduli lymphatici solitarii (intestini tenuis) 135
Noduli lymphatici tubarii 295
Noduli lymphatici vaginales 163
Noduli lymphatici vesicales 155
Noduli thymici accessorii 173
Noduli valvularum semilunarium 179
Noduli velorum semilunarium 179
Nodus 29
Nodus (fasciculi atrioventricularis) 177
Nodus lymphaticus 175
Nodi lymphatici bronchopulmonales 213
Nodi lymphatici buccales 212
Nodi lymphatici colici 215
Nodi lymphatici gastroepiploici dextri 215
Nodi lymphatici gastroepiploici sinistri 215
Nodi lymphatici ileocolici 215
Nodi lymphatici iliaci communes 215
Nodi lymphatici iliaci externi 215
Nodus lymphaticus juguloomohyoideus 212
Nodus lymphaticus jugulodigastricus 212
Nodi lymphatici (lyphonodi) vide: **Lymphoglandula** 211
Nodi lymphatici mandibulares 212
Nodi lymphatici parasternales 214
Nodi lymphatici phrenici 214
Nodi lymphatici pulmonales 214
Nodi lymphatici pylorici 215
Nodi lymphatici tracheobronchiales inferiores 213
Nodi lymphatici tracheobronchiales superiores 214
Nodus sinuatrialis 177
Nomen 29
Norma 29
Nucha 29, 38
Nucleous 29
Nucleus 29
Nucleus accessorius (mesencephalicus) n. trigemini 230

Nucleus alae cinereae 222
Nucleus ambiguus 222
Nucleus amygdalae 243
Nucleus ant. thalami 234
Nucleus anterodorsalis 234
Nucleus anteromedialis 234
Nucleus anteroventralis 234
Nuclei arcuati 223
Nucleus caudatus 241
Nuclei cochleares, ventralis et dorsalis 226
Nucleus colliculi inf. (corp. quadrig.) 231
Nucleus colliculi rostralis (corp. quadrig.) 231
Nucleus corporis geniculati lat. 235
Nucleus corporis geniculati med. 235
Nuclei corporis mamillaris 233
Nucleus cuneatus 222
Nucleus cuneatus accessorius 222
Nucleus dentatus (cerebelli) 229
Nucleus dorsalis 219
Nucleus dorsalis corporis trapezoidei 226
Nucleus dorsalis n. glossopharyngei 222
Nucleus dorsalis n. vagi 222
Nucleus dorsomedialis (hypothalami) 233
Nucleus emboliformis 229
Nucleus fastigii 229
Nucleus funiculi cuneati 222
Nucleus funiculi gracilis 222
Nucleus globosus 229
Nucleus gracilis 222
Nucleus habenulae 235
Nucleus hypothalamicus 233
Nucleus inf. (n. vestibuli) 226
Nucleus intercalatus 222
Nucleus interpeduncularis 230
Nuclei intralaminares 235
Nuclei laterales (medull. oblong.) 222
Nucleus lat. (n. vestibuli) 226
Nucleus lat. dorsalis 235
Nucleus lat. thalami 235
Nucleus lemnisci lat. 226
Nucleus lentiformis 243
Nucleus lentis 281
Nucleus med. centralis 235
Nucleus med. (n. vestibuli) 226
Nucleus med. thalami 235
Nuclei motorii n. trigemini 226
Nucleus n. abducentis 225
Nuclei n. acustici 226
Nuclei nervorum capitalium 217
Nuclei nervorum cerebralium 217
Nuclei nervorum cranialium 217
Nucleus n. facialis 225
Nucleus n. hypoglossi 222
Nucleus n. oculomotorii 230
Nucleus n. trochlearis 230
Nuclei n. vestibularis 226
Nuclei n. vestibulocochlearis 226
Nucleus niger 231
Nucleus olivaris accessorius dorsalis 223
Nucleus olivaris accessorius med. 223
Nucleus olivaris inf. 222
Nucleus olivaris metencephali 226
Nucleus olivaris sup. 226
Nuclei originis 217
Nucleus originis accessorius (parasymphaticus) n. oculomotorii 230
Nucleus originis dorsalis (parasymphaticus) n. vagi 221
Nucleus originis n. accessorii 222
Nucleus originis salivatorius medullae oblongatae 222
Nucleus originis salivatorius pontis 226
Nucleus paraventricularis (hypothalami) 233
Nucleus partis lat. fasciae dorsalis 222
Nucleus partis med. fasciae dors. 222
Nuclei pontis 227
Nucleus post. (hypothalami) 233
Nucleus post. (Pulvinar thalami) 235
Nucleus pulposus 92
Nucleus radicis descendentis n. trigemini 230
Nucleus reticularis thalami 235
Nucleus rostralis (thalami) 234
Nucleus ruber 231
Nucleus sensorius principalis n. trigemini 226
Nucleus subthalamicus 235
Nucleus sup. (n. vestibuli) 226
Nucleus supraopticus (hypothalami) 233
Nuclei tegmenti 231
Nuclei terminales 217
Nucleus terminalis alae cinereae 200
Nucleus terminalis dorsalis n. cochleae 226
Nucleus terminalis dorsalis n. vestibuli 226
Nuclei terminales filarum olfactoriarum 241
Nucleus terminalis lat. n. vestibuli 226
Nucleus terminalis med. (triangularis) n. vestibuli 226
Nucleus terminalis n. trigemini 225
Nucleus terminalis spinalis n. vestibuli 226
Nucleus terminalis tractus spinalis nervi trigemini 222
Nucleus terminalis ventralis n. cochleae 226
Nuclei thalami 234

Nucleus thoracicus 219
Nucleus tractus mesencephalici n. trigemini 230
Nucleus tractus solitarii 222
Nucleus tractus spinalis n. trigemini 222
Nuclei tuberales (hypothalami) 233
Nucleus ventralis anterolateralis 235
Nucleus ventralis corporis trapezoidei 226
Nucleus ventralis intermedius 235
Nucleus ventralis posterolateralis 235
Nucleus ventralis posteromedialis 235
Nucleus ventromedialis (hypothalami) 233
Nutricius 29

Obex 202
Obliquus 29
Obturator 29
Occiput 29
Occiput 78
Occultus 29
Octavus 29
Oculus 29
Oculus 277
Oesophagus 133
Olecranon 47
Olfactus 29
Oliva 29
Oliva 221
Omentum 29
Omentum lienale 169
Omentum majus 169
Omentum minus 169
Omphalos 29
Operculum 29
Operculum 237
Operculum frontale 237
Operculum parietale 237
Operculum temporale 237
Ophtalmicus 29
Ora 29
Ora serrata 280
Orbicularis 29
Orbiculus 29
Orbiculus ciliaris 278
Orbita 29
Orbita 80
Organon 29
Organon auditus 285
Organa genitalia 155
Organa genitalia feminina 160
Organa genitalia masculina 155
Organa genitalia muliebria 160
Organa genitalia virilia 155
Organon gustus 297
Organa lacrimalia 284
Organa oculi accessoria 282
Organon olfactus 297
Organon parenchymatosum 125
Organa sensuum 277
Organon spirale 288
Organon status et auditus 285
Organa urinalia 152
Organa uropoetica 152
Organon visus 277
Organon vomeronasale 142
Organum vestibulocochleare 285
Orificium 29
Orificium ext. canalis isthmi 162
Orificium ext. (uteri) 162
Orificium int. canalis isthmi 162
Orificium int. (uteri) 162
Orificium ureteris 155
Orificium urethrae ext. (muliebris) 165
Orificium urethrae ext. (virilis) 160
Orificium urethrae int. 155
Orificium vaginae 164
Origo 29
Origo mandibularis (m. orbicularis oris) 122
Origo maxillaris (m. orbicularis oris) 122
Origo nasalis (m. orbicularis oris) 122
Os 38
Ossa accessoria carpi 48
Ossa antebrachii 46
Os basilare 63
Os brachii 45
Os breve 43
Os capitatum 48
Ossa carpi 47
Ossa carpi distalia 47
Ossa carpi proximalia 47
Os centrale carpi 48
Ossa cinguli extremitatum pelvinarum 49
Ossa cinguli extremitatum thoracicarum 44
Os coccygis 61
Os costale 62
Os coxae 49
Ossa cranii 63
Ossa cruris 52
Os cuboideum 57
Os cuneiforme primum 57
Os cuneiforme secundum 57
Os cuneiforme tertium 57
Ossa digitorum manus 48

Ossa digitorum pedis 57
Os ethmoidale 73
Ossa extremitatis inf. 49
Ossa extremitatis pelvinae 49
Ossa extremitatis pelvinae liberae 51
Ossa extremitatis sup. 44
Ossa extremitatis thoracicae 44
Ossa extremitatis thoracicae liberae 45
Ossa faciei 74
Os femoris 51
Os frontale 72
Os hamatum 48
Os hyoideum 78
Os ilium 49
Os incisivum 75
Os interparietale 64
Os ischii 50
Os lacrimale 74
Os longum 43
Os lunatum 47
Ossa membri inf. 49
Os membri sup. 44
Os metacarpale III. 48
Ossa metacarpalia I.—V. 48
Ossa metacarpi 48
Ossa metatarsalia I.—V. 57
Ossa metatarsi 57
Os multangulum majus 47
Os multangulum minus 47
Os nasale 74
Os naviculare manus 47
Os naviculare pedis 56
Os occipitale 63
Os (oris) 29
Os (ossis) 29
Os palatinum 75
Os parietale 71
Os pisiforme 47
Os planum 43
Os pneumaticum 43
Os pubis 50
Os sacrum 60
Os scaphoideum 47
Ossa sesamoidea (manus) 48
Ossa sesamoidea (pedis) 57
Os sphenoidale 64
Ossa suprasternalia 62
Ossa suturarum 79
Ossa tarsi 54
Ossa tarsi accessoria 54
Ossa tarsi distalia 54
Ossa tarsi proximalia 54
Os temporale 66
Os trapezium 47
Os trapezoideum 47
Os trigonum 55
Os triquetrum 47
Os zygomaticum 76
Ossicula auditus 293
Ossicula tympani 293
Ossiculum 29
Osteologia 43
Ostium 29
Ostium abdominale tubae uterinae 161
Ostium aortae (cordis) 178
Ostium appendicis vermiformis 136
Ostium arteriosum (cordis) 178
Ostium arteriosum dextrum (cordis) 178
Ostium arteriosum sinistrum (cordis) 178
Ostia atrioventricularia 178
Ostium atrioventriculare dextrum 178
Ostium atrioventriculare sinistrum 178
Ostium cardiacum 133
Ostium iliocaecocolicum 136
Ostium pharyngeum tubae 131
Ostium pyloricum 134
Ostium trunci pulmonalis 178
Ostium tympanicum tubae auditivae 294
Ostium tympanicum tubae pharyngotympanicae 294
Ostium urethrae ext. 160
Ostium urethrae int. 155
Ostium uteri 162
Ostium uterinum tubae 161
Ostium vaginae 164
Ostium v. cavae inf. 178
Ostium v. cavae sup. 178
Ostia vv. pulmonalium 180
Ostium venosum (cordis) 178
Oticus 29
Otoconia 287
Ovarium 160
Ovarius 29
Ovulum 161
Ovum 29

Pachymeninx 250
Palatum 29
Palatum 126
Palatum durum 80
Palatum molle 126
Palatum osseum 80

Pallidus 29
Pallium 29
Pallium 236
Palma 29
Palma manus 40
Palmaris 18, 29
Palpebra 29
Palpebrae 283
Palpebra inf. 283
Palpebra sup. 283
Pampiniformis 29
Pancreas 138
Pancreas accessorium 138
Paniculus 30
Panniculus adiposus 298
Papilla 30
Papillae 298
Papillae circumvallatae 130
Papillae conicae 130
Papilla dentis 129
Papilla duodeni 135
Papilla duodeni major 135
Papilla duodeni minor 135
Papilla fasciculi optici 280
Papillae filiformes 130
Papillae foliatae 130
Papillae fungiformes 130
Papilla incisiva 127
Papillae lacrimales 285
Papillae lenticulares 130
Papillae linguales 130
Papilla mammae 300
Papilla n. optici 208
Papilla parotidea 127
Papilla pili 299
Papillae renales 153
Papilla salivaria buccalis 127
Papilla salivaria sublingualis 126
Papillae vallatae 130
Papyraceus 30
Paracolpium 171
Paracysticum 171
Paradidymis 156
Paraganglion 30
Parametrium 171
Paraproctium 171
Parasympathicus 30
Parenchyma 30, 125
Parenchyma testis 156
Paries 30
Paries ant. (vaginae) 163
Paries ant. (ventriculi) 133
Paries carotica (cavi tympani) 292
Paries dorsocaudalis (ventriculi) 133
Paries ext. ductus cochlearis 287
Paries inf. (ossium cranii) 80
Paries jugularis (cavi tympani) 291
Paries labyrinthica (cavi tympani) 291
Paries lat. (ossium cranii) 80
Paries mastoidea (cavi tympani) 291
Paries med. (ossium cranii) 80
Paries membranacea (cavi tympani) 292
Paries membranacea (tracheae) 149
Paries nasalis (ossium cranii) 80
Paries post. (vaginae) 163
Paries post. (ventriculi) 133
Paries sup. (ossium cranii) 80
Paries tegmentalis (cavi tympani) 291
Paries temporalis (ossium cranii) 80
Paries tympanicus (ductus cochlearis) 287
Paries ventrocranialis (ventriculi) 133
Paries vestibularis ductus cochlearis 287
Paroophoron 164
Parotis 30
Pars 30
Pars abdominalis et pelvina syst. symp. 274
Pars abdominalis (m. pectoralis majoris) 115
Pars abdominalis (oesophagi) 133
Pars abdominalis (ureteris) 154
Pars acetabularis (rami ossis ischii) 50
Pars acetabularis (rami ossis pubis) 50
Pars alaris (m. nasalis) 122
Pars alveolaris (mandibulae) 77
Pars ampullaris 137
Pars analis (recti) 137
Pars ant. (commissurae ant.) 244
Pars ant. (lobuli quandrangularis) 228
Pars ant. (rhinencephali) 241
Pars anularis vaginae fibrosae 104
Pars aponeurotica fasciae lumbodorsalis 118
Pars ascendens (duodeni) 135
Pars auditiva (labyrinthi membranacei) 287
Pars basilaris (fasciculi pedunculomamillaris) 233
Pars basilaris (ossis occipitalis) 63
Pars basilaris pontis 227
Pars bucipharyngica 132
Pars caeca (retinae) 280
Pars calcaneocuboidea 90
Pars calcaneonavicularis 90
Pars cardiaca (ventriculi) 133
Pars cartilaginea (septi nasi) 142
Pars cartilaginea tubae auditivae 295

Pars cartilaginea tubae pharyngotympanicae 295
Pars cavernosa (urethrae femininae) 165
Pars cavernosa (urethrae virilis) 160
Pars centralis (ventriculi lat.) 241
Pars cephalica et cervicalis systematis autonomici 271
Pars cephalica et cervicalis syst. sympathici 271
Pars ceratopharyngica 133
Pars cervicalis (medullae spinalis) 218
Pars cervicalis (oesophagi) 133
Pars chondropharyngica 132
Pars chordae ductus venosi 139
Pars chordae venae umbilicalis 139
Pars ciliaris retinae 280
Pars clavicularis (m. pectoralis majoris) 115
Pars cochlearis (n. octavi) 260
Pars conoides (lig. coracoclav.) 83
Pars convoluta (renis) 153
Pars corticostrialis (radiationis corporis striati) 243
Pars costalis (diaphragmatis) 116
Pars costovertebralis (pleurae) 151
Pars cranialis (mediastini) 152
Pars cricopharyngica 133
Pars cruciformis vaginae fibrosae 104
Pars cupularis (recessus epitympanici) 291
Pars cutanea (septi nasi) 142
Pars descendens (duodeni) 135
Pars diaphragmatica (cordis) 176
Pars diaphragmatica (pleurae) 151
Pars diaphragmatica (urethrae virilis) 160
Pars diencephalica ventriculi tertii 232
Pars distalis (hypophyseos) 173
Pars dorsalis (cordis) 176
Pars dorsalis (mediastini) 152
Pars dorsalis pontis 225
Pars encephalica (syst. parasymphatici) 276
Pars epididymica (ductus deferentis) 156
Pars facialis platysmatis 123
Pars fetalis 166
Pars flaccida (membranae tympani) 292
Pars fornicata pallii 239
Pars frontalis (capsulae int.) 243
Pars frontalis (coronae radiatae) 243
Pars frontalis (marginis aditus orbitae) 80
Pars frontalis (operculi) 237
Pars frontalis (radiationis corporis callosi) 242
Pars frontalis (tractum corticopontinorum) 231
Pars funicularis (ductus deferentis) 156
Pars gastrica (faciei visceralis lienis) 141
Pars gastrolienalis 169
Pars gastromesocolica 169
Pars geniculata (radiationis tractus optici) 244
Partes genitales externae (muliebres) 164
Partes genitales externae (viriles) 158
Partes genitales internae (muliebres) 160
Partes genitales internae (viriles) 155
Pars glossopharyngica 132
Pars grisea hypothalami 233
Pars hepatoduodenalis 169
Pars hepatogastrica 169
Pars horizontalis (inferior) (duodeni) 135
Pars horizontalis (ossis palatini) 76
Pars humeroradialis (art. cubiti) 83
Pars humeroulnaris (art. cubiti) 83
Pars hyoidea 69
Pars iliaca (lineae terminalis) 51
Pars impar ventriculi telencephali 232
Pars inf. (duodeni) 135
Pars inf. fossae rhomboideae 224
Pars inf. (gyri frontalis medii) 237
Pars infraclavicularis 264
Pars infundibularis 173
Pars inguinalis (ductus deferentis) 156
Pars intercartilaginea (rima glottidis) 148
Pars interlacunaris fasciae ilicae 117
Pars intermedia fossae rhomboideae 224
Pars intermedia (hypophyseos) 173
Pars intermembranacea (rima glottidis) 148
Pars interstitialis (tubae uterinae) 161
Pars intramuscularis (urethrae femininae) 165
Pars intramuscularis (urethrae masculinae) 159
Pars iridica retinae 280
Pars lacrimalis (m. orbicularis oculi) 122
Pars laryngea (pharyngis) 132
Pars lat. (arci pedis longitudinalis) 41
Pars lat. (cordis) 176
Pars lat. (fasciculi dorsalis) 248
Pars lat. (fasciculi dors. medullae oblongatae) 221
Pars lat. (fasciculi dors. medullae spinalis) 220
Pars lat. (m. thyreoarytaenoidei) 148
Pars lat. (ossis occipitalis) 63
Pars lat. (ossis sacri) 61
Partes laterales (prostatae) 158
Pars lat. ventriculi telencephali 241
Pars libera (columnae fornicis) 240
Pars libera (ductus deferentis) 156
Pars lumbalis (diaphragmatis) 115
Pars lumbalis (medullae spinalis) 218
Pars mamillaris hypothalami 232
Pars marginalis (sulci cinguli) 239

Pars mastoidea 71
Pars maxillaris (marginis aditus orbitae) 80
Pars med. (arci pedis longitudinalis) 41
Pars med. (fasciculi dorsalis) 248
Pars med. (fasciculi dors. medullae oblongatae) 221
Pars med. (fasciculi dors. medullae spinalis) 220
Pars mediastinalis (pleurae) 151
Pars membranacea (nasi) 142
Pars membranacea septi atriorum 177
Pars membranacea (urethrae virilis) 160
Pars membranacea (ventriculorum) 177
Pars mesencephalica (radiationis tractus optici) 244
Pars mesencephalica (syst. parasympathici) 276
Pars mobilis septi nasi 143
Pars muscularis septi atriorum 177
Pars muscularis (ventriculorum) 177
Pars mylopharyngica 132
Pars nasalis (ossis frontalis) 73
Pars nasalis (pharyngis) 131
Pars obliqua (m. arytaenoidei) 148
Pars obliqua (m. cricothyreoidei) 147
Pars occipitalis (capsulae int.) 243
Pars occipitalis (coronae radiatae) 243
Pars occipitalis (radiationis corporis callosi) 243
Pars occipitotemporalis (tractum corticopontinorum) 231
Pars olfactoria tunicae mucosae nasi 143
Pars opercularis (gyri frontalis inf.) 237
Pars optica hypothalami 232
Pars optica retinae 280
Pars oralis (pharyngis) 132
Pars orbitalis (gyri frontalis inf.) 237
Pars orbitalis (m. orbicularis oculi) 122
Pars orbitalis (ossis frontalis) 72
Pars ossea (septi nasi) 142
Pars ossea tubae auditivae 295
Pars ossea tubae pharyngotympanicae 295
Pars pallida nuclei lentiformis 243
Pars palpebralis (m. orbicularis oculi) 122
Pars pancreatica (faciei visceralis lienis) 141
Pars parasymphatica (syst. nerv. autonom.) 271
Pars parietalis (coronae radiatae) 243
Pars parietalis (m. epicranii temporoparietalis) 122
Pars parietalis (operculi) 237
Pars parietalis (radiationis corporis callosi) 242
Pars parietalis (ventriculi lat.) 241
Pars pelvina (ductus deferentis) 156
Pars pelvina (ureteris) 154
Pars pericardiaca (pleurae) 151
Pars perpendicularis (ossis palatini) 75
Pars petromastoidea 67
Pars petromastoidea (mastoidea + petrosa) 71
Pars petrosa (pyramis) 67
Pars pharyngea 173
Pars phrenicogastrica (mesogastrii dorsalis) 169
Pars phrenicogastrica (omenti minoris) 169
Pars post. (commissurae ant.) 244
Pars post. (hepatis) 139
Pars post. (lobuli quadrangularis) 228
Pars post. (rhinencephali) 242
Pars praeurethralis (prostatae) 158
Pars prima (radicis n. facialis) 225
Pars principalis (hypophyseos) 173
Pars propria (fasciae dors. medullae spinalis) 220
Pars prostatica (urethrae) 159
Pars pterygopharyngica 132
Pars pubica (lineae terminalis) 51
Pars pubica (rami ossis ischii) 50
Pars pylorica 134
Pars radiata (renis) 153
Pars radioulnaris (art. cubiti) 83
Pars recta (m. cricothyreoidei) 147
Pars renalis (faciei visceralis lienis) 141
Pars retrolentiformis capsulae int. 243
Pars rhombencephalica (syst. parasympathici) 276
Pars sacci lacrimalis 122
Pars sacralis (lineae terminalis) 51
Pars sacralis (syst. parasympathici) 276
Pars secunda (radicis n. facialis) 225
Pars sellaris (fossae cranii mediae) 79
Pars spongiosa (urethrae virilis) 160
Pars squamalis (temporalis) 66
Pars squamosa (temporalis) 66
Pars statica (labyrinthi membranacei) 287
Pars sternalis (diaphragmatis) 116
Pars sternocostalis (cordis) 176
Pars sternocostalis (m. pectoralis majoris) 115
Pars striosubthalamica (radiationis corporis striati) 244
Pars striothalamica (radiationis corporis striati) 243
Pars subfrontalis (sulci cinguli) 239
Pars sublentiformis capsulae int. 243
Pars sup. (duodeni) 135
Pars sup. fossae rhomboideae 224
Pars sup. (gyri frontalis med.) 237
Pars sup. (hepatis) 139
Pars supraclavicularis 264

Pars symphatica (syst. nerv. autonom.) 271
Pars symphysica (ramus ossis pubis) 51
Pars tecta (columnae fornicis) 240
Pars tecta duodeni 135
Pars tegmentalis (fasciculi pedunculomamillaris 233
Pars temporalis (coronae radiatae) 243
Partes temporales (fossae cranii mediae) 79
Pars temporalis (operculi) 237
Pars temporalis (radiationis corporis callosi) 243
Pars temporalis (ventriculi telencephali) 241
Pars tensa (membranae tympani) 292
Pars thalamica (radiationis tractus optici) 244
Pars thoracalis (medullae spinalis) 218
Pars thoracalis (oesophagi) 133
Pars thoracalis syst. sympathici 273
Pars thyreopharyngica 133
Pars tibiocalcanearis (lig. deltoidis) 88
Pars tibionavicularis (lig. deltoidis) 88
Pars tibiotalaris ant. (lig. deltoidis) 88
Pars tibiotalaris post. (lig. deltoidis) 88
Pars transversa (m. arytaenoidei) 148
Pars transversa (m. nasalis) 122
Pars transversa (v. portae) 207
Pars trapezoides (lig. coracoclav.) 83
Pars triangularis (gyri frontalis inf.) 237
Pars triangularis (m. epicranii temporoparietalis) 122
Pars tuberalis (hypophyseos) 173
Pars tympanica 70
Pars umbilicalis 305
Pars umbilicalis (v. portae) 207
Pars uterina (placentae) 166
Pars uterina (tubae uterinae) 161
Pars ventralis (mediastini) 152
Pars ventralis pontis 227
Pars vestibularis (n. octavi) 260
Pars vocalis (m. thyreoarytaenoidei) 148
Pars zygomatica (marginis aditus orbitae) 80
Parvus 30
Patella 54
Pecten 30
Pecten ossis pubis 50
Pectus 30
Pectus 38
Pedalis 30
Pediculus arcus vertebrae 58
Pedunculus 30
Pedunculus cerebellaris inf. 250
Pedunculus cerebellaris inf. (Corpus restiforme) 221
Pedunculus cerebellaris medius 250
Pedunculus cerebellaris medius (pontis) 225
Pedunculus cerebellaris sup. 250
Pedunculus cerebellaris sup. (Brachium conjunctivum) 229
Pedunculus cerebri 229
Pedunculus corporis mamillaris 233
Pedunculus corporis mamillaris 250
Pedunculus flocculi 228
Pedunculus thalami inf. 233
Pellis 30
Pellucidus 30
Pelvis 30
Pelvis 51
Pelvis major 51
Pelvis minor 51
Pelvis renalis 153
Penicilli 141
Penis 158
Perforatus 30
Pericardium 176
Perichondrium 30
Pericranium 78
Perilympha 287
Perimetrium 163
Perimysium 99
Perineon 30
Perineum 166
Periodontium 129
Perionyx 300
Periorbita 282
Periochium 157
Periorchium + *Epiorchium* 157
Periosteum 30
Periosteum 43
Periosteum alveolare 129
Peripheria 30
Peritendineum 99
Peritoneum 30
Peritonaeum 168
Peritonaeum parietale 168
Peritonaeum viscerale 168
Permanens 30
Peroneus 30
Perpendicularis 30
Pes 30
Pes 41
Pes anserinus 109
Pes hippocampi 241
Petiolus cartilaginis epiglottidis 146
Petiolus epiglottidis 146

Petra 30
Petrosus 30
Phalanges digitorum manus 48
Phalanges digitorum pedis 57
Phalanx 30
Phalanx distalis 48
Phalanx media 48
Phalanx prima 48
Phalanx proximalis 48
Phalanx secunda 48
Phalanx tertia 48
Phallus 30
Pharynx 30
Pharynx 131
Philtrum 30
Philtrum 126
Pia mater encephali 251
Pia mater spinalis 251
Pigmentum 30
Pili 299
Pilus 30
Pinea 30
Pinguecula 284
Pinna 30
Piriformis 30
Pisiformis 30
Pituita 30
Pius 30
Placenta 166
Placenta foetalis 166
Placenta materna 166
Placenta uterina 166
Planta pedis 41
Plantaris 30
Plantaris 18
Planum nuchale 63
Planum occipitale 63
Planum orbitale 74
Planum popliteum 52
Planum sphenoideum 64
Planum sternale 62
Planum temporale 79
Planus 31
Platysma 120
Pleura 31
Pleura 151
Pleura costalis 151
Pleura diaphragmatica 151
Pleura mediastinalis 151
Pleura parietalis 151
Pleura pericardiaca 151
Pleura pulmonalis 151
Plexus 31
Plexus analis (venosus) 209
Plexus a. cerebri ant. (syst. sympathici) 272
Plexus a. cerebri media (syst. sympathici) 272
Plexus aorticus abdominalis (syst. sympathici) 274
Plexus aorticus (lymphaticus) 216
Plexus aorticus thoracalis (syst. sympathici) 273
Plexus arteriae chorioideae (syst. sympathici) 272
Plexus arteriae ovaricae (syst. sympathici) 274
Plexus auricularis post. (syst. sympathici) 272
Plexus autonomici 271
Plexus axillaris (lymphaticus) 216
Plexus basilaris 203
Plexus brachialis 263
Plexus cardiacus (syst. sympathici) 273
Plexus caroticus communis (syst. symp.) 272
Plexus caroticus ext. (syst. sympathici) 272
Plexus caroticus int. (syst. sympathici) 272
Plexus cavernosus clitoridis (syst. sympathici) 276
Plexus cavernosi concharum 142
Plexus cavernosus (partis cephalicae et cervicalis syst. sympathici) 272
Plexus cavernosus penis (syst. symphatici) 275
Plexus cervicalis 263
Plexus chorioideus partis lat. ventriculi telencephali 252
Plexus chorioideus ventriculi lat. 252
Plexus chorioideus ventriculi quarti 252
Plexus chorioideus ventriculi tertii 252
Plexus coccygeus 271
Plexus coeliacus (lymphaticus) 216
Plexus coeliacus (syst. sympathici) 274
Plexus coronarius (cordis) ant. (syst. sympathici) 273
Plexus coronarius (cordis) post. (syst. sympathici) 273
Plexus deferentialis (syst. sympathici) 275
Plexus dentalis inf. 257
Plexus dentalis sup. 255
Plexus entericus (syst. autonomici) 274
Plexus femoralis (syst. sympathici) 276
Plexus gangliosus ciliaris 279
Plexus gastricus ant. (n. vagi) 262
Plexus gastricus inf. (syst. sympathici) 274
Plexus gastricus post. 262
Plexus gastricus sup. (syst. sympathici) 274
Plexus glandulae vesiculosae (syst. sympathici) 275

Plexus haemorrhoidalis medius (syst. sympathici) 275
Plexus haemorrhoidalis sup. (syst. sympathici) 275
Plexus haemorrhoidalis (venosus) 209
Plexus hepaticus (syst. sympathici) 274
Plexus hypogastricus (lymphaticus) 216
Plexus hypogastricus (syst. sympathici) 275
Plexus iliacus ext. (lymphaticus) 216
Plexus iliacus (syst. sympathici) 275
Plexus inguinalis (lymphaticus) 216
Plexus intermesentericus (syst. autonomici) 275
Plexus ischiadicus 268
Plexus jugularis (lymphaticus) 216
Plexus lienalis (syst. sympathici) 274
Plexus lingualis (syst. sympathici) 272
Plexus lumbalis 268
Plexus lumbalis (lymphaticus) 216
Plexus lumbosacralis 268
Plexus lymphatici 216
Plexus lymphaticus 175
Plexus mammarius int. (syst. sympathici) 273
Plexus mammarius (lymphaticus) 216
Plexus maxillaris ext. (syst. sympathici) 272
Plexus maxillaris int. (syst. sympathici) 272
Plexus meningeus (syst. sympathici) 272
Plexus mesentericus inf. (syst. sympathici) 275
Plexus mesentericus sup. (syst. sympathici) 274
Plexus myentericus (syst. sympathici) 274
Plexus nervorum spinalium 218
Plexus occipitalis (syst. sympathici) 272
Plexus oesophageus ant. (n. vagi) 262
Plexus oesophageus post. (n. vagi) 262
Plexus ophthalmicus (syst. sympathici) 272
Plexus ovaricus (syst. sympathici) 274
Plexus pampiniformis 207
Plexus pancreaticus 274
Plexus parotideus (n. facialis) 259
Plexus periarterialis (syst. autonomici) 218
Plexus pharyngeus (venosus) 200
Plexus pharyngeus ascendens (syst. sympathici) 272
Plexus pharyngeus (n. vagi) 261
Plexus pharyngooesophagicus dorsalis 200
Plexus pharyngooesophagicus ventralis 200
Plexus phrenicus (syst. sympathici) 274
Plexus popliteus (syst. sympathici) 276
Plexus prostaticus (syst. sympathici) 275
Plexus pterygoideus 201
Plexus pudendalis 209
Plexus pudendus 271
Plexus pulmonalis ant. 261
Plexus pulmonalis post. 261
Plexus pulmonalis (syst. sympathici) 273
Plexus rectalis 209
Plexus rectalis caudalis (syst. sympathici) 275
Plexus rectalis cranialis (syst. sympathici) 275
Plexus rectales inferiores 275
Plexus renalis (syst. sympathici) 274
Plexus sacralis 268
Plexus sacralis ant. 209
Plexus sacralis medius (lymphaticus) 216
Plexus spermaticus (syst. sympathici) 274
Plexus subclavius (syst. sympathici) 273
Plexus submucosus (syst. sympathici) 274
Plexus subserosus (syst. autonomici) 274
Plexus suprarenalis (syst. sympathici) 274
Plexus sympathici 271
Plexus temporalis superficialis (syst. sympathici) 272
Plexus testicularis (syst. autonomici) 274
Plexus thyreoideus impar 199
Plexus thyreoideus inf. (syst. sympathici) 273
Plexus thyreoideus sup. (syst. sympathici) 272
Plexus tympanicus 260
Plexus uretericus (syst. autonomici) 274
Plexus uterovaginalis (syst. sympathici) 275
Plexus uterovaginalis (venosus) 209
Plexus vasculosus 175
Plexus venosus 175
Plexus venosus areolaris 202
Plexus venosus canalis hypoglossi 204
Plexus venosus caroticus int. 204
Plexus venosus foraminis ovalis 204
Plexus venosus mamillae 202
Plexus venosus prostaticus 209
Plexus venosus rectalis 209
Plexus venosus sacralis 209
Plexus venosus sclerae 205
Plexus venosus suboccipitalis 199
Plexus venosus uterinus 209
Plexus venosus vaginalis 209
Plexus venosi vertebrales anteriores 206
Plexus venosi vertebrales externi 206
Plexus venosi vertebrales interni 206
Plexus venosi vertebrales posteriores 206
Plexus venosus vesicalis 209
Plexus vertebralis (syst. sympathici) 273
Plexus vesicalis (syst. sympathici) 275
Plexus vesicalis (venosus) 209
Plexus vesicopudendalis 209
Plica 31

Plicae adiposae (pleurae) 151
Plicae alares 87
Plicae ampullares (tubae uterinae) 162
Plica a. hepaticae communis 170
Plicae articulares 82
Plica aryepiglottica 148
Plica axillaris ant. 39
Plica axillaris post. 39
Plica caecalis 171
Plica capitis epididymidis 157
Plica caudae epididymidis 157
Plica cecalis vascularis 170
Plica chordae tympani 294
Plica chordae uteroinguinalis (teretis) 171
Plicae ciliares 278
Plicae circulares 135
Plica ductus nasolacrimalis 285
Plica duodenalis inf. 170
Plica duodenalis sup. 170
Plica duodenojejunalis 170
Plica duodenomesocolica 170
Plica duodenomesocolica caudalis 170
Plica duodenomesocolica cranialis 170
Plicae epididymidis 171
Plica epigastrica 171
Plica fimbriata 130
Plica fossae navicularis 160
Plicae gastricae 134
Plica gastropancreatica 169
Plica glossoepiglottica 132
Plica glossoepiglottica mediana 132
Plica ileocaecalis 171
Plica iliocaecalis caudalis 171
Plica iliocaecalis cranialis 171
Plica incudis 294
Plica interureterica 155
Plicae iridis 279
Plicae isthmicae (tubae uterinae) 162
Plica lacrimalis 285
Plica lata uteri 171
Plica longitudinalis duodeni 135
Plica malleolaris ant. 292
Plica malleolaris post. 292
Plica mediastinopulmonalis 151
Plica mucosa 125
Plica mucosa (pharyngis) 132
Plica nervi laryngici 132
Plicae palatinae transversae 127
Plica palatotubalis 131
Plicae palmatae 162
Plica palpebro-nasalis 284
Plica paraduodenalis 170
Plica pharyngotubalis 131
Plica phrenicocolica 170
Plicae phrenicolienales 170
Plica pubovesicalis 171
Plica rectouterina 171
Plicae reticulares tunicae mucosae 141
Plica salpingopalatina 131
Plica salpingopharyngea 131
Plica semilunaris 131
Plicae semilunares coli 136
Plica semilunaris conjunctivae 284
Plica serosa 125
Plica spiralis 141
Plica stapedis 294
Plica sublingualis 126
Plica suspensoria ovarii 171
Plica synovialis 82
Plica synovialis infrapatellaris 87
Plica synovialis patellaris 87
Plicae transversales recti 138
Plica triangularis 131
Plicae tubariae (tubae uterinae) 162
Plicae tunicae mucosae vesicae felleae 141
Plica umbilicalis lat. 171
Plica umbilicalis lat. 154
Plica umbilicalis media 171
Plica ureterica 155
Plica v. cavae cranialis (sinistrae) (pericardii) 199
Plica ventricularis 148
Plica vesicalis transversa 171
Plica vestibularis 148
Plicae villosae 134
Plica vocalis 148
Pneumaticus 31
Pollex 31
Pollex 49
Polus 31
Polus ant. (bulbi oculi) 277
Polus ant. (lentis) 281
Polus frontalis (cerebri) 237
Polus occipitalis (cerebri) 238
Polus post. (bulbi oculi) 277
Polus post. (lentis) 281
Polus temporalis (cerebri) 237
Pons 31
Pons 225
Ponticulus 292
Poples 31
Poples 40

Porta 31
Porta arteriarum (pericardii) 177
Porta hepatis 139
Porta venarum (pericardii) 177
Portio 31
Portio densa (omenti minoris) 169
Portio ext. (partis prostaticae urethrae) 160
Portio flaccida (omenti minoris) 169
Portio intermedia (partis cavernosae urethrae) 160
Portio int. (partis prostaticae urethrae) 160
Portio major (n. trigemini) 253
Portio minor (n. trigemini) 253
Portio supravaginalis (cervicis) 162
Portio vaginalis (cervicis) 162
Porus 31
Porus acusticus ext. 295
Porus acusticus int. 290
Porus gustatorius 297
Porus sudoriferus 300
Posterior 17
Praecuneus 240
Praeputium 158
Praeputium clitoridis 165
Primus 31
Princeps 31
Prisma 31
Prismata adamantina 129
Processus 31
Processus accessorius 60
Processus alae parvae 65
Processus alaris 73
Processus alaris cruris lat. (cart. apicis nasi) 144
Processus alveolaris (maxillae) 75
Processus ant. (mallei) 293
Processus articularis (mandibulae) 78
Processus articulares inferiores (vertebrae) 59
Processus articulares superiores (ossis sacri) 60
Processus articulares superiores (vertebrae) 58
Processus brevis (mallei) 293
Processus caudatus (hepatis) 139
Processus ciliaris 278
Processus clinoideus ant. 65
Processus clinoideus medius 65
Processus clinoideus post. 65
Processus cochleariformis 291
Processus condyloideus 78
Processus coracoideus 44
Processus coronoideus (mandibulae) 78
Processus coronoideus (ulnae) 47
Processus costarius 60
Processus costotransversarius vertebrae cervicalis 59
Processus dorsi sellae 65
Processus ensiformis 62
Processus ethmoidalis 74
Processus falciformis (lig. sacrotuberosi) 86
Processus frontalis 75
Processus frontalis (ossis zygomatici) 76
Processus frontosphenoidalis 76
Processus intrajugularis (ossis occipitalis) 63
Processus intrajugularis (ossis temporalis) 69
Processus jugularis 63
Processus lacrimalis 74
Processus lat. (mallei) 293
Processus lat. tali 55
Processus lat. tuberis calcanei 56
Processus lenticularis (incudis) 293
Processus longus (mallei) 293
Processus mamillaris 60
Processus marginalis (ossis zygomatici) 76
Processus mastoideus 71
Processus maxillaris 74
Processus maxillaris (ossis zygomatici) 76
Processus med. tuberis calcanei 56
Processus muscularis 78
Processus muscularis (cart. arytaenoideae) 146
Processus orbitalis 76
Processus palatinus 75
Processus papillaris (hepatis) 139
Processus paramastoideus 64
Processus post. (sphenoidalis) 144
Processus post. tali 55
Processus proximalis tali 55
Processus pterygoideus 66
Processus pterygospinosus 66
Processus pyramidalis (ossis palatini) 76
Processus retroarticularis 67
Processus retromandibularis 127
Processus sellae medius 65
Processus sphenoidalis (ossis palatini) 76
Processus sphenoidalis septi cartilaginei 144
Processus spinosus 59
Processus styloides ossis metacarpi tertii 48
Processus styloideus (ossis metacarpalis III.) 48
Processus styloideus (ossis temporalis) 69
Processus styloideus (radii) 46
Processus styloideus (ulnae) 47
Processus supracondyloideus 46
Processus temporalis (ossis zygomatici) 76
Processus transversus (vertebrae) 59

Processus trochlearis 56
Processus uncinatus 138
Processus uncinatus (ossis ethmoidalis) 73
Processus vaginalis (ossis sphenoidalis) 66
Processus vaginalis peritonaei 172
Processus vermiformis 136
Processus vocalis (cart. arytaenoideae) 146
Processus zygomaticus (maxillae) 75
Processus zygomaticus (ossis frontalis) 72
Processus zygomaticus (ossis temporalis) 67
Processus xiphoideus 62
Profundus 17
Projectio 31
Prominens 31
Prominentia 31
Prominentia canalis facialis 292
Prominentia canalis semicircularis lat. 292
Prominentia laryngea 144
Prominentia malleolaris 292
Prominentia spiralis 287
Prominentia styloidea 291
Promontorium 31
Promontorium (ossis sacri) 61
Promontorium (ossis temporalis) 291
Pronator 31
Propior 31
Prosencephalon 232
Prostata 158
Protuberantia mentalis 77
Protuberantia occipitalis ext. 63
Protuberantia occipitalis int. 64
Proximalis 18
Pterygoma 31
Pubes 31
Pubes 299
Pudendum femininum 164
Pudendum muliebre 164
Pudendus 31
Pulmo 31
Pulmo 150
Pulpa 31
Pulpa coronale 129
Pulpa dentis 129
Pulpa lienis 141
Pulpa radicularis 129
Pulposus 31
Pulvinar 233
Punctum 31
Puncta lacrimalia 285
Pupilla 31
Pupilla 279
Pupillaris 31
Putamen 243
Pylorus 31
Pylorus 134
Pyramis 67
Pyramis 31
Pyramis (medullae oblongatae) 221
Pyramides renales 153
Pyramis (vermis) 228
Pyramis vestibuli 288

Quadrangulum 31
Quadratus 31
Quadriceps 31

Racemosus 31
Racemus 31
Radialis 18
Radiatio 31
Radiatio acustica 243
Radiatio corporis callosi 242
Radiatio corporis striati 243
Radiatio occipitothalamica 244
Radiatio optica 244
Radiatio tractus optici 232
Radix 31
Radix ant. (nn. spinalium) 262
Radix arcus vertebrae 58
Radix brevis ganglii ciliaris 252
Radix clinica 129
Radix cochlearis (n. acustici) 259
Radices craniales (n. accessorii) 262
Radix (Radices) dentis 129
Radix descendens (mesencephalica) n. trigemini 230
Radix inf. (cochlearis) 259
Radix inf. (plex. cerv.) 263
Radix lat. (n. mediani) 264
Radix lat. (tractus optici) 232
Radix linguae 129
Radix longa ganglii ciliaris 253
Radix med. (n. mediani) 264
Radix med. (tractus optici) 232
Radix mesenterii 168
Radix mesocoli transversi 168
Radix mesostenii 168
Radix motoria 253
Radix myelencephalica (n. accessorii) 262
Radix nasi 143
Radix n. facialis 225
Radix oculomotoria 252

Radices parietales (v. cavae inf.) 207
Radix penis 158
Radix pili 299
Radices plexus (brachialis) 263
Radix post. (nn. spinalium) 262
Radix pulmonis 150
Radix sensoria 253
Radix spinalis (n. accessorii) 262
Radix sup. (vestibularis) 259
Radix sup. (plex. cerv.) 263
Radices sympathicae ganglii ciliaris 272
Radix sympathica ganglii otici 258
Radix sympathica ganglii pterygopalatini 256
Radix sympathica ganglii submaxillaris 272
Radices sympathicae ganglii submaxillaris 258
Radix (systematis nervorum) 217
Radix unguis 299
Radix vestibularis (n. acustici) 259
Radices viscelares (v. cavae inf.) 207
Radius 46
Radii lentis 282
Radii stellarum lentis 282
Ramulus 31
Ramuli ciliares 185
Ramuli conjunctivales 185
Ramuli episclerales 185
Ramus 31
Rr. abdominales (aa. intercostalium) 191
Rr. abdominales (n. phrenici) 263
R. acetabularis (a. obturatoriae) 194
R. acetabuli (a. circumflexae femoris med.) 196
R. acromialis (a. thoracoacromialis) 188
R. acromialis (a. transversae scapulae) 187
Rr. ad pontem (a. basilaris) 186
Rr. alveolares maxillares posteriores (n. maxillaris) 254
Rr. alveolares superiores anteriores (n. infraorbitalis) 255
R. alveolaris sup. medius (n. infraorbitalis) 254
Rr. alveolares superiores posteriores (n. maxillaris) 254
R. ampullae lat. 260
R. ampullae sup. 260
R. anastomoticus 217
R. anastomoticus cum a. lacrimali (a. meningeae mediae) 184
R. anastomoticus cum chorda tympani (ggl. otici) 258
R. anastomoticus cum n. auriculotemporali (ggl. otici) 258
Rr. anastomotici cum n. faciali (n. auriculotemporalis) 257
R. anastomoticus cum n. glossopharyngeo (n. facialis) 259
R. anastomoticus cum n. glossopharyngeo (n. vagi) 261
R. anastomoticus cum n. hypoglosso (n. lingualis) 257
R. anastomoticus cum n. laryngeo inf. (n. vagi) 261
R. anastomoticus cum n. spinoso (ggl. otici) 258
R. anastomoticus cum n. ulnari (n. mediani) 265
R. anastomoticus cum n. zygomatico 253
R. anastomoticus cum plexu tympanico (n. facialis) 259
R. anastomoticus cum ramo auriculari n. vagi (n. glossopharyngei) 260
R. anastomoticus (nervorum) 217
R. anastomoticus peronaeus 269
R. anastomoticus ulnaris (r. superficialis n. radialis) 266
Rr. anteriores (aa. intercostalium) 190
R. ant. (a. obturatoriae) 194
R. ant. (a. thyreoideae sup.) 182
R. ant. ascendens (fissurae cerebri lat.) 236
R. ant. horizontalis (fissurae cerebri lat.) 236
R. ant. (n. auricularis magni) 263
Rr. anteriores (nn. cervicalium) 263
Rr. anteriores (nn. thoracalium) 266
R. ant. (n. laryngei inf.) 261
R. ant. (nn. lumbalium) 267
R. ant. (n. obturatori) 268
Rr. anteriores (nn. spinalium) 262
R. ant. (nn. thoracalium) 266
R. ant. (rr. anteriores aa. intercostalium) 190
R. ant. (v. portae) 207
Rr. arteriosi interlobulares 140
Rr. articulares (a. genu supremae) 196
R. ascendens (a. circumflexae femoris lat.) 196
R. ascendens (a. transversae colli) 187
R. ascendens (fissurae cerebri lat.) 236
Rr. auriculares anteriores (a. temporalis superficialis) 183
R. auricularis (a. auricularis post.) 183
R. auricularis (a. occipitalis) 182
R. auricularis (n. vagi) 261
R. biventricus (n. facialis) 259
Rr. bronchiales anteriores (n. vagi) 261
Rr. bronchiales (aortae thoracicae) 190

Rr. bronchiales (a. mammariae int.) 186
Rr. bronchiales (bronchorum) 149
R. bronchialis eparterialis 149
Rr. bronchiales hyparteriales 149
Rr. bronchiales posteriores (n. vagi) 261
Rr. buccales (n. facialis) 259
Rr. calcanei laterales (a. peroneae) 198
Rr. calcanei laterales (n. suralis) 270
Rr. calcanei mediales (a. tibialis post.) 198
Rr. calcanei mediales (n. tibialis) 270
Rr. capsulares 153
Rr. cardiaci inferiores (n. recurrentis) 261
Rr. cardiaci superiores (n. vagi) 261
Rr. cardiaci thoracici 261
R. caroticotympanicus 185
R. carpeus dorsalis (a. radialis) 189
R. carpeus dorsalis (a. ulnaris) 189
R. carpeus volaris (a. radialis) 189
R. carpeus volaris (a. ulnaris) 189
Rr. caudati 207
R. circumflexus 181
R. circumflexus fibulae (a. tibialis post.) 197
R. clavicularis (a. thoracoacromialis) 188
R. cochleae (a. auditivae int.) 288
Rr. coeliaci (n. vagi) 262
R. collateralis (rr. posteriores aa. intercostalium) 190
R. colli (n. facialis) 259
R. communicans 217
R. communicans 175
R. communicans (a. peronaeae) 198
R. communicans cum chorda tympani 257
R. communicans cum ganglione ciliari 253
Rr. communicantes cum n. linguali (ggl. submax.) 258
R. communicans cum ramo laryngeo interno 261
R. communicans cum ramo meningeo (n. mandibularis) 258
R. communicans (ggl. ciliaris) cum n. nasociliari 254
R. communicans (nn. spinalium) 262
Rr. communicantes (syst. nerv. autonom.) 271
R. communicans (vasorum, nervorum) 217
R. costalis lat. (a. mammariae int.) 186
R. cricothyreoideus 182
Rr. cutanei anteriores (n. femoralis) 268
R. cutaneus ant. (n. iliohypogastrici) 268
R. cutaneus ant. (pectoralis et abdominalis) (nn. intercostalium) 267
Rr. cutanei anteriores (rr. anteriores aa. intercostalium) 191
R. cutaneus brachii rad. 266
Rr. cutanei cruris med. (n. sapheni) 268
R. cutaneus lat. (n. iliohypogastrici) 268
R. cutaneus lat. (pectoralis et abdominalis) (nn. intercostalium) 266
Rr. cutanei laterales (rr. anteriores aa. intercostalium) 190
R. cutaneus lat. (rr. posteriores aa. intercostalium) 190
R. cutaneus lat. (rr. postteriores nn. thoracalium) 266
R. cutaneus med. (rr. posteriores aa. intercostalium) 190
R. cutaneus med. (rr. posteriores nn. thoracalium) 266
R. cutaneus (n. obturatorii) 268
R. cutaneus palmaris (n. ulnaris) 265
Rr. cutanei (rr. perfor. a. mammariae int.) 186
R. deltoideus (a. profundae brachii) 188
R. deltoideus (a. thoracoacromialis) 188
Rr. dentales (a. alveol. sup. ant.) 184
Rr. dentales (a. alveol. sup. post.) 184
Rr. dentales (a. maxillaris int.) 183
Rr. dentales inferiores (plexus dentalis inf.) 257
Rr. dentales superiores (plexus dentalis sup.) 255
R. descendens ant. (a. coronariae cordis sinistrae) 181
R. descendens (a. circumflexae femoris lat.) 196
R. descendens (a. occipitalis) 183
R. descendens (a. transversae colli) 187
R. descendens (n. hypoglossi) 263
R. descendens post. (a. coronariae cordis dextrae) 181
R. dexter (a. hepatica propriae) 191
R. dexter (a. pulmonalis) 181
R. dexter (v. portae) 207
R. digastricus (n. facialis) 259
R. dorsalis (a. collateralis radialis) 188
Rr. dorsales (a. intercostalis supremae) 187
R. dorsalis (aa. lumbalium) 191
R. dorsalis (a. recurrentis ulnaris) 189
Rr. dorsales linguae 182
R. dorsalis manus (n. ulnaris) 265
R. dorsalis (vv. intercostalium) 206
Rr. duodenales (a. pancreaticoduodenalis sup.) 192
Rr. epiploici (a. gastroepiploicae dextrae) 192
R. ext. (n. accessorii) 262
R. ext. (n. laryngei sup.) 261
R. femoralis (n. genitofemoralis) 268
R. fibularis (a. tibialis post.) 197

R. frontalis (a. maxillaris int.) 183
R. frontalis (a. temporalis superficialis) 183
Ramus frontalis (fissurae cerebri lat.) 236
R. frontalis (n. frontalis) 253
Rr. gastrici (n. vagi) 262
R. genitalis (n. genitofemoralis) 268
Rr. gingivales inferiores (plexus dentalis inf.) 257
Rr. gingivales superiores (plexus dentalis sup.) 255
Rr. glandulares (a. maxillaris ext.) 182
Rr. glandulares (a. thyreoideae inf.) 187
Rr. glandulares (a. thyreoideae sup.) 182
Rr. glandulares chordae tympani 259
Rr. glandulares (ggl. submandibularis) 258
Rr. glandulares n. glossopharyngici 260
Rr. hepatici (n. vagi) 262
R. hyoideus (a. lingualis) 182
R. hyoideus (a. thyreoideae sup.) 182
R. iliacus (a. iliolumbalis) 194
R. inf. (a. glutaeae sup.) 194
Rr. inferiores (n. cutanei colli) 263
R. inf. (n. oculomotorii) 252
R. inf. ossis ischii 50
R. inf. ossis pubis 51
R. infrahyoideus (a. thyroideae sup.) 182
R. infrapatellaris (n. sapheni) 268
Rr. inguinales (a. femoralis) 196
Rr. inguinales (vv. pudendales ext.) 210
Rr. intercostales (a. mammariae int.) 186
Rr. interganglionares (syst. nerv. autonom.) 271
R. int. (n. accessorii) 262
R. int. (n. laryngei sup.) 261
R. interventricularis (a. coronariae cordis dextrae) 181
R. interventricularis (a. coronariae cordis sinistrae) 181
Rr. intestinales (n. vagi) 262
Rr. isthmi (faucium (n. lingualis) 257
Rr. labiales (a. femoralis) 196
Rr. labiales inferiores (n. mentalis) 257
Rr. labiales (n. ilioinguinalis) 268
Rr. labiales post. 195
Rr. labiales superiores (n. infraorbitalis) 255
Rr. labiales (vv. pudendales ext.) 210
Rr. lacrimales n. petrosi superficialis majoris 255
Rr. laryngopharyngei (n. sympathici) 272
R. lat. (n. accessori) 262
R. lat. (n. frontalis) 253
R. lat. (rr. posteriores nn. cervicalium) 263
R. lat. (rr. posteriores nn. lumbalium) 267
R. lat. (r. post. nn. sacralium et n. coccygei) 267
Rr. lat. (v. portae) 207
Rr. lienales (a. lienalis) 192
Rr. lienales (n. vagi) 262
Rr. linguales (n. glossopharyngei) 260
Rr. linguales (n. hypoglossi) 262
Rr. linguales (n. lingualis) 257
R. lingualis (n. facialis) 259
R. lumbalis (a. iliolumbalis) 194
Rr. malleolares lat. 198
Rr. malleolares med. 198
Rr. mammarii externi (a. thoracalis lat.) 188
Rr. mammarii laterales (a. thoracalis lat.) 188
Rr. mammarii laterales (nn. intercostalium) 267
Rr. mammarii laterales (rr. anteriores aa. intercostalium) 191
Rr. mammarii mediales (aa. intercostalium) 191
Rr. mammarii mediales (nn. intercostalium) 267
Rr. mammarii (rr. perforantes a. mammariae int.) 186
R. mandibulae 77
R. marginalis mandibulae (n. facialis) 259
R. mastoideus (a. occipitalis) 182
Rr. mastoidei (a. stylomastoideae) 183
R. med. (n. accessorii) 262
R. med. (n. frontalis) 253
R. med. (rr. posteriores nn. cervicalium) 263
R. med. (rr. posteriores nn. lumbalium) 267
R. med. (rr. posteriores nn. sacralium et n. coccygei) 267
Rr. med. (v. portae) 207
Rr. mediastinales 167
Rr. mediastinales (aortae thoracalis) 190
R. membranae tympani (n. meatus auditorii ext.) 256
R. meningeus accessorius (a. meningeae mediae) 183
R. meningeus (a. occipitalis) 183
R. meningeus (a. vertebralis) 186
R. meningeus (nn. spinalium) 262
R. meningeus (n. vagi) 261
R. meningicus (n. mandibularis) 256
R. meningicus (n. maxillaris) 254
R. meningicus (n. ophthalmici) 253
Rr. mentales (n. mentalis) 257
Rr. musculares (a. cervicalis ascendentis) 187
Rr. musculares (a. femoralis) 196
Rr. musculares (a. genu supremae) 196
Rr. musculares (a. occipitalis) 183
Rr. musculares (a. ophthalmicae) 185
Rr. musculares (a. radialis) 189

Rr. musculares (a. ulnaris) 189
Rr. musculares intrabulbares 252
R. muscularis (nervorum) 217
Rr. musculares (n. axillaris) 266
Rr. musculares (n. femoralis) 268
Rr. musculares (n. iliohypogastrici) 268
Rr. musculares (n. ilioinguinalis) 268
Rr. musculares (n. ischiadici) 269
Rr. musculares (n. mediani) 264
Rr. musculares (n. musculocutanei) 264
Rr. musculares (n. obturatorii) 268
Rr. musculares (n. peronaei communis) 269
Rr. musculares (n. peronaei profundi) 269
Rr. musculares (n. peronaei superficialis) 269
Rr. musculares (n. radialis) 265
Rr. musculares (nn. thoracalium) 266
Rr. musculares (n. tibialis) 270
Rr. musculares (n. ulnaris) 265
Rr. musculares parasympathici (partis encephalicae syst. parasympathici) 276
Rr. musculares parasympathici (partis sacralis syst. sympathici) 276
Rr. musculares (plexus lumbalis) 268
Rr. musculares (rr. anteriores aa. intercostalium) 190
Rr. musculares (rr. perforantes a. mammariae int.) 186
Rr. musculares (rr. posteriores aa. intercostalium) 190
R. mylohyoideus (a. maxillaris int.) 183
Rr. nasales anteriores (n. ethmoidalis ant.) 253
Rr. nasales anteriores septi (n. ethmoidalis ant.) 253
R. nasalis ext. (n. ethmoidalis ant.) 254
Rr. nasales externi (n. infraorbitalis) 255
Rr. nasales interni (n. ethmoidalis ant.) 253
Rr. nasales interni (n. infraorbitalis) 255
Rr. nasales laterales (n. ethmoidalis ant.) 253
Rr. nasales mediales (n. ethmoidalis ant.) 253
R. nasalis (n. infraorbitalis) 255
Rr. nasales posteriores inferiores (n. palatini ant.) 256
Rr. nasales posteriores septi (ganglii sphenopalatini) 256
Rr. nasales posteriores superiores laterales (ganglii sphenopalatini) 255
Rr. nasales posteriores superiores mediales (ganglii sphenopalatini) 256
R. obturatorius (r. pubici a. epigastricae inf.) 195
R. occipitalis (a. auricularis post.) 183
Rr. occipitales (a. occipitalis) 183
R. occipitalis (fissurae cerebri lat.) 236
R. occipitalis (n. auricularis post.) 259
Rr. oesophagei (aortae thoracalis) 190
Rr. oesophagei (a. gastricae sinistrae) 191
Rr. oesophagei (a. thyreoideae inf.) 187
Rr. oesophagei (n. recurrentis) 261
Rr. oesophagei (n. vagi) 261
Rr. oesophagici (syst. sympathici) 273
Rr. orbitales (ganglii sphenopalatini) 255
R. ossis ischii 50
R. ossis pubis 50
R. ovarii (a. uterinae) 195
Rr. palatini (n. lingualis) 232
R. palmaris n. mediani 265
R. palmaris (n. ulnaris) 265
R. palmaris n. ulnaris 265
R. palpebralis inf. (n. infratrochlearis) 254
Rr. palpebrales inferiores (plexus dentalis sup.) 255
R. palpebralis sup. (n. infratrochlearis) 254
Rr. pancreatici (a. lienalis) 192
Rr. pancreatici (a. pancreaticoduodenalis sup.) 192
Rr. parietales (aortae abdominalis) 191
Rr. parietales (aortae thoracalis) 190
Rr. parietales (a. hypogastricae) 194
R. parietalis (a. maxillaris int.) 183
R. parietalis (a. temporalis superficialis) 183
Rr. parotidei (a. temporalis superficialis) 183
Rr. parotidei (n. auriculotemporalis) 257
Rr. parotidei (v. facialis) 201
Rr. parotidici (v. facialis, v. retromandibularis) 201
Rr. pectorales (a. thoracoacromialis) 188
Rr. pectorales (rr. anteriores aa. intercostalium) 191
Rr. perforantes 185
Rr. perforantes (a. mammariae int.) 186
Rr. perforantes (aa. metacarpalium volarium) 189
Rr. perforantes (aa. metatarsalium plantarium) 198
R. perforans (a. peronaeae) 198
Rr. pericardiaci (aortae thoracalis) 190
R. pericardiacus (n. phrenici) 263
Rr. perineales (n. cutanei femoris post.) 269
R. petrosus superficialis (a. meningeae mediae) 184
Rr. pharyngei (a. pharyngeae ascendentis) 182
Rr. pharyngei (a. thyreoideae inf.) 187
R. pharyngeus (ggl. pterygopalatini) 256

Rr. pharyngei (n. glossopharyngei) 260
Rr. pharyngei (n. vagi) 261
Rr. phrenici (n. phrenici) 263
Rr. phrenicoabdominales (n. phrenici) 263
R. plantaris profundus (a. dorsalis pedis) 197
Rr. posteriores (aa. intercostalium) 190
R. post. (a. obturatoriae) 194
R. post. (a. thyreoideae sup.) 182
R. post. (fissurae cerebri lat.) 236
R. post. (n. auricularis magni) 263
Rr. posteriores (nn. cervicalium) 263
R. post. (n. laryngei inf.) 261
Rr. posteriores (nn. lumbalium) 267
R. post. (n. obturatorii) 268
Rr. posteriores (nn. sacralium et n. coccygei) 267
R. post. (nn. spinalium) 262
Rr. posteriores (nn. thoracalium) 266
R. post. (pectoralis et abdominalis) (nn. intercostalium) 267
R. post. (rr. anteriores aa. intercostalium) 190
R. post. (v. portae) 207
Rr. praeauriculares (a. temporalis superficialis) 183
R. profundus (a. cervicalis ascendentis) 187
R. profundus (a. circumflexae femoris med.) 196
R. profundus (a. glutaeae sup.) 194
R. profundus (a. obturatoriae) 194
R. profundus (a. plantaris med.) 198
R. profundus (a. transversae colli) 187
R. profundus (n. obturatorii) 268
R. profundus (n. plantaris lat.) 270
R. profundus (n. radialis) 265
R. profundus (r. volaris manus n. ulnaris) 265
Rr. pterygoidei (a. maxillaris int.) 184
R. pubicus (a. epigastricae inf.) 195
R. pubicus (a. obturatoriae) 194
Rr. pulmonales (syst. sympathici) 273
R. pyramidis superficialis (a. meningeae mediae) 184
Rr. radicis 129
R. renalis (n. splanchnici minoris) 273
Rr. renales (n. vagi) 262
R. saphenus (a. genu supremae) 196
Rr. scrotales 210
Rr. scrotales (a. femoralis) 196
Rr. scrotales (n. ilioinguinalis) 268
Rr. scrotales post. 195
R. sinister (a. hepatica propriae) 192
R. sinister (a. pulmonalis) 181
R. sinister (v. portae) 207
R. sinus carotici (n. glossopharyngei) 260
Rr. spinales (a. cervicalis ascendentis) 187
R. spinalis (a. iliolumbalis) 194
Rr. spinales (a. intercostalis supremae) 187
Rr. spinales (a. sacralis lat.) 194
Rr. spinales (a. vertebralis) 186
R. spinalis (aa. lumbalium) 191
R. spinalis (rr. posteriores aa. intercostalium) 190
R. spinalis (vv. intercostalium) 206
R. stapedius (a. stylomastoideae) 183
Rr. sternales (a. mammariae int.) 186
Rr. sternocleidomastoidei 182
R. sternocleidomastoideus (a. thyreoideae sup.) 182
R. stylohyoideus (n. facialis) 259
R. stylopharyngeus (n. glossopharyngei) 260
Rr. submaxillares (ggl. submax.) 258
Rr. subscapulares (a. axillaris) 188
R. superficialis (a. cervicalis superficialis) 187
R. superficialis (a. circumflexae femoris med.) 196
R. superficialis (a. glutaeae sup.) 194
R. superficialis (a. obturatoriae) 194
R. superficialis (a. plantaris fibularis) 198
R. superficialis (a. plantaris med.) 198
R. superficialis (n. plantaris lat.) 270
R. superficialis (n. radialis) 266
R. superficialis (r. volaris manus n. ulnaris) 265
R. sup. (a. glutaeae sup.) 194
Rr. sup. (n. cutanei colli) 263
R. sup. (n. oculomotorii) 252
R. sup. ossis ischii 50
R. sup. ossis pubis 50
R. suprahyoideus 182
Rr. suprarenales (a. renalis) 193
Rr. suprarenales superiores (a. phrenicae inf.) 191
R. sympathicus ad ganglion ciliare 254
Rr. temporales (n. facialis) 259
Rr. temporales superficiales (n. auriculotemporalis) 257
R. tentorii 253
Rr. thymici 186
R. thyreohyoideus (n. hypoglossi) 263
R. tonsillaris (a. maxillaris ext.) 182
Rr. tonsillares (n. glossopharyngei) 260
Rr. tracheales (a. thyreoideae inf.) 187
Rr. tracheales (n. recurrentis) 261
R. transversus (a. prof. femoris) 196
R. tubae pharyngotympanicae 260
R. tubae (plexus tympanici) 260
R. tubarius (a. uterinae) 195
R. tympanicus post. 183
R. tympanicus sup. (a. meningeae mediae) 184

R. ulnaris (n. cutanei antibrachii med.) 264
Rr. ureterici (a. ductus deferentis) 194
Rr. ureterici (a. renalis) 193
Rr. ureterici (a. testicularis seu a. ovaricae) 193
R. utriculi (n. utricularis) 260
Rr. ventrales (nn. sacralium et n. coccygei) 267
Rr. vestibulares (a. auditivae int.) 288
Rr. viscerales (aortae abdominalis) 191
Rr. viscerales (aortae thoracalis) 190
Rr. viscerales (a. hypogastricae) 194
R. volaris (a. collateralis radialis) 188
R. volaris (a. recurrentis ulnaris) 189
R. volaris manus (n. ulnaris) 265
R. volaris (n. cutanei antibrachii med.) 264
R. volaris profundus 189
R. volaris superficialis (a. radialis) 189
Rr. zygomatici (n. facialis) 259
R. zygomaticofacialis 254
R. zygomaticotemporalis 254
Raphe 32
Raphe chorioideae 278
Raphe (medullae oblongatae) 221
Raphe palati 126
Raphe palpebralis lat. 283
Raphe penis 159
Raphe perinei 166
Raphe pharyngis 132
Raphe (pontis) 225
Raphe pterygomandibularis 132
Raphe sclerae 277
Raphe scroti 160
Recessus 32
Recessus ant. (fossae interpeduncularis) 229
Recessus camerae post. (oculi) 281
Recessus cochlearis 288
Recessus costodiaphragmaticus 151
Recessus costomediastinalis 151
Recessus duodenalis inf. 170
Recessus duodenalis sup. 170
Recessus duodenojejunalis 170
Recessus duodenomesocolicus caudalis 170
Recessus duodenomesocolicus cranialis 170
Recessus ellipticus 288
Recessus epitympanicus 291
Recessus hepatorenalis 170
Recessus ileocaecalis inf. 171
Recessus ileocaecalis sup. 170
Recessus inf. omentalis 170
Recessus infundibuli 232
Recessus intersigmoideus 170
Recessus lat. fossae rhomboideae 224
Recessus lat. ventriculi quarti 224
Recessus lienalis 170
Recessus membranae tympani ant. 294
Recessus membranae tympani post. 294
Recessus membranae tympani sup. 294
Recessus opticus 232
Recessus paracolici 171
Recessus paraduodenalis 170
Recessus pharyngeus 131
Recessus phrenicohepatici 171
Recessus pinealis 234
Recessus piriformis 132
Recessus pleurales 151
Recessus post. (fossae interpeduncularis) 229
Recessus praecardiacus 151
Recessus retrocaecalis 171
Recessus retroduodenalis 170
Recessus rostralis (fossae intercruralis) 229
Recessus sacciformis (art. cubiti) 83
Recessus sacciformis (art. radioulnaris distalis) 84
Recessus sacculi 288
Recessus sphaericus 288
Recessus sphenoethmoidalis 80
Recessus subhepatici 170
Recessus subphrenici 171
Recessus subpopliteus 113
Recessus sup. omentalis 169
Recessus suprapinealis 234
Recessus triangularis 232
Recessus utriculi 288
Rectum 137
Rectus 32
Recurrens 32
Reflexus 32
Regio 32
Regio abdominalis lat. 305
Regiones abdominis 305
Regio abdominis caudalis 305
Regio abdominis media 305
Regio acromialis 306
Regio analis 306
Regio antibrachii dorsalis 306
Regio antibrachii radialis 306
Regio antibrachii ulnaris 306
Regio antibrachii volaris 306
Regio auricularis 303
Regio axillaris 305
Regio brachii ant. 306
Regio brachii lat. 306
Regio brachii med. 306

Regio brachii post. 306
Regio buccalis 303
Regio calcanea 307
Regiones capitis 303
Regio clavicularis 305
Regiones colli 304
Regio colli ant. 304
Regio colli lat. 304
Regio colli post. 304
Regiones corporis 303
Regio costalis lat. 305
Regio coxae 305
Regio cruris ant. 307
Regio cruris lat. 307
Regio cruris med. 307
Regio cruris post. 307
Regio cubiti ant. 306
Regio cubiti lat. 306
Regio cubiti med. 306
Regio cubiti post. 306
Regio deltoidea 306
Regiones digitales (manus) 306
Regiones digitales pedis 307
Regiones dorsales digitorum (manus) 306
Regiones dorsales digitorum pedis 307
Regio dorsalis manus 306
Regio dorsalis pedis 307
Regiones dorsi 305
Regio epigastrica 305
Regiones extremitatis inf. 306
Regiones extremitatis pelvinae 306
Regiones extremitatis sup. 306
Regiones extremitatis thoracicae 306
Regiones faciei 303
Regio femoris ant. 307
Regio femoris lat. 307
Regio femoris med. 307
Regio femoris post. 307
Regio frontalis 303
Regio genu ant. 307
Regio genu post. 307
Regio glutaea 306
Regio hyoidea 304
Regio hypochondriaca 305
Regio hypogastrica 305
Regio infraclavicularis 305
Regio inframammalis 305
Regio infraorbitalis 303
Regio infrascapularis 305
Regio infratemporalis 303
Regio inguinalis 305
Regio interscapularis 305
Regio labialis inf. 303
Regio labialis sup. 303
Regio laryngea 304
Regio lumbalis 305
Regio malleolaris lat. 307
Regio malleolaris med. 307
Regio mammalis 305
Regio mastoidea 303
Regio mediana dorsi 305
Regiones membri inf. 306
Regiones membri sup. 306
Regio mentalis 303
Regio mesogastrica 276
Regio mesogastrica 305
Regio nasalis 303
Regio nuchae 304
Regio occipitalis 303
Regio olecrani 306
Regio olfactoria 143
Regio olfactoria tunicae mucosae nasi 297
Regio oralis 303
Regio orbitalis 303
Regio palpebralis inf. 303
Regio palpebralis sup. 303
Regio parietalis 303
Regio parotideomasseterica 304
Regio patellaris 307
Regiones pectoris 305
Regio pectoris ant. 305
Regio pectoris lat. 305
Regio perinealis 39
Regio perinealis 306
Regiones plantares digitorum pedis 307
Regio plantaris pedis 307
Regio pubica 305
Regio pudendalis 306
Regio respiratori 143
Regio retromalleolaris lat. 307
Regio retromalleolaris med. 307
Regio retromandibularis 304
Regio sacralis 305
Regio scapularis 305
Regio sternalis 305
Regio sternocleidomastoidea 304
Regio subhyoidea 304
Regio submandibularis 275
Regio submaxillaris 304
Regio submentalis 304
Regio supraorbitalis 303
Regio suprascapularis 305

Regio suprasternalis 304
Regio suralis 307
Regio temporalis 303
Regio thoracica lat. 276
Regio thyreoidea 304
Regio trochanterica 307
Regio umbilicalis 305
Regiones unguiculares (manus) 306
Regiones unguiculares pedis 307
Regio urogenitalis 306
Regio vertebralis 305
Regiones volares digitorum (manus) 306
Regio volaris manus 306
Regio zygomatica 303
Ren 152
Renalis 32
Respiratio 32
Rete 32
Rete acromiale 188
Rete arteriosum 175
Rete articulare cubiti 189
Rete articulare genu 197
Rete calcaneum 198
Rete canalis hypoglossi 204
Rete carpi dorsale 189
Rete carpi volare 189
Rete dorsale pedis 197
Rete foraminis ovalis 204
Rete malleolare lat. 197
Rete malleolare med. 197
Rete mirabile 175
Rete patellae 197
Rete testis 155
Rete vasculosum 175
Rete venosum 175
Rete venosum dorsale manus 203
Rete venosum dorsale pedis 210
Rete venosum plantare 211
Retia venosa vertebrarum 206
Reticulum 32
Retina 280
Retinaculum 32
Retinaculum caudale cutis 298
Retinacula cutis 298
Retinaculum extensorum 103
Retinaculum flexorum 104
Retinaculum lig. arcuati 87
Retinaculum mm. extensorum inf. 111
Retinaculum mm. extensorum sup. 110
Retinaculum mm. fibularium distale 111
Retinaculum mm. fibularium proximale 111
Retinaculum mm. flexorum 111
Retinaculum mm. peronaeorum inf. 111
Retinaculum mm. peronaeorum sup. 111
Retinaculum patellae lat. 87
Retinaculum patellae med. 87
Retinacula unguis 299
Retroflexus 32
Retrogressus 32
Rhinencephalon 241
Rhombencephalon 221
Rhomboides 32
Rima 32
Rima cornealis 277
Rima glottidis 148
Rima oris 38, 126
Rima palpebrarum 283
Rima pudendi 164
Rima vestibuli 148
Rivus lacrimalis 285
Rostralis 17
Rostrum 32
Rostrum corporis callosi 240
Rostrum sphenoidale 65
Rotundus 32
Ruber 32
Rudimentum 32
Rudimentum processus vaginalis 157
Ruga 32
Rugae iridis 279
Rugae vaginales 163

Sacculus 32
Sacculus 285
Sacculi alveolares 151
Sacculus laryngis 148
Saccus 32
Saccus conjunctivae 284
Saccus endolymphaticus 285
Saccus lacrimalis 285
Sacrum 32
Sagittalis 17
Saliva 32
Saliva 128
Sanguis 32
Sanguis 176
Scala 32
Scala tympani 290
Scala vestibuli 290
Scalenus 32
Scapha 32
Scapha 296

Scapula 44
Scapus 32
Scapus pili 299
Sceletus 32
Sclera 32
Sclera 277
Scrobiculus cordis 38
Scrotum 32
Scrotum 160
Sebaceus 32
Sebum 32
Sebum cutaneum 300
Sebum palpebrale 284
Secretum 32
Sectio 32
Sectiones cerebelli 228
Sectiones corporum quadrigeminorum 231
Sectiones hypothalami 233
Sectiones medullae oblongatae 221
Sectiones medullae spinalis 218
Sectiones mesencephali 230
Sectiones pedunculi cerebri 230
Sectiones pontis 225
Sectiones telencephali 242
Sectiones thalamencephali 234
Segmenta bronchopulmonalia 150
Segmenta renalia 152
Segmentum 32
Sella 32
Sella turcica 65
Semen 32
Semicanalis m. tensoris tympani 70
Semicanalis tubae auditivae 70
Semicanalis tubae pharyngotympanicae 70
Sensorium 32
Sensus 32
Septulum 32
Septula testis 155
Septum 33
Septum anococcygicum 166
Septum anuli femoralis 109
Septum atriorum 177
Septum atrioventriculare 177
Septum bulbi urethrae 159
Septum canalis musculotubarii 70
Septum cartilagineum (nasi) 142
Septum cervicale intermedium 251
Septum corporum cavernosorum 165
Septum femorale 109
Septum glandis (penis) 158
Septa interalveolaria (mandibulae) 77
Septa interalveolaria (maxillae) 75
Septum interatriale 177
Septum intermusculare 99
Septum intermusculare ant. (fibulare) 110
Septum intermusculare cruris ant. 110
Septum intermusculare cruris post. 110
Septum intermusculare femoris lat. 108
Septum intermusculare femoris med. 109
Septum intermusculare (humeri) lat. 101
Septum intermusculare (humeri) med. 101
Septum intermusculare post. (fibulare) 110
Septa interradicularia (mandibulae) 77
Septa interradicularia (maxillae) 75
Septum interventriculare 177
Septa intraalveolaria (mandibulae) 77
Septa intraalveolaria (maxillae) 75
Septum leptomeningicum apinale 251
Septum linguae 130
Septum mediastinale 152
Septum membranaceum (nasi) 142
Septum membranaceum ventriculorum 177
Septum mobile nasi 143
Septum musculare ventriculorum 177
Septum nasi 142
Septum nasi osseum 79
Septum nuchae 93
Septum orbitale 283
Septum pectiniforme (clitoridis) 165
Septum pectiniforme corporis cavernosi penis 159
Septum pellucidum 240
Septum penis 159
Septum scroti 160
Septum sinuum frontalium 73
Septum sinuum sphenoidalium 64
Septum ventriculorum 177
Serotinus 33
Serratus 33
Serum 33
Serum 125
Sesamoides 33
Sigmoideus 33
Simplex 33
Sinciput 37
Singularis 33
Sinister 17
Sinus 33
Sinus aortae 181
Sinus a. carotidis int. 184
Sinus a. pulmonalis 181
Sinus caroticus 181
Sinus cavernosus 203

Sinus circularis 204
Sinus coronarius 199
Sinus costomediastinalis 151
Sinus durae matris 203
Sinus epididymidis 157
Sinus ethmoidei 73
Sinus ethmoidei ant. (cavi nasi) 143
Sinus ethmoidei (cavi nasi) 143
Sinus ethmoidei post. (cavi nasi) 143
Sinus frontalis 143
Sinus intercavernosus ant. 204
Sinus intercavernosus post. 204
Sinus lactiferi 301
Sinus lienis 141
Sinus maxillaris (cavi nasi) 143
Sinus maxillaris (maxillae) 75
Sinus nasales 143
Sinus obliquus pericardii 176
Sinus occipitalis 203
Sinus paranasales 143
Sinus petrosus inf. 203
Sinus petrosus sup. 203
Sinus phrenicocostalis 151
Sinus phrenicomediastinalis 151
Sinus pleurae 151
Sinus post. (cavi tympani) 292
Sinus prostaticus 160
Sinus rectales 138
Sinus rectus 203
Sinus renalis 152
Sinus sagittalis inf. 203
Sinus sagittalis sup. 203
Sinus sigmoides 203
Sinus sphenoidalis 143
Sinus sphenoparietalis 204
Sinus tarsi 56
Sinus tonsillaris 131
Sinus transversus 203
Sinus transversus pericardii 177
Sinus trunci pulmonalis 181
Sinus tympani 291
Sinus unguis 299
Sinus urogenitalis 166
Sinus venarum (cavarum) 178
Sinus (venosus) 175
Sinus venosus sclerae 277
Sinus vertebrales longitudinales 206
Skeleton extremitatis inf. liberae 51
Skeleton extremitatis sup. liberae 45
Skeleton membri inf. liberi 51
Skeleton membri sup. liberi 45
Smegma clitoridis 165
Smegma praeputii 159
Solitarius 33
Solum 33
Solum tympani 291
Spatium 33
Spatia anguli iridis 279
Spatium apparatus suspensorii (lentis) 282
Spatium circumbulbare 283
Spatium episclerale 283
Spatia intercostalia 63
Spatium interfasciale 283
Spatia interglobularia 129
Spatia interossea metacarpi 85
Spatia interossea metatarsi 92
Spatia intervaginalia 277
Spatium perichorioideale 278
Spatium perilymphaticum 287
Spatium perinei profundum 167
Spatium perinei superficiale 168
Spatium praevesicale 171
Spatium retroperitoneale 172
Spatium retroperitoneale pelvis 172
Spatium retropubicum 171
Spatia zonularia 282
Sperma 33
Sperma (semen) 156
Spermaticus 33
Sphenoidalis 33
Sphericus 33
Spheroides 33
Spina 33
Spina angularis 66
Spina frontalis 73
Spina helicis 296
Spina iliaca ant. inf. 49
Spina iliaca ant. sup. 49
Spina iliaca post. inf. 49
Spina iliaca post. sup. 49
Spina ischiadica 50
Spinae mandibulae 77
Spina mentalis 77
Spina m. genioglossi 77
Spina m. geniohyoidei 77
Spina nasalis ant. 75
Spina nasalis ossis frontalis 73
Spina nasalis post. 76
Spina ossis ischii 50
Spina ossis sphenoidis 66
Spinae palatinae 75
Spina scapulae 44

Spina supra meatum 71
Spina trochlearis 72
Spina tympanica major 70
Spina tympanica minor 70
Splanchnicus 33
Splanchnologia 125
Splenium 33
Splenium corporis callosi 240
Spondylus 33
Spongiosus 33
Spongium anguli iridocornealis 279
Spurius 33
Squama 33
Squama frontalis 72
Squama occipitalis 63
Squama temporalis 66
Squamosus 33
Stapes 293
Statoconia 287
Status 33
Stella 33
Stella lentis ant. 281
Stella lentis post. 281
Stellatus 33
Sternum 62
Stoma 33
Stomachus 33
Stratum 33
Strata alba corticis 217
Stratum album profundum (corp. quadrig.) 231
Stratum basale (epidermidis) 298
Stratum cerebrale (retinae) 280
Stratum cinereum (cerebelli) 229
Stratum circulare (intestini crassi) 136
Stratum circulare (membranae tympani) 293
Stratum circulare (recti) 137
Stratum circulare (tunicae muscularis tubae uterinae) 162
Stratum circulare (tunicae muscularis urethrae muliebris) 165
Stratum circulare (tunicae muscularis ventriculi) 134
Stratum corneum (epidermis) 298
Stratum corneum (unguis) 300
Stratum cutaneum (membranae tympani) 293
Stratum ext. (thecae folliculi) 161
Stratum ext. (tunicae muscularis ductus deferentis) 156
Stratum ext. (tunicae muscularis ureteris) 154
Stratum ext. (tunicae muscularis vesicae urinariae) 154
Stratum ferrugineum (cerebelli) 229
Stratum fibrosum 82
Stratum fibrosum (cutis) 298
Stratum ganglionare n. optici 280
Stratum ganglionare retinae 280
Stratum gangliosum (cerebelli) 229
Stratum germinativum 298
Stratum germinativum unguis 300
Stratum granulosum (cerebelli) 229
Stratum granulosum (epidermidis) 298
Stratum granulosum (ovarii) 161
Stratum griseum centrale 230
Stratum griseum colliculi sup. 231
Stratum griseum (corporis callosi) 240
Stratum int. (thecae folliculi) 161
Stratum int. (tunicae muscularis ductus deferentis) 156
Stratum int. (tunicae muscularis ureteris) 154
Stratum int. (tunicae muscularis vesicae urinariae) 154
Stratum interolivare lemnisci 223
Stratum longitudinale (intestini crassi) 136
Stratum longitudinale (recti) 137
Stratum longitudinale (tunicae muscularis tubae uterinae) 162
Stratum longitudinale (tunicae muscularis urethrae muliebris) 165
Stratum longitudinale (tunicae muscularis ventriculi) 134
Stratum lucidum (epidermidis) 298
Stratum medium (tunicae muscularis ductus deferentis) 156
Stratum medium (tunicae muscularis ureteris) 154
Stratum medium (tunicae muscularis vesicae urinariae) 154
Stratum moleculare (cerebelli) 229
Stratum mucosum (membranae tympani) 293
Stratum neuroepitheliale 280
Stratum nucleare (medullae oblongatae) 221
Stratum papillare (corii) 298
Stratum perichorioideum 278
Stratum pigmenti (bulbi oculi) 279
Stratum pigmenti corporis ciliaris 279
Stratum pigmenti iridis 279
Stratum pigmenti retinae 279
Stratum radiatum (membranae tympani) 293
Stratum reticulare (corii) 298
Stratum spinosum (epidermidis) 298
Stratum synoviale 82
Stratum zonale (corp. quadrigem.) 231

Stratum zonale (thalami) 234
Stria 33
Stria alba tuberis 232
Stria intermedia (trigoni olfactorii) 242
Stria longitudinalis lat. (corporis callosi) 240
Stria longitudinalis med. (corporis callosi) 240
Stria malleolaris 292
Stria med. (trigoni olfactorii) 242
Striae medullares corticis (renis) 153
Stria medullaris (thalami) 234
Striae medullares (ventriculi quarti) 224
Stria membranae tympani ant. 292
Stria membranae tympani post. 292
Striae olfactoriae 240
Stria olfactoria intermedia 242
Stria olfactoria lat. 242
Stria olfactoria med. 242
Stria terminalis 241
Striae transversae (corporis callosi) 240
Stria vascularis 287
Striatus 33
Stroma 33, 125
Stroma glandulae thyreoideae 172
Stroma iridis 279
Stroma ovarii 161
Stroma vitreum 281
Stylus 33
Subiculum promontorii 291
Substantia 33
Substantia adamantina 129
Substantia alba 217
Substantia compacta 43
Substantia corticalis (cerebelli) 229
Substantia corticalis (cerebri) 242
Substantia corticalis (gl. suprarenalis) 173
Substantia corticalis (lentis) 281
Substantia corticalis (lgl.) 211
Substantia corticalis (ossis) 43
Substantia corticalis (renis) 153
Substantia eburnea 129
Substantia gelatinosa 217
Substantia gelatinosa centralis 219
Substantia gelatinosa (medullae spinalis) 219
Substantia glandularis (prostatae) 158
Substantia grisea 217
Substantia grisea centralis 219
Substantia grisea centralis 230
Substantia intermedia centralis 219
Substantia intermedia lat. 219
Substantia lentis 281
Substantia medullaris (gl. suprarenalis) 173
Substantia medullaris (lgl.) 211
Substantia medullaris (renis) 153
Substantia muscularis (prostatae) 158
Substantia nigra 231
Substantia ossea (dentis) 129
Substantia perforata ant. 240
Substantia perforata ant. 242
Substantia perforata intercruralis 229
Substantia perforata post. 229
Substantia propria (corneae) 278
Substantia propria sclerae 277
Substantia reticularis alba (cerebri) 240
Substantia reticularis alba (medullae oblongatae) 223
Substantia reticularis grisea 223
Substantia spongiosa 43
Succus 33
Succus entericus 135
Succus gastricus 134
Succus pancreaticus 138
Succus prostaticus 158
Sudor 33
Sudor 300
Sulcus 33, 217
Sulcus adolfactorius ant. 241
Sulcus adolfactorius post. 242
Sulcus ampullaris 286
Sulcus anthelicis transversus 297
Sulcus anuli tympanici 70
Sulcus aorticus (pulmonis sinistri) 150
Sulcus a. occipitalis 71
Sulcus a. subclaviae (pulmonis) 150
Sulcus a. temporalis 67
Sulcus a. vertebralis 60
Sulci arteriarum 71
Sulci arteriosi (ossium cranii) 79
Sulcus auriculae post. 296
Sulcus basilaris 225
Sulcus bicipitalis lat. 101
Sulcus bicipitalis med. 101
Sulcus calcanei 56
Sulcus calcarinus 240
Sulcus canaliculi mastoidei 69
Sulcus caroticus 65
Sulcus carpi 48
Sulcus centralis 237
Sulcus centralis insulae 237
Sulci cerebelli 227
Sulci cerebri 236
Sulcus chiasmatis 65
Sulcus cinguli 239

Sulcus circularis 237
Sulcus collateralis 239
Sulcus coronarius (cordis) 176
Sulcus corporis callosi 239
Sulcus costae 62
Sulcus cristae pyramidis 68
Sulcus cruris helicis 297
Sulci cutis 298
Sulcus dorsolateralis (medullae oblongatae) 221
Sulcus dorsolateralis (medullae spinalis) 218
Sulcus ethmoidalis 74
Sulcus fasciculi optici 65
Sulcus frontalis inf. 237
Sulcus frontalis sup. 237
Sulcus frontopalpebralis 284
Sulcus glutaeus 40
Sulcus hamuli pterygoidei 66
Sulcus helicotragicus 296
Sulcus hippocampi 239
Sulcus horizontalis cerebelli 227
Sulcus hypothalamicus 232
Sulcus infraorbitalis 74
Sulcus infrapalpebralis 284
Sulcus intermedius ant. (medullae spinalis) 218
Sulcus intermedius post. (medullae spinalis) 218
Sulcus interparietalis 239
Sulcus intertubercularis 45
Sulcus interventricularis dorsalis (cordis) 176
Sulcus interventricularis ventralis (cordis) 176
Sulcus juxtaauricularis 50
Sulcus lacrimalis (maxillae) 75
Sulcus lacrimalis (ossis lacrimalis) 74
Sulcus lat. ant. (medullae oblongatae) 221
Sulcus lat. ant. (medullae spinalis) 218
Sulcus lat. (cerebri) 236
Sulcus lat. (mesencephali) 229
Sulcus lat. post. (medullae oblongatae) 221
Sulcus lat. post. (medullae spinalis) 218
Sulcus lectuli unguis 299
Sulcus limitans (fossae rhomboideae) 224
Sulcus limitans ventriculorum 217
Sulcus longitudinalis ant. (cordis) 176
Sulcus longitudinalis post. (cordis) 176
Sulcus lunatus 238
Sulcus malleolaris 53
Sulcus malleoli fibulae 54
Sulcus malleoli tibiae 53
Sulcus matricis unguis 299
Sulcus med. cruris cerebri 229
Sulcus medianus dorsalis (medullae oblongatae) 221
Sulcus medianus linguae 130
Sulcus medianus (pontis) 225
Sulcus medianus post. (medullae spinalis) 218
Sulcus medianus (ventriculi quarti) 223
Sulcus mentolabialis 38
Sulcus m. bicipitis brachii radialis 100
Sulcus m. bicipitis brachii ulnaris 101
Sulcus m. flexoris hallucis longi (calcanei) 56
Sulcus m. flexoris hallucis longi (tali) 55
Sulcus m. peronaei (longi) (calcanei) 56
Sulcus m. peronaei (longi) (ossis cuboidei) 57
Sulcus mylohyoideus 77
Sulcus nasolabialis 38
Sulcus n. oculomotorii 229
Sulcus n. petrosi superficialis majoris 67
Sulcus n. petrosi superficialis minoris 67
Sulcus n. radialis 46
Sulcus n. spinalis 59
Sulcus n. ulnaris 46
Sulcus obturatorius 50
Sulci occipitales laterales 238
Sulci occipitales superiores 238
Sulcus occipitalis transversus 238
Sulcus occipitotemporalis 239
Sulcus olfactorius (cavi nasi) 142
Sulcus olfactorius (cerebri) 237
Sulci orbitales 237
Sulci palatini 75
Sulcus palatinus major 75
Sulcus palatovaginalis 66
Sulcus palpebralis inf. 284
Sulcus palpebralis sup. 284
Sulcus palpebromalaris 284
Sulci paracolici 171
Sulci paraglenoidales 50
Sulcus parietooccipitalis 240
Sulcus parolfactorius ant. 241
Sulcus parolfactorius post. 242
Sulcus petrosus inf. (ossis occipitalis) 63
Sulcus petrosus inf. (ossis temporalis) 68
Sulcus petrosus sup. 68
Sulcus popliteus 52
Sulcus postcentralis 238
Sulcus praecentralis 237
Sulcus promontorii 291
Sulcus pterygopalatinus (ossis sphenoidalis) 66
Sulcus pterygopalatinus (ossis palatini) 75
Sulcus pulmonalis 63
Sulcus rhinalis 239
Sulcus sagittalis (ossis frontalis) 72
Sulcus sagittalis (ossis occipitalis) 64

Sulcus sagittalis (ossis parietalis) 71
Sulcus sclerae 277
Sulcus sigmoideus 71
Sulcus sinus sagittalis sup. 71
Sulcus sinus sigmoidei (partis petrosae) 69
Sulcus spiralis 287
Sulcus spiralis int. 287
Sulcus subclaviae 62
Sulcus subclavius apicis pleurae 151
Sulcus subclavius (pulmonis) 150
Sulcus subparietalis 239
Sulcus (systematis nervorum) 217
Sulcus tali 55
Sulcus temporalis inf. 238
Sulcus temporalis medius 238
Sulcus temporalis sup. 238
Sulci temporales transversi 237
Sulcus tendinis m. fibularis longi (calcanei) 56
Sulcus tendinis m. fibularis longi (ossis cuboidei) 57
Sulcus terminalis atrii dextri 178
Sulcus terminalis (linguae) 130
Sulcus transversus (ossis occipitalis) 64
Sulcus transversus (ossis parietalis) 71
Sulcus tubae auditivae 66
Sulcus tubae pharyngotympanicae 66
Sulcus tympanicus 70
Sulcus v. cavae 139
Sulcus v. cavae cranialis (pulmonis dextri) 150
Sulcus v. subclaviae 62
Sulci venosi (ossium cranii) 79
Sulcus ventrolateralis (medullae oblongatae) 221
Sulcus ventrolateralis (medullae spinalis) 218
Sulcus vomerovaginalis 66
Supercilia 299
Supercilium 37, 283
Superficialis (sublimis) 17
Superior 17
Supinus 33
Sura 33
Sura 41
Suspensus 33
Sustentaculum 34
Sustentaculum tali 56
Sutura 34
Sutura 81
Sutura conchomaxillaris 97
Sutura conchopalatina 97
Sutura coronalis 96
Suturae cranii 96
Sutura ethmoideomaxillaris 97
Sutura frontalis 96
Sutura frontoethmoidalis 96
Sutura frontolacrimalis 96
Sutura frontomaxillaris 96
Sutura incisiva 75
Sutura infraorbitalis 74
Sutura intermaxillaris 97
Sutura internasalis 97
Sutura lacrimoconchalis 97
Sutura lacrimoethmoidea 97
Sutura lacrimomaxillaris 97
Sutura laevis 81
Sutura lambdoidea 96
Sutura mastoideosquamalis 96
Sutura mendosa 81
Sutura nasofrontalis 96
Sutura nasomaxillaris 97
Sutura occipitalis transversa 96
Sutura occipitomastoidea 96
Sutura palatina mediana 97
Sutura palatina transversa 97
Sutura palatoethmoidalis 97
Sutura palatomaxillaris 97
Sutura parietomastoidea 96
Sutura parietotemporalis 96
Sutura plana 81
Sutura sagittalis 96
Sutura serrata 81
Sutura sphenoethmoidalis 96
Sutura sphenofrontalis 96
Sutura sphenomaxillaris 97
Sutura sphenoorbitalis 96
Sutura sphenoparietalis 96
Sutura sphenosquamosa 96
Sutura sphenozygomatica 97
Sutura squamosa 81
Sutura squamosa (suturae cranii) 96
Sutura squamosomastoidea 96
Sutura vomeroethmoidea 97
Sutura vomeromaxillaris 97
Sutura vomeropalatina 97
Sutura zygomaticofrontalis 96
Sutura zygomaticomaxillaris 97
Sutura zygomaticotemporalis 97
Sympathicus 34
Symphysis 34
Symphysis 81
Symphysis ossium pubis 86
Symphysis pubica 86
Symphysis sacrococcygea 93
Symphysis sterni 62

Synarthrosis 81
Synchondrosis 34
Synchondrosis 81
Synchondrosis arycorniculata 147
Synchondrosis basilateralis ossis occipitalis 98
Synchondroses cranii 98
Synchondrosis epiphyseos 43
Synchondrosis intersphenoidalis 98
Synchondrosis intraoccipitalis ant. 98
Synchondrosis intraoccipitalis post. 98
Synchondrosis manubriosternalis 95
Synchondrosis petrooccipitalis 98
Synchondrosis sphenooccipitalis 98
Synchondrosis sphenopetrosa 98
Synchondrosis squamolateralis ossis occipitalis 98
Synchondroses sternales 95
Synchondrosis sternalis 62
Synchondrosis sternocostalis costae primae 95
Synchondrosis xiphosternalis 95
Syndesmologia 81
Syndesmosis 82
Syndesmosis radioulnaris 83
Syndesmosis tibiofibularis 88
Syndesmosis tympanostapedia 294
Synostosis 82
Synovia 34
Synovia 82
Systema 34
Systema digestorium 126
Systema lymphaticum 211
Systema musculorum 99
Systema nervorum 217
Systema nervorum centrale 218
Systema nervorum parasympathicum 276
Systema nervorum peripheric um 252
Systema nervorum sympathicum 271
Systema nervosum autonomicum 271
Systema respiratorium 142
Systema urogenitale 152
Systema vasorum 175

Tactus 34
Tactilis 34
Taenia 34
Taenia chorioidea 241
Taenia chorioidea thalami 234
Taeniae coli 137
Taenia fimbriae 241
Taenia fornicis 240
Taenia libera 137
Taenia mesocolica 137
Taenia omentalis 137
Taenia rhombencephali 224
Taeniae telarum 217
Taenia thalami 234
Taenia ventriculi quarti 224
Talus 54
Tapetum 243
Tarsus 54
Tarsus inf. (palpebrae) 283
Tarsus palpebrae 283
Tarsus sup. (palpebrae) 283
Tectorius 34
Tectum 34
Tectum mesencephali 229
Tegmen 34
Tegmen tympani 68
Tegmen ventriculi quarti 224
Tegmentum 34
Tegmentum 230
Tegmentum rhombencephali 221
Tela 34
Tela chorioidea partis lat. ventriculi telencephali 252
Tela chorioidea ventriculi quarti 252
Tela chorioidea ventriculi tertii 252
Tela conjunctiva 34
Tela elastica 34
Tela subcutanea 298
Tela submucosa 125
Tela submucosa (intestini crassi) 137
Tela submucosa (intestini recti) 137
Tela submucosa (intestini tenuis) 135
Tela submucosa (oesophagi) 133
Tela submucosa (pharyngis) 132
Tela submucosa (tracheae et bronchorum) 150
Tela submucosa (tubae uterinae) 162
Tela submucosa (ventriculi) 134
Tela submucosa (vesicae urinariae) 155
Tela subserosa (hepatis) 140
Tela subserosa (intestini crassi) 136
Tela subserosa (intestini tenuis) 134
Tela subserosa (peritonaei) 168
Tela subserosa (tubae uterinae) 154
Tela subserosa (uteri) 163
Tela subserosa (ventriculi) 134
Tela subserosa (vesicae felleae) 140
Tela subserosa (vesicae urinariae) 154
Telencephalon 236
Tempora 37
Tempora 78
Tendo 34

Tendo 99
Tendo calcaneus 110
Tendo cricoesophageus 133
Tendo m. tricipitis surae 110
Tensor 34
Tentorium 34
Tentorium cerebelli 250
Tenuis 34
Teres 34
Terminalis 34
Terminatio 34
Terminationes nervorum liberae 218
Termini ad extremitates spectantes 18
Termini ad membra spectantes 18
Termini ontogenetici 165
Testis 155
Thalamencephalon 233
Thalamus 233
Theca 34
Theca folliculi 161
Thenar 103
Thorax 34
Thorax 38
Thymus 173
Tibia 52
Tibialis 18
Tonsilla 34
Tonsilla cerebelli 228
Tonsilla lingualis 130
Tonsilla palatina 131
Tonsilla pharyngea 131
Tonsilla tubaria 131
Toruli tactiles 298
Torus 34
Torus intervenosus 178
Torus m. levatoris 131
Torus occipitalis 64
Torus palatinus 80
Torus tubarius 131
Trabecula 34
Trabeculae carneae 177
Trabeculae carneae 180
Trabeculae carneae atriorum 177
Trabeculae carneae ventriculorum 177
Trabeculae corporis spongiosi 159
Trabeculae corporum cavernosorum 159
Trabeculae lienis 141
Trabeculae septomarginalis 179
Trachea 38
Tracheae et bronchi 149
Tractus 34
Tractus 217
Tractus bulbo-thalamicus 248
Tractus centralis (thymi) 173
Tractus cerebello-nuclearis 247
Tractus cerebellorubralis 247
Tractus cerebello-tegmentalis 247
Tractus cerebello-thalamicus 247
Tractus corticis ad pontem 246
Tractus cortico-bulbaris 246
Tractus cortico-cerebellaris 246
Tractus cortico-habenularis 247
Tractus corticohypothalamici 247
Tractus cortico-mamillaris 247
Tractus corticopontini 231
Tractus corticospinales (pyramidales) 246
Tractus corticospinalis (pyramidalis) ant. 246
Tractus cortico-spinalis lat. 246
Tractus cortico-spinalis lat. (medullae spinalis) 220
Tractus corticospinalis (pyramidalis) lat. 246
Tractus cortico-spinalis ventralis 219
Tractus cortico-tectalis 246
Tractus cortico-tegmentalis 247
Tractus cortico-thalamici 245
Tractus cruralis transversus 247
Tractus dentatoolivaris 223
Tractus dorsolateralis (medullae spinalis) 220
Tractus fastigio-bulbaris 247
Tractus frontopontinus 246
Tractus geniculocorticalis (cochlearis) 245
Tractus geniculocorticalis (radiatio optica) 452
Tractus habenulointercruralis 247
Tractus habenulo-peduncularis 247
Tractus iliotibialis 108
Tractus lemnisci lat. (acustici) 249
Tractus lemnisci med. 249
Tractus longitudinalis med. 230
Tractus mamillotegmentalis 233
Tractus medullae spinalis 249
Tractus mesencephalicus n. trigemini 230
Tractus nervosi associationis 244
Tractus nervosi commissurales 245
Tractus nervosi projectionis 245
Tractus nucleo-cerebellaris 249
Tractus occipitopontinus 246
Tractus olfacto-habenularis 247
Tractus olfactohippocampicus 247
Tractus olfacto-mesencephalicus 247
Tractus olfactorius 242
Tractus olivocerebellares 247

Tractus olivocerebellaris 247
Tractus opticus 232
Tractus parietopontinus 246
Tractus ponto-cerebellares 247
Tractus pulvinocorticalis (radiationis opticae) 247
Tractus pyramidalis 231
Tractus pyramidalis (corticospinalis) ant. 219
Tractus pyramidalis (corticospinalis) lat. 220
Tractus reticulospinales 248
Tractus reticulospinalis (medullae spinalis) 220
Tractus rubrolemniscalis 248
Tractus rubro-reticularis 248
Tractus rubro-spinalis 248
Tractus rubrospinalis (medullae spinalis) 220
Tractus rubrothalamicus 248
Tractus solitarius 222
Tractus spinalis n. trigemini 222
Tractus spinobulbaris 248
Tractus spinocerebellaris ant. 220
Tractus spino-cerebellaris dorsalis 220
Tractus spinocerebellaris post. (medullae spinalis) 220
Tractus spino-cerebellaris ventralis 220
Tractus spino-olivaris 248
Tractus spino-tectalis 248
Tractus spinotectalis (medullae spinalis) 220
Tractus spino-thalamicus 248
Tractus spinothalamicus ant. (medullae spinalis) 219
Tractus spinothalamicus lat. (medullae spinalis) 220
Tractus spiralis foraminosus 290
Tractus supraopticohypophysialis 250
Tractus systematis nervorum centralis 244
Tractus tecto-bulbaris 248
Tractus tecto-spinalis 248
Tractus tectospinalis (medullae spinalis) 220
Tractus tegmentalis centralis 248
Tractus temporopontinus 246
Tractus thalamo-corticales 245
Tractus thalamo-habenularis 248
Tractus thalamo-olivaris 248
Tractus thalamo-spinalis 248
Tractus vestibulospinalis 219
Tractus vestibulo-spinalis 248
Tragus 296
Tragi (pili) 299
Transversalis 17
Transversus 17
Trigonum 34
Trigonum caroticum 304
Trigonum collaterale 241
Trigonum colli lat. 304
Trigonum deltoideopectorale 305
Trigonum femorale 109
Trigona fibrosa (cordis) 177
Trigonum habenulae 234
Trigonum inguinale 171
Trigonum lumbale 117
Trigonum mentale 77
Trigonum n. hypoglossi 224
Trigonum n. vagi 224
Trigonum olfactorium 242
Trigonum omoclaviculare 304
Trigonum retromolare (mandibulae) 77
Trigonum submandibulare 304
Trigonum subpineale 234
Trigonum vesicae 155
Triticeus 34
Trochanter major 52
Trochanter minor 52
Trochanter tertius 52
Trochlea 34
Trochlea humeri 46
Trochlea muscularis 99
Trochlea (m. obliqui oculi sup.) 282
Trochlea peronealis (fibularis) 56
Trochlea phalangis 48
Trochlea tali 55
Truncus 34, 37
Truncus brachiocephalicus 181
Truncus bronchomediastinalis (dexter) 211
Truncus caudalis (plexus brachialis) 263
Truncus celiacus 191
Truncus corporis callosi 240
Truncus costocervicalis 187
Truncus cranialis (plexus brachialis) 264
Truncus (fasciculi atrioventricularis) 177
Truncus intermedius (plexus brachialis) 264
Truncus intestinalis 211
Truncus jugularis 211
Truncus linguofacialis 182
Trunci lumbales 211
Truncus lumbosacralis 268
Truncus lymphaceus dexter 211
Truncus medius (plexus brachialis) 264
Trunci plexus (brachialis) 263
Truncus pulmonalis 181
Truncus subclavius 211
Truncus sympathicus 271
Truncus thyreocervicalis 187

Truncus vagalis ant. 262
Truncus vagalis post. 262
Tuba 34
Tuba auditiva 294
Tuba pharyngo-tympanica 294
Tuba uterina 161
Tuber 34
Tuber calcanei 55
Tuber cinereum 232
Tuber frontale 72
Tuber ischiadicum 50
Tuber maxillare 74
Tuber omentale (hepatis) 139
Tuber omentale (pancreatis) 138
Tuber ossis ischii 50
Tuber parietale 71
Tuber vermis 228
Tuberculum 34
Tuberculum adductorium 52
Tuberculum ant. (atlantis) 60
Tuberculum ant. thalami 234
Tuberculum ant. (vertebrarum cervicalium) 59
Tuberculum articulare 67
Tuberculum auriculae Darwini 296
Tuberculum caroticum (vertebrae cervicalis VI.) 59
Tuberculum cinereum 221
Tuberculun conoideum 45
Tuberculum corniculatum 147
Tubercula coronae dentis 128
Tuberculum costae 62
Tuberculum cuneiforme 147
Tuberculum epiglotticum 146
Tuberculum fibulare (processus proximalis tali) 55
Tuberculum fibulare tuberis calcanei 56
Tuberculum ilicum 49
Tuberculum infraglenoidale 44
Tuberculum intercondyloideum lat. 53
Tuberculum intercondyloideum med. 53
Tuberculum intervenosum 178
Tuberculum jugulare 63
Tuberculum majus 45
Tuberculum marginale 62
Tuberculum mentale 77
Tuberculum minus 45
Tuberculum nuclei cuneati 221
Tuberculum nuclei gracilis 221
Tuberculum obturatorium ant. 51
Tuberculum obturatorium ischiadicum 51
Tuberculum obturatorium post. 51
Tuberculum obturatorium pubicum 51
Tuberculum ossis multanguli majoris 47
Tuberculum ossis navicularis 47
Tuberculum ossis scaphoidei 47
Tuberculum ossis trapezii 47
Tuberculum partis lat. (fasciae dors. medullae oblongatae) 221
Tuberculum pharyngeum 63
Tuberculum post. (atlantis) 60
Tuberculum post. (vertebrarum cervicalium) 59
Tuberculum pubicum 50
Tuberculum rostrale (thalami) 234
Tuberculum scaleni 62
Tuberculum sellae 65
Tuberculum supraglenoidale 44
Tuberculum supratragicum 296
Tuberculum thyreoideum inf. 145
Tuberculum thyreoideum sup. 144
Tuberculum tibiale (processus proximalis tali) 55
Tuberculum tibiale tuberis calcanei 56
Tuberositas 34
Tuberositas coracoidea 44
Tuberositas costae II. 62
Tuberositas costalis (claviculae) 45
Tuberositas deltoidea 46
Tuberositas glutaea 52
Tuberositas iliaca 50
Tuberositas infraarticularis 44
Tuberositas infraglenoidalis 44
Tuberositas masseterica 77
Tuberositas m. serrati ant. 62
Tuberositas ossis cuboidei 57
Tuberositas ossis metatarsalis I. 57
Tuberositas ossis metatarsalis V. 57
Tuberositas ossis navicularis 56
Tuberositas phalangis distalis 48
Tuberositas pronatoria 46
Tuberositas pterygoidea 77
Tuberositas radii 46
Tuberositas sacralis 61
Tuberositas supraarticularis 44
Tuberositas supraglenoidalis 44
Tuberositas tibiae 53
Tuberositas tractus iliotibialis 52
Tuberositas ulnae 47
Tuberositas unguicularis 48
Tubulus 34
Tubuli contorti 155
Tubuli renales 153
Tubuli renales contorti 153
Tubuli renales recti 153

Tubuli seminiferi contorti 155
Tubuli seminiferi recti 155
Tubus 34
Tubus digestorius 133
Tunica 34
Tunica adventitia 125
Tunica adventitia (ductus deferentis) 156
Tunica adventitia (oesophagi) 133
Tunica adventitia (tubae uterinae) 161
Tunica adventitia (ureteris) 154
Tunica adventitia (vesicae seminalis) 157
Tunica albuginea corporis spongiosi 159
Tunica albuginea corporum cavernosorum 159
Tunica albuginea (lienis) 141
Tunica albuginea (testis) 155
Tunica conjunctiva 284
Tunica conjunctiva bulbi 284
Tunica conjunctiva palpebrarum 284
Tunica dartos 160
Tunica ext. (adventitia) (vasorum) 175
Tunica ext. oculi 277
Tunica ext. (thecae folliculi) 161
Tunica fibrosa 125
Tunica fibrosa bulbi 277
Tunica fibrosa (hepatis) 140
Tunica fibrosa (lienis) 141
Tunica fibrosa oculi 277
Tunica fibrosa renis 152
Tunicae funiculi spermatici et testis 157
Tunica int. bulbi 279
Tunica int. oculi 279
Tunica int. (thecae folliculi) 161
Tunica intima (vasorum) 176
Tunica media oculi 278
Tunica media (vasorum) 176
Tunica mucosa 125
Tunica mucosa cavi tympani 294
Tunica mucosa (ductus deferentis) 156
Tunica mucosa (intestini crassi) 137
Tunica mucosa (intestini recti) 137
Tunica mucosa (intestini tenuis) 135
Tunica mucosa (laryngis) 149
Tunica mucosa (linguae) 130
Tunica mucosa nasi 143
Tunica mucosa (oesophagi) 133
Tunica mucosa (oris) 126
Tunica mucosa (pharyngis) 132
Tunica mucosa (tracheae et bronchorum) 150
Tunica mucosa (tubae auditivae) 295
Tunica mucosa (tubae uterinae) 162
Tunica mucosa tympanica 294
Tunica mucosa (ureteris) 154
Tunica mucosa (urethrae muliebris) 165
Tunica mucosa (uteri) 163
Tunica mucosa (vaginae) 163
Tunica mucosa (ventriculi) 134
Tunica mucosa (vesicae felleae) 140
Tunica mucosa (vesicae seminalis) 157
Tunica mucosa (vesicae urinariae) 155
Tunica muscularis 125
Tunica muscularis cervicis (uteri) 162
Tunica muscularis (ductus deferentis) 156
Tunica muscularis (intestini crassi) 136
Tunica muscularis (intestini recti) 137
Tunica muscularis (intestini tenuis) 134
Tunica muscularis (oesophagi) 133
Tunica muscularis (tracheae et bronchorum) 149
Tunica muscularis (tubae uterinae) 162
Tunica muscularis (ureteris) 154
Tunica muscularis (urethrae muliebris) 165
Tunica muscularis (uteri) 163
Tunica muscularis (vaginae) 163
Tunica muscularis (ventriculi) 134
Tunica muscularis (vesicae felleae) 140
Tunica muscularis (vesicae seminalis) 157
Tunica muscularis (vesicae urinariae) 154
Tunica propria 34
Tunica propria (corii) 298
Tunica propria mucosae pharyngis 132
Tunica propria (tubuli seminiferi) 155
Tunica serosa 125
Tunica serosa (hepatis) 139
Tunica serosa (intestini crassi) 136
Tunica serosa (intestini tenuis) 134
Tunica serosa (lienis) 141
Tunica serosa (peritonaei) 168
Tunica serosa (tubae uterinae) 161
Tunica serosa (uteri) 163
Tunica serosa (ventriculi) 134
Tunica serosa (vesicae felleae) 140
Tunica serosa (vesicae urinariae) 138
Tunica submucosa (urethrae muliebris) 165
Tunica testis 157
Tunica vaginalis communis (testis et funiculi spermatici) 157
Tunica vaginalis propria testis 157
Tunica vasculosa bulbi 278
Tunica vasculosa oculi 278
Tympanum 35

Ulna 46
Ulnaris 18

Umbilicus 35
Umbilicus 39
Umbo 35
Umbo membranae tympani 292
Uncinatus 35
Uncus 35
Uncus gyri hippocampi 239
Ungues 299
Unguis 35
Urachus 154
Ureter 154
Urethra feminina 165
Urethra masculina 159
Urethra muliebris 165
Urethra virilis 159
Urina 35
Uterus 35
Uterus 162
Utriculus 35
Utriculus 285
Utriculus prostaticus 160
Uvula 35
Uvula (palatina) 130
Uvula (vermis) 228
Uvula vesicae 155

Vagina 35, 163
Vagina bulbi 283
Vagina carotica 121
Vagina ext. n. optici 251
Vaginae fasciculi optici 251
Vaginae fibrosae digitorum manus 104
Vaginae fibrosae digitorum pedis 112
Vagina fibrosa tendinis 99
Vagina int. (fasciculi optici) 251
Vagina int. n. opitici 251
Vagina m. recti abdominis 117
Vaginae mucosae (digitorum manus) 104
Vaginae mucosae (digitorum pedis) 112
Vagina mucosa intertubercularis 100
Vaginae n. optici 251
Vagina processus styloidei 69
Vaginae synoviales digitorum manus 104
Vaginae synoviales digitorum pedis 112
Vaginae synoviales tendinum 104
Vaginae synoviales tendinum digitorum 106
Vaginae synoviales tendinum (digitorum pedis) 112
Vagina synovialis communis mm. flexorum 106
Vagina synovialis intertubercularis 100
Vagina synovialis m. obliqui sup. 124
Vagina synovialis musculorum peroneorum (fibularium) communis 114
Vagina synovialis tendinis 99
Vagina synovialis tendinis m. flexoris carpi radialis 106
Vagina synovialis tendinis m. flexoris hallucis longi 114
Vagina synovialis tendinis m. tibialis post. 114
Vaginae synoviales tendinum digitorum pedis 115
Vagina synovialis trochleae 124
Vagina synovialis trochleae (m. bulbi) 282
Vaginae tendinum digitales 106
Vaginae tendinum digitales pedis 115
Vagina tendinum mm. abductoris longi et extensoris brevis pollicis 105
Vagina tendinis m. extensoris carpi ulnaris 106
Vagina tendinum mm. extensorum carpi radialium 105
Vagina tendinum mm. extensoris digitorum communis et extensoris indicis 105
Vagina tendinis m. extensoris digiti minimi 105
Vaginae tendinum m. extensoris digitorum pedis longi 114
Vagina tendinis m. extensoris hallucis longi 113
Vagina tendinis m. extensoris pollicis longi 105
Vagina tendinum musculorum fibularium communis 114
Vagina tendinis m. fibularis longi plantaris 115
Vagina tendinis m. flexoris carpi radialis 106
Vagina tendinum mm. flexorum communium 106
Vaginae tendinum m. flexoris digitorum pedis longi 114
Vaginae tendinum mm. flexorum digitorum pedis 114
Vagina tendinis m. flexoris hallucis longi 114
Vagina tendinis m. flexoris pollicis longi 106
Vagina tendinum mm. peronaeorum communis 114
Vagina tendinis m. peronaei longi plantaris 115
Vagina tendinis m. poplitei 113
Vagina tendinis m. tibialis ant. 113
Vagina tendinis m. tibialis post. 114
Vagina vasorum 176
Vagus 35
Vallecula 35
Vallecula cerebelli 227
Vallecula cerebri lat. 236
Vallecula epiglottica 132
Vallum 35
Vallum unguis 299
Valva 35

Valva atrioventricularis dextra 179
Valva atrioventricularis sinistra 180
Valva ileocecalis 136
Valva trunci pulmonalis 179
Valvula 35
Valvulae anales 138
Valvula a. pulmonalis 179
Valvula bicuspidalis (mitralis) 180
Valvula coli 136
Valvula foraminis ovalis 180
Valvula fossae navicularis 160
Valvula lymphatica 175
Valvula processus vermiformis 136
Valvula pylori 134
Valvula semilunaris ant. 179
Valvulae semilunares aortae 180
Valvulae semilunares (a. pulmonalis) 179
Valvula semilunaris dextra (aortae) 180
Valvula semilunaris dextra (a. pulmonalis) 179
Valvula semilunaris post. 180
Valvula semilunaris sinistra (a. pulmonalis) 179
Valvula semilunaris sinistra (aortae) 180
Valvula sinus coronarii 178
Valvula spiralis 141
Valvula tricuspidalis 179
Valvulae vasorum 176
Valvulae vasorum lymphaceorum 175
Valvula venae cavae inf. 178
Valvula venarum 176
Valvuli aortae 180
Vas 35
Vasa aberrantia hepatis 140
Vas afferens 153
Vasa afferentia (lgl.) 211
Vas anastomoticum 175
Vasa auris int. 288
Vas capillare 175
Vas collaterale 175
Vas communicans 175
Vas efferens 153
Vasa efferentia (lgl.) 211
Vasa labyrinthi 288
Vasa lymphacea 211
Vas lymphaticum 175
Vasa lymphatica 211
Vasa lymphatica profunda 211
Vasa lymphatica superficialia 211
Vas prominens 288
Vasa sanguinea retinae 280
Vas spirale 287
Vasa vasorum 176
Vascularis 35
Vastus 35
Vellus 35
Velum 35
Velum medullare ant. 224
Velum medullare inf. 224
Velum medullare post. 224
Velum medullare sup. 224
Velum palatinum 130
Velum semilunare dextrum 179
Velum semilunare dorsale 179
Velum semilunare sinistrum 179
Velum semilunare ventrale 180
Vena 35
Vena 175
Venae 198
Vv. adumbilicales 208
Vv. anales 209
V. anastomotica inf. 204
V. anastomotica sup. 204
V. angularis 201
Vv. anonymae dextra et sinistra 199
V. appendicularis 208
V. aqueductus cochleae 288
V. aquaeductus vestibuli 288
Vv. arciformes (renis) 154
Vv. articulares mandibulae 201
Vv. articulares temporomandibulares 201
Vv. auditivae internae 203
Vv. auriculares anteriores 201
V. auricularis post. 202
V. axillaris 202
V. azygos 205
V. basalis 205
V. basilica 202
Vv. basivertebrales 206
Vv. brachiales 202
V. *brachicephalica dextra et sinistra* 199
Vv. bronchiales anteriores 199
Vv. bronchiales posteriores 206
V. bulbi penis (vel vestibuli) 209
V. canaliculi cochleae 200
V. canaliculi vestibuli 288
V. canalis pterygoidei 200
V. cava inf. 207
V. cava sup. 199
Vv. cavernosae (penis) 159
Vv. centrales (hepatis) 140
V. centralis (gl. suprarenalis) 173
V. centralis retinae 205
V. cephalica 202

V. cephalica accessoria 202
Vv. cerebelli inferiores 204
Vv. cerebelli superiores 204
Vv. cerebri 204
Vv. cerebri inferiores 204
Vv. cerebri internae 204
V. cerebri magna 205
V. cerebri med. 204
Vv. cerebri superiores 204
V. cervicalis profunda 199
V. chorioidea 205
Vv. chorioideae minores 205
Vv. ciliares anteriores 205
Vv. ciliares posteriores 205
Vv. circumflexae femoris laterales 210
Vv. circumflexae femoris mediales 210
V. circumflexa ilium profunda 209
V. circumflexa ilium superficialis 210
Vv. colicae dextrae 208
V. colica media 208
V. colica sinistra 208
V. comitans 175
Vv. comitantes 210
V. comitans n. hypoglossi 200
Vv. conjunctivales anteriores 205
Vv. conjunctivales posteriores 205
Vv. cordis 199
Vv. cordis anteriores 199
V. cordis magna 199
V. cordis media 199
Vv. cordis minimae 199
V. cordis parva 199
V. coronaria ventriculi 208
Vv. corticales radiatae (renis) 154
Vv. costoaxillares 202
V. cutanea 175
V. cystica 208
Vv. digitales communes pedis 210
Vv. digitales palmares 203
Vv. digitales pedis dorsales 211
Vv. digitales plantares 211
Vv. digitales volares communes 203
Vv. digitales volares propriae 203
Vv. diploicae 204
V. diploica frontalis 204
V. diploica occipitalis 204
V. diploica temporalis ant. 204
V. diploica temporalis post. 204
V. dorsalis clitoridis 209
Vv. dorsales linguae 200
V. dorsalis penis 209
Vv. dorsales penis subcutaneae 209
Vv. duodenales 208
V. emissaria 175, 204
V. emissaria condylaris 204
V. emissaria mastoidea 204
V. emissaria occipitalis 204
V. emissaria parietalis 204
Vv. encephali 204
V. epigastrica inf. 209
V. epigastrica sup. 200
V. epigastrica superficialis 210
Vv. episclerales 205
V. ethmoidalis ant. 205
V. ethmoidalis post. 205
V. facialis ant. 201
V. facialis communis 201
V. facialis post. 201
V. faciei profunda 201
V. femoralis 209
V. femoropoplitea 210
Vv. fibulares 210
Vv. frontales 201
Vv. gastricae breves 208
V. gastrica dextra 208
V. gastrica sinistra 208
V. gastroepiploica dextra 208
V. gastroepiploica sinistra 208
Vv. genus 210
Vv. glutaeae inferiores 208
Vv. glutaeae superiores 208
Vv. haemorrhoidales inferiores 209
V. haemorrhoidalis media 209
V. haemorrhoidalis sup. 208
V. hemiazygos 205
V. hemiazygos accessoria 205
Vv. hepaticae 207
V. hypogastrica 208
V. ileocolica 208
V. iliaca communis 208
V. iliaca ext. 209
V. ilica int. 208
V. iliolumbalis 208
Vv. intercapitulares (manus) 203
Vv. intercapitulares (pedis) 211
Vv. intercostales 205
Vv. intercostales anteriores 200
Vv. intercostales post. 206
V. intercostalis sup. dextra 206
V. intercostalis sup. sinistra 200
V. intercostalis suprema 200
Vv. interlobares (renis) 154

Vv. interlobulares (hepatis) 140
Vv. interlobulares (renis) 154
V. interventricularis dorsalis cordis 199
Vv. intervertebrales 206
Vv. intestinales 208
Vv. jejunales et ilei 208
V. jugularis ant. 202
V. jugularis ext. 202
V. jugularis int. 200
Vv. jugulares superficiales 202
V. jugularis superficialis dorsalis 202
V. jugularis superficialis ventralis 202
Vv. labiales 209
V. labialis inf. 201
V. labialis sup. 201
Vv. labyrinthi 203
V. lacrimalis 205
V. laryngea inf. 199
V. laryngea sup. 200
V. lienalis 208
V. lingualis 200
Vv. lumbales 207
Vv. lumbales (I. et II.) 206
V. lumbalis ascendens 206
V. mammaria int. 199
Vv. massetericae 201
Vv. maxillares 201
V. mediana antibrachii 202
V. mediana basilica 202
V. mediana cephalica 202
V. mediana colli 202
V. mediana cubiti 202
Vv. mediastinales 206
Vv. mediastinales anteriores 199
Vv. meningeae 200
Vv. meningeae mediae 201
V. mesenterica inf. 208
V. mesenterica sup. 208
Vv. metacarpeae dorsales 203
Vv. metacarpeae palmares 203
Vv. metacarpeae volares 203
Vv. metatarseae dorsalis pedis 211
Vv. metatarseae plantares 211
Vv. musculares (v. ophthalmicae) 205
Vv. musculophrenicae 200
Vv. nasales externae 201
Vv. nasales internae 201
V. nasofrontalis 205
V. obliqua atrii sinistri 199
Vv. obturatoriae 208
V. occipitalis 202
Vv. oesophageae (v. anonymae) 199
Vv. oesophageae (v. azygos) 206
V. ophthalmica inf. 205
V. ophthalmica sup. 205
V. ophthalmomeningea 205
V. ovarica 207
V. palatina 201
Vv. palpebrales 205
Vv. palpebrales inferiores 201
Vv. palpebrales superiores 201
Vv. pancreaticae 208
Vv. pancreaticoduodenales 208
Vv. parotideae anteriores 201
Vv. parotideae posteriores 201
Vv. parumbilicales 208
Vv. pectorales 202
Vv. perforantes 210
Vv. pericardiacae 199
Vv. pericardiacophrenicae 199
Vv. peronaeae 210
Vv. pharyngeae 200
V. phrenica abdominalis 207
V. phrenica inf. 207
Vv. phrenicae superiores 199
Vv. phrenicae sup. 206
Vv. phrenicae thoracicae 199
Vv. popliteae 210
V. portae 207
V. post. ventriculi sinistri 199
Vv. praeauriculares 201
V. prepylorica 208
Vv. profundae clitoridis 209
Vv. profundae femoris 210
V. profunda linguae 200
Vv. profundae penis 209
V. pudenda int. 209
Vv. pudendae externae 210
Vv. pulmonales 198
Vv. pulmonales dextrae 198
Vv. pulmonales sinistrae 198
Vv. radiales 202
Vv. rectales inferiores 209
Vv. rectales mediae 209
V. rectalis cranialis 208
Vv. renales 207
Vv. renis 154
V. retroauricularis 202
V. retromandibularis 201
V. sacralis caudalis 208
Vv. sacrales laterales 209
V. sacralis media 208

V. saphena accessoria 210
V. saphena magna 210
V. saphena parva 210
V. scapularis dorsalis 202
Vv. scrotales anteriores 210
Vv. scrotales posteriores 209
V. septi pellucidi 205
Vv. sigmoideae 208
V. spermatica 207
Vv. spinales externae anteriores 206
Vv. spinales externae posteriores 206
Vv. spinales internae 206
V. spiralis modioli 288
Vv. stellatae 154
V. sternocleidomastoidea 200
V. stylomastoidea 201
V. subclavia 202
V. subcostalis 205
Vv. subcutaneae abdominis 200
V. sublingualis 200
V. submentalis 201
V. supraorbitalis 201
Vv. suprarenales 207
V. *suprascapularis* 202
Vv. supratrochleares 201
Vv. temporales profundae 202
Vv. temporales superficiales 201
V. temporalis media 201
V. terminalis 205
V. testicularis 207
V. thalamostriata 205
V. thoracalis lat. 202
V. thoracica int. 199
Vv. thoracicae longitudinales 206
V. thoracica longitudinalis dextra 205
V. thoracica longitudinalis sinistra 205
V. thoracica longitudinalis sinistra accessoria 205
V. thoracoacromialis 202
Vv. thoracoepigastricae 202
Vv. thymicae 199
V. thyreoidea ima 199
Vv. thyreoideae inferiores 199
V. thyreoidea sup. (v. facialis) 202
Vv. thyreoideae superiores (v. jugularis int.) 200
Vv. thyroideae mediae 200
Vv. tibiales anteriores 210
Vv. tibiales posteriores 210
Vv. tracheales 199
Vv. transversae colli 202
V. transversa faciei 201
V. transversa scapulae 202
Vv. tympanicae 201
Vv. ulnares 202
V. umbilicalis 207
Vv. uterinae 209
V. vertebralis 199
V. vertebralis accessoria 199
Vv. vesicales 209
Vv. vestibulares 288
Vv. vorticosae 205
Venter 35
Venter ant. (m. digastrici) 120
Venter frontalis (m. occipitofrontalis) 122
Venter inf. (m. omohyoidei) 121
Venter mandibularis (m. digastrici) 120
Venter mastoideus (m. digastrici) 121
Venter occipitalis (m. occipitofrontalis) 122
Venter post. (m. digastrici) 121
Venter sup. (m. omohyoidei) 121
Ventralis 17
Ventriculus 35
Ventriculus 133
Ventriculus cordis 177
Ventriculus dexter 178
Ventriculus laryngis 148
Ventriculus lat. 241
Ventriculus quartus 223
Ventriculus sinister 180
Ventriculus telencephali 241
Ventriculus terminalis 218
Ventriculus tertius 232
Venula 35
Venula 175
Venulae rectae medullares 154
Venulae rectae (renis) 154
Vermis 35
Vermis 227
Vertebra 35
Vertebrae 58
Vertebrae caudales 60
Vertebrae cervicales 59
Vertebrae coccygeae 60
Vertebrae lumbales 60
Vertebra prominens 59
Vertebrae sacrales 60
Vertebrae thoracales 59
Vertex 35, 78
Vertex corneae 278
Vertex vesicae 154
Verticalis 17
Verus 35
Vesica 35

Vesica fellea 140
Vesicalis 35
Vesica urinaria 154
Vesicula 35
Vesicula ophthalmica 277
Vesicula seminalis 157
Vestibularis 35
Vestibulum 35, 288
Vestibulum bursae omentalis 169
Vestibulum laryngis 148
Vestibulum nasi 142
Vestibulum oris 126
Vestibulum vaginae 164
Vestigium 35
Vestigium processus vaginalis 157
Vibrissae 299
Villus 35
Villi articulares 82
Villi intestinales 135
Villi pleurales 152
Villi synoviales 82
Vinculum 35
Vinculum 99
Vincula lingulae (cerebelli) 227
Vinculum tendinum 104
Viscus (viscera) 35
Visus 35
Vita 35
Vitellus 35
Vitreus 35
Vocalis 36
Vola 36
Vola manus (Palma) 40
Volaris 18
Vomer 73
Vortex 36
Vortex coccygeus 299
Vortex cordis 177
Vortices pilorum 299
Vorticosus 36
Vulva 36

Xiphoideus 36

Zona 36
Zona hemorrhoidalis 138
Zona incerta 235
Zona orbicularis 87
Zonula 36
Zonula ciliaris 282
Zygomaticus 36

FROM THE REVIEWS OF THE GERMAN EDITION

". . . This book should be in the possession of all serious-minded anatomists and available in all anatomical, and indeed medical, libraries. The author is to be complimented on the very considerable task which he has accomplished so accurately."

JOURNAL OF ANATOMY, London

". . . It is a valuable and useful work for all anatomists and clinicians who can read German."

EXCERPTA MEDICA, Amsterdam

". . . Das Buch nimmt somit in der Reihe der Wörterbücher der Medizin eine Sonderstellung ein und wird nicht nur für den Studenten und den praktischen Arzt, sondern besonders auch für den wissenschaftlich tätigen Arzt ein ausgezeichnetes Nachschlagewerk sein."

DEUTSCHE ZAHN-, MUND- UND KIEFERHEILKUNDE, Leipzig

"E' un completo dizionario di termini anatomici, di utile e facile consultazione."

MINERVA MEDICA, Torino

Distributors
KULTURA
Budapest 62. P.O.B. 149