AMBRUS ÁBRAHÁM

Microscopic Innervation of the Heart and Blood Vessels in Vertebrates Including Man

Akadémiai Kiadó, Budapest

A. ÁBRAHÁM

MICROSCOPIC INNERVATION OF THE HEART AND BLOOD VESSELS IN VERTEBRATES INCLUDING MAN

In the first part of the monograph the author discusses the structure and the microscopic innervation of the different layers of the heart wall in fishes, amphibians, reptiles, birds, mammals and man. The heart receptors of the dog, fox, cat, horse, pig, sheep and cattle are treated in detail. The second part deals with the innervation of arteries, veins and capillaries. After the description of the baroreceptors of the aortic arch, carotid sinus, carotid arteries and of the pulmonary artery, the correlation between hypertension and baroreceptors, as well as the chemoreceptors of birds, mammals and man are discussed. Separate chapters are devoted to the innervation of the coronary, renal and cerebral arteries and veins. The work is based on the author's own investigations; the drawings and photographs are original.



AKADÉMIAI KIADÓ
PUBLISHING HOUSE OF THE HUNGARIAN ACADEMY OF SCIENCES
BUDAPEST

MICROSCOPIC INNERVATION OF THE HEART AND BLOOD VESSELS IN VERTEBRATES INCLUDING MAN

MICROSCOPIC INNERVATION OF THE HEART AND BLOOD VESSELS IN VERTEBRATES INCLUDING MAN

A. ÁBRAHÁM
Member of the Hungarian Academy of Sciences



AKADÉMIAI KIADÓ · BUDAPET 1969

Title of the origina

DIE MIKROSKOPISCHE INNERVATION DES HERZENS UND DER BLUTGEFÄSSE VON VERTEBRATEN
published by Akadémiai Kiadó, Budapest

English translation by

S. KOCH

© Akadémiai Kiadó, Budapest 1969

Joint edition published by Akadémiai Kiadó, Budapest
and
Pergamon Press, Oxford

Printed in Hungary

FOREWORD

THOUGH we feel it an honour to write a Foreword for this remarkable book, it is at the same time a pleasure.

Professor Ábrahám is justly renowned for his authoritative contributions to the literature of cardiovascular neurohistology and the present volume speaks for itself in this respect. It provides an enormous mass of information on the details of autonomic innervation of the heart and blood vessels in vertebrates, copiously illustrated by photomicrographs and by drawings made in his laboratory from his own material. The amazing details of the ramifications of the vagal sensory fibres in the aortic arch and of those of the glossopharyngeal nerve in the carotid glomus are revealed by the use of thick sections cleared by a superb histological technique. If the book provided no more than this it would still represent a notable addition to the histological literature.

Additionally, however, the author discusses his various anatomical findings in the light of their physiological importance, proved or possible, and this will ensure that the book will command a wide spectrum of readers. Cross-pollination between physiologists and histologists has always been profitable. Sometimes the functional studies have indicated the need for further histological investigations as exemplified by the results of Cyon and Ludwig on the effects of stimulating the vagal depressor nerve in 1866, which led eventually to the demonstration of the site of the relevant nerve endings in the aortic arch by Köster and Tschermak in 1902. De Castro, on the other hand, from his examination of the fine details of innervation of the carotid body was the first to suggest that the glomus mechanism might subserve a chemoreceptor function and this was proved shortly afterwards by the physiological studies in the Gent laboratory. The moral is clear — structural and functional studies should desirably continue side by side, a fact realized as long ago as 1865 by Carl Ludwig in designing his Physiological Institute. In this respect Professor Ábrahám's book not only provides a general review of the subject, but also gives many clues for future experimental investigations in the physiological laboratory. To mention only two, the presence of baroreceptors in the renal artery and the details of innervation of the coronary sinus will stimulate the imagination of those working on the control of these respective circulations. We wish the book every success.

C. HEYMANS and E. NEIL

Farmakologisch & Terapeutisch Instituut
der Rijksuniversiteit, Gent, and
Department of Physiology, Middlesex
Hospital Medical School, London, W. 1

CONTENTS

Preface to the English Edition	XI
Preface to the German Edition	XII
Introduction	XIII
1. MATERIAL AND METHODS	1
Vital Staining with Methylene Blue	1
Bielschowsky–Gros' Method	2
Bielschowsky–Ábrahám's Procedure	4
Ábrahám's Procedure	5
Bielschowsky–Gros–Cauna's Procedure	5
2. INNERVATION OF THE HEART	7
Bony Fishes	7
Venous Sinus	9
Atrium	12
Atrioventricular Funnel	15
Ventricle	17
Arterial Bulb	18
Nerve Endings of the Myocardium	18
Ganglia	19
Amphibia	22
Venous Sinus	23
Atrium	25
Atrial Septum	26
Ventricle	34
Heart Bulb	37
Nerve Endings of the Myocardium	39
Origin of the Intracardiac Nerve Fibres	39
Ganglia	41
Pericardium	43
Reptiles	43
Venous Sinus	45
Atrium	47
Atrial Septum	50
Ventricle	51
Nerve Endings of the Myocardium	55
Ganglia	57
Birds	64
Atrium	65
Atrial Septum	70

Ventricle 70
Ventricular Septum 73
Muscular Valve 74
Nerve Endings of the Myocardium 78
Stimulus-conducting System 79
Localization of Acetylcholinesterase Activity in the Stimulus-conducting System 83
Ganglia 84
Mammals 85
Historical 85
Anatomy of Heart Nerves 86
The Sympathetic Nerve Supply of the Heart 86
The Vagal Nerve Supply of the Heart 88
Cardiac Plexus 88
Histology of the Cardiac Nerves 89
Atrium 90
Atrial Septum 97
Ventricle 99
Ventricular Septum 104
Stimulus-conducting System 105
Historical 105
Sinoatrial System 108
Histology of the Sinoatrial System 109
Innervation of the Sinoatrial Node 111
Atrioventricular System 115
Histology of the Atrioventricular System 116
Innervation of the Atrioventricular System 120
Localization of Acetylcholinesterase in the Stimulus-conducting System 128
Sinoatrial Node 128
Aschoff–Tawara Nodule 130
His' Bundle 130
Nerve Endings in the Myocardium 133

3. RECEPTORS OF THE HEART 135

Epicardial Receptors 135
Myocardial Receptors 137
Endocardial Receptors 139
Dog 139
Fox 139
Cat 143
Horse 148
Pig 150
Sheep 150
Calf 153
Phylogenetic Aspects of Receptors 157
Origin of the Intracardial Nerve Fibres 159
Efferent Fibres 159
Afferent Fibres 160

Ganglia 161
Valves 172
Pericardium 173

4. INNERVATION OF BLOOD VESSELS 174

Historical 174
Arteries 177
Innervation of the Arteries 178
Tunica Adventitia 194
Tunica Media 196
Tunica Intima 200
Veins 201
Arteriovenous Anastomoses 204
Capillaries 206
Nerve Cells in the Vessel Walls 209
Receptors in the Vessel Walls 210
Pressoreceptors 211
Aortic Arch 211
Birds 211
Mammals 214
Dog 215
Pig 218
Calf 233
Buffalo 254
Goat 255
Sheep 257
Man 260
Pathological Alterations in Human Aortic Fibres 269
Cholinesterase Activity in the Aortic Arch 273
Carotid Sinus 275
Birds 275
Mammals 278
Dog 278
Pig 279
Horse 281
Calf 283
Sheep 285
Man 286
Pathological Alterations of the Sensory Nerve Fibres of the Human Carotid Sinus 301
Common Carotid Artery 304
External Carotid Artery 306
Internal Carotid Artery 306
Pulmonary Artery 306
Are there Interstitial Cells Present in the Reflexogenic Areas? 310
Baroreceptors and Hypertension 311
Pressoreceptors and Phylogenesis 316

5. CHEMORECEPTORS 319

Glomus Caroticum 319
Birds 319
Mammals 321
Dog 324
Man 325
Accessory Glomera 338
Birds 339
Mammals 340
Man 341
Innervation of the Heart Vessels 342
Coronary Vessels 342
Coronary Arteries 342
Sinus Coronarius Cordis 349
Vena Cordis Magna 353
Intracardial Vessels 357
Innervation of Renal Vessels 357
Renal Arteries 358
The Juxtaglomerular Apparatus 363
Renal Veins 364
Renal Capillaries 365
Innervation of Cerebral Vessels 365
Cerebral Arteries 367
Cerebral Veins 372
Cerebral Capillaries 373
References 374
Author Index 413
Subject Index 416

PREFACE TO THE ENGLISH EDITION

THIS WORK is essentially the English translation of the monograph entitled *Die mikroskopische Innervation des Herzens und der Blutgefässe von Vertebraten* published in 1964. There are, of course, small changes in it, concerning the figures as well as the text. The number of figures has been increased by five, and some of the old ones are replaced by new ones. I inserted also the description of my new silver impregnation method, and on the basis of my new investigations I completed the data concerning the human carotid sinus and significantly amplified the chapter dealing with the structure and innervation of the human carotid body. New chapters deal with "Baroreceptors and Hypertension" and with the carotid body of the dog. The references are completed by papers recently published.

Szeged, 16th July 1968 THE AUTHOR

PREFACE TO THE GERMAN EDITION

I HAVE devoted more than 35 years to the investigation of the nervous system's histological structure. My studies were first concerned with the nervous system of worms, crustaceans and molluscs. Later, I examined the structure of the endings innervating the skin, the sensory organs, the intestines, respiratory organs, endocrine glands, cardiovascular system and excretory organs in vertebrates. Of course, I have also investigated other organs and organ systems such as the autonomic ganglia, the interneuronal synapses and the central nervous system of insects. My most detailed investigations have been concerned with the structure of the receptors and the comparative histology of the autonomic nervous system. These are especially the areas, whose problems interest me, in which I see — mainly for comparative aims — further the solution of conspicuous tasks. Nevertheless, my preferential field has been the clarification of the nerve connections in the cardiovascular system. Consequently, the aim of this work has been to elucidate and elaborate monographically just this topic on the basis of comparison.

In preparing this volume I have relied much on the assistance of my co-workers particularly Dr. Aranka Stammer, Dr. I. Horváth, Dr. L. Erdélyi and Miss Mária Fischer. The illustrations have been prepared by Miss Erzsébet Dános and Dr. Géza Mráz. I am indebted to all of them for their valuable contribution.

I offer this book to all readers interested in the cardiovascular system with the sincere wish to contribute to their knowledge on that vitally important organ system as well as to those seeking further information on the structure and forms of connection of the autonomic nervous system.

Szeged, 20th June 1964 THE AUTHOR

INTRODUCTION

My investigations on the innervation of the cardiovascular system were started with the examination of the nervous connections in the myocardium. These studies were later extended also to the relations of the myocardial conductive system and the nervous system. Then I focused my interest on the innervation of blood vessels and dwelt on this topic for more than 20 years. The primary aim of these studies has been to clarify the general aspects of the nervous connections between blood vessels of different structure and function. The next step was the structural study of pressoreceptors and chemoreceptors. Of these the pressoreceptors have been examined in more detail, aiming at a precise description of relations in the carotid sinus and aorta of man and various mammals. Parallel to this, systematic examinations have been conducted, particularly during the recent years, on cardiac innervation in man and various vertebrates. Part of these studies has been reported in different periodicals both at home and abroad. Since the published material, completed with the more recent results obtained in the meantime, has enabled a comprehensive presentation of the information collected on the innervation of the above organs, I felt entitled to compile this monograph in order to make available the data in a concise, organized form. Relying on a large number of publications, several thousands of preparations and manifold investigations, I hope to have been able to present a realistic description of the microscopy of cardiovascular innervation in vertebrates, throwing simultaneously a light also on some evolutionary aspects. This volume is based mainly on my own experience, information from the relevant literature of the world being included only when I was sure of its proper appreciation of the topic's significance. The scarcity of the references made is accounted for by the fact that, using the most up-to-date facilities in my examinations, it is my conviction that they reflect the actual relations as truly as possible and as such may convey a deeper understanding of established facts than the presentation of often controversial or even deficient data. On the other hand, a detailed bibliography and a critical evaluation of the relevant literature would have added too much to the bulk of this volume. The illustrations, including more than 200 drawings and photographs, are all original, made from preparations in our own collection.

1. MATERIAL AND METHODS

THE present studies have been extended to all taxonomic classes of vertebrates and also to man. Studies have been performed mainly on species easily accessible in this country while materials from several representative species have been supplied from the Budapest Zoo. For the latter, the author is indebted to Dr. Cs. Anghy, Director of the Zoo. Human material was obtained from the Institute of Pathological Anatomy, University Medical School, Szeged, State Hospital, Gyöngyös, and the MÁV Hospital, Budapest, for which the author pays tribute to the late Professor B. Korpássy and offers his sincere thanks to the Chief Pathologist, H. Csermely.

Two main histological staining procedures were used throughout, viz. vital staining with methylene blue and silver impregnation. Of the former, a technique adapted by myself mainly to frogs, and Schadabasch's procedure, known from microtechnical literature and applied by now all over the world, deserve special mentioning. For impregnation with silver, different modifications of Bielschowsky's method as suggested by Gros, Ábrahám, Jabonero and Cauna were found to be most suitable. Further to these, also the techniques proposed by Bodian, Ranson, Romanes and Ramón y Cajal — the latter in modification No. 4 — were used.

VITAL STAINING WITH METHYLENE BLUE

I have tried a wide variety of methods available for vital staining with methylene blue until I finally developed the one described below and used mainly for studies on the green toad. The toad was narcotized with ethylether and given intra-abdominally a large amount of 0·5 per cent (or still more dilute) solution of methylene blue in distilled water. Then the animal was bled by decapitation. About 6 hr later the abdomen was laid open and the organs exposed to the air. By that time methylene blue had usually intensively stained the nerves of not only the skin but also of the cardiovascular system, muscles and other organs. Both macroscopic total preparations and histological sections stained by the above method revealed particularly clearly the morphological details of cardiovascular innervation. Total preparations were used to obtain a gross view but the microscopic structures were examined in histological sections prepared from embedded or frozen specimens. Certain areas of such sections may occasionally exhibit some remarkably fine details. Nevertheless, they are in general not satisfactory for a thorough study of the nervous system's microscopic structure.

Of all methods of vital staining with methylene blue the one described by Schadabasch proved to be the best in our hands. This procedure would reveal the

most minute details, sometimes even very fine terminal ramifications of the end plates, although it definitely fails to permit the study of the specialities of nerve fibre endings.

BIELSCHOWSKY–GROS' METHOD

The method of Bielschowsky and Gros has been applied very successfully in our studies. Its description, including some of our own improvements and modifications is presented below.

1. The specimen is fixed in 10 or 20 per cent neutral formalin for at least 1 week. Prolonged fixation improves rather than impairs the preparation's quality, particularly with tissues of compact structure like blood vessels, skin, smooth muscle, ligaments and sensory organs. For fixation, smaller specimens should be preferably used, though after prolonged treatment even large ones would yield good impregnated preparations. It should be noted that excellent neurohistological preparations were frequently obtained from materials fixed in non-neutral formalin for several months.

2. The appropriately fixed specimen was washed first in running tap water for 1–2 hr then in distilled water for a similar period. This was followed by freezing and sectioning. In general, sections of 40 μ thickness were found to be the most appropriate ones. These permitted namely an *in toto* study of nerve fibres together with their ramifications, endings and arborizations and connections with the ganglia and individual nerve cells. For a detailed analysis of the closer relations and connections between the nervous system and a given tissue the preparation of thinner sections was, however, required, whereas the elucidation of some more general relations could be best achieved in thicker sections. The frozen sections were placed in distilled water.

3. The sections were kept in distilled water for 1–2 hr and subsequently placed in a 20 per cent silver nitrate solution for 1 hr or longer. According to our own experience, 2–3 hr are usually enough to obtain a satisfactory impregnation even of very compact tissues, for example skin, tunica media of blood vessels, tunica muscularis of the intestines, etc. The sections may, however, be kept in silver nitrate for even longer periods, if required.

4. After treatment with silver nitrate, the sections were placed in a 20 per cent solution of neutral formalin (80 ml tap water + 20 ml neutral formalin). Formalin treatment is continued until the formation of a white mist-like precipitate is no longer observable upon repeated transfers of the section into fresh formalin solution. For the transfer of sections an appropriate capillary glass loop seems to be the most handy tool. Formation of the precipitate is readily observable if a Petri dish, a watch glass or other appropriate flat containers are used for bathing in the 20 per cent formalin solution. In general, three transfers will do; when not, a fourth one should be additionally performed, a thorough extraction of excess silver nitrate being essential. The procedure is relatively simple and even beginners will soon realize its most critical points. Three baths, viz. on a total 10 min of formalin

treatment, will generally result in satisfactory extraction of excess silver nitrate from all but the nervous tissue in the section.

5. The last treatment with 20 per cent formalin being completed, the section is rinsed briefly in tap water as suggested by Hachiro–Seto. This serves to avoid precipitate formation in the silver nitrate–ammonia solution used as the next bath for the section.

Rinsing in distilled water prior to formalin treatment has been suggested by several authors. As to the duration of treatment with distilled water, Reiser proposed a few seconds, whereas Seto 30 min. In our opinion, although both methods are economical in the use of formalin, they do not possess any special advantage.

6. The silver nitrate–ammonia solution is prepared as follows: To 5 ml of a 20 per cent silver nitrate solution are added a few drops of a 25 per cent ammonia solution. Upon mingling, a brownish precipitate forms. To the precipitate, ammonia is added dropwise until it dissolves completely. Usually a deposit of dark granules forms at the bottom which, however, do not interfere with the mechanism and success of impregnation. To the silver nitrate–ammonia solution thus prepared, one drop of ammonia is added per millilitre on a watch glass.

7. From the 20 per cent formalin solution the section is transferred by means of a glass rod into the silver nitrate–ammonia solution and allowed to stand therein until the nerve cells, fibres and endings assume a full black colour. Impregnation takes usually a very short time. Thus the whole process may be observed under the microscope at a low magnification. Should the impregnation also involve the nuclei and connective tissue fibres, the section is discarded and additional ammonia added to the solution in a quantity of three drops per 2 ml. A fresh section is then placed in the solution and observed. As soon as a complete impregnation of nerve fibres and nerve endings takes place, the section is transferred to ammonia-water.

8. Ammonia-water is prepared by adding 2 ml of ammonia to 8 ml distilled water. In this solution the section is allowed to stand for 1 min.

9. From ammonia-water the section is transferred to distilled water to which 2 to 3 drops of glacial acetic acid have been added per 10 ml.

10. After being washed thoroughly in distilled water for at least 1 hr, the preparation is ready for mounting. It is, however, greatly recommended to apply gold treatment first, as it markedly improves the quality of the preparation.

11. For this purpose, 2 to 3 drops of a 1 per cent gold chloride solution are added per 10 ml of distilled water. The sections are kept in this solution until their original yellow–brown colour turns to a pale greyish-violet shade. Usually half an hour has been sufficient to assume the desired hue.

12. Sections are placed in an 0·5 per cent sodium thiosulphate solution, the thinner ones for 30–40 sec, while thicker ones for 1–2 min. Subsequently they are washed thoroughly in distilled water, then dehydrated and, after clearing in xylol, mounted with Canada balsam. In this laboratory, after removal from the 20 per cent silver nitrate solution the sections are treated further *en masse* and not individually. Thus, no further microscopy is required and also the success of impregnation is greatly promoted.

BIELSCHOWSKY–ÁBRAHÁM'S PROCEDURE

Bielschowsky's method, as modified by Ábrahám, proved to be very helpful for the examination of heart and vessels. The modified procedure is the following:

1. The specimen is fixed in 10 per cent formalin. For this purpose, acid-free formalin should preferably be used, though numerous experiences have shown that excellent preparations are obtainable also from specimens fixed in acid formalin for several months. Usually fixation for 2 or 3 weeks would suffice, yet results are more reliable when the specimen is kept in the fixing fluid for several months or even for a year.

2. The fixed material is washed in distilled water for 10–15 min, then sections are cut with a freezing microtome. Direction of cutting as well as the thickness of sections should be adjusted to the aims of the actual examination. With vessels, tangential sections are most frequently made so as to include the adventitia, that is its portion adjacent to the media itself, showing as great an area of them as possible. With such sections a thickness of 40 μ would do. The sections are placed in distilled water and allowed to stand therein for 6–8 hr or longer.

3. The sections are transferred into a 10 per cent silver nitrate solution and kept there in the dark at room temperature for 60–70 hr.

4. The sections are removed from the silver nitrate solution with an appropriately tipped glass rod, washed quickly in distilled water and placed in silver nitrate–ammonia solution.

5. Silver nitrate–ammonia solution is prepared by adding 3 drops of fresh 40 per cent sodium hydroxide solution to 5 ml of a 20 per cent silver nitrate solution. To the precipitate formed a 25 per cent ammonia solution is added dropwise until the liquid turns perfectly clear. Occasionally it would remain slightly opaque, without, however, interfering with impregnation. Subsequently, 20 ml of distilled water are added to the solution. Then the sections are placed therein and allowed to stand until assuming a tobacco-brown hue. According to our own experience this takes 3–4 min. Afterwards the sections are transferred into the next bath.

6. Fifty millilitres of distilled water + 3 drops of glacial acetic acid. In this bath the sections are kept for 1½ min or somewhat longer.

7. Reduction in formalin. The reducing liquid is prepared from 85 ml tap water and 15 or, if required, 20 ml of neutral formalin. In this medium the sections are kept until they emit white clouds. The reduction usually occurs in 20 min but sometimes may even take 1 hr. Recently it has been found that impregnation will be better when from the misty formalin the sections are transferred into a second, perhaps even a third bath and exposed to light. For this purpose both natural and artificial illumination may be used. After reduction is completed the sections are placed in excess distilled water and allowed to stand therein for at least 1 hr.

8. Sections washed thoroughly in distilled water for at least 1 hr are dehydrated and mounted in Canada balsam. The preparations thus obtained will permit the most refined examinations. Their quality, however, may be improved further by gold treatment.

ÁBRAHÁM'S PROCEDURE

Recently we have developed the following method for the impregnation of nerve structures.

1. The specimen is fixed in a 10 per cent formalin solution for 2–3 months. Shorter fixation may sometimes yield only poor preparations. Prolonged fixation seems to be favourable. According to our experience, in many cases, excellent preparations have been obtained from specimens fixed for several years.

2. Washing in tap water for 15 min.

3. Washing in distilled water for 15 min.

4. Sectioning by means of a freezing microtome. The thickness of the sections is in general 20–40 μ. Thicker sections are, however, needed for the examination of the total area of the end branchings, or the whole extent of the nerve endings. For such purposes the sections should be 50 μ or still thicker. The sections are then placed in distilled water for 15 min.

5. Impregnation in a 20 per cent silver nitrate solution for 10 min.

6. Washing in distilled water. Thin sections should be just rinsed while sections impregnated for more than 10 min and those relatively thick should be washed for a longer time. It is advantageous to move them in the water.

7. Impregnation in ammoniacal silver solution for 3–5 min, or longer till the sections become brown. Sometimes 10–15 min are needed. The ammoniacal silver solution is prepared as follows. Two drops of 40 per cent sodium hydroxide solution are added to 10 ml of a 20 per cent silver nitrate solution. The brown precipitate is dissolved by adding dropwise ammonium hydroxide (25 per cent solution). The solution thus obtained is filled up to 100 ml with distilled water.

8. The sections are placed for 1–2 sec in an acetic acid solution prepared by adding 5 drops of glacial acetic acid to 100 ml distilled water.

9. Reduction in 10 per cent neutral formol for 20 min. It is greatly recommended that the solution be changed 2 to 3 times. Here the sections become yellowish-brown, the nerve cells and nerve fibres deep black. Prolonged formalin treatment is favourable for the impregnation, particularly when done with special illumination.

10. Gold treatment, dehydration and mounting. With this method the nerve cells and their processes, the nerve fibres and their endings, appear extremely sharp and clear.

BIELSCHOWSKY–GROS–CAUNA'S PROCEDURE

We prepared numerous preparations with the method of Bielschowsky, Gros and Cauna which, adapted slightly to our purposes, is the following:

1. Fixation in 10 per cent neutral formalin for 3–4 weeks. Prolongation of the fixation is always useful. Incubation of sections in 10 per cent neutral formalin, is advantageous.

2. Sections of 25–40 μ thickness are cut with a freezing microtome.

3. Sections are placed in 20 per cent silver nitrate for 10 min. Occasionally this treatment should be prolonged.

4. Sections are transferred into 3 per cent neutral formalin for 15 min. Formalin bath is changed twice, occasionally three times.

5. Sections are placed for 15 min in silver nitrate–ammonia solution, prepared as follows. To the required amount of a 20 per cent silver nitrate solution a 25 per cent ammonia solution is added dropwise until the precipitate formed dissolves completely.

6. Sections are placed in 3 per cent formalin for 5 min. Formalin bath is changed twice or, if required, on several occasions.

7. Sections are rinsed in distilled water for 30–60 min.

8. Sections are dehydrated in rising concentrations of alcohol, cleared in xylol and mounted with a mixture of xylol and Canada balsam.

Since the microscopic view of the preparations shows a sharp enough contrast between the background tissues and nerve fibres, they may be safely used for further examination. A further increase of the picture's sharpness and the resolving of minute details, e.g. of delicate interconnections, is greatly promoted by gold treatment.

Jabonero's silver carbonate method has also been employed, either according to the original description or as adapted by Doležel or ourselves. The procedures of Ranson, Romanes and Cajal were less satisfactory for study of the cardiovascular system.

In the next chapter the nerve connections of the heart and blood vessels are described and interpreted.

2. INNERVATION OF THE HEART

In vertebrates, the heart is a hollow muscular organ of ventral localization. The number and shape of its cavities vary with the different taxonomic groups. The heart wall is constituted mainly by muscle fibres and in a minor part by connective tissue. Its outer and inner surfaces are lined with simple epithelium. In the higher vertebrates its muscular structure consists of two parts, demonstrable also morphologically, viz. the system responsible for mechanical activity and the specialized impulse-producing and -conducting system. There are obvious differences between the muscle fibres constituting the two parts. In lower vertebrates, blood supply of the heart wall is provided by the blood flowing through the heart's cavities, whereas in the higher vertebrates it is provided by the coronary arteries originating in the initial portion of the aorta. The nerve fibres supplying the heart wall arise partly in the vagus, partly in the cervical sympathetic and partly in intracardial ganglion cells.

The shape and structure of the heart are similar in the various groups of vertebrates but, according to their respective stages of evolution, there are great differences in their cavity systems and particularly in the numbers and positions of the associated vessels. With respect to these differences, the microscopy of cardiac innervation of different groups of vertebrates is discussed separately in the details covered by the scope of our studies.

BONY FISHES (TELEOSTEI)

Bony fishes have a ventrally situated venous heart of relatively small dimensions. It is found in the cranialmost portion of the body cavity. This part of the body is the pericardial cavity. The heart is enveloped by the pericardium, and consists of the venous sinus (sinus venosus) to which is attached a dorsally positioned atrium continued bottom forwards in the ventricle. The anterior, gradually tapering part of the ventricle forms the arterial bulb continued anteriorly in the arterial trunk. Essentially the venous sinus arises from the union of the two ventral Cuvieri ducts and the hepatic veins. Its shape is variable depending on the extent and direction of the hepatic vein's participation in the formation of the cavity. At the junction of the venous sinus with the atrium there are two obliquely situated valves. Essentially these valves are constituted by folds arisen from the invagination of the walls of the venous sinus and atrium.

The atrial wall is thin, forming ventrally two large diverticula. These constitute the heart auricles (auriculae cordis) which embrace ventrally from both sides the arterial trunk. Towards the ventricle the atrium narrows. This infundibular

structure is the atrioventricular funnel that extends down to the ventricle's base. The atrial muscles continue in the ventricular muscles through the funnel base. The atrium and ventricle are separated by a circular groove (sulcus coronarius) filled with connective tissue originating from the epicardium.

Towards its inner surface the atrial wall continues in pectinate muscles (musculi pectinati) arranged in a comb-like fashion. The rich branching of these muscular columns gives rise to fan-like structures extending into the atrial cavity. Before continuing in the ventricular muscle, the atrial muscle forms a small sphincter by concentric and parallel arrangement of the fibres.

The ventricle wall is muscular, its shape depending on the thickness and on the arrangement of fibres adjacent to the lumen. The greater part of the wall consists of muscular columns (trabeculae carneae) of varying thickness and arrangement, constituting a sponge-like lacunar matrix (spongiosa). The outer surface of this inner spongiose muscular matrix is enveloped by a thin solid part (pars corticalis). In some species (*Salmonidae*) the cortical part is separated from the spongy matrix by a thin layer of connective tissue.

The aperture (ostium atrioventriculare) between atrium and ventricle is closed by two membranaceous valves. These valves attach to the atrial wall and are interconnected with the circular muscle columns. Valves are found also on the aperture (ostium arteriosum) between the ventricle and the conus arteriosus.

Adjacent to the ostium arteriosum the ventricle narrows to form the conus arteriosus (bulbus cordis) whose proximal part is richer in muscles than the distal one. The latter is not so much a part of the heart as the initial portion of the arterial trunk (truncus arteriosus). In some cases the conus arteriosus regresses and only a small part of it, called the bulbus arteriosus, remains.

The histological structure of the heart of bony fishes as well as the microscopy of its innervation, has so far escaped the interest of investigators. Thus, information is lacking on the histological structure of the individual heart portions, structure and path of conduction system, ganglia and the microscopic relationships between the individual heart portions and their nerve supply. Such reasons have prompted us to examine the heart of bony fish species easily accessible in this country.

In these studies numerous technical problems have been encountered particularly at the beginning, owing to the difficulties of rendering visible the nerve system in the wall of the fish heart. Nevertheless, in due course we succeeded in obtaining satisfactory preparations first from the atrium, atrioventricular orifice, and later also from the ventricle and arterial bulb of the carp's heart. We used easily accessible fish species captured from the river Tisza, viz. carp (*Cyprinus carpio*), silur (*Silurus glanis*) and pike-perch (*Lucioperca lucioperca*). Hearts to be examined were fixed in 10 per cent neutral formalin and impregnated with the Bielschowsky–Gros, or Bielschowsky–Ábrahám procedure. According to our own experience the latter method was best as it produced very clear pictures particularly of the atria. To obtain information also on the general histological architecture, stained preparations were made of materials fixed in Heidenhain's "Susa" or

Zenker's fixing fluid and embedded in paraffin. Staining was made mostly with hematein and eosine, but numerous preparations were stained with iron hematoxylin, van Gieson's stain, or with Mallory's staining technique. Further to this, some parts of the wall were stained by the Koelle–Friedenwald's method as modified by Gerebtzoff, to obtain histochemical evidence on intraganglial synapses. To study the neurosecretion of the wall ganglia, parts of the wall where impregnation indicated the presence of larger amounts of ganglia were fixed in Bouin and Müller's fixing fluid and stained with Gömöri's chromohematoxylin stain.

Since parts of the heart differ not only in the anatomical but also in their histological structure, they are discussed separately with respect to their histological structure, the sequence being: venous sinus, atrium, atrioventricular orifice, ventricle and arterial bulb.

Venous Sinus (Sinus venosus)

Essentially the venous sinus is not an active part of the heart, being simply a continuum of the venous ducts whose function is the collection and partly also the storage of blood. Its wall is thin and structurally resembles the large venous trunks. The tunica intima, tunica media and tunica adventitia are clearly distinguishable histologically.

The tunica intima is constituted by two parts, endothelium and lamina propria. The endothelial cells are elongate and thin, broadening only around their large oval nuclei. The lamina propria thickens adjacent to the atrium, containing many elastic fibres. In other regions it is thinner, being constituted mainly by collagenous bundles. Most fibres are arranged concentrically but there are also more or less longitudinal fibres and adjacent to them smooth muscle cells as well.

The tunica media consists of smooth muscle cells which inwardly are arranged mainly in a longitudinal direction, whereas outwardly rather in a circular pattern, yet neither of them constitutes a clearly distinguishable homogeneous, coherent layer. The bundles of smooth muscle constituting the inner layer are thin and relatively numerous collagenous connective tissue bundles are apparent among them.

The adventitia appeared to be thick in all the examined species. It consists mainly of connective tissue fibres, containing here and there a varying number of elastic fibres, too. In certain regions it is compact, whereas in others loose in structure. In the loose areas connective tissue fibres prevail and elastic fibres are much fewer in number. In the carp, masses of fat cells were also found in the proximity of the atrium. There are numerous vessels (vasa vasorum) of varying diameter. Beside them, larger nerve bundles were seen accompanied by single or aggregated nerve cells along their path.

The nerve fibres supplying the venous sinus arise partly from the vagus and partly from the cervical symphathetic and enter the sinus along the two Cuvierian ducts. The fibres arrive in two large main trunks and branch to the walls. Along

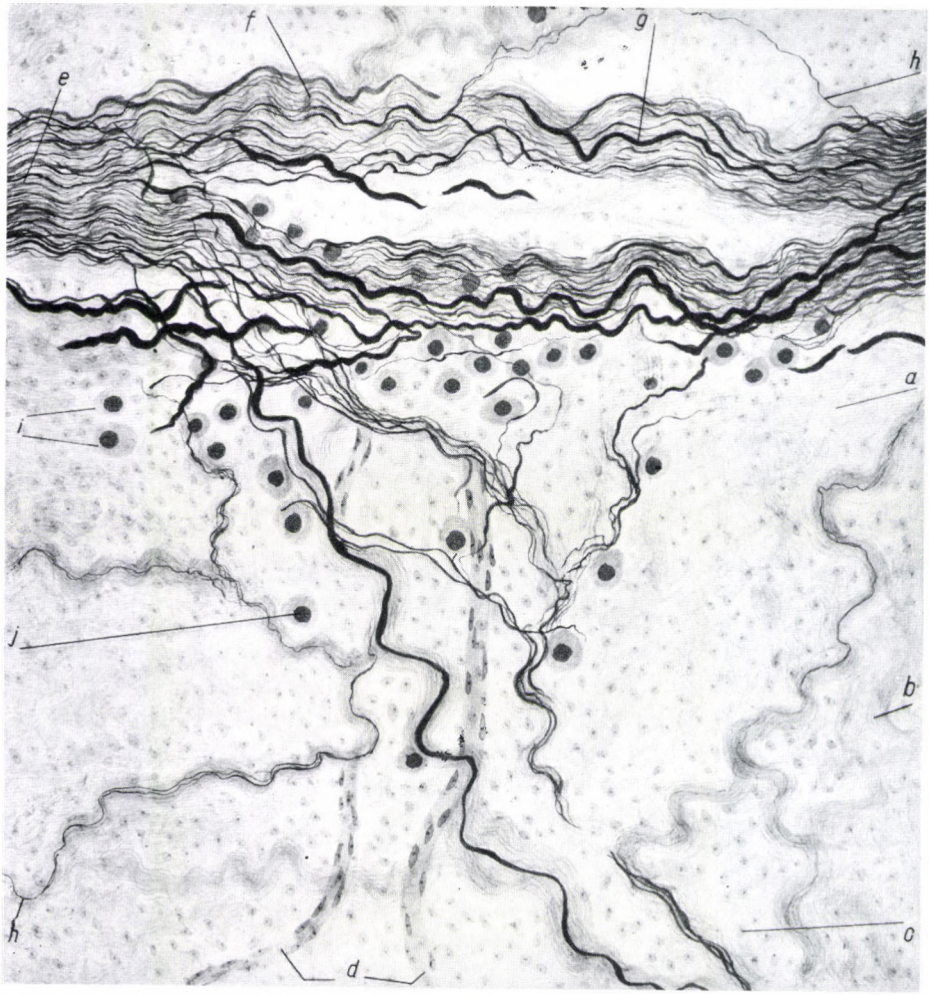

FIG. 1. *Cyprinus carpio.* Venous sinus. (a) Connective tissue; (b) connective tissue fibres; (c) nucleus of connective tissue cell; (d) capillaries; (e) nerve trunk; (f) nerve bundle; (g) thick nerve fibre; (h) thin nerve fibre; (i) nerve cell; (j) nucleus of nerve cell. Bielschowsky–Ábrahám's method. Microscopic magnification 600×, reduced photographically to ½

the descent of the trunks scattered groups of nerve cells are present (Fig. 1). From the smaller trunks exit rami containing a varying number of fibres which branch to the adventitia to form the loose adventitial plexus present in the vessel walls. Fibres arising from this plexus go to the media and form a plexus on the bundles of smooth muscle. Certain fibres of this plexus gradually ramify to constitute a delicate end plexus, some fibres of which conjugate with the smooth muscle cells by delicate end bulbs. At the transition of the sinus wall into the

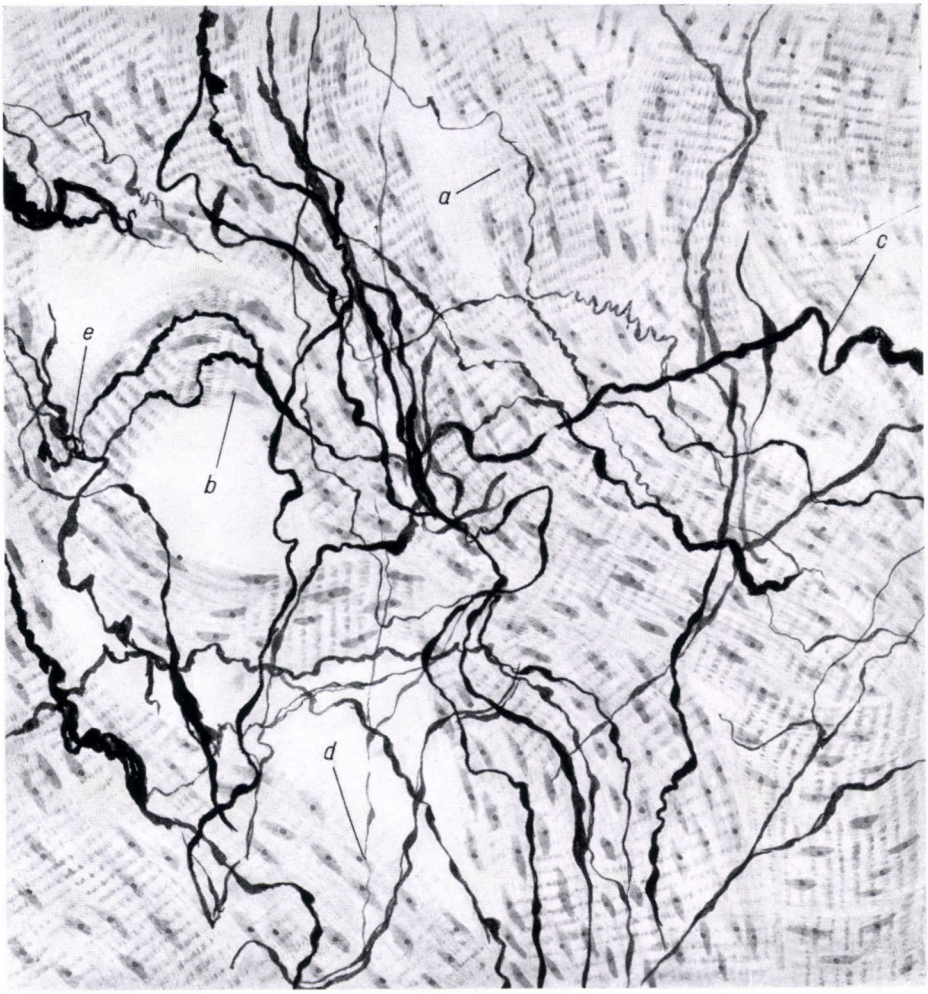

FIG. 2. *Cyprinus carpio.* Nerve plexus in the wall of the venous sinus. (a) Striated muscle fibre; (b) nucleus of striated muscle fibre; (c) thick nerve fibre; (d) thin nerve fibre; (e) nerve plexus. Bielschowsky–Ábrahám's method. Microscopic magnification 400×, reduced photographically to ½

atrial wall the muscles of the media consist of striated fibres. In this area particularly rich nerve plexuses are seen (Fig. 2). Many of the fibres constituting the plexus are thick and exhibit a winding path. These are characterized by elongate varices within which the neurofibrils are occasionally well seen. The appearance of these fibres is suggestive of their vagal origin and they may well be considered receptor elements. In the intima no nerve fibres whatever can be found.

Atrium

When viewed in an inward direction, the epicardium, myocardium and endocardium are relatively easily demarcated from each other. On the ventral surface of the atrium the epicardial epithelium consists of flattened cells with somewhat elongate nuclei, whereas on the dorsal surface the epithelial cells assume a cuboidal shape. The subepithelial connective tissue consists mainly of collagenous fibres containing, however, some elastic fibres as well. In the carp, on the atrial side the epicardium is connected with the myocardium by a loose connective tissue comprising relatively numerous fat cells. In the latter tissue as well as in the epicardium in general, there are numerous smaller and larger blood vessels.

The epicardium is relatively rich in nerve fibres. They are arranged in bundles of undulating descent or pass as single nerve fibres between the fibres of the connective tissue. Within the larger bundles beside the thin fibres thicker ones are also seen. In some areas of the nerve fibre plexus, nerve cells are present in large numbers. The greater part of the fibres descend adjacent to the vessels but some of them are seen at a certain distance in the connective tissue. Sections of the silur's epicardium are particularly characteristic: here the nerve fibres seem to be wound around the vessels, descending almost like a spiral. Further to this, in the carp, but mainly in the silur, nerve fibres may arrange in a loose coil-like pattern mainly at the borders of the myocardium. In the three fish species examined, no significant differences have been found between the microscopic innervation of the epicardium.

In all the three fish species, the atrial part of the myocardium is thin and spongiose in structure. There is no distinct stratification, yet in the silur's atrium an inner circular and outer longitudinal layer may be distinguished. At the basis of the valves at the inflow of the venous sinus both layers display solid structures. The myocardium consists of branched striated muscle fibres with conspicuous, relatively large, central nuclei. The layers and smaller or larger columns of muscle fibres are connected by interstitial connective tissue. The atrial portion of the myocardium is extraordinarily rich in nerve fibres (Fig. 3). It is traversed by thick bundles of fibres going to the atrioventricular orifice. Nerve cells are not infrequent in the neighbourhood of the thick fibres. Some of these fibres are conspicuously thick, containing well-visible neurofibrils. The thick fibres form a loose, broad-mesh plexus that passes through the myocardial connective tissue. Innervation of the atrial myocardium is roughly uniform in the fish species examined.

In comparison with the corresponding part of the heart in higher vertebrates, in fishes the atrial wall is remarkably rich in nerve fibres. Appropriately impregnated sections of the atrium show such an immense mass and inextricable plexus of nerve trunks and smaller or larger nerve bundles as is practically unparalleled in any other muscular innervation. At the first superficial view it seems that the striated muscle fibres are made invisible by the mass of nerve trunks and fibres (Fig. 4). The nerve fibres seem to be entirely interwoven with the muscular ones. Some sections show several nerve fibres running over the surface of one muscle

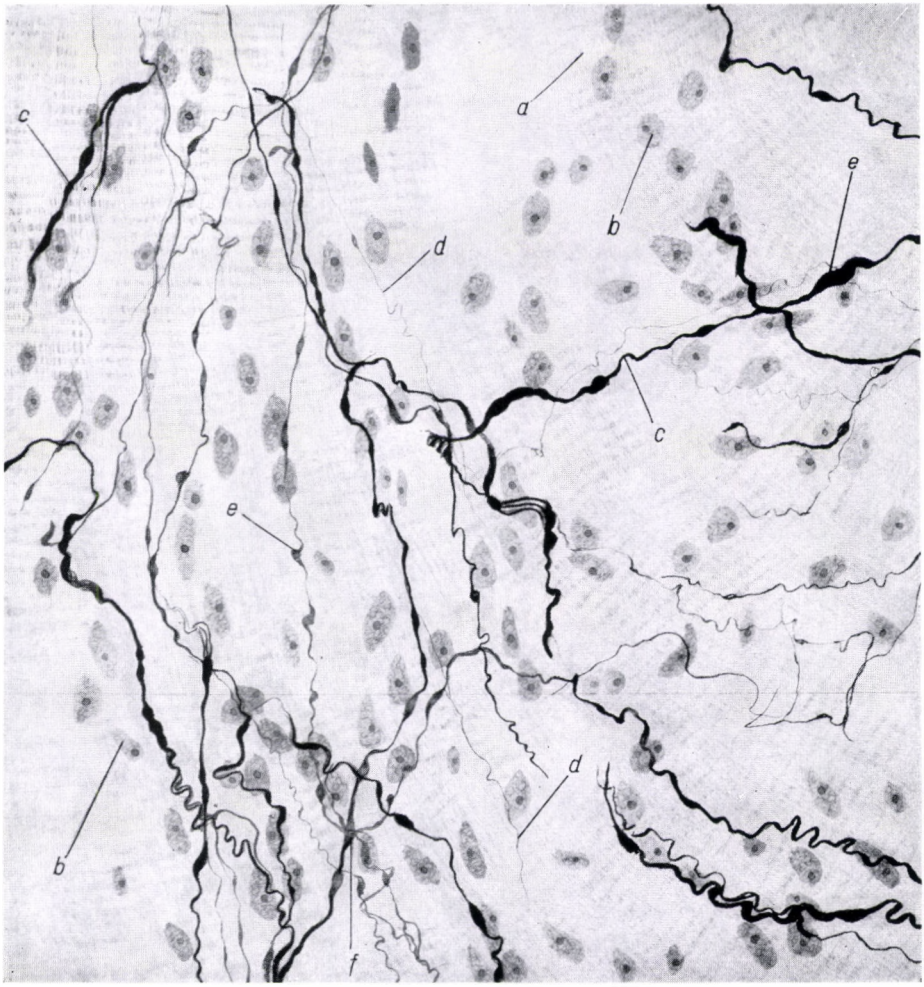

FIG. 3. *Cyprinus carpio.* Nerve fibres in the atrial wall. (a) Striated muscle fibre; (b) nucleus of striated muscle fibre; (c) thick nerve fibre; (d) thin nerve fibre; (e) varix; (f) nerve fibre plexus. Bielschowsky–Ábrahám's method. Microscopic magnification 600×, reduced photographically to ½

fibre, accompanying it almost along its whole length. Smooth-edged and thicker forms are frequent, but still more often the nerve fibres carry smaller or larger varices of angular or irregular shape. Irregular and unusual branchings, as well as oval lattices in the descent of fibres, are not infrequent either. The relation between the mass of nerve fibres seen in preparations whose impregnation has been only occasionally successful, and the muscular fibres supplied by them, is discussed in a later chapter dealing with the general aspects of connections between myocardial and nerve fibres.

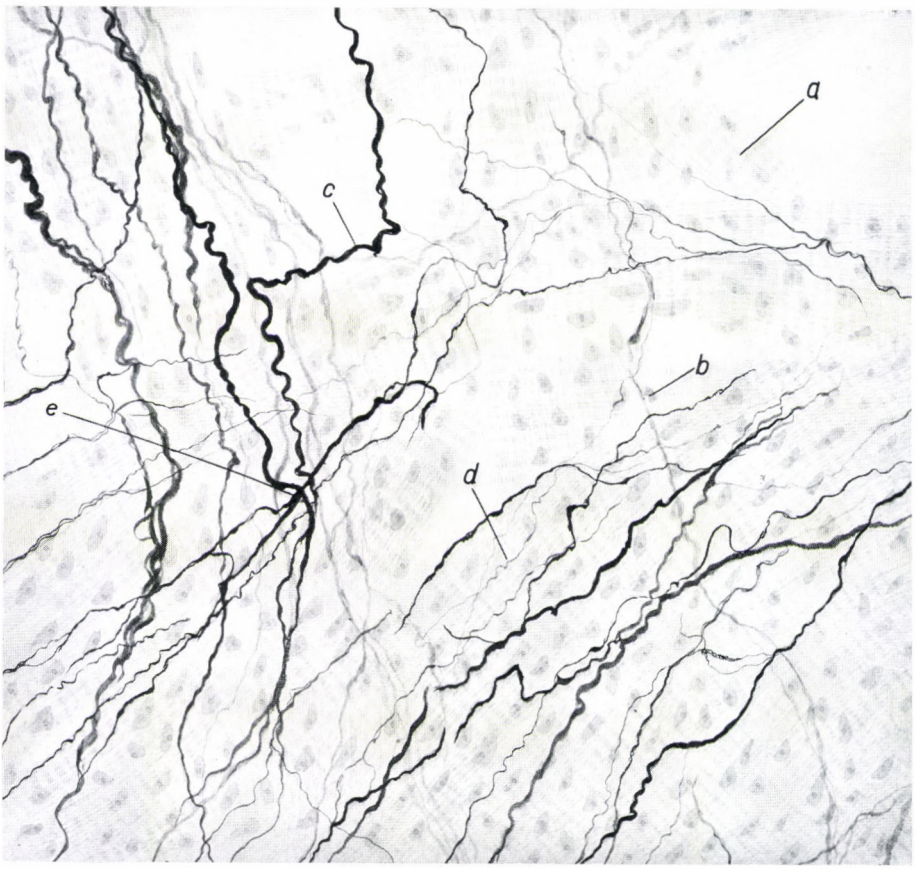

FIG. 4. *Cyprinus carpio.* Heart; nerve fibre plexus in the right atrium. (a) Striated muscle fibre; (b) nucleus of striated muscle fibre; (c) thick nerve fibre; (d) thin nerve fibre; (e) nerve fibre plexus. Bielschowsky–Ábrahám's method. Microscopic magnification 600×, reduced photographically to ½

The atrial endocardium is usually a thin connective tissue layer constituted mainly by collagenous fibres but containing also many elastic ones. Towards the atrial lumen the endocardium is bordered by the flat cells of endothelium with spheroid or more often elongate nuclei. The innervation of the endocardium is supplied by a finer and looser, occasionally well-impregnable plexus situated directly under the endothelium.

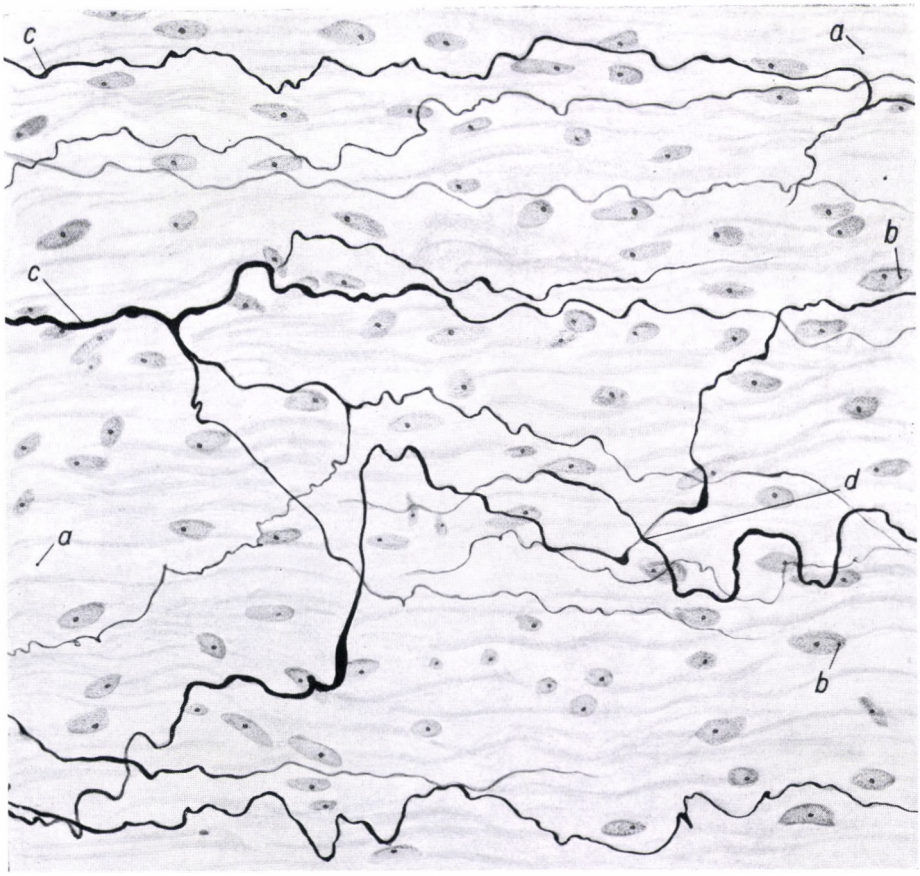

FIG. 5. *Cyprinus carpio*. Heart; atrioventricular funnel. Nerve fibres in the myocardium. (a) Striated muscle fibre; (b) nucleus of the striated muscle fibre; (c) nerve fibre; (d) nerve plexus. Bielschowsky–Ábrahám's method. Microscopic magnification 600×, reduced photographically to ½

Atrioventricular Funnel

Histologically, the atrioventricular funnel is identical with the atrium. Differences have been encountered in the thickness, mass and descent of the individual layers. These differences are outlined as follows. The epicardium is conspicuously thick and remarkably rich in vessels. Muscle fibres constituting the myocardium form two not quite distinct layers: an outer longitudinal and an inner circular one. The outer layer is fairly conspicuous, constituted by smaller and larger bundles of muscle fibres which continue in the atrial myocardium. Fibres constituting the inner layer form a circular pattern of closely arranged fibres. The endocardium of the atrioventricular funnel, too, is thicker than that of the atrium, mainly at the site where the pouched valves arise. Under the valvular endothelium a larger mass



FIG. 6. *Cyprinus carpio*. Heart; innervation of the atrial myocardium. (a) Striated muscle fibre; (b) nucleus of the striated muscle fibre; (c) nerve fibre; (d) nerve ending. Bielschowsky–Ábrahám's method. Microscopic magnification 900×, reduced photographically to ½

of connective tissue, constituted by collagenous columns and elastic fibres, is found. In the middle part of the endocardium there are branched connective tissue cells with great affinity for stain and silver impregnation. The extensively granulated processes of these cells anastomose with the processes of the adjacent similar cells. The epicardium of the atrioventricular funnel is rich in nerve plexuses. Yet the myocardium is richer in nerve fibres, particularly in the carp. Between the circular and longitudinal muscle columns numerous nerve fibres are found either singly or joined in bundles. The fibres are in general thin and undulating, though some thick fibres of presumably vagal origin may also be present (Fig. 5). The single fibres ramify several times in a dichotomic fashion and perhaps these branchings would most truly reveal the hypolemmal end bulbs of the finest rami ending on the muscle

fibres. As a matter of fact, these end bulbs are not apparent in masses in each preparation, but some of them present a markedly clear view of a fairly great number of end rings. In this context it ought to be emphasized again that the perfect impregnation of nerve fibres in the fish heart is not an easy task. Numerous difficulties have to be surmounted and failures coped with. The tenacious worker, ready to face the hardships of this work, will, however, surely succeed when handling the task with sufficient care. In this laboratory, many beautiful sections have been obtained from all heart specimens examined as well as from their individual layers, yet most excellent preparations were yielded by the initial portion of the atrium and the wall of the atrioventricular funnel (Fig. 6).

Ventricle (Ventriculus)

The layers constituting the ventricle wall were fairly well distinguishable in all the three fish species. The ventral surface of the ventricular epicardium is covered by a simple layer of flat epithelial cells assuming a cuboid appearance on the dorsal surface. In comparison with the other layers the epicardium is thin. Its connective tissue is constituted mainly by collagenous and by a few elastic fibres. There are very numerous vessels in the connective tissue layer, namely in the carp.

The innervation of the ventricular epicardium resembles that of the atrial one. It is traversed by smaller and larger nerve trunks, bundles and plexuses comprising fibres of varying thickness. The terminal sensory organs and endings, characteristic of the epicardium of the higher vertebrates, do not occur in a typical form in fishes.

In all the three fish species examined the ventricular myocardium is thick and as a rule spongiose in structure. Two parts of it may be distinguished: a more solid outer layer constituted mainly by circular columns and an inner layer with a more obvious spongiose structure consisting essentially of longitudinally arranged fibres. Both layers are formed of striated muscle fibres with fairly conspicuous striation and large, spheroid central nuclei.

The ventricular myocardium is rich in nerve fibres. It is traversed by an extensive plexus also comprising a few thick fibres of particular appearance. Here and there the thick fibres are arranged in a loose coil-like pattern and some of our sections have been suggestive of coil-like endings as well. Were this true, these endings would represent the proprioceptors of the myocardium whose presence in higher vertebrates has been recently confirmed both by physiological and morphological methods. In the ventricular myocardium, too, plexuses are very rich in fibres. The nerve fibres traverse the muscular fibres and their endings are essentially similar to those observed in the atrial muscles junctioning with the muscle fibres by end bulbs or rings.

The ventricular endocardium thickens at the site of the valves between the bulbus and ventricle, but its other parts are rather thin. Its connective tissue is essentially similar to those of the endocardium portions discussed above and its endothelium consists of markedly flattened cells. The connective tissue layer is rich in nerve fibres. The fibres arrange into plexuses. Fibres leaving the plexuses

occasionally run a long clearly discernible path ending in obvious end bulbs in which the neurofibrillar plexus is sometimes well visible. In view of this structure it seems to be highly probable that these neurofibrillar end bulbs represent the sensory elements of the endocardium and as such they naturally belong to the vagal nerve fibre system.

Arterial Bulb (Bulbus arteriosus)

At its exit from the heart the arterial bulb is thick, becoming thinner distally. Its outer layer, the adventitia, consists of fibrous connective tissue containing also elastic fibres. This layer is not particularly rich in nerves. The fibres form a loose plexus and are mostly smooth-edged, thin fibres of the vegetative type. Some thick fibres may, however, be present too. Although the endings were not seen, we are convinced that they are the sensory elements of the adventitia. The greater part of the media is constituted by circularly arranged smooth muscle cells. Between the muscle bundles there is fibrous connective tissue containing relatively many elastic fibres. The innervation of the media resembles that of the media of the venous sinus, viz. the general pattern of innervation in vessels' media. The smooth muscle tissue is traversed by a delicate plexus, a terminal reticulum being absent. The end fibres of the plexus disappear between the smooth muscle cells without showing any characteristic ending.

The intima is fibrous connective tissue thickening at the ventricular orifice of the bulbus, but being narrow in its other portions. Towards the lumen it is lined by a simple endothelial layer. Similarly to the vascular intima, no nerve elements are present in the intima of the arterial bulb either.

Nerve Endings of the Myocardium

Examination of the heart of bony fishes reveals a very rich innervation in certain areas of the myocardium, particularly in the atrium adjacent to the venous sinus and in the atrioventricular funnel near the ventricle. As previously mentioned, fibres constituting the delicate end plexuses run parallel to the muscle fibres, covering them almost entirely. In all the three fish species examined a closer study of the individual fibres revealed that in both atrium and ventricle the majority of them end freely in end bulbs (Fig. 7). Hence we confirm our previous conclusion of 1937, in connection with the higher vertebrates, that there *are* free nerve endings in the myocardium. The reader may be aware that this concept is not solely ours but has since been shared by others. As a matter of fact, the end rings were not seen in each preparation from each fish, yet relatively many preparations have been obtained from fish heart which, at the first sight, would convince any observer that some of the terminal nerve fibres actually end freely and the smaller or larger end bulbs or discs assume a hypolemmal position in the cytoplasm of the striated muscle fibres



FIG. 7. *Cyprinus carpio*. Atrium, myocardial innervation. (a) Striated muscle fibre; (b) nucleus of the striated muscle fibre; (c) nerve fibre bundle; (d) nerve fibre; (e) nerve ending. Bielschowsky–Ábrahám's method. Microscopic magnification 1250×, reduced photographically to ½

Ganglia

In every case, the localization of ganglia has been restricted to the venous sinus, atrium and ventricle. In the arterial bulb no ganglia were demonstrable. This is natural considering that the arterial bulb is simply a part of a vessel. In the thick vegetative nerve trunk traversing the adventitia of the venous sinus, smaller or larger nerve cells of the multipolar type and occasionally also larger ganglia have been detected (Fig. 8). In the atrium of the carp, silur and pike-perch alike a relatively large ganglion is apparent which broadens and extends to the initial

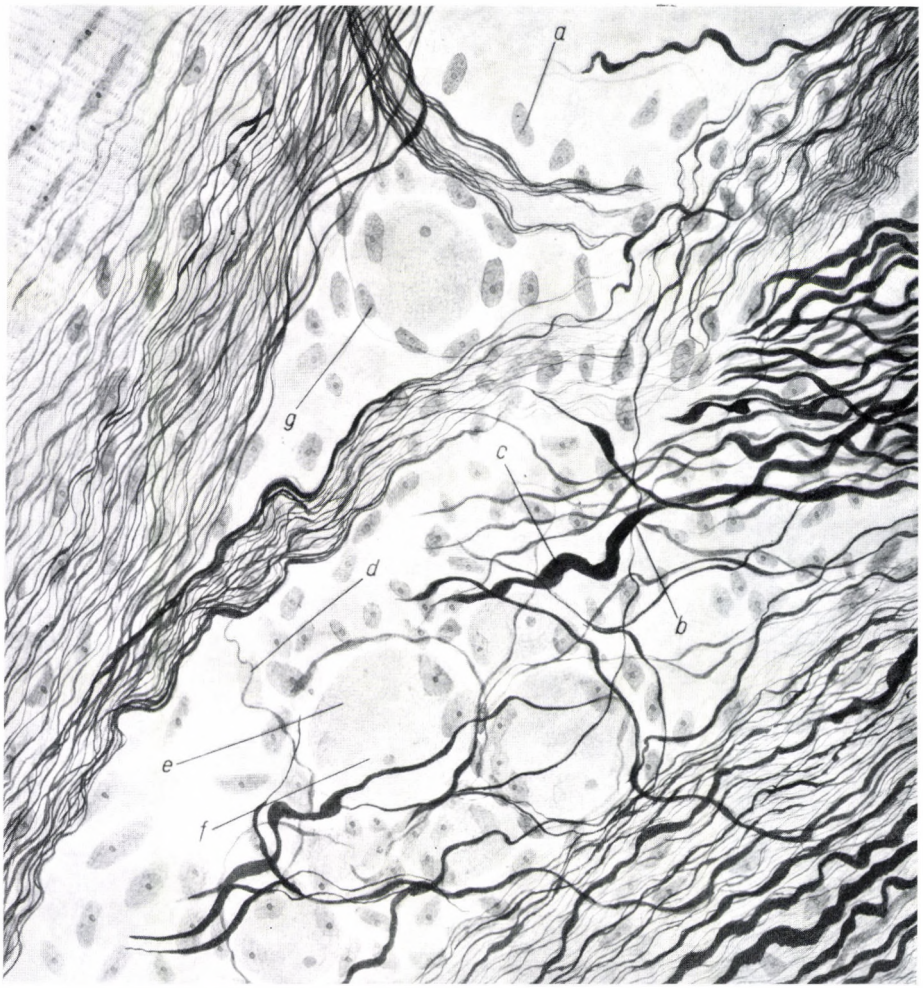

FIG. 8. *Silurus glanis*. Heart; nerve plexus in the venous sinus (a) Nucleus of connective tissue cell; (b) nerve plexus; (c) thick nerve fibre; (d) thin nerve fibre; (e) nerve cell; (f) nucleus of the nerve cell; (g) nucleus of the satellite cell. Bielschowsky–Ábrahám's method. Microscopic magnification 600×, reduced photographically to ½

portion of the ventricle. This ganglion comprises a large number of fibres and cells which constitute a practically inextricable plexus. As far as I am informed no descriptions of this ganglion have been available in the relevant literature.

Ganglia extending to the ventricle are usually loose, resembling rather a plexus system within which the nerve cells are arranged closely in rows which extend in every direction from certain points of the plexus. Another characteristic of these ganglia is their large dimension, extending mainly in line with the heart's longi-

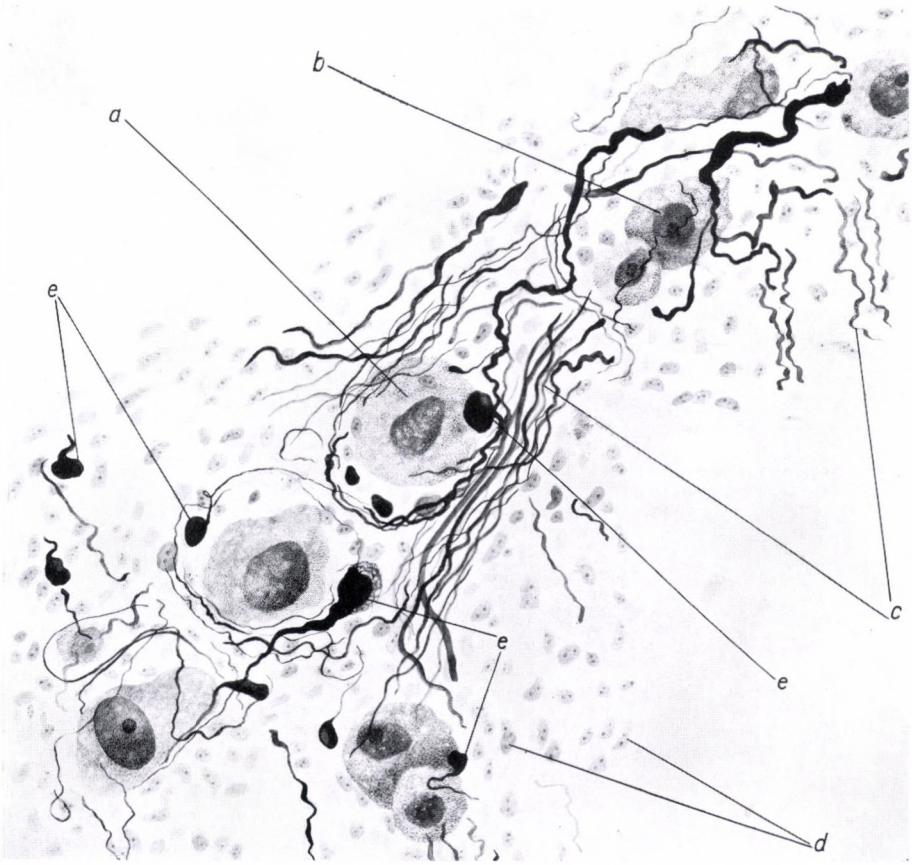

FIG. 9. *Cyprinus carpio*. Heart; ganglion in the atrial wall. (a) Nerve cell; (b) nucleus of the nerve cell; (c) nerve fibre; (d) nucleus of connective tissue cell; (e) end knob. Bielschowsky–Ábrahám's method. Microscopic magnification 400×, reduced photographically to ½

tudinal axis over a relatively large distance. A further typical feature is the marked dissimilarity of the fibres in both thickness and descent. There are some conspicuously thick fibres seen not only in the trunks but also in the ganglia, occurring in the latter in great masses and exhibiting an undulating pathway.

In general the nerve cells are large, elongate and rounded at both ends. Their nuclei are spherical and relatively small. The greater part of these cells is of the unipolar type and their processes extend in the form of thick undulating fibres beyond the ganglion far into the respective nerve trunks. Around the cells smaller or larger end bulbs are frequently seen, which are evidently the endings of preganglionic fibres and as such are themselves synapses (Fig. 9).

Some of the preganglionic fibres surround the elongate nerve cell bodies in the form of a pericellular spiral (Fig. 10).

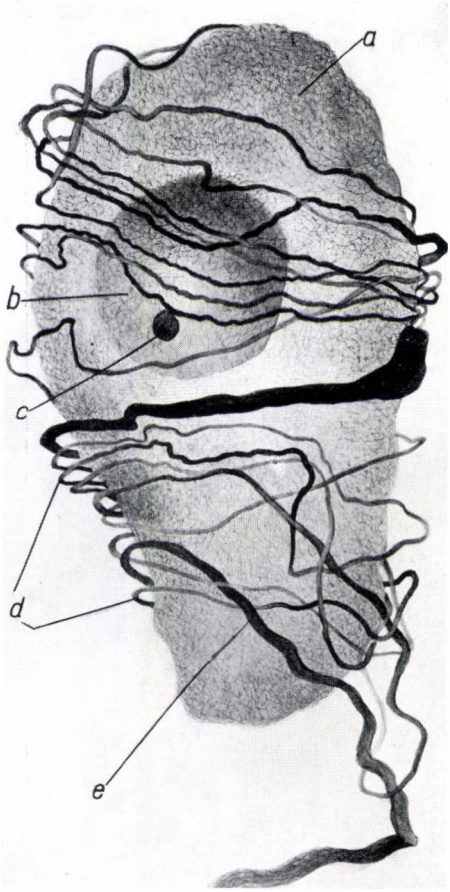

FIG. 10. *Cyprinus carpio*. Heart; pericellular spirals in the atrial epicardium. (a) Nerve cell; (b) nucleus of the nerve cell; (c) nucleolus; (d) pericellular spirals; (e) preganglionic fibre. Bielschowsky–Ábrahám's method. Microscopic magnification 1800×, reduced photographically to ⅔

The occurrence of synapses within the ganglia was shown also by cholinesterase tests carried out in the carp's heart by the method of Koelle–Friedenwald as modified by Gerebtzoff. The cells became dark brown and granular. This implies a cholinesterase activity in the cell surface confirming physiologically the presence of synapses. This correlated well with the morphological finding which, together with the enzyme assay, supports the hypothesis that the ganglia synapse with the preganglionic fibres. No anastomoses have been observed among the adjacent cells. The fibres running between the cells constitute a plexus, whereas in the ganglia no terminal reticulum is present.

In the ganglion cells, staining with Gömöri's chromohematoxylin-phloxin technique, some vacuolization and granulation can be seen mainly at the surface. But these findings are not sufficient in themselves to demonstrate that neurosecretory activity occurs in the cells.

AMPHIBIA

The heart of amphibia comprises four cavities and is localized ventrally. It consists of the venous sinus (sinus venosus), two atria (atrium), ventricle (ventriculus), and heart bulb (bulbus cordis). The nerve interconnections between the individual heart portions have been examined on water frogs (*Rana ridibunda*) and in the spotted salamander (*Salamandra maculosa*). Histological specimens were stained with Ehrlich's vital methylene blue and different silver impregnation techniques.

Ehrlich's vital methylene blue stain was applied supravitally and intravitally. Specimens were fixed in 10 per cent ammonium molybdenicum and the nerve paths examined in frayed preparations. This procedure provided reliable information on the pathway and the gross branchings of nerves, but proved unsuitable

for a closer examination of the fine structures. For this purpose, Schadabasch's procedure was more helpful but not sufficiently refined.

For the detection of the system of innervation in the frog's heart the silver impregnation techniques appeared to be most satisfactory. Of these Bielschowsky's method proved to be superior, both in Gros' and Ábrahám's adaptation. Good preparations have been obtained also by staining with the methods of Bielschowsky–Gros–Cauna, Jabonero and Ramòn y Cajal, respectively. The latter was used in Cajal's modification No. IV throughout.

All information given below on the nerve interconnections in the hearts of the frog and spotted salamander has been derived from preparations obtained by the silver methods listed above. As a matter of fact, fixed and stained preparations were also prepared to clarify the histological conditions. The cholinesterase activities of nerve cells and nerve fibres were examined with Gerebtzoff–Coupland–Holmes' test and the neurosecretion with Gömöri's chromohematoxylin-phloxin staining technique.

Prior to impregnation the heart specimens were fixed in 10 per cent neutral formalin usually for 1–2 months. Fixation was frequently carried out by injecting formalin into the heart after its afferent and efferent vessels had been tied down and placing the whole heart afterwards in formalin. In most cases frozen sections of 20–40 μ thickness were prepared and treated with silver, occasionally with gold, according to one of the above methods. Interconnections between the heart wall and the nerve system were studied in totally impregnated preparations from the atrial wall, mainly from the septum between the atria (septum atriorum). Such preparations were very helpful and even conclusive with respect to the study of the general nerve pictures.

Innervation of the individual portions of the heart is discussed below, in the following sequence: venous sinus, atria, atrial septum, ventricle, heart bulb and finally the cardiac ganglia.

Venous Sinus (Sinus venosus)

The venous sinus' wall is extraordinarily thin yet readily dilated. Histologically it is separable into tunica intima, tunica media and tunica adventitia. The tunica intima consists of endothelium and lamina propria. The round nuclei of the large polygonal endothelial cells protrude markedly towards the lumen. As a rule, the nuclei comprise only one nucleolus, but some comprise two. The lamina propria consists of collagenous fibres containing also many elastic ones. The thickness of the lamina propria is variable in the different regions. The tunica media consists of smooth muscle cells, part of them being arranged circularly, and part of them longitudinally. Adjacent to the atrium, single striated muscle fibres and smaller or larger bundles and trabecules, constituted of striated muscle fibres, are apparent. The latter are arranged mainly longitudinally. In both cases the muscle elements are traversed by connective tissue columns. The adventitia is relatively thick, its structure being alternately compact and loose. In certain parts numerous chromatophores and smaller or larger vessels are present.



FIG. 11. *Rana ridibunda*. Heart; nerve plexus in the wall of the venous sinus. (a) Striated muscle fibre; (b) nucleus of the striated muscle fibre; (c) thick nerve fibre; (d) thin nerve fibre; (e) nerve fibre plexus. Bielschowsky–Ábrahám's method. Microscopic magnification 600×, reduced photographically to ½

The nerve fibres traversing the wall of the venous sinus are well visible in *in toto* impregnated preparations. The minority of them are thin sympathetic fibres covered by a Schwannian sheath containing slightly elongated nuclei while the majority are myeline-sheathed thick fibres of vagal origin going towards the atria in smaller or larger trunks. Nerve cells are frequently seen within or along the trunks' path or sometimes even at a certain distance from them. Two types of these cells were distinguished. Both were unipolar with a relatively thick process

which was in one type surrounded by a spirally descending fibre, while in the other the spiral fibre was missing. The nerve cells are relatively large and in their cytoplasm the neurofibrils are occasionally well visible. The nuclei are large, round and central. In some trunks and trunk portions the cells form group-like aggregations but mostly they arrange at a variable distance from each other along the trunks' paths. The connective tissue is traversed by nerve fibres of varying thickness which in certain regions constitute a loose plexus. In the smooth muscle layer delicate plexuses are seen. The available preparations have not permitted a definitive conclusion concerning the closer relationship of the smooth muscle cells with the nervous system, yet it is certain that within the smooth muscle layer no trace of a terminal reticulum has been detected, in spite of the opinions supporting its existence. In fact, there is but a simple end plexus whose fine terminal fibres end in hypolemmal bulbs within the smooth muscle cells. These endings are, however, only seldom detected and then with difficulty. The same applies to wall portions where the smooth muscle tissue mingles with striated muscle tissue or there is a transition of smooth muscle into striated muscle (Fig. 11).

Atrium

In the atrial wall the characteristic layers of the heart wall are sharply defined. The epicardium is thicker on the ventral surface than on the dorsal one. It consists mainly of collagenous fibres. The epithelial cells constituting its border are cuboidal on the dorsal, while flat on the ventral surface. It connects with the myocardium by a loose connective tissue. In general, the myocardium is thin and its structure loosely arranged. The striated muscle fibres form a spongiose system. The muscle fibres are slightly elongated and show branching. The endocardium thickens at the base of the sino-atrial valves but otherwise it is relatively thin. Its connective tissue fibres are mainly of the collagenous type, but also elastic fibres occur therein in a relatively large number. The endocardium is bordered by squamous endothelial cells against the atrial lumen and also against both sides of the atrial septum. The latter's large round nuclei are markedly protrusive.

The nerve fibres supplying the epicardium originate partly from the smaller nerve trunks descending from the venous sinus and partly from trunks passing or traversing the Remák ganglion. In the form of larger bundles these trunks enter the atrial septum whence they pass dorsally towards the ventricle. The nerve trunks consist mainly of varicose undulating fibres but in a minor number they also contain smooth-edged, thin, sympathetic fibres. Many of the thicker fibres are myeline-sheathed. Not infrequently there are nerve bundles composed exclusively of myeline-sheathed nerve fibres. These pass to the ventricle at the base of the atrioventricular valves. In the epicardium itself there is a rich plexus, some fibres of which terminate in end rings of varying sizes.

The atrial muscles are richly interwoven with rami stemming from greater nerve trunks and with single nerve fibres as well. The terminal fibres constitute a delicate plexus some fibres of which end freely on the striated muscle fibres (Fig. 12).



FIG. 12. *Rana ridibunda*. Heart; nerve plexus in the atrium. (a) Connective tissue; (b) nucleus of connective tissue cell; (c) striated muscle fibre; (d) nucleus of the striated muscle fibre; (e) nerve fibre; (f) nerve plexus; (g) nerve ending. Bielschowsky–Ábrahám's method. Microscopic magnification 600×, reduced photographically to ½

The endocardium is relatively rich in nerve fibres, namely at its junction with the right atrium. In general, nerve fibres run in parallel with the connective tissue fibres constituting the largest mass immediately below the endothelium. Some sensory fibres terminate in end discs.

Atrial Septum (Septum atriorum)

The atrial septum separating the two atria is a thin transparent membrane. Its bulk is constituted by its middle layer, the myocardium, bordered against the lumens by thin endocardium. The muscle cells of the myocardium ramify to form

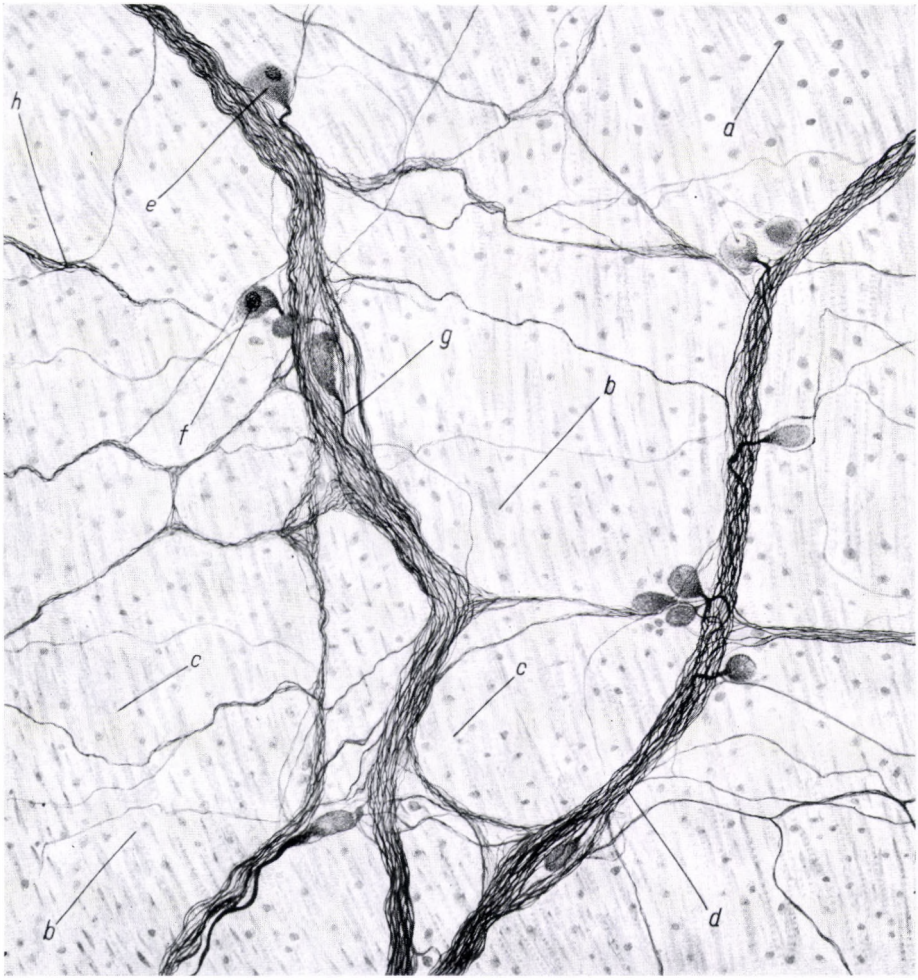

FIG. 13. *Rana ridibunda*. Heart; nerve plexus in the atrial septum. (a) Nucleus of endothelial cell; (b) striated muscle fibre; (c) nucleus of striated muscle fibre; (d) nerve bundle; (e) nerve cell; (f) nucleus of the nerve cell; (g) process of the nerve cell; (h) nerve fibre plexus. Bielschowsky–Ábrahám's method. Microscopic magnification 280×, reduced photographically to ½

a loose plexus. To this network is attached the endocardium whose structure is identical with that of the atrial wall's endocardium.

Of all parts of the heart the atrial septum is richest in nerves. In the septum pass the two larger trunks arising from the ramus cardiacus, the nervus septalis dorsalis and nervus septalis ventralis. Along these nerve trunks, nerve cells aggregate in masses and there are several single nervous cells attaching to the trunks as well (Fig. 13). The cells are unipolar, extending thick processes into the trunks



FIG. 14. *Rana ridibunda*. Heart; nerve cells in the atrial septum. (a) Nucleus of endothelial cell; (b) striated muscle fibre; (c) nucleus of striated muscle fibre; (d) nerve cell; (e) nucleus of the nerve cell; (f) process of the nerve cell; (g) nerve fibres. Bielschowsky–Ábrahám's method. Microscopic magnification 1300×, reduced photographically to ½

wherein they are seen to cover quite large distances. The cell body is usually conspicuously large, roundish or slightly elongate. The nucleus is nearly spherical localizing in every case at the cell's border near to its surface. The cytoplasm is granulated, neurofibrils are not visible except at the exit of the process from the cell. At this site they form parallel bundles which accompany the process along its pathway in the trunk over quite a large distance. The cell process passes through the trunk in a slightly narrowed but otherwise unchanged form without branching.

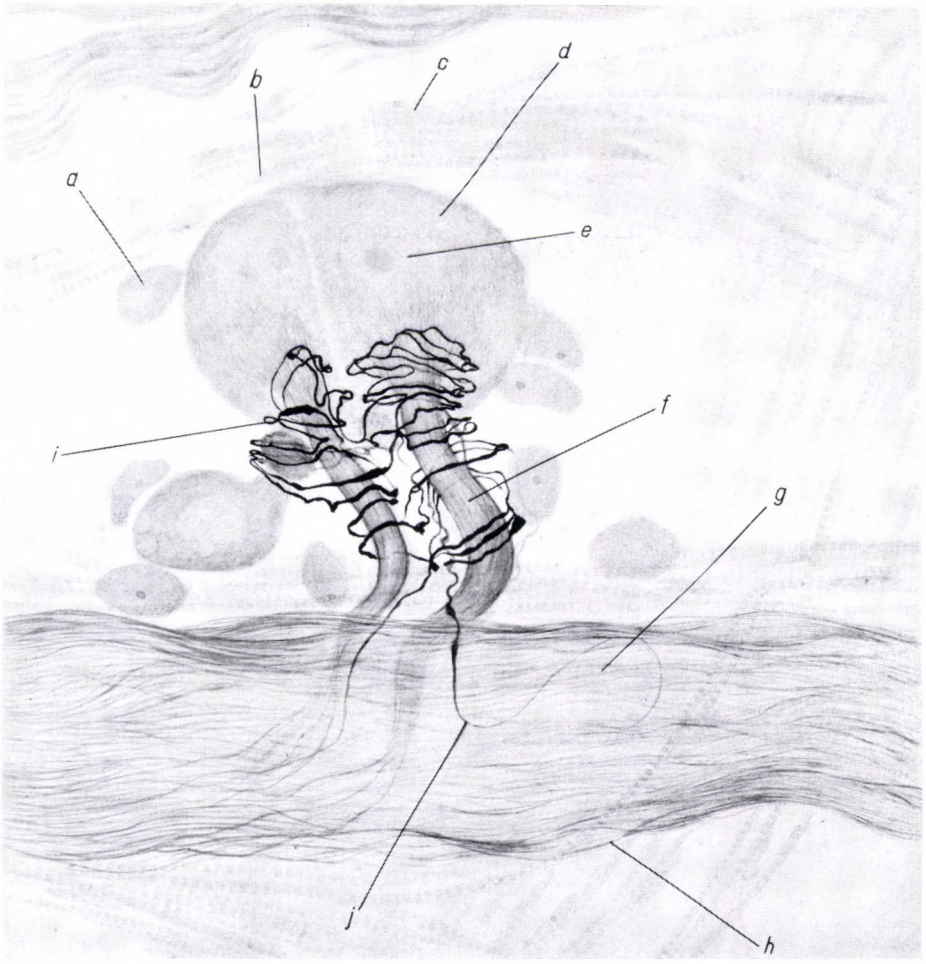

FIG. 15. *Rana ridibunda*. Heart; pericellular spirals in the atrial septum. (a) Nucleus of endothelial cell; (b) striated muscle fibre; (c) nucleus of striated muscle fibre; (d) nerve cell; (e) nucleus of nerve cell (f); process of nerve cell; (g) nerve trunk; (h) nerve fibre; (i) pericellular spirals; (j) preganglionic fibre. Bielschowsky–Ábrahám's method. Microscopic magnification 1300×, reduced photographically to ½

Infrequently, however, sections have been encountered showing the branching of the process into two uniformly thick rami running further on in the same direction within the trunk (Fig. 14).

Many of the unipolar nerve cells attaching to the trunks connect with a relatively thin, spirally descending nerve fibre. This, known as a spiral fibre, circumflects several times the neck part of the usually pear-shaped cell and the process debouching therefrom as well.

Occasionally the spiral fibre may connect two cells. This coupling is brought about in that the fibre approaching two closely neighbouring cells circumflects first the process extending from one of them, then passes to the process of the other which it again circumflects several times and finally winds around both cells (Fig. 15). In both cases it is clear that the fibre has originated from a nerve trunk and is thus an entirely foreign morphological structure in relation to either cell.

Spiral fibres detected around nerve cells confront the neurohistologist with severe problems. Some investigators consider this phenomenon a phylogenetic character, while others (Stöhr, 1957) a pathological alteration. Again others believe that the spirals are transmitting stimuli and as such should be regarded as synapses (Ábrahám, 1950–56; Kirsche, 1958). To derive a definitive conclusion from these controversial views let us examine all problems encountered and try to solve them on the basis of experimental results.

According to one concept the spiral fibres are simply processes of nerve cells equipped with a spiral apparatus. This opinion is contradicted by all preparations obtained by the up-to-date silver impregnation method. These preparations show that the spiral fibre wound round the cell is not a process thereof but approaches it from a distant source and its position in the nerve trunk, too, can be precisely identified.

The other opinion states that the nerve spirals are temporary structures appearing and disappearing in the course of phylogenesis whence they should be considered accidental, viz. structures which are sometimes absent, sometimes again present, thus having essentially no bearing on nerve function. Undoubtedly, this view cannot be accepted. Theories like that have been advanced by workers studying the vegetative nervous system obviously only in higher vertebrates and who have been lacking experience on similar systems in the higher invertebrates and the lower vertebrates. They first appear in fishes being particularly conspicuous around the cells constituting the heart ganglia. In amphibia, too, they are demonstrable within the ganglia as well as along the path of nerve trunks. There *are* spirals in reptilia, birds and mammals as well. If this be true then spirals must not be considered accidental structures but rather actual parts of a highly organized nervous system and as such a functional necessity. That spirals are no chance remnants of phylogenesis is, apart from the above considerations, shown also by the fact that they are entirely lacking in the vegetative nervous system of the higher invertebrates. As an example, we refer to the gastrointestinal innervation in leeches and snails. As shown by our recent studies, these animals possess numerous pear-shaped, unipolar nerve cells whose single thick process enters into the nerve trunk. Pictures of the garden snail's (*Helix pomatia*) nerve system, that yielded readily to impregnation, appeared to be completely identical with those obtained from the atrial septum (septum atriorum) of the frog (*Rana ridibunda*) (Fig. 16), except for one substantial feature, viz. in the snail both spiral networks and pericellular baskets have been definitely missing. This again implies that the spirals are not accidental structures involved in the course of phylogenesis but are, as stated above, essential structures of the vegetative nervous

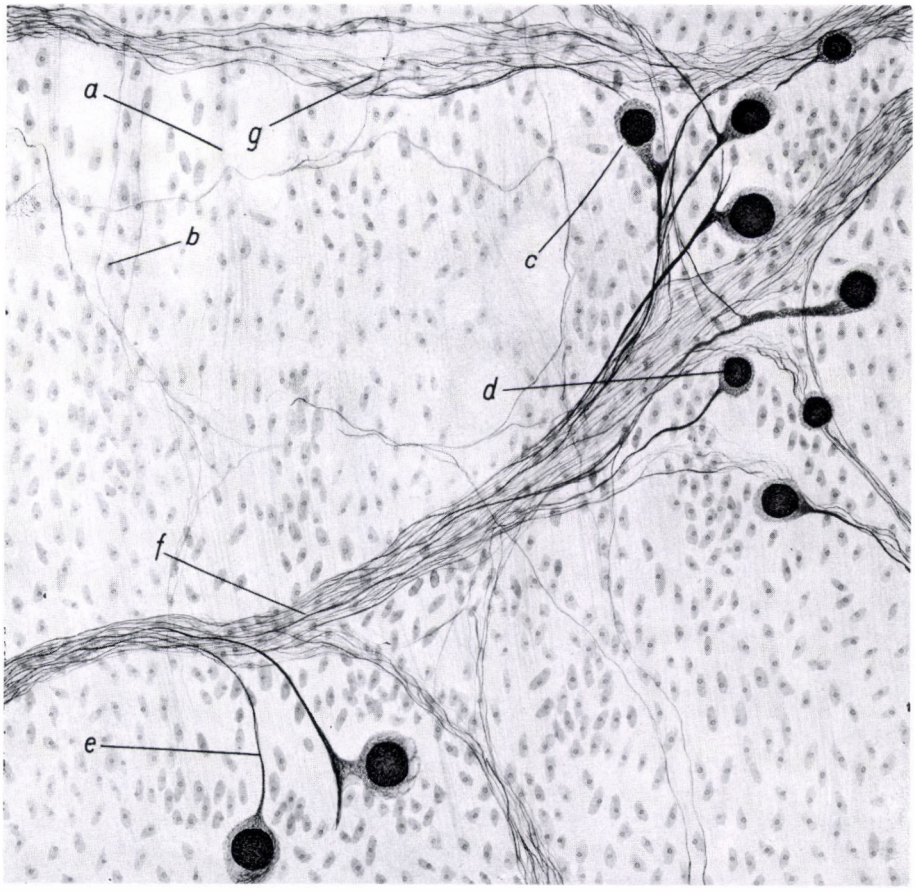

FIG. 16. *Helix pomatia*. Nerve fibre plexus in the intestinal wall. (a) Muscle fibre; (b) nucleus of muscle fibre; (c) nerve cell; (d) nucleus of nerve cell; (e) process of nerve cell; (f) nerve fibre bundle; (g) nerve plexus. Bielschowsky–Gros' method. Microscopic magnification 256×, reduced photographically to ½

system whose development was necessitated by certain higher functions of vertebrates.

The spiral fibre has no relationship with the nerve cell around which it winds passing to it from other distant fibre structures as a broader synaptic formation covering a larger area and communicating impulses of greater intensity, either continually or, if so required by the nature of the synapsis, periodically. Hence the spiral structures seen around the larger nerve cells of the venous sinus and the atrial septum are stimulus conductors that according to Kirsche's concept belong to synapses of greater transmission area.

The question arises of what origin might be the spiral nerve fibres encountered in the frog's heart. Analysis of normal pictures hardly allows reliable conclusions.

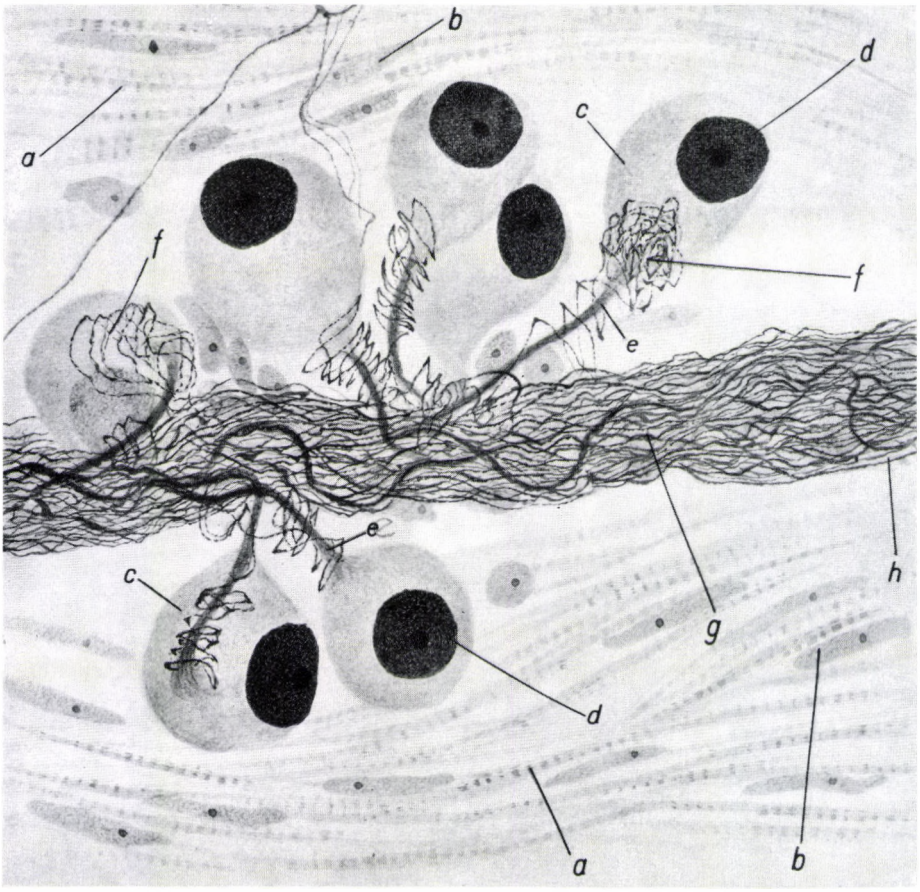

FIG. 17. *Rana ridibunda*. Heart; degenerating nerve fibre plexus in the atrial septum, 22 days after bilateral vagotomy. (a) Striated muscle fibre; (b) nucleus of striated muscle fibre; (c) nerve cell; (d) nucleus of nerve cell; (e) process of nerve cell; (f) degenerating pericellular spirals; (g) nerve trunk; (h) degenerating nerve fibre. Bielschowsky–Ábrahám's method. Microscopic magnification 1350×, reduced photographically to ½

Therefore, in the course of our studies, nerve section experiments were also performed. In larger frogs one or both of the vagi were cut either simultaneously or subsequently after a short interval. The frogs, particularly the female ones, tolerated the intervention well. Fatalities were quite infrequent. Operated frogs were then killed after various intervals, their hearts filled with neutral formalin and the large vessels tied down. After several months the venous sinus and atrial septum were exposed and subjected to total impregnation. The preparations obtained from these animals have shown that degeneration has started several days after vagal section. It was, however, quite slowly progressive in the area of the atrial septum.

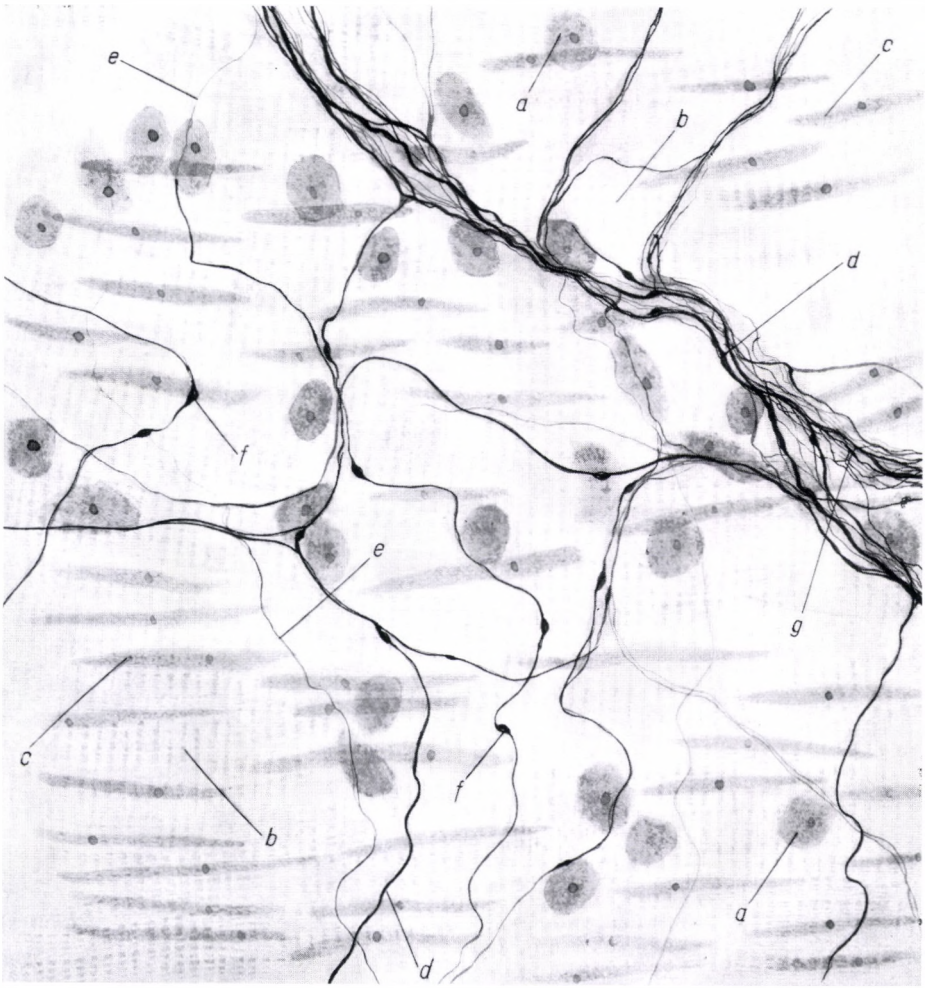

FIG. 18. *Rana ridibunda*. Heart; nerve plexus in the atrial septum. (a) Endothelial cell; (b) striated muscle fibre; (c) nucleus of striated muscle fibre; (d) thick nerve fibre; (e) thin nerve fibre; (f) varix; (g) nerve fibre plexus. Bielschowsky–Ábrahám's method. Microscopic magnification 600×, reduced photographically to ½

Whilst the nerve fibres of the ventricular myocardium became granulated and fell asunder, there was hardly any sign of degeneration in the nerve spirals. In material obtained from frogs killed between the 20th and 22nd day after neurotomy the degeneration of spirals was, however, quite obvious yet still incomplete. The preparations revealed only a transformation of the nervous tissue to small granula which were still attached to each other but already showed signs of a forthcoming decomposition (Fig. 17). These nerve pictures present firm evidence

that the spiral fibres have no genetic relationship with the nerve cells since they belong to the vagal fibre system and as such they start to degenerate after cutting the vagus. If this be true, then the pericellular spirals are actually synapses belonging to the vagal fibre structure which as end portions of the preganglionic fibres are responsible for the conduction of impulses to the processes, i.e. bodies of the nerve cells.

Concerning the general innervation of the atrial septum, the following observations have been made. Like the endocardium of the atrial wall, that of the atrial septum also contains delicate plexuses some fibres of which end here and there in end rings. These fibres, supposedly belonging to the vagal sensory system, are apparently the receptors of the atria.

Muscle fibres constituting the myocardial layer of the septum are thin and long, occasionally extending at a great distance from each other. Nerve bundles and rami exiting from the trunks gradually give rise to branches which form plexuses on the muscle fibres (Fig. 18). The end fibres of these plexuses are very thin, varicose and in total preparations they can be pursued over a great distance without detecting any closer relationship between them and the muscle fibres. In general, even the finest preparations seem to be inadequate for a precise study of end connections. This is, however, not true, as tenacious microscopic examinations have revealed that the most delicate nerve end fibres terminate in tiny rings, supposedly under the sarcolemma. Krause reports structures resembling antler's branches. We did not detect such patterns in our preparations. The nerve trunks passing through the septum (nervus septalis dorsalis, nervus septalis ventralis) continue at its dorsal end in two larger ganglia, known as Bidder's ganglia.

Ventricle (Ventriculus)

Histologically, from outside towards its inside the ventricle is constituted by epicardium, myocardium and endocardium. The epicardium consists of collagenous connective tissue bundles with many elastic fibres among them. Towards the outer surface the epicardium is bordered by a single-layered epithelium with elongate and remarkably flat cells.

The myocardium consists of striated muscle fibres which, owing to the manifold functions of the ventricle, arrange in various directions. Of these the surface layer appears to be most homogeneous bordering the ventricle's cavities like a coherent cortex. To this cortex are attached inwardly bundles of different arrangements and directions which *in vivo* serve for the physiological dilatation and contraction of the subcavities of the complicated system of heart cavities.

In the ventricle, too, the endocardium consists of fibrous connective tissue whose loosely arranged collagenous fibre structure is traversed by elastic fibres. Endothelial cells, lining the inner surface of the connective tissue in a simple layer, are elongate and flat, forming a pouch only where their nuclei are located. The layers of the ventricle wall are richly supplied with nerves. In thicker nerve trunks passing within the epicardium as well as in the nerve bundles exiting therefrom,

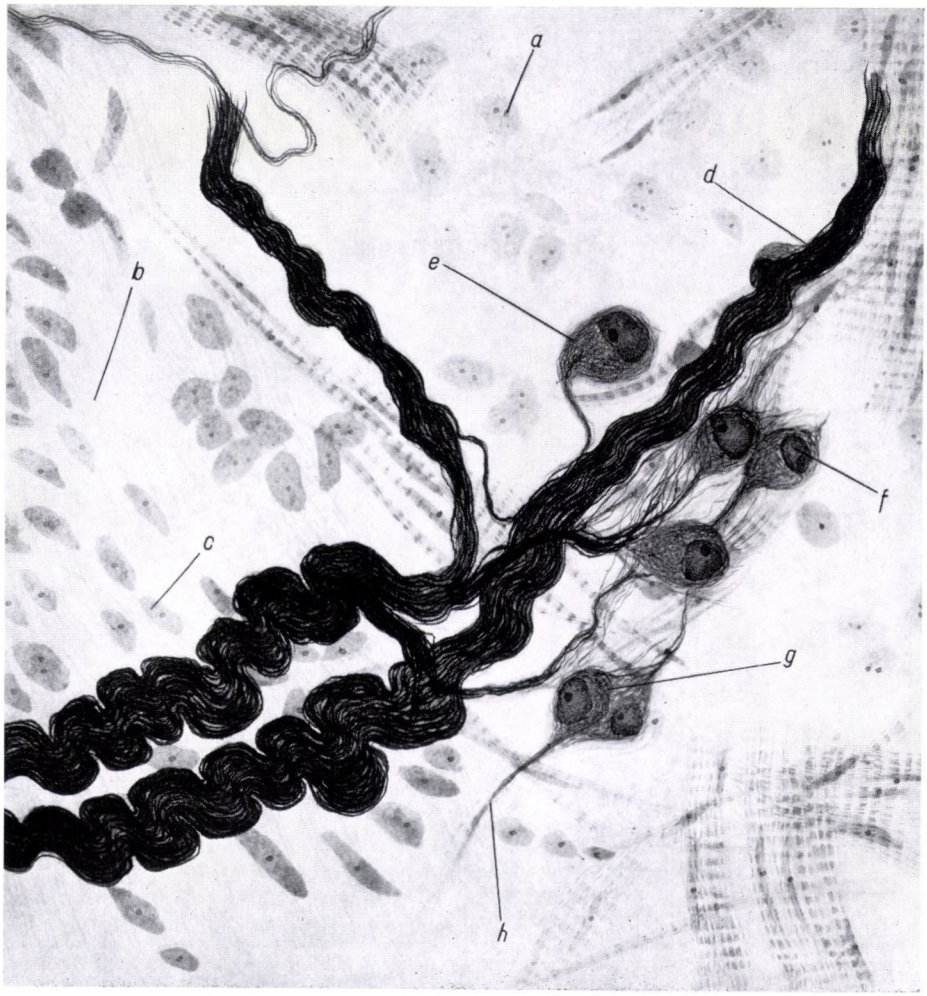

FIG. 19. *Salamandra maculosa*. Heart; nerve fibre plexus in the atrial epicardium. (a) Nucleus of epithelial cell; (b) connective tissue; (c) nucleus of connective tissue cell; (d) nerve bundle; (e) nerve cell; (f) nucleus of nerve cell; (g) neurofibril; (h) process of nerve cell. Bielschowsky–Ábrahám's method. Microscopic magnification 150×, reduced photographically to ½

myelinated fibres are also seen which, after loosing their myeline sheath, gradually mingle with the sympathetic fibres.

The epicardium is traversed by loose nerve plexuses whose end fibres terminate here and there in well-visible end rings. As a matter of fact, the end rings are but infrequently seen. If they are there at all they are, however, quite conspicuous. Their location and shape both suggest that together with the end rings seen in the atrial epicardium they are functioning as receptors of the heart wall. The end

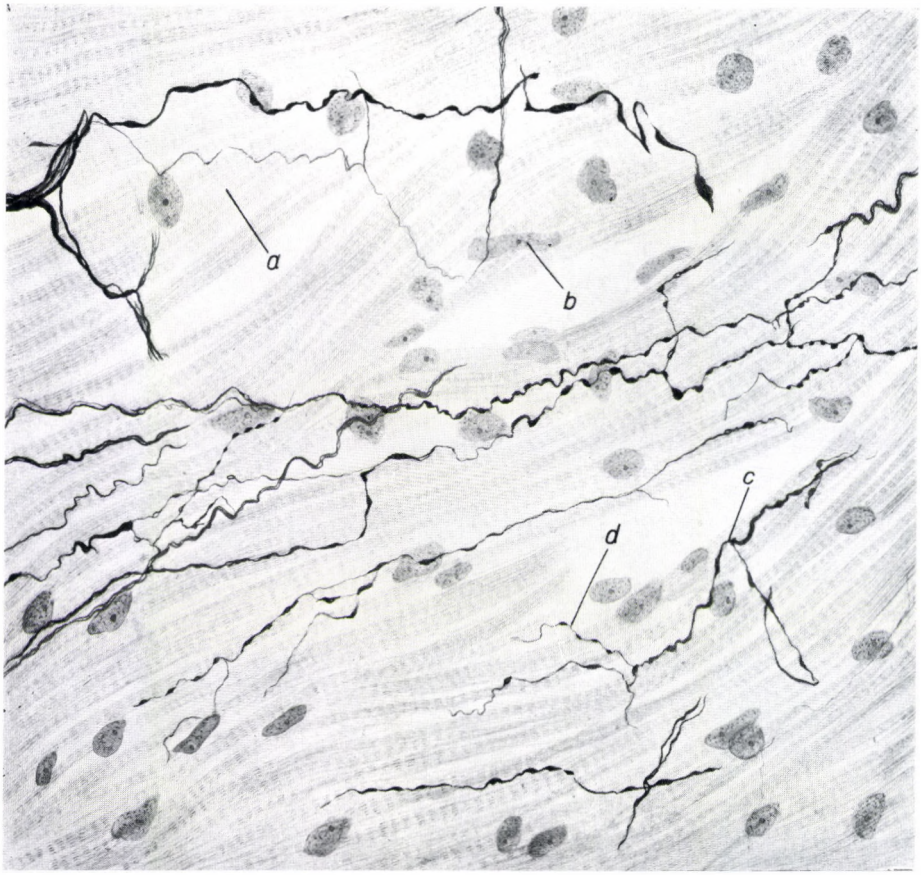

FIG. 20. *Rana ridibunda*. Heart; nerve fibre plexus in the ventricular wall, 20 hr after bilateral vagotomy. (a) Striated muscle fibre; (b) nucleus of striated muscle fibre; (c) nerve fibre; (d) degenerating nerve fibre. Bielschowsky–Ábrahám's method. Microscopic magnification 600×, reduced photographically to ½

rings detected in the epicardium and occasionally also in the endocardium may well be considered the first appearance of the receptor system in the vertebrate heart which, emerging upwards in the system, gradually grows and multiplies making its appearance in the mammals in the form of complicated nerve end apparatuses. In the epicardium, numerous ganglia and along the nerve trunks nerve cells are seen (Fig. 19).

The ventricular myocardium is rich in fibres. Nerve trunks of varying size, exiting from the region of Bidder's ganglion, go mostly dorsally in the cortex of the muscular layer. Nerve fibres, too, are of varying thickness, their path being either straight or often winding like a spiral. Not infrequently quite thick fibres are seen, occasionally also their myeline sheath is well visible. As a rule, thick fibres

are accompanied by particularly thin ones which either run adjacent to them or which traverse their path winding to and fro and forming loops. The path of thin fibres is not quite straight in some muscular columns. Sometimes they form a loop and continue their path in the opposite direction. Also, such fibres occasionally thicken in a given area, then become thin and descend among the muscular columns without further demonstrable changes in their diameter (Fig. 20). In other cases varices of varying size are seen at nearly regular distances both on thick and thin fibres. Sometimes the varices are elongate and sometimes roundish or ovoid in shape. It is of interest that in one and the same microscopic picture the different fibres show a dissimilar appearance of varices and few of them carry no varices at all.

The endocardium is markedly rich in nerve fibres particularly at the exit of the heart bulb from the chamber. The nerve fibres form well-visible plexuses especially adjacent to the myocardium; in these plexuses some of the fibres show distinct end rings. The number of rings is high in certain regions: in some of them discs are seen adjacent to each other. Like similar structures in the epicardium and endocardium, these discs seem to constitute the receptors of the heart wall.

Heart Bulb (Bulbus cordis)

The heart bulb arises from the left muscular region of the ventricle wall. Its base is thick and it narrows slightly cranially and continues in the arterial trunk. The epicardium exhibits the usual structure and adjacent to it extends the myocardium which consists of striated muscle fibres and as such has to be considered a true portion of the heart. Its muscles are highly developed and consist mainly of circular bundles. Towards the lumen the muscles are bordered by a 30–40 μ thick elastic membrane containing also collagenous fibres. The innermost layer is a typical endocardium.

The epicardium is traversed by larger nerve trunks consisting of myelinated fibres and bare axons. From the trunks exit rami of varying size containing fibres of different thickness. The fibres gradually branch to form delicate end plexuses. Here again many of the delicate fibres constituting the end plexuses have been found to terminate in end rings.

The myocardium is practically interwoven with nerve fibres of varying thickness. Between the different layers of striated muscle fibres nerve plexuses of variable appearance are seen. Some of them show a markedly loose plexus. All of them contain thick fibres which here and there exhibit pouching as well as conspicuously thin ones running occasionally adjacent to the path of the thick fibres. At the ending of some thin fibres, but also along their path, end rings are frequently seen, sometimes even being aggregated in groups.

Beside the loose plexuses there are some constituted by many nerve fibres. Dense plexuses are seen mainly in regions where the muscular tissue borders directly on the endocardium. Fibres constituting the dense plexuses are mostly thin thus lending them the appearance of an end plexus. Within the plexus some



FIG. 21. *Rana ridibunda*. Heart; nerve fibre plexus in the wall of bulbus cordis. (a) Connective tissue; (b) nucleus of connective tissue cell; (c) striated muscle fibre; (d) nucleus of striated muscle fibre; (e) nerve fibre; (f) nerve ending. Bielschowsky–Ábrahám's method. Microscopic magnification 600×, reduced photographically to ½

fibres run a markedly undulating, sometimes even zigzag path. Most of the fibres are free of varices, but numerous end rings are apparent. Some of these are located actually at the fibres' ends, while others are found along their descent, either singly or in pairs. In every case, the latter have been identified as end rings whose interconnection with the nerve fibre is either inconspicuous or on the other hand its connecting branch is well visible at a higher magnification (Fig. 21). The proximity of the plexus to the endocardium and the extensive system of end rings are both suggestive of the presence of a rich sensory system functioning in the bulbar wall as a receptor apparatus. In view of the system's location and structure there is reason to suppose that actually it constitutes a depressor afferent system similar to that found in the aortic arch of higher vertebrates.

Nerve Endings of the Myocardium

The question arises how the nerve fibres traversing all parts of the myocardium would conjugate with the striated muscle fibres. This question has already been put several times and answered in various ways in the past. The discrepancy of opinions should be ascribed on one hand to the dissimilarity of methods employed and on the other hand to hypotheses derived from opposed schools of thought. Before stating our position it is worth while to survey the theories advanced in this context.

Studying preparations treated with gold and osmic acid, Ranvier (1880) concluded that in the frog's heart the nerve fibres enter the muscle fibres yet do not terminate therein but pass into the adjacent muscle fibres. Openchowsky (1883), examining hearts of amphibia by gold treatment found that nerve fibres terminate on the muscle fibres in end rings and never penetrate the muscle fibres.

Later on Jacques (1894) and Smirnow (1890), using Ehrlich's and Golgi's method for examination of the myocardium in the frog's heart, supported Openchowsky's concept.

Hofmann (1902), being closer to Ranvier's opinion, stated that the nerve fibres did not enter the myocardial muscle fibres, nor did they end freely but formed a coherent closed plexus.

Michailow (1908), who employed a modification of Ramòn y Cajal's method for the study of the frog's heart, established that the nerve fibres end freely between the myocardial muscle fibres, yet the neurofibrils pass further and end nowhere.

Refraining from further references, we try to outline our concept below as derived from observations on our own preparations. As already mentioned, nerve fibres interweaving richly in all parts of the myocardium are gradually branching off. These ramifications give rise to very thin end fibres packed with delicate varices terminating within the muscle fibres iredctly under the sarcolemma. That nerve fibres actually end there can be clearly seen in all good preparations. Another question is whether these end rings are located inside the muscular fibre or are merely attached to the sarcolemma's surface. In this respect the light microscope allows no definitive information. Yet we believe we might surely rely on a general observation made in connection with all nerve endings studied, viz. the position of the end ring to the muscle fibre's nucleus in the microscopic picture. If the nerve end ring and muscle cell nucleus are both clearly visible at a given adjustment of the microscope, this implies that both of them are located within the muscle cell's protoplasm. As this phenomenon was repeatedly observed in the course of our studies we have considered it a further support for our position stated already in 1937 that nerve fibres terminate hypolemmally in end rings within the myocardial muscle cells.

Origin of the Intracardiac Nerve Fibres

Nerve fibres supplying the heart wall arise partly from the vagus, partly from the cervical sympathetic and partly from the intracardiac ganglia. Concerning the nature of fibres innervating the individual histological layers of the heart wall we

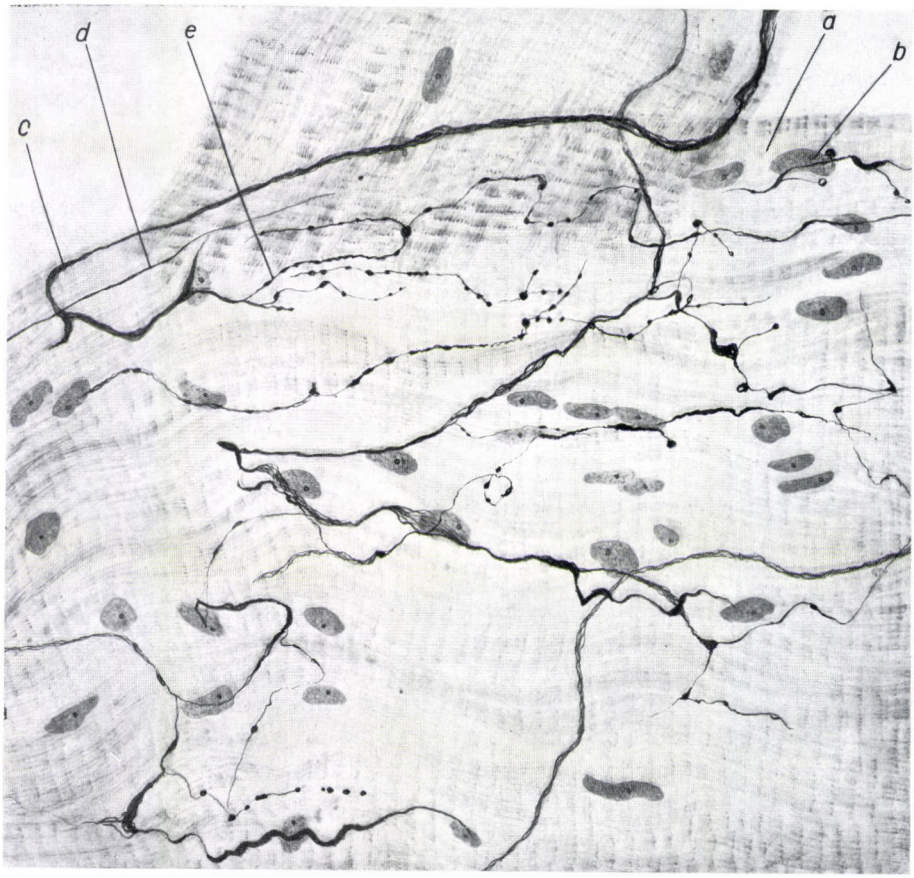

FIG. 22. *Rana ridibunda*. Heart; degenerating nerve plexus in the ventricular wall, 20 hr after bilateral vagotomy. (a) Striated muscle fibre; (b) nucleus of striated muscle fibre; (c) nerve fibre bundle; (d) nerve fibre; (e) degenerating nerve fibres. Bielschowsky–Ábrahám's method. Microscopic magnification 600×, reduced photographically to ½

are restricted to theoretical considerations. In this context it seems to be natural to assume that nerve fibres supplying the epicardium and endocardium all arise from the vagus whereas those supplying the myocardium might arise from the other two sources as well. Nevertheless, normal nerve pictures do not permit a differentiation of the source of the individual nerve fibres in the myocardium. In any case it seems to be fairly certain that the thick myelinated fibres seen everywhere in the heart wall's myocardium belong to the vagal sensory system. It must not be stated, however, that non-myelinated fibres are partly sympathetic fibres and partly postganglionic fibres of the intracardiac ganglia as the central efferent vagal fibres should additionally be taken into consideration.

To approach this problem more closely, a further series of experiments was performed. The right or left vagus of a number of large frogs (*Rana ridibunda*) was cut immediately below the jugular ganglion. Frogs, particularly the females, tolerated this intervention very well; the vagus of the other side was then also cut either in immediate sequence or simultaneously. In the latter case mortality was relatively high, yet many of the frogs survived for 20, 30, 40 or even 50 days after bilateral vagotomy. In the operated animals degeneration of the ventricular myocardium was found to have started 20 hr after bilateral vagus intersection. In the more delicate fibres, namely in end fibres, typical granulation was seen and later on most of the fibres decomposed and disappeared (Fig. 22).

The above experiments revealed degeneration not only in the nerve fibres supplying the atrial myocardium but also in those supplying the ventricular myocardium. This implies that the central vagal fibres also go into the ventricular myocardium. Hence it is very likely that not all vagal fibres terminate in the ganglia located within the venous sinus but that some of them traverse the ganglia and end in the ventricle. This phenomenon is, however, explicable also by assuming that all nerve fibres of the ventricular myocardium are postganglionic fibres that degenerate after a bilateral vagotomy owing to the absence of impulses through the degenerating preganglionic fibres.

Ganglia

In the frog's heart three larger ganglia are present, viz. Remák's ganglion in the venous sinus, Ludwig's ganglion in the lower portion of the right atrial wall and the two ganglia of Bidder, situated left and right along the atrial septum (septum atriorum). These ganglia are actually plexuses containing nerve cells. Nerve cells are relatively large, with a single process, within which the neurofibrils are occasionally very clear. The broad process either branches off gradually, or narrows and enters a nerve trunk. Part of the cells are characterized by association with a spiral fibre or a pericellular basket. Observations, experimental results and theoretical considerations all indicate that the latter are synapses in the sense of Kirsche's concept viz. synapses with a large transmission area. Further to this, in some cells, namely in those comprised in the interseptal nerves, there are knots of varying dimensions which owing to their shape and location may be considered synapses with small transmission area (Fig. 23).

Nerve cells located in the three large plexuses denominated as ganglia and also those located along the nervus septalis dorsalis and nervus septalis ventralis display an intensive cholinesterase activity restricted, however, to the surface of the cell and its process. This observation confirms the morphological implication that these cells belong to the system of the vagal nerve.

In the ganglia there are also nerve cells in which this enzymic reaction is absent. These are regarded as of sympathetic origin (Fig. 24). In preparations stained with Gömöri's chromohematoxylin-phloxin granules of smaller or greater size were occasionally demonstrable; however, they cannot be considered neurosecretion

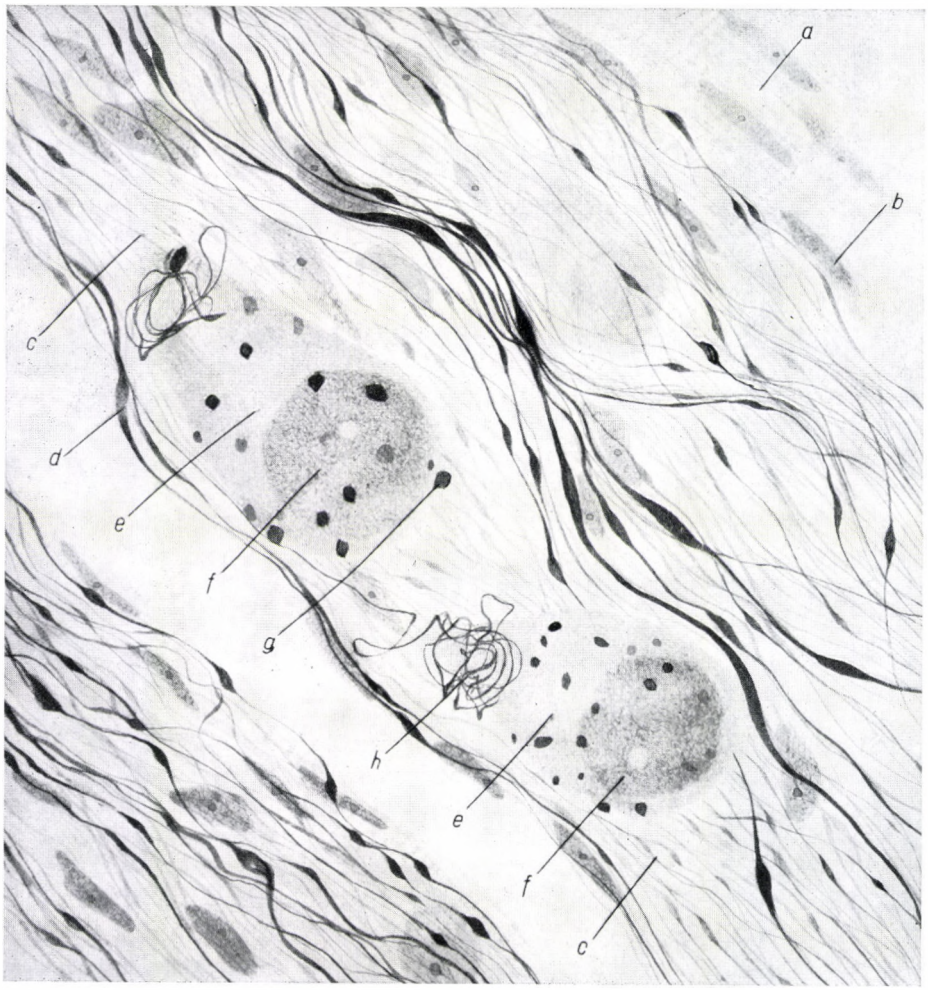

FIG. 23. *Rana ridibunda*. Heart; synapses in the atrial septum. (a) Striated muscle fibre; (b) nucleus of the striated muscle fibre; (c) nerve fibre; (d) varix; (e) nerve cell; (f) nucleus of the nerve cell; (g) end knob; (h) pericellular spiral. Bielschowsky–Ábrahám's method. Microscopic magnification 1350×, reduced photographically to ½

material at all. First of all the number of the granules is very variable in the single cells and granules were not to be found along the process of the cell. According to the literary data and our experience concerning the insect brain (Dytiscus marginalis) one could speak about neurosecretion only in such cases if it is evident that the granules produced in the cell body are evacuated from the cell. In such a sense we could not speak about neurosecretion in the ganglion cells in the heart of the frog nor in general in the cells of the whole sympathetic nerve system.



FIG. 24. *Rana ridibunda*. Localization of acetylcholinesterase activity in the nerve plexus of the atrial septum. (a) Nerve cells; (b) nerve bundle; (c) nerve fibre. Microphotography

Pericardium

The pericardium is an extraordinarily thin connective tissue membrane which readily peels off from the heart. It contains many pigment cells and elastic fibres. Here and there the latter accumulate in masses and after staining with resorcin–fuchsin these areas seem to be quite black. The pericardium is richly innervated. The smaller and larger nerve bundles, and the single fibres derived from them constitute a loose plexus (Fig. 25). Some of these fibres are thick, others quite thin. Their appearance suggests that thick fibres have a sensory function, whereas thin ones serve for vascular innervation. No sensory endings were found.

REPTILES (REPTILIA)

In reptiles, the heart is situated in the anteriormost part of the body ventrally in the middle line. Its parts are the venous sinus, two atria and two ventricles. The innervation of the individual parts was studied microscopically on animals easily accessible to us: steppe monitor (*Varanus griseus*), common snake (*Tropi-*

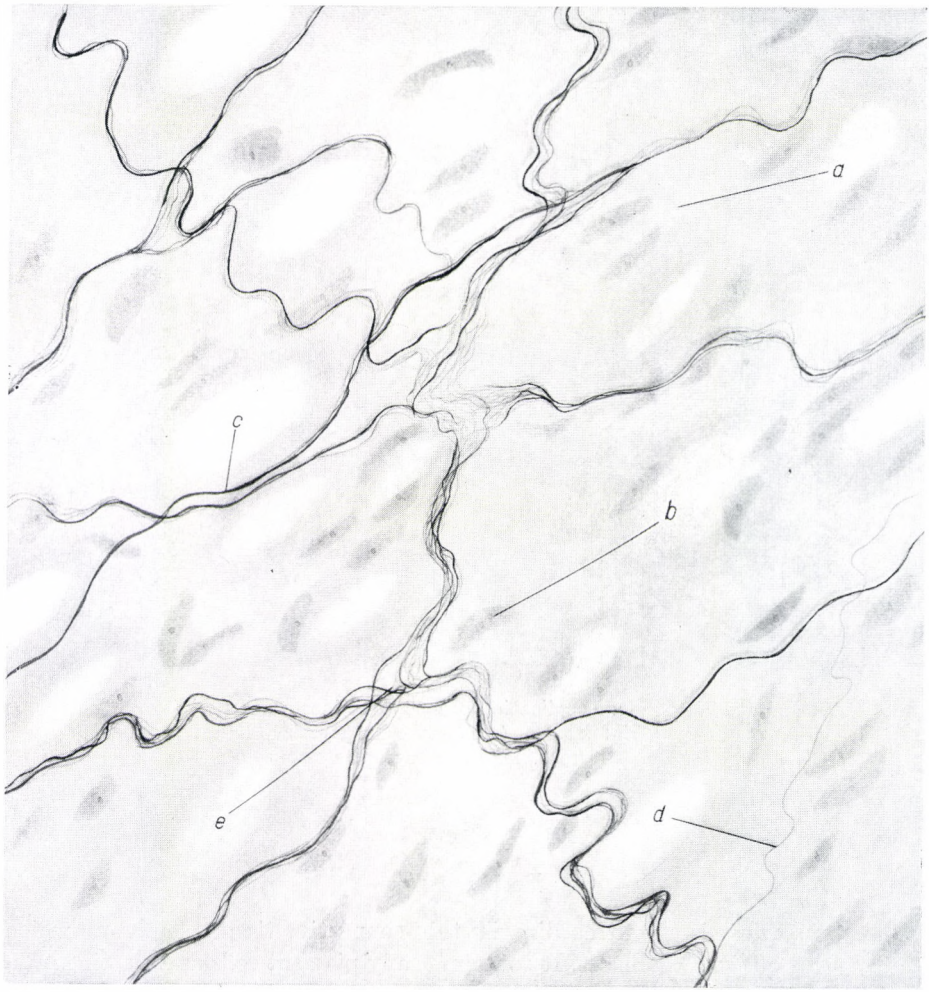

FIG. 25. *Rana ridibunda*. Heart; nerve plexus in the pericardium. (a) Bundle of connective tissue fibres; (b) nucleus of connective tissue cell; (c) thick nerve fibre; (d) thin nerve fibre; (e) nerve plexus. Bielschowsky–Ábrahám's method. Microscopic magnification 400×, reduced photographically to ½

donotus natrix), regal python (*Python reticulatus*) and the pond tortoise (*Emys orbicularis*).

For the impregnation of heart specimens Bielschowsky–Ábrahám's and Jaboneo's methods proved to be most helpful. In this context it is noted that the impregnation of the pond tortoise's heart was particularly successful when uni- or bilateral vagotomy was performed in the living animals. Vagotomy was easily performed and as a rule the tortoises tolerated the operation well. Only the frequent fits of transitory asphyxia interfered notably with the normal life of the animals. In some



FIG. 26. *Emys orbicularis*. Heart; nerve fibre plexus from the root of the vena cava inferior. (a) Striated muscle fibre; (b) nerve cell; (c) thick nerve fibre; (d) thin nerve fibre; (e) nerve fibre plexus. Bielschowsky–Ábrahám's method. Microscopic magnification 600×, reduced photographically to ½

of them, post mortem examination revealed the development of enormous diverticula in the oesophagus. The animals survived for several months after bilateral vagotomy.

In the following we discuss separately the innervation of the individual heart parts with proper reference to some histological aspects.

Venous Sinus (Sinus venosus)

The venous sinus is, as in amphibia also in reptiles, essentially a continuum of the venous wall and markedly rich in nerve fibres. Different nerve trunks and bundles were found in large numbers in all three layers, particularly in the

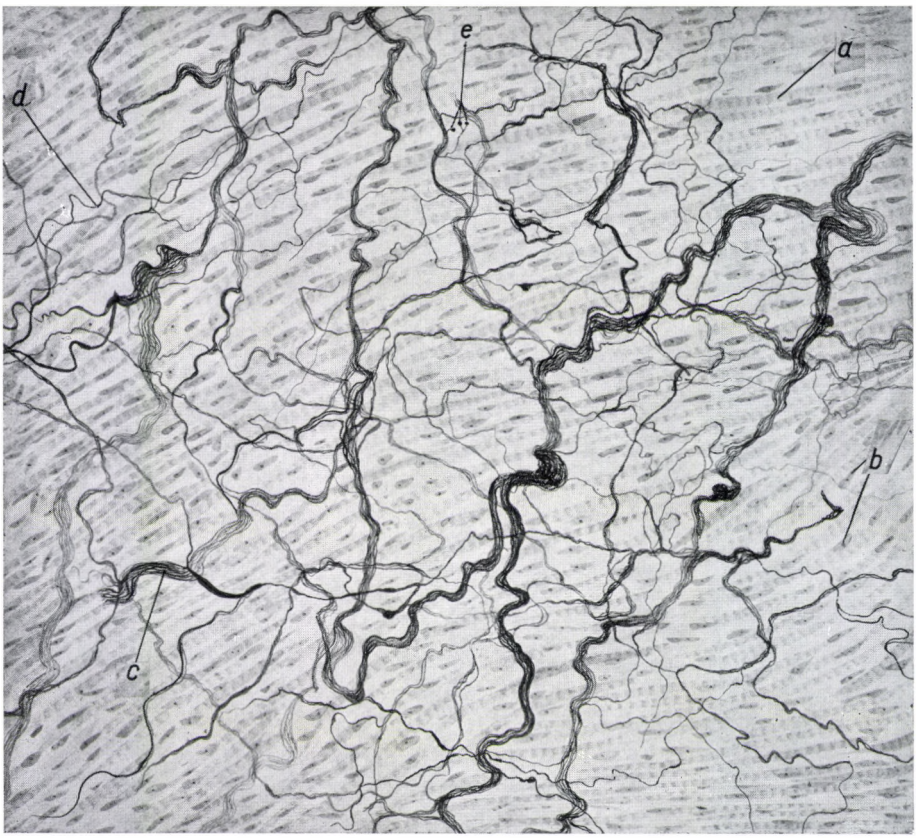

FIG. 27. *Varanus griseus*. Myocardial plexus in the right atrium. (a) Striated muscle fibre; (b) nucleus of striated muscle fibre; (c) nerve bundle; (d) nerve fibre; (e) nerve ending. Bielschowsky–Ábrahám's method. Microscopic magnification 600×, reduced photographically to ½

media. From the bundles arise smaller or larger rami from which exit the nerve fibres to form rich plexuses together with the thicker trunks. The extension and density of plexus vary in the individual layers in accordance with their functions. Thus the nerve plexus is richest in the adventitia, particularly in transition areas between smooth and striated muscles. In this plexus, ganglia and also larger nerve cells attaching to the nerve bundles are frequently seen. These cells, or chains of cells, are particularly conspicuous in the venous sinus of the tortoise, steppe monitor (*Varanus griseus*) and the regal python (Fig. 26).

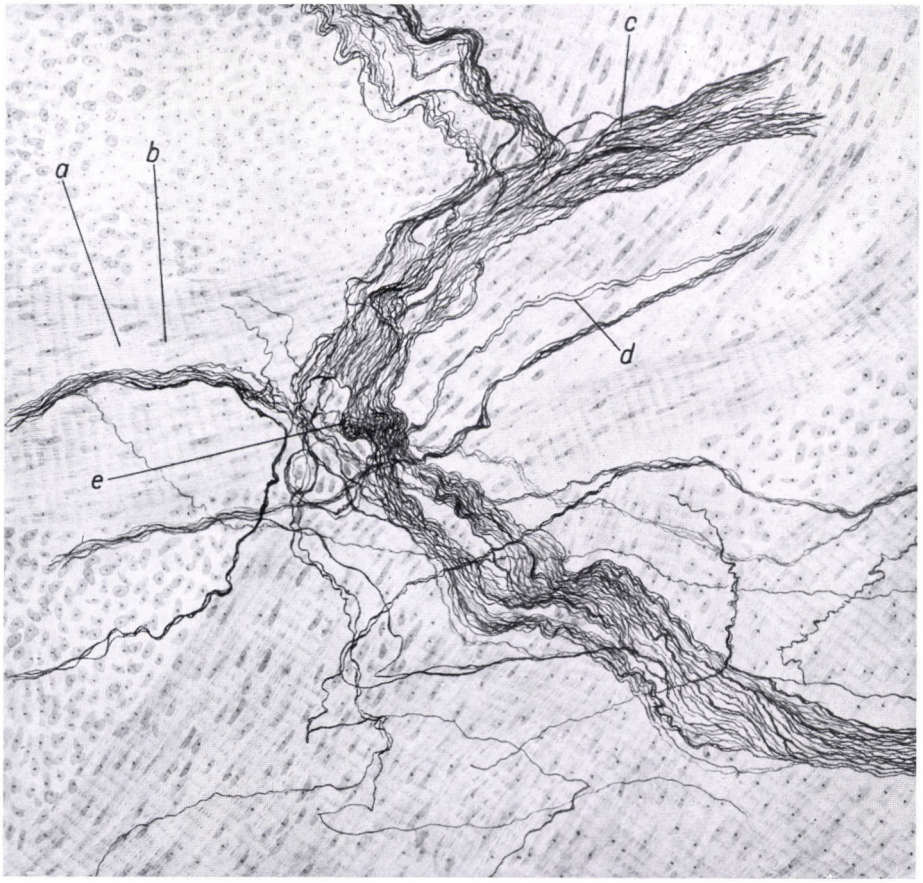

FIG. 28. *Emys orbicularis*. Nerve plexus in the right atrium. (a) Striated muscle fibre; (b) nucleus of striated muscle fibre; (c) nerve bundle; (d) nerve fibre; (e) nerve fibre plexus. Bielschowsky–Ábrahám's method. Microscopic magnification 600×, reduced photographically to ½

Atrium

In all reptiles examined, the atrial wall was relatively thin and as such suited for *in toto* impregnation. In this respect the most conclusive nerve pictures were obtained from the tortoise. The layers constituting the atrial wall are discussed below.

The epicardium is thin and consists of collagenous connective tissue fibres mingled with relatively numerous elastic fibres, namely in the region bordering the myocardium. From outside, the epicardium is covered by a simple epithelial layer. Between the connective tissue bundles there are nerve trunks of varying dimensions, consisting mostly of smooth undulating fibres. Among these fibres some thicker

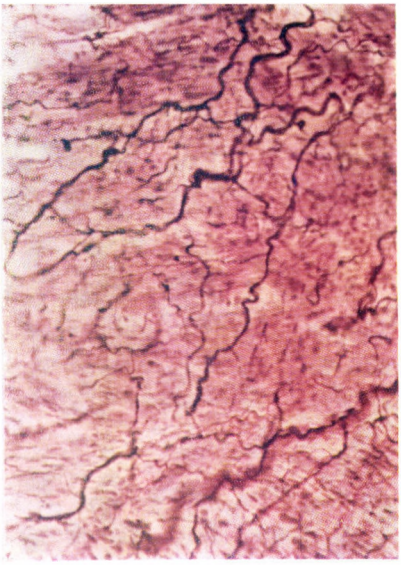

a



b

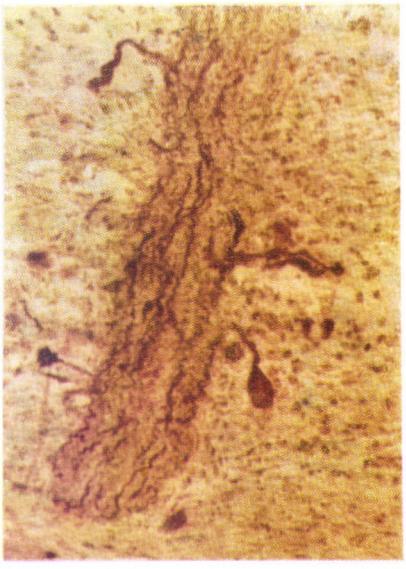

c

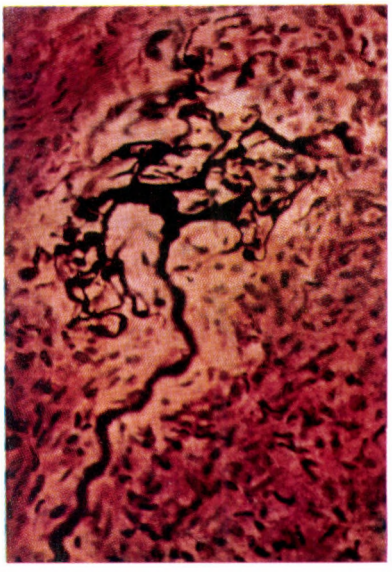

d

PLATE I

(a) *Varanus griseus.* Nerve plexus in the right atrial myocardium
(b) *Ovis aries.* Loops of the vessels in the sclero-corneal junction; innervation
(c) *Sus scrofa domestica.* Heart; sensory nerve end plates at the border of the sinoatrial node
(d) *Sus scrofa domestica.* Aortic arch; receptor in the adventitia

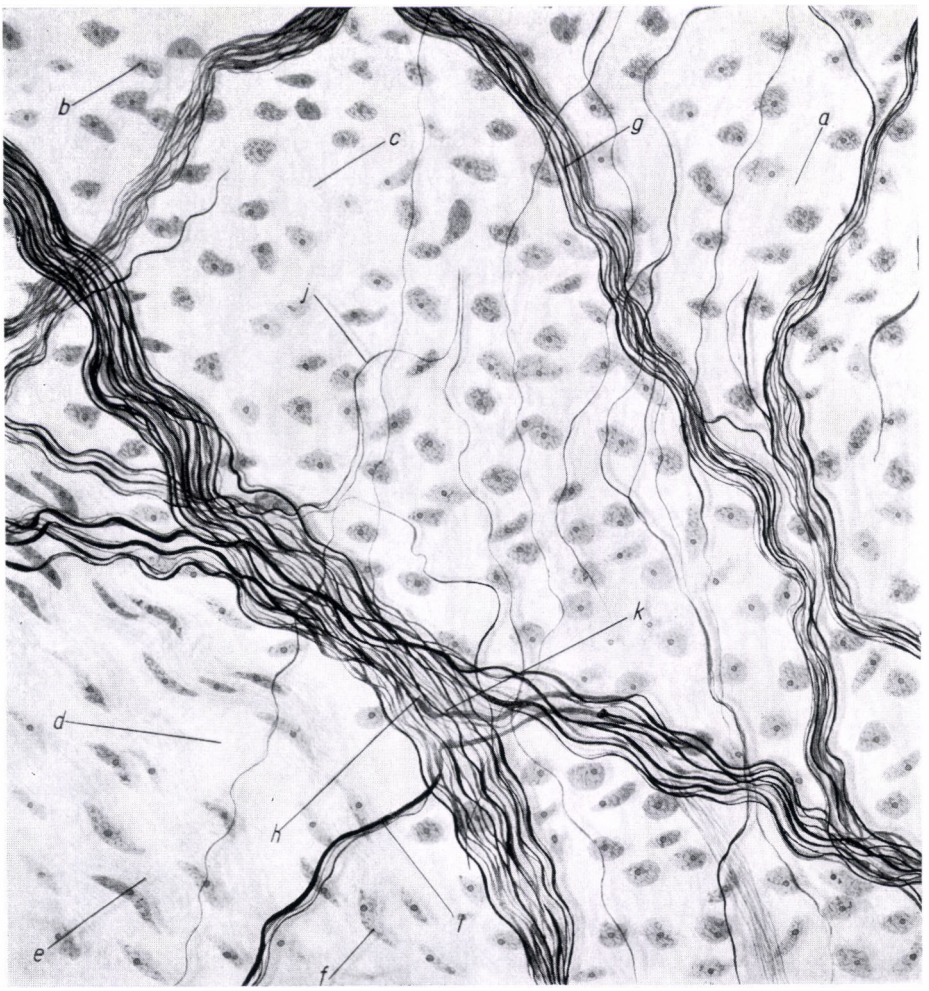

FIG. 29. *Python reticulatus*. Heart; nerve plexus in the atrial endocardium. (a) Connective tissue; (b) nucleus of the connective tissue cell; (c) connective tissue fibre; (d) striated muscle tissue; (e) striated muscle fibre; (f) nucleus of the striated muscle fibre; (g) nerve bundle; (h) nerve plexus; (i) thick nerve fibre; (j) thin nerve fibre; (k) branching. Bielschowsky–Ábrahám's method. Microscopic magnification 640×, reduced photographically to ½

ones, presumably of vagal origin, are also seen. Here and there they conjugate with the connective tissue bundles by fine varicose branches. The nature of this connection remains to be investigated. In our preparations we consistently failed to identify nerve endings that would suggest a sensory function of the fibres in question. However, the shape and location of the ramifications are indicative of their receptor function.

The myocardium consists of striated muscles arranged in bundles. The bundles ramify and their branches anastomose giving rise to a very dense muscular texture. In the atrial regions the myocardium is trabecular; from the dense muscular network the trabeculae extend into the lumen. The inter-trabecular areas of the atrial wall are very thin and consist only of connective tissue through which the epicardium and endocardium are linked with each other.

The atrial myocardium is extremely rich in nerves, particularly when compared to the ventricular myocardium which, mostly in snails, is far less well supplied than is the atrium (Fig. 27, Plate I/a, p. 48). The rich innervation is particularly conspicuous in the right atrium of tortoises, traversed by enormous nerve trunks that conjugate to form a dense network. Within the trunks there are roughly uniform, smooth fibres of undulating descent, mingled with some elongate varicose fibres surpassing them in length. Among the interconnected trunks and bundles thinner rami and single fibres are frequently seen, occurring in masses mainly along the larger trunks and occasionally connecting with them to form a rich plexus (Fig. 28). Also, in the wall of the right atrium, large unipolar nerve cells often occur inside the plexuses or along them. In the overwhelming majority of cases the process of nerve cells located along the plexus is seen to enter therein and to continue its path between the fibres.

The atrial endocardium is extraordinarily thin and consists of collagenous connective tissue bundles containing some elastic fibres. Towards the lumen the endocardium is bordered by endothelium. This layer is innervated by a loose nerve plexus constituted by smooth undulating fibres and also by some thicker fibres and tree-like ramifications (Fig. 29).

Atrial Septum (Septum atriorum)

The structure as well as the innervation of the atrial septum are of particular interest. Its thickness depends on the dimensions of the heart. In general it is thin enough for total impregnation. Essentially it is a duplicate of the myocardium and endocardium. The myocardium is trabecular. Between the trabecules there are large connective tissue lattices traversed here and there by thinner bundles of muscle fibres.

The atrial septum is fairly rich in nerves. It is traversed by a plexus of large nerve bundles along which giant ganglia are seen. In addition to the ganglia, smaller and larger groups of nerve cells are present either inside or outside the trunks. Similarly to those described in connection with the innervation of the venous sinus wall these cell groups also consist of large roundish unipolar cells (Fig. 30). Beside nerve trunks and bundles there are many single nerve fibres exiting from the trunks to form a rich plexus inside the bundles of striated muscle. Some fibres of the plexus are closely associated with the muscle fibres, terminating hypolemmally in end rings. We shall revert to this question in context with nerve interconnections in the ventricular myocardium (Fig. 31).

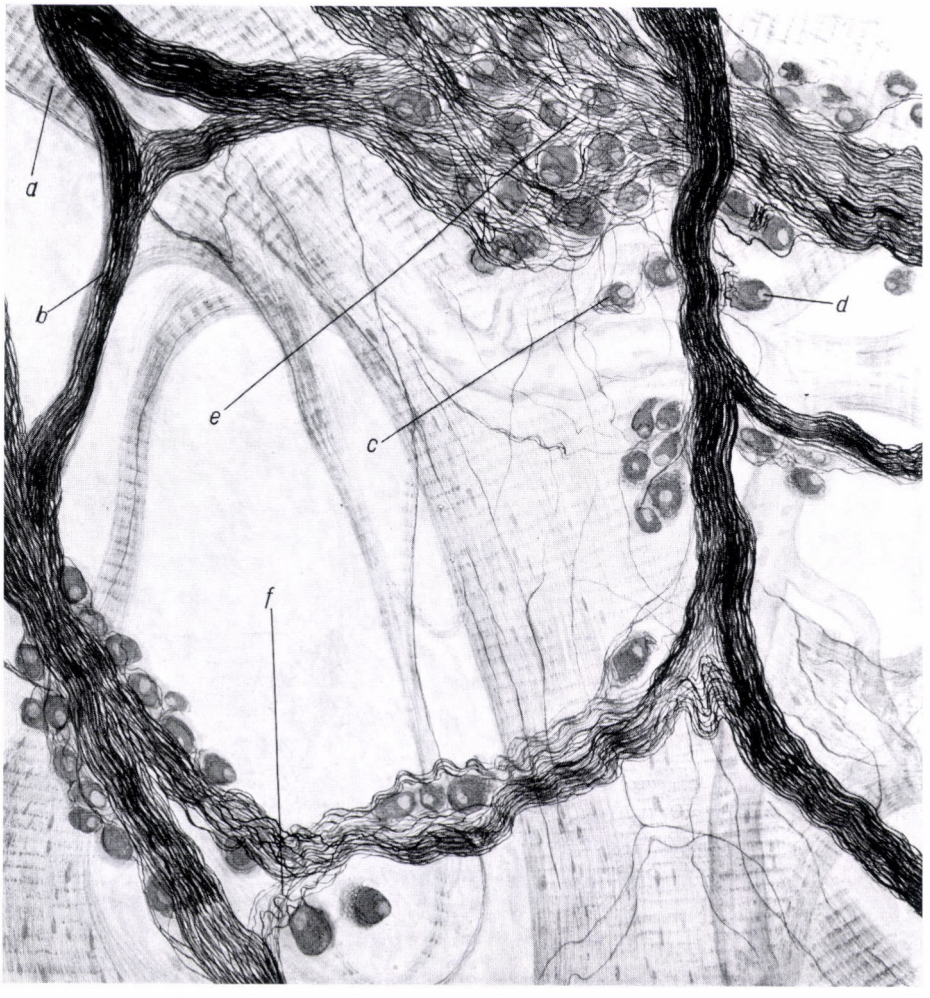

FIG. 30. *Emys orbicularis*. Heart; nerve fibre plexus in the atrial septum. (a) Striated muscle fibre; (b) nerve fibre bundle; (c) nerve cell; (d) nucleus of the nerve cell; (e) ganglion; (f) nerve plexus. Bielschowsky–Árbahám's method. Microscopic magnification 120×, reduced photographically to ½

Ventricle (Ventriculus)

The walls of the ventricles are thicker than those of the atria thus permitting the separation of the individual layers more readily. The ventricular epicardium consists of collagenous connective tissue fibres traversed by elastic fibres. It is richly innervated similarly to the atrial epicardium. The plexuses are loose, broad-meshed, comprising also thick fibres.

The ventricular myocardium consists of compactly arranged bundles of striated muscle fibres. It contains numerous arteries of varying dimensions as well as veins

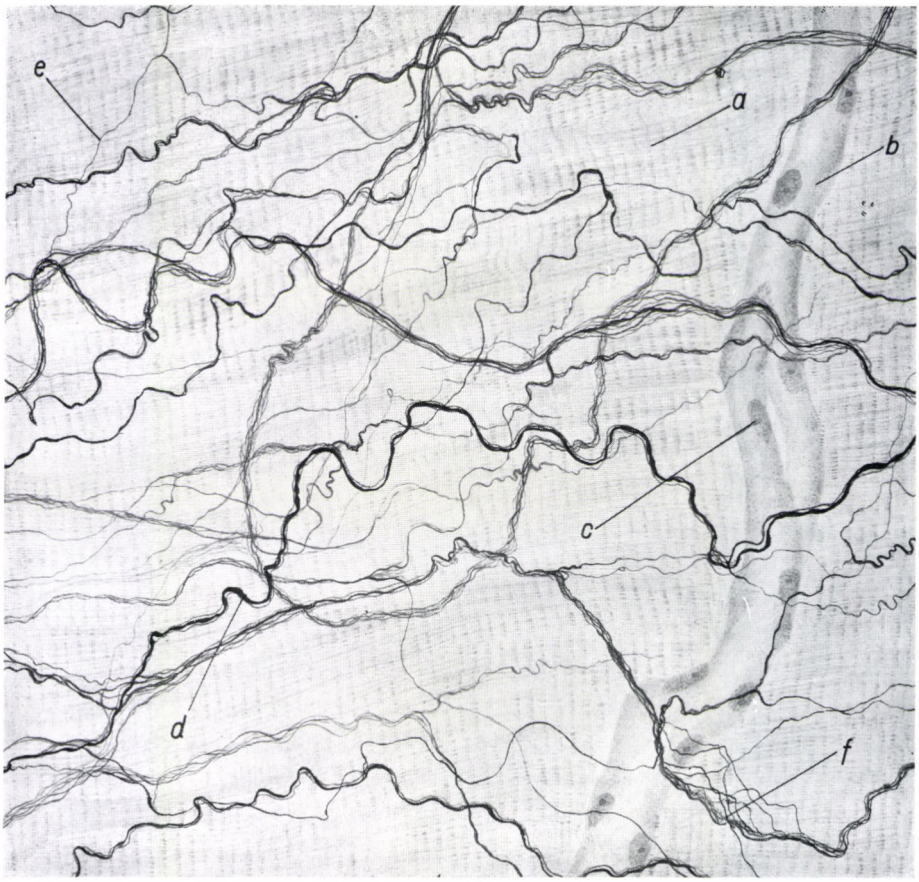

FIG. 31. *Emys orbicularis*. Nerve plexus in the atrial septum. (a) Striated muscle fibre; (b) capillary vessel; (c) nucleus of endothelial cell; (d) thick nerve fibres; (e) thin nerve fibres; (f) nerve fibre plexus. Bielschowsky–Ábrahám's method. Microscopic magnification 600×, reduced photographically to ½

and capillaries. Its innervation differs greatly in the various representative species of this group of animals. As a matter of fact, these differences may depend also on the success of impregnation; thus one should be careful about conclusions. According to our own experience, in lizards and snails the innervation of the ventricular myocardium is poor, large nerve trunks and bundles usually could be seen between the muscle bundles. In lizards and snails, however, only a few nerve branches and single fibres were seen in the myocardium, delicate plexuses being absent. Most of the fibres are thin and smooth-bordered, their diameters remaining unaltered throughout. Adjacent to the ventricular apex, however, exceptionally thick fibres may be seen descending usually alone and yielding to impregnation only in portions as a result of their winding path. A rich supply of nerve fibres is

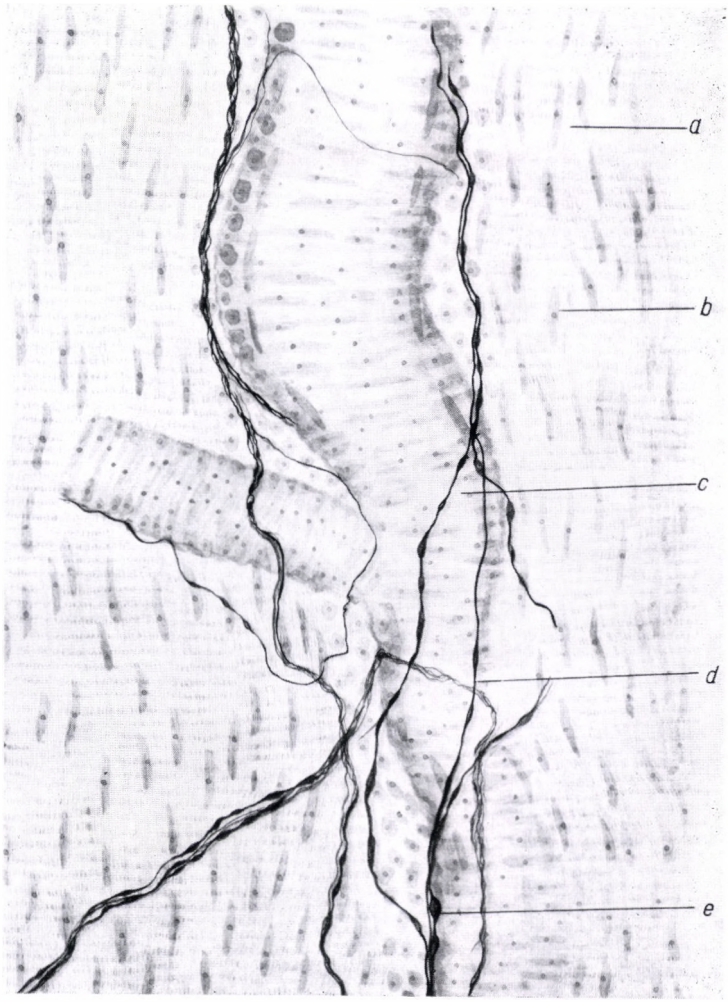

FIG. 32. *Python reticulatus*. Heart; nerve fibres in the left ventricular myocardium. (a) Striated muscle fibre; (b) nucleus of striated muscle fibre; (c) artery; (d) nerve fibre; (e) varix. Bielschowsky–Ábrahám's method. Microscopic magnification 600×, reduced photographically to ½

present along the large arteries of the myocardium. In these areas nerve fibres and bundles are numerous not only on the arterial walls but also around them. In the nerve bundles characteristic varicose fibres are apparent. It was found that in examined lizards and snails, the nerve fibres supplying the ventricular myocardium run along the larger blood vessels (Fig. 32).

In the tortoise, the ventricular myocardium was found to be fairly or even extraordinarily rich in nerve fibres. This applies to both vagotomized and normal animals. In the ventricular myocardium of these animals, particularly in the right



FIG. 33. *Emys orbicularis*. Nerve fibres and nerve endings in the wall of the right ventricle, 17 days after bilateral vagotomy. (a) Striated muscle fibre; (b) nucleus of striated muscle fibre; (c) thick nerve fibre; (d) thin nerve fibre; (e) nerve end ring. Bielschowsky–Ábrahám's method. Microscopic magnification 1350×, reduced photographically to ½

one, an enormous mass of nerve fibres became apparent upon impregnation (Fig. 33). Many of these fibres were conspicuously thick, markedly winding and rich in neurofibrils.

Beside them there are also masses of thinner sharply bordered fibres and of fibres whose endings are very distinct. Evidently, the unexpectedly large mass and clear picture of innervation visible was brought about by the argentophilia due to vagal section.

The ventricular endocardium is a very thin, delicate connective tissue membrane bordered against the lumen by endothelium. In this layer, in the steppe monitor, phyton and tortoise as well, impregnation occasionally revealed a fairly fine nerve plexus containing beside thin fibres also some thick vagal ones.

Nerve Endings of the Myocardium

The question arises how the myocardial nerve fibres conjugate with the striated muscle fibres. This is of importance, not only in a general respect, but in view of the comparative nature of this study, an attempt should be made to answer this question in relation to reptiles. It ought to be mentioned in this context that so far the nerve endings have been demonstrably convincing enough only in the myocardium of the steppe monitor (*Varanus griseus*) and pond tortoise (*Emys orbicularis*). Without previous vagotomy, steppe monitor yielded preparations which definitely show that nerve fibres end on the muscle fibres by end rings. Such preparations were obtained from the right atrium of the steppe monitor's heart by silver impregnation.

Sections prepared from the pond tortoise's myocardium have generally clearly shown the termination of a part of nerve fibres in end rings on the muscle fibres. The same observation was made earlier by Boeke (1930). He believed the rings to be the end bulbs of vagal fibres. As to the sympathetic fibres he noted that they conjugate with the muscle fibres in the form of so-called basal plexuses. This concept proved generally valid for the animals in which extracardial heart nerves had been left intact. Nevertheless, the nerve pictures were largely dissimilar when bilateral vagotomy was performed. In such cases the end rings were seen in enormous masses and particularly clearly in the preparations. A thorough study of these pictures revealed that some of the end rings are smaller and paler, while the remainder are larger and sharper. This, as well as the enormous quantity of rings, implied that after vagotomy the endings of all the myocardial nerve fibres become visible and they are—as supposed by us from the beginning—actually end rings. This is further supported by the fact that in the preparations, in addition to the end rings nerve fibres also appear in enormous masses. Some of these fibres are thin, others thick. Thick fibres are characterized by elongate varices, frequent ramification and well-visible neurofibrils inside. Also, occasionally they assume a spiral-like shape indicating the start of degeneration. Smooth fibres are thin, roughly parallel in descent and here and there they form loose plexus.

In the extraordinarily rich myocardial plexus end rings are so numerous that not all of them should be regarded as vagal nerve endings. As a matter of fact, the explanation is somewhat difficult as in the tortoise the vagus and sympathicus descend separately, thus only the vagus was cut and the sympathetic was left intact. Nevertheless, it must not be disregarded that some sympathetic fibres are descending within the vagus' path. However, in lower vertebrates the extracardial heart nerves contain mainly fibres of vagal origin (Fig. 34). Anyhow, the unexpectedly large mass of nerve end rings seen in these preparations backs the supposition that the functional disconnection of vagal preganglional fibres produce conditions enhancing the argentophilia of myocardial sympathetic fibres. The masses of end rings seen in many of the preparations to form the continuity partly of thin and partly of thick fibres indicate that all myocardial nerve fibres of the tortoise's heart, viz. the central vagal fibres, sympathetic fibres descending in the vagal trunk as well as sympathetic fibres descending in the extracardial



FIG. 34. *Emys orbicularis.* Heart; nerve fibres and nerve endings in the wall of the right ventricle. (a) Striated muscle fibre; (b) nucleus of striated muscle fibre; (c) thick nerve fibre; (d) thin nerve fibre; (e) nerve fibre plexus; (f) nerve end knobs; (g) nerve end ring. Bielschowsky–Ábrahám's method. Microscopic magnification 1350×, reduced photographically to ½

sympathic trunk all terminate in end rings. Naturally, the same applies also to the postganglionic fibres arising from the ganglia and supplying the ventricular regions. It is, however, more difficult to determine the location of the nerve endings. Anyway, the uniformly sharp picture of end rings and of the nuclei of striated muscle fibres at a given microscopic setting indicates a hypolemmal position of the end rings. In our opinion this localization corresponds to the physiological role of the myocardium and is also supported by Tcheng's observation (1950) on the myocardium of mammals.

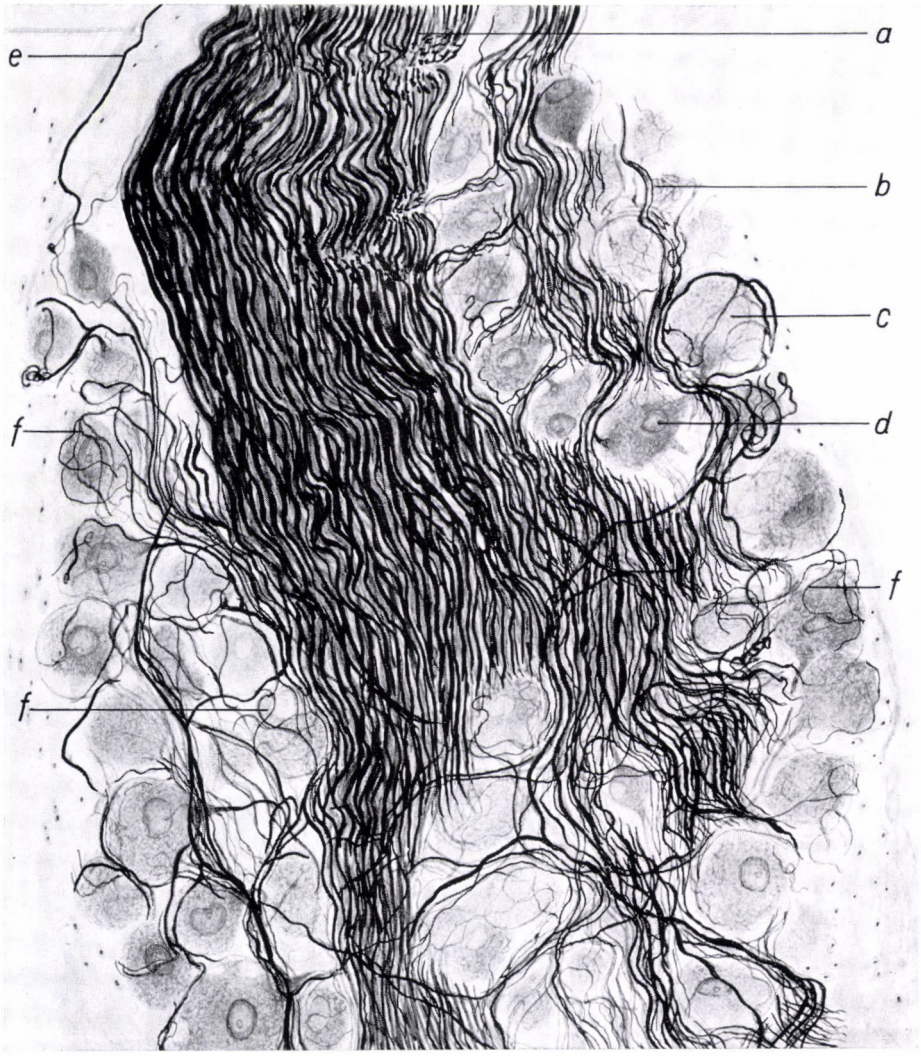

FIG. 35. *Varanus griseus*. Ganglion in the right atrial epicardium. (a) Nerve bundle; (b) nerve fibre; (c) nerve cell; (d) nucleus of the nerve cell; (e) process of the nerve cell; (f) pericellular basket; Bielschowsky–Ábrahám's method. Microscopic magnification 300×, reduced photographically to ½

Ganglia

In the heart of reptiles, ganglia are found only in the atrial walls and the atrial septum. As a rule, these ganglia are small. Larger ganglia were seen in the heart of the steppe monitor, whereas smaller ones in that of the regal python and pond tortoise. Particularly elongate ganglia have been detected in the heart of the common snake.

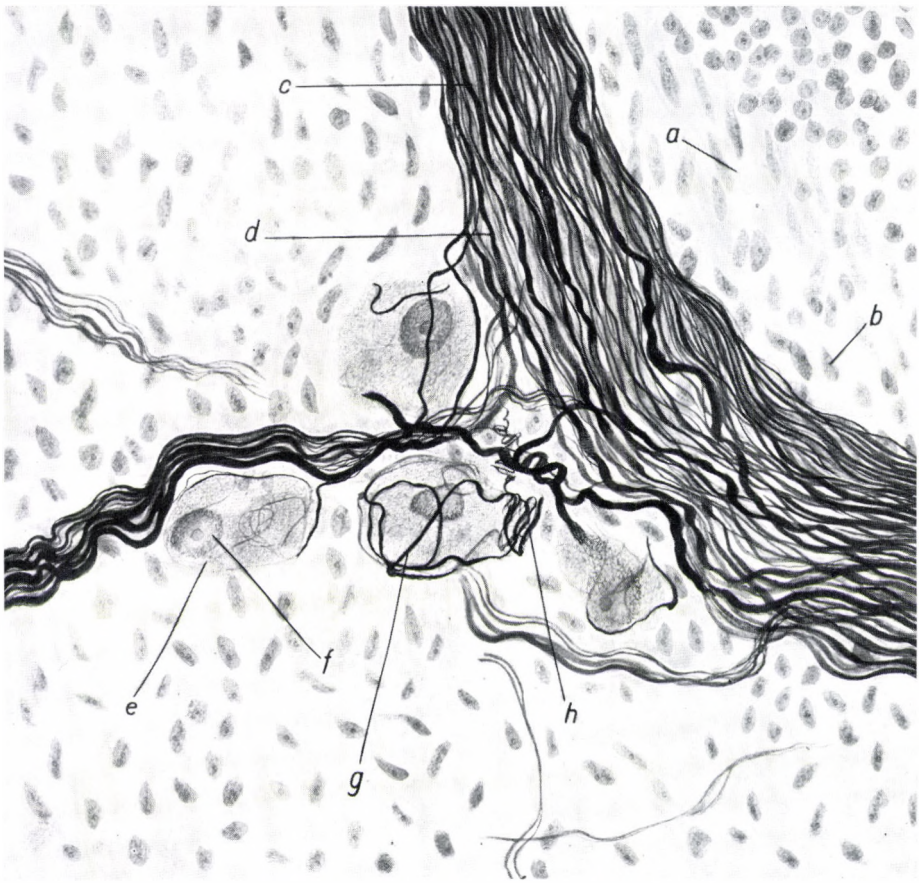

FIG. 36. *Python reticulatus*. Heart; nerve plexus in the right atrial epicardium. (a) Connective tissue fibre; (b) nucleus of connective tissue cell; (c) nerve bundle; (d) nerve fibre; (e) nerve cell; (f) nucleus of nerve cell; (g) pericellular basket; (h) preganglionic fibre. Bielschowsky–Ábrahám's method. Microscopic magnification 600×, reduced photographically to ½

In the steppe monitor (*Varanus griseus*) heart ganglia are broad and long, rich both in cells and fibres. The majority of cells are unipolar and carry a pericellular apparatus (Fig. 35).

Ganglia of the regal python (*Python reticulatus*) resemble those of steppe monitor but are much smaller in size. They are usually located in sites passed by larger nerve trunks whose bundles traverse the ganglia without interruption. Essentially these ganglia may be considered reserves or amplifiers joining to the nerve trunks their own fibres. The largest numbers of ganglia are seen in the heart of the pond tortoise, namely in the epicardium of the right atrial wall. In general these ganglia are small, loose, consisting of a few large cells. Bundles and single nerve fibres

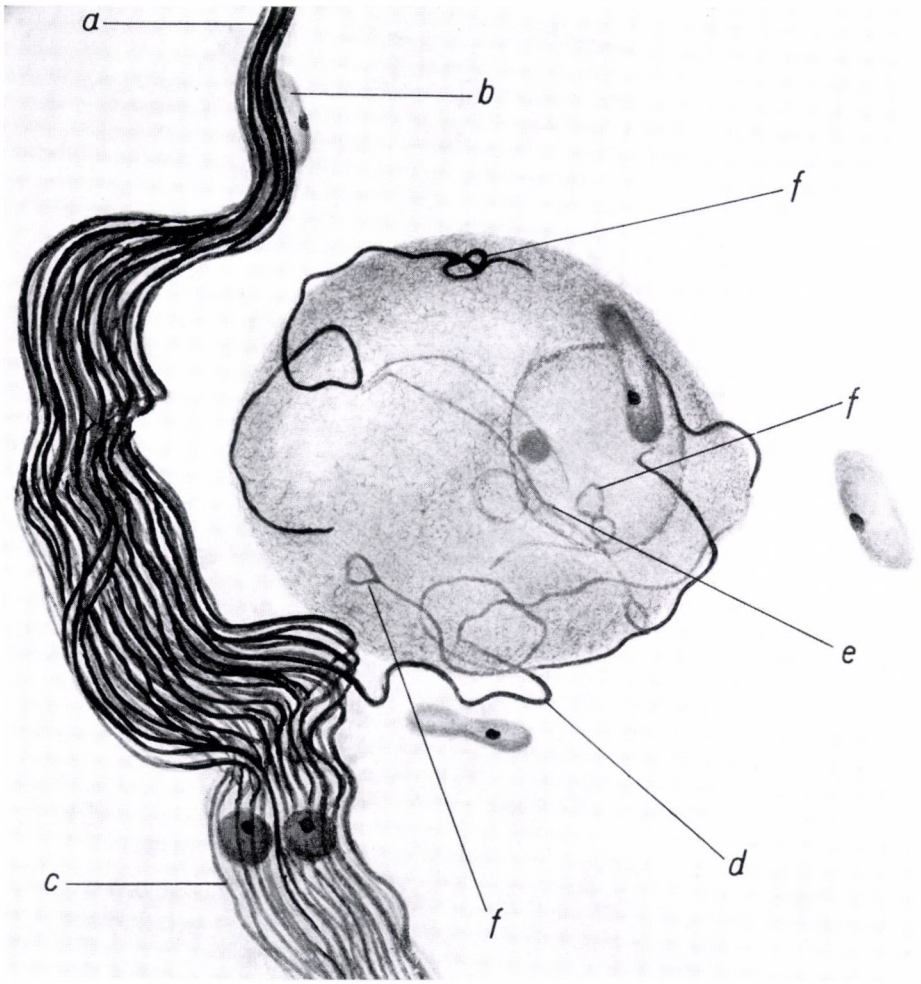

FIG. 37. *Emys orbicularis*. Heart; nerve fibre bundle and nerve cell in the right atrial epicardium. (a) Nerve fibre bundle; (b) Schwann's nucleus; (c) nerve fibre; (d) preganglionic fibre; (e) pericellular plexus; (f) nerve end ring. Bielschowsky–Ábrahám's method. Microscopic magnification 1800×, reduced photographically to ½

traversing these ganglia, too, are sharply bordered, undulating and readily impregnated. In certain portions of the wall the ganglia aggregate into groups. In the common snake, ganglia are large and elongate consisting of spheroid cells with granular cytoplasm. The ganglia are compact, traversed by only a few fibres and are mostly without a visible pericellular apparatus.

Ganglion cells resemble those constituting the vegetative ganglia, all the three cell forms of the latter (unipolar, bipolar and multipolar) being present among them.



FIG. 38. *Python reticulatus*. Heart; nerve plexus in the right atrial epicardium. (a) Connective tissue; (b) nucleus of connective tissue cell; (c) nerve bundle; (d) nerve fibre; (e) nerve cell; (f) nucleus of nerve cell; (g) pericellular plexus. Bielschowsky–Ábrahám's method. Microscopic magnification 1350×, reduced photographically to ½

In the ganglia examined the prevalence of unipolar cells was conspicuous. The processes have in general great affinity to impregnation. Occasionally, processes of variable length are also seen. Some of the shorter ones do not extend beyond the ganglionic area and terminate in elongate neurofibrillar end plates, the so-called dendrit lamellae.

Nerve cells were seen not only within the ganglia but also inside or along the path of nerves, sometimes in large masses. Such cells are arranged in a row on one

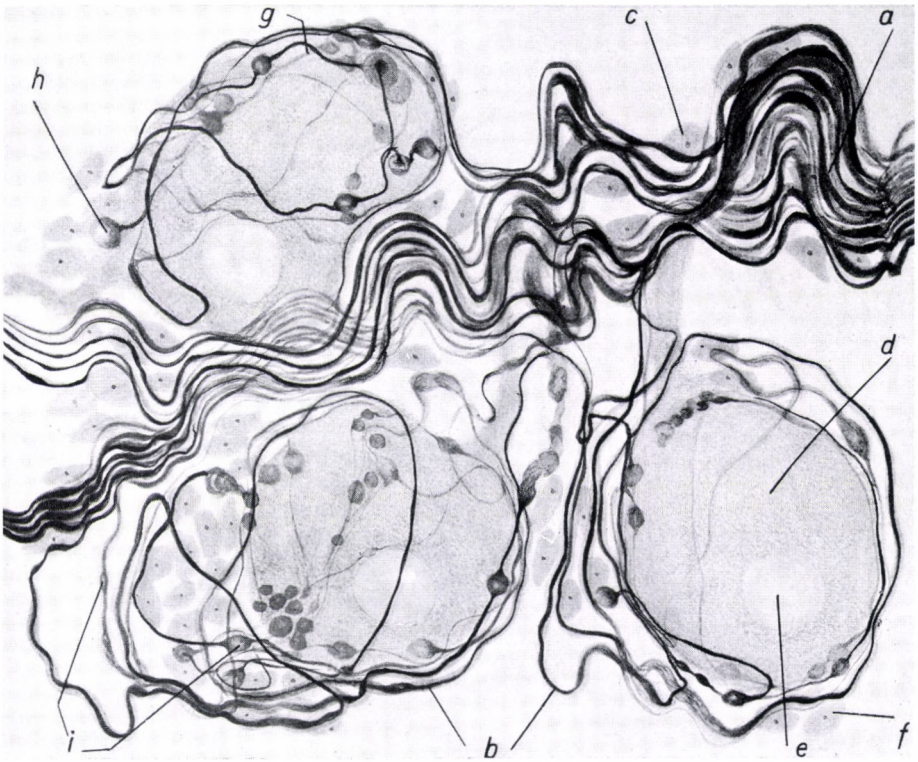

FIG. 39. *Emys orbicularis*. Heart; synapses on the ganglion cells of the atrial septum. (a) Nerve bundle; (b) nerve fibre; (c) neurilemmal nucleus; (d) nerve cell; (e) nucleus of the nerve cell; (f) pericyte nucleus; (g) pericellular plexus; (h) synapsis; (i) varix. Bielschowsky–Ábrahám's method. Microscopic magnification 1350×, reduced photographically to ½

or either side of the nerve, accompanying it sometimes over quite a large distance through emitting processes into the nerve bundle. Cells accompanying the nerve bundles are as a rule unipolar with small granula and markedly eccentric nuclei (Fig. 36).

In the nerve cells, or around them, various end rings, end plexuses, end baskets and spirals are very frequently seen. These configurations are considered endings of the preganglionic fibres and, as such, synapses.

On certain ganglion cells numerous end rings are seen without any obvious connection with the nerve fibres. End rings of this kind were seen in the ventricular epicardium of the steppe monitor. Nevertheless, even there some rings have been obviously in connection with nerve fibres; thus there is no doubt that end rings actually represent synapses. In the tortoise's heart nerve cells were also seen to carry a loose plexus of fibres within which end rings were apparent here and there. This revealed that the nerve cell, or the pericellular plexus of fibres, is approached

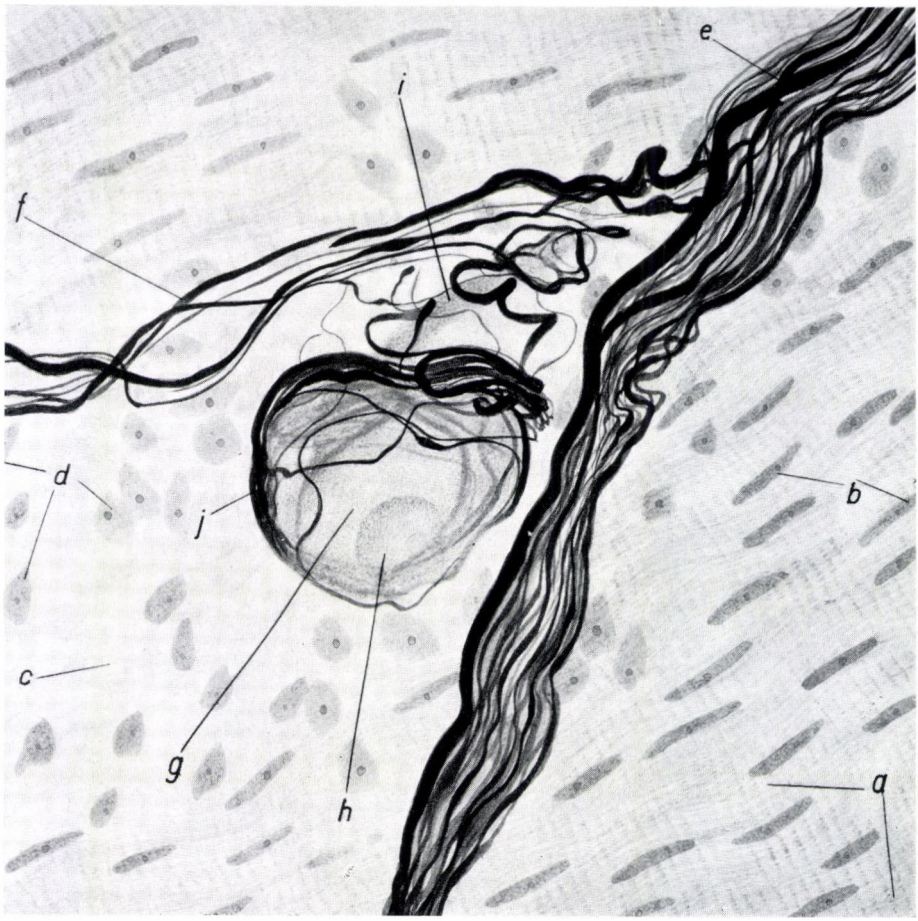

FIG. 40. *Python reticulatus*. Heart; pericellular basket in the right atrial epicardium. (a) Striated muscle fibre; (b) nucleus of the striated muscle fibre; (c) connective tissue; (d) nucleus of connective tissue cell; (e) nerve bundle; (f) nerve fibre; (g) nerve cell; (h) nucleus of nerve cell; (i) process of nerve cell; (j) pericellular basket Bielschowsky–Ábrahám's method. Microscopic magnification 1350×, reduced photographically to ½

by a branch from the nerve trunk, thus indicating the synaptic character of the end rings.

The number of nerve cells surrounded by complicated pericellular plexuses, baskets or spirals is relatively high in the ganglia and mainly along the smaller and larger nerve trunks supplying the hearts of reptiles. Such structures are seen in the hearts of the regal python and mainly in that of the pond tortoise (Fig. 37). In the python, large spherical unipolar nerve cells are arranged almost as in a row in the right atrial epicardium, all of them being surrounded either entirely or

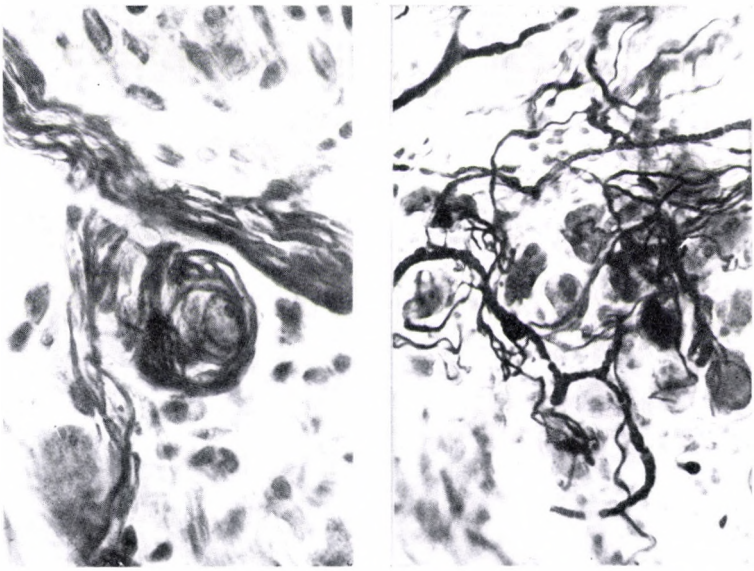

a b

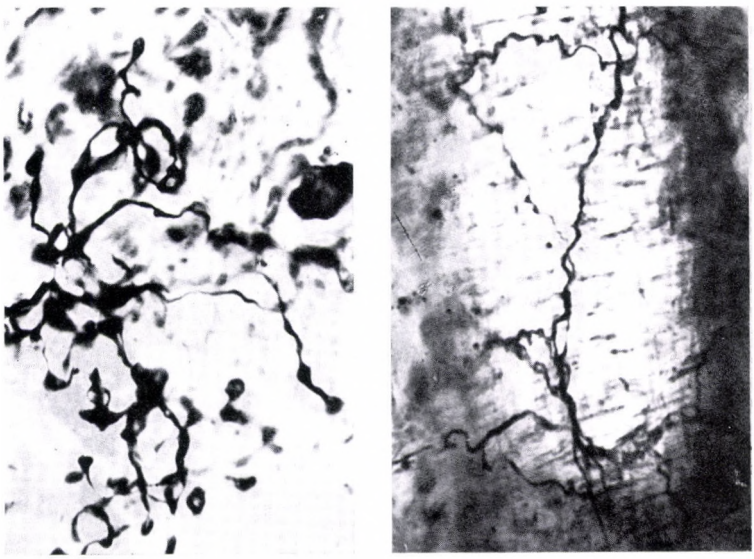

c d

PLATE II

(a) *Python reticulatus.* Heart; pericellular plexus in the right atrial epicardium
(b) *Talpa europaea.* Heart; pericellular plexus in the right atrial epicardium
(c) *Sus scrofa domestica.* Arcus aortae; receptors in the adventitia
(d) *Epimys rattus norvegicus.* Kidney; Arteria interlobularis, nerve plexus in the tunica media

unilaterally by a dense plexus constituted by the end plexus of a thick fibre exiting from the trunk (Fig. 38).

In general, the end branch system is loose and encloses the entire cell. Not infrequently, however, pericellular fibres are arranged at the cell's borders forming a cable-like coil at the site where the cell attaches to the preganglionic fibre. The whole picture gives the impression of the cell being placed in a densely woven basket and surrounded on its free side by a loose plexus. This and similar structures indicate that this apparatus serves the storage and to a certain degree also the fortification of impulses conducted through the preganglionic fibres (Fig. 39). Occasionally, pericellular plexuses appear to be particularly rich and clear not only around the single cells occurring along the nerve trunks' path, but also around those aggregated to form ganglia. Such configurations were seen in preparations obtained from the pond tortoise's right atrium after the animal had been kept alive for several weeks following bilateral vagotomy. In vagotomized tortoises, in ganglia located in the right atrial epicardium near to the entrance of the large veins, rich plexuses of nerve fibres were seen to surround the nerve cells (Fig. 40, Plate II/a, p. 63). The fibres constituting the plexuses whose association with the preganglionic fibres was obvious in every case, were partly thin and smooth-edged and partly markedly varicose. Most of the beads forming the varices were roundish or slightly elongate, arranging either in groups or in rows. In addition, in every case clearly demarcated bulbs were seen on the surface of ganglial cells entangled in the plexuses. The end bulbs showed an obvious continuity with the fibre system constituting the plexus. The pericellular textures, baskets and spirals constituting the end apparatuses of the preganglionic fibres are considered synapses of large transmission areas.

BIRDS (AVES)

The heart of birds is a highly developed organ with four cavities. It is situated along the median line of the body and extends from the second to the fifth rib. The venous sinus exhibits signs of involution, transforming gradually into the right atrium. Its shape, attachment to and, in general, its relation with, the right atrium is dissimilar in certain larger groups of birds. As in most vertebrates, also in birds the heart receives its nerve supply from the vagus and the cervical sympathetic. Branches of these nerves, visible even macroscopically, are generally well known. Details of the pathways as well as of the interconnections of the innervated tissues with nerves, plexuses and nerve fibres in the heart wall are described below as revealed by various modifications of the Bielschowsky method in numerous avian species: black-headed gull (*Larus ridibundus*), common cormorant (*Phalacrocorax carbo sinensis*), goose (*Anser domesticus*), wild-goose (*Anser fabalis*), duck (*Anas domestica*), poachard (*Anas platyrhyncha*), wild-duck (*Bucephala clangula*), flamingo (*Phoenicopterus roseus*), peewit (*Vanellus vanellus*), common coot (*Fulica atra*), water rail (*Rallus aquaticus*), white stork (*Ciconia alba*), black stork (*Ciconia nigra*), common heron (*Ardea cinerea*), night-heron (*Nycticorax nycticorax*), turtle-dove (*Turtur turtur*), common cage-bird

(*Streptopelia decaocto*), pigeon (*Columba domestica*), pheasant-cock (*Phasianus colchicus*), hen (*Gallus domesticus*), turkey (*Meleagris gallopavo*), sparrow-hawk (*Accipiter nisus*), montagu's harrier (*Circus macrourus*), common buzzard (*Buteo buteo*), marsh-harrier (*Circus aeruginosus*), long-eared owl (*Asio otus*), magpie (*Pica pica*), crow (*Corvus frugilegus*), jackdaw (*Colaeus monedula*), sparrow (*Passer domesticus*), fieldfare (*Turdus pilaris*). The innervation of the different parts of the heart is discussed in the usual sequence: atria, ventricles and intracardial ganglia.

Atrium

The right atrium is significantly larger than the left one. The atrial walls are thin and in general smooth, except for the right atrium where muscle trabeculae of varying size extend deeply into the lumen. The most massive trabecula goes from the bottom of the atrium to the muscular valve. Histologically, the structure of the atria corresponds to the general architecture of the heart wall. As a matter of fact the different species exhibit notable differences in the structure and, namely, in the thickness of the individual layers.

The epicardium is thin, consisting of loose connective tissue showing sometimes also the presence of fat cells. Outwards the collagenous layer continues in a network-like portion constituted by elastic fibres. Both layers of connective tissue comprise a greater or lesser number of connective tissue cells carrying processes. Outwards the epicardium is bordered by a simple epithelial layer consisting of elongate cells with spheroid nuclei.

The epicardium is richly innervated (Fig. 41). Generally it is traversed by larger trunks which conjugate by rami of varying dimensions to form a rich plexus. From this plexus exit thicker fibres, presumably of vagal origin, covering usually large distances in the connective tissue without showing any ending suggestive of a sensory function. The total absence of receptor structures in the epicardium in highly organized hearts as those of birds is surprising considering the mass occurrence and variable functions of such structures in the mammalian heart. In spite of our thorough and detailed examinations we failed to detect the sites and shapes of endings of the specially thick fibres exiting from various nerve trunks and rami to terminate in the epicardial connective tissue. Naturally beside the thick fibres there are also numerous thin, undulating sympathetic fibres supplying the vessels of the epicardium. At the outer border of the epicardium the ramifications of the thick nerve trunks give rise to a denser plexus constituted, however, of thinner fibres owing to rich ramification.

In the epicardium also, ganglia of various sizes are seen mainly along the vessels. Larger ganglia occur at the entrance of the great hollow veins. Elongate ganglia occur in a particularly large number in the atrial plexuses passing along the coronary arteries, but occasionally they are seen also in the paths of nerves. Nevertheless, the latter are accompanied rather by rows of single nerve cells. The structures as well as the interconnections of ganglia and nerve cells with the extracardial nerve fibres will be discussed in context with the ganglia.

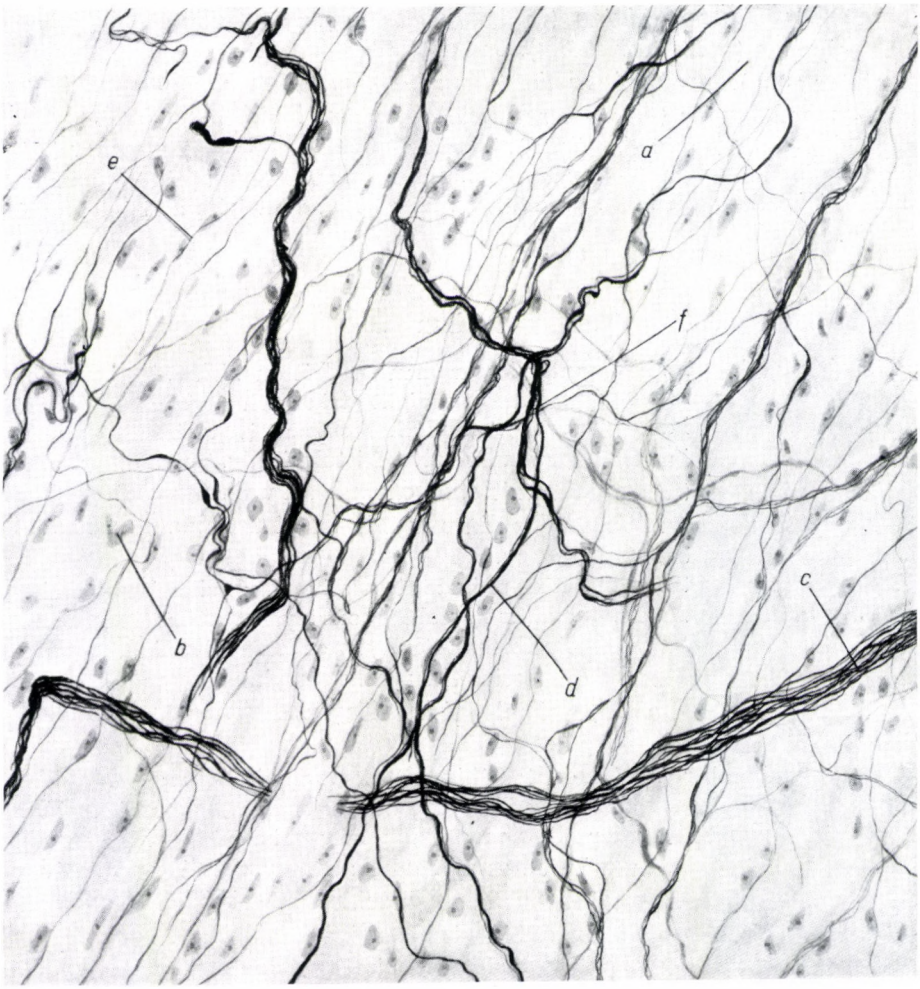

FIG. 41. *Vanellus vanellus*. Heart; epicardial plexus in the right atrium. (a) Connective tissue fibre; (b) nucleus of connective tissue cell; (c) nerve bundle; (d) thick nerve fibre; (e) thin nerve fibre; (f) nerve fibre plexus. Bielschowsky–Ábrahám's method. Microscopic magnification 600×, reduced photographically to ½

Apart from a collagenous basal tissue, the myocardium consists mainly of striated muscle fibres. The muscle fibres are branching and their branches form anastomoses with each other. The muscle fibres have polygonal cross sections. Their nuclei are elongate, central and relatively poor in chromatin. Inside the muscle fibres the transversely striated myofibrils are well visible. The sarcolemma is thin. Between the myofibrils the delicately granulated sarcoplasm is well visible. In the atrial region the myocardial pattern is non-homogeneous, the fibres being arranged



FIG. 42. *Vanellus vanellus*. Heart; myocardial plexus in the right atrium. (a) Striated muscle fibre; (b) nucleus of striated muscle fibre; (c) nerve bundle; (d) nerve trunk; (e) nerve fibre; (f) nerve plexus. Bielschowsky–Ábrahám's method. Microscopic magnification 600×, reduced photographically to ½

mainly in the right atrium in a relatively loose system of trabeculae. The trabeculae constitute a large-meshed *gitterfaser* ("lattice-fibre") pattern.

In both atria, the myocardium is remarkably rich in nerve fibres. In the areas near to the epicardium, there are plexuses constituted by smaller and larger trunks and rami arising from them anastomose here and there with other similar rami. The smaller rami gradually divide to form groups of nerve fibres (Fig. 42). These groups occasionally consist of two to three fibres passing along the muscle fibres over a relatively large distance. Such single nerve fibres are occasionally apparent in masses giving the impression that each muscle fibre is supplied by a separate nerve fibre. We even obtained pictures implying the role of several nerve fibres in the innervation of a single muscle fibre.

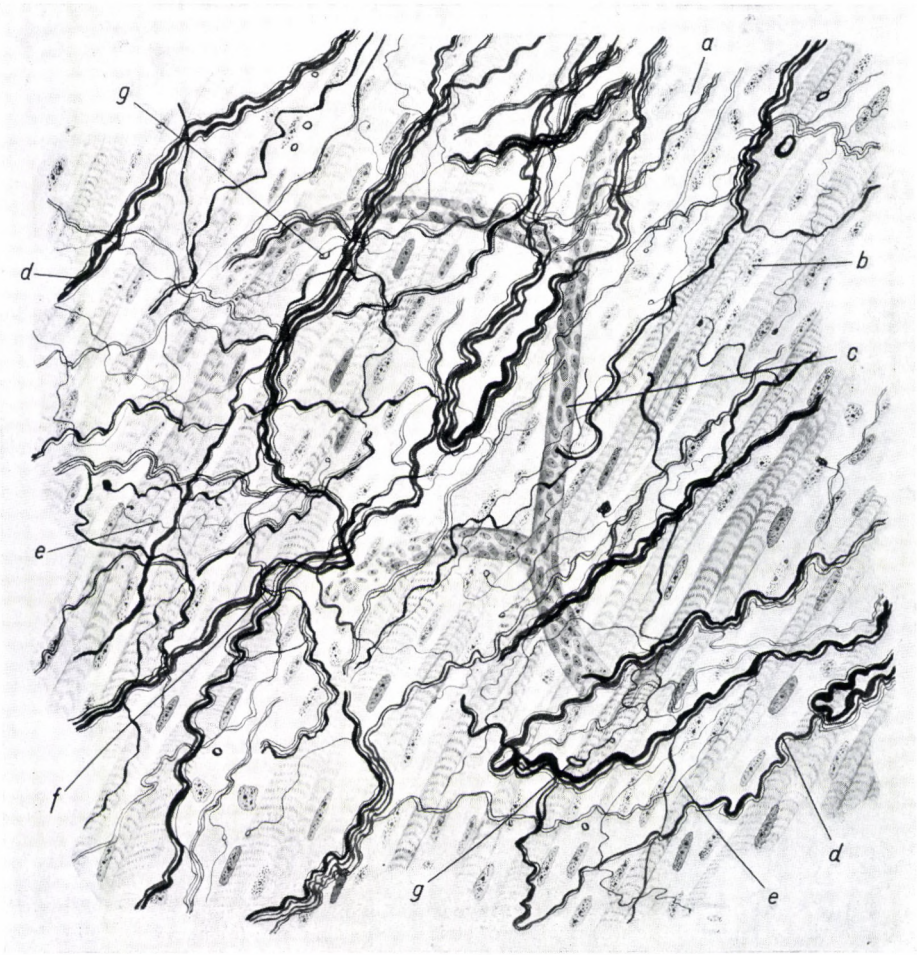

FIG. 43. *Anas domestica*. Heart; atrial septum, nerve fibre plexus in the myocardium. (a) Striated muscle fibre; (b) nucleus of striated muscle fibre; (c) precapillary artery; (d) thick nerve fibre; (e) thin nerve fibre; (f) nerve fibre plexus; (g) nerve end ring. Bielschowsky–Ábrahám's method. Microscopic magnification 300×, reduced photographically to ½

Endings of nerve fibres are only seldom apparent in the ordinary atrial muscles. Nevertheless, some fine end fibres are seen to terminate hypolemmally in end rings. In a special area of the myocardium, that is in the muscles of the muscular valve, end connections are clearly visible. This muscle region is very rich in nerve fibres. The fibres constitute a dense plexus and fibres exiting from this plexus may be sometimes followed over quite a distance. In preparations obtained from this muscle of the domestic duck (*Anas domestica*), distinctly ring-shaped nerve endings were seen in very large numbers (Fig. 43).

The endocardium is essentially a thin connective tissue layer that structurally resembles the epicardium. It is constituted by thick collagenous fibres and a minor number of elastic fibres, being bordered towards the atrial lumen by an endothelium consisting of low polygonal cells. In the connective tissue layer there are also connective tissue cells with mutually anastomosing processes. The endocardium contains relatively numerous capillaries forming an intricate network.

The nuclei of the epithelial cells are large and spherical. The special elements of the endocardium are the Purkinje fibres found also in the atrial septa, atrial endocardium and myocardium to be discussed later.

The Purkinje fibres are roughly spheroid fibres with a cross section of 25–30 μ. Their cytoplasm is granulated and rich in mitochondria. Their nuclei are spherical and chromatin-poor. As a rule, each cell comprises two adjacent nuclei. The cells are bordered by a sarcoplasm-layer of crust-like structure. In cross sections, the myofibrils are arranged in rows. The length of Purkinje fibres varies from 50 to 60 μ. Sometimes they run adjacent to each other, sometimes they collide, then again arrange themselves in rows. In the latter case the striated myofibrils go from one Purkinje fibre to the other. The Purkinje fibres stain well with any staining technique but they are best visualized when the frozen sections are impregnated with the Bielschowsky method. With this method of processing, the Purkinje fibres differ sharply from the other types of myocardial muscles and appear particularly clearly in the picture. The Purkinje fibres belong to the stimulus-conducting system of the heart. It ought to be mentioned here that in the hearts of lower vertebrates there is no trace of Purkinje fibres. Impregnation with the Bielschowsky method of the hearts of different reptiles failed to reveal myocardial fibres exhibiting an affinity to Bielschowsky–Ábrahám silver impregnation similar to that of the Purkinje fibres. This phenomenon is noteworthy because birds and reptiles both belong to the group of Sauropsida, thus according to their phylogenetic features they are very closely related genetically. The fact that these muscle fibres of particular shape and function are making their appearance first and uniquely in the avian heart remains to be explained, as fibres known in the mammalian heart as Purkinje fibres are fundamentally different in their form and localization as well as in their function. This problem is of great phylogenetic interest and comparative studies of different representative species of the Sauropsida would certainly repay examination.

The atrial epicardium is particularly richly innervated. The connective tissue is, namely in certain regions, traversed by nerve trunks of varying sizes. From these trunks exit rami which here and there branch off to fibres.These fibres are relatively thick and carry irregular varices of varying sizes. At some sites they become particularly thin, then again quite thick. According to our observations the delicate end fibres terminate freely in end bulbs in the connective tissue adjacent to the endothelial cells of the endocardium. The pathways, structures, endings and naturally also the positions of these fibres imply a very rich sensory system responsible for the perception of the internal pressure impulses exerted on the wall by the blood. It is of interest that the right atrium joined by the large veins s richer in nerve fibres than the left one.

Atrial Septum (Septum atriorum)

The atrial septum was found to be thick in all bird species examined except for the sparrow and stork in which it was very thin, almost transparent. Essentially the atrial septum is a duplication of the endocardium supported by a basal layer of myocardial tissue of varying thickness. The endocardium is relatively thick, consisting of loose connective tissue constituted by numerous connective tissue cells and relatively few fibres. The bulk of the latter consists of undulating collagenous bundles among which elastic fibres are also seen though in a relatively small number. The endocardium facing the lumen is covered by endothelium. The endothelial cells are very flat with small spheroid nuclei. In the endocardium Purkinje fibres are apparent in large numbers, forming here and there bundles or even coherent sheets. The endocardium is traversed by big nerve trunks that gradually ramify to give rise to a rich pattern of nerve bundles. The latter gradually divide into rami that diverge and anastomose to form an extensive plexus whose bulk is found immediately at the border between the endocardium and myocardium. From this plexus exit delicate fibres which descend singly or in pairs between the connective tissue cells, then conjugate to form another plexus whose fibres again branch off several times. These branches become loose and granular and disappear between the connective tissue cells without exhibiting any special terminal structure.

The myocardium consists of thin, elongate striated muscle fibres with occasional branchings. The muscle cells have relatively small, central nuclei. The striation is very dense but is not sharp. This, however, does not apply to all muscle fibres as fibres with sharp and occasionally thick striation are also seen. The latter type, however, occurs relatively rarely in the myocardium of the atrial septum.

The innervation of the septal myocardium is similar to, though somewhat richer than, that of the atrial myocardium. Large nerve trunks, thickening here and there are seen mainly at the two septal borders. Nerve fibres constituting the trunks are undulating, varicose and occasionally show thickening and branching off. Rami thus arisen run in a winding path over a long distance, then join singly or occasionally in groups into the descent of the muscle fibres. The gradually narrowing end fibres terminate in small spheres arranged in a row along the sarcolemma of the muscle fibre, then disappear without showing any particular end structure. No special forms or interconnections have been observed between the nerves and the fibres conducting the stimuli. In general, nerve fibres accompany the stimulus-conducting fibres over a long distance and after close and extensive conjugation with them they gradually disappear.

Ventricle (Ventriculus)

According to their functions, the walls of the two ventricles differ largely in thickness. The left ventricle wall is much thicker than that of the right one. Histologically, however, they exhibit essentially identical structures, the epi-

cardium, myocardium and endocardium being easily distinguishable in both of them.

The ventricular epicardium is relatively thick and, being attached to the myocardium by a loose layer throughout, it is readily detachable from it. Its inner part consists of fat tissue which as usual contains numerous blood vessels. The next layer consists of collagenous connective tissue bundles some of which are thick and markedly undulating. On the outside this layer is covered by a thin one, consisting mainly of elastic fibres. As a matter of fact, the elastic layer contains collagenous fibres, too, and both connective tissue layers contain connective tissue cells with mutually anastomosing processes. Outside the elastic layer is covered by a simple epithelium constituted by flat elliptic cells which here and there are pressed quite flat.

For the examination of the epicardium's innervation specimens of the epicardial membrane, removed *in toto*, proved to be most suitable. In general, the epicardium is quite thin in any avian species thus being suitable for *in toto* impregnation and examination even at high magnifications. As shown by the *in toto* preparations,the epicardial plexus (plexus epicardialis) is extraordinarily rich, consisting of three poorly distinguishable systems. The outer system comprises the thick nerve trunks which conjugate with the neighbouring similar trunks through multiple mutual exchange of fibres. Exchange of fibres means that fibres exiting from one trunk pass unramified into another one wherein they descend further without branching or changing its diameter. As a matter of fact, the exchange phenomenon occurs with single fibres as well as with smaller or larger rami. Thus a plexus is formed wherein all kinds of nerve fibre structures are found (Fig. 44). The second, deeper plexus lacks large trunks, being constituted mainly by smaller or larger rami of varying thickness that exit from the larger trunks of the upper plexus. In the third plexus, found in the innermost layer of the epicardium attaching closely to the myocardial plexus, mainly rami constituted by a few fibres and many single nerve fibres are seen. Morphologically the nerve fibres constituting the plexus may be divided into two large groups. Into one group are classified the thick fibres, while the thin ones fall into the other. Thick fibres are much fewer in number than thin fibres. Undoubtedly, the thick fibres, on which here and there also the myeline sheath is seen, belong to the vagal sensory system. The thick fibres branch off to form delicate end rami whose path may be readily followed up between the collagenous fibres over a shorter or longer distance. It is of interest that except for a very few small end rings or end bulbs, no receptor structures are seen at the termination of the end fibres. In this context again arise two important questions. For what reason are the sensory end apparatuses present in large numbers and performing important functions in the mammalian heart, absent from the highly organized avian heart? What is the explanation of the sudden appearance of these highly differentiated and specialized structures in mammals implying a virtual absence of phylogenetic continuity? Another problem is posed from the functional point of view, too, as a means for transferring stimuli and local functional influences from the heart to the medullary centres seem to be missing. Plainly put, it is difficult to see what structures of the individual histological layers serve

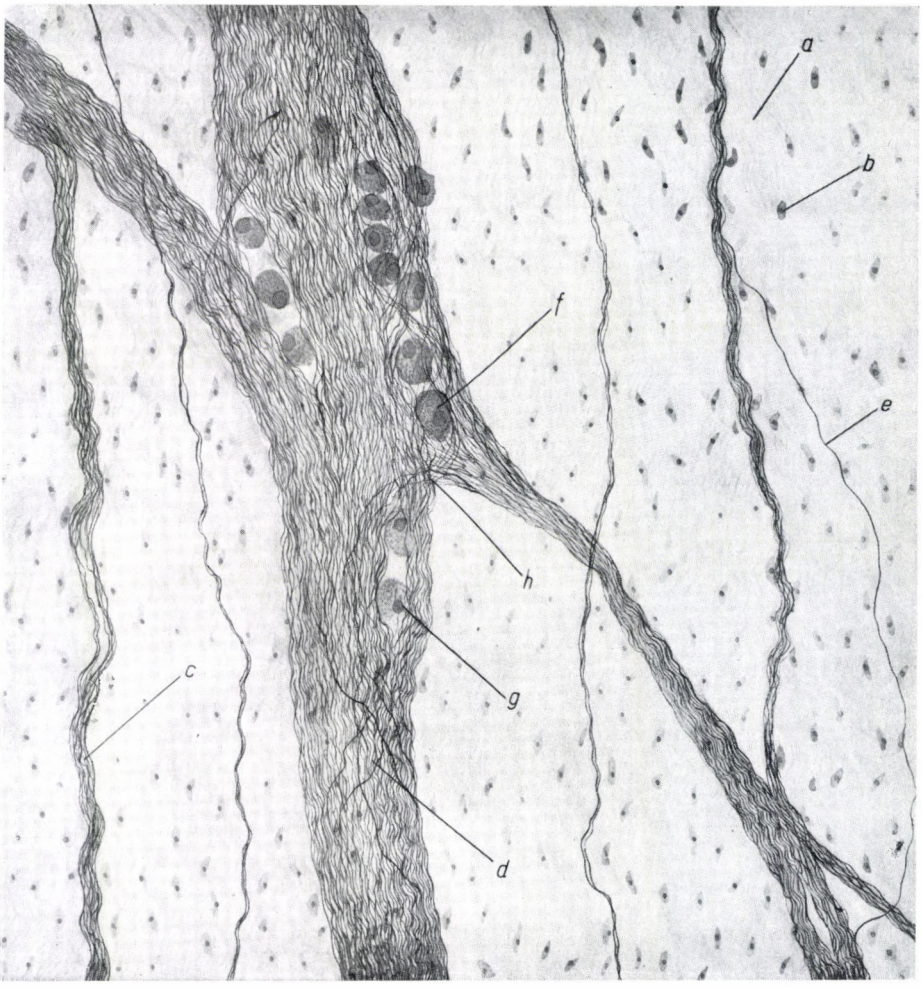

FIG. 44. *Vanellus vanellus*. Heart; nerve plexus in the ventricular epicardium. (a) Connective tissue fibre; (b) nucleus of connective tissue cell; (c) nerve bundle; (d) nerve trunk; (e) nerve fibre; (f) nerve cell; (g) nucleus of nerve cell; (h) nerve plexus. Bielschowsky–Ábrahám's method. Microscopic magnification 240×, reduced photographically to ½

for the reception and centripetal transfer of proprioceptive stimuli in the avian heart. We shall return to these questions later.

The ventricular myocardium consists of striated muscle fibres. The structural pattern of the muscle fibre groups corresponds to their functions. The structure of the fibres themselves is similar to that described for the striated fibres of the atrial myocardium. The former are, however, more compact, their myofibrillar striation is less clear, their sarcolemma less distinct and their nuclei are smaller.

As to their innervation, they are generally less amply supplied than the atrial myocardium. As a rule, the nerve trunks and smaller rami descend along the vessels although in some myocardial areas trunks and rami of varying thickness may constitute a true plexus. It must be noted as a general rule that in the ventricular myocardium the nerve fibres are thin, smooth and keep closely together. In rami exiting from the trunks the fibres usually run a linear path parallel with each other. Not infrequently also single fibres are seen to pass along the muscle fibres, but in certain areas and special cases they constitute a delicate plexus in the muscular tissue. Single nerve fibres as well as fibres exiting from the end plexuses occasionally may be followed up over a long distance. In such cases — quite infrequently, though — the very thin fibres carrying many delicate uniform varices at regular distances are seen to terminate hypolemmally in end rings inside the muscle fibres. As already mentioned, these endings are not uniformly conspicuous in all avian species and in each cardiac region, yet there are certain bird species and certain heart wall regions where this kind of nerve ending is encountered with a great frequency over a large area. Thus, with reference to our observations on both the atrial and ventricular myocardium we feel entitled to apply also to birds our definitive statement that postganglionic fibres, which are actually effectors of the heart muscle fibres, terminate hypolemmally in end rings on the muscle fibres.

The ventricular endocardium is an extraordinarily thin, hardly distinguishable connective tissue layer bordered against the ventricular lumen by a definitely flattened simple epithelium. As to its innervation, in general there has been detected also a plexus which with respect to its localization has been considered the endocardial plexus (plexus endocardialis). This plexus is quite poor. Its fibres are thin and delicate and arborize at the ends. These branches attach closely partly to the collagenous fibres and partly to the cytoplasm of the epithelial cells.

Ventricular Septum (Septum ventriculorum)

The ventricular septum is a stave-like muscular structure. Its shape and thickness vary with the individual avian species and depend also on the position and thickness of the atrial walls. Towards the ventricular lumen it is bordered by endocardium, its middle, thick part consists of muscle fibres. Its nerve supply lacks any well-defined features. In the endocardium there is a loose plexus constituted alternately by thin and thick fibres. The thicker fibres ramify several times and their end branches are attached to connective tissue bundles and endothelial cells. The endocardium contains Purkinje fibres on both sides. These fibres traverse the endocardium longitudinally and here and there ramify to form plexus-like structures. Purkinje fibres are seen also in the myocardium of the ventricular septum. This is essentially a typical mechanical muscle tissue whose branching fibres anastomose with each other. Striation is dense and less sharp, the nuclei are elongate and chromatin-poor. The myofibrils are not sharply differentiated towards the sarcoplasm. As to the innervation of the septal

myocardium, the following was found. In the thin connective tissue septa between the muscle bundles nerve trunks of varying sizes are running which here and there branch off to fibres. These fibres descend either singly or in pairs, sometimes between, sometimes on the surfaces of muscle fibres. The conjugations of nerve fibres with the muscle fibres are only infrequently seen. In such cases delicate end fibres are seen to be attached by end rings of variable sizes to the cytoplasm immediately below the sarcolemma of muscle fibres.

Muscular Valve (Valvula cardiaca dextra)

The valves found in the avian heart are essentially duplications of the endocardium bordered towards the lumen by simple endothelium. Under the endothelium there is a connective tissue layer constituted by collagenous fibre bundles and many elastic fibres, particularly in the neighbourhood of the endothelium. The thickness and structure of the connective tissue layer vary with the individual types of valves.

The muscular valve closing the right atrium towards the right ventricle (valvula cardiaca dextra), differs markedly from the former both anatomically and neurologically. The main feature of this valve is that its bulk is constituted by a relatively thick muscular membrane covered towards the lumens by endocardium. As to its structure, the latter is identical with that of the right atrium, or ventricle, described above. The muscle layer of the muscular valve is constituted by atrial muscles on the atrial and by ventricular muscles on the ventricular side. Between the two muscular layers there is an epicardial connective tissue extending to the valve's border interrupting the continuity of the atrial as well as of the ventricular muscle bundles. Near to the free edge of the valve, bundles of atrial origin form radially arranged fibres constituting the auricular ring parallel with the valve's free border. In certain avian species the atrial and ventricular muscles of the valve have no connection with each other. For example, in the Australian ostrich the two muscle layers are separated by a fibrous ring (anulus fibrosus).

The muscular valve is attached dorsally to the ventricular septum (septum ventriculorum) at the left dorsal ventricular corner. At this site there is possibility for a conjugation between the atrial and ventricular muscles. This is of particular importance from the point of view of interconnection, resp. continuity, between the atrial and ventricular conducting systems. The short ventral papillary muscle of the muscular valve extends ventrally towards the outer wall of the right ventricle. Some workers have considered this muscle a remnant of the bulbus. In some genera [e.g. *Apteryx* (Owen)] a certain part of this valve is membranaceous.

Concerning the nerve interconnections of the muscular valve, this structure of the avian heart appears to be especially rich in nerve fibres. This rich supply seems to be explicable partly by the presence of epicardial connective tissue in the middle of the valve, secondly by its richness in muscles and thirdly by the fact that the second largest centre of the stimulus conducting system is found in the muscular valve. The bulk of nerve fibres is found in the epicardial connective tissue in the

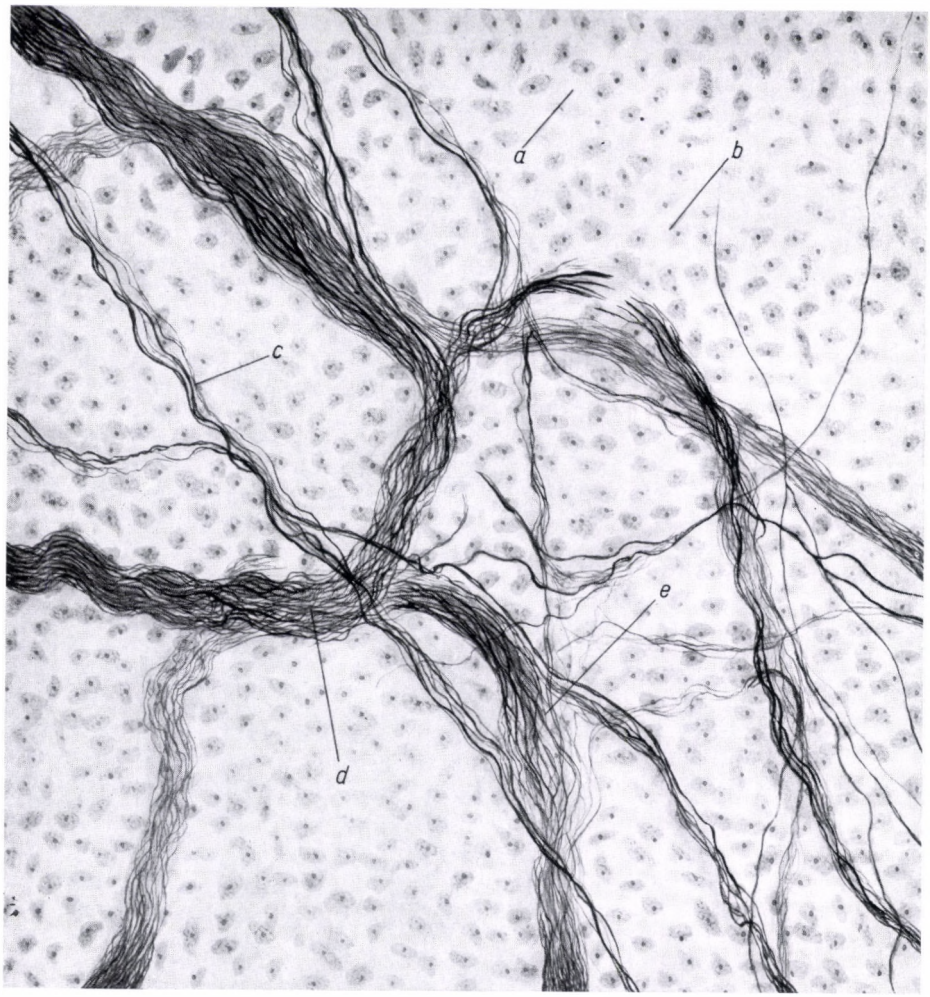

FIG. 45. *Phalacrocorax carbo sinensis*. Heart; nerve plexus in the ventricular epicardium. (a) Connective tissue; (b) nucleus of connective tissue cell; (c) nerve bundle; (d) nerve trunk; (e) nerve plexus. Bielschowsky–Ábrahám's method. Microscopic magnification 600×, reduced photographically to ½

form of enormous trunks and plexuses (Fig. 45). The epicardial connective tissue is traversed by very large nerve bundles whose thin fibres descend between the connective tissue cells without showing any perceptible endings of sensory nature. The myocardium, mainly the atrial one, also contains an extraordinarily large number of nerve fibres. Here and there it is traversed by thick bundles from which exit thin fibres of undulating descent, sometimes in masses and sometimes in a lesser number. The latter, either thick or thin, run a winding path on the surface of muscle fibres. Occasionally, nerve fibres appear in the myocardium in such



FIG. 46. *Phoenicopterus roseus*. Heart; muscular valve; nerve plexus in the myocardium. (a) Striated muscle fibre; (b) nucleus of striated muscle fibre; (c) nerve bundle; (d) nerve fibre; (e) nerve plexus. Bielschowsky–Ábrahám's method. Microscopic magnification 600×, reduced photographically to ½

enormous masses that the identification of their origins, conjugations and interconnections is practically impossible. The distributed bundles, together with the masses of nerve fibres, occasionally form very dense plexuses whose presence implies a substantial role of the nervous system in the function of the muscle layers of the muscular valve (Fig. 46). Beside the extraordinary richness, large mass and special patterns of plexuses and branchings, the innervation of the muscular valve is characterized also by the fact that it is the unique part of the avian heart where the connections between nerve fibres and muscle fibres are clearly and convincingly apparent.

The endocardial layers of the muscular valve are rich in nerve fibres both on its atrial and ventricular surfaces. Some of the fibres are thick, some thin, showing either undulating or straight descent or even a markedly winding path. The bundles

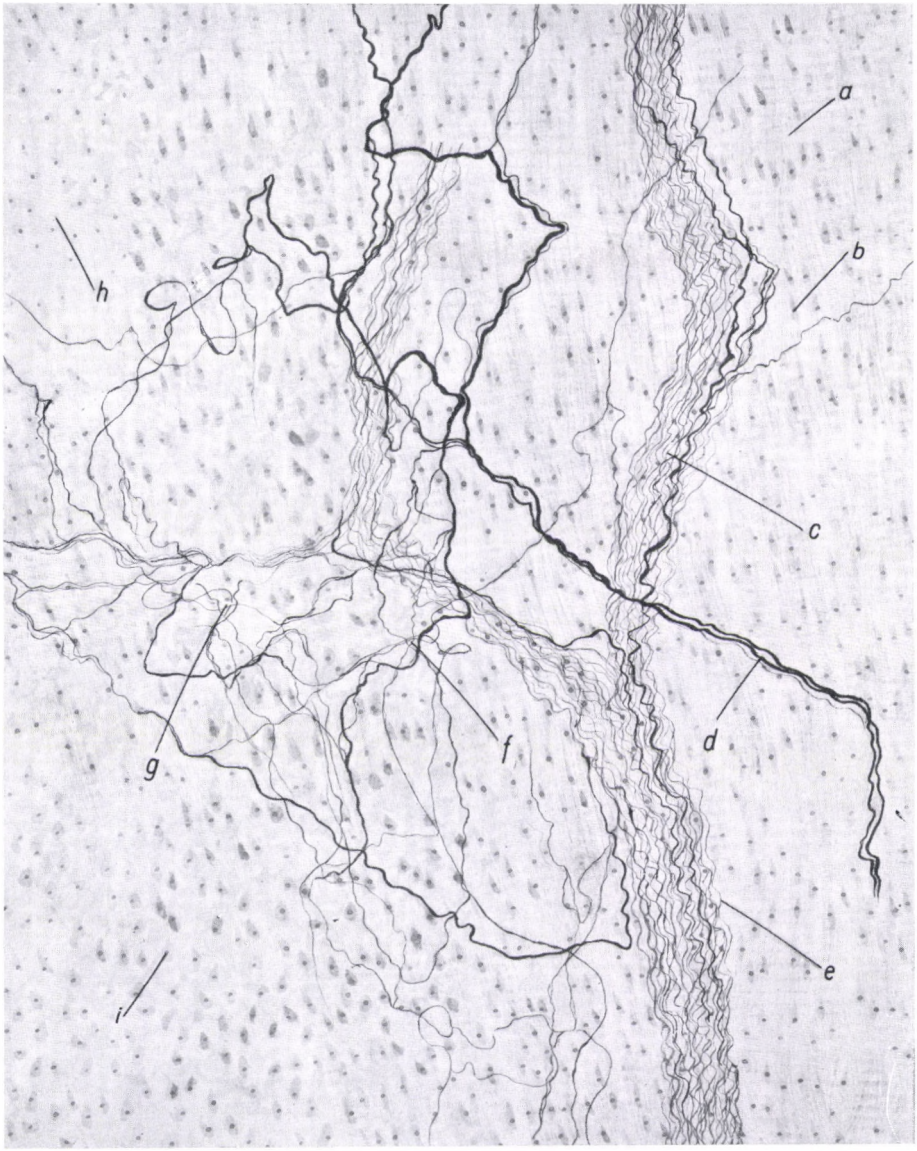

FIG. 47. *Ardea cinerea*. Heart; muscular valve; nerve plexus from the border of the myocardium. (a) Striated muscle fibre; (b) nucleus of striated muscle fibre; (c) nerve bundle; (d) thick nerve fibre; (e) thin nerve fibre; (f) nerve plexus; (g) nerve end plexus; (h) connective tissue; (i) nucleus of connective tissue cell. Bielschowsky–Ábrahám's method. Microscopic magnification 320×, reduced photographically to ½

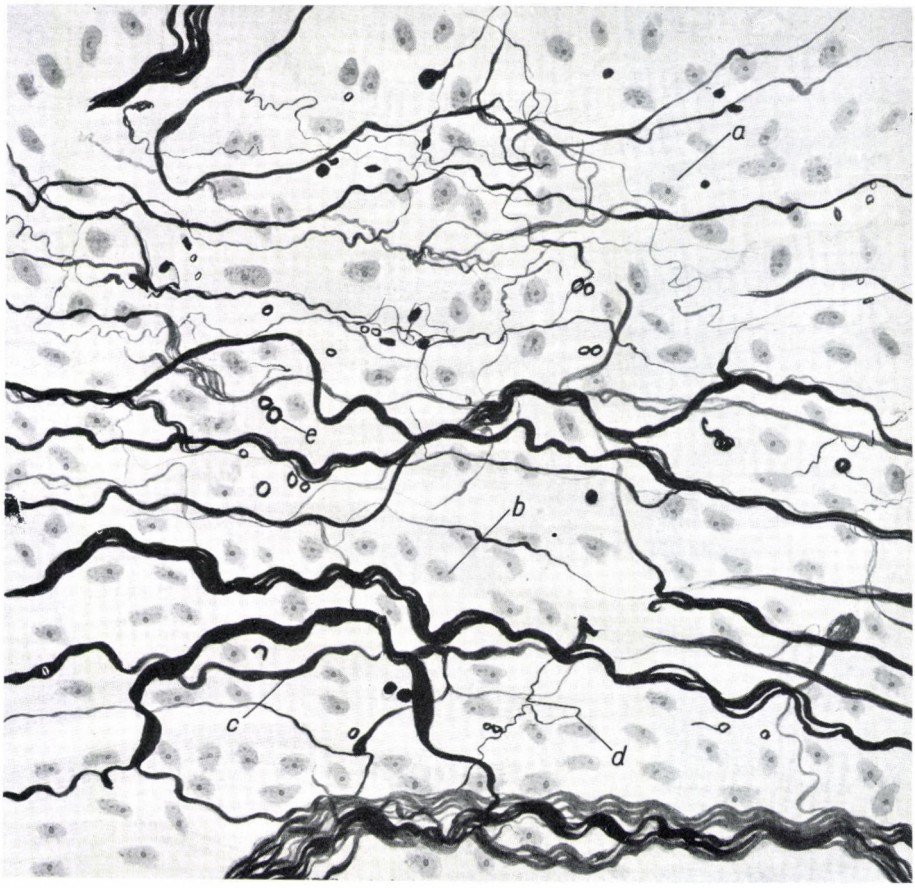

FIG. 48. *Anas domestica*. Heart: muscular valve; myocardial plexus. (a) Striated muscle fibre; (b) nucleus of the striated muscle fibre; (c) thick nerve fibre; (d) thin nerve fibre; (e) nerve end ring. Bielschowsky–Ábrahám's method. Microscopic magnification 600×, reduced photographically to ½

are frequently interconnected by fibres, passing from one bundle to the other. This form of interconnection results in the formation of rich plexus. Within the plexus system and also independently of it, there are some quite thick, often arborized fibres. According to their appearance we have considered them to be receptors of the muscular valve (Fig. 47).

Nerve Endings of the Myocardium

The problem of interconnections between the nervous system and the myocardium has been repeatedly referred to in the foregoing account. We have frequently stated and in most cases have also demonstrated by numerous examples

that nerve fibres entering into the myocardium terminate in end rings localized right under the sarcolemma as evidenced by light microscopy. The validity of this finding has been convincingly confirmed by histological pictures yielded by the impregnation of tangential sections of frozen sections obtained from the muscle layer of the muscular valve. In these sections end rings attached to the delicate nerve end fibres were apparent in large numbers (Fig. 48).

Stimulus-Conducting System

The stimulus-conducting system of the avian heart has been extensively studied recently. The methods employed for the investigation of this fairly intricate problem have included all available facilities of up-to-date microtechniques. Yet we are far from having a satisfactory knowledge of this subject; moreover, the closer approach to the problem has even increased the conflict between opinions and interpretations. This is natural considering the special structure, position and function of this muscular system making appearance first in the avian heart during the course of phylogenesis. No similar system has been demonstrable morphologically in any of the lower vertebrates, not even in groups closely related to birds. The objective settlement of the problem is rendered still more difficult by the fact that this system is specific for birds, being absent in the lower forms as well as in the higher ones. One thing is certain, however, and as such agreed by all investigators, that is the presence of a special stimulus-conducting system in the avian heart that resembles both structurally and functionally the similar system in the mammalian heart. This has been convincingly supported also by examinations performed by us with an adaptation of the Bielschowsky method on the heart of birds belonging to various families. In the impregnated preparations a highly particular myocardial system has been apparent, differing substantially from the myocardium performing mechanical work and being present in various structures and masses in all parts of the heart, constituting the latter's bulk. Essentially this system is identical with the experimentally demonstrated stimulus-conducting system constituted mainly by uniformly thick brick-shaped muscle fibres comprising as a rule two closely situated nuclei and conjugating with the similar muscle elements in various ways (Fig. 49). In preparations impregnated by the method adapted by us, the latter type of muscle fibres differed sharply from those performing mechanical work. The brick-shaped fibres sometimes arranged in a row to form elongate trabeculae, sometimes again various masses and groupings of them gathered around a given point or formed special broad-meshed reticula showing a repetitive structural pattern over large areas. These special cells and cell systems are occasionally arranged sequentially or side by side along the arteries; at other times they appear independently of vessels in a trabecular pattern of unicellular thickness inside the heart wall's endocardium, or myocardium.

As in the sections processed with the Bielschowsky–Ábrahám's method the stimulus-conducting fibres were seen particularly clearly and their appearance differed distinctly from that of mechanical muscle fibres, we thought it worth while



FIG. 49. *Circus aeruginosus*. Heart; stimulus-conducting fibres in the wall of the right ventricle. (a) Connective tissue; (b) nucleus of connective tissue cell; (c) striated muscle fibre; (d) stimulus-conducting fibre; (e) nucleus of stimulus-conducting fibre; (f) artery; (g) nerve bundle; (h) nerve fibre. Bielschowsky–Ábrahám's method. Microscopic magnification 300×, reduced photographically to ½

to examine the behaviour of the two types of muscles in the PAS reaction. The atrial septum (septum atriorum) and ventricular septum (septum ventriculorum) were treated with the PAS method. As a result, the elements of the mechanical muscle stained intensively red, whereas the stimulus-conducting system did not stain at all. This implied a high glycogen content of the mechanical fibres, whereas there was a total or nearly total absence of glycogen in the stimulus-conducting fibres.

After the detection of the centres and bundles of the mammalian heart's stimulus-conducting system, several workers have attempted to establish phylogenetic, morphological and functional correlations between them and the stimulus-conducting cell groups and bundle systems in the avian heart. Some of these attempts have been on the right track and the correlation of consistent observa-

tions has been promising. Yet they have not permitted a closer approach to the problem simply because they *ab ovo* aimed at a compromise, although from the angle of phylogenesis a direct relation of avian with mammalian heart stimulus-conducting system has been unfeasible. In our opinion, the stimulus-conducting system of the avian heart is a specific and unique structure appearing for the first and last instance exclusively in birds and correlating neither genetically nor functionally with the stimulus-producing and -conducting systems known in the mammalian heart. This is supported by the structural dissimilarity, the entirely different behaviour towards silver nitrate and the radically different amount and grouping of nerve interconnections in the two systems.

Regardless of the various contradictory and non-general statements and relying partly on relevant literary data and partly on our own observations, the following may be stated concerning the system of Purkinje fibres in the avian heart.

The Purkinje fibres form larger characteristic groups in two areas of the avian heart. One of them is the area of the right atrium adjacent to the orifice of the upper hollow vein, while the other the muscular valve (valvula dextra). In these areas the amount and the particular arrangement of Purkinje fibres seem to allow the suggestion that these regions should be considered both morphologically and functionally as stimulus-producing centres.

In all birds tested, a large system of Purkinje cell network was detected at the orifice of the upper hollow vein. These fibres are definitely argentophilic and the network's structure and localization remind one of the sinoatrial node of mammals. Remarkable differences have been encountered in the different groups and species of birds in respect of the form, localization, structure and extent of the fibre network as well as in the length and thickness of the single fibres, the volume, shape and localization of nuclei. Nevertheless, it can be stated that this system is always present in the same area of the heart covering a relatively large region, being more or less clearly separated from the mechanical muscles and having no connections with the ordinary heart muscle fibres. This particular group of fibres should be regarded as the primary stimulus-producing centre of the avian heart, corresponding to the sinoatrial nodule in respect of its morphological features (Fig. 50).

No longer or thicker bundles of Purkinje fibres originate from the sinoatrial nodule at the orifice of the upper hollow vein. It may be, however, reasonably supposed that the smaller and larger Purkinje fibre networks, which are present mainly along the arteries but also in other areas of the right atrial endocardium and myocardium, are connected with, or even originate from, the sinoatrial nodule forming a coherent system with the former. Another relatively extensive system of Purkinje fibres is encountered in the muscular valve (valvula cardiaca dextra). In this area, too, the system is localized within the atrial endocardium. As to its structure, one may state that it generally resembles that observed in the region of the upper atrial nodule. The only difference is that the former's structure is more compact and certain characteristic structures may appear multiply linked with each other. It should be noted that whilst the structure and localization of the upper atrial nodule are generally the same in all genera of birds, those of the lower atrial nodule may vary remarkably with the individual genera.

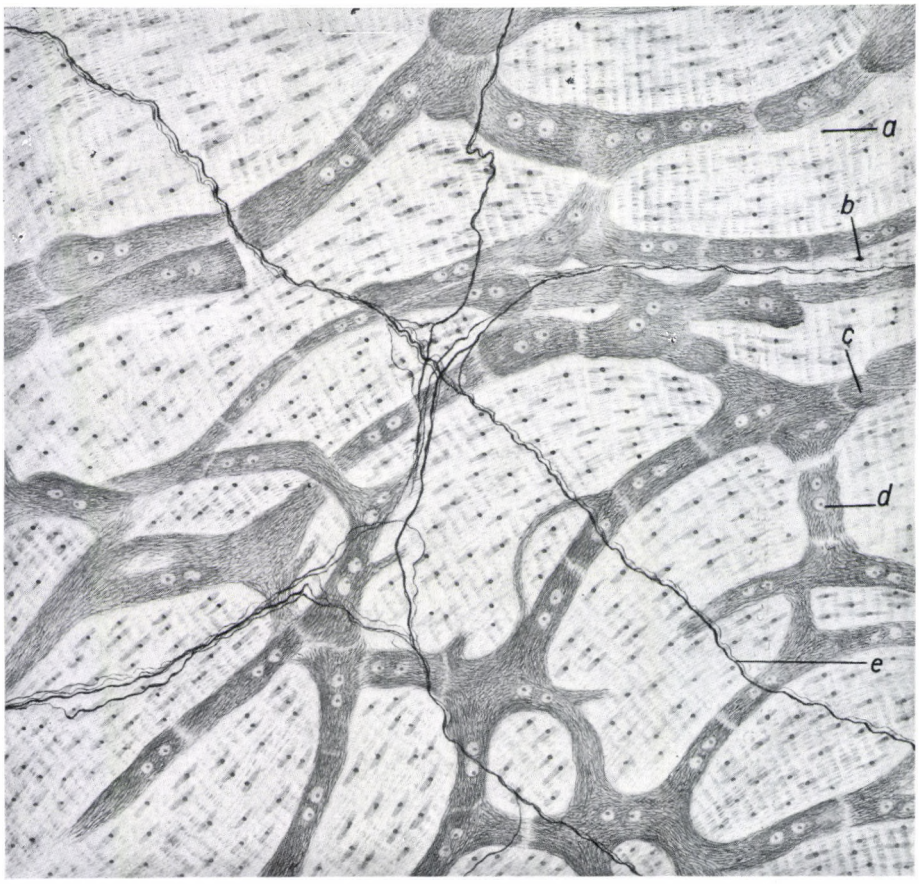

FIG. 50. *Phalacrocorax carbo sinensis.* Heart; stimulus-conducting system in the wall of the right atrium. (a) Striated muscle fibre; (b) nucleus of the striated muscle fibre; (c) stimulus-conducting fibre; (d) nucleus of stimulus-conducting fibre; (e) nerve fibre. Bielschowsky–Ábrahám's method. Microscopic magnification 240×, reduced photographically to ½

There is no evidence available for the existence of connections between the upper and lower atrial nodules. In most cases, morphological proof for such a connection is definitely missing. Nevertheless, the presence of Purkinje cells, bundles and trunks in the endocardium and myocardium of not only the left atrium and atrial septum but also of the ventricles mainly along the arteries implies the interconnection of the lower atrial nodule on one hand with the upper atrial nodule and, on the other hand—through the muscular valve—with the left atrium, the ventricular septum and the ventricular walls as well. Further support for this implication is served by the presence of uninterrupted Purkinje fibre bundles running in the atrial endocardium of the muscular valve down to the bottom of the left atrium and to the ventricular septum (septum ventriculorum).

Our studies on frozen sections did not permit the determination of a coherent or an ontogenetical separation of the stimulus-conducting system in the avian heart. The ubiquitous and subsequent occurrence of typical structures in all layers but the epicardium, however, suggests that the stimulus-conducting system of the avian heart is a coherent morphological structure making its appearance in all parts of the heart with the upper and lower atrial nodules as its centres. This system serves for the co-ordination of the heart's movements and for the maintenance and control of rhythmic contractions.

As to the interconnections of the stimulus conduction and the nervous system, the following has been observed. The stimulus-conducting system is extremely poorly supplied with nerves. Nerve trunks of a certain volume and fibre content are seen only in areas where Purkinje fibres aggregate in groups along the smaller and larger arteries. In these regions the association of single nerve fibres or bundles with stimulus-conducting fibres or, occasionally, with Purkinje cells is apparent. Nevertheless, in spite of the considerable number of preparations examined, we still have been unable to detect the precise nature of the above connections.

The innervation of the atrial nodule of birds is very poor as compared to that observable in mammals. The nerve fibres of both atrial nodules seem to originate from the endocardial plexuses. These fibres are thin, of undulating descent and pass on to the Purkinje fibres at varying distances from each other. Nevertheless, no close connection between the Purkinje fibres and the nervous system has been suggested even by very successfully impregnated preparations.

Our observations on the structure of the stimulus-conducting system and on its connection with the nervous system present objective evidence for the high efficiency of stimulus conduction and a particular autonomy of function of the avian heart. The ubiquitous presence of stimulus-conducting structures in all layers of the heart and their remarkable independence of the nervous system suggest a particularly high degree of automation. This is shown also by the extreme scarcity of interoceptive apparatuses implying a limited interoception. Should this be the case, the influence of the central nervous system on the activity of the avian heart must be very moderate.

All these phenomena appear to reflect the highly specialized functional and adaptational requirements imposed upon the avian heart by the special conditions of avian life.

Localization of Acetylcholinesterase Activity in the Stimulus-Conducting System

The stimulus-conducting system of the avian heart was examined also in respect of localization of acetylcholinesterase activity. For this purpose the method of Coupland–Holmes was applied. The studies were performed on pigeon heart. No significant differences were found between the localization of cholinesterase activity in stimulus-conducting fibres and mechanical muscle fibres, both exhibiting a weak homogeneous activity.

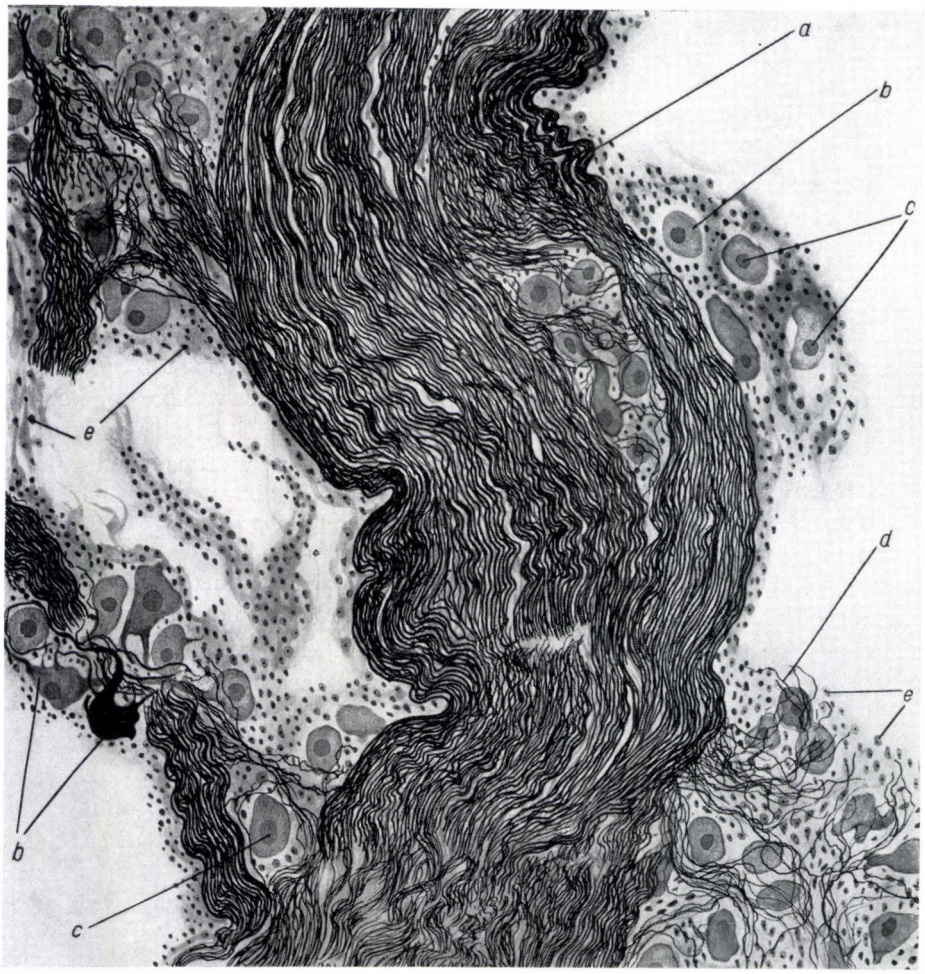

FIG. 51. *Gallus domesticus.* Heart; ganglion in the right atrial epicardium. (a) Nerve trunk; (b) nerve cell; (c) nucleus of nerve cell; (d) nerve fibres; (e) nucleus of the satellite cell. Bielschowsky–Ábrahám's method. Microscopic magnification 200×, reduced photographically to ½

Ganglia

Ganglia are essential elements of the nervous system in the avian heart. Their localizations, dimensions and structures are variable, their only general feature being their occurrence in extraordinarily large numbers. Further to this, in birds, unlike the other vertebrates already discussed, ganglia are present not only in the atria but also in the ventricles though in a much smaller number. As to their localization, ganglia are found in the atria, epicardium, sulcus coronarius cordis, atrial septum and ventricular myocardium. Larger ganglia occur in the atria near the

orifice of the large hollow veins, in the sulcus coronarius cordis and adjacent to the coronary artery and its branches. Ganglia in the area of the large venous orifices are generally large, comprising numerous cells surrounded by a particularly rich system of extracardial plexuses. Ganglia present in masses in the coronary sulcus are mostly elongate and narrow; some of them, however, are broad and larger. In the ventricles small ganglia are generally seen consisting of a few cells adjacent to the nerve trunks. It should be noted that in contrast to the ready impregnation of nerve fibres both in the heart wall and ganglia, impregnation of the nerve cells is generally poor, being limited mainly to their central areas. Processes of the nerve cells as a rule resisted impregnation. Successful impregnation of the processes as well as the cells was achieved only in certain ganglia in the coronary sulcus of very young chickens (Fig. 51). In these preparations, the prevalence of multipolar cells was demonstrated unlike the lower vertebrates, exhibiting an overwhelming occurrence of unipolar nerve cells. Multipolar cells have usually elongate, irregular, triangular shapes.

MAMMALS (MAMMALIA)

The mammalian heart consists of four cavities and its arterial and venous parts are completely separated from each other. The venous sinus is fused with the right atrium and the veins open directly into the right atrium. Of the valves present in lower vertebrates at the aperture of the venous sinus, one became the valve of the lower hollow vein (valvula Eustachii), and the other that of the coronary sinus (valvula Thebesii). The atria are entirely separated from each other, their walls are smooth and the trabecular structure is seen only in the ventral portion of the heart where both atria continue in the so-called heart auricle (auricula cordis). Between the right atrium and right ventricle there is the tricuspid valve (valvula tricuspidalis), whereas between the left atrium and ventricle is the bicuspid valve (valvula bicuspidalis). The free margins of the valves are attached by tendons (chordae tendinae) to the papillary muscles (musculi papillares) of the ventricle wall.

Historical

As in other vertebrates, the heart of mammals also functions automatically. The influence of the nervous system on this automatism is, however, remarkable. The existence of such influences was already assumed by Galen. He, however, had described only a single heart nerve on the left side. Vesalius (1543), too, recognized only one heart nerve, also on the left side, arising from the vagal nerve at the exit of the nervus recurrens from the trunk. Essentially this nerve is identical with Galen's heart nerve which, in its descent, passes through the pericardium and on the left side behind the pulmonary artery runs to the basis cordis where it subdivides into fine rami.

Closer information on cardiac innervation was provided by Fallopius (1600) who investigated the heart's nerve supply on the basis of certain theoretical considera-

tions. His approach stemmed from the idea that nature would be unjust to provide the heart with only one nerve whilst supplying rich innervation to other important visceral organs such as intestines, liver and spleen, etc. Fallopius described all nerves known at present to reach the heart except for the right upper nerve which, indeed, remained undiscovered by most of the later anatomists, too. He found a plexus of fibres (plexus nervosus) on the pulmonary artery to which attached four nerves on the left side, one sent by the nervus recurrens, one by the nervus vagus succeeding the exit of the nervus recurrens and two by the nervus sympathicus. These conditions were discovered by Fallopius only on the left side. On the right side he found only one biradical heart nerve originating from the sympathicus and from the thoracic vagus.

The findings of Fallopius were confirmed by Willis (1664), Vieussens (1716), Senac (1749), Haller (1762), Neubauer (1786), Walter (1783), Berends (1793) and others. In 1794 Scarpa published a work entitled "Tabulae neurologicae ad illustrandam historiam cardiacorum nervorum", including a precise and detailed description of cardiac plexuses.

The book by Remak, published in 1844, revealed that beside nerve plexuses there are also nerve cells in the heart. This was practically the last step of the series of investigations into cardiac innervation. It was established that nerves controlling the heart's movements may be divided into two groups. One of them consists of nerves arising extracardially such as the cardial branches of the vagal and sympathetic nerves. The other group is represented by cardiac ganglia located in the heart's wall and communicating by processes partly with the rami of the vagal and sympathetic nerves and partly with the structures constituting the heart's wall. Later investigators (Hirschfeld, 1853; Drummond, 1859; Reynier, 1880; Thane, 1896; Mollard, 1908; Hovelacque, 1927; Mitchell, 1953, 1955) have restricted themselves to the clarification and closer investigation of details.

Accordingly, a closer approach to the innervation of the mammalian heart should proceed from the examination of branches received from distant nerve trunks and be continued by the structural study of ganglia found in the heart wall, namely in its atrial portions. Below we give a short anatomical survey of these nerve elements and continue by discussing of their microscopic relations.

Anatomy of Heart Nerves

Owing to a certain autonomy in comparison to vagal branches, nerve branches sent to the heart from the sympathicus have been designated nervi cardiacei. The less autonomic vagal branches have been termed rami cardiacei.

The Sympathetic Nerve Supply of the Heart (Nervi cardiacei)

The preganglionic fibres of sympathetic fibres innervating the heart constitute the axons of the nerve cells located in the intermedio-lateral horn of the spinal cord's grey matter, more precisely in the 1st to 4th, or the 2nd to 5th thoracic spinal segments. These axons, covered by very thin myelin sheaths and included

into the white connecting rami descend through the ventral roots of the corresponding spinal segments to the first five paravertebral ganglia. Nerve cells present in the lateral horn of the grey matter are essentially neurons located in the passage of the sympathetic system and conducting impulses from the higher cerebrospinal centres to the more distant elements of the system. As a matter of fact, these cells are influenced also by the sensory fibres ascending through the intervertebral ganglia into the corresponding segments of the spinal cord's grey matter.

Part of the preganglionic fibres ends in the paravertebral ganglia, while others traverse them and pass further within the sympathetic trunk synapsing with some of the nerve cells constituting the cervical ganglia. The axons of these synaptic nerve cells are the efferent or postganglionic fibres running to the structures constituting the heart wall, namely the myocardium.

Three pairs of sympathetic heart nerves arise from the jugular sympathetic ganglia, or the sympathetic trunk, whereas the fourth comes from four or five upper thoracic ganglia. The finding that thoracic sympathetic fibres also participate in cardiac innervation was temporarily attributed to Braeucker (1927), resp. Ionescu and Enachescu (1928); Mitchell (1949), however, traced this discovery back to Weber (1815), who described the above conditions on the basis of his studies on calves. In man, the observation of Weber was confirmed by Swan (1830).

The uppermost of the four sympathetic heart nerves is the superior cardiac nerve (nervus cardiacus superius), arising by one or two roots from the lower medial part of the superior cervical ganglion and receiving additional fibres from the sympathetic trunk immediately below that ganglion. It descends dorsally behind the lower thyroid artery, then it follows on the left the innominate artery and on the right the common carotid artery to reach the heart. It anastomoses with the upper cardiac branches of the vagus as well as with the two laryngeal nerves.

The second sympathetic heart nerve (nervus cardiacus medius seu magnus) arises from the middle cervical ganglion (ganglion cervicale medium) or, in its absence, from the corresponding region of the sympathetic trunk. From its origin it descends obliquely downwards and inwards, anastomosing frequently with the recurrent vagal nerve (nervus recurrens vagi).

The lower sympathetic heart nerve (nervus cardiacus inferior seu parvus) arises from the lower cervical (ganglion cervicale inferius) and from the first thoracic ganglion (ganglion stellatum). It anastomoses with the recurrent nerve and unites with the middle cardiac nerve to form the nervus cardiacus crassus.

The fourth branch consists of four or five fine sympathetic rami arising both left and right from the two to four (infrequently also five and six) thoracic sympathetic ganglia or from the interganglionic portions of the thoracic sympathetic trunk. Some of these rami enter directly the cardiac plexus, others join transitorily the filaments running to the trachea, oesophagus, aorta or pulmonary artery. Later on they separate and go to the heart. According to Saccomanno (1943), the heart nerves exiting from the thoracic sympathetic arise, from the first six or seven paravertebral ganglia and supply the cardiac plexus with many more fibres than the cervical sympathetic heart nerves.

The Vagal Nerve Supply of the Heart (Rami cardiacei)

The parasympathetic preganglionic nerve fibres of the heart run within the vagal nerve and in the cranial part of the nervus accessorius. The latter soon joins the vagus. The preganglionic fibres maintaining their myeline sheaths also within the vagal cardiac rami, synapse with the ganglia of the cardiac plexus and of the heart wall. We owe the description of vagal branches to Walter (1783, 1819), Andersch (1793), Scarpa (1794), Swan (1830), Valentin (1843), Bourgery (1844), Hirschfeld (1853), Sappey (1872), Schwalbe (1881), Reynier (1880), Cyon (1905), Sobotta and McMurrich (1907), Mollard (1908), Müller (1924), Braeucker (1927), Hovelacque (1927), Tinel (1937) and Tardieu and Tardieu (1948). The vagal branches form an upper and a lower group.

Trunks constituting the upper group (rami cardiacei superiores) arise in the jugular part of the vagus between the nervus laryngeus superior and inferior and communicate immediately with the corresponding sympathetic cardiac rami, namely with those coming from the middle cervical or paravertebral thoracic ganglia.

The trunks constituting the lower group (rami cardiacei inferiores) arise in the inflexion of the nervus recurrens, in the vagus itself and in the nervus recurrens.

Out of the vagal rami the nervus depressor descends separately. It has usually two roots, one from the vagus and one from the nervus laryngeus superior. That nerve, presently called aortic nerve (nervus aorticus) descends inside the vago-sympathetic sheath in all mammals but the rabbit. In the latter animal this nerve descends to the aortic arch on both sides outside the vago-sympathetic sheath. The left one arrives at the anterior and the right one at the posterior surface of the arch.

Cardiac Plexus (Plexus cardiacus)

Shortly after leaving their sites of origin, the sympathetic and vagal heart rami approach each other until by mutual exchange of their trunks, rami and fibres they form a common plexus, the cardiac plexus (plexus cardiacus). The cardiac plexus has two parts. The superficial finer plexus (plexus cardiacus superficialis seu anterior) is located on the concave side of the aortic arch (arcus aortae), extending to the pulmonary artery's division. The deeper and richer plexus (plexus cardiacus profundus) is found in the area enclosed by the aorta and the tracheal bifurcation.

The superficial plexus (plexus cardiacus superficialis seu anterior) is constituted mainly by the upper branches of the left vagus and the fibre trunks of the left superior cardiac nerve. These are joined by some fibres from right and left lower heart nerves as well as by branches of the right heart nerves passing along the innominate artery.

Plexus cardiacus profundus seu posterior is richer than plexus cardiacus superficialis seu anterior. All heart nerves and branches contribute to its formation, except for the left upper heart branch and the vagalrami discussed in connection with the superficial plexus.

Both cardiac plexuses emit thick peripheral branches descending mainly along the coronary arteries. These rami constitute the two coronary plexuses (plexus coronarii), i.e. the left and the right one (plexus coronarius dexter and plexus coronarius sinister).

The right coronary plexus (plexus coronarius dexter) receives fibres from both plexuses. These fibres surround the aorta and are grouped at the origin of the right coronary artery (arteria coronaria dextra). They pass along the right coronary artery and provide for the motor and sensory innervation of the right ventricle and left atrium.

The left coronary plexus (plexus coronarius sinister) receives most of its nerve fibres from the deep cardiac plexus (plexus cardiacus profundus), but some of its rami are sent from the upper cardiac plexus (plexus cardiacus superior). Its branching off starts behind the pulmonary artery and the rami descend towards the origin of the left coronary artery (arteria coronaria sinistra). Part of the branches follow a descending path (rami descendentes) along the anterior heart surface down to the apex, part of them to the margo obtusus cordis. Only a minor part of the fibres reaches the heart's dorsal surface. The latter receives its nerve supply mainly from the right coronary plexus.

The rami of the right and left coronary plexuses form separately located but interconnected plexuses in the epicardium, myocardium and endocardium and are termed after the layer in which they are located. In this sense we distinguish between epicardial, myocardial and endocardial plexuses (plexus epicardialis, plexus myocardialis and plexus endocardialis). These plexuses, apart from the outer part of the epicardial plexus visible also macroscopically, are apparent only in properly impregnated preparations. They are constituted by fibre plexuses, bundles and fibres whose structure, descent and interconnections can be studied only microscopically.

Histology of the Cardiac Nerves

Histological examinations were performed on the hearts of the following mammalian species, including man: mole (*Talpa europaea*), common bat (*Myotis myotis*), domestic cat (*Felis domestica*), fox (*Vulpes vulpes*), dog (*Canis familiaris*), rabbit (*Lepus cuniculus*), rat (*Epymis rattus*), guinea-pig (*Cavia cobaya*), swine (*Sus scrofa domestica*), sheep (*Ovis aries*), cow (*Bos taurus*), horse (*Equus caballus*) and man (*Homo sapiens*). Examinations were carried out by different staining and impregnation methods. For this particular purpose the method of Bielschowsky proved to be best in the modifications suggested by Gros, Ábrahám, Jabonero and Cauna. Nerve transfixions were performed in cats, foxes and rabbits partly to clarify the relationship of extracardiac nerve fibres with the tissues of the heart wall and the intracardiac ganglia, partly because our previous studies revealed a marked increase of argentophilia of nerve fibres after transfixion of the nerve. Most of our examinations were made on frozen sections of 30–40 μ thickness, impregnated in most cases also with gold.

Below we describe first the forms of interconnections between the mural plexuses and the individual histological layers of the different heart portions and secondly the innervation of the valves and pericardium.

Atrium

In the relatively thin atrial wall, as in the lower vertebrates three layers are distinguished. Outside there is the epicardium, subsequently the myocardium and the innermost layer is the endocardium. The epicardium and endocardium are relatively thin, myocardium constituting the bulk of the atrial wall.

Essentially the epicardium is a connective tissue layer of varying thickness, constituted by collagenous bundles. It is attached to the myocardium by a loose, fibrous connective tissue. In that loose tissue here and there great masses of fat cells are accumulated, thus the epicardium is relatively easily peeled off from the heart's wall. In the collagenous tissue also large numbers of connective tissue cells are apparent, containing elongate central nuclei. These cells usually extend to numerous, granulated processes. The processes, namely their granulations, are markedly argentophilic, thus particularly in darker, silver-impregnated preparations they appear with a marked sharpness. The processes of the cells mutually anastomose, constituting a coherent network. Outwards, the connective tissue layer continues in a thinner layer rich in elastic fibres. In the latter, fibres are undulating and display a certain affinity to silver nitrate. This phenomenon is particularly conspicuous in *in toto* impregnated epicardium preparations. Outwards the elastic layer is covered by a simple epithelium consisting of polyhedral, flat or sometimes elongate cells. Their cytoplasms are homogeneous, their nuclei are centrally situated and chromatin-poor.

The atrial epicardium is extraordinarily rich in nerve fibres. Nerve trunks exiting from the coronary plexus and descending along the coronary arteries into the atria reach the wall at this area to form the epicardial plexus (plexus epicardialis). Most nerve trunks found in this plexus are thick consisting of some myelinated vagal sensory fibres, the rest being central vagal or sympathetic fibres, thin smooth-edged, undulating. Rami exiting from the thick trunks form plexuses which are joined also by rami coming from the adjacent trunks (Fig. 52).

As in all higher vertebrates, here also the mutual exchange of fibres has been frequent, viz. a greater or lesser number of fibres are often seen to exit from one nerve trunk, enter another one and continue their passage in the latter. Fibres exiting from a nerve trunk in pairs or singly constitute a fine plexus, namely in the inner part of the epicardium. In some animals (cat) there are numerous thick fibres in these epicardial plexuses. As a rule, thick fibres descend singly, run an undulating path and at their ends they subdivide into delicate rami constituting larger nerve endings. Such nerve endings are innumerable, particularly in the feline epicardium. The rich telodendrion plexuses constituting the latter contain groups of small roundish sensory cells and here and there connect with each other by ultraterminal fibres. Such nerve endings were found also in other animal species,

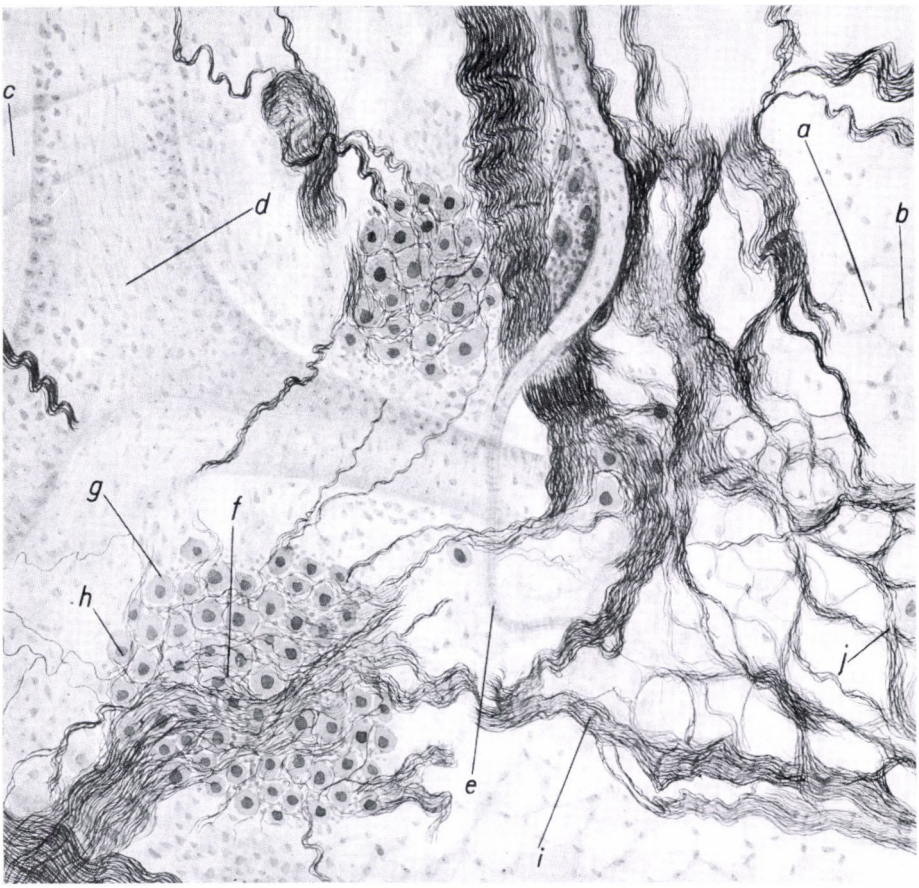

FIG. 52. *Felis domestica*. Heart; nerve fibre plexus in the right atrial epicardium. (a) Fat cell; (b) nucleus of fat cell; (c) connective tissue; (d) artery; (e) striated muscle fibre; (f) ganglion; (g) ganglion cell; (h) nucleus of ganglion cell; (i) nerve fibre bundle; (j) nerve fibre plexus. Bielschowsky–Ábrahám's method. Microscopic magnification 600×, reduced photographically to ½

exhibiting, however, certain differences in form, structure and grouping. This problem will be discussed later. In the atrial epicardial plexus numerous sympathetic ganglia are seen, mainly at the entrance of the large hollow veins (Fig. 53).

The atrial myocardium consists of ramified striated muscle fibres. The muscle cells have large nuclei of roundish, occasionally brick-like shape. In impregnated preparations the myofibrils are quite conspicuous. Striation is dense but not too marked. The sarcoplasm is granulated, the sarcolemma thin and attaches closely to the muscle fibre layer. The connective tissue constituting the myocardium's basal tissue appears here and there in larger masses and the collagenous bundles are well visible particularly in intensively impregnated preparations.

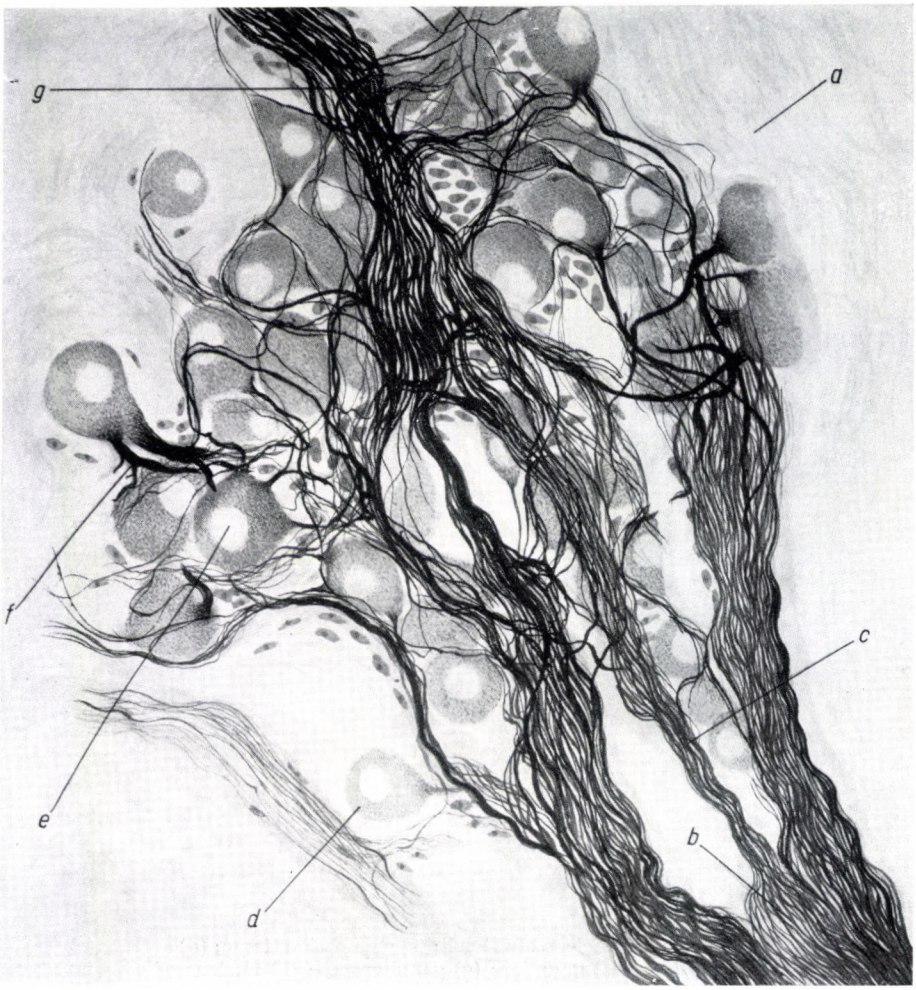

FIG. 53. *Canis vulpes*. Ganglion in the right atrial epicardium. (a) Connective tissue; (b) nerve trunk; (c) nerve bundle; (d) nerve cell; (e) nucleus of nerve cell; (f) process of nerve cell; (g) nerve fibre plexus. Bielschowsky–Ábrahám's method. Microscopic magnification 600×, reduced photographically to ½

In the atrial myocardium, nerve trunks arriving from the epicardial plexus constitute plexuses which are in some places rich and in others poor (Fig. 54). In general, they are readily impregnated and also the forms of connections between the single nerve and muscle fibres are well visible although the end bulbs were seldom seen even in cases where nerve sections were performed. It was, however, definitely demonstrable that between the bundles of muscle fibres there were descending bundles of nerve fibres constituted by smooth fibres of varying thickness which sent single nerve fibres to the muscle fibres. The former then followed

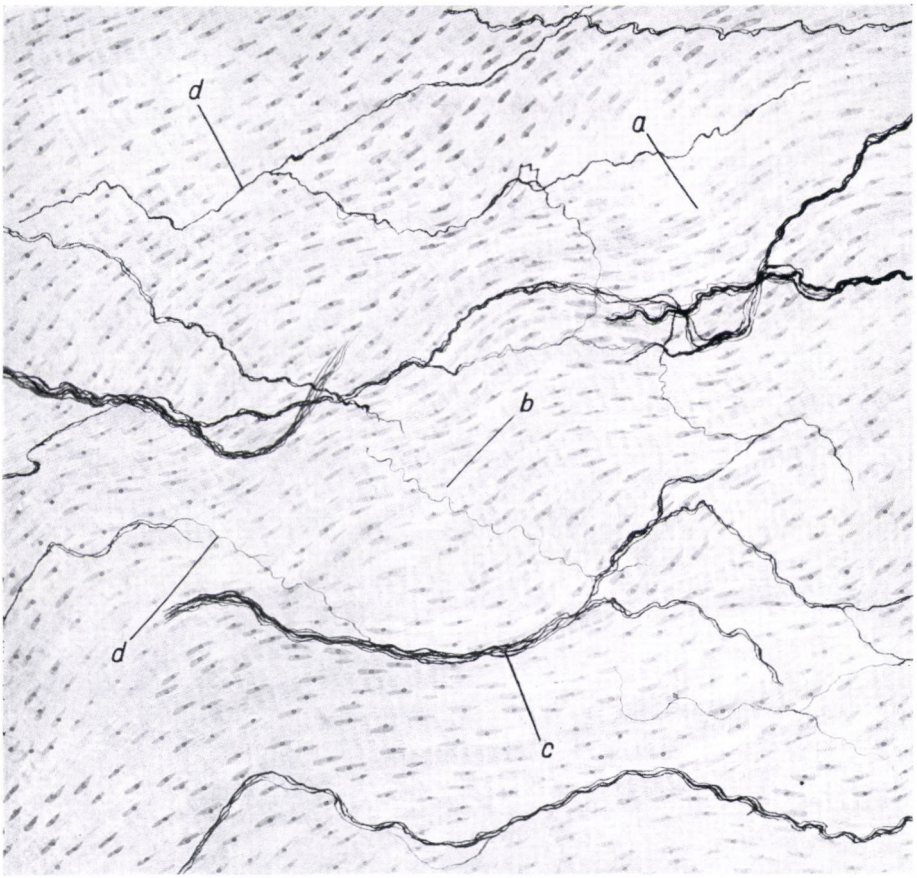

FIG. 54. *Canis vulpes*. Heart; myocardial plexus in the right atrium. (a) Striated muscle fibre; (b) nucleus of striated muscle fibre; (c) nerve bundle; (d) nerve fibre. Bielschowsky–Ábrahám's method. Microscopic magnification 240×, reduced photographically to ½

the muscle fibres' course running either along them or attaching to their surfaces. The delicate thin nerve fibres end inside the muscle fibres, probably in a hypolemmal manner by end bulbs similar to the endings seen in the myocardia of the other animals discussed in the foregoing (Fig. 55).

The endocardium is thin, consisting in most cases of fine collagenous connective tissue bundles containing also a variable number of elastic fibres. Its thickness is variable and in some species, e. g. in man, it contains also large masses of smooth muscle cells. With the common staining techniques, large nuclei become apparent within the cells constituting the connective tissue layer. In slightly over-impregnated endocardium in which the nerve fibres were, naturally, invisible, connective tissue cells appeared with a particular clearness. Their processes were

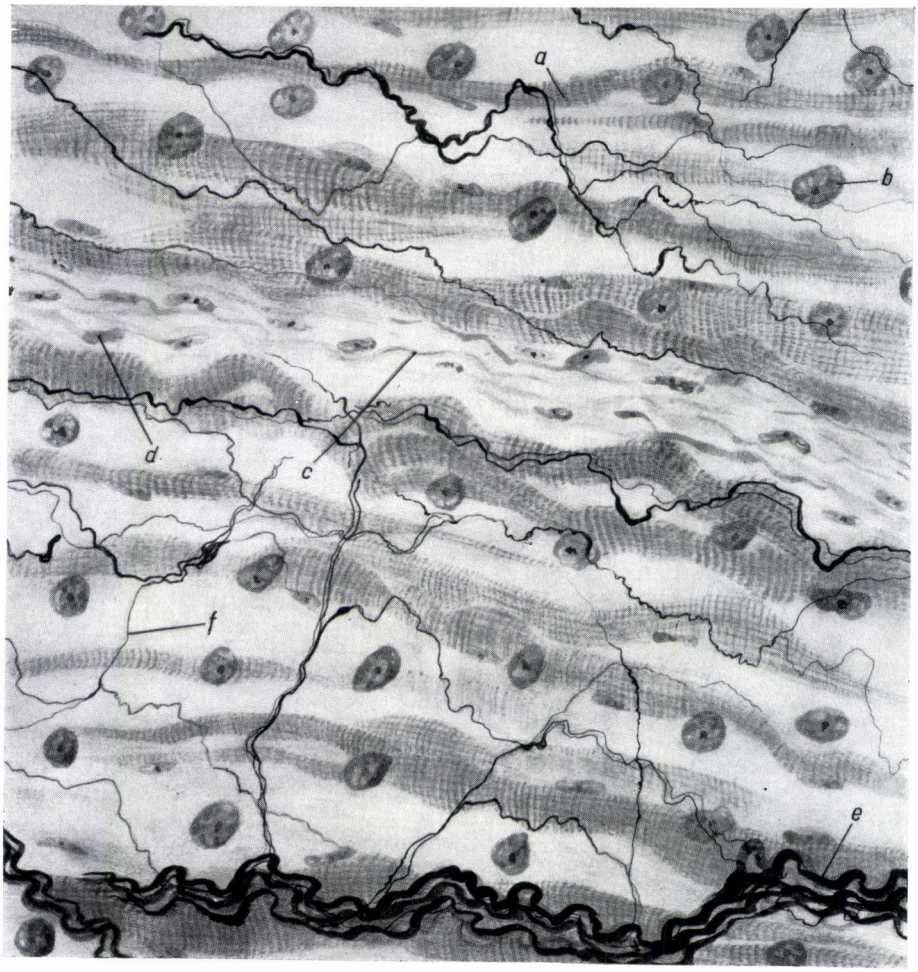

FIG. 55. *Sus scrofa domestica.* Heart; nerve plexus in the right atrial myocardium. (a) Striated muscle fibre; (b) nucleus of the striated muscle fibre; (c) connective tissue fibre; (d) nucleus of the connective tissue cell; (e) nerve bundle; (f) nerve fibre. Bielschowsky–Ábrahám's method. Microscopic magnification 600×, reduced photographically to ½

seen to anastomose to form a particularly dense network of cell processes. It should be noted that in the course of our neurohistological work, impregnated connective tissue cells were nowhere seen with such clarity as were those apparent in the atrial endocardium.

Inside the endocardium is lined by epithelium consisting of flat or polygonal cells. These cells are characterized by unproportionally large nuclei of regular spherical shape. This typical nuclear shape is an important aid in the examination

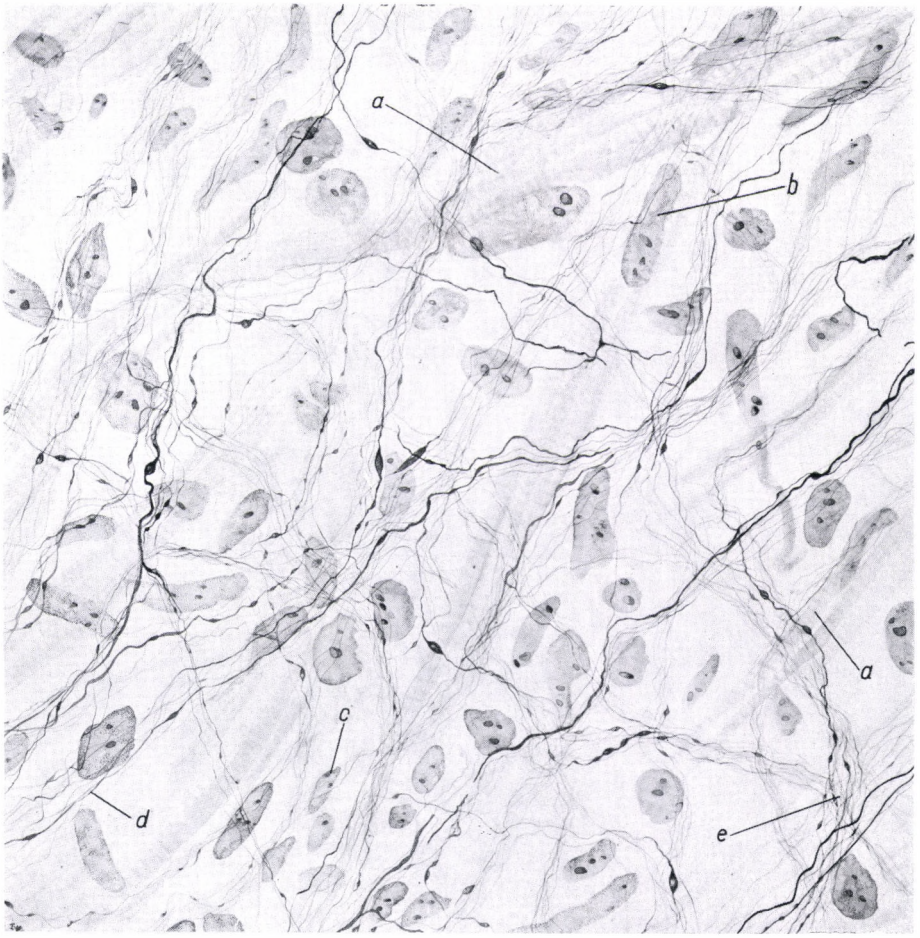

FIG. 56. *Epimys rattus norvegicus*. Heart; nerve plexus in the right atrial endocardium. (a) Striated muscle fibre; (b) nucleus of striated muscle fibre; (c) nucleus of connective tissue cell; (d) nerve fibre; (e) nerve plexus. Bielschowsky–Ábrahám's method. Microscopic magnification 1350×, reduced photographically to ½

of frozen sections when the association of the connective tissue with epicardium or endocardium has to be decided.

The innervation of the atrial endocardium is rich and markedly differentiated. On its myocardial border larger and smaller rami constitute a large-mesh network. The fibres of the network are relatively thick (Fig. 56). In some species (rat) a sequence of varix-like protrusions is seen. From the plexus exit single fibres, traversing each other in all directions to form the second, inner nerve structure of the endocardium. They constitute a third, very delicate plexus located directly on



FIG. 57. *Felis domestica*. Heart; receptors in the right atrial endocardium, 72 hr after section of the right vagus. (a) Connective tissue; (b) nucleus of the connective tissue cell; (c) striated muscle fibre; (d) nucleus of striated muscle fibre; (e) nerve fibre; (f) neurofibrillar end plate. Jabonero's method. Microscopic magnification 400×, reduced photographically to ½

the endothelial cells. This suggests that the fibres of the network may connect with the cytoplasm of the endothelial cells as well. The thin end fibres of the third plexus terminate freely in end bulbs between the endothelial cells. In other cases, the thick fibres traversing the endocardium exhibit arborization. The rami thus arisen branch again and the extraordinarily rich but easily visible nerve end trees are attached by smaller or larger end plates to the endocardial elements (Fig. 57).

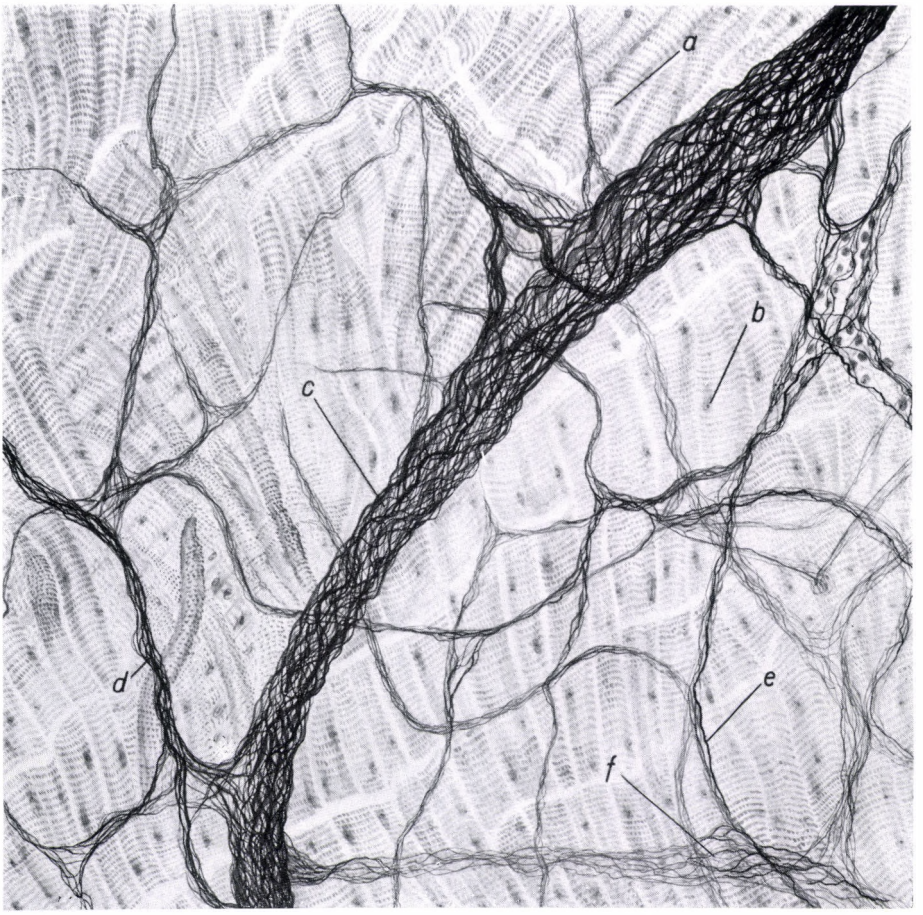

FIG. 58. *Epimys rattus norvegicus*. Nerve fibre plexus in the atrial septum. (a) Striated muscle fibre; (b) nucleus of striated muscle fibre; (c) nerve trunk; (d) nerve bundle; (e) nerve fibre; (f) nerve fibre plexus. Bielschowsky–Ábrahám's method. Microscopic magnification 160×, reduced photographically to ½

Atrial Septum (Septum atriorum)

Essentially the atrial septum is a doubling of the endocardium, with a central, relatively thick myocardial layer. The endocardium is a whitish, slightly translucent connective tissue membrane of varying thickness, bordered against the lumen by endothelium. The inner part of the connective tissue membrane consists of relatively thick collagenous fibres of undulating path. In strongly impregnated preparations also fibres of spiral spring-like shape may be seen. The inner part of the connective tissue membrane contains numerous elastic fibres. They are mark-

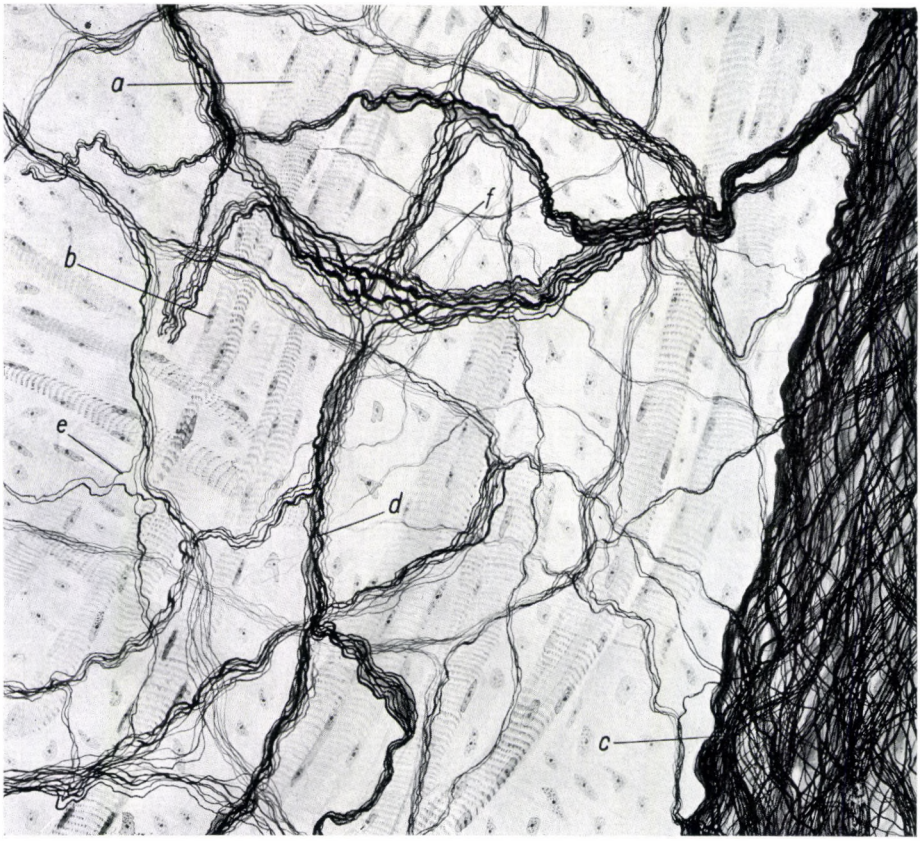

FIG. 59. *Epimys rattus norvegicus*. Nerve plexus in the atrial septum. (a) Striated muscle fibre; (b) nucleus of striated muscle fibre; (c) nerve trunk; (d) nerve bundle; (e) nerve fibre; (f) nerve fibre plexus. Bielschowsky–Ábrahám's method. Microscopic magnification 300×, reduced photographically to ½

edly undulating and run through and through each other's path to form a network-like system in whose empty meshes markedly branched connective tissue cells are seen. Their processes anastomose and together with the elastic fibres constitute a rich network. The endothelial cells are elongate and their middle parts protrude slightly into the lumen. Their nuclei are round and centrally situated, differing markedly from those of the connective tissue cells both in shape and appearance.

Nerve fibres form a plexus in the endocardium. Essentially this plexus consists of two parts. One extends towards the myocardium and consists of rami containing a smaller or larger number of fibres. The other, attaching directly to the endothelial cells, is constituted by thin fibres which show rich ramifications in higher mammals the individual rami ending in triangular neurofibrillar end plates of varying dimensions.

Like the other muscular parts of the heart wall, the myocardium consists of ramified, anastomosing striated muscle fibres with clearly visible Eberth's lines. Some time ago the latter were regarded as myofibrillar aggregations but, at present, they are considered cell borders on the basis of electron microscopic examinations. The myocardium is extraordinarily rich in nerves. This is obvious also in sections, but particularly true pictures are presented by *in toto* preparations obtained from the atrial septum of small mammals. These show that inside the muscular layer very thick nerve trunks are passing centrally, and send systems of branches towards both endocardial layers (Fig. 58). These branches, too, form a very rich network constituted mainly by smooth-edged sympathetic fibres and a lesser number of thick vagal fibres. From the second plexus, formed by the systems of branches, exit masses of single fibres to form delicate plexuses on both sides of the border between myocardium and endocardium. The connections of muscle fibres and nerve fibres are very close here also, yet the end structures are but infrequently apparent. The shape and position of the connections are discussed in a later chapter (Fig. 59).

Ventricle (Ventriculus)

The walls of the two ventricles are relatively thick, that on the left one being thicker for functional reasons. In cross sections of the wall the individual histological layers are clearly recognizable. The epicardium and endocardium both have a loose structure and whitish colour, whereas the myocardium's structure is more compact and shows a reddish hue owing to the large amount of blood present therein.

The epicardium is a relatively thick connective tissue layer. It is peeled off very easily from the ventricles' walls, particularly from the left one. In the overwhelming majority of the cases it is bordered against the myocardium by a well-developed connective tissue consisting of loose fibres and outwards by a simple epithelium. Its middle part consists essentially of a structurally more compact connective tissue layer whose thickness varies with the species, but in every case consists of collagenous bundles among which also some elastic fibres and connective tissue cells are present. The inner loose connective tissue layer is constituted by bundles of collagenous fibres and a smaller number of elastic fibres. Among the bundles many fat cells are present here and there; this is the reason why the epicardium peels off so easily from the myocardium. Between connective tissue layer and epithelium there is a connective tissue matrix consisting mostly of elastic fibres which arrange in a network-like fashion beneath the epithelium. The epithelial cells are elongate, have roundish nuclei and attach closely to the epicardium's outer fibrous layer. In general, the individual layers are attached to each other firmly and keep together also during prolonged treatment.

Examinations of the atrial epicardium's nerve elements are most readily performed in *in toto* preparations. In these, nerve trunks, thinner and thicker rami and sometimes even single fibres appear quite sharply. In general, however, only the

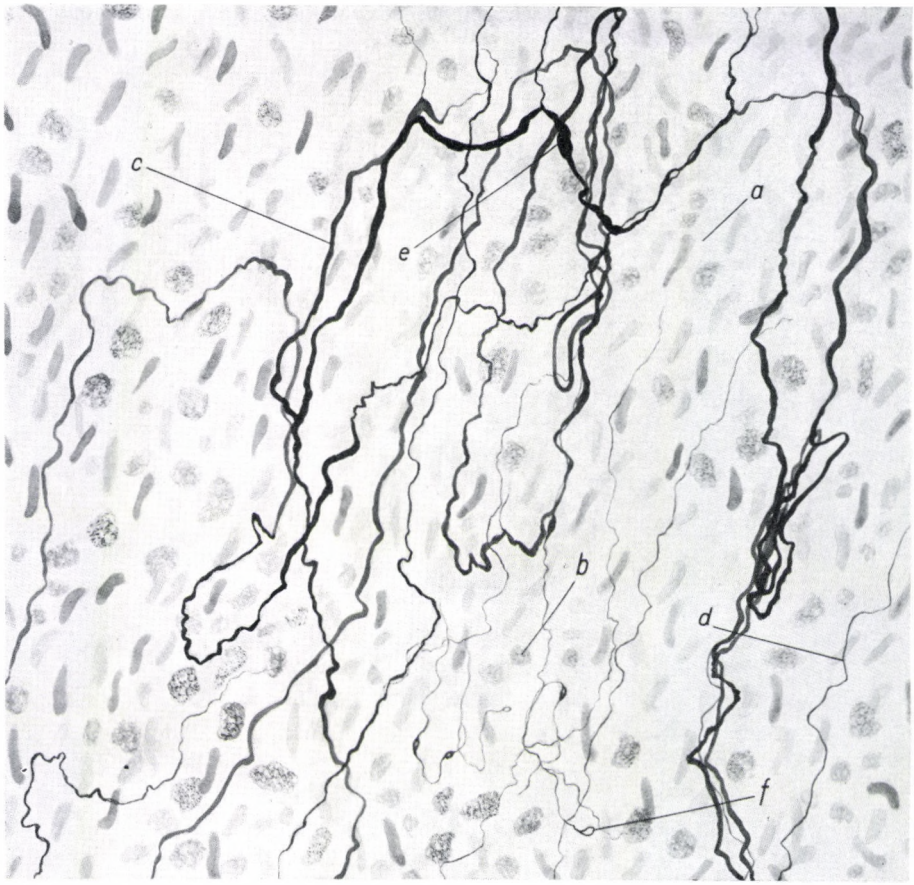

FIG. 60. *Ovis aries*. Heart; nerve plexus in the right atrial epicardium. (a) Connective tissue; (b) nucleus of the connective tissue cell; (c) thick nerve fibre; (d) thin nerve fibre; (e) varix; (f) nerve ending. Bielschowsky–Ábrahám's method. Microscopic magnification 400×, reduced photographically to ½

gross plexuses are well seen, as the more delicate fibres and end connections escape impregnation. Therefore precise information on the arrangements and connections of epicardial nerve elements can be obtained only by examining them in *in toto* preparations as well as in frozen sections. On the basis of thorough studies of this type, we derived the following general conclusions applying to all kinds of mammals.

Essentially the true epicardial plexus consists of three systems of plexuses: outer, middle and inner systems. The outer system is formed by thick trunks which anastomose by their smaller rami. The middle system is constituted by ramifications of varying thickness, whose bundles and single fibres enclose several smaller or larger areas. The inner network is formed mainly by rami and single fibres

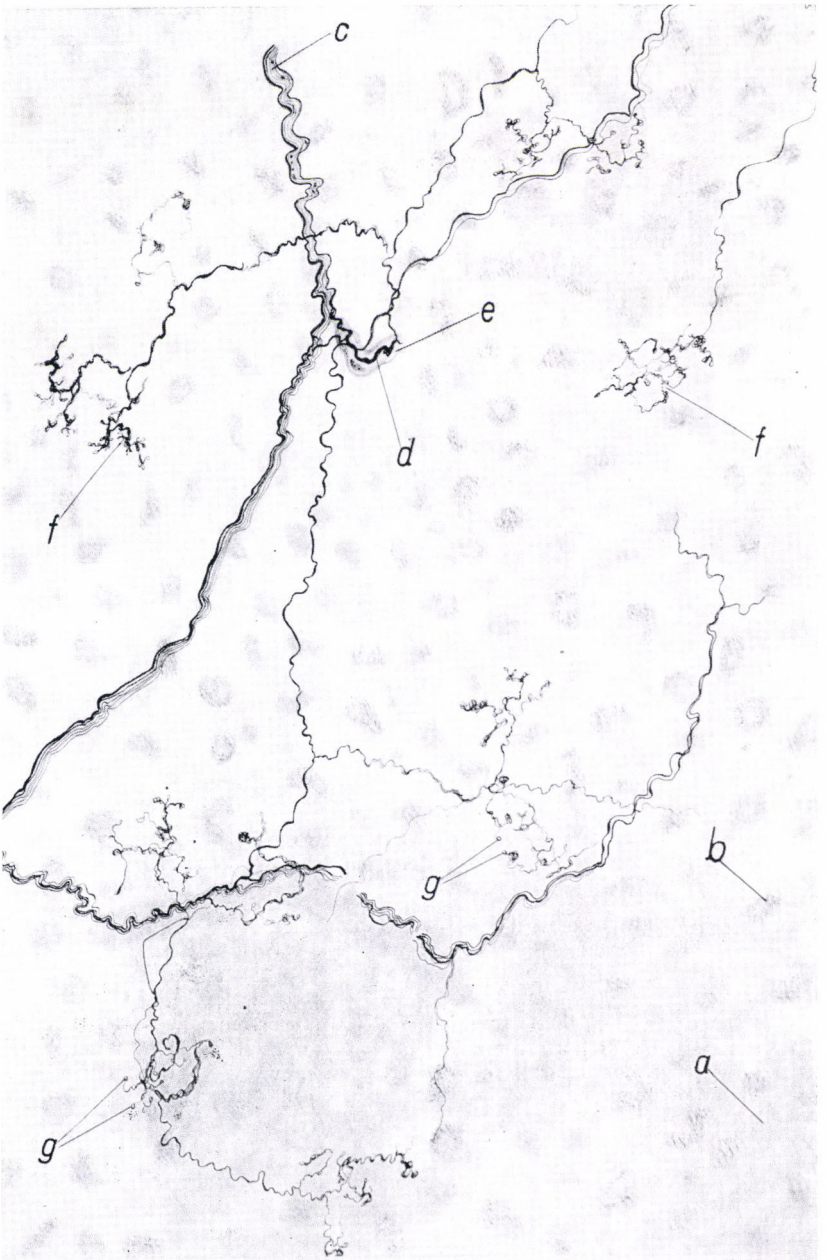

FIG. 61. *Felis domestica.* Heart; receptor system in the right ventricular epicardium, 168 hr after bilateral vagotomy. (a) Connective tissue; (b) nucleus of epithelial cell; (c) nerve bundle; (d) thick nerve fibre; (e) myelin sheath; (f) nerve end organ; (g) end ring. Jabonero's method. Microscopic magnification 200×, reduced photographically to ½



FIG. 62. *Fiber zibethicus*. Heart; nerve plexus in the ventricular myocardium. (a) Striated muscle fibre; (b) nucleus of striated muscle cell; (c) capillary vessel; (d) nerve bundle; (e) nerve fibre. Bielschowsky–Ábrahám's method. Microscopic magnification 600×, reduced photographically to ½

which, during their passage to the myocardium, gradually subdivide to form a denser plexus (Fig. 60). In all the three plexuses, markedly thick fibres are present in quite large numbers. Particularly thick fibres are seen in the cat's epicardium. They are sensory fibres, all terminating in sensory end apparatuses of particular shapes which in certain cases occur in masses in the epicardium, namely in its outer part immediately adjacent to the epithelium (Fig. 61).

The ventricular myocardium consists of ramified striated muscle fibres arranged in bundles. The myocardial basal tissue consisting of collagenous fibres and a lesser



FIG. 63. *Canis familiaris*. Endocardial plexus in the right ventricle. (a) Connective tissue; (b) nucleus of the connective tissue cell; (c) striated muscle fibre; (d) nucleus of striated muscle fibre; (e) nerve plexus; (f) thick fibre; (g) thin fibre; (h) varix. Bielschowsky–Ábrahám's method. Microscopic magnification 400×, reduced photographically to ½

number of elastic fibres, is well visible between the muscle bundles along the vessels and to a lesser extent also along some of the muscle fibres. In slides stained by simple methods, the basal tissue is as a rule not apparent, except along the vessels where it may be quite well visible. If, however, frozen sections are slightly over-impregnated or if excess ammonia is mixed in the silver nitrate, the elements of the basal connective tissue appear quite sharply and show a very rich system of fibres which may be easily mistaken for a nerve plexus by the untrained observer. Fibres constituting the connective basal tissue are mark-

edly undulating, spiral or spring-like and traverse the myocardium amply in all directions.

Nerve fibres going from the epicardium to the myocardium in the form of smaller trunks and rami, constitute the myocardial plexus which is divided into several layers on the basis of its structure. These layers differ from each other in the formation, position and the rich or loose character of their plexuses. In our opinion, differentiation on that basis is unfeasible. It should be noted, however, that adjacent to the epicardial and endocardial plexuses, the myocardial plexus appears to be more rich than in the middle part of the myocardium (Fig. 62).

The ventricular endocardium is a thin, whitish membrane thickening markedly at the exit of the large arterial trunks and continuing in their intima. It is attached closely to the myocardium. It is composed of a relatively thin connective tissue membrane bordered against the lumen by endothelium. The connective tissue layer consists mainly of collagenous bundles and also numerous elastic fibres are present, mostly adjacent to the epithelium. There are also some smooth muscle cells, arranged occasionally in bundles. The endothelial cells are flat, with roundish nuclei and homogeneous cytoplasm.

The nerve fibres go from the myocardium to the endocardium in the form of smaller or larger rami to constitute the loose endocardial plexus. The rami forming this plexus contain relatively few nerve fibres. Most of these fibres are of vagal origin, thick and undulating in descent. The minority of the fibres are thin smooth sympathetic ones, mainly supplying the vessels (Fig. 63). The thick fibres become gradually thinner and go directly beneath the endothelium where they form particular sensory endings which are but infrequently seen. In other areas they become markedly thin and form a dense plexus, some end fibres of which attach to the endothelial cells' cytoplasm by end bulbs.

Ventricular Septum (Septum ventriculorum)

Shape, dimension and thickness of the ventricular septum vary widely with the individual mammalian species. Essentially it is a slightly bent, relatively thick muscle layer, covered on both sides by endocardium. Its surface is generally smooth, but in certain cases it is uneven and also protrusions occur on its surface. The layers constituting the ventricular septum are described below.

The endocardium is a whitish, relatively thin and transparent membrane consisting of a connective tissue layer bordered against the lumen by endothelium. The connective tissue layer is of compact structure and attaches closely to the myocardium. It is constituted by collagenous connective tissue bundles in whose discontinuities there are smaller or larger undulating elastic fibres and starlet-shaped branched connective tissue cells. Elastic fibres and connective tissue cells are both markedly argentophilic. The endothelium is very thin, consists of flat cells in whose thickened and protruding central part chromatin-poor nuclei are apparent. The endocardium is poor in nerve fibres, containing here and there some richer networks constituted predominantly by thick fibres. Some fibres of the

plexuses form loose coils, others arborize and their delicate end fibres attach by triangular end plates to the connective tissue elements. Some delicate end fibres terminate in end bulbs immediately beneath the endothelium (Fig. 64). In the endocardium of the ventricular septum in the cat, there are numerous elongate ganglia belonging to the sympathetic system, according to their structure and sensory endings exhibiting several typical forms. In the case of bilateral vagus section, the latter degenerate, thus they obviously belong to the vagal sensory system.

The myocardial layer of the ventricular septum hardly differs from the normal myocardial muscles. Its innervation roughly corresponds to that of the ventricular myocardium with the difference that at the site of its junction with the endocardium or sometimes even more distantly, numerous nerve trunks, rami and fibre plexuses are present supplying the Purkinje bundles that enter into the system of mechanical muscles. There are rich fibre plexuses along the vessels. Some of these fibres follow the capillaries almost along their whole length. In the myocardium, sensory fibres are present also adjacent to the endocardium. They traverse the muscle fibres in a winding path, forming here and there loops and loose coil-like end structures.

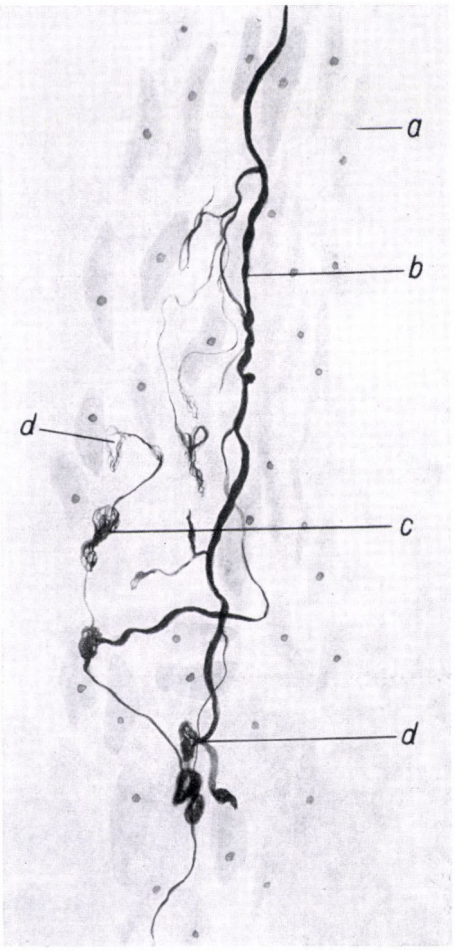

FIG. 64. *Felis domestica*. Sensory nerve terminal system in the endocardium of the ventricular septum. (a) Nucleus of the connective tissue cell; (b) nerve fibre; (c) neurofibrillar intermediary plate; (d) neurofibrillar end plate. Bielschowsky–Gros–Cauna's method. Micro-scopic magnification 1350×, reduced photographically to ½

STIMULUS-CONDUCTING SYSTEM

Historical

The investigation of the stimulus-conducting system has a long history. The first examinations were made in 1845 by Purkinje, who described specially large polyangular cells in the heart of sheep. These cells were named after him, Purkinje cells. Nevertheless, Purkinje's discovery was neither properly understood nor

appreciated by his contemporaries. The Purkinje cells were regarded as embryonic heart muscle cells and were believed to transform gradually to active heart muscle fibres (Koelliker, Aeby, Ranvier). A further contribution to the exploration of the stimulus-conducting system was provided by Gaskell, who in 1883 described a bundle constituted by stimulus-conducting fibres in the atrioventricular portion of the tortoise's heart. Later on the same bundle was found in the heart of mammals (man, sheep, dog, mouse) by His (1893) and it was his discovery that became generally known. Nevertheless, this discovery, too, remained unappreciated by the contemporaries, although some of them made attempts to correlate the His' bundle with the heart's automatism. His himself had hinted at the bundle's possible relationship with the stimulus-conducting system. Research was conducted further in spite of the scanty interest. Retzer and Bräunig (1904) extended their studies also to the lower vertebrates and confirmed their findings experimentally, yet failed to arouse proper interest.

A decisive change of this attitude was brought about by Tawara's monograph published in 1906 under the title "Das Reizleitungssystem des Säugetierherzens". Tawara described the presence in the heart of mammals of a node of particular structure, located in the lower part of the right atrium and closely related with His' bundle. He also followed up the entire path of His' bundle and found it to continue in two branches going to the walls of the right and left ventricle, respectively. At the end of these branches he identified Purkinje fibres as the terminal parts of the stimulus-conducting system. He presented histological evidence that the node, named later Aschoff–Tawara's node, was enclosed by a connective tissue sheath, consisted of sarcoplasm-rich and myofibril-poor muscle fibres and was richly supplied with nerves. The nerve elements, described separately prior to Tawara, were fitted by him into a system claimed to produce and conduct the impulses required for heart function. Aschoff and Fahr confirmed Tawara's finding by discovering pathological alterations of the His' bundle in the hearts of patients with incoordinate cardiac function.

In 1906 the new stimulus to research work resulted in a further discovery. Wenkebach described a coherent muscle bundle in the region of the sinus and embryonic atrium and claimed it to be analogous with the atrioventricular system. In the physiological experiments conducted by him, that area proved to be most sensitive to stimulation. It should be noted that already Hippocrates observed a limited post-mortem functioning of the right auricle which he called therefore "ultimum moriens". Proceeding from Wenkebach's findings, Keith and Flack (1907) described in the hearts of the mouse and rat a node resembling the Aschoff–Tawara node. At present this node is called the sinoatrial node or, after its discoverers, the node of Keith and Flack.

The classical studies outlined in the foregoing text revealed in the mammalian heart wall the presence of two anatomically independent systems, viz. the sinoatrial and atrioventricular system. The extensive morphological and physiological studies conducted in the meantime have verified the independent existence of the two systems. Nevertheless, most of the details still remain unclarified.

The stimulus-conducting system of the human heart has been thoroughly explored and described on the basis of the investigations of His (1893), Keith and Flack (1907), Mackenzie (1910), Engel (1910), Haas (1911), Morison (1912), Mönckeberg (1921, 1924, 1926), Koch (1922), Benninghoff (1923), Géraudel (1928), Seto (1936), Ábrahám (1940), Duckworth (1952), etc. The information available on domestic animals is still far from being satisfactory. Most descriptions are restricted to certain details and given animal species (sheep, rat, calf, cat). Very scanty data have been, however, published on certain important domestic animals (pig, rabbit, horse, goat, dog).

In the course of their examinations on the atrioventricular system of domestic animals, Tawara (1906), Wilson (1909) and Engel (1910) detected the richness of nerve supply of the stimulus-conducting fibres and described also vegetative ganglia within the same system.

The rich innervation of the sinoatrial node was first reported by Keith and Flack (1907). More extensive studies were performed by Morison (1912), Meiklejohn (1913) and Woollard (1926), who demonstrated the presence of nerve fibres from the 18th prenatal day on and attracted attention to the rich nerve supply of the sinus. In man, Meiklejohn (1914) found numerous ganglia adjacent to the sinoatrial node. In animals, Oppenheimer (1912) and Eversbusch (1916) described ganglia and scattered nerve cells in the sinus region.

A detailed microscopic examination of the stimulus-conducting system was first performed by Mönckeberg (1921). Based on the studies of Holl, Lange, Petersen and Schander, Zimmermann (1923) described the anatomy and histology of the stimulus-conducting systems of the horse, calf, sheep, pig, dog and cat. Spaltcholz (1924) and Géraudel (1928) described the blood supply of the stimulus-conducting system. End rings were first demonstrated by Boeke (1926) in the stimulus-conducting system of the tortoise. Wolhynski (1928) examined the nerve fibres of the stimulus-conducting system in calf hearts stained with methylene blue.

Based on examinations of mammalian hearts, Lawrentiew and Gurwitsh-Lasowskaya (1930) divided the atrioventricular plexus into two parts, viz. a superficial and a deeper system. They reported ring-like nerve endings in the deeper system. They examined also the nerve cells constituting the ganglia and found them to belong to Dogiel's type I. The same authors described sensory endings in the connective tissue layer of the atrioventricular system and claimed their resemblance to the endocardial nerve endings. Plechkova (1936) described several sensory endings in the stimulus-conducting system of the cat and noted that in the mammalian heart the sympathetic fibres do not reach the ventricular muscles.

On the basis of the investigations of Seto (1936), Akkeringa (1949) and, recently, Meyling (1955), some authors adapted the reticular concept also to the heart's nerve system, claiming Reiser–Stöhr's terminal reticulum to be the true end formation and denying the presence of free endings in the myocardium.

Nonidez (1937) demonstrated the presence of sensory endings inside the muscular elements of the stimulus-conducting system. Schaefer (1950), examining the action current of the heart, found that baro- and chemoreceptors must be present both in atrial and ventricular muscles. Chabarowa (1953) performed experimental

morphological studies on sheep heart and concluded that in the common stem of the atrial and ventricular bundles the major part of the superficially located plexus consists of parasympathetic fibres. On the basis of the degeneration of pericellular apparatuses she regarded the ganglia located therein as belonging to the parasympathetic system and the sensory endings as belonging to the vagus system. Kuntz (1953) described encapsulated sensory endings in the atrioventricular bundle of man.

Since Yamanda (1934) and Halpern (1955), Muir (1955) also studied the sinoatrial node of the rat and found it to be recognizable from the 15th day of prenatal life on, in the form of a modified myocardium. He found that the node attained its largest size on the 1st to 3rd day prior to birth; in embryos and newly born rats it was essentially a compact syncytium. According to Muir, in postnatal life connective tissue enters into the sinoatrial node and its muscle elements come to resemble those of the ordinary myocardium. As to innervation, Muir noted that very likely there are no specialized endings, neither does the nerve supply differ from that of the surrounding tissues.

In this institute the structure and the innervation of the stimulus-conducting system have been studied both in human and animal material during the past years. The results have been described in several papers, thus in this volume we mainly report our findings on the heart of the pig (*Sus scrofa*), cow (*Bos taurus*) and horse (*Equus caballus*), and correlate them with the relevant literary data. For histological examination, specimens were fixed in Heidenhain's "Susa", for neurological studies in 10 per cent neutral or slightly alkaline (pH 7·5–8·0) formalin. Histological sections were stained with haematein–eosin, Van Gieson, Mallory and Heidenhain's iron haematoxylin stains. Glycogen was demonstrated by the special staining method of Best or with PAS-reaction. Neurohistological examinations were performed with Bielschowsky–Ábrahám's method which, by slight adaptations, proved to be perfectly suitable for the demonstration of even the most delicate nerve endings. Also, the methods of Gros, Jabonero and Gros-Cauna were frequently employed.

Sinoatrial System

In the pig, cow and horse, the sinoatrial node (nodulus sinoauricularis Keith–Flack) is found at the orifice of the upper hollow vein, more precisely, on its medial side where it joins the right auricle (auricula dextra) at the topmost point of the right atrium. After removal of the epicardium, the node is distinguishable also macroscopically, differing from the surrounding muscles by its deeper grey hue. In the pig and horse it has an irregular semilunar shape, while in the cow it resembles an asymmetric "V". The node's middle part is crossed by a small vessel, visible also macroscopically. This is the artery supplying the sinoatrial node. It is a branch of the right coronary artery and its descent over the heart to the sinoatrial node may easily be followed, particularly in calves. These observations correlate well with the findings of Koch (1909) in man. He, too, established that the

artery supplying the sinoatrial node exited from the right coronary artery. Spalteholz (1924) noted that in certain animals this branch arose in the left coronary artery. The veins of the sinoatrial node were studied in detail by Géraudel (1928), who found that these veins opened into the right auricle through several delicate orifices. Consistent observations were made by us: in every case, we found two or three delicate holes between the sinoatrial node and the margin of the right auricle and regarded them as orifices of veins.

From the sinoatrial node exit rami containing stimulus-conducting fibres, going to the muscles of the right atrium. Mönckeberg (1924) described five such rami in man. These rami were found by us also in the three species of domestic animals used for this examination. The largest branch runs, like an elongate tail of the node, into the terminal sulcus and corresponds to the bundle of Wenkebach, described also by Schoeneberg. In the terminal crest (crista terminalis) region near the node, the branch protrudes in a nodular fashion, particularly in the pig. Later it runs beneath the endocardium and loops around the upper hollow vein. This protrusion is but infrequently apparent in the hearts of the horse and calf. Along its descent, several smaller rami go from the bundle to the atrial muscles. In the pig's heart, we detected also the bundle of Thorel, described by Mönckeberg, but could not follow it further than the vena cava inferior. Histologically, fibre bundles resembling those exiting from the sinoatrial node were seen also around the Aschoff–Tawara nodule. These bundles may have been continuities of the branch of Thorel. Similarly to Zimmermann, we, too, failed to identify this branch in the horse and calf, at least not in the form known in the pig. The other branches are smaller and carry stimulus-conducting fibres from the sinoatrial node to the parietal muscles, in the direction of the auricle, vena cava superior and atrial septum. In the calf, the stalks of the V-shaped sinoatrial node are connected with each other by very delicate stimulus-conducting fibre bundles. The sinoatrial nodes of the pig, horse and calf are structurally similar, differing only in delicacy.

Histology of the Sinoatrial System

The sinoatrial nodes of the pig, horse and calf are uniformly built up by the syncytia of closely attached stimulus-conducting fibres, crossing each other in all the three dimensions. The pig's sinoatrial node is so compact that it gives the impression of a uniform syncytium. The horse and calf have somewhat loose sinoatrial nodes wherein the stimulus-conducting fibres may be followed over a long distance, seem to be more independent, but in most cases the close syncytial connection between the fibres is apparent as well. The spaces left between the fibres are filled by connective tissue which here and there expands to form connective tissue islands between the syncytia of stimulus-conducting fibres. The node is surrounded by a tissue from the epicardium and is traversed here and there by smooth muscle bundles. In the pig this connective tissue is loose, while in the horse it is dense. In the latter, unlike the pig, some elastic fibres were also detected but never in masses. In the sinoatrial system fat cells were only occasionally seen.

In preparations stained with haematein–eosin or van Gieson's stain, the sinoatrial node is well distinguishable from the surrounding heart muscles, the former staining much more pale. A vivid carmine staining is achieved of the sinoatrial node and the corresponding stimulus-conducting system in preparations stained with Best's carmine. The surrounding tissues are paler as a result of their lower glycogen content. Preparations treated with PAS are particularly beautiful in that they show the stimulus-conducting system in a bright red colour caused by their high glycogen content. In such preparations the nuclei remain unstained, giving the impression of empty holes. In every case, stained preparations show clearly the descent of the nodal artery (artery of the sinoatrial node) supplying the sinoatrial system with capillaries. The sinoatrial node has a somewhat better blood supply than the surrounding heart muscle and contains a correspondingly higher number of capillary branches.

The diameter and length of stimulus-conducting fibres is hard to estimate owing to the sinoatrial node's compact structure. Information is somewhat more easily available in calves and horses both having looser nodes. In this species, fibres of smaller or larger diameter may be distinguished by their thickness/length ratios. The thinner type attains less than half of the diameter of mechanical heart muscle fibres. This type of fibre occurs frequently in the sinoatrial node of the horse, fairly often in that of the cow and only occasionally in the pig. The second, thicker type fibres are 2-fold or even $2^1/_2$-fold in diameter when compared to common muscle fibres. Essentially, the sinoatrial node is constituted by thick fibres continuing in a slightly swollen form also in the branches exiting from the node. The length of the stimulus-conducting fibres is 50–150 μ within the bundle; within the branches they may be even longer. The nuclei of stimulus-conducting fibres are swollen and blister-like, polymorphous and larger than those of the mechanical heart muscle fibres. In the pig they are often double. A pale halo is frequently observed around the large blister-like nuclei, causing displacement of the myofibrils and making the sarcoplasm visible. In the nuclei there are often one or two nucleoli, but in the pig sometimes even five of them were seen. Nuclei are not only larger than those of the mechanical fibres but also their number exceeds that found in ordinary heart muscle fibres. In the stimulus-conducting fibres no Eberth's lines are seen; only here and there is the fibres' straight body interrupted by some slight invagination. Around the invagination the fibres' margins are wrinkled. The fibres contain only some myofibrils located beneath the sarcolemma and forming there a loose network. In the middle of the fibres, only single myofibrils are occasionally seen. The myofibrils have an undulating descent and arrange in all the three dimensions of space, as shown clearly in preparations stained with Heidenhain's iron hematoxylin. Striation is less conspicuous and more confluent in myofibrils than in the ordinary heart muscle. In impregnated preparations obtained from the horse, striation appears more sharply on thinner than on thicker fibres. In the heart of the horse, the myofibrils vary in thickness. On thicker ones, striation is very sharp, whereas on thinner ones it is confluent. In this respect, preparations treated with PAS provide reliable information.

From the sinoatrial node exit parallel-running bundles of stimulus-conducting fibres. These bundles carry fibres to the upper vena cava, the auricle, the atrial wall and septum. The fibres carried by these bundles are thicker and foamier than those in the sinoatrial nodule. Their straight descent and sharper striation resembles those of the mechanical fibres, but their typical features are still recognizable. Their nuclei are large and blister-like, their cytoplasm stains pale, the myofibrils are loosely arranged and the Eberth's lines are invisible. These differences are obvious only in the fibres passing inside the trunks, while those exiting to the heart muscle fibres vanish gradually, rendering a further follow-up of the system impossible.

Innervation of the Sinoatrial Node

The sinoatrial node, and in general also the terminal crest (crista terminalis) and terminal sulcus (sulcus terminalis) are quite rich in nerve fibres. This was observed earlier by Keith and Flack. Their finding was confirmed by later investigators. Concerning the system's innervation, larger trunks containing fibres of varying diameters and in their surroundings smaller and larger ganglia are seen in a remarkably large number adjacent to the stimulus-conducting tissue in the epicardium and endocardium of the sinoatrial node and its immediate surroundings. In this region, Oppenheimer (1912) described ganglia in the ungulates, while in the cat Eversbusch (1915) observed scattered nerve cells. According to our own experience, the ganglia as a rule comprise multipolar nerve cells, some of which are quite small in comparison with those found in other portions of the stimulus-conducting system. In the pig and cow, many cells were found whose processes did not impregnate, thus only the rounded cell bodies and the chromatin-poor nuclei were seen in the preparations. The presence of such cells in the heart ganglia of sheep was described also by Lawrentiew. He also saw such cells beside the heart ganglia in other vegetative ganglia and named them micro-cells. In calves, micro-cells located in the perisinal ganglia were circumflected by varicose fibres. Over some of the micro-cells fibres terminating in spheres of varying sizes and presumably of vagal origin were apparent. These endings have been considered by us to be synapses.

In all the three animal species, the nerve trunks enter the sinal connective tissue after repeated branchings, ramify gradually over the stimulus-conducting fibres to form a loose network. This particular network was uniform in all the three species. Yet certain differences were encountered in the finer innervation. These differences are obvious in both the efferent and afferent nerve endings as well as in the structure of ganglia interconnected with the stimulus-conducting system.

The largest number of nerve fibres was found in the pig's sinoatrial system. From the trunks containing mixed fibres exit here and there some thicker, apparently vagal fibres accompanied by thinner sympathetic fibres. In the stimulus-conducting fibrous tissue surrounding the nerve trunks, the thick fibres branch off several times, and are attached closely to the sarcolemma of stimulus-conducting fibres;

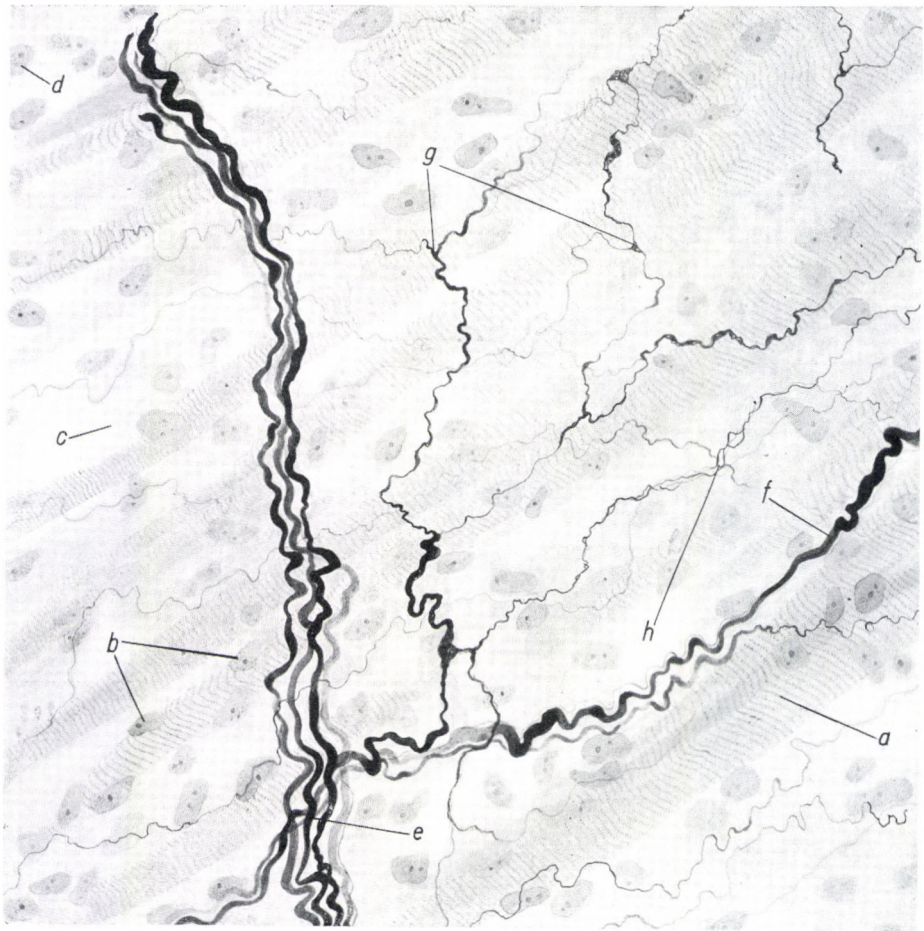

FIG. 65. *Sus scrofa domestica*. Nerve fibre plexus in the sinoatrial node. (a) Stimulus-conducting fibre; (b) nucleus of stimulus-conducting fibre; (c) connective tissue; (d) nucleus of the connective tissue cell; (e) nerve bundle; (f) thick nerve fibre; (g) branching; (h) nerve fibre plexus. Bielschowsky–Ábrahám's method. Microscopic magnification 600×, reduced photographically to ½

they surround these by forming a delicate plexus. The vagal origin of the thicker fibres is indicated by their structural features in that they are slightly varicose and show neurofibrillar structure in the appropriately impregnated areas. Along their descent these fibres branch off several times in triangular patterns and become gradually thinner. Certain branches of the nerve fibres yield terminal rami carrying delicate nodules on their preterminal portions. From these fibres exit short side branches ending in terminal spheres, somewhat larger in dimension than the varices. In preparations permitting the study of the main fibre's entire path, endings appear beneath the sarcolemma as end spheres or rings arisen from loops

of the fibres' terminal portions. Thinner fibres exiting from the trunk pass along the thicker ones for a while then branch off, terminating occasionally along the thick fibres. In other cases, they separate from the thick fibres and follow an independent passage or conjugate with the network of another fibre system and also end there. Here, too, they terminate in end spheres or end rings, sometimes epilemmally (Fig. 65). Innervation of the branches exiting from the sinoatrial node is essentially similar to that of the node. The stimulus-conducting fibres are, however, accompanied by the nerves over a longer distance. Endings are but infrequently seen.

In ungulates, Oppenheimer (1912) described a rich reticulum of nerves entirely surrounding the stimulus-conducting fibres. We are bound to disagree with this statement. In fact, the nerve supply of the stimulus-conducting fibres is very rich and many of them are entirely surrounded by nerve branches, yet there is no true nerve reticulum present, as the individual fibres fail to anastomose, remaining independent in every case. In terminal plexuses nerve endings are often seen.

In the sinoatrial system of the pig, beside efferent nerve fibres afferent ones are also frequently seen. The latter show particular end structures of which two typical forms are known. One type, found at the border of the myocardium, has been a new discovery not only in the pig's heart but also for the heart in general. A thick trunk, consisting predominantly of thick fibres, enters into the sinoatrial node. From this trunk exit eight to ten thick fibres on each side. These fibres ramify immediately adjacent to the trunk. Some of them return into the trunk, whereas the others either terminate in several small neurofibrillar end plates after having branched several times, or in one large neurofibrillar end plate, without branching. The shape and structure of the end plates is quite variable (Fig. 66, Plate I/c, p. 48). We believe that our discovery of these special nerve endings enables us to answer two important questions, one of them being raised from a morphological (a), the other from an experimental physiological (b) point of view. (a) The location of the vagal depressor fibres as well as the site of their endings have been a matter of dispute for several decades. The question was whether they pass down to the heart wall or all end in the aortic arch. Most authors were of the opinion that all aortic fibres terminate in the aortic wall, but the minority postulated that some of them also enter the heart. The sensory type end-apparatus detected by us supports the latter concept in that the broad plate-like endings of the thick fibres are obviously of a depressor character. (b) On the part of experimental physiology, Schaefer (1950) was the first to claim the presence of baroreceptors in the heart wall. Our findings confirm this supposition, indicating the presence in the heart of pressoreceptors, resp. interoreceptors of baroreceptor activity. The other type of sensory endings was found in the epicardial connective tissue, near to the sinoatrial node. That, too, is constituted by thick vagal fibres branching off several times and forming a dense arborized end system whose markedly narrowing end fibres terminate in delicate end rings.

Like the pig's sinoatrial system, also those of the horse and calf are innervated by a rich plexus circumflecting the loose, stimulus-conducting fibres arranging in all dimensions of space. The fibres, even the most delicate ones, descend smoothly,

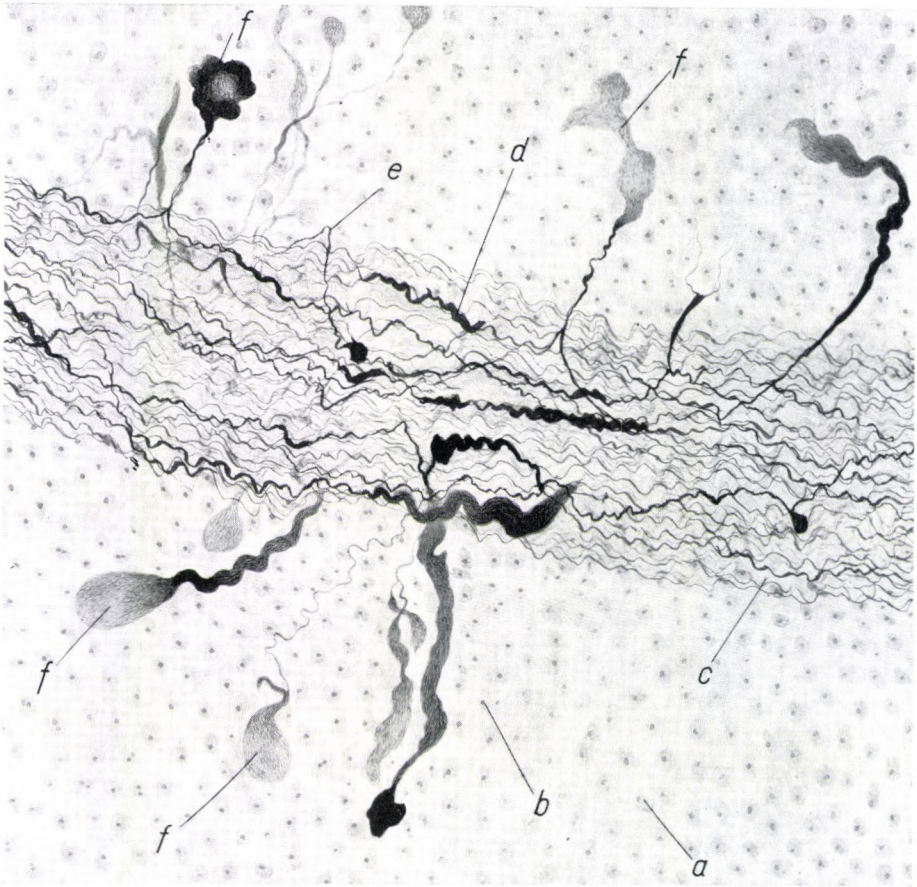

FIG. 66. *Sus scrofa domestica*. Sensory nerve end plates at the border of the sinoatrial node. (a) Nucleus of connective tissue cell; (b) nucleolus of a connective tissue cell; (c) nerve trunk; (d) thick nerve fibre; (e) thin nerve fibre; (f) nerve end plate. Bielschowsky–Ábrahám's method. Microscopic magnification 600×, reduced photographically to ½

finely varicose fibres being present only in the pericellular apparatuses of the adjacent ganglia. In the calf and horse, no nerve endings similar to those detected in the pig were seen on the stimulus-conducting fibres. Our preparations suggest that in the former two species, end connections are very likely constituted by the delicate, nearly submicroscopic plexus of nerve fibres seen particularly well in the sinoatrial system of the calf. So far no sensory endings have been detected in the calf and horse.

Atrioventricular System

The Aschoff—Tawara nodule (nodulus atrioventricularis Aschoff—Tawara) is located in the right atrium's lower part, ventrally from the entrance of the coronary sinus, caudally from the oval fossa and above the medial cuspis of the tricuspid valve. It is of elongate–ovoid shape, its width being equal with that of the His' bundle in the pig, whereas it is in every case broader in the horse and calf. It is separated from the endocardium by a thin muscular layer that connects also with the medial valve. It attaches closely to the anulus fibrosus in whose anterior corner (trigonum fibrosum dextrum) a roughly triangular cartilage is found in the horse and pig, and a bone of similar shape (os cordis) in the calf. It lies adjacent to the aorta. According to Holl, the connective tissue, bordering the Aschoff–Tawara nodule as processus tendineus aortae, also originates from this area. In the heart of the rat, guinea-pig and dog, Schinde and Ohmori (1928) described an accessory system associated closely with the Aschoff—Tawara nodule. In the domestic animals examined we failed to identify this system.

The bundle of His (fasciculus atrioventricularis His) exits from the Aschoff–Tawara nodule and runs towards the ventricular septum. The common stem (crus commune) of this bundle passes in the atrial part of the septum membranaceum cordis which provides it with a connective tissue sheath. Above the ventricular septum (septum ventriculorum) the bundle of His divides, at a sharp angle, into two branches known as the branches of Tawara (crus dextrum et sinistrum).

The right branch of Tawara (crus dextrum) assumes initially a subendocardial position, then goes to the myocardium and passes further intramuscularly in the ventricular septum. Reaching the septal papillary muscle it sends a weak branch to it, whereas the rest of the fibres pass further in the transverse muscle (musculus transversus). This constant muscle bundle, traversing the right ventricle's lumen, was already known by Leonardo da Vinci, thus Holl named it after him. Tandler (1913) called it trabecula septomarginalia, while after King (1937) it has been called also the moderator fascicle. The stimulus-conducting fibres passing inside this fascicle traverse the right ventricular lumen and go to the parietal papillary muscle. In man, Benninghoff described branchings and returning loops of the stimulus-conducting fibres carried by the fascicle. In the animal species examined by us, no such conditions were detectable. We found that at the base of the parietal papillary muscle the fascicle arborized, yielding rami which passed to the ventricular muscles along with the system of Purkinje fibres.

The left Tawara branch turns after its exit slightly downwards and runs closely to the heart cartilage (in the calf at the medial border of the os cordis) along the edge of the ventricular septum. It traverses the right posterior aortic valve (spatium intervalvulare Henlei) and goes to the left ventricular septum. The left branch is bordered against the aorta by the musculus subaorticus Jerisch, weakly developed in the pig, but quite large in the horse and calf. The left branch is broader and flatter than the right one and passes further immediately beneath the endocardium. In the calf it is visible under the endocardium owing to its greyish colour, whereas in the horse and pig it has the same colour as the heart muscle,

being thus inapparent. According to Ungar (1924), its path is easily followed up in iodine-treated material. At the middle of the ventricular septum the branch broadens and subdivides into three smaller rami. A weaker branch passes on in the ventricular septum, while the two stronger ones (fasciculus anterior and posterior) enter the left ventricular lumen from beneath the endocardium. During its passage to the left ventricular apex it gives rise to tendinous rami which then unite again. The latter were called by Benninghoff "pseudo-chordae tendineae". The system of interconnected tendinous branches is richest in the calf. In the horse, two muscular branches, resembling the septomarginal trabecula, extend into the left ventricle's lumen. In the pig, the branches attach closely to the endocardium, running along it to the apex of the left ventricle. At their ends they continue in Purkinje fibres and vanish among the ventricular muscles. In man, Koch (1922) described bundles returning from the site of branching of the left branch, and compared them to the trabecula septomarginalia. In the mammals examined by us, no such returning branches were detected.

According to the studies of Haas (1911), in man the artery supplying the atrioventricular system arises in the right coronary artery and goes from the posterior coronary sulcus as "ramus septi fibrosi" to the atrial septum, then enters the node richly branching. We, too, found that in the horse and pig the Aschoff–Tawara nodule, the His' bundles' crus commune part and right branch receive their blood supply mainly from the right coronary artery. It appeared, however, that in the calf, the right and left coronary arteries have an equal share in the blood supply of these areas. The stronger arterial branch passing along the left branch of His' bundle was, however, identified as a branch of the left coronary artery in all the three species. Nevertheless, consistently with Spalteholz (1924) we also wish to emphasize the great variability encountered in the vessel supply. As to the veins of the atrioventricular system, we agree with Géraudel's statement (1928) that these veins open into the right atrium through the Thebesian foramina. In the animal species examined by us, the veins were found to open into the right atrium near the lower margin of the upper hollow vein. Johnstone, Wakefield and Currey's (1923) studies on the finer vessel supply of the atrioventricular system of calves revealed a much poorer vascular system in this area than in the ordinary heart muscle. This was supported by the observation of Wearn and Zschiesche (1928) who described a vessel supply about half as rich in the atrioventricular system as in the heart muscle. We agree with the above authors as to the poorness of capillary supply, yet we did not see any notable difference in the general blood supply of the atrioventricular system and mechanical heart muscles.

Histology of the Atrioventricular System

The Aschoff–Tawara nodule is similar in architecture to the sinoatrial node. Essentially it is built up from the loose syncytium of stimulus-conducting fibres arranged in all dimensions of space. The interspaces of the fibres are filled by connective tissue, making appearance occasionally in large island-like masses among the stimulus-conducting fibres. Out of the three animal species examined

the Aschoff–Tawara nodule shows the densest structure in the pig. In the calf it consists of loosely arranged and in the horse, of very loosely arranged, stimulus-conducting fibres. Another typical feature of the calf's Aschoff–Tawara nodule is that it is divided by a fairly broad connective tissue membrane into a larger atrial nodule and a much smaller ventricular nodule. The nodules of the pig and calf are both constituted mainly by loose fibrous connective tissue but in the calf there are more elastic fibres. In the horse, the connective tissue continues in a lamellar, dense, fibrous tissue above the His' bundle. In the connective tissue the number of elastic fibres is considerably lower. In man, Renon and Géraudel (1913) found numerous elastic fibres in the Aschoff–Tawara nodule. In man, Bullard (1921) observed the presence of numerous fat cells, whereas we failed to detect them in the Aschoff–Tawara nodules even of fat animals.

As with the sinoatrial system, the atrioventricular system also comprises two kinds of fibres, viz. thick and thin ones. The diameters of thick and thin fibres exceed those of the ordinary heart muscle fibres by about 3 and $1^1/_2$ times, respectively. Benninghoff (1930) described similar thin and thick fibres in the atrioventricular system of man. He claimed that the Aschoff–Tawara nodule, His' bundle and the initial regions of the right and left Tawara branches consisted of thin fibres, whereas the endmost branches of the bundle of thick fibres. According to our own experience, the entire atrioventricular bundle is composed of thick Purkinje fibres right from the exit of His' bundle onwards.

In the atrioventricular and sinoatrial systems alike, the stimulus-conducting fibres appear paler in haematein–eosin or van Gieson's stain. With Best's carmine, they stain more vividly than the surrounding heart muscle fibres. When treated with PAS, they appear in a bright red colour, except for the nuclei and the neighbouring cytoplasm portion which both remain completely unstained (Fig. 67). In cattle, Koch distinguished an atrial and a ventricular part of the Aschoff–Tawara nodule on the basis of Best's staining. We agree with this differentiation yet claim to contradict the statement that the atrial nodule is more reticular in structure than the ventricular one and also stains better owing to its higher glycogen content. We found an identical reticulation in both nodules, the difference being that the atrial one contained somewhat thicker fibres than the ventricular one. Yet they stained homogeneously. Preparations stained with Heidenhain's iron hematoxylin are very conclusive as they show clearly the crossings of myofibrils arranged in all the three dimensions of space. The myofibrils are about uniform in thickness, except for those in the pig's Aschoff–Tawara nodule, where relatively thin as well as thick ones may be encountered. The striation of the myofibrils is so vague that it is perceived rather than seen in stained preparations. In impregnated preparations, however, it appears sometimes quite clearly in the Aschoff–Tawara nodules of the horse and calf. Nuclei are large, mostly ovoid or blister-like, often doubled. In the pig they may be quintuple, in the calf even octonary. The fibre systems, with one to eight nuclei per fibre, give very remarkable pictures. It is of interest that in some cells the nuclei are arranged in a row along the longitudinal axis, while in others, along the perpendicular axis of the fibre. Naturally, the nuclei may often form groups instead of rows. The numbers, arrangements and



FIG. 67. *Equus caballus*. Left branch of the His' bundle. PAS-stain. Glycogen in the stimulus-conducting fibres. (a) Connective tissue; (b) nucleus of connective tissue cell; (c) stimulus-conducting fibre; (d) nucleus of the stimulus-conducting fibre; (e) fat cell; (f) nucleus of the fat cell; (g) mechanical muscle fibre; (h) transverse striation; (i) glycogen. Microscopic magnification 120×, reduced photographically to ¾



FIG. 68. *Bos taurus*. Right branch of the His' bundle. Polynuclear stimulus-conducting fibres. (a) Stimulus-conducting fibre; (b) nucleus of stimulus-conducting fibre; (c) connective tissue; (d) nucleus of connective tissue cell; (e) myofibrils; (f) nerve bundle; (g) nerve fibre. Bielschowsky–Ábrahám's method. Microscopic magnification 160×, reduced photographically to ¾

mainly the particular groupings of the nuclei are suggestive of amitotic divisions occurring in certain, or at least not simultaneously in all nuclei. This accounts for the observation that the number of nuclei is in some stimulus-conducting fibres even, while in others odd (Fig. 68). Part of the nuclei are surrounded by a pale cytoplasmic halo. Such fibres were called cavernous fibres by Benninghoff. The sarcoplasm stains pale. At higher magnifications, it appears sometimes homogeneous and sometimes delicately granulated. The granules consist most probably of glycogen. Neither cell margins, nor Eberth's lines are seen. According to Schaefer, the cell syncytia are kept together by a colloidal cement rendered invisible by having a refraction equal to that of the cytoplasm. As shown by electron micrographs, the stimulus-conducting fibres consist of several elongate or sometimes polyhedric cells separated by thin membranes allowing for the passage of myofibrils, however.

Innervation of the Atrioventricular System

Like the sinoatrial node, the Aschoff–Tawara node also receives mixed fibres from massive nerve trunks. The masses of trunks present in the matrix of the processus tendineus aortae most probably originate from the aortic plexus. Beside the trunks, ganglia of varying sizes are also seen around the Aschoff–Tawara nodules of all the three species. Cells are in general larger in these ganglia than in those of the sinoatrial node and their morphology is more variable. Many multipolar forms are seen, but there are also bipolar ones. Many nerve cells have particular shapes in the ganglia, namely in those of the pig. Synapses appearing in the form of end rings or compact end bulbs on the surface of ganglial cells are not exceptional in the pig and calf. In the pig the nodule is innervated by thick and thin fibres exiting from the trunks and entering the nodule's connective tissue to form a superficial, loose plexus on the surface of stimulus-conducting fibres. The thick nerve fibres carry solid varices being here and there in contact with each other. Owing to repeated ramifications, the nerve fibres become gradually thinner. Bundles of thin fibres, comprising also some non-branching thick ones, attach closely to the stimulus-conducting fibres' sarcolemma. Here they form rich plexuses often entirely covering the fibre. The nerve fibre supply of the atrioventricular system is so rich in the pig that in certain regions the atrioventricular system seems to consist entirely of nerve fibres. When looking at such preparations, the observer cannot avoid wondering whether the myogenic theory is justified (Fig. 69).

Nerve fibres accompanying the stimulus-conducting fibres terminate by end rings or end bulbs on the stimulus-conducting fibres, apparently hypolemmally. It should be noted that nerve endings occur much less frequently on the stimulus-conducting fibres of the Aschoff–Tawara nodule than on the sinoatrial node.

A rich supply of sensory fibres is observable in the Aschoff–Tawara nodule's connective tissue border adjacent to the septum membranaceum cordis. The sensory fibres are quite thick, myelinated and after de-myelinization they branch off richly in the connective tissue. Thick rami are roughly, whereas the thin ones are delicately varicose. They terminate in end spheres along the vessels and on the connective tissue cells.

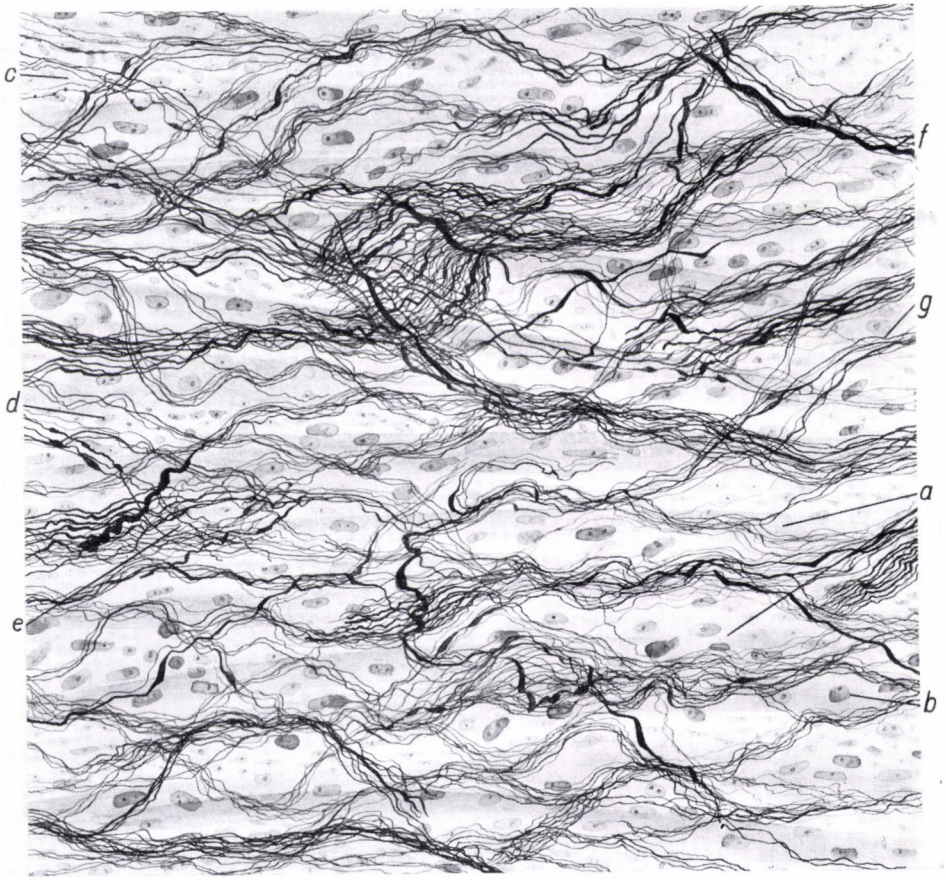

FIG. 69. *Sus scrofa domestica*. Aschoff–Tawara nodule. (a) Stimulus-conducting fibre; (b) nucleus of stimulus-conducting fibre; (c) connective tissue; (d) nucleus of connective tissue cell; (e) nerve fibre plexus; (f) thick nerve fibre; (g) thinnerve fibre. Bielschowsky–Ábrahám's method. Microscopic magnification 160×, reduced photographically to ½

The plexus supplying the Aschoff–Tawara nodules of the horse and calf is, as in the pig, constituted by thick and thin fibres. The stimulus-conducting fibres are entirely surrounded by nerve fibres exiting from the plexus in masses. In the horse, the terminal rami carry delicate varices. The markedly narrowed terminal fibres end freely, terminal structures being seen quite infrequently.

The innervation of the calf's Aschoff–Tawara nodule differs from that of the pig and horse. In the calf, the thick and thin fibres constituting the superficial loose plexus continue in a delicate end plexus whose parts may, on the basis of the available pictures, well be considered terminal structures. The latter were examined by us with special care as they bore a slight resemblance to the structures described as reticula by Seto (1936), Akkeringa (1949) and Meyling (1955). In the pig and

calf, this type of end structure is clearly visible both in the atrioventricular node and in the His' bundle, to be discussed later. With high-power immersion objectives, an exceptional richness of nerve fibres and plexuses is seen. Nevertheless, all fibres are independent, forming plexuses rather than reticula. In thick sections or poorly impregnated preparations, however, plexuses may be mistaken for reticula. Pictures seen in properly fixed and impregnated sections have never shown a convincingly reticular structure. All publications on the existence of a reticulum in this region appear to be erroneous and derive from misinterpretation of not quite satisfactory preparations (Seto, 1936; Meyling, 1955). The absence of a reticulum is evidenced by a number of adequately processed sections in our collection, one of them being demonstrated in Fig. 70 drawn from a high-power microscopic picture (Fig. 70). Naturally the mere presence of a terminal plexus *per se* does not clarify the morphological aspects of stimulus conduction. Irrespective of its richness and delicacy (Fig. 69), the plexus is definitely not an end structure. Our failure to detect nerve endings in the calf may be ascribed to the inadequacy of impregnation.

In the following account we discuss the innervation of the atrioventricular bundle whose common stem (crus commune) receives the richest nerve supply of all parts of the stimulus-conducting system. Microscopic preparations obtained from this structure show quite clearly the close relationship of the nerve system with the stimulus-conducting system. This again led us to question the validity of the myogenic theory which seems to be scarcely feasible in view of the extraordinarily rich nerve supply (Fig. 70).

The common stem of His' bundle receives nerve fibres partly from the Aschoff–Tawara nodule and partly from the surrounding rich endocardial plexus. In the pig, the plexus formed of thick and thin nerve fibres enters the bundle's connective tissue matrix, intertwines with the Purkinje fibres forming a rich superficial system of plexuses on their surfaces. In the superficial plexus the fibres ramify, become thinner and form a secondary plexus in which the thick fibres exhibit strong, the thin ones delicate varicosity. The thicker fibres have an undulating descent and the fibrils are well visible within them (Fig. 71).

The nerve plexus running in the common stem of His' bundle continues in its two branches, accompanying them in the form of two larger plexuses. Nerve pictures seen in specimens from the right and left Tawara branches correspond to those obtained from the common stem. Like the common stem, the two branches are also supplied by rich plexuses also showing nerve endings, some of them efferent and some afferent.

The efferent endings are smaller end rings or end spheres located epilemmally on the stimulus-conducting fibres while hypolemmally on the Purkinje fibres. Afferent endings appear to be scattered over the whole area of the atrioventricular system, being present in the superficial plexus as well as in the connective tissue adjacent to the bundle. The latter may appear in several forms. In some areas around the common stem end rings, end spheres of various types as well as other more or less irregular terminal structures are apparent, part of which are the connecting end structures of the thin fibres (Fig. 72).

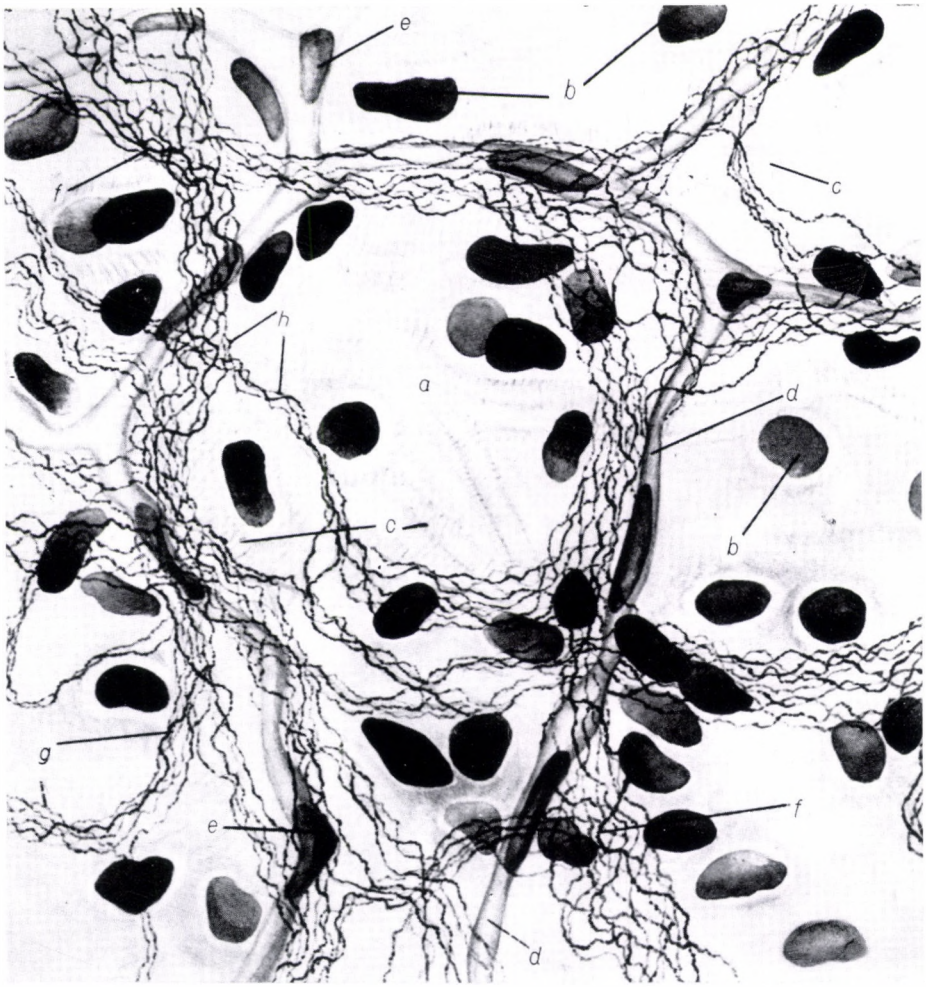

FIG. 70. *Bos taurus*. Heart; innervation of the Aschoff–Tawara nodule. (a) Stimulus-conducting fibre; (b) nucleus of the stimulus-conducting fibre; (c) transverse striation; (d) capillary vessel; (e) nucleus of endothelial cell; (f) nerve plexus; (g) nerve fibre; (h) varix. Bielschowsky–Ábrahám's method. Microscopic magnification 600×, reduced photographically to ½

In the connective tissue adjacent to His' bundle, afferent fibres are present in a smaller number passing in particularly rich plexuses constituted by very thick fibres terminating in bulky end bulbs. These types of sensory endings are found closely to the rich nerve fibre system running along the descent of His' bundle and as such belonging to the bundle's sensory system (Fig. 73). In the horse, the common stem of the atrioventricular bundle is characterized by the simultaneous presence of nuclear degeneration and regeneration processes. These phenomena are indicated by the presence of small granules, exhibiting great affinity to nuclear

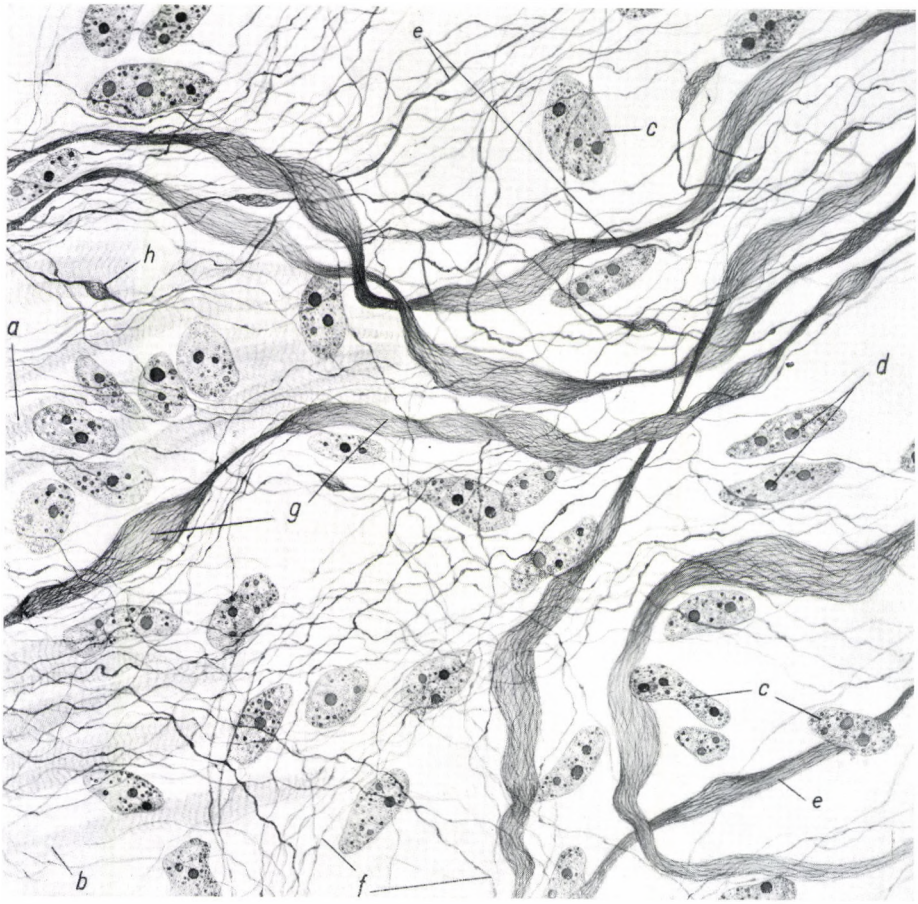

FIG. 71. *Sus scrofa domestica*. Nerve fibre plexus in the His' bundle. (a) Stimulus-conducting fibre; (b) transverse striation; (c) nucleus of connective tissue cell; (d) nucleolus of connective tissue cell; (e) thick nerve fibre; (f) thin nerve fibre; (g) neurofibril; (h) varix. Bielschowky-Ábrahám's method. Microscopic magnification 1350×, reduced photographically to ½

stains and silver impregnation, around the nuclei of the stimulus-conducting fibres. The fact that granules are sometimes seen over a larger area and sometimes only immediately adjacent to the nucleus indicates their migration from the nucleus through a discontinuity of the nuclear membrane. In the majority of cases also the deterioration of the nucleus is well visible at the site from where the granules started to migrate. The phenomena described above imply a continuous process of nuclear degeneration and regeneration in that the nuclear chromatin migrates gradually to the cytoplasm and the deteriorating nucleus thereby regains its chromatin constituent again. It may be assumed as well that the nuclei deteriorate

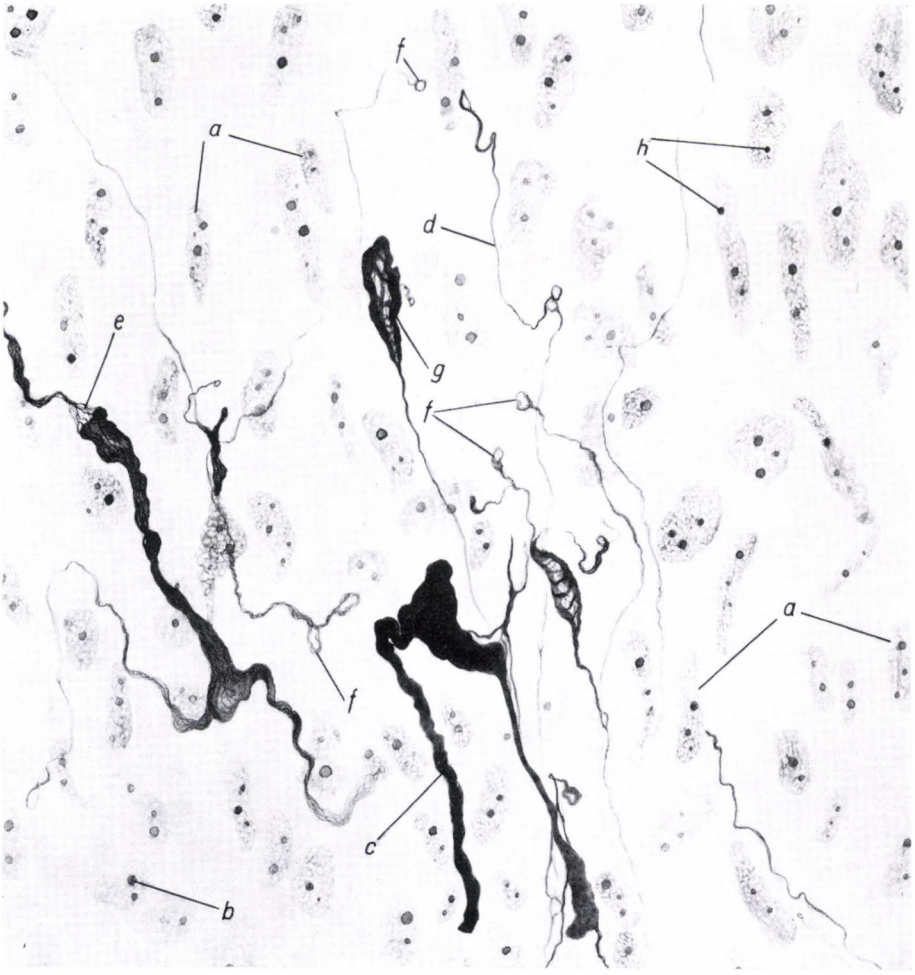

FIG. 72. *Sus scrofa domestica*. Nerve fibre plexus in the His' bundle. (a) Connective tissue cell; (b) nucleolus of the connective tissue cell; (c) thick nerve fibre; (d) thin nerve fibre; (e) neurofibril; (f) nerve ending. Bielschowsky–Ábrahám's method. Microscopic magnification 900×, reduced photographically to ½

completely and are subsequently newly formed. The available pictures, however, suggest that both nuclear degeneration and regeneration are incomplete processes.

The nerve endings seen in large masses in the common stem of the horse's atrioventricular bundle bear a striking resemblance to those found in the cytoplasm of the stimulus-conducting fibres. This is, however, not characteristic, implying only that either the material was more suitable for impregnation or that the method applied may have been, owing to some slight modification, more

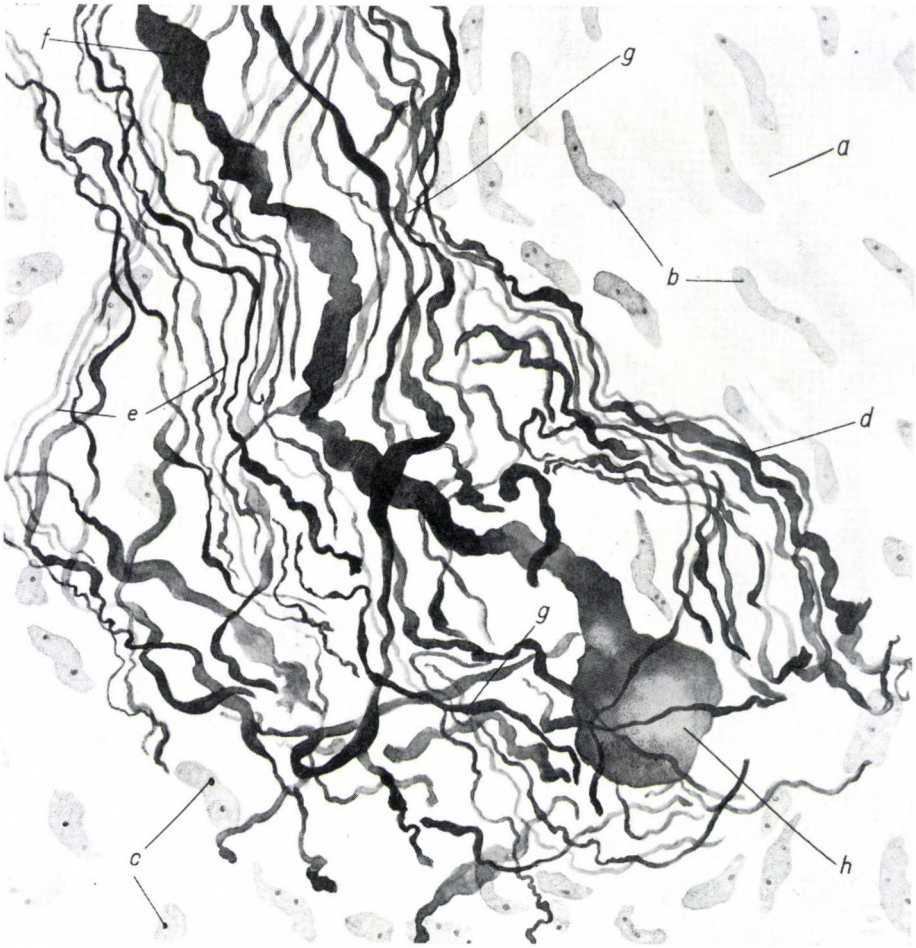

FIG. 73. *Sus scrofa domestica*. Sensory nerve end knob at the border of His' bundle. (a) Connective tissue bundle; (b) nucleus of connective tissue cell; (c) nucleolus of connective tissue cell; (d) thick nerve fibre; (e) thin nerve fibre; (f) varix; (g) nerve fibre plexus; (h) sensory end knob. Bielschowsky–Ábrahám's method. Microscopic magnification 900×, reduced photographically to ½

suitable for making endings visible. Anyway, after reaching the sarcolemma of the stimulus-conducting fibres, nerve fibres from the superficial plexus of His' bundle become markedly varicose, enter the sarcolemma and, after branching off several times, form end structures of variable shapes reaching frequently almost to the nucleus (Fig. 74).

In the right and left branch of the bundle no such nerve endings were seen. In the branches, the nerve fibres, carrying many delicate varices, are winding

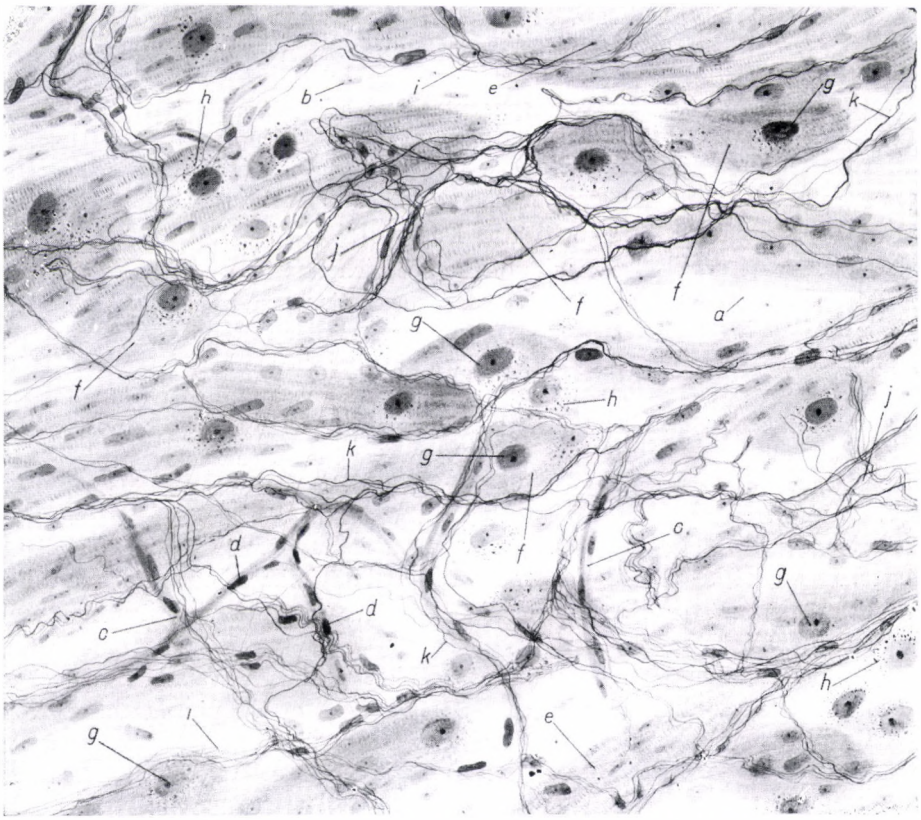

FIG. 74. *Equus caballus*. Nerve fibre plexus from the His' bundle. (a) Connective tissue cell; (b) nucleus of the connective tissue cell; (c) capillary; (d) nucleus of the endothelial cell; (e) ordinary cardiac muscle fibre; (f) impulse-conducting cardiac muscle fibre; (g) nucleus of the conducting cardiac muscle fibre; (h) chromatin granules; (i) nerve fibre bundle; (j) nerve fibre plexus; (k) nerve fibre. Bielschowsky–Ábrahám's method. Microscopic magnification 600×, reduced photographically to ½

spirally around the large blister-like Purkinje fibres. These structures remind us of those described by Engel and Morison in the left branch of the atrioventricular bundle of man, with the difference that these are no reticula but plexuses.

In the connective tissue along the bundle of His smaller ganglia are seen, while in the bundle itself scattered nerve cells occur. The latter are usually multipolar and show variable shapes dependent very likely on age. Various sensory endings characteristic of this area are present in the endocardium of the ventricular septum near to the myocardium along the right and left branches of His' bundle.

Localization of Acetylcholinesterase in the Stimulus-conducting System

Two completely contradictory concepts have been advanced during the past years on the histochemical behaviour of the stimulus-conducting system. Based on his examinations on rabbit, guinea-pig and calf, Schiebler (1953, 1955) denied the presence of acetylcholinesterase in the stimulus-conducting system. In contrast, and Mohr Gerebtzoff (1954), and also Dumont (1954, 1957), examining similar material, reported positive results of the acetylcholinesterase test. Dumont described the presence of an intensive positive reaction also in the Purkinje fibres of the dog's atrioventricular system, and sometimes also in the interfibrous areas. He stated that, at least in the dog, the Purkinje fibres inside both branches of His' bundle are covered by a sheath of marked acetylcholinesterase activity. Mohr and Gerebtzoff, and also Dumont, observed a special intensive cholinesterase activity also in the fibres of the nodal system. Concerning the nerve elements, all authors have agreed that the ganglia are definitely acetylcholinesterase positive. Opinions are, however, divergent in respect of the histochemical behaviour of the nerve fibres. Mohr and Gerebtzoff observed enzymatic activity in all postganglionic fibres. In one of his papers also Dumont hinted at similar observations and like Schiebler, he, too, described the cholinergic nerve fibres as the sites of acetylcholinesterase activity.

Having had a satisfactory amount of morphological data available, we decided to examine the cardiac stimulus-conducting system of the pig, horse, calf and buffalo for the localization of acetylcholinesterase activity.

Examinations were carried out by the method of Koelle and Friedenwald as modified by Gerebtzoff (1953) and Coupland and Holmes, respectively. Assays for specific cholinesterase were made in the Aschoff–Tawara nodule, stimulus-conducting fibres of the atrioventricular bundle, ganglial cells, nerve fibres and nerve end apparatuses. Specimens were fixed according to the prescriptions latest 20 minutes after exit. Incubation was made with acetylthiocholine-iodide substrate at pH 5 and pH 6·2 at 37°C. Good preparations were obtained 4–6 hr after treatment with ammoniumpolysulphide. Controls were run on the stellate ganglion, and the superior cervical ganglion as well as on portions of the sympathetic trunk, vagus nerve and ganglion nodosum vagi. The reaction was stopped by the addition of prostigmine to the incubation mixture.

Sinoatrial Node

The stimulus-conducting fibres of the sinoatrial node showed a pronounced acetylcholinesterase reaction in all animal species examined. The dark brown hue appearing at the margins of the thicker, or over the whole, surface of the thinner stimulus-conducting fibres bordered the sinoatrial system sharply against the pale myocardial muscles. The dark brown reticular mass formed by the fibres is particularly well visible in the pig, even at a low magnification. In the interspaces of the fibres the reaction was not entirely negative either, producing a homogeneous



FIG. 75. *Bos taurus*. Positive acetylcholinesterase reaction on nerve cells, on cholinergic nerve fibres and in the region of the sinoatrial node. Coupland–Holmes' method. (a) Nerve cell; (b) nerve trunk; (c) nerve fibre. Section thickness 20 μ. Substrate: acetylthiocholine-iodide; pH 5; incubation 6 hr. Magnification 80×

lighter yellowish colour. Comparison of these preparations with the corresponding morphological ones raises two question: (a) is the specific cholinesterase activity of the stimulus-conducting fibres localized to the sarcolemma, the sarcoplasm or the myofibrils or to all of them? (b) whether the extraordinarily dense systems of end plexuses seen in impregnated preparations from the sinoatrial node, and also from the stimulus-conducting fibres of the pig and calf, may be identified by the cholinesterase reaction and if they may, what forms the nerve end connections would take?

(a) The thicker stimulus-conducting fibres exiting from the node show an intensive cholinesterase activity rather at their margins, the enclosed cytoplasm being only of a paler yellowish colour. This implies that the bulk of specific cholinesterase is localized in the sarcolemma. Naturally, some of it may be present also in the cytoplasm. Myofibrils remaining invisible, in every case were regarded acetylcholinesterase as negative.

(b) The second question presents a more intricate problem. In general, most acetylcholinesterase-positive nerve trunks are found immediately beneath the epicardium where ganglia of varying sizes are also located, presenting strongly positive reaction (Fig. 75). According to the general experience, only a few cholin-

ergic nerves are present in the sinoatrial system. As shown by the reaction, they occur either in the form of smaller trunks among the stimulus-conducting fibres or along the vessels and in the connective tissue between the stimulus-conducting fibres. From the cholinergic trunks thin fibres are seen to go to the stimulus-conducting fibres (mainly in the calf but sometimes also in the pig and horse) where they can be followed for only a very short distance owing to the latter's marked activity. Hence there is no evidence concerning the share of cholinergic efferent end apparatuses in the reaction observed in the stimulus-conducting fibres themselves. Thus this type of histochemical examination failed to yield definite conclusions on the nature of nerve endings in the animal species examined.

Aschoff–Tawara Nodule

The specific acetylcholinesterase activity of the Aschoff–Tawara nodule corresponds roughly to that exhibited by the sinoatrial node, being, however, somewhat less in intensity. In comparison with the latter, larger masses of cholinergic nerves are present, appearing in the form of very thick trunks mainly at the orifice of the aorta. From the large trunks exit smaller ones, which again subdivide into single fibres and constitute a plexus. The ganglia located along the larger nerve trunks beneath the aorta's orifice also gave strong positive reactions. Acetylcholinesterase activity in the ganglial cells obviously involves the entire neuroplasm, pale spots being seen only at the sites of the nuclei.

Identification of the vagal part within the heart ganglia presents a further problem. We failed to clarify this on a morphological basis as no vagus-type nerve cells were demonstrable. Around the Aschoff–Tawara nodule, however, our attention was attracted by some morphologically peculiar nerve cells, which structurally resemble the sympathetic cells of type Dogiel I. We believed them to belong to the parasympathetic system but were in no position to confirm this assumption morphologically. Our recent histochemical studies, however, allowed a closer approach to the problem. Some scattered cells with definitely cholinergic processes are apparent in nearly all ganglia of the pig and several in the sinoatrial ganglia of the calf. To provide an adequate basis for the interpretation of this phenomenon, the stellate ganglion, superior cervical ganglion and ganglion nodosum vagi were examined as controls. In ganglion nodosum vagi there was a special cholinesterase activity in the cells' processes, while in the stellate and superior cervical ganglia only the cell body was found to be active. Thus we concluded that in the pig the cholinergic processes are postganglionic parasympathetic fibres, and we suppose these cells to belong to the vagal system. The synapses demonstrated in the ganglia by morphological methods could not be verified convincingly by enzyme assay.

His' Bundle

In the nodal elements of the stimulus-conducting system, definitely positive acetylcholinesterase reaction was demonstrable in the stimulus-conducting fibres. This correlates well with the findings of Dumont, Mohr and Gerebtzoff. This is not

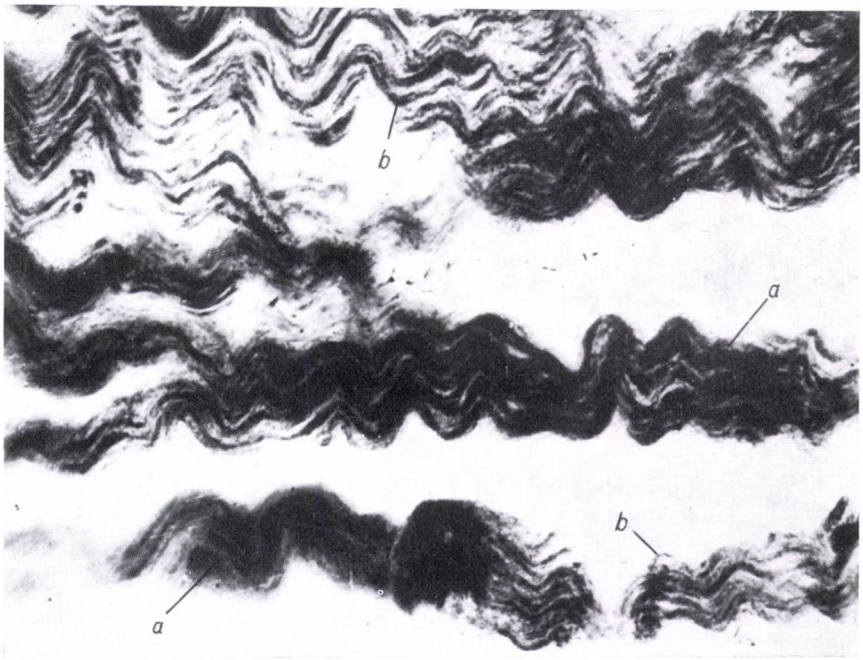

FIG. 76. *Sus scrofa domestica.* Positive acetylcholinesterase reaction in the cholinergic nerve trunk of the atrioventricular bundle. Coupland–Holmes' method. (a) Nerve trunk; (b) nerve fibre. Section thickness 40 μ. Substrate: acetylthiocholine-iodide; pH 6·2; incubation 4 hr. Magnification 225×

the case with the reactions of the Purkinje fibres. Fibres giving strong positive and entirely negative reactions were found adjacent to each other in the left and right Tawara branches. Thus in this respect we are bound to support the concept of Schiebler. We must admit, though, that in the crus commune of a pig we, too, have observed a certain homogeneous activity which, with a lesser intensity, was sometimes found in the branches as well. Since, however, this phenomenon was observed in only some sections obtained from a single animal, it was considered a methodical failure. The known lability of the ammoniumpolysulphide solution, the time of its storage and the mode of 0·1 M $CuSo_4$ addition may result in aberrant reactions, unless prevented.

The rich nerve supply of the atrioventricular bundle (crus commune) is demonstrable also histochemically. In preparations treated with the method of Coupland and Holmes, large masses of cholinergic nerves, carrying scattered nerve cells and smaller ganglia, are apparent inside as well as outside the bundle. Sometimes colour reactions are as intensive as if the preparation were impregnated (Fig. 76).

The negative reaction of the tissue itself allows a closer histochemical study of the interconnections between the intracardial nerve system and the stimulus-conducting fibres. For this purpose, specimens from the buffalo proved to be the

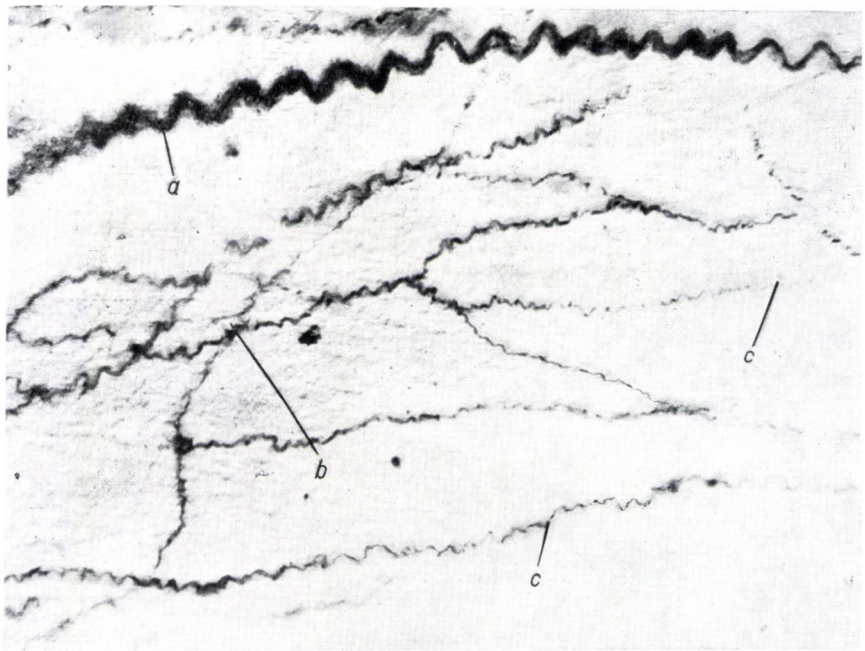

FIG. 77. *Bos bulbalus*. Enzymic activity in the nerve plexus near the left branch of the atrioventricular bundle. Coupland–Holmes' method. (a) Nerve bundle; (b) nerve plexus; (c) nerve fibres. Section thickness 40 μ. Substrate: acetylthiocholine-iodide; pH 5; incubation 7 hr. Magnification 225×

most favourable test materials, yet essentially the phenomenon can be pursued also with other species. In all probability, the advantages of the applied method can be best utilized with the buffalo, owing to the greater cholinesterase activity in its cardiac stimulus-conducting system. The pictures reveal definitely nerve-like patterns so it would be erroneous to conclude that the end connections of the intracardial nervous system were reticula. This is clearly visible in Fig. 77, showing the histochemical picture of the buffalo's His' bundle. Nerve branches exiting from the thicker cholinergic trunks are seen to surround with a delicate system of plexuses the pale areas corresponding to Purkinje fibres. Frequently some of the fibre bundles or individual fibres give a stronger reaction. It is not quite clear whether this reflects a methodical peculiarity or an actual functional state of the nerve involved. Owing to the intensity and homogeneity of the reaction it is not quite clear either whether the enzyme is localized in the fibres' neurilemma or in its axon or in both.

Efferent endings present here and there in the stimulus-conducting system in the form of end rings or end spheres, were not demonstrable by the method of Coupland and Holmes, the minute precipitate formed in this reaction being most probably below the light microscope's resolution. End fibres, however, were occasionally quite well visible.

No enzyme activity was demonstrable in the interoceptors present in large numbers over the entire area of the pig's stimulus-conducting system (Ábrahám and Erdélyi, 1957). This is the more surprising as Ábrahám (1956), using the method modified by Gerebtzoff, demonstrated the presence of specific cholinesterase in the receptors of the pig's aortic arch. This suggests that further studies may reveal enzyme activity also in intracardial receptors. This is the more feasible as Holmes (1957) has already found a pseudo-cholinesterase activity in the receptors located at the origin of the pulmonary as well as of the superior vena cava.

NERVE ENDINGS IN THE MYOCARDIUM

Nerve endings in the myocardium have presented a difficult problem, whose clarification may nevertheless be attempted, even with the hardly perfect methods available. The relevant literary data are controversial. Earlier investigators (Demoor and Heymans, 1895; Smirnow, 1900; Michailow, 1908; De Witt, 1909; Sato, 1920; Hoshi, 1926; Jones, 1927; Lawrentiew, 1929; Okada, 1921, and others) stated that the nerve fibres end freely. Others, however, as Hofmann (1902), Fukutake (1925), etc., stated the opposite, noting that nerve fibres do not end individually on the muscle fibres but conjugate with them collectively, in the form of a delicate end plexus or terminal plexus.

According to the origin of the heart nerves, Boeke (1933) distinguished between two forms of nerve end structures in the myocardium, viz. free endings and basal plexuses. In the first group he classified the intracytoplasmic endings, viz. end bulbs which in his opinion were of vagal origin, whereas in the second group he placed the delicate plexuses constituted by the end fibres of the sympathetic nerves.

In his study on the innervation of the human heart, Seto (1936) consistently failed to identify end bulbs in any of the several thousand preparations examined. In his view, the end bulbs of Boeke were cross sections of thick fibres. This concept was rendered quite feasible by the relatively high incidence of thick fibres in the myocardium. Seto stated and also testified by drawings that there were no free nerve endings on the myocardial muscle fibres, the end connection between them being constituted—like between the smooth muscle cells and the nerve system—by Reiser–Stöhr's terminal reticulum.

The author of this volume has devoted more than 25 years to the study of the morphological connections of the muscle tissue and nerve system and the nerve endings in the myocardium. Yet none of the several methods applied yielded evidence for the presence of a terminal reticulum in the myocardium. In every case, a delicate, almost neurofibril-like plexus was seen to attach to the muscle fibres, whose single nerve fibres ended freely inside the striated muscle fibres. I have, however, always emphasized the scarcity in mammals of ring- or sphere-shaped nerve endings, noting that even uni- or bilateral vagus section will not increase their incidence remarkably. End rings are still less frequently seen in the human myocardium. It is, however, quite certain that even there the end connection is not a terminal reticulum but a plexus, definitely lacking any kind of anastomosis.

Discussion of the myocardial nerve endings should include those in the mechanical as well as in the stimulus-conducting muscle fibres. As already mentioned in the foregoing text, nerve endings in the stimulus-conducting fibres are more readily observed than those in the mechanical muscle fibres. In pictures of the sinoatrial node as well as of the crus commune of His' bundle, particularly in certain mammalian species (pig, horse), it is clearly seen that nerve fibres enter the muscle fibres and terminate freely therein. Occasionally, nerve fibres entering the stimulus-conducting fibres are even seen to ramify and pass further therein over varying distances.

3. RECEPTORS OF THE HEART

SENSORY endings in the heart have been described by numerous authors. Hachiro Seto has reported various sensory endings in the atrial endocardium. One of them was essentially a dendritic branching of a thick fibre. The rami yielded by this branching become narrower and continue in a delicate plexus, some of whose end fibres terminate in neurofibrillar end plates. Structurally these end plates resemble the terminal patterns of the aortic nerve. The second ending described by Seto was a broad loose coil, also located in the atrial endocardium beneath the endothelium. The third end structure was seen in the atrial myocardium. It was essentially a nerve plexus formed by a thick fibre around a small vein. Further, two nerve end structures were found by Hachiro Seto in the stimulus-conducting system. They were spiral structures, each formed by the branching of a thick fibre arranged around the muscle fibres similarly to the end spindles.

We, too, found numerous receptors in the hearts of mammals but they did not correspond to the forms described by Seto, and partly not even to those reported by other authors for different animal hearts. Since the individual end structures are typical for the single layers of the heart we describe them below in this context.

EPICARDIAL RECEPTORS

The rich nerve supply of the epicardium and mainly the high incidence of thick fibres in the nerve plexuses have been *ab ovo* suggestive of the presence of rich sensory systems. Yet examinations had consistently failed irrespective of whether the end structures were looked for in membranes or sections. The plexuses had been well visible but only infrequently did we succeed in impregnating terminal structures. Delicate, sometimes elongate end rings were first seen only in the epicardial plexuses of sheep. The true sensory endings became apparent only when left or right or bilateral vagus sections were regularly performed. After vagotomy, enormous sensory systems became apparent both in the epicardium and endocardium, particularly in the cat. As, for impregnation, *in toto* preparations were prepared from specimens of epicardium, they showed not only the end structures and the associated end fibres but also the nerve trunks and the various rami exiting therefrom. Structurally the end apparatuses were rich arborizations whose terminal fibres passed across each other and ended separately in well visible end rings, as shown in the cat heart preparation presented in Fig. 78.

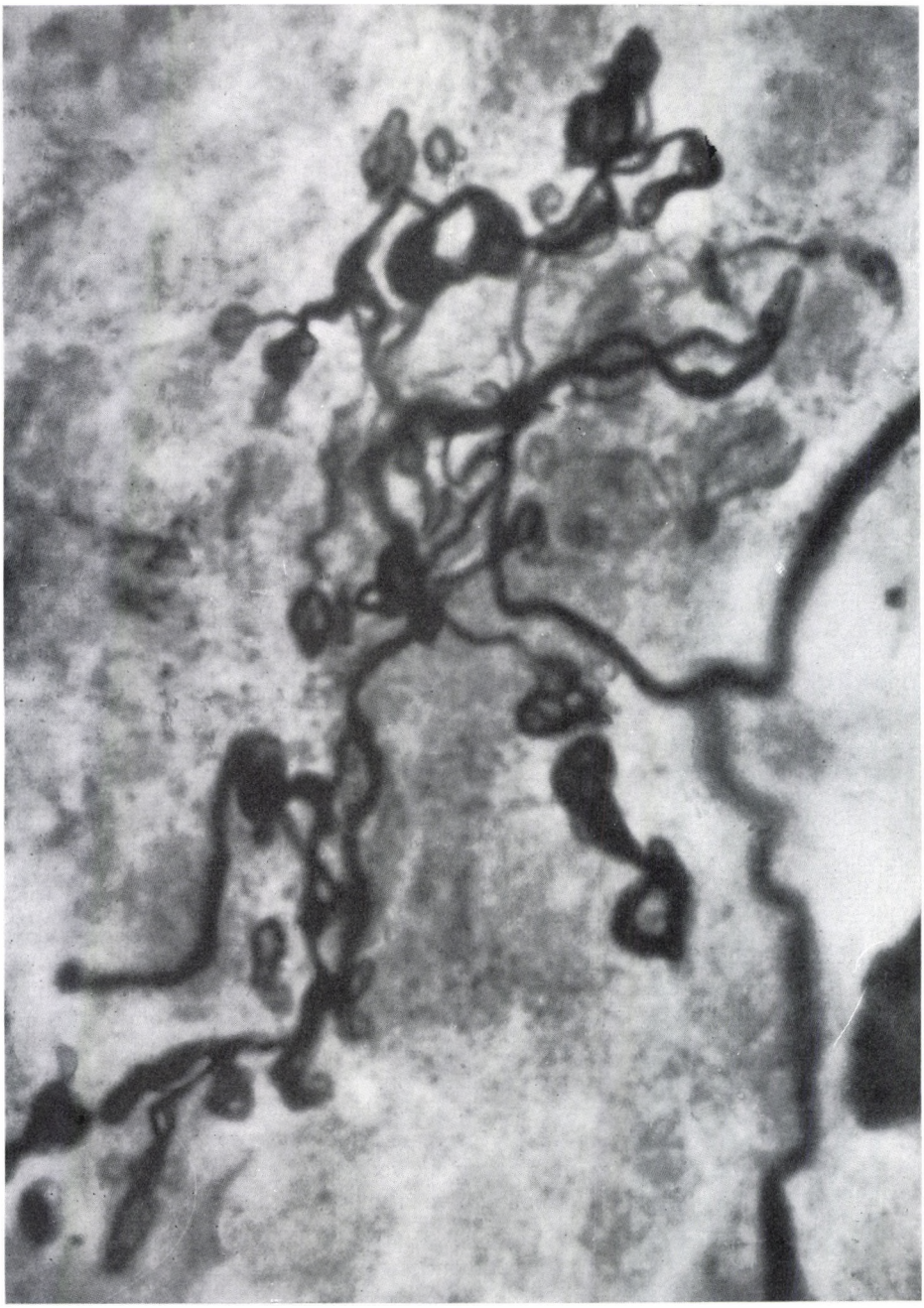

FIG. 78. *Felis domestica.* Receptor from the plexus epicardialis of the right ventricle. Jabonero's method. Microphotography

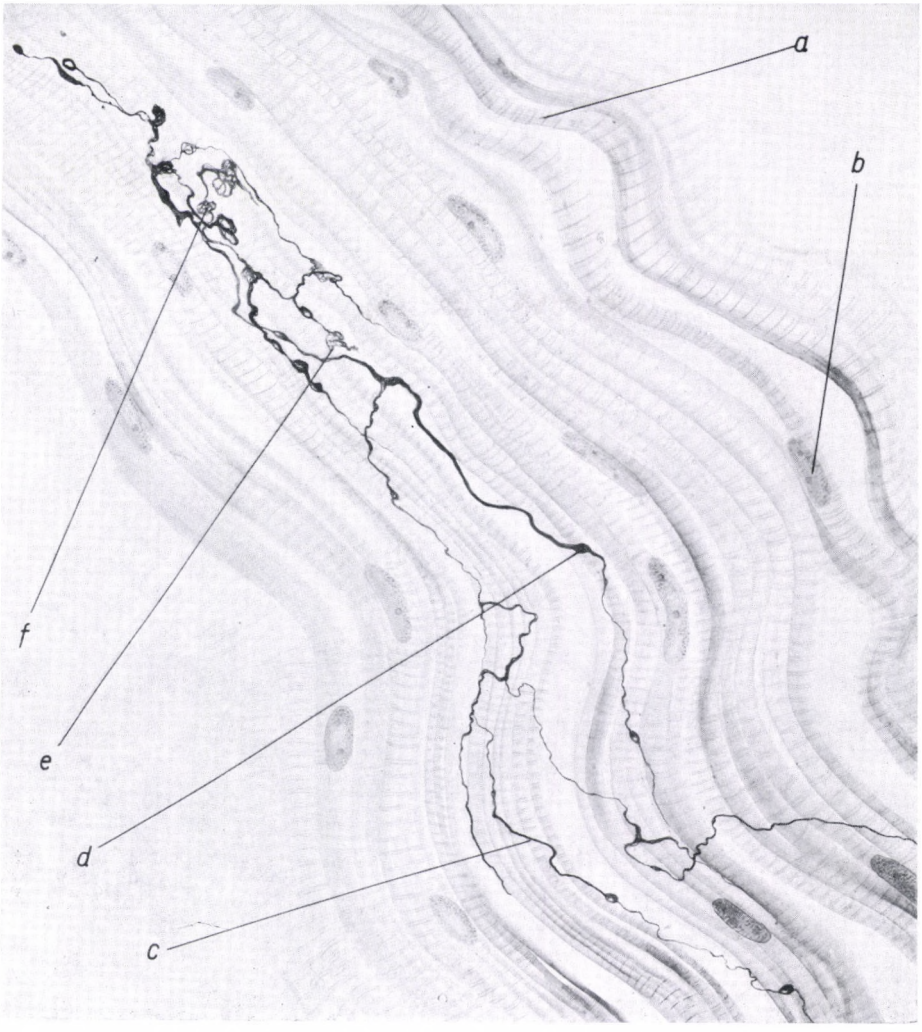

FIG. 79. *Felis domestica*. Sensory nerve end system in the right atrial myocardium. (a) Striated muscle fibre; (b) nucleus of striated muscle fibre; (c) nerve fibre; (d) varix; (e) nerve ending; (f) neurofibril. Bielschowsky–Ábrahám's method. Microscopic magnification 800×, reduced photographically to ½

MYOCARDIAL RECEPTORS

In general, receptors occur in a much lesser number in the myocardium than in the epicardium. We found myocardial receptors only in the cat and even there only in two areas, viz. in the right atrial wall and in the atrial septum. One type of ending is located right on the mechanical striated muscle fibres, being essentially a system of neurofibrillar end plates arising from the dendritic branching of a single

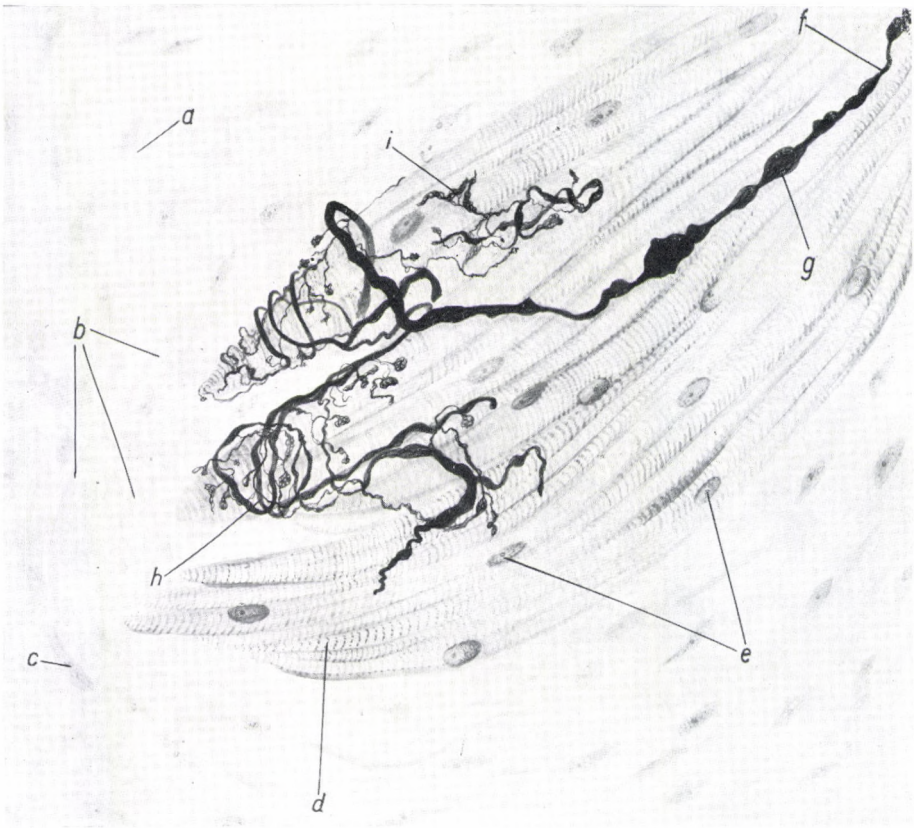

FIG. 80. *Felis domestica.* Atrial septum, nerve end organ in the myocardium, 72 hr after bilateral vagotomy (left vagus cut 24 hr after right vagus section). (a) Connective tissue; (b) connective tissue fibre; (c) nucleus of the connective tissue cell; (d) striated muscle fibre; (e) nucleus of the striated muscle fibre; (f) nerve fibre; (g) varix; (h) nerve end plexus; (i) neurofibrillar end plate. Jabonero's method. Microscopic magnification 600×, reduced photographically to ½

thick varicose fibre. The end plates are of variable shapes and dimensions. Consistently with Chabarowa, we, too, found this end structure in the right atrial wall, at the orifices of the large venae cavae (Fig. 79).

The other type of end structure was found in the myocardium of the cat's atrial septum. This formed a more complicated system but was also constituted by the rich terminal branching of a single thick fibre. The rami yielded by branching of the main fibre branched off again, and the secondary rami thus formed wound spirally around the striated muscle fibres. The spirals continued in delicate terminal rami, ending in neurofibrillar end plates on the striated muscle fibres. This end structure, found in the cat also by Chabarowa, resembles the end muscular spindle or rather its sensory part. Evidently, both end structures described above are proprioceptors of the myocardium (Fig. 80).

ENDOCARDIAL RECEPTORS

The endocardium is particularly rich in receptors. Numerous and various nerve end structures are present in the right atrial wall, namely in the area where the orifice of the large veins continues in the heart wall. As a matter of fact, the other parts of the endocardium are not lacking end structures either. Naturally this applies mainly to animal species which have been available easily enough for experimental purposes. We may state that in these species the conditions of innervation are well known. This does not apply to mammals of large dimensions, nor to those less easily available for experiment. Nevertheless, we succeeded in demonstrating even in the latter certain important receptor apparatuses a knowledge of which seems to be essential for the interpretation of heart reflexes.

Below we give detailed descriptions of all kinds of nerve end structures found in the endocardia of the mammalian species examined by us. The data are presented in a systematic sequence.

Dog *(Canis familiaris)*

In the dog, near to the orifice of the upper vena cava or rather in the area where the latter's media is already constituted by myocardial muscle, coil-like structures were found. Two types of these structures may be distinguished. One of them is actually a homogeneous, loose, coil-like ending of a thick myelinated fibre. The other, too, is coil-like but richer and more complicated in structure. Both of them are located in the endocardial connective tissue, very closely to the endothelium.

In the left atrial endocardium of the dog, not infrequently much more complicated end structures are also present resembling the particularly rich nerve endings seen in the wall of the carotid sinus of the dog and also of other mammals. This is essentially an easily surveyed system of branches exiting from a single conspicuously thick and sharply fibrillated fibre. The thick fibre branches off several times. Rami exiting from the main branch are fibrillated and gradually branch off themselves. The branches run a winding path and divide into delicate terminal rami which continue in roughly circular and sharply fibrillated end plates. In the end plates and generally also in the total terminal structure, the independency and sharpness of the individual rami as well as the independency of neurofibrils are particularly conspicuous (Fig. 81).

Fox *(Vulpes vulpes)*

In the left atrial endocardium of the fox's heart so far two forms of sensory-type endings have been detected by impregnation. One of them is more extensive but still well distinguishable, being actually the rich and fairly dense end structure of a thick fibre. The thick main fibre which here and there runs an undulating path and shows an over-all fibrillation, divides into two branches. These rami, too, are



FIG. 81. *Canis familiaris.* Heart; nerve end organ in the left atrial endocardium. (a) Main branch; (b) lateral branches; (c) neurofibrils; (d) end branch; (e) neurofibrillar end plate; (f) end ring. Jabonero's method. Microscopic magnification 800×, reduced photographically to $^{2}/_{5}$

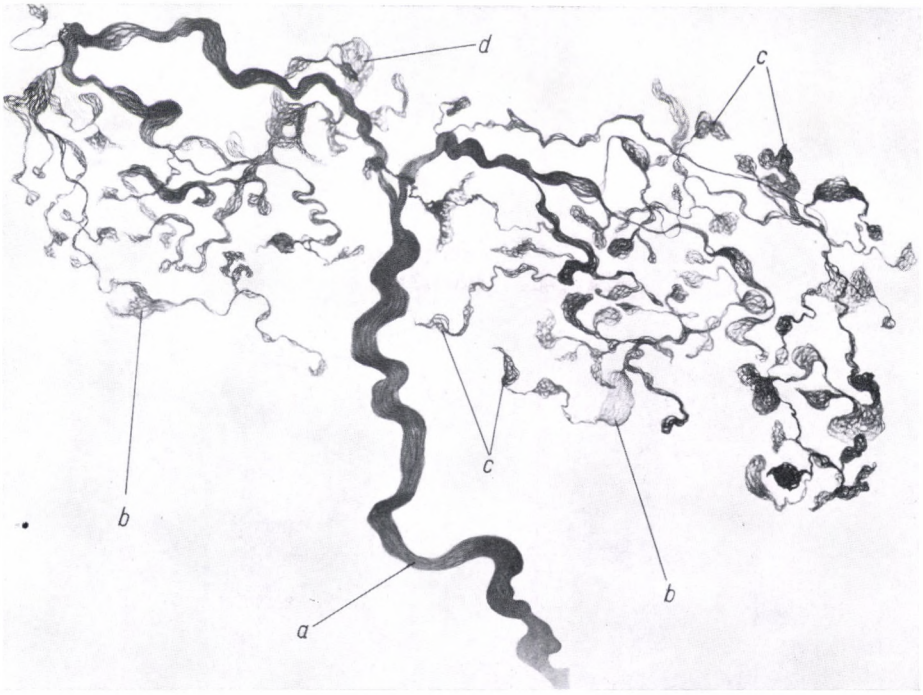

FIG. 82. *Canis vulpes*. Sensory nerve end organ in the left atrial endocardium. (a) Nerve fibre; (b) neurofibrillar intermediary plate; (c) neurofibrillar end plate; (d) neurofibril. Bielschowsky–Ábrahám's method. Microscopic magnification 800×, reduced photographically to ½

undulating, varicose and fibrillated. The side branches subdivide into many delicate terminal rami which are still more sharply fibrillated and continue gradually in neurofibrillar end plates. The end plates are varying in shape, sometimes roundish, sometimes elongate, elliptic or angular, here and there fimbriated. In every case, the neurofibrils are clearly visible (Fig. 82).

The other nerve end structure found in the left atrial endocardium of the fox is elongate in shape. Essentially it is a thick myelinated fibre branching off and being surrounded by a thick plexus of nerves almost along its entire length. The main fibre giving rise to the rich end structure is covered by a thick myeline sheath seen to reach up to the site of branching. The thick fibre divides into two rami. One of them branches off repeatedly, while the other returns and arborizes along the main branch sending delicate terminal branches to surround the former along its entire length. In the end structures of both large rami neurofibrils, neurofibrillar intermediary and end plates are well visible. The whole system is extraordinarily rich and differs profoundly from the other one. The dissimilarity of the two kinds of end structures suggests their belonging to two different nerve fibre systems. It seems to be likely that one of them belongs to the system of the vagus, whereas the other to that of spinal ganglia (Fig. 83).

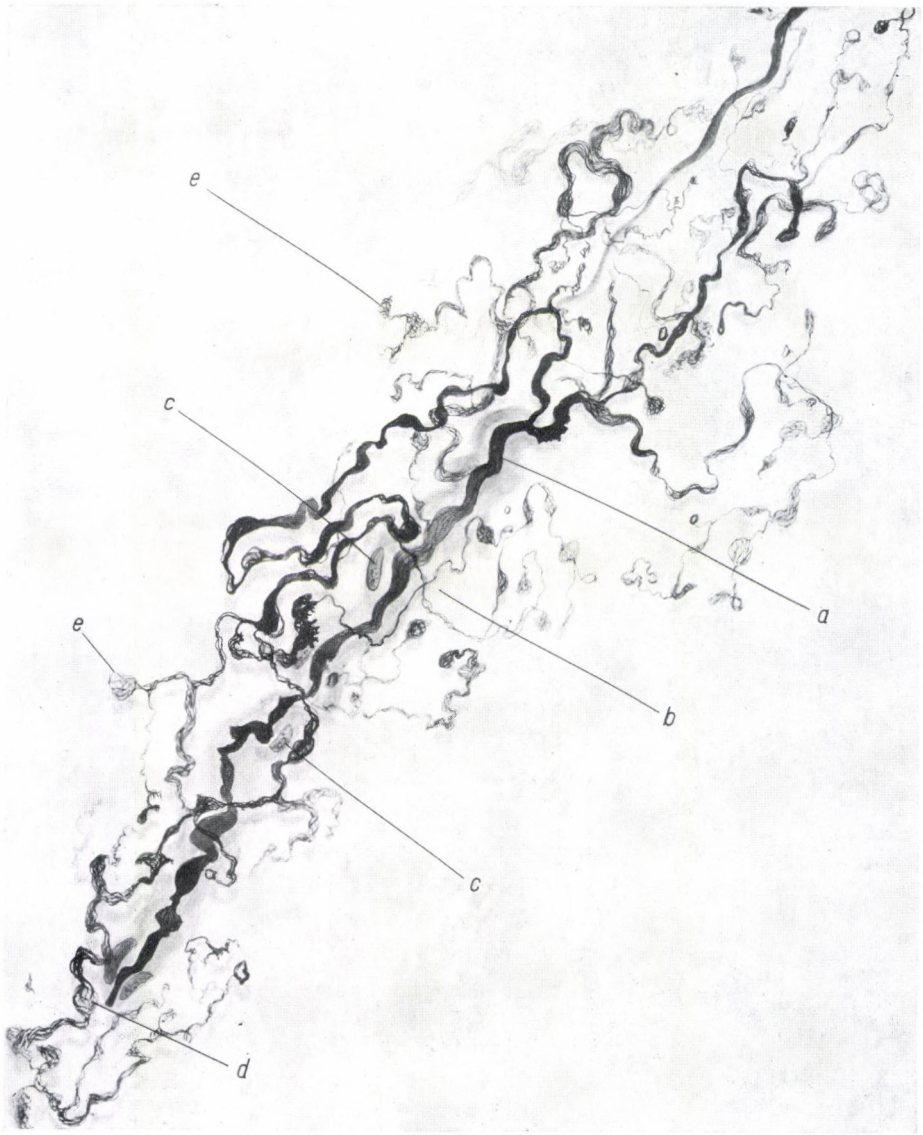

FIG. 83. *Canis vulpes*. Sensory nerve end organ in the left atrial endocardium. (a) Axon; (b) myelin sheath; (c) nucleus of the neurilemma; (d) neurofibrillar intermediary plate; (e) neurofibrillar end plate. Bielschowsky–Ábrahám's method. Microscopic magnification 400×, reduced photographically to ½

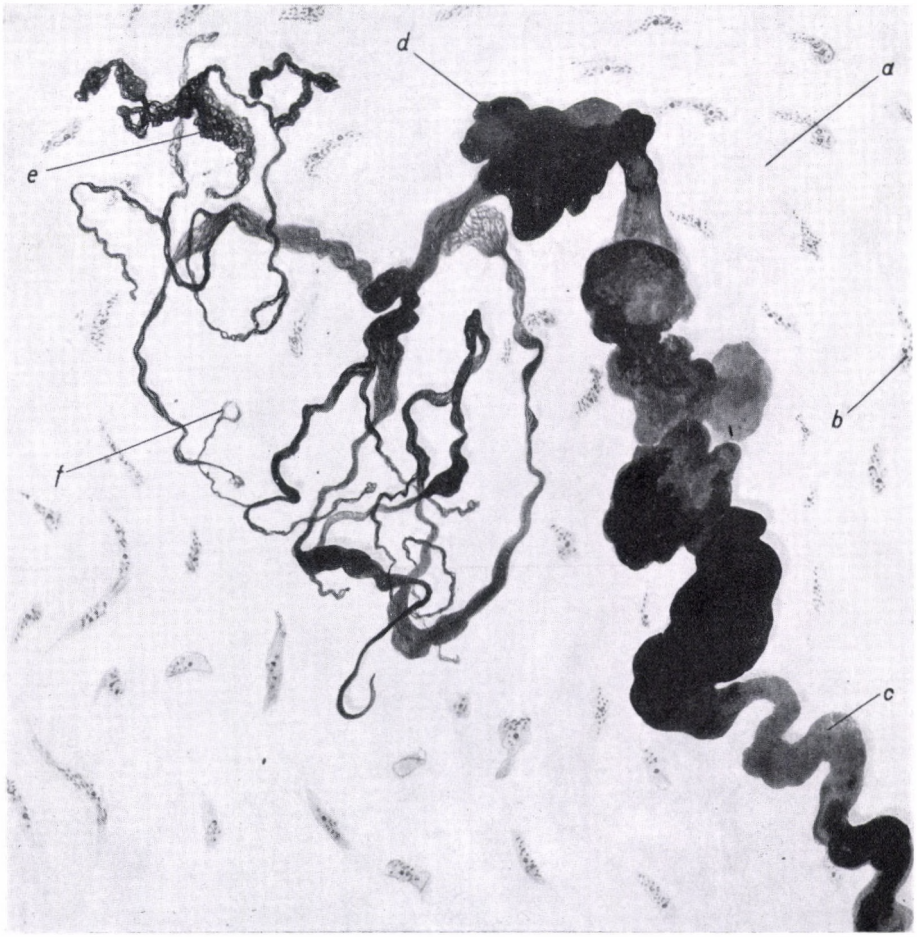

FIG. 84. *Felis domestica.* Sensory nerve end organ in the right atrial endocardium. (a) Connective tissue; (b) nucleus of the connective tissue cell; (c) axon; (d) varix; (e) neurofibril; (f) nerve ending. Jabonero's method. Microscopic magnification 800×, reduced photographically to ½

Cat *(Felis domestica)*

In the right atrium of the cat a mass of sensory end systems is present. They are particularly well seen in impregnated preparations obtained after uni- or bilateral vagotomy. In good preparations sometimes several independent thick fibres were encountered together with their end systems. All thick fibres are undulating and their descent may be pursued over quite a long distance. The descent and appearance of these fibres are occasionally quite specific, resembling those of depressor fibres. All of them branch off at their ends. The rami thus arisen branch off again and all terminate in a delicate neurofibrillar end plate. The end branches and end plates form relatively well defined terminal structures (Fig. 84).

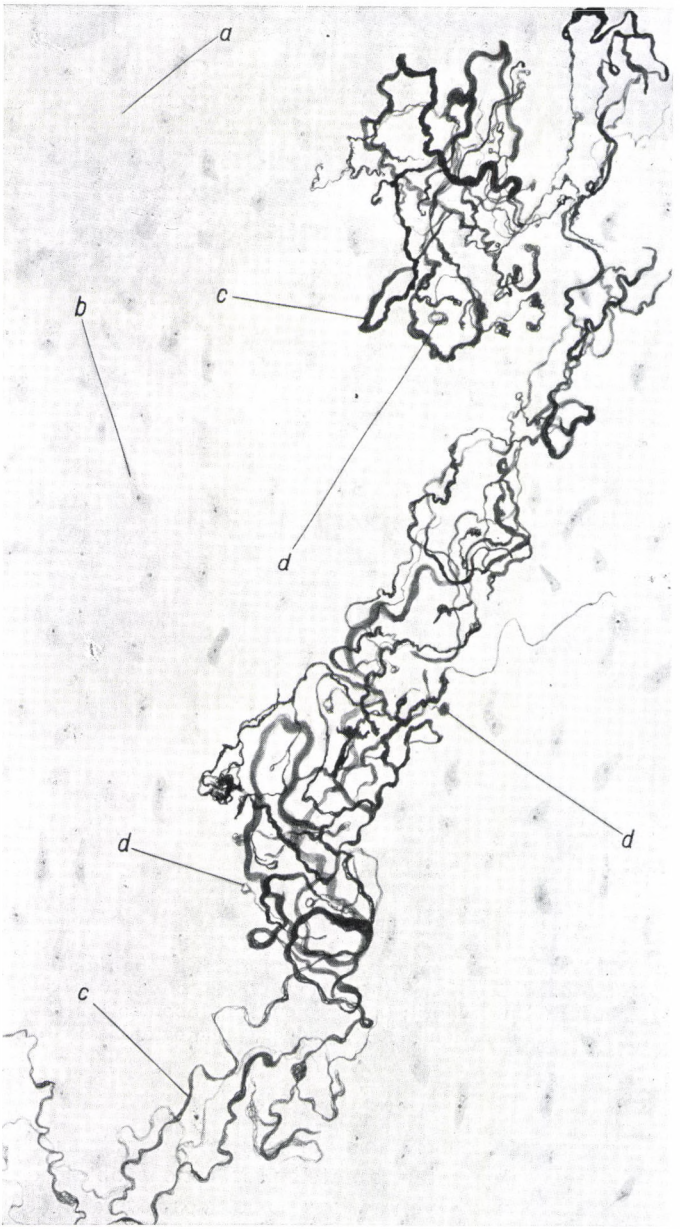

FIG. 85. *Felis domestica.* Nerve end fibre system in the right atrial endocardium. Right vagus cut. (a) Connective tissue; (b) nucleus of connective tissue cell; (c) nerve fibre; (d) nerve ending. Jabonero's method. Microscopic magnification 800×, reduced photographically to ½

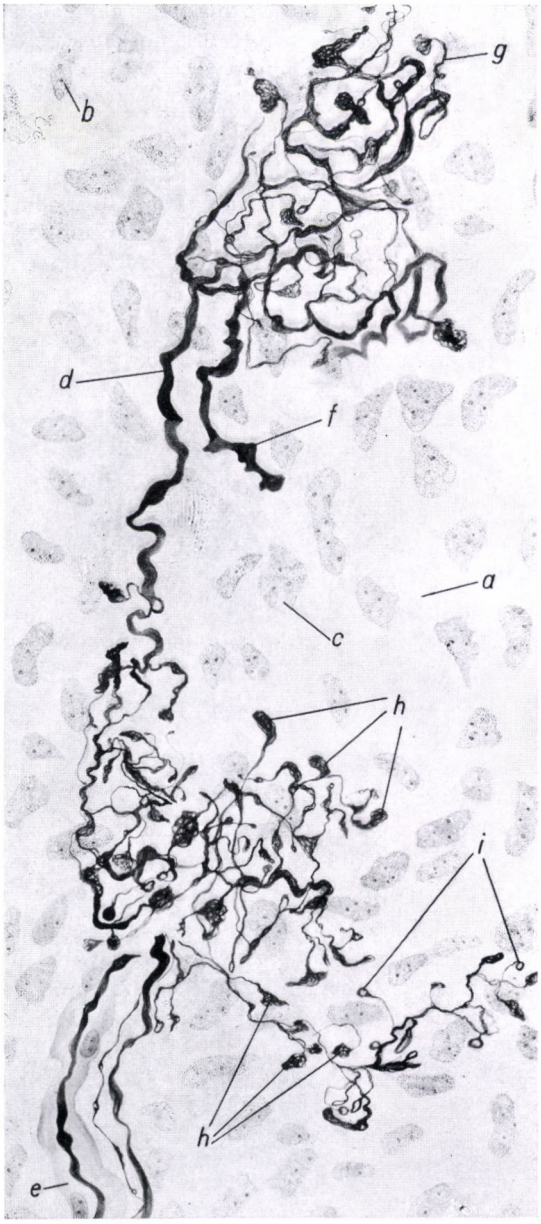

FIG. 86. *Felis domestica*. Nerve end organs in the left atrial endocardium. Bilateral vagotomy (left vagus cut 104 hr before and right vagus cut 50 hr before). (a) Connective tissue; (b) nucleus of the connective tissue cell; (c) nucleus of endothelial cell; (d) main branch; (e) myelin sheath; (f) varix; (g) end branch; (h) neurofibrillar end plate; (i) end ring. Jabonero's method. Microscopic magnification 800×, reduced photographically to ½

In the right atrial endocardium there are often also elongate loose end structures constituted as a rule by several thick fibres. Sometimes more than one of these terminal structures are seen in a single preparation; they may vary in dimensions but their basic structure is uniform. Essentially they are elongate plexuses extending over a large area and showing a relatively large number of smaller or larger end rings. In other cases, larger neurofibrillar end plates are not infrequently seen along the fibres and mainly inside certain larger coil-like formations. The structure of these end apparatuses implies that reception is not restricted to the end systems of thick fibres but may be shared also by the end formations present along the fibres thus presenting a larger surface for the perception of occasional changes (Fig. 85, Plate IV/c, p. 244).

In some cases two different end systems, rich also by themselves, may conjugate by a thick fibre. Both systems are constituted by the terminal ramification of a thick myelinated varicose fibre. After uni- or bilateral vagotomy these systems, namely the most delicate fibre branches, appear with an unusual clarity. They frequently carry spherical varices of varying dimensions and also neurofibrillar intermediary plates. Also, other end plates of elongate, angular or sometimes leaf-like shapes may appear in very sharp definition. The independence of end fibres and end plates is clearly apparent in preparations obtained 72 hr after bilateral, but particularly after unilateral vagus section. Anastomosis and cytoplasmic confluence are lacking both between end fibres and end plates. Also, it is evident that the end plates have no association whatever with the local special formations. Structures possibly connected with the end plates are seen neither beneath nor around them. The end plates simply receive the physiological stimuli from the surrounding connective tissue as special conducting systems being definitely absent between the connective tissue and nerve end apparatuses (Fig. 86, Plate V/a, p. 247).

In some instances end structures were seen surrounded in a capsule-like fashion by connective tissue fibres. Such formations were particularly clearly apparent in animals having survived vagotomy for a longer time. These end structures looked like typical coils, with occasional swellings of the fibres. The presence of smaller and larger end rings inside the coils was, however, suggestive of the fact that they were rather some rich dendritic nerve fibre branchings of a dense coil-like pattern enclosed by a connective tissue capsule. Nevertheless, the individual fibres remained independent, ending freely in end rings (Fig. 87, Plate IV/b, p. 244).

The pictures presented by the capsule-less end systems of certain fibres are of particular interest. With an appropriate choice of the degeneration time it was shown that the neurilemma disappeared first from the fibre. Later on the myeline sheath broke up to spherical particles containing occasionally a pycnotic nucleus from the neurilemma. Subsequently, or sometimes even earlier, the axon was falling asunder, parts of it remaining apparent, while others vanished completely. It is of particular interest that after the complete disappearance of the axon the end structure was still nearly intact although having no connection whatever with the fibre. This remarkable phenomenon seemed to be supportive of a certain limited physiological independence of the end systems. The reason for this may be hardly explained on the basis of our present knowledge. Perhaps the nutrition of the end

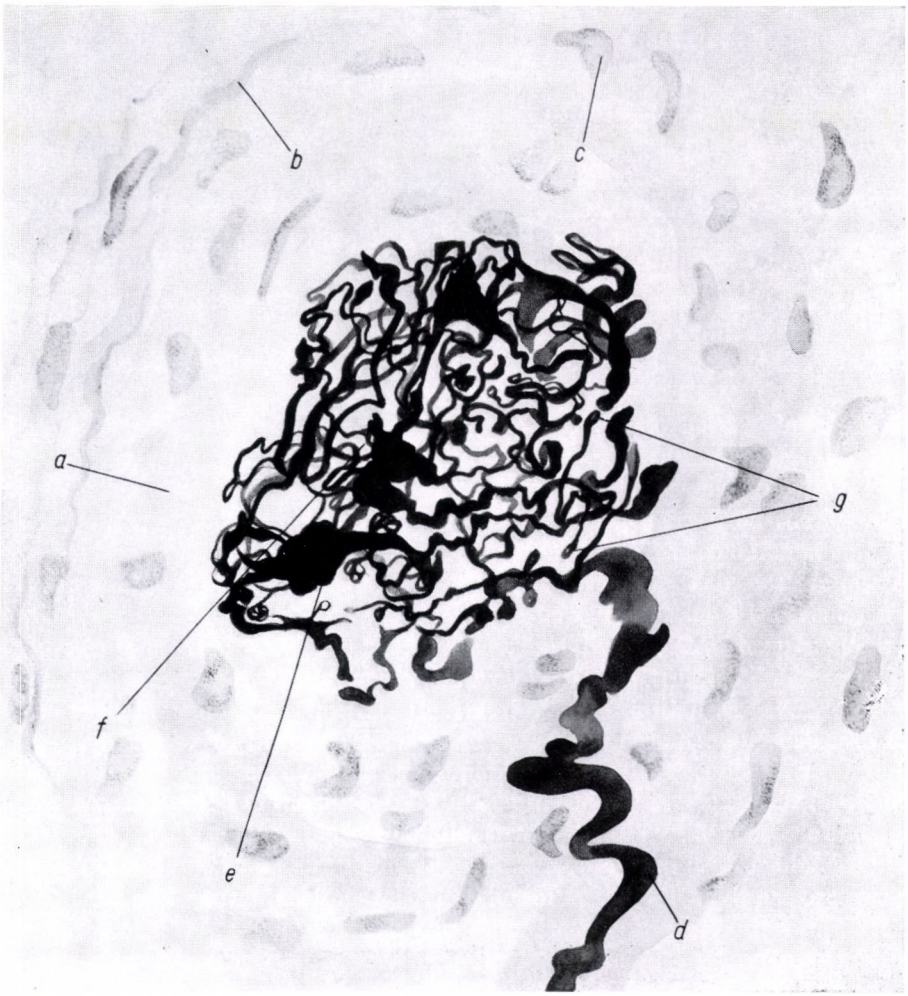

FIG. 87. *Felis domestica*. Nerve end coil in the right atrial endocardium. (a) Connective tissue capsule; (b) connective tissue fibre; (c) nucleus of connective tissue cell; (d) axon; (e) varix; (f) nerve fibre plexus; (g) nerve ending. Jabonero's method. Microscopic magnification 800×, reduced photographically to ½

structure is to a certain degree independent of that of the mother fibre's axon. Yet it ought to be emphasized that this kind of independence is only temporary as, somewhat later, the fibres constituting the end system also fall to pieces and disappear completely in due course (Fig. 88).

In the endocardium of the cat there are also other sensitive nerve end organs. Yet they are similar to the ones mentioned above. However, it is striking that the epicardium as well as the endocardium are so abundantly supplied with sensory nerves.

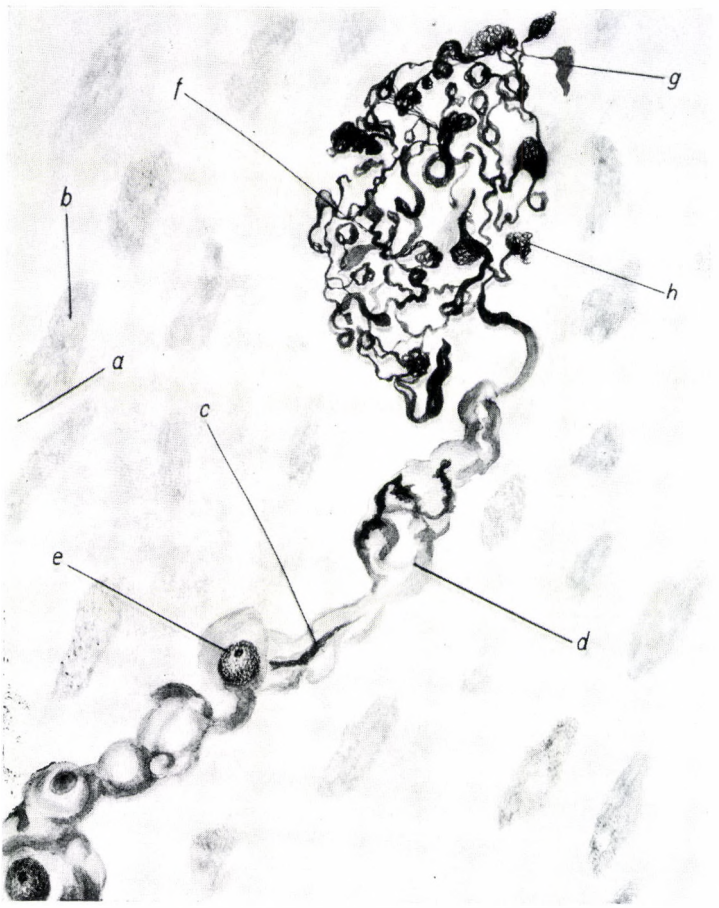

FIG. 88. *Felis domestica*. Disintegrating sensory nerve end organ in the left atrial endocardium. Bilateral vagotomy (268 hr after left and 168 hr after right vagus cut). (a) Connective tissue bundle; (b) nucleus of connective tissue cell; (c) disintegrating axon; (d) myelin sheath; (e) Schwann's nucleus; (f) nerve fibre plexus; (g) nerve end plate; (h) neurofibrils. Bielschowsky–Ábrahám's method. Microscopic magnification 800×, reduced photographically to ¾

Horse *(Equus caballus)*

In the heart of the horse, loose coil-like end systems of particular structure are apparent in the right atrial endocardium. The peculiarity of these structures lies in their being constituted by numerous delicate smooth fibres carrying scanty varices. The shape and arrangement of these fibres implies that the above structures are greater chemoreceptor systems like those found fairly often in the outermost adventitial layer of the larger arterial trunks, mainly among the fat tissue.



FIG. 89. *Equus caballus*. Heart; sensory nerve end organ in the right atrial endocardium. (a) Connective tissue; (b) nucleus of the connective tissue cell; (c) striated muscle fibre; (d) nerve fibre bundle; (e) varix; (f) nerve end coil. Bielschowsky–Ábrahám's method. Microscopic magnification 600×, reduced photographically to ½

This interpretation is, however, opposed by the absence of the small cells with spherical nuclei, typical of the chemoreceptors (Fig. 89).

Accordingly, the coil-like end systems should be regarded as simple pressure or pain receptors. Nevertheless, in the horse's atrial endocardium there are also nerve end systems which, beside delicate nerve end fibres arranged in a coil-like fashion also comprise small roundish cells typical for ganglia. These structures have been considered by us as chemoreceptors.

Pig *(Sus scrofa domestica)*

Some of the nerve trunks passing in the sinus region's endocardial connective tissue comprise beside thin undulating fibres also thick undulating ones, usually more than one per trunk. After branching, these thick fibres sometimes become thinner, exit from the trunk and after repeated dichotomic branching divide into numerous fibres innervating extensive areas. The forms of these branchings remind us of pressoreceptors (Fig. 90).

Beside the sensory endings described above other kinds of sensory endings are also found in the endocardial connective tissue of the lower part of the pig's right atrium. They may be classified into several types. Some of them arise by the abrupt division of a thick fibre into two neurofibril-like end fibres passing further as ultraterminal fibres lacking any special ending. In other cases, terminal fibres arisen by repeated branchings terminate in more or less elongate elliptic end plates.

Certain sensory endings typical of the pig, are occasionally seen in impregnated preparations from the atrial endocardium of this animal. Some branches exiting from the strikingly thick, markedly and densely fibrillated main fibre become particularly thick and their whole matrix arranges in a row of smaller and larger beads inside which the neurofibrils are well visible. Some of the thinner branches are transformed into large neurofibrillar end plates, while others branch off several times and terminate in end plates of varying patterns. The fine structure and general appearance of these nerve endings remind us of those of the pressoreceptor endings.

Sheep *(Ovis aries)*

Impregnation revealed only a single type of sensory end apparatus in the sheep's endocardium. We are convinced that here, too, the different sensory functions are performed by different kinds of end structures, yet so far we have failed to demonstrate more than one type by impregnation of endocardial membrane specimens. Remarkably, this type differed radically from all nerve end structures hitherto described and still more remarkably, it resembles the end systems detected by impregnation in the sheep's aortic arch. Essentially the end structure is a fairly dense and extensive loose coil, with some fibres terminating here and there in delicate end rings or smaller elliptic neurofibrillar end plates (Fig. 91).

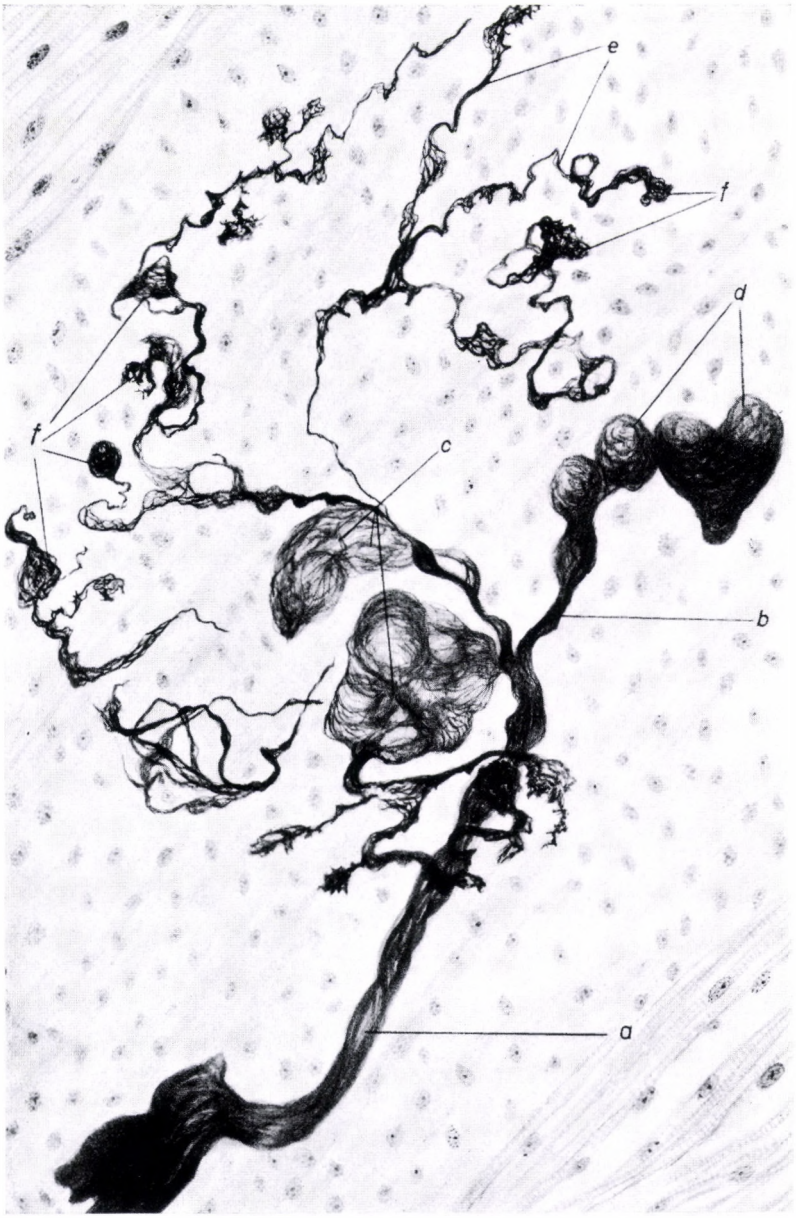

FIG. 90. *Sus scrofa domestica*. Heart; nerve end organ in the left atrial endocardium. (a) Main branch; (b) lateral branch; (c) neurofibrils; (d) varix; (e) end branch; (f) neurofibrillar end plate. Jabonero's method. Microscopic magnification 600×, reduced photographically to ¾

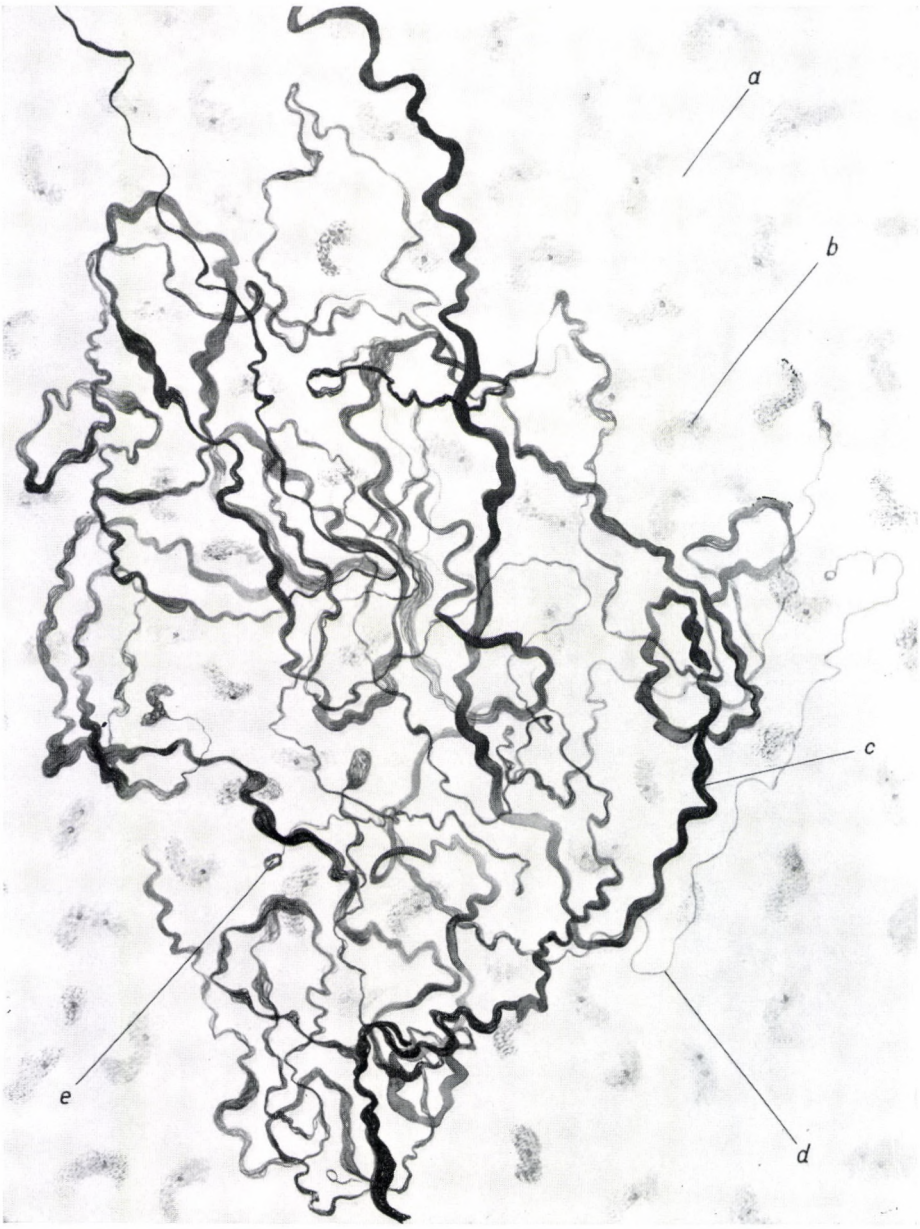

FIG. 91. *Ovis aries*. Heart; sensory nerve end system in the left atrial endocardium. (a) Connective tissue; (b) nucleus of the connective tissue cell; (c) thick nerve fibre; (d) thin nerve fibre; (e) nerve ending. Bielschowsky–Ábrahám's method. Microscopic magnification 600×, reduced photographically to ½

Calf *(Bos taurus)*

The endocardium of the atria is very rich in nerve endings. We do not claim to have succeeded in detecting all sorts of the nerve end structures occurring in this tissue, yet we believe, we have impregnated most of them in *in toto* preparations of the endocardial membrane. A survey of these end formations revealed two fairly well-distinguishable types.

Into the first type may be classified the structurally loose nerve endings. These are constituted by the associated ramifications of several thick fibres. The thick fibres run an undulating path, forming here and there elongate thick varices. Their descent is characterized by frequent broadenings, markedly fibrillar structures and narrowings. The thick fibres branch off subsequently several times. As a rule, ramifications are dichotomic. The end fibres are particularly delicate and terminate in end plates of varying dimensions, some exhibiting a clearly neurofibrillar structure. These forms are infrequent, being present mostly in the right atrial endocardium (Fig. 92).

Into the second type may be classified the structurally more dense nerve end systems of different morphology. Some of them contain terminal fibres of particular structure. Some parts of these fibres are very thick, others again conspicuously thin. The neurofibrils are clearly visible both in the thick and thin portions. The thick fibres branch off subsequently several times and continue in more delicate rami with well visible neurofibrils. Essentially the same applies to the end branches terminating in homogeneous or fibrillar end plates of varying dimensions. The individual end plates are sharply bordered against each other and have evidently no genetic nor special functional relationship with the connective tissue cells of the basal tissue. Anastomoses are absent between the terminal branches (Fig. 93).

To the second group of structurally more dense end systems belong the elongate plexuses with extensively interwoven branch systems along a single thick nerve fibre. Here, too, the main branch is fibrillar, the side branches being delicate, irregularly varicose and undulating. The number of end fibres is remarkably high. The end structures are small, elongate or roundish neurofibrillar plates.

In the dense end structures fibres and end plates are sometimes so numerous that hardly anything else is seen in the preparations. Such end structures are actually end systems of one thick fibre each of which, however, becomes associated with end systems of other thick fibres. On the thick fibres the myeline sheath, above it the neurilemma and its nuclei are clearly visible. The markedly varicose branches which arise by ramification show varying diameters. Like depressor fibres, these thick fibres are also characterized by yielding branches superior to the main fibre in thickness. In the descent of secondary and terminal branches numerous intermediary neurofibrillar plates are apparent. The end plates are large and as with those seen in the aortic arch and carotid sinus they are of ivy-leaf-like, or angular shape. Owing to the rich branchings, there are numerous end plates. The plates being large, they presumably render the respective region of the atrial wall

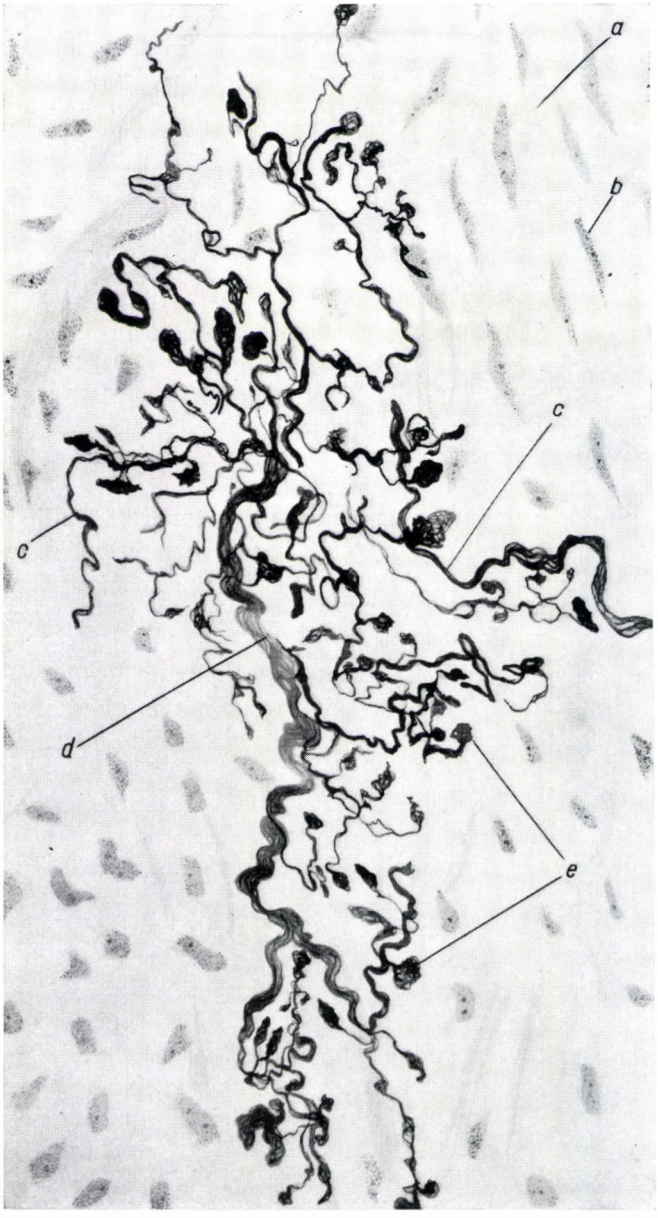

FIG. 92. *Bos taurus*. Heart; sensory nerve end system in the right atrial endocardium. (a) Connective tissue; (b) nucleus of the connective tissue cell; (c) nerve fibres; (d) neurofibrils; (e) nerve end plates. Bielschowsky–Ábrahám's method. Microscopic magnification 400×, reduced photographically to ½

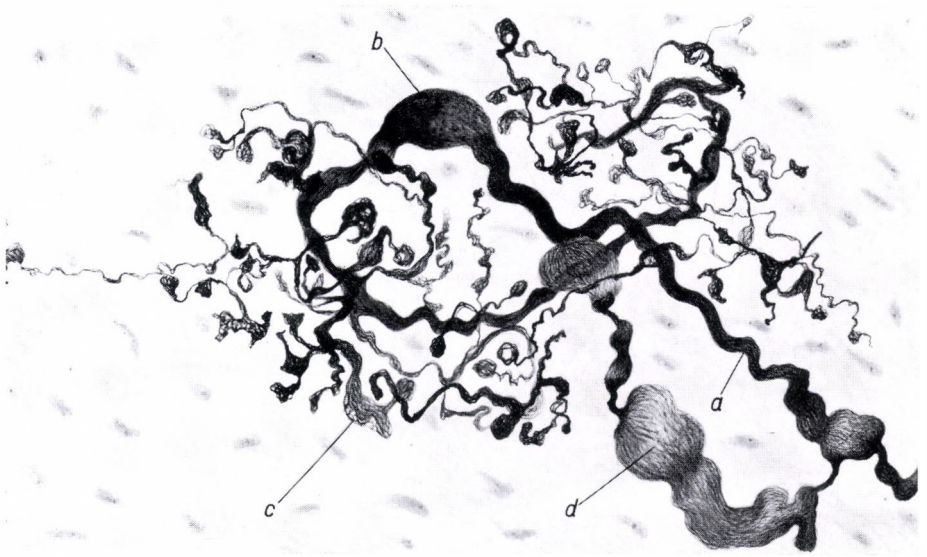

FIG. 93. *Bos taurus*. Heart; sensory nerve end system in the right atrial endocardium. (a) Nerve fibre; (b) varix; (c) neurofibrils; (d) neurofibrillar intermediary plate. Bielschowsky–Ábrahám's method. Microscopic magnification 800×, reduced photographically to ½

particularly sensitive. Nerve endings of similar type were also found in the right atrial endocardium (Fig. 94).

The dense-type end structures may sometimes exhibit flower-like patterns. As a rule, such endings are infrequent. In the calf they are present in the right atrial endocardium. Of all end systems these patterns exhibit the most readily surveyable structure. Also, they give a clear picture of the endings of vagal myelinated fibres. The thick, markedly varicose myelinated fibre divides into three well-distinguishable branches similarly to the depressor fibres. Two of the branches have been torn the path and end structure of the third can be well pursued in the preparation, but over a certain distance this branch, too, is accompanied by a thick myelin sheath in which also the neurilemmal nuclei are clearly recognizable. The fibre, whose axon carries varices of variable shapes and dimensions, thickens and towards its end continues in sphere-like structures in which arise two thin myelinated side branches. The branches, carrying alternately elongate and angular varices, diverge from each other, bend in an arc-like fashion and after a longer or shorter path both continue in rich but easily defined end systems. These systems are characterized by the thick fibres' sudden branching. The rami thus arisen branch off again and the terminal branches among which intermediary neurofibrillar plates are apparent, continue in larger neurofibrillar end plates. The latter are sometimes angular, sometimes tapering but in every case well defined and sharply bordered against the connective tissue. The easily defined structures of these nerve end systems render them particularly suitable for a precise examination of the connection

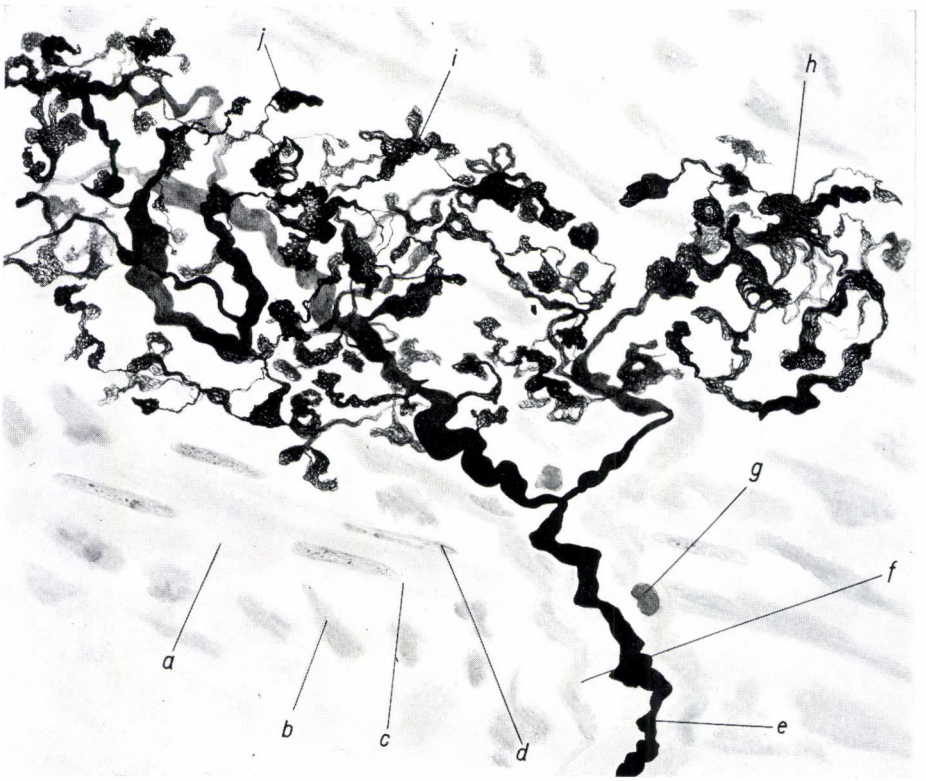

FIG. 94. *Bos taurus*. Sensory nerve end system in the left atrial endocardium. (a) Connective tissue; (b) nucleus of the connective tissue cell; (c) smooth muscle cell; (d) nucleus of the smooth muscle cell; (e) axon; (f) myelin sheath; (g) Schwann's nucleus; (h) neurofibrils; (i) neurofibrillar intermediary plate; (j) neurofibrillar end plate. Bielschowsky–Ábrahám's method. Microscopic magnification 600×, reduced photographically to ½

between sensory endings and the basal tissue. In this context the reticulum and the special cells present an important problem.

The complete absence of anastomoses between the thick as well as the thin fibres of the reticulum has been definitely demonstrable. Hence no such reticulum does actually exist. Also, there is no anastomosis, or any other kind of conjugation, between the neurofibrillar end plates either. Thus the system is independent as a whole and so is each of its constituents. The existence of specialized connective tissue cells may be excluded as well. End plates are attached to the connective tissue wherever they are, thus no specialized connective tissue cells exist (Fig. 95, Plate IV/a, p. 244).

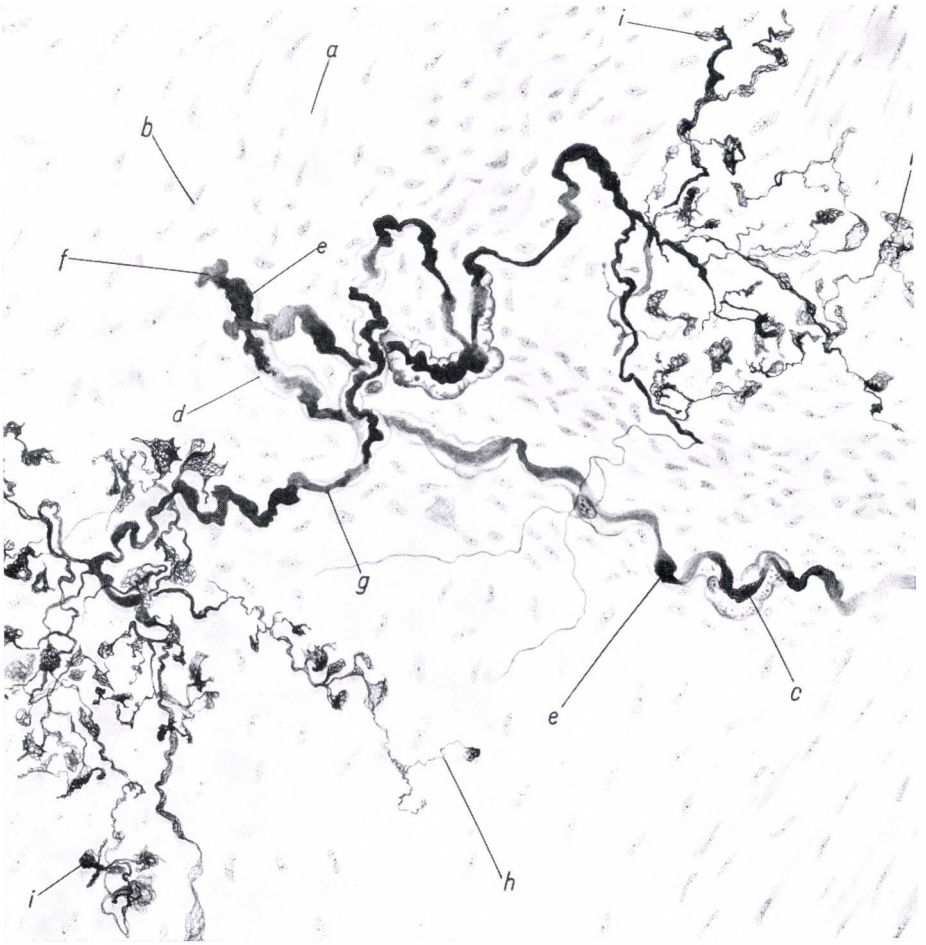

FIG. 95. *Bos taurus*. Nerve end organ in the endocardium of the right atrium. (a) Connective tissue; (b) nucleus of the connective tissue cell; (c) axon; (d) myelin sheath; (e) varix; (f) main fibre; (g) lateral branch; (h) terminal branch; (i) neurofibrillar end plate. Jabonero's method. Microscopic magnification 400×, reduced photographically to ½

PHYLOGENETIC ASPECTS OF RECEPTORS

A closer study of receptors in the hearts of vertebrates permits some interesting conclusions. In all vertebrates, both epicardium and endocardium contain rich nerve plexuses in which thick fibres and special dendritic branchings occur often. These branches are relatively well distinguishable in preparations obtained from the fish heart. Impregnated preparations show, particularly in the carp's epicardium, loose plexuses which, judging by their positions, are very likely sensory plexuses.

Unfortunately, as yet we have failed to reveal nerve endings in these plexuses, thus there has been no unequivocal evidence for their sensory nature. However, in view of their locations and other features, we have tentatively considered these plexuses and dendritic branchings as cardiac receptors, both in the epi- and endocardium.

In amphibia, the receptor nature of epicardial plexuses could be shown in the water frog. In that animal, after bilateral vagotomy, impregnation has revealed well-defined end rings on some of the terminal fibres of the plexuses in question. These nerve pictures, whose like was often seen also in the atrial endocardium and adventitia of the heart bulb, indicate that in amphibia afferents terminate, similarly to effectors, in end rings. Sensory end structures resembling the receptors of mammals were absent both in fishes and amphibia.

In the heart of Sauropsida, including both reptiles and birds, impregnation revealed plexuses both in the epi- and endocardium but no end rings were apparent. Naturally, this does not imply the absence of end rings inside the plexuses and we actually suppose their presence, yet have failed to demonstrate them in reptiles and birds alike. It should be noted that in a single case the impregnated preparation from a bird had shown a narrow lamella-like nerve ending which structurally appeared to be a receptor. Anyhow, we suppose or rather claim the presence of end rings and similar terminal structures also in birds. But the types of terminal structures seen in masses in the mammalian heart are evidently absent from the avian heart. This is indicated by several hundreds of preparations prepared in this laboratory by different methods from the epicardium and endocardium of various avian species. This fact appeared to be remarkable not only from a morphological and physiological point of view, but also as a general phylogenetical problem. It seems to be difficult to explain the sudden unprecedented appearance of highly differentiated end structures in the heart of mammals. The absence of end structures in the avian heart appears to be the more surprising, as these animals represent already a high evolutionary level and their hearts have to meet particularly high requirements. We are completely ignorant as to the possible answers concerning the problem of how a highly complicated structure like the cardiac interoceptor could appear unprecedented without any intermediary forms or phylogenetic continuity. The phylogenesis of mammals has been more or less known to follow a line separated from that of birds, nevertheless this fact fails to offer a solution for the problem. Interoceptors reminiscent of those in the mammalian heart are absent also from the hearts of reptiles. The high number and the variable forms of receptors present in the mammalian heart suggest a very intimate connection of this organ with the central nervous system. These types of interconnections are apparently missing from the avian heart. This difference is difficult to explain as the avian heart is known to be exposed to very remarkable functional labour. Thus, cardiac receptors appear to present a problem inexplicable on a mere phylogenetic basis. The discontinuity in the evolution of cardiac receptors has so far remained an unfilled gap of our knowledge.

ORIGIN OF THE INTRACARDIAL NERVE FIBRES

Investigators of the microscopic innervation of the heart's individual layers are frequently confronted with the problem of detecting the precise relationship of the individual cardiac nerves to the fibres connecting a given layer with the central nervous system. To settle this question as satisfactorily as we can, we shall discuss the efferent and afferent cardiac nerve fibres separately.

Efferent Fibres

As already outlined previously, intracardiac nerve fibres belong partly to the vagus, partly to the sympathetic and partly to the intracardiac ganglia. Fibres originating in intracardial ganglia naturally serve for supplying the myocardial nerve elements, thus only the role of central vagal and sympathetic fibres remains to be clarified.

On the basis of literary data and of our own experience, the role of central vagal fibres in the heart's innervation appears to be as follows. Central vagal and sensory fibres enter together the extracardial plexuses and pass through the coronary plexuses into the heart wall. There they end in the cardiac ganglia as preganglionic fibres. This is indicated also by impregnated preparations from normal heart, yet a firm proof is yielded by heart preparations obtained after vagotomy. Pictures of the hearts of vagotomized mammals show degenerated fibres inside the ganglia (Fig. 96). Thus these fibres evidently belong to the vagal fibre system. The preparations also show, however, that some of these fibres terminate on the nerve cells as terminal rings or bulbs. In some cases even a distinct excavation was seen on the cell's surface at the site of the end ring's or end bulb's location. Apparently, vagal fibres reach only to the ganglia, terminate therein and synapse with the ganglion cells. This interpretation seems to be thoroughly feasible, though not quite convincing as in fact the number of nerve endings detected on the ganglial cells is relatively too low to account for the entire orbit of vagal effects. This may be explained either by incomplete impregnation or, on the other hand, by supposing that a substantial number of efferent vagal fibres passes through the ganglia. Further to this the assumption must not be excluded either that by this route a large number of vagal fibres conjugate directly with the myocardial elements.

The problem of the descents and terminations of sympathetic fibres is less intricate, hence also less interesting, but none the less of substantial importance as they are responsible for the conduction of a part of central impulses to the heart muscle fibres. Part of the sympathetic fibres serves the innervation of the intracardial vessels' walls, part of them go to the myocardial muscle fibres. Thus they are intermingled with the entire heart wall, forming on the striated muscle fibres delicate end plexuses whose single terminal fibres end supposedly on, or in, the muscle fibres.



FIG. 96. *Felis domestica*. Nerve plexus in the atrial septum, 72 hr after bilateral vagotomy. (a) Nerve cell; (b) nerve bundle; (c) degenerating preganglionic fibre; (d) synapsis. Bielschowsky–Ábrahám's method. Microscopic magnification 600×, reduced photographically to ½

Afferent Fibres

Most of the afferent fibres belong to the vagal sensory system. Experimental vagotomy indicated that bilateral vagus section results in degeneration of the majority of sensory systems in the epicardium as well as in the endocardium of both the atria and ventricles. This was readily demonstrable in the cat. Yet some sensory endings did not degenerate even after bilateral vagotomy. Thus it was assumed that part of the receptors originate in the first interspinal ganglia rather than in the vagus. This was supported by our vagus section experiments in cats as well as by the results of Chabarova in cats and goats. She found in these animals that after the section of the first four thoracic nerves part of the sensory fibres degenerated. This experiment presented a fair proof of the fact that cardiac

receptors, i.e. afferent fibres, originated from two systems, viz. the vagal nerve and the first four thoracic interspinal ganglia. It warrants further careful and systematic study to decide which of the above described sensory end apparatuses belong to the vagal and which to the thoracic interspinal ganglial fibre systems. No particular difficulties are possibly involved, as well defined types have already been distinguished among the end apparatuses.

GANGLIA

Relatively numerous ganglia of varying size are present in the heart wall, namely in the atrial regions. These ganglia are the heart wall's vegetative centres with some, probably independent, functions. Their main role is, though, to serve the impulse conduction through the pre- and postganglionic fibres to the effector organ.

In mammals, the arrangement of ganglia is less regular and characteristic than in lower vertebrates, yet the larger groups of ganglion cells are present in the former in about the same regions as in the frog. Ganglia are found in particularly large numbers in the epicardium at the origin of the upper and lower venae cavae. Some ganglia are present also in the left atrial epicardium, along the left and right coronary arteries as well as in the walls of the coronary sulcus and coronary sinus. Further to this, there are ganglia in the sinoatrial node, at the origin of His' bundle, and in the atrial and ventricular septa as well. Nerve cells are present in the atrioventricular sulcus as well as in the upper parts of the ventricles. Francillon has supposed that in the human heart, ganglia located along the pulmonary artery's origin and around the coronary sulcus are analogous with the Bidder ganglion, those along the terminal sulcus and left atrial wall with the Remak ganglion and those in the atrial septum with the Ludwig ganglion.

The dimensions of cardiac ganglia are variable. In general, they are large at the orifice of large veins, in the atrial septum and in the wall of the coronary sinus. The same applies to ganglia located along the coronary arteries and especially to those surrounding the initial portion of His' bundle (Fig. 97). Nerve cells are multipolar and most of them belong to Dogiel's type I. This implies that they extend a single long process over a long distance, their other processes being short and ending close to the cell, forming as a rule an end knot or a neurofibrillar plate

Structurally, the heart's ganglia are generally loose. Most of the fibres are afferent, being mostly conspicuously thick. Both entering and leaving fibres are arranged in larger bundles, comprising beside thin hair-tress-like fibre groups also some undulating, sometimes markedly winding thick fibres. Occasionally, preganglionic fibres are seen to reach the cells forming all kinds of end structures around them. The close but readily surveyed connection of preganglionic fibres with nearly all ganglion cells has been particularly apparent in tangential sections prepared from the right atrium of the mole's heart (Fig. 98, Plate II/b, p. 63).

Both in man and animals, some cells of peculiar morphology have been observed which may be degenerated forms as well as species or organ specific features.

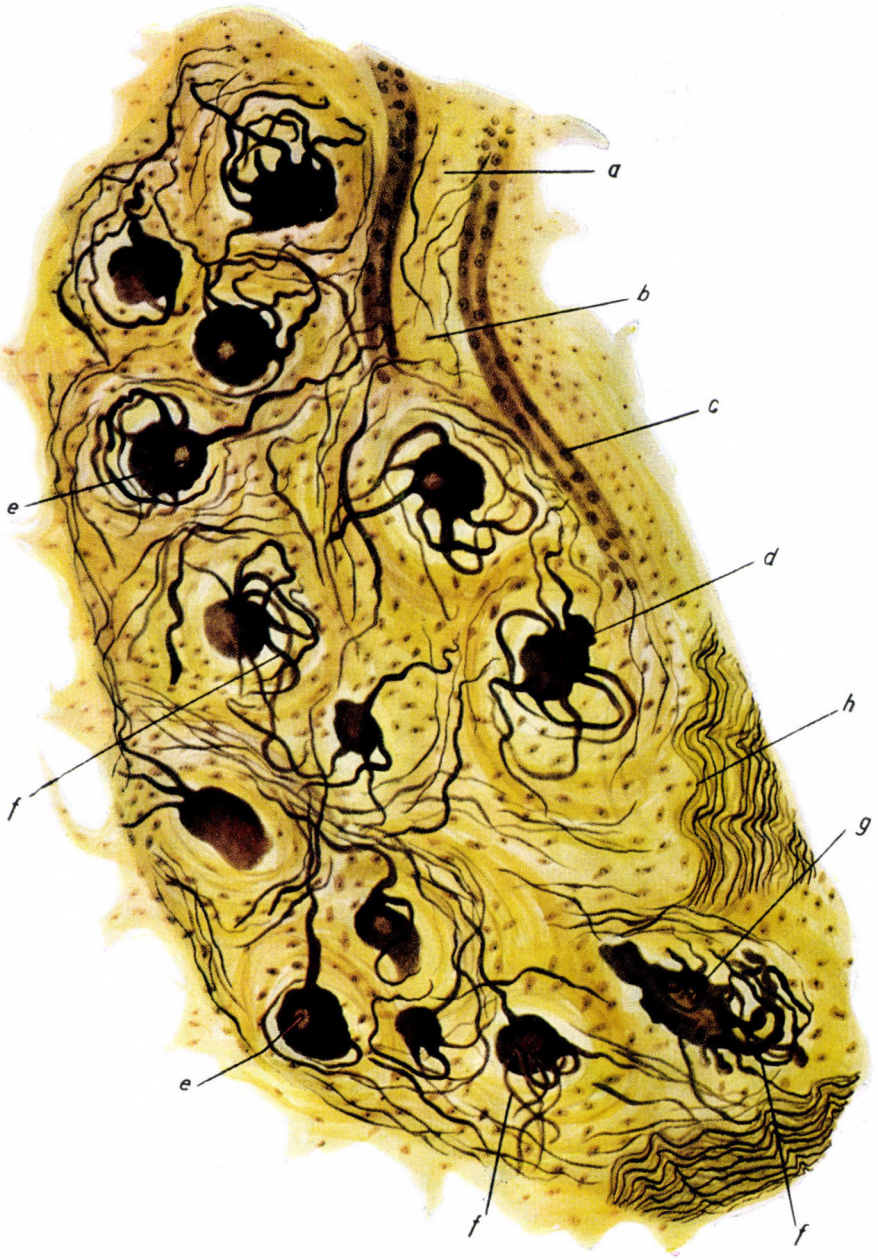

FIG. 97. *Homo.* Ganglion in the wall of the sinus coronarius cordis. (a) Connective tissue; (b) nucleus of the connective tissue cell; (c) precapillary artery; (d) nerve cell; (e) nucleus of the nerve cell; (f) process of the nerve cell; (g) specialized nerve cell; (h) nerve bundle. Bielschowsky–Gros–Cauna's method. Microscopic magnification 300×, reduced photographically to ½

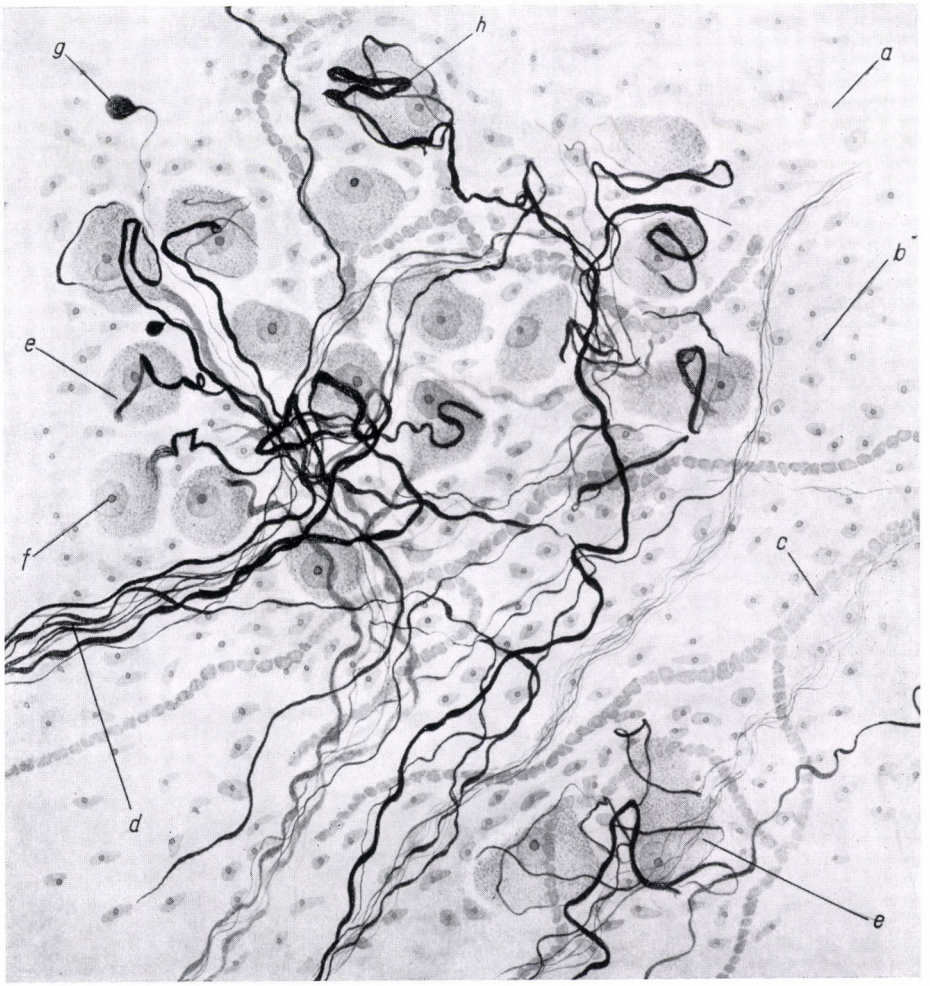

FIG. 98. *Talpa europaea*. Heart; ganglion in the epicardium of the right atrium. (a) Connective tissue; (b) nucleus of the connective tissue cell; (c) capillary; (d) nerve bundle; (e) nerve cell; (f) nucleus of nerve cell; (g) end knob; (h) pericellular plexus. Bielschowsky–Gros' method. Microscopic magnification 600×, reduced photographically to ½

Special cell forms were found around the Aschoff–Tawara nodule in the pig's heart. In some of them, dendrites are replaced by giant plates linked by thin protoplasmic threads with the cell's body. Essentially these cells are Dogiel type I cells which, irrespective of their peculiar morphology, show all essential characters of the neuron. Naturally, in some particular cell forms the neuronal character is not apparent, yet in nearly every case the nucleus is eccentric, which is an important feature of this cell type. A further characteristic is constituted by the fact that in

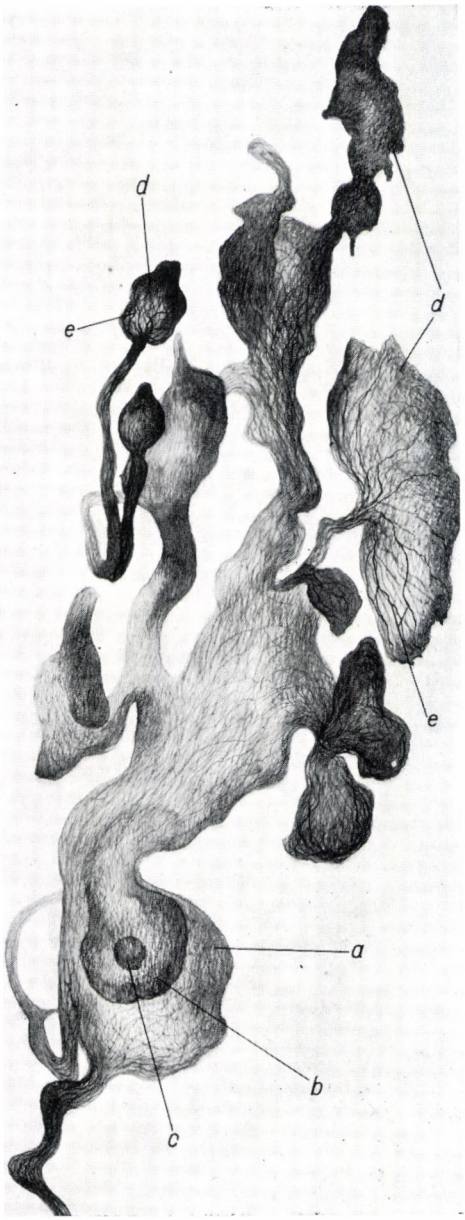

FIG. 99. *Sus scrofa domestica*. Specialized nerve cell in the right ventricular epicardium. (a) Cell body; (b) nucleus; (c) nucleolus; (d) cell process; (e) neurofibrils. Jabonero's method. Microscopic magnification 800×, reduced photographically to ½

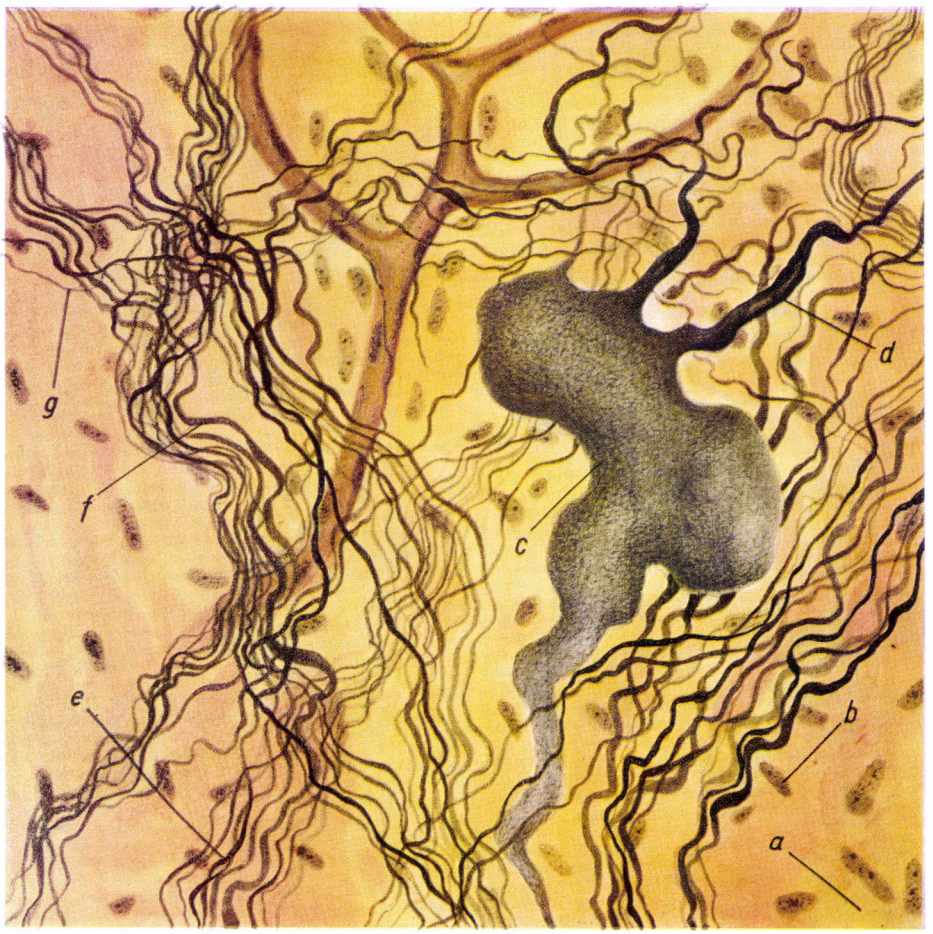

FIG. 100. *Fiber zibethicus*. Heart; nerve plexus in the right atrial epicardium. (a) Connective tissue; (b) nucleus of the connective tissue cell; (c) nerve cell; (d) nerve cell process; (e) nerve bundle; (f) thick nerve fibre; (g) thin nerve fibre. Bielschowsky–Gros' method. Microscopic magnification 800×, reduced photographically to ½

some cells, similar to the cytoplasm, the nucleus also elongates markedly in a given direction and on this side of the nucleus the nuclear membrane is hardly visible (Fig. 99). In other cases, dendrites exiting from the cells are so bulky that they might well be regarded as independent cells. Again, in other cases they may pass over a long distance, forming beads of varying sizes and cell-like structures, terminating finally in peculiar end structures lacking the typical intradendritic elements.

Special cell forms were detected in large masses also in the musk-rat's right atrial epicardium, near to the orifices of the venae cavae. These cells were not arranged

in ganglia but occurred singly within the large epicardial plexuses. It is of interest that in the preparations not a single cell showed a normal sympathetic cell morphology. Generally, the dendrites were disproportionally thin compared with those in the pig. The processes, likely to be considered neurites owing to their shapes and origins, were markedly thick, shapeless and, in association with the plexus' fibres, extended over a long distance from the cell (Fig. 100).

Special cell forms were seen in large masses also in human material, namely in the coronary sinus wall of aged individuals. Most of these cells were ganglial elements characterized mainly by the thickness, unusual position and conjugation of their processes. Another uncommon phenomenon has been the presence of beads, thickenings, branchings and confluences present on the processes along their whole pathway (Fig. 101). These cells, too, exhibited lattice formation but in the myocardial layer of the coronary sinus' wall dendrites of single cells were also seen to extend over a long distance from the cell prior to melting together. Thus here, too, a lattice formation took place, characterized by the presence of large lamella-like cytoplasmic thickenings, end bulbs and elongate beads on the processes (Fig. 102).

No similar intercellular connections were ever observed between cells located along a nerve's path. In this context we are faced with the recently widely discussed problem of continuity in vegetative nervous function. The problem has two aspects: whether or not a connection does exist between the individual ganglial cells and if it does, what is its nature and in what way the preganglionic fibres entering the ganglia are connected with the latter's cells.

As to the first question, an intimate connection between the individual ganglial cells has been postulated by some investigators. Two forms of connections have been described, viz. the cytoplasmic confluence and the dendritic continuity. The former is interpreted as the direct continuation of one cell's cytoplasm in that of the other's. Dendritic continuity means direct confluence of one cell's dendrite with that of the other. Cytoplasmic confluence was described by Greving in certain ganglia of the gastrointestinal system, while dendritic continuity was claimed by Hachiro Seto to occur in the human heart wall. Yet we are bound to disagree with these authors as, in our vast neurohistological experience including most groups of invertebrates and all groups of vertebrates, we failed to detect even a single proof for either form of continuity. Undoubtedly, on superficial observation, some less successful preparations may give the impression of such a continuity. But in every case, such judgements appear to be misinterpretations of the actual conditions. Without questioning the value of the studies of Hachiro Seto on the innervation of the human heart, I take an opposite position stating that continuity between the cells of the heart wall ganglia is nonexistent.

Our studies indicate the synaptic nature of the connection between the dendrites of ganglial cells. The same applies to preganglionic fibres as revealed by the degeneration phenomena observed after vagotomy. Two types of synapses may be distinguished here also, viz. synapses of small and large transmission area (Kirsche). Into the first group are classified the nerve end bulbs, rings and clubs.

In mammals, synapses of small transmission area are well defined and easily surveyable in preparations obtained after vagotomy. The fate of preganglionic



FIG. 101. *Homo.* Specialized nerve cell in the wall of the coronary sinus. (a) Nerve cell; (b) window; (c) process of nerve cell; (d) varix; (e) end plate. Bielschowsky–Gros–Cauna's method. Microscopic magnification 800×, reduced photographically to ½



FIG. 102. *Homo*. Special nerve cell in the wall of the coronary sinus. (a) Nerve cell; (b) window; (c) cell process; (d) dendrite plate; (e) end knob; (f) striated muscle fibre; (g) nucleus of striated muscle fibre; (h) connective tissue; (i) nucleus of connective tissue cell. Bielschowsky–Gros–Cauna's method. Microscopic magnification 800×, reduced photographically to ½

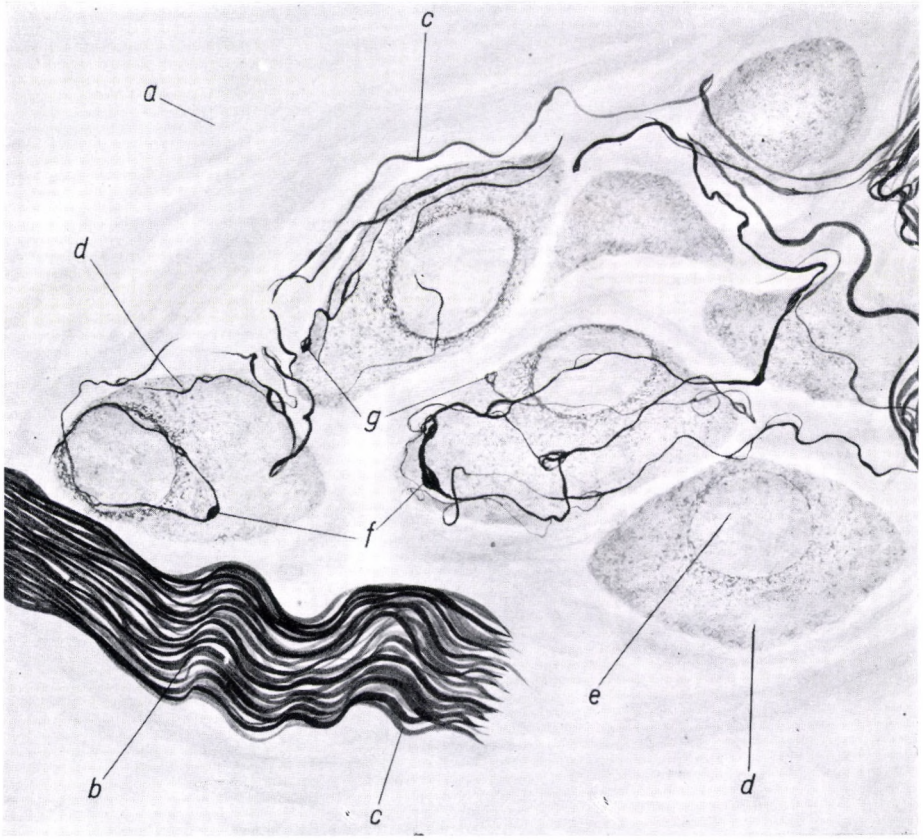

FIG. 103. *Felis domestica*. Heart; ganglion cells and synapses in the right atrial epicardium. Bilateral vagotomy (48 hr after left and 24 hr after right vagus cut). (a) Connective tissue; (b) nerve bundle; (c) nerve fibre; (d) nerve cell; (e) nucleus of nerve cell; (f) varix; (g) synapsis. Jabonero's method. Microscopic magnification 1350×, reduced photographically to ½

fibres may be followed up in preparations made at different intervals after vagus incision. Lawrentiew, the father of experimental neurohistology, observed under such conditions degenerating preganglionic fibres in the ganglia and on the nerve cells, and—with proper timing—the synapses could also be rendered visible. We, too, often saw synapses of small transmission area in bilaterally vagotomized cats. In the majority of cases these synapses were small compact end bulbs or slightly elongate end rings, located inside the nerve cells (Fig. 103). Fairly often we saw the nerve fibres' ends inserted in a small indentation on the cell's surface. In the non-vagotomized mole, characteristic synapses of small transmission area were seen in ganglia of the right atrial region. They were smaller or larger end bulbs, seen either on or among the cells. The fact that in most cases

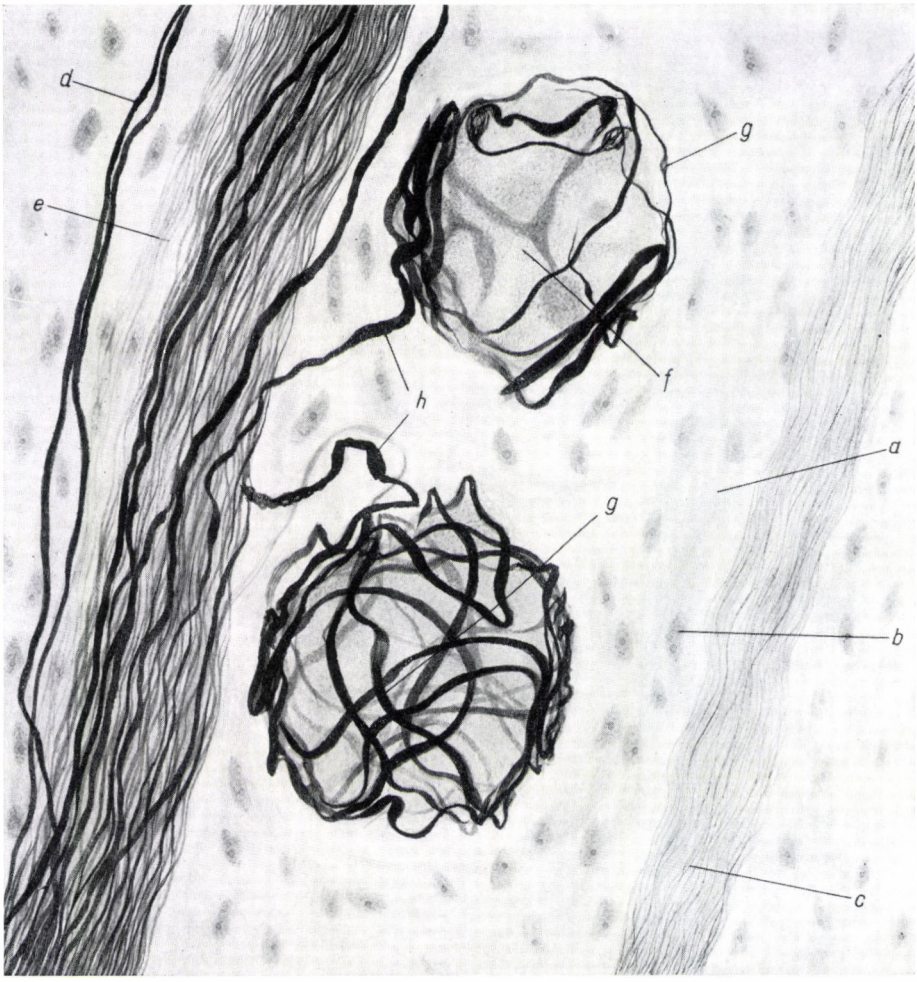

FIG. 104. *Talpa europaea*. Heart; pericellular plexus in the right atrial epicardium. (a) Connective tissue; (b) nucleus of connective tissue cell; (c) nerve bundle; (d) thick nerve fibre; (e) thin nerve fibre; (f) nerve cell; (g) pericellular plexus; (h) preganglionic fibre. Bielschowsky–Gros' method. Microscopic magnification 1500×, reduced photographically to ½

the connection between the end bulb and the nerve fibre is easily visible, serves as a proof for the true synaptic nature of these structures.

Beautiful and convincing pictures of synapses of large transmission area, appearing in the form of pericellular baskets and plexuses, were impregnated in the right atrium of the mole's heart. The absence of genetic relationship between the approaching fibre and the nerve cell was obvious in every case. The thick guest fibre was seen to arrive at the cell in its original form and to surround it precisely without branching like a playball placed in a string bag (Fig. 104).

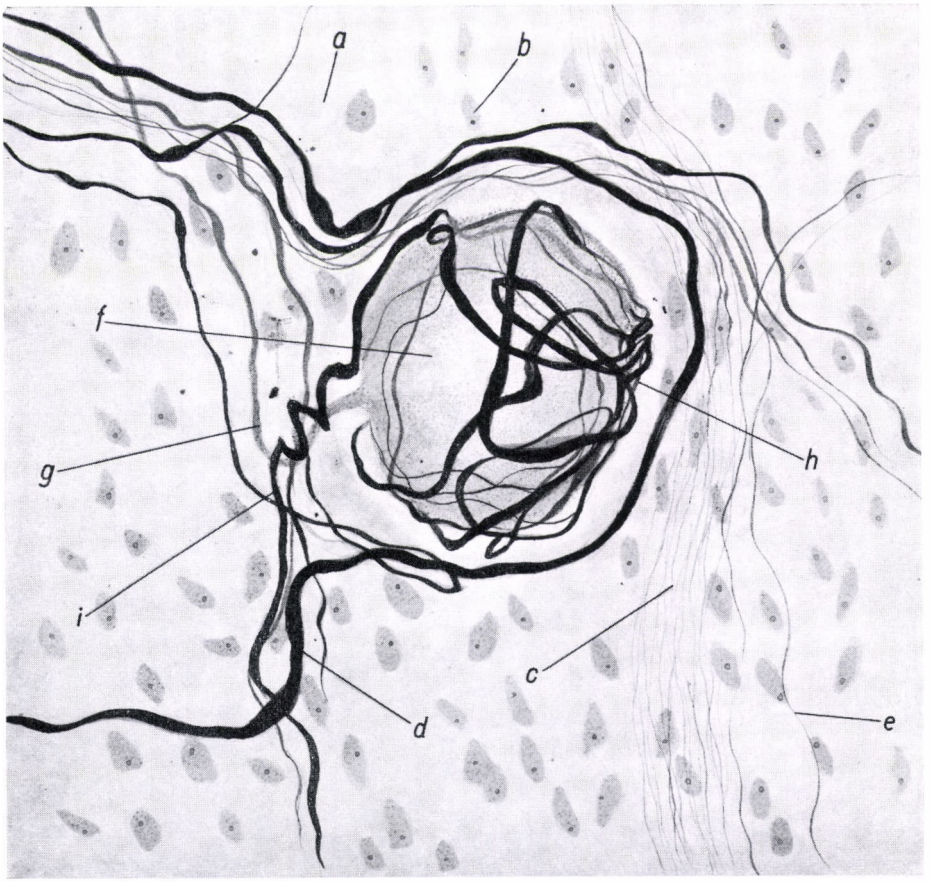

FIG. 105. *Talpa europaea*. Nerve plexus in the right atrial epicardium. (a) Connective tissue; (b) nucleus of the connective tissue cell; (c) nerve bundle; (d) thick nerve fibre; (e) thin nerve fibre; (f) nerve cell; (g) process of nerve cell; (h) pericellular plexus; (i) preganglionic fibre. Bielschowsky–Ábrahám's method. Microscopic magnification 1500×, reduced photographically to ½

In some cases the preganglionic fibre does not branch off even on the cell's surface, neither does it become narrower. In other cases it narrows, then broadens again and terminates in a neurofibrillar plate. In a third case, thick fibres, assuming deep black hue on impregnation, are winding around the cell, embracing it nearly completely. These fibres are accompanied by thin, poorly impregnated ones. Near to them, an undulating thick fibre arrives at the cell surface, surrounding it almost entirely (Fig. 105).

This picture, and also the former are so clear and convincing that they *ab ovo* exclude even the faintest suspicion of accident or irregularity. These pictures are the more persuasive as they show hardly any cells not surrounded by some kind of nerve fibre plexus and whose connection with a fibre sent from distant systems should not be clearly visible.

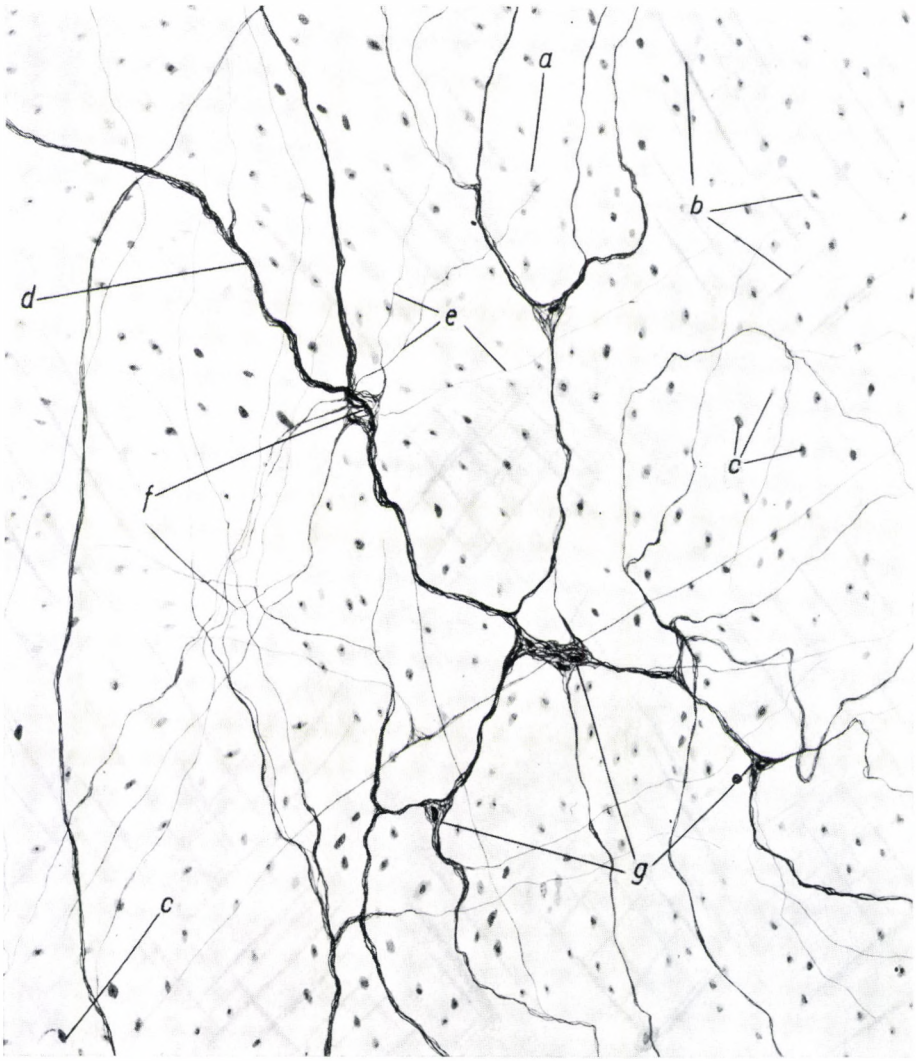

FIG. 106. *Lepus cuniculus*. Nerve plexus in the pericardium. (a) Connective tissue; (b) connective tissue fibres; (c) nucleus of connective tissue cell; (d) nerve bundle; (e) nerve fibre; (f) nerve plexus; (g) point of branching. Bielschowsky–Ábrahám's method. Microscopic magnification 120×, reduced photographically to ½

VALVES

Studies hitherto performed have shown the richness of nerve supply in both the atrioventricular valves and those closing the orifices of the large arterial trunks. Workers interested in the study of the innervation of the mammalian heart's valves are apparently often inclined to declare the presence of true reticula beside

the nerve plexuses. Our preparations do not support this observation. Also sensory nerve endings have been described in addition to the plexuses; they are supposed to be baroreceptors in the valves of the mammalian heart. No such endings were found by us.

PERICARDIUM

The pericardium is innervated by the phrenic nerve and the sympathicus. Nerve fibres form plexuses in different parts of the pericardium. These plexuses comprise beside the smooth-edged thin fibres also some thick myelinated ones.

The pericardium is very difficult to impregnate. Up to now we have succeeded in impregnating only the rabbit's pericardium. In this tissue larger masses of nerve fibres were found mainly near to the atrial orifices of large veins. Here we observed the presence of rich plexuses comprising thick as well as very delicate fibres (Fig. 106). The former belong most probably to the phrenic nerve, while the latter to the sympathetic nerve system. Plexuses are in some places loose and in others dense. Single fibres were often seen to exit from the plexuses and run along a path which was easily followed. No sensory nerve endings were encountered in the pericardium.

4. INNERVATION OF BLOOD VESSELS

HISTORICAL

NEARLY 160 years have passed since Samuel Luca in his paper entitled *Quaedam observationes anatomicae circa nervos arterias adeuntes et comitantes*, published in Frankfurt, had reported the important observation that from the nerve trunks rami pass to the arteries, some of them ending in the periarterial connective tissue and others in the vessels' muscle layer. This discovery was of substantial importance from the anatomical, physiological, pathological and pharmacological point of view. Luca noted that "unterscheiden sich diese den Arterien eigentümlichen Nerven schon durch ihre äussere Gestalt. Sie sind dünner, cylindrisch, schwer vom Zellgewebe zu unterscheiden, durchbohren das Zellgewebe der Arterie schräg und gehen geradeswegs auf ihre Muskelhaut zu. Hier werden sie halb durchsichtig, breiten sich aus und legen sich in der Gestalt einer zarten Membran auf die Muskelhaut der Arterie."* Later on he noted that "Je jünger die Menschen sind, desto häufiger sind die eigentümlichen Nerven der Arterien, die zu ihrer Muskelhaut gehn; mit dem zunehmenden Alter werden sie weniger, so wie die Gefässe der Gefässe in ihnen weniger werden. Damit ist eine Abnahme des bildenden, wie des thierischen Lebensprocesses verbunden."**

Some years later Goering published his *Dissertatio inauguralis anatomica-physiologica de nervis vasa praecipue extremitatum adeuntibus*, in which he stated "Ego in hanc tunicam (i.e. muscularis) nervulos sese immergere non vidi, sed tenues nervulos arteriis se affigentes observavi, quorum cylindri primitivi (Fontana) radiatim tunicae muscularis adhaerentes, in ejus superficie terminantur ita, ut eorum actio in vasa non possit negari."*** This served as final proof of the important fact that nerves enter the vessel walls, their function being consequently controlled by the nervous system. Nevertheless, already these first two descriptions show an obvious inconsistency concerning the presence or absence of nerve fibres in the tunica media. This controversy has continued many decades as reflected by Busch's

* ". . . the nerves associated with arteries are distinguishable already by their appearance. They are thinner, cylindrical in shape and difficult to discern against the tissue, cross the arterial tissue transversely and go right to its muscular layer. Therein they become semi-transparent, broaden and spread in the form of a delicate membrane over the artery's muscular layer."

** "The younger the human being, the higher is the number of the arterial nerves going to the arteries' muscular layer; with advancing age their number decreases like that of the vasa vasorum. This is associated with the decrease of creative process as well as of the animal's vital process."

*** "I did not see nerve fibres penetrate into that layer (i.e. muscular), but I saw fine nerve fibres passing to the arteries and end in the muscular layer's surface by radially adhering 'primitive cylinders' (Fontana) in a way that excluded the denial of their action on the vessel."

statement (1929): "... a few investigators think that the muscularis of the blood vessels perhaps does not contain any nerves at all, others are of the opinion that innervation takes place through peripheral nerve-nets, which may either be quite closed and extracellular or may give off branches which end in free terminations external of the muscle cell; and still other workers assert definitely that every single smooth muscle cell has an intracellular, intranuclear nerve-ending." In 1948 Millen still noted that "anatomical descriptions of the pattern of vascular innervation have been very conflicting". The same applies to vascular physiology although the investigations of Langley (1921) and Bayliss (1923), as well as observations made with Leriche's (1914) periarterial neurectomy have contributed many valuable data.

The conflicts and errors of anatomical descriptions result from the fact that by gross dissection, connective tissue bundles and fibres may be easily mistaken for nerves. This accounts for the contradictory observations made by numerous authors having performed careful dissections on the basis of Leriche's (1914) and Brüning's (1925) studies after sympathectomy. Thus their observations were misleading, not revealing the actual conditions.

The clarification of the origin of nerve plexuses seen occasionally even macroscopically in the adventitia was approached by the anatomical dissection methods by Kramer (1914), Potts (1915), Laubman (1924), Bergglas (1925), Hirsch (1925), Hahn and Hunczek (1925), and Braeucker (1927). Yet, owing to the difficulties outlined above, these examinations were not reliable enough as evidence was lacking whether a bundle in question had been actually a nerve or simply a connective tissue bundle. In this respect, staining of the macroscopic nerve plexuses as proposed by Worobiew (1925) and Kondratieff (1926) has been a great step forward. These authors elaborated an elective staining method for macroscopic nerves and their branchings. With this method, first Ljetnik (1925) made observations superior to all previous findings. Ljetnik and some other investigators revealed that of the nerves entering the vascular walls some are of craniocerebral, others of cerebrospinal, and again others of sympathetic origin. It was also found that the nerves giving off branches to the vessels' walls pass along the vessels at quite a small distance from their walls. The same branches deliver numerous minor rami to the periadventitia where they form plexuses. The latter anastomose with the adventitial plexuses. From the periadventitial tissue nerve branches go to the vessel wall at right angles, dividing it into segments. Fibre bundles entering the vascular wall pass in a longitudinal direction along the outer margin of the adventitia and run further on unparallel with the vessel's longitudinal axis.

With vessels, segmental innervation may be considered general, but according to Leriche (1943), there are also long sympathetic paths accompanying the arteries along their whole, or at least the greater part of their length. Clinicians and physiologists (Rein, Rieder, Busch, Kappis, Schief, Langley, Wiedehopf, Machus and Melichow) deny the existence of long efferent paths attributing the leading role to segmental innervation. Of the surgeons, Brüning and Stahl inclined to a compromise, whereas Gask and Ross (1934) took a guarded position. In my opinion, beside the segmental nerve fibre bundles the long paths also play a role

in vascular innervation and very likely the sympathetic supply accompanies the arteries as far as the capillaries. The possibility that peripherally the vessels are innervated exclusively by cerebrospinal fibres may also be considered. It is not certain either, whether the nerve fibres passing in the adventitia serve exclusively for the innervation of the vessel wall, as they often give off branches to the surrounding connective tissue. As noted by Stöhr, some of the nerve fibres seem to use the vessel wall only as a "temporary hiding place". These are details which have no bearing on the essential fact that vascular nerve supplies are almost inextricably interwoven with the peripheral nervous system.

As is the case with the macroscopic innervation of the vessels, much remains to be clarified also in their microscopic innervation. Namely the nerve connections in the tunica media warrant further investigation, although they have been extensively studied both by anatomists and histologists. Already Remák (1844) and Purkinje (1854) had noted that there are nerve fibres passing inside the vessel wall, but the circumstance that they actually enter the vessel wall was clarified by Koelliker (1854). The same was stated later on by His (1863) and also by Lehman (1864).

In a paper published at the middle of the past century, Beale (1864) noted that "not only are nerve-fibres distributed in considerable number upon the external surface of the artery, ramifying in the connective tissue, but I have also followed the fibres among the circular fibres of the arterial coat. . . . These nerves invariably form networks with meshes". The observations of Beale were confirmed by Ciaccio (1864), who wrote: ". . . the capillaries of the skin of the frog are largely supplied with nerves. In the finest arteries and the largest capillaries the nerve fibres run parallel and close by them, but in the finest ones, the nerve-fibres after running with them some distance, generally cross them and pass from one capillary to another. The nerve-fibres distributed to all capillaries are in connection with one another, so that they form a lax plexus, which lies on different planes".

During his studies on the mesentery of frogs Lippmann (1869) found that myelinated and non-myelinated nerve fibres go to the vessels, forming a "relativ weitmaschiges Netzwerk rings um das Gefässrohr (Primärplexus)",* from which 0·006–0·008 mm thick fibres go to the vessel walls to form a network(plexus) in their adventitia. Lippmann noted that in the muscular tunica, nerve fibres run parallel with the muscle cells' longitudinal axis, then form a plexus which gives off terminal fibres to the muscle cells' nuclei.

Arnold (1871) gave a detailed description of the vessel wall's microscopic innervation, also noting that the terminal nerve rami are in connection with the muscle cells' nuclei.

In his treatise entitled *Traité technique d'Histologie*, Ranvier (1889) gave the following description of vascular innervation: ". . . un premier plexus à mailles larges et inégales, plexus fondamental. Puis, à la surface externe de la tunique musculaire, ils se résolvent en un plexus à mailles étroites et assez régulières, plexus intermédiaire, qui jadis a été assez bien décrit par His d'après des pré-

* "relatively large-mesh network around the vessel tube (primary plexus)".

parations à l'acide acétique, et qui cet auteur a pris pour un réseau terminal. Le vrai plexus terminal ou plexus intramusculaire est formé de fibres beaucoup plus fines, qui se dégagent du plexus intermédiaire et qui très probablement fournissent des taches motrices aux cellules contractiles de la tunique musculaire."*

On the basis of examinations carried out on lizards, Bremer (1872) described three nerve nets in the wall of small arteries, one in the tunica adventitia, one in the intermediary zone and one in the tunica muscularis. He also noted that the vascular nerves do not anastomose with the other peripheral nerves. "Ein Nerv, der einmal an ein Gefäss herangetreten ist, verlässt dasselbe nicht mehr."**

A precise study of vascular innervation could be started only after the elaboration of neurohistological staining methods with gold chloride, methylene blue and, particularly, silver nitrate. In the hands of the versed neurohistologist, these techniques proved to be adequate tools for rendering visible the fine structure of the nervous system (Arnstein, 1887; Ramón y Cajal, 1891; Agababow, 1892; Ballowitz, 1894; Smirnow, 1895; Demoor and Heymans, 1895; Gad, 1895; Dogiel, 1898; Siehler, 1901; Kytmanoff, 1901; Leontowitsch, 1901; Lapinsky, 1905; Hoffmann, 1907; Michailow, 1908; Glaser, 1913; Kramer and Todd, 1914; Hirsch, 1925; Fukutake, 1925; Stöhr, 1926). Nevertheless, in this context, too, we should like to emphasize that making visible the vascular nervous system is still one of the most difficult tasks of neurohistology.

Below we describe first the innervation of arteries, veins, arteriovenous anastomoses and capillaries, and secondly that of coronary arteries, intracardial, renal and cerebral vessels.

ARTERIES (ARTERIAE)

The innervation of arteries is discussed on the basis of our examinations of various avian and mammalian species and in man. As the material obtained from these different sources has not shown notable differences, the results are discussed generally according to the three histological layers of the vessel wall, which have been uniformly found in all species examined. As our statements on the nerve connections in the three layers are general, a mixed illustration material from all the three fields has been presented without particular selection. In this sense, further on we refer simply to the nerve connections of the tunica adventitia, tunica media and tunica intima, without discussing the minor differences encountered in the arteries of various origin.

* ". . . a first plexus of large and unequal meshes, the basal plexus. Further, on the external surface of the muscular layer they arborize to form a plexus of small and relatively equal mesh, the intermediary plexus, having been quite correctly described by His on the basis of acetic acid preparations and having been supposed by the same author to be the final path. The true final plexus or intramuscular plexus is, however, formed by much finer fibres branching off from the intermediary plexus and very probably supplying motoric stimuli to the muscular layer's contractile cells."

** "A nerve, once having approached a vessel, never leaves it again."

Innervation of the Arteries

The nerve fibres innervating the arteries come from the connective tissue and are of various thickness and origin. They branch off in the outward adventitial layer, pass on in a longitudinal direction and in association with a varying number of fibres, form a loose plexus. The latter constitutes the outermost arterial plexus, named by Woollard the adventitial plexus. Most of the fibres constituting the plexus are sympathetic fibres without a myeline sheath, but in certain segments of the arteries there are also nerve trunks, or bundles constituted almost entirely by thick myelinated fibres. Beside them there are also some thick myelinated fibres which descend separately either singly or in pairs, down to their terminal branches.

Inward from the adventitial plexus between the adventitia and media there is a second plexus named by Busch the interlamellary plexus. This, too, contains some myelinated fibres but, apart from certain distinctly sensitive vessel portions, their number is as a rule low.

The third plexus, whose fibres are—according to Millen—"present between the smooth muscle cells", is found inside the interlamellary plexus. The location of the three plexuses is essentially similar in the large, medium and small arteries, naturally with the difference that with thinner arterial walls the number of nerve fibres also decreases.

The three neurological layers were observed also by other investigators, among them by Dogiel, the Russian expert on peripheral nerves, and by Stöhr, anatomist and histologist in Bonn, who published several treatises on vascular innervation. In his first publication on this topic, Stöhr denied the presence of the third plexus stating that were there a plexus in the media, large numbers of nerve fibres and nerve endings should be present therein but he found them definitely absent. Let us quote from one of his papers: "In Hunderten von Präparaten habe ich nicht eine Spur von Nerven in der Muscularis bemerkt, ganz selten sah ich einmal ein vereinzeltes Faserchen sich von dem tiefen Adventitiaplexus nach der Media hinabzweigen und selbst da war ich nicht ganz sicher, ob nicht ein Schrägschnitt die Ursache der Erscheinung war."* This statement of Stöhr was opposed by the experimental results of Busch, Wollard and Millen. As will be seen later on, I, too, support the latter concept, yet to compensate for Stöhr's error I should like to note here that under the microscope, the media quite frequently appears to be nerve-free apart from some delicate fibres apparent on its adventitial surface. Hence until recently, I considered the media nerve-free myself, interpreting its function as dependent on the nerve connections on its outer surface, as stated by Goering 152 years ago. Yet my recent examinations of the microscopic innervation of arterial portions from numerous humans, mammals, birds, reptiles, amphibia and fishes convinced me that the media of certain arterial segments

* "In several hundreds of preparations I failed to detect even the trace of a nerve in the muscularis. Quite infrequently I saw a single fibre going from the adventitial plexus to the media and even then I was not quite sure whether the phenomenon was not due simply to transverse sectioning."

contains rich nerve plexuses whose end fibres extend between the muscle cells. Such segments include the coronary arteries of the calf and pig, the aorta of the cat, fox, dog and badger as well as the vessels supplying the brain base, the splenic and the renal arteries. In contrast, there are certain arterial portions or even entire arteries which completely fit in with Stöhr's description in that no nerve fibres are demonstrable in them with the available method. The feasibility of this interpretation is supported by the fact that, for example, in the wall of the coronary sinus the adventitial plexuses are always well impregnated, whilst nerve fibres in the media remain without impregnation. Similar conditions have been observed in the coronary arteries of the human heart, in the aortic arch and also elsewhere.

If there is, however, actually a nerve plexus in the media, one wonders what the connection between the medial smooth muscle tissue and nerve fibres may be like. This question was raised long ago but as yet no satisfactory answer has been given. This is not surprising, considering the difficulties involved in the techniques as well as in the objective evaluation of the microscopic pictures. This question presents but one aspect of the much disputed problem of the smooth muscle's innervation, interpreted in several ways yet still inadequately clarified.

To throw a light on that complex problem, we have to revert to an earlier concept based on the study of Golgi preparations, and postulating that between the smooth muscle cells of the media, sympathetic fibres form a plexus from which exit thin fibres to the muscle cells, terminating there epilemmally in spherical or button-like free endings. This hypothesis was not accepted generally, another being advanced stating that the end structures of the delicate terminal fibres end intracellularly, near to the nucleus. Some workers have carried this theory still further, noting that the intracellular nerve fibres divide into delicate terminal fibrils, passing on in the muscle cell's cytoplasm, then disappearing without any perceivable border between fibrils and cytoplasm In the light of up-to-date neurohistology, the above interpretations appear to be unsupported, yet at the same time we are bound to confess that still no definite conclusions could be drawn even from our most successful preparations. Therefore, various explanations have been offered both by morphologists and physiologists.

Marchand asserted the association of the nerve ending with the muscle cell and postulated a neuromuscular system. Kroetz regarded the vegetative nervous system and the effector organ as a functional unit, designating it as a vegetative end apparatus. Brodie and Dixon termed the connections "neuromuscular linking tissue". Langley used several terms for the designation of the connection between smooth muscle tissue and vegetative nerve system, e.g. "end apparatus", "nerve ending", "myoneuronal connection site", "neural region", "receptive subtance", and others. These terms, too, reflect the uncertain attitudes of investigators in this question. Therefore, most workers take pains to avoid the use of exact terms for the neuromuscular connection in the smooth muscle region.

A clarification of the problem has been, at least partially, attempted recently by different workers on the basis of extensive neurohistological studies. Agababow, Boeke, Kolmer, Clark, Rossi, Krümmel, Pines, Pinsky and Ábrahám examined the smooth muscles of the eye, while Boeke those of the hair arrector muscles.

Nerve connections of the smooth muscle elements of the spleen and cholecyst were studied by Riegele and Harting, those of the bronchial muscles by Hayashi, of the uterine tube by Beaufays, of the intestinal tract by Van Esveld, Hill, Lawrentiew, Reiser, Sunder-Plassmann, Kolossow and Sabussow, Kolossow and Polykarpowa, Lawrentiew and Borowskaya, Iwanow and Radostina, Ábrahám, Schadabasch, Ottaviani, Boniventino and Stöhr.

The results of the above examinations have been incongruent, yielding uncertain and contradictory information concerning the descent and structure of fibres. In fact, as end connections have not been quite clearly apparent even in the best preparations and with optimal magnification, the interpretation of microscopic pictures has largely allowed for subjective error. In view of these difficulties Stöhr (1932), having studied the problem thoroughly for many years, ventured to offer a solution in 1932 and still tries to defend his position although it has been a matter of dispute ever since. In the muscular layer of the human caecal appendix, Stöhr and his co-worker Reiser detected with Bielschowsky's method "eine aus feinsten, teilweise noch mit Kernen versehenen Nervenfäserchen bestehende, überaus netzartige" formation* and described it as "nervöses Terminalreticulum",** claiming to have solved the problem of nerve end connections in the smooth muscle.

Stöhr reported the presence of terminal reticulum also in the media of arteries. In the same publication he noted that "die Media für den Nachweis nervöser Elemente vielleicht infolge des ausserordentlich festen Zusammenhanges der glatten Muskelfasern, vielleicht aus anderen nicht bekannten Gründen ein ungünstiges Objekt zu sein scheint".*** Yet, he claimed to have obtained, by very tenacious work, preparations showing clearly "Eine dichte Fülle feinster, gerade noch mit Silber imprägnierbarer und nur bei stärkster Vergrösserung hervortretenden Nervenfibrillen breitet sich auf der Muscularis aus und zwängt sich gelegentlich zwischen die glatten Muskelfasern hinein. Teilweise sind noch Schwannsche Kerne vorhanden, teilweise fehlen sie völlig."† Stöhr claimed this particularly delicate reticulum to be the terminal reticulum and as such the single nerve end formation in the media, intima and adventitia alike.

According to Stöhr's concept, there is "ein untrennbarer Zusammenhang"†† between the vascular nerves and the organs supplied by the vegetative nervous system, involving not only the larger nerve trunks, bundles and fibres but also the terminal reticulum, linking "die kleinsten Arterien mit den übrigen vegetativ

* ". . . an entirely net-like formation consisting of most delicate, partly nucleated nerve fibrils".

** "nervous terminal reticulum".

*** ". . . the media seems to be inappropriate for the demonstration of nerve elements, probably because of the extraordinarily close connection of smooth muscle fibres or for some other unknown reasons".

† ". . . a dense mass of most delicate nerve fibrils, just impregnable by silver and apparent only at the highest magnification, to extend over the muscularis and enter between the smooth muscle fibres here and there. In a part of these fibrils the Schwann cell nuclei were still present, whereas in the rest they were absent".

†† ". . . an inseparable connection".

innervierten Zellen des jeweiligen Organes zu einer, in nervöser Beziehung untrennbaren höheren funktionellen Einheit miteinander."* In the sense of these considerations Stöhr has expressed his conviction that "die vegetativen Nervenfasern enden nicht 'frei', oder mit einer kleinen kopfförmigen Verdickung an den einzelnen Zellen des Erfolgsorganes"** noting that "als periphere Endformation unseres vegetativen Nervensystems kommt—lediglich das nervöse, teilweise noch kernhaltige Terminalreticulum in Betracht, eine syncytial gebaute netzartige Konstruktion".***

In the literature, Stöhr's theses were met with different responses. Some workers supported, while others opposed them. For my part, I opposed them from the beginning, having so commented first in a publication on the innervation of the avian intestinal tract in 1936, as cited below: ". . . kann ich Stöhr nicht beistimmen, weil ich einerseits selbst an den besten Präparaten das Terminalreticulum nicht zu entdecken vermochte und andererseits die feinen Fasern, die nach ihm die Verbindungsglieder der Nervenendigungen seien, und von ihm syncytiales Wabenwerk genannt werden, meiner Meinung nach keine Nerven sondern anderen Gewebsgruppen angehörende feine Faserngebilde sind."†

Stöhr answered by questioning the adequacy of my technique, noting that it does not provide for the impregnation of the finest nerve fibrils. Thus the terminal reticulum theory again gained a wider field as Stöhr himself and all neurohistologists trained in his institute have claimed to have found the same terminal reticulum with the same impregnation technique again and again. Simultaneously with my article appeared the criticism of Lawrentjew and Borowskaja (1936) soon followed by that of Nonidez (1937). Lawrentjew and Borowskaja regarded the terminal reticulum as artefact. Nonidez stated that the fine fibrils regarded as terminal reticulum by Stöhr and his co-workers are simply argyrophilic fibres having no relationship whatever with nerve fibres. In a study of arterial innervation, I wrote the following in 1938: "Der Verlauf der Fasern ist an mancher Stelle so wellig, dass sich die Wellen manchmal dermassen nähern, dass ein an das Stöhr–Reisersche Terminalreticulum erinnerndes Bild zustande kommt. Das alles sehen wir auf der rechten Seite der Abbildung sehr deutlich, dass aber dieses ein wahrhaftes Terminalreticulum wäre, kann ich nicht bestimmt behaupten, schon deshalb nicht, weil solche Anastomosen, die das Hauptmerkmal des Reticulums bilden, hier nicht anzutreffen sind, und an dem scheinbaren Netz gewahrt man, dass die

* ". . . the smallest arteries with the rest of vegetatively innervated cells of a given organ to a higher functional unit, inseparable in respect of innervation."

** "vegetative nerve fibres do not end 'freely' or by a small head-like thickening on the individual cells of the effector organ . . ."

***"... The only structure feasibly considered a peripheral end structure of our vegetative nervous system is the partly still nucleated nervous terminal reticulum, a net-like structure constituted by syncytia."

† ". . . I am in no position to agree with Stöhr, on one hand because I failed to detect a terminal reticulum even in the best preparations and, on the other hand, because the delicate fibres, claimed by Stöhr to connect the nerve endings with each other and termed by him a syncytial network, are in my opinion not nerves but fine fibres belonging to other tissue groups."

Fasern ihre Selbständigkeit beibehalten."* The comments by Nonidez and myself were refused by Stöhr as follows: "In Abbildung 5, die gleichfalls einen Ausschnitt aus der direkt auf der Media ruhenden, nervösen Fasermasse darstellt, verlaufen nur wenige mittelstarke Nervenfasern im Gesichtsfeld: in ihrer Existenz bereits das Resultat einer vollkommenen Imprägnierung des Nervengewebes erblicken zu wollen, wie es etwa vor kurzem Nonidez und Ábrahám behauptet haben, scheint mir nicht angängig. Denn eine gute Imprägnierung lässt im Präparat weitere wesentlich zärtere Nervenelemente hervortreten."** Yet, as will be seen later, I consistently failed to detect a terminal reticulum in any of the several hundred preparations surveyed.

Since further literary discussion seemed to be useless, in summer 1938 I visited Stöhr in Bonn to have a look at the preparations from which the published pictures of the beautiful and at any rate interesting terminal reticula had been derived. Stöhr displayed readily all his preparations, showing in them with a specially high magnification his favourite structure, the terminal reticulum. I observed the preparations very thoroughly, yet I am bound to confess that I failed to detect the terminal reticulum even in Stöhr's preparations and told him so. He did not seem to be much surprised, as—he told—the recognition of the terminal reticulum requires a certain fantasy. To which I replied that in my opinion such questions should be decided as much without fantasy as possible!

After a survey of Stöhr's preparations, I showed him some of mine. In those obtained from the intestines of the tench, Stöhr believed he could detect in the muscularis mucosae "wonderful terminal reticula", to use his own words. I explained that in my opinion these are not so much terminal reticula as plexuses whose fibres have remained independent and belong to the smooth muscles. We were unable to reach an agreement and parted with the decision to carry on the fight against each other without, however, changing our mutual friendly attitudes. And so it went on: where I saw a plexus, Stöhr saw a terminal reticulum. I think that our incongruent positions to this question were influenced also by the development of two opposed schools of thought, although Stöhr stated repeatedly also later his belief in the reticulum rather than the plexus.

The concept of terminal reticulum has been supported by many investigators, mainly in the German literature (Reiser, 1932, 1938, 1952; Knoche, 1950, 1951, 1952, 1958; Greving, 1951; Walter, 1957), although others (Boeke, 1951; Herzog, 1954) have severely criticized it. Recently, however, the terminal reticulum has

*"The descent of fibres is sometimes so undulating that their waves approaching each other closely may give a picture actually reminiscent of the terminal reticulum of Stöhr and Reiser. This is clearly visible on the right side of the figure, yet I would not state this were a true terminal reticulum, especially as there are no anastomoses of the type constituting the main feature of the reticulum; also, the fibres constituting the virtual reticulum have evidently remained independent."

** ". . . In Fig. 5, also representing a cutting of nerve fibre mass lying on the reticulum, only a few nerve fibres of medium thickness are descending in the field of vision: to interpret their existence already as a result of the nerve tissue's complete impregnation—as stated not long ago by Nonidez and Ábrahám—seems to be impossible in my opinion, as a good impregnation would have offered a possibility to detect further, substantially thinner nerve elements in the preparation."

tended to disappear from the German literature (Taubert, 1960; Knoche, 1961; Brettschneider, 1965) as both light microscopic and electron microscopic examinations have indicated the definite lack of any morphological basis for that assumption. If this is true and accordingly, the nerve end connection system of vegetative nerves is not constituted by a reticulum, the question still remains what might be the nature of the structure linking the smooth muscle tissue with the nervous system to a functional unit. Various explanations are still offered of this question.

Based on his experimental morphological studies, Lawrentiew (1936) concluded "dass die sympathischen Neuronen ihre Selbständigkeit bis dicht an die Nervenendigungen bewahren und dass ihre Axonen mit den anderen Axonen und Verflechtungen nicht verschmelzen".* This statement is in sharp contrast with the views of several authors who asserted that the vegetative nervous system is built up of syncytia. According to Lawrentiew, among the vegetative nerve plexuses there is only a single syncytium, formed by Schwannian elements: "Innerhalb dieses Syncytiums ziehen sich vollkommen selbständige Axonen hin, deren Endigungen offenbar mit gesonderten Glattmuskel- und Drüsenzellen verbunden sind".** On this basis Lawrentiew considered unreasonable "zwischen dem Modus der Verteilung und der Endigung der spinalen und autonomen Nervenfasern irgendeinen ausschlaggebenden Unterschied anzunehmen".*** The above statements of Lawrentiew are essentially in accordance with our position except that in our opinion the Schwannian syncytium is often absent, there is no Schwannian membrane on the terminal fibres and nerve endings are but occasionally apparent in the preparations.

On the work of Boeke (1933–51) rests a frequently cited concept of end connections of the vegetative nervous system, called basal plexus. According to this theory, the end connection apparatus of the vegetative nervous system is a plasm-embedded tissue constituted by a net of bundles of neurofibrils and Schwannian nuclei. The plasm accompanies the network along its whole path so that the neurofibrils have no contact whatever with the tissues they innervate. The basal plexus is connected with the periterminal net, which essentially is a plasmatic organ constituted by neurofibrils and interstitial cells located in the effector cells' cytoplasm to conduct impulses arriving through the neurofibrils of the basal plexus to the effector cells, or effector tissues.

Boeke's views on the basal plexus have been adopted and used for the interpretation of results by numerous workers (Szentágothai, Bakay, Temesrékási, Jabonero, Walter, Meyling). In the course of our studies we had, and still often have, the impression that Boeke's concept has some factual basis, thus widening our knowledge in certain fields and in special instances. In fact, in the region of the intestinal tract, in the adventitia of larger vessels, in the throat mucosa of the frog and also elsewhere, nerve pictures have been encountered which support the

* "that sympathetic neurons preserve their independence until reaching closely to the nerve terminals and their axons do not unite with other axons and networks."

** "Inside that syncytium are passing entirely independent axons, whose endings are evidently connected with separate smooth muscle and secretory cells."

*** "to assume any notable difference between the mode of distribution and the terminals of the spinal and autonomic nerve fibres."



FIG. 107. *Columba domestica*. Beak skin. Arrectores plumarum, nerve plexus. (a) Smooth muscle cell; (b) nucleus of smooth muscle cell; (c) thick nerve fibre; (d) thin nerve fibre. Bielschowsky–Gros–Cauna's method. Microscopic magnification 140×, reduced photographically to ½

validity of Boeke's hypothesis, whereas in other cases not even traces of plasmodium or Schwannian cells have been detected (Fig. 107). Furthermore it may well be considered a fact that nerve fibres passing beneath the Schwannian membrane are axons rather than neurofibrils and do not anastomose with each other at all. Taubert (1960), too, has demonstrated that occasionally the Schwannian plasmodium is absent. On the basis of his studies on unstained preparations he wrote as follows: "Es kamen vielmehr feine und feinste Nervenfäserchen in grosser Zahl zu Gesicht, die vollständig frei von einer begleitenden Gliaplasmaformation im

umgebenden Gewebe liegen. Es hat sich niemals mit Sicherheit feststellen lassen, wo und auf welche Weise das Begleitplasmodium sein Ende findet."*

Szentágothai essentially accepted the concept of Boeke (1937–8) and based on secondary degeneration phenomena encountered after nerve transfixions, concluded as follows: "Die Endverzweigungen der postganglionären Fasern bilden innerhalb eines netzartig gebauten Syncytiums Schwannscher Zellen einen Plexus, dessen Nervenelemente individuelle Axonen, d.h. Nervenzellenfortsätze sind."** Therefore, in his opinion, it is definitely false to speak about a diffuse net-like system in context of the vegetative nerves. Later on (1957) he added that ". . . die plexiformen Nervenendformationen aus zwei verschiedenen Elementen, einem netzförmigen Syncytium Schwannscher Zellen (Lemmoblasten) und innerhalb dieser einen Plexus bildender Endverzweigungen verschiedener (sympathischer, parasympathischer und sensibler) Neurone bestehen".***

Simultaneously with this statement he emphasized again that the thread-like elements encountered within the plexiform end formations by silver impregnation are not so much neurofibrils as axons, dividing into end rami within the plasmodium constituted by lemmoblasts. The above statements of Szentágothai are in general right and correlate with Brettschneider's electron microscopic results (1961) except for the fact that the Schwannian cells are certainly independent cells forming no plasmodium.

Jabonero (1953–61) treated relatively frequently within a short period the problem of the vegetative nervous system and in this context also that of end formations. His relevant statements were mainly theoretical considerations, altered several times with the increasing number of the regions examined (vacuoles, neurosecretion, distal syncytium). A concept of his that has been generally accepted was that most peripheral vegetative paths consist of two territories: one being the preganglionic neuronal, the other the postganglionic, structurally syncytial territory. In the postganglionic territory there are some nerve fibres ending freely in end bulbs (eye, adrenal), and others whose end apparatuses constitute the so-called distal syncytium. The latter is a plasmatic system constituted by fibres, nuclei and interstitial cells, independent of, and genetically unrelated to, the postganglionic fibres. Postganglionic fibres end on, or in, the distal syncytium and conduct nerve impulses to it which initiates a process resulting in the production of stimulus conducting substances. These substances initiate the reactive processes taking place in the cytoplasm of the effector organs. According to Jabonero, the distal syncytium is actually a synapsis of distant activity (*Synapse auf Distanz*).

* "It were rather the fine and finest nerve fibrils that became apparent, lying in the surrounding tissue entirely free of an accompanying glia-plasma-formation. In no case could it be stated with certainty, where and how the accompanying plasmodium would terminate."

** "The end branching of postganglionic fibres constitutes, inside a net-like syncytium of Schwannian cells, a plexus whose elements are individual axons, that is, nerve cell processes."

*** ". . . plexiform nerve end formations consist of two different elements, a net-like syncytium of Schwannian cells (lemmoblasts) and inside it the plexus-forming branchings of different (sympathetic, parasympathetic and sensory) neurons."



FIG. 108. *Columba domestica*. Beak skin. Arrectores plumarum. Nerve plexus. (a) Smooth muscle cell; (b) nucleus of smooth muscle cell; (c) thick nerve fibre; (d) thin nerve fibre; (e) nerve bundle; (f) nerve ending. Bielschowsky–Gros–Cauna's method. Microscopic magnification 640×, reduced photographically to ½

The observations of Jabonero on the end connections are partly right and partly unfeasible. In fact, a part of the vegetative paths is of a neuronal structure; also, on a part of the postganglionic fibres end formations are visible, while not on the others. Also, it is true that nerve endings located in the smooth muscle fibres of the eye and adrenal medullary substance, particularly in the former, are readily impregnable by any up-to-date silver impregnation technique. The theory of Jabonero on the so-called distal synapses is, however, thoroughly unfeasible. According to our observations, such synapses do not exist at all. In our opinion,

this concept of Jabonero stems from a misinterpretation of the actual conditions. We found that after their exit from the plexus, the delicate vegetative terminal fibres became thinner and thinner, and passing on, or between, the smooth muscle cells terminated freely without forming any kind of end structure (Fig. 108). This end formation undoubtedly differs from the termination of nerve fibres found in the eye and adrenal medulla which in our opinion is not a peculiarity considering the identical conditions found with striated muscle fibres in vertebrates of the group Anamnia. In fishes, frogs and tailed amphibia, nerve fibres accompany the striated muscle fibres over a long distance attaching closely to their sarcolemma, then they become thinner and disappear, without forming any special terminal structure.

According to Meyling (1953–5), the effector organs contain stainable and impregnable end nets which are, however, in no direct continuity with postganglionic fibres. He claims that peripheral nerve nets consist of mutually anastomosing interstitial cells, extending many processes which are in a synaptic conjugation with the postganglionic fibres. The interstitial cells exhibit tigroid granulation and neurofibrillation, and in their complexity render the peripheral end-net capable of independent function. The postganglionic fibres synapse with the interstitial cells through end formations which conduct as well as receive stimuli. The net of simultaneously functioning interstitial cells responds not only to impulses conducted through the postganglionary fibres, but also to the physical and chemical composition of hormones and adjacent tissue fluids, which regulate, after the reception of local stimuli, the function of the associated tissues. Furthermore, it produces certain substances (neurosecretion) which are then transferred to the associated tissues. It requires neither special competence nor extensive experience to categorize Meyling's concept of the peripheral nerve net as a product of the realm of fantasy, devoid of all morphological basis. We repeat again what has been mentioned previously in this context that, according to our own experience, cells called interstitial cells and attributed with the structure and function of nerve cells by Meyling are actually anastomosing connective tissue cells with processes devoid of any special role in the reception as well as conduction of stimuli.

The peripheral anastomoses, another concept of Meyling, should also be discussed in this place. He carried his generalization so far as to consider even the nerve fibres running in the Auerbach plexus as anastomosing. Instead of discussing the absurdity of this in detail, let us refer to Fig. 109 which would convince any objective observer that there are no such anastomoses whatever between the nerve fibres constituting the Auerbach plexus.

Temesrékásy (1955, 1956, 1959) considered the basal plexus of Boeke the apparatus of transmission in the smooth muscle tissue, noting that "Zwischen den glatten Muskelfasern befindet sich in allen Tierarten und auch im menschlichen Material ein dreidimensionales, aus Schwannschen Zellen bestehendes Syncytium, das mehrere (4–12) feinste Nervenfäserchen enthält".* The fibres pass alongside

* "In all animal species and also in man, between the smooth muscle cells there is a three-dimensional syncytium composed of Schwannian cells, containing several (4–12) delicate nerve fibrils."



FIG. 109. *Emys orbicularis*. Jejunum. Plexus myentericus. (a) Nerve cell; (b) nerve cell process; (c) nerve fibre; (d) nerve trunk; (e) nerve fibre plexus. Microphotography

or across each other but never anastomose, remaining independent throughout as evidenced by normal nerve pictures as well as by those representing secondary degeneration phenomena brought about by nerve transfixion (Lawrentjew, 1931, 1934; Schimmert (Szentágothai), 1936–37; Lawrentjew and Borowskaja, 1936; Bullón and Stiefel, 1935; Temesrékási 1955, 1959). Also Temesrékási denies the existence of Stöhr's terminal reticulum: "Das Schwannsche Syncytium wird von einzelnen ausserordentlich feinen Nervenfäserchen verlassen, die einen besonderen typischen, geraden Verlauf haben."* Some end fibres have ring-shaped terminals. According to Knoche (1959–60), the terminal formation of the vegetative nervous system consists of a plexus of independent nerve fibres and neurofibrils in which no end structures are demonstrable by any of the impregnation or staining methods presently available. Nerve fibres and neurofibrils are lying in a granulous plasma net showing round or oval nuclei but no definite cell borders under the light microscope. In the end fibres there are no vacuoles (Walter, 1957; Taubert, 1960) and there is no morphological basis to attribute secretory function (Jabonero) to the end system. Intermediary cells, much referred to since Cajal's report, are actually Schwannian cells differing from the true ones only by having triangular rather than elongate nuclei. Interstitial cells must not be considered nerve cells as the neurofibrils occasionally present in them are not their own products and no satellite cells are present around the cell bodies. In respect of intermediary cells, essentially the same has been stated also by Taubert (1960), who wrote: "In meinem Material konnte ich ausserhalb der 'nervösen Strombahn' (Feyrter, 1952) in keinem Falle irgendeinen Zelltyp nachweisen, in dem ich auf Grund auch nur einer einzigen morphologischen Besonderheit ein zu nervöser Leistung befähigtes Element sehen möchte."**

The newer experimental studies of Knoche (1961) performed on smooth muscle tissue of the cat's nictitating membrane and reflecting, in our opinion, the true conditions in every respect, have led him to the following conclusion: "Im Gegensatz zu Stöhrs (1957) und Reisers (1959) deskriptiven Untersuchungen einer syncytialen Bauweise des vegetativen Nervensystems, zeigen, die morphologisch-experimentellen Resultate dessen neurale Gliederung auf".***

Electron microscopic studies by Brettschneider (1959) of the intestinal innervation of albino rats have been of particular importance in respect of nerve connections of the vegetative nervous system and smooth muscle tissue. The results obtained by these examinations are according to Brettschneider himself "mit den Ergebnissen lichtmikroskopischer Untersuchungen nicht in Einklang gebracht werden, soweit letztere für die präterminale und terminale vegetative Faserstrecke eine endigungslose, netzförmige Verknüpfung (Terminalreticulum) der leitenden Elemente

* "... From the Schwannian syncytium exit individual very delicate nerve fibres showing a typical straight path."

** "In no case except the 'nervöse Strombahn' (Feyter, 1953) was demonstrable in my material any cell type in which, on the basis of some morphological peculiarity, I could have detected even a single element capable of nervous function."

*** "In contrast to the descriptive examinations by Stöhr (1957) and Reiser (1959) of the vegetative nervous system's syncytial architecture, the morphological and experimental results indicate a neural structure thereof."

des vegetativen Nervensystems annehmen".* Brettschneider found that the vegetative nervous system's end fibres run independently of each other in the form of thin bundles to the end organs, viz. in the case of the intestines, or intestinal villi, to the epithelial cells and conjugate with them. This kind of conjugation is a true synapsis, showing clearly the presynaptic and postsynaptic membranes and the intersynaptic space between them under the electron microscope. Brettschneider explained: "Niemals wird eine plasmatische Kontinuität mit anderen Gewebselementen festgestellt".** In addition, special importance may be attached to the following statement of Brettschneider: "Das Leitgewebe ist ein Verband einzelner Zellindividuen. Syncytien und echte Netze sind nicht zu sehen."***

In our view (1936, 1938), the vegetative nervous system's terminal formation consists of independently descending fibres, arranged in end buttons, yet not showing formations to be considered as end apparatuses in most of the cases. In the course of our studies we attached little importance to Schwannian plasmodium, Schwannian nuclei as well as the often discussed interstitial cells. The reason for this was that Schwannian nuclei are often absent and the intermediary cells have been considered by us simple connective tissue cells. This concept of ours is essentially consistent with that of Lawrentiew. The relevant paper of ours was published independently of Lawrentiew in No. 5, Vol. 23 (1936) of the *Zeitschrift für Zellforschung und mikr. Anatomie*, that is in the same periodical in which Lawrentiew and Borowskaja published their similar report. I stated: "Nach meiner Überzeugung enden sowohl die Fasern des Vagus und des Sympathicus als die Fortsätze der Ganglienzellen auch in dem Darmkanal der höheren Wirbeltiere alle einzeln, doch kennen wir diese Endigungen nicht, da unsere Instrumente und Methoden stets versagen, sobald wir die intime Verbindung des Nervensystems und der Erfolgsorgane näher kennenlernen wollen."† We did not change our views when, based on the examination of end connection between intestinal muscles and nerve system in the intestinal tract of Gastropodes (1940), using impregnation method and 5 μ thick serial sections, we derived the following conclusion: "Mein endgültiger Standpunkt in dieser Frage ist aber, dass die Verbindung zwischen dem Nerven- und Muskelsystem von einem feinen, nur bei stärkster Vergrösserung sichtbaren Geflecht hergestellt wird, in dem aber wirkliche Netze und Endigungen nicht nachgewiesen werden können".†† "Das Stöhr–Reisersche Terminalreticulum ist

*"... not to be correlated with the results obtained by light microscopy, inasmuch as the latter was suggestive of a terminal-free net-like conjunction (terminal reticulum) of the vegetative nervous system's main elements for the preterminal and terminal vegetative fibre path."

**"In no case was a plasmatic continuity demonstrable with other tissue elements."

***"The conduction tissue is an association of individual cells. Syncytia and true nets are not visible."

† "In my conviction, both vagal and symphatetic fibres as well as processes of ganglial cells end independently also in the intestinal tract of higher vertebrates, yet their endings are unknown as our instruments and methods have consistently failed when aimed to approach more closely the intimate connection between the nervous system and effector organs."

†† "My final position in this question is, however, that the connection between the nervous and muscle system is brought about by a delicate plexus seen only at highest magnification and evidently lacking true nets and terminals."

auch hier bloss ein feines Geflecht, in welchem die Selbständigkeit der kontinuierlichen Elemente immer sicher erkennbar ist."* We interpreted the nerve connections of the smooth muscle in a similar way during our examinations of the reptile lung (1941): "Meiner Ansicht nach kommen wir der Wahrheit am nächsten, wenn wir sagen, dass das glatte Muskelgewebe ausserordentlich feine und reichhaltige Geflechte enthält, von denen einzelne Fasern zur Oberfläche der glatten Muskelzellen laufen und sich nach ihrem Eintreffen der Zelloberfläche eng anschmiegen."**

In our study on the general structure of the vegetative nervous system (1956) we wrote the following about the end connections: "Im Sinne meiner Untersuchungen, die sich—mit Ausnahme der Tunicaten—auf alle Stämme des Tierreiches erstrecken, bilden die Endfasern des vegetativen Nervensystems überall Endgeflechte, in denen die Selbständigkeit der einzelnen Fasern erhalten bleibt und diese oft auch nachweisbar frei endigen. Am Ende des Nervenfasersystems gibt es kein Reticulum. Das reizübertragende System ist in jedem Falle ein Geflecht (Plexus) und nicht ein Netz (Reticulum, bzw. Terminalreticulum)."***

Concerning the terminal formation of peripheral vegetative paths, our position has been unchanged in that we still state that nerve fibres constituting the bundles, plexuses and end plexuses, remain independent and the terminal fibres end freely in the tissues without the interconnection of interstitial cells.

As to the nerve connections present in the tunica media, the following conclusions were drawn by Woollard (1926) on the basis of examinations with methylene blue: "This muscular plexus is composed of the finest non-medullated nerves". "They ramify through all the layers of the muscular coat and in the aorta they form a deep and superficial plexus in the tunica media. This intramuscular plexus is a real net: that is to say the fibres divide and rejoin and divide again, so that the whole is continuous throughout the length of the vessels, thus offering the possibility of conduction in all directions. From the individual strand in the net tiny side branches are given off and these end in small swellings after an extremely short course." As to the location of endings, Woollard noted that "these terminals are always pericellular and not intracellular". Lapinsky has been of a similar opinion, noting that he never saw intraplasmic endings. Anyway, in this respect many conflicting opinions have been formed. The majority of workers state that nerve endings are localized on the muscle cells' surfaces, while others have asserted that they terminate in the cytoplasm, i.e. the nucleus, of muscle cells.

* "Here, too, the terminal reticulum of Stöhr and Reiser is but a delicate plexus in which the independency of the continual elements is always distinctly recognizable."

** "In my opinion, the closest approach to truth is to say that the smooth muscle tissue contains extraordinarily delicate and rich plexuses from which go single fibres to the surfaces of smooth muscle cells and associate with them closely once arrived."

***"In the sense of my studies embracing except for Tunicates all strains of the animal kingdom, end fibres of the vegetative nervous system form everywhere terminal networks whose single fibre constituents preserve their independence and are often seen to end freely. There is no reticulum at the termination of the nerve fibre system. In every case, the stimulus-conducting system is a network (plexus) and not a net (reticulum, i.e. terminal reticulum)."

In his description of nerve endings in the smooth muscle tissue, Woollard mentions certain "large branching" cells found by him both in large and small vessels. Sometimes these cells were associated with axons, sometimes they again appeared to be independent of them. Woollard noted that the cells extended processes which "entwine with the axis cylinder". The particularity of this phenomenon was that "these structures persist after denervation by removal of the sympathetic trunk". Similar cells were described and drawn from the rabbit's ear by Eugling who also noted that "they persist after denervation of the vessels. They do not resemble nerve cells morphologically and one cannot make out Nissl granules in them." In this sense it may be well postulated that these cells, although controlled by nerves, are actually not nerve cells having no continuity with the nerve fibres.

Based on examinations with methylene blue on specimens from frog, guinea-pig, rabbit and man, Busch (1929) stated that nerve fibres located in the vessel walls may be classified into two morphological groups. One group is formed by fibres terminating freely. Most of them are myelinated, occur only in larger vessels and even there only in the adventitia. In no case were such fibres detected in deeper layers. Functionally they are sensory fibres. Fibres forming the other group are in every case unmyelinated. They are characterized by "the formation of peripheral nerve-nets and whose finest ramifications seem to end in a closed net of neurofibrils which is probably placed extracellularly between the individual muscle-cells, touching these opposite their nuclei".

Millen (1949), too, supported the presence of endings, as shown by his description of the fine plexuses found in the media of small arteries: "Exceedingly fine branches of this plexus can be traced: some appear to end freely in the tunica media, while others show knob-like ending in close relation to the nuclei of the smooth muscle cells." Further to this, Millen reported "a short segment of a very beaded fibre can be seen approaching the nucleus as a series of moniliform expansions almost at right angles to it and one knob lies just above the nucleus".

A survey of the data cited above inevitably raises the question whether the nerve system connects with the tunica media by a "terminal reticulum" or by free nerve endings. Below we state our position as derived from our examinations carried out with various modifications of the Bielschowsky method.

Fibres exiting from the interlamellary network form a plexus on the surface of the media. This sends thin branches into the media to constitute a plexus. The latter formation was in every case found to be a true plexus rather than a reticulum.

The fibres of that plexus are all readily followed and seem to have endings. I am afraid of not being cautious enough in using the term "ending" as in most cases not one but several knobs, spheres or buttons are seen on the fibres. Although in all probability the endmost structures actually constitute the ending, it is probable that they are smaller varices rather than true endings. Nevertheless, in view of the fact that various kinds of nerve endings have been demonstrable with the methods applied by us, there seems to be little reason to give up the existence of nerve endings right in the vascular area. If these are the actual endings, then we are bound to accept that fibres from plexuses in the tunica media end freely

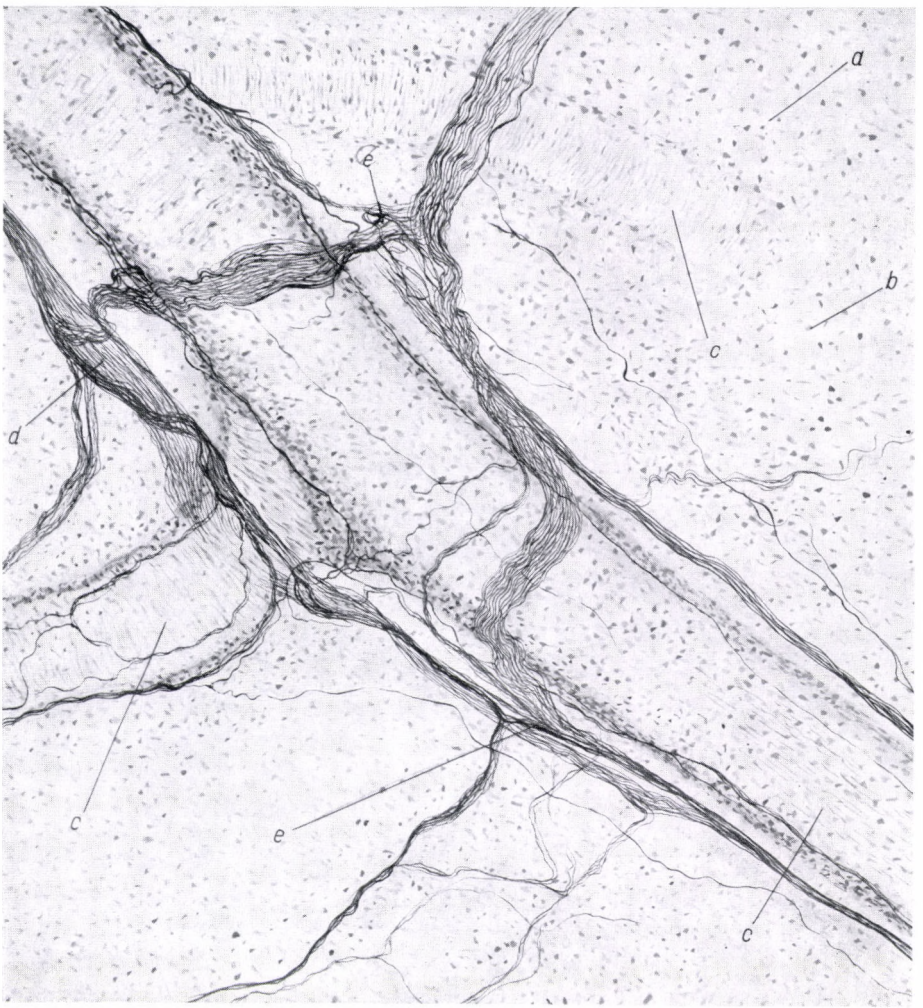

FIG. 110. *Meleagris gallopavo*. Septum narium; mucous membrane, nerve fibre plexus along the arteries. (a) Connective tissue; (b) nucleus of the connective tissue cell; (c) artery; (d) nerve bundle; (e) nerve fibre plexus. Bielschowsky–Gros' method. Microscopic magnification 640×, reduced photographically to ½

on, or between, the smooth muscle fibres. The conclusion derived from examinations with methylene blue, i.e. that nerve fibres would also enter the smooth muscle cells' cytoplasm, does not seem to be convincing as in my opinion vital staining with methylene blue is unsuitable for refined neurohistological examinations. My own observations suggest that nerve fibres in the tunica media end on, or between, the muscle cells.

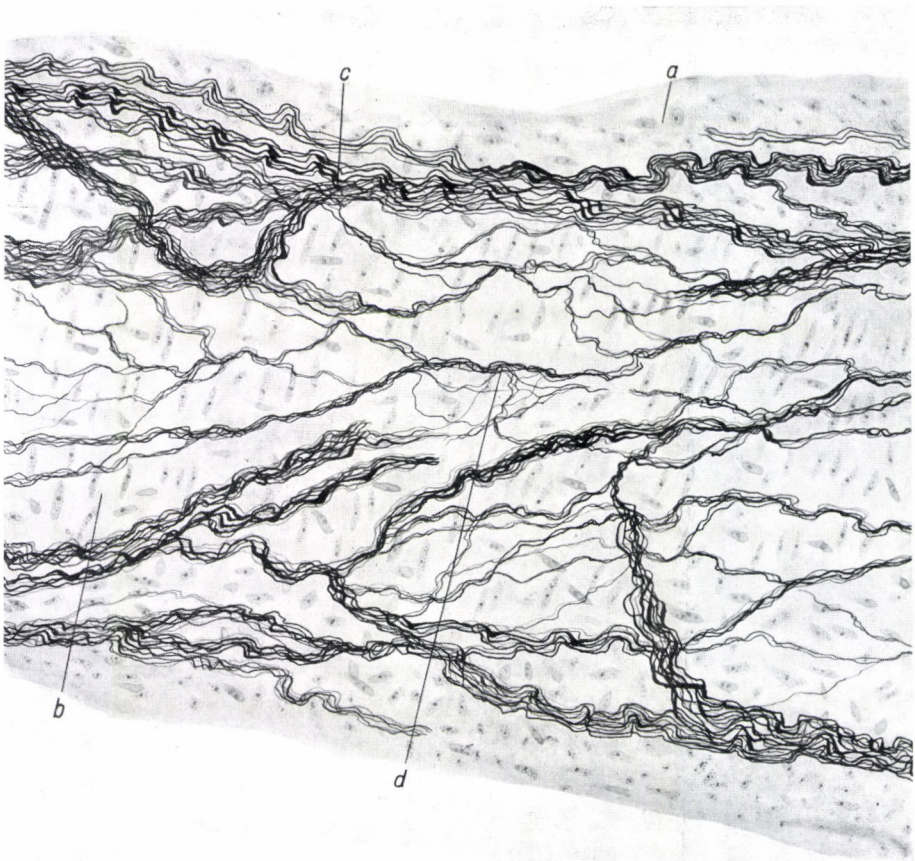

FIG. 111. *Canis familiaris*. Heart; artery in the left atrium. (a) Tunica adventitia; (b) tunica media; (c) nerve plexus in the adventitia; (d) nerve plexus in the media. Jabonero's method. Microscopic magnification 300×, reduced photographically to ½

Tunica Adventitia

After having given a historical and critical survey of the relevant literary data on the nerve-end connections of arteries, we describe below, based mainly on our own experience, the distribution of nerve elements in the histological layers of the arteries as well as the connections demonstrable between the tissue layers constituting the vessel wall and the vascular nerve supply. First we discuss the nerve connections in the tunica adventitia, secondly the innervation of the tunica media and thirdly that of the tunica intima.

The nerve trunks supplying the arteries arrive partly from segmentally and partly from longitudinally descending nerve plexuses. In the periarterial connective tissue, rich in fat cells and vessels, they are arranged in major trunks. From these trunks, consisting mainly of smooth, undulating fibres, exit bundles of varying

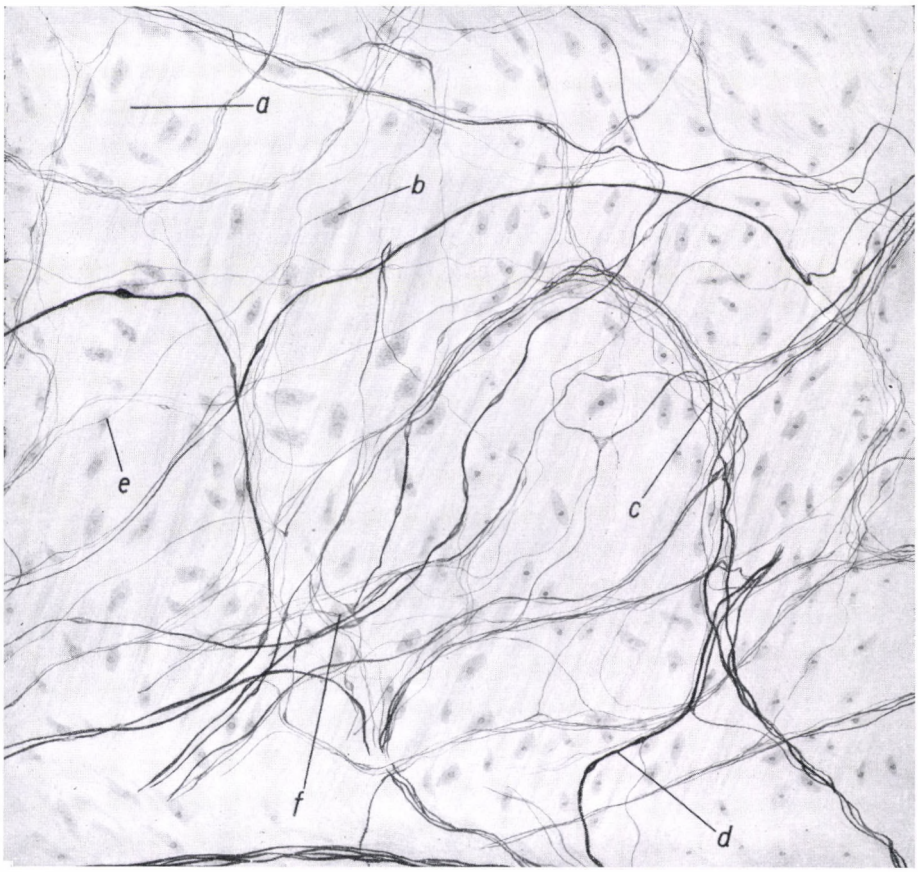

FIG. 112. *Gallus domesticus*. Carotis cerebralis; nerve plexus in the adventitia. (a) Connective tissue bundle; (b) nucleus of connective tissue cell; (c) nerve bundle; (d) thick nerve fibre; (e) thin nerve fibre; (f) nerve fibre plexus. Bielschowsky–Ábrahám's method. Microscopic magnification 600×, reduced photographically to ½

dimensions in a parallel direction (Fig. 110). The bundles, some of which are located at right angles to the adventitia, and some of which give off thin branches, associate with each other in the middle part of the adventitia to form a plexus. This is the outer adventitial plexus, which is markedly rich in some portions of the aorta, in the intracardial arteries and particularly in the basilar artery. Most of the fibres constituting the plexus are smooth-edged and uniform in thickness. Their appearance is suggestive of their sympathetic origin in certain areas. Beside the thin fibres, there are sometimes also present thick ones of particular morphology, branching off near to, or even on, the media. On the basis of their appearance and dendritic branchings we have considered these fibres the sensory elements of the adventitia (Fig. 111).

A large part of the nerve fibres exiting from the outer adventitial plexuses go towards the media to form a second plexus immediately at the border between the two layers. Occasionally, the plexus nature of this network is very conspicuous. It is constituted mainly of thin fibres of sympathetic appearance. Yet sometimes also here, thick fibres of evidently sensory nature are seen. This network is the second adventitial plexus, called interlamellary plexus by Busch (Fig. 112).

The two adventitial plexuses show marked differences not only according to the kind of artery and age, but also under certain pathological conditions. The principle is, however, the same in any case. Therefore, we omit the description of the minor differences encountered in the individual groups, resp. some special arteries. The cardiac, renal and cerebral vessels, where these differences are most conspicuous, will be discussed separately.

Tunica Media

The neurohistological picture of the tunica media is described below. On its outward surface linked with the adventitia, a loose nerve plexus is clearly apparent in most cases. In some segments of the vessel this may contain also some thick myelinated fibres. The latter are particularly conspicuous in the aortic arch where they are clearly distinguishable from the uniform, smooth, thin, sympathetic fibres, forming often a hair-tress like pattern. An excellent model for the examination of these relations is presented by the dog's aortic arch which, together with the similar organs of other beasts of prey, has been particularly suitable for the study of innervation (Fig. 113). The picture, taken at low magnification, shows bundles constituted by thin, almost neurofibril-like fibres and some thick fibres. The bundles of thin fibres may be followed up over a long distance, the thick ones branch off soon and conjugate with the muscle cells, or with the adventitial margin by particular end structures. Mixed fibres are present only in the reflexogenic areas or, occasionally, in their immediate neighbourhood. In the other arterial segments, the plexus consists almost exclusively of sympathetic fibres, thick ones of apparently cerebrospinal origin being present only in arteries with wide lumens.

In some arteries the tunica media appears to be almost entirely free of nerve fibres. In microscopic specimens only a few fibres were seen to descend between the muscle cells, singly, in pairs or united to smaller rami. In the arteries providing for the blood supply of large areas, however, numerous nerve fibres are running in the media. This was observed in the cerebral arteries, mainly in those supplying the base of the brain in birds, mammals and man (Fig. 114). A well-developed plexus was also detectable in the media of the aortic arch of dogs, cats and badgers, further in the coronary arteries and in the intracardial arteries in the right atrium of the pig (Fig. 115).

In the aortic arch of the cat, delicate plexuses occur mainly around the small arteries and capillaries. In these plexuses there are some varicose, delicately fibrillar thick fibres and some hardly visible thin ones, carrying small varices.

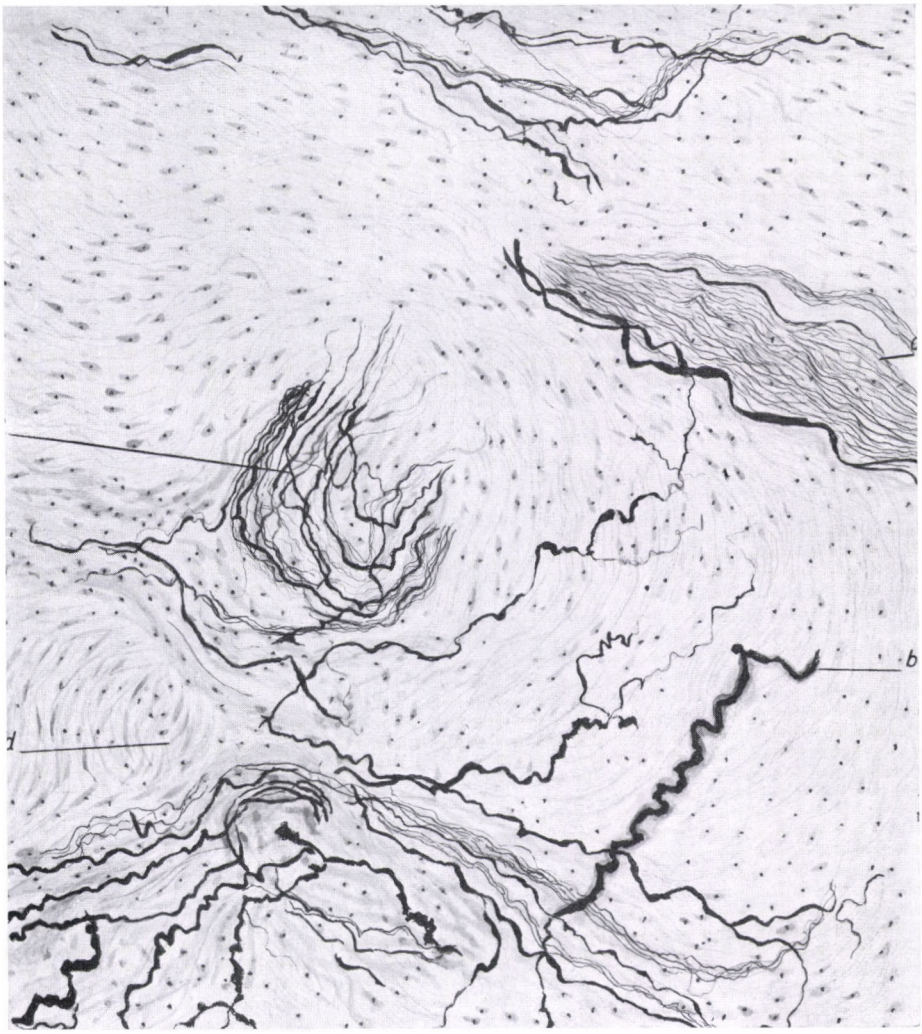

FIG. 113. *Canis familiaris*. Aortic arch. (a) Sympathetic fibres; (b) myelinated fibres; (c) mixed nerve fibre plexus; (d) smooth muscle tissue. Bielschowsky–Gros' method. Microscopic magnification 600×, reduced photographically to ½

The latter fibres run adjacent to, or beneath or above, each other, become gradually thinner and disappear between the smooth muscle cells without showing any particular terminal structure. The perivascular plexuses of the cat are so rich that at first sight they seem to justify Stöhr's concept that each muscle cell of the media is controlled by a separate nerve fibre (or, in our opinion, nerve ending) (Fig. 116). The appearance of these endings was clarified in sections obtained from the aorta

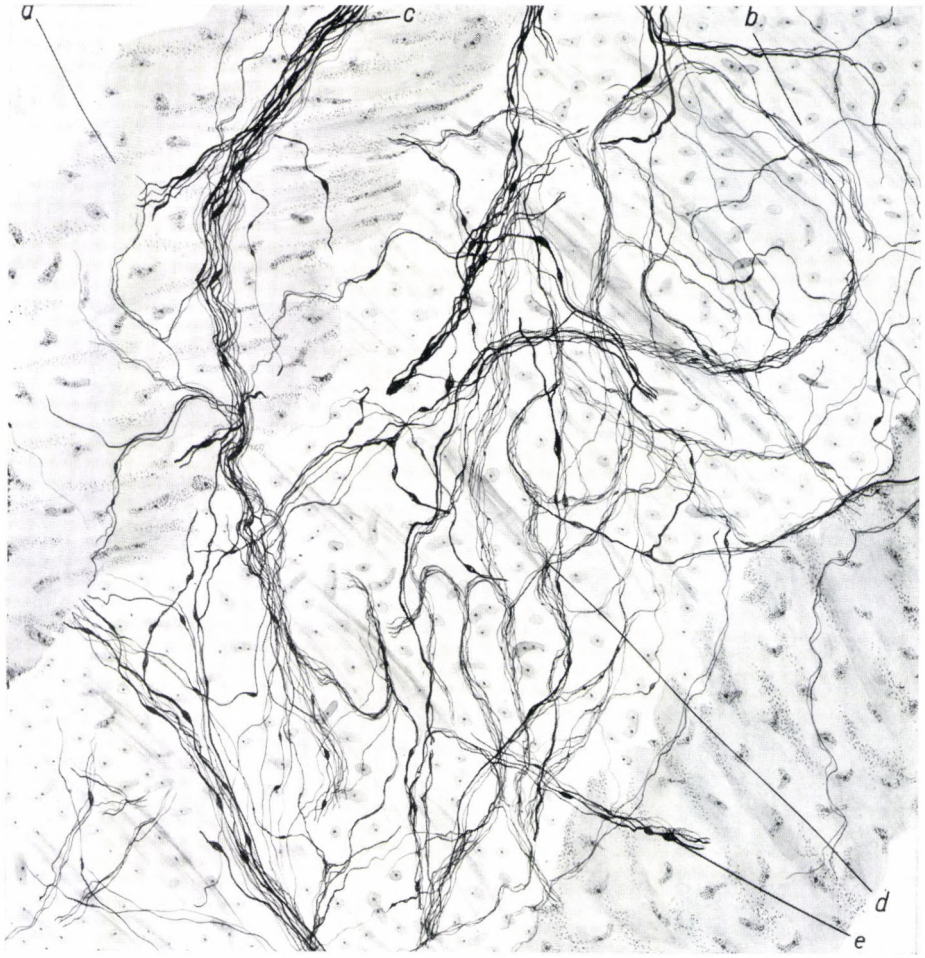

FIG. 114. *Gallus domesticus*. Carotis cerebralis; nerve plexus in the adventitia. (a) Tunica adventitia; (b) tunica media; (c) nerve bundle; (d) nerve fibre plexus; (e) varix. Bielschowsky–Ábrahám's method. Microscopic magnification 300×, reduced photographically to ½

of the dog and fox, or the coronaries of the calf. Occasionally, the plexus' fibres narrowed gradually, arranged in coherent drop-like patterns, then gradually disappeared. These pictures gave the impression that the fibres were true end fibres conjugating with the muscle cells at several sites and ending freely. Thus it appears that nerve fibres running in the media terminate in end bulbs resembling intraepithelial nerve endings, clearly defined here and there in rich plexuses. If that be true, it remains to be clarified whether the end bulbs' positions are epilemmal or intracytoplasmic. This is very difficult to decide, our only means for

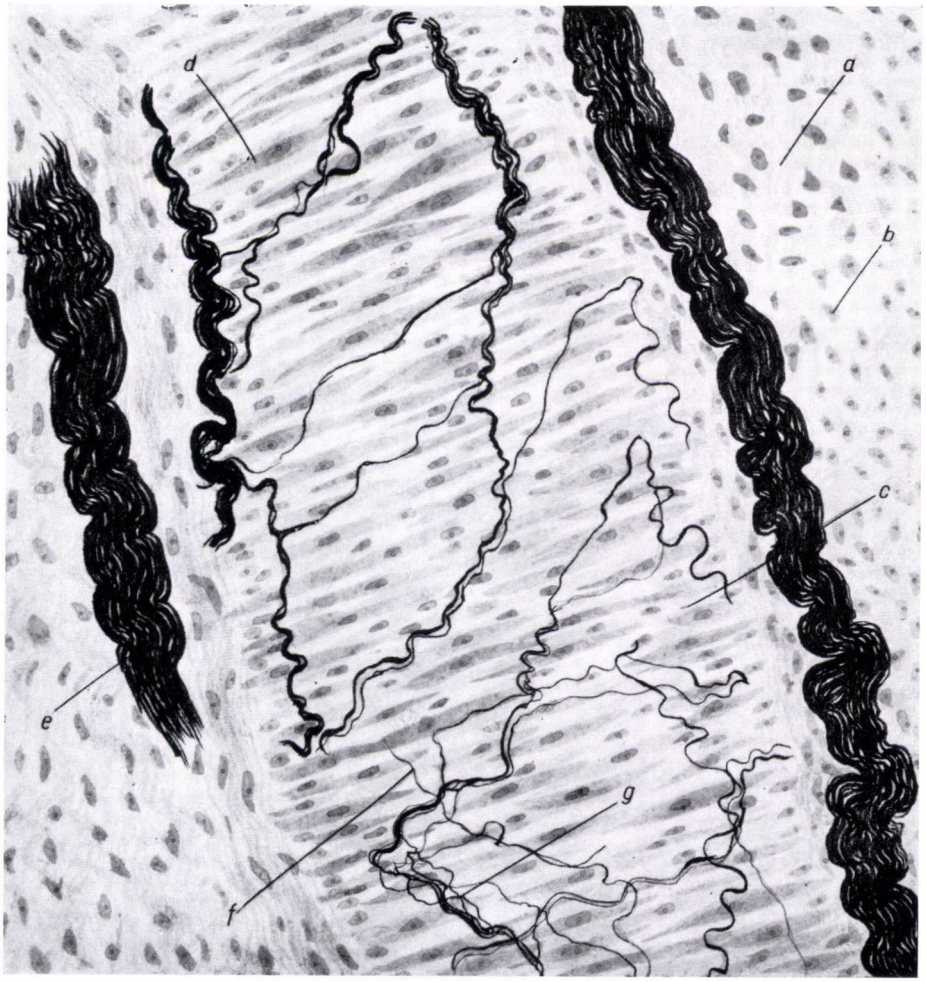

FIG. 115. *Canis familiaris*. Artery in the right atrium; nerve plexus in the media. (a) Connective tissue; (b) nucleus of connective tissue cell; (c) tunica media; (d) smooth muscle fibre; (e) nerve bundle; (f) nerve fibre; (g) nerve fibre plexus. Bielschowsky–Ábrahám's method. Microscopic magnification 400×, reduced photographically to ½

this purpose being the proper adjustment of the micrometer screw. If at a given adjustment of the microscope the end bulb's and the muscle cell's nuclei are seen in one and the same plane, the end bulb's position may be regarded as intracytoplasmic. The pictures examined by us suggested that in the media both epilemmal and intracytoplasmic positions may occur. Terminal reticulum is absent.



FIG. 116. *Felis domestica*. Aortic arch; nerve plexus in the media. (a) Tunica media; (b) capillary; (c) nucleus of smooth muscle cell; (d) nerve bundle; (e) nerve fibre; (f) nerve end plexus. Bielschowsky–Ábrahám's method. Microscopic magnifica- tion 400×, reduced photographically to ½

Tunica Intima

We consistently failed to detect any kind of nerves in the tunica intima of birds, mammals and man alike. Since certain literary reports have been available on the presence of nerve fibres in the intima, we studied this problem with special care. We prepared cross sections in both directions from the walls of the larger arteries and examined them thoroughly after proper impregnation. The results have confirmed our earlier statement that there are no nerve fibres in the intima of the arterial wall.

VEINS (VENAE)

Neurohistologically, the innervation of veins is essentially similar to that of the arteries. This applies particularly to the larger veins where, similarly to the arteries, large nerve trunks run in the adventitia, whose fibres gradually decrease in number, become thinner, finer and undulating while passing inwards. The structure and connection of sympathetic fibres innervating the thin tunica media also resemble those of the arteries. Here, too, Stöhr saw a terminal reticulum and as the pattern seen by him was present in both muscular and muscleless veins, he stated that "das nervöse Terminalreticulum nicht lediglich als ein für die Muskelfasern bestimmten motorischen Endapparat".* "Der Gedanke, jenem Endnetz auch eine trophische Funktion zuzuteilen, liegt nahe, wenn er sich auch schwer beweisen lassen dürfte."** Further to this, Stöhr also stated for the veins what he had stated for arteries, viz. the vessel walls are so richly supplied with nerves that it seems to be feasible "dass wir für jede einzelne Zelle der Gefässwand die Möglichkeit einer Einwirkung des Nervensystems in Rechnung setzen dürfen".*** As to the post capillary veins, Stöhr accepted the concept of Reiser and Yoshitoshi, asserting that there is a continuity between the terminal reticula present inside and out side the vessel wall. Having observed similar phenomena in the interconnections of the innervation of a small vein and the surrounding fat cells, he was inclined to share Wassermann's opinion that the growth of fat cells is, both in embryos and adults, associated with that of vessels. The nervous control of the fat cells' function was demonstrated first by Dogiel and later on also by Boeke. Similar observations were reported also by Kostowieczki, Wilkinson and Burkitt. Millen, too, has found a nervous control of fat tissue, noting that it contains also sensory apparatuses, as observed already by Dogiel. The presence of nerve fibres, sometimes in quite a large number, in the perivascular fat tissue has also been demonstrated in this laboratory. According to our own experience, most nerve fibres occur in the fat tissue present at the outer margin of the adventitia of the aortic arch and around the bifurcation of the pulmonary artery. In general, we found the richest nerve supply in the fat tissue of the chemoreceptor region.

Numerous interesting data have been published on the innervation of larger veins such as the vena cava superior and inferior, vena iliaca, vena renalis and vena portae. Michelazzi found a relatively large ganglion in the periadventitial connective tissue of the pulmonary vein. The presence of sensory end apparatuses in the veins' walls has been also reported in the literature. In the media of the guinea-pig's vena cava, Rachmanow described nervous end arborizations and a Vater–Pacini type end apparatus in the surrounding connective tissue. The same structures were detected by Eich in the portal vein of human newborn.

* ". . . the nervous terminal reticulum must not be regarded as a special motor end apparatus of muscle fibres alone."

** "One is tempted to attribute also a trophic function to the terminal reticulum, which is, however, hard to prove."

*** ". . . to suppose the influence of the nervous system on each muscle cell present in the vessel wall."

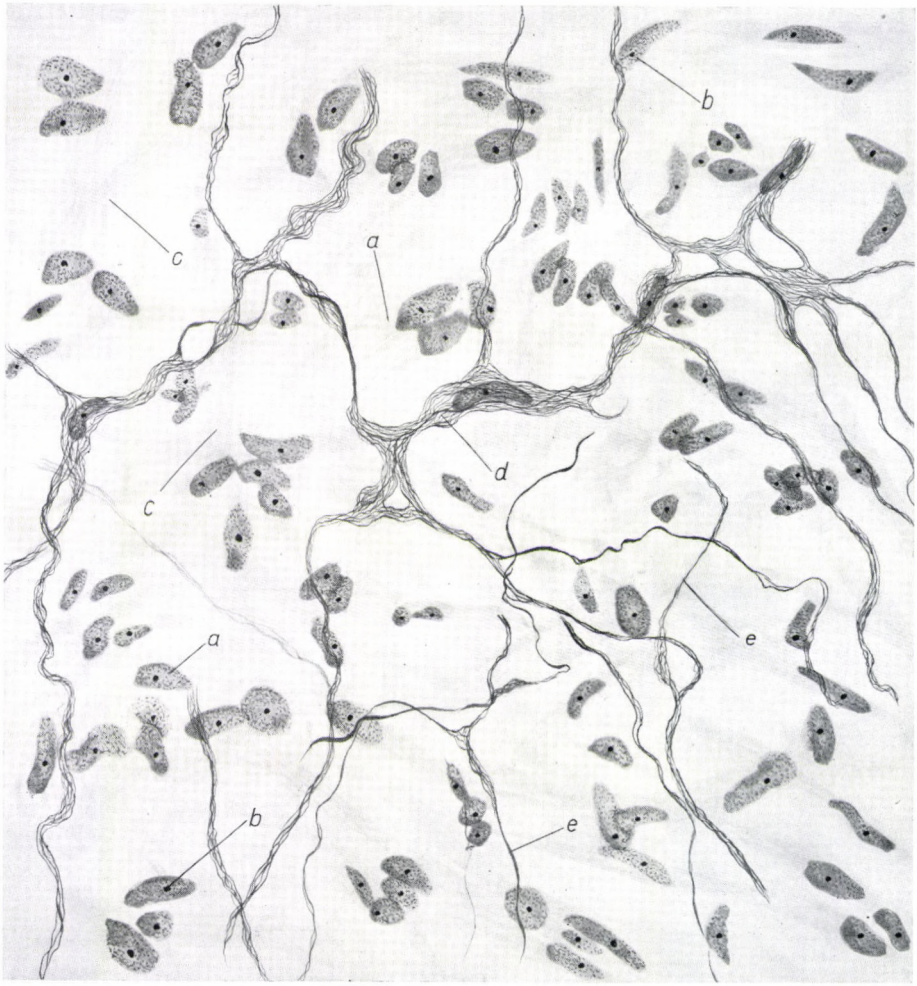

FIG. 117. *Homo.* Vena saphena magna: nerve plexus from the adventitia. (a) Connective tissue cell; (b) nucleus of the connective tissue cell; (c) connective tissue fibre; (d) nerve bundle; (e) nerve fibre. Cauna's method. Microscopic magnification 600×, reduced photographically to ½

From the intima of the uterine veins Keifer described bipolar and tripolar cells which in his opinion were "wirklich nervöser Natur" (truly nervous in nature). This concept was opposed by Stöhr and I am myself of the opinion that these cells are connective tissue cells identical with Woollard's branching cells, whose connective tissue nature has been confirmed—as outlined already in the foregoing—by nerve section experiments.

In this institute, the vena femoralis, vena saphena magna, vena cava superior and vena cordis magna were examined in more detail. The results roughly corre-

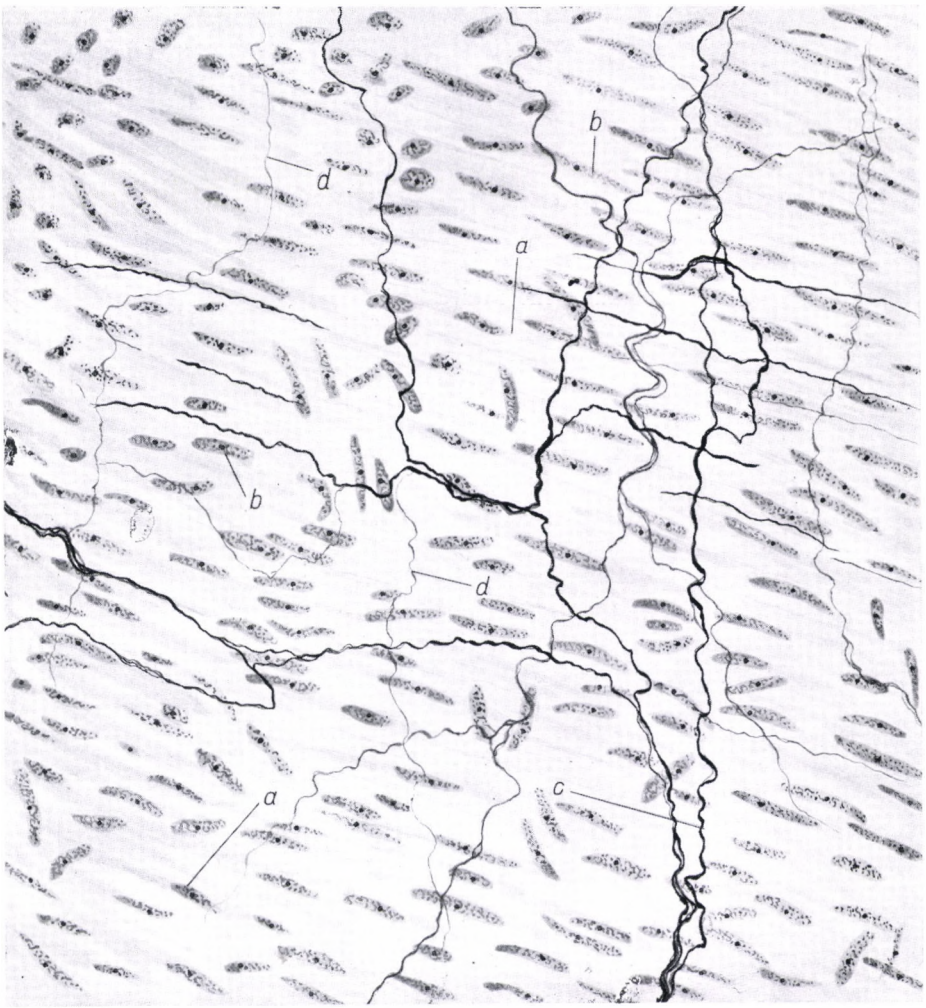

FIG. 118. *Ardea cinerea*. Vena pulmonalis; nerve plexus in the media. (a) Smooth muscle cell; (b) nucleus of the smooth muscle cell; (c) thick nerve fibre; (d) thin nerve fibre. Bielschowsky–Ábrahám's method. Microscopic magnification 600×, reduced photographically to ½

sponded to the general pattern of vascular innervation, as described above. The vena saphena magna, however, deserves separate discussion, being extraordinarily rich in nerve fibres owing to the bulky muscular layer in its wall. Particularly numerous nerve fibres occur in its adventitia. Most of them are myeline-free, sympathetic fibres present in large numbers mainly in the vasa vasorum (Fig. 117). Nerve fibres are numerous on, and along, the vasa vasorum as is seldom seen in any arteries. In general, these fibres are thin, and their paths are easily followed

up separately over a long distance but some of them soon branch off. Beside their appearance their sympathetic origin is also supported by the fact that some of them terminate on a capillary in the form of an end bulb. No sensory endings were found in the adventitia.

The thick muscular layer of the vena saphena magna is richly supplied with nerves. To the muscle bundles are attached loose plexuses whose unmedullated fibres frequently ramify. Individual rami may be followed over a long distance. They become gradually thinner and their delicate end branches terminate on the sharply bordered muscle cells. Some of the terminal fibres form a coil-like structure. There is no terminal reticulum, the tunica intima contains no nerve fibres. The venae cavae (vena cava superior, vena cava inferior), too, are relatively rich in nerve fibres, mainly at their entrance into the heart. As seen in the venae cavae of the calf, the nerve fibres are arranged in larger trunks and bundles passing along the arteries supplying the vein's wall. The trunks and bundles give off rami of varying sizes to supply the muscle tissue at the vein's origin and the neighbouring connective tissue. Of the veins with a muscular wall we examined also the pulmonary vein of birds. In the large material handled, preparations obtained from the pulmonary vein of the common heron (*Ardea cinerea*) proved to be suitable for the study of innervation. They revealed an extraordinarily rich supply of nerve fibres in the pulmonary vein, mainly in its smooth muscle layer. This area was traversed by giant nerve trunks branching richly here and there so that the characteristic smooth muscle tissue is, so to speak, flooded over by nerve fibres (Fig. 118). The nerve fibres are undulating and no Schwann-type nuclei are apparent.

In the pulmonary vein beside the rich plexuses, larger loose ones are also seen from which exit large numbers of single fibres, as a rule smooth-edged, uniform in diameter over a long portion and easily followed over a long distance. In general, it may be stated that in higher vertebrates there are but few regions where the interconnections of smooth muscle and nervous system would be so clearly apparent as in the pulmonary vein of birds. Here it is clearly seen that end fibres form neither plexuses nor terminal reticula. Each fibre descends independently and also conjugates independently with the muscle fibre's surface.

ARTERIOVENOUS ANASTOMOSES

The innervation of arteriovenous anastomoses has been extensively studied. Masson described a rich innervation in the arteriovenous anastomosis of the human finger. In similar structures of the dog's tongue, Brown saw unmedullated fibres in the media and myelinated fibres in the adventitia, the latter branching richly to the connective tissue. Nerve endings of the Vater–Pacini type were seen near arteriovenous anastomoses by Grosser, Schumacher and Clara.

We examined the nerve connections of arteriovenous anastomoses in the loop-vessels. In our hands, the sheep's sclera, processed by the method of Bielschowsky–Ábrahám, proved to be best for this purpose. Along both the artery and the vein

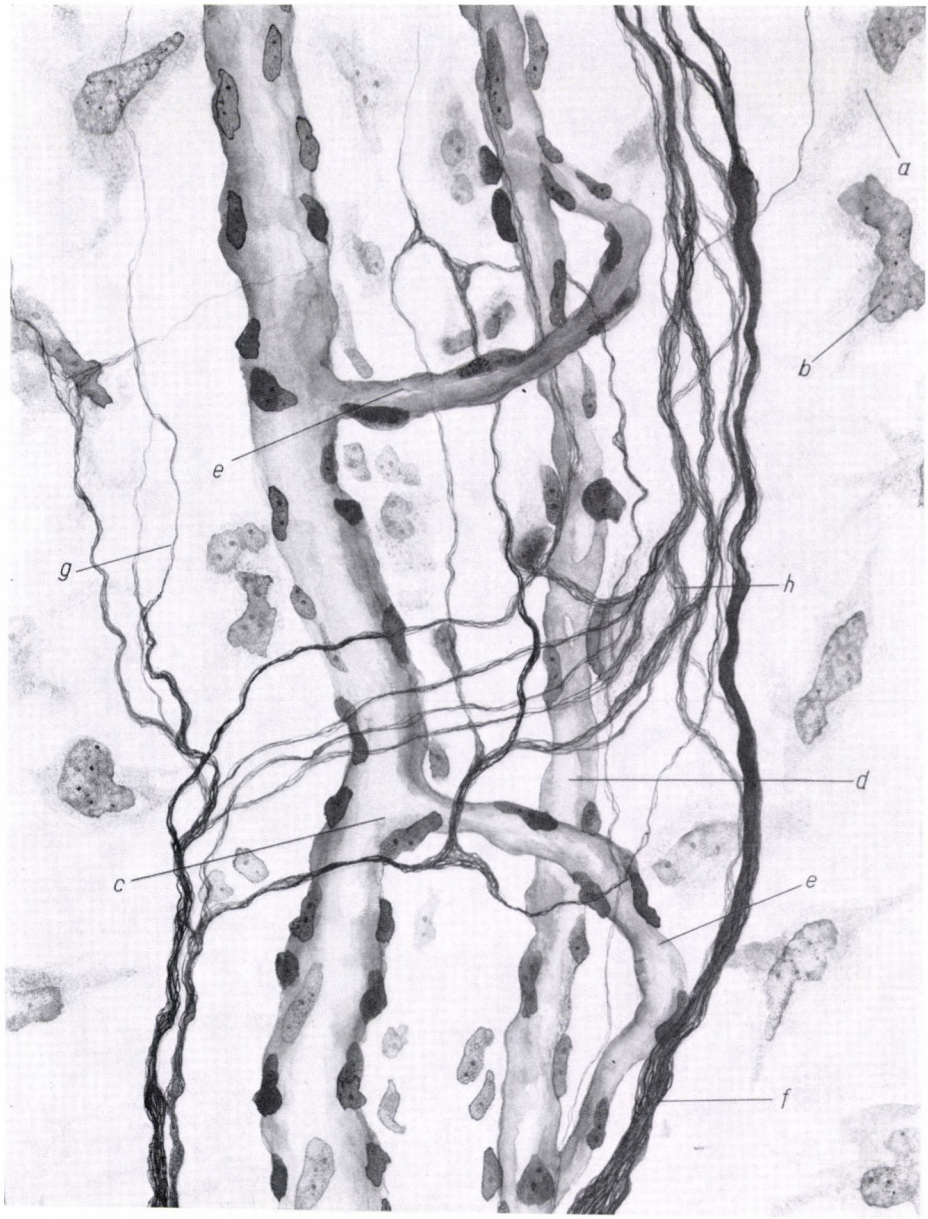

FIG. 119. *Ovis aries.* Loops of the vessels in the sclero-corneal junction; innervation. (a) Connective tissue cell; (b) nucleus of connective tissue cell; (c) artery; (d) vein; (e) linking branch; (f) nerve bundle; (g) nerve fibre; (h) nerve plexus. Bielschowsky–Gros' method. Microscopic magnification 600×, reduced photographically to ½

passed thick nerve trunks constituted by many fibres some of which were smooth and undulating, suggesting a sympathetic nature. Smaller nerve bundles exiting from these trunks passed along the conjugating vessels (anastomosis), forming a manifold interconnection between the two nerve trunks. The whole nerve picture, markedly richer than those seen in the region of any particular artery or vein, indicated a more intensive nervous control of arteriovenous anastomoses than of the arteries and veins themselves (Fig. 119, Plate I/b, p. 48).

CAPILLARIES (CAPILLARES)

Demonstration of the interconnection between capillary walls and nervous system constitutes one of the most difficult tasks of neurohistology. The fact that most capillaries are accompanied and traversed by delicate thin nerve fibres has long been known. The first investigators concerned with the innervation of capillaries (His, 1863; Ciaccio, 1864; Tomas, 1869; Klein, 1870; Beale, 1872; Meyer, 1880; Grünhagen, 1883; Gad, 1895; Siehler, 1901; Joris, 1906; Michailow, 1908; Glaser, 1914) considered the nerve fibres, descending alternately along both sides of capillaries, responsible for capillary innervation. This may be approximately true as the repeated conjugation would account by itself for the transmission of nervous impulses. It is, however, not unfeasible to suppose that this periodic conjugation is inadequate to conduct the rapid and intensive impulses required for abrupt alterations of the capillaries' lumens, sometimes over quite a large area. Therefore, further investigations were conducted giving rise to the concept that the nerve fibres in question are only accompanying fibres of the capillaries, and there are also some other fibres associated closely with the vessel walls. This was supported by the results of Nesterowsky (1875), Krimke (1884), Botezat (1908) and perhaps still more evidently by those of Bremer (1882) and Ceccherelli (1904).

Later on, the problem was investigated by Barbsdale and Woollard but, according to Stöhr, with little success. Better results were obtained by Ohno, Gerneck, Clark and Don, de Castro, Schadabasch, Akkeringa, Wilkinson, Hinsey, Lawrentiew, Zwaifach and Sunder-Plassmann who published pictures offering a feasible explanation for the rapid simultaneous onset of nervous effects over a large area.

Stöhr, who advocated the nerve end connective function of terminal reticulum in the capillary region also, commented as follows: "Das gleiche nervöse Terminalreticulum, das glatte Muskelfasern, Drüsen- und Bindegewebszellen mit seinen zarten Waben umklammert, zieht auch die Kapillarwand in seinen Bereich".* This opinion of Stöhr was opposed by Michelis and Nonidez who stated the argentophilic fibre nature of "terminal reticulum". Neither did Busch, Woollard and Millen see any terminal reticulum on the capillaries.

The author of this volume failed to detect on the capillaries any kind of terminal reticulum or cytoplasmic conjugation described by Boeke, between pericytes and

* "The same nervous terminal reticulum that intertwines the muscle fibres, gland and connective tissue cells with its delicate fibres, extends also to the capillary wall."



FIG. 120. *Rana ridibunda*. Stomach; pars pylorica; capillary innervation in the tunica muscularis. (a) Smooth muscle cell; (b) nucleus of smooth muscle cell; (c) capillary; (d) nucleus of the endothelial cell; (e) nerve bundle; (f) nerve fibre. Bielschowsky–Gros' method. Microscopic magnification 640×, reduced photographically to ½

capillary endothelial cells in several hundreds of preparations obtained by various silver impregnation techniques. Our examinations indicated a definite nervous control of the capillaries' walls supplied partly by the accompanying fibres, partly by the closely associated loose plexuses. Free endings, as described earlier particularly by workers using Golgi's method, or observed after vital staining with methylene blue, were never apparent in our preparations.

In certain portions of the vessels, especially in the outer adventitial layer, the capillaries are accompanied by thick sympathetic trunks giving off small lateral

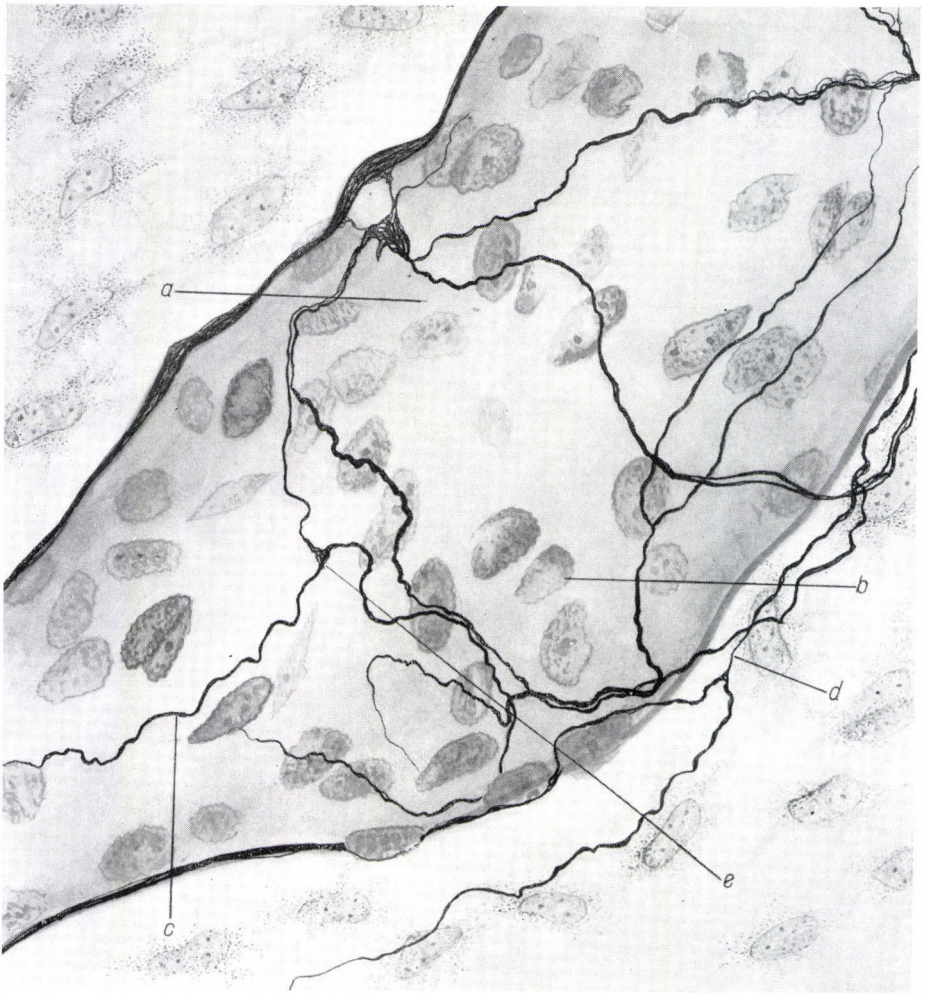

FIG. 121. *Homo.* Arteria coronarius cordis; capillary innervation. (a) Endothelium; (b) nucleus of endothelial cell; (c) nerve fibre; (d) accompanying fibre; (e) point of junction. Bielschowsky–Gros' method. Microscopic magnification 900×, reduced photographically to ½

branches to the adjacent plexus of capillaries. These branches are particularly strong in the cat's aortic arch whose vessels are, according to our experience, under the most pronounced sympathetic control.

Along the capillaries there are frequently seen nerve fibres which do not follow strictly the vessel's path but pass away from it, then return here and there, wind, and conjugate with the endothelium over variable distances. These fibres, known as accompanying fibres and described also by Stöhr, are well visible in the intestinal submucosa, arterial adventitia, myocardium, palatine mucosa of frogs, and also

elsewhere. They appear in a particularly beautiful pattern in the aortic arch and coronary arteries, especially in the calf.

In the coronary arteries, beside the accompanying fibres there are also numerous other fibres serving obviously for the innervation of the capillary wall (Fig. 121). As shown in Fig. 121, the latter fibres form two systems. Part of them descend parallel to the vessel wall, part of them traverse the empty areas in all directions. They are undulating, here and there fibrillar and in some places seem to divide to form a neurofibrillar network. No endings are apparent, yet it is possible that certain fibres end on, or inside, the endothelial cells. In this context we wish to emphasize again that problems of terminations are difficult to clarify with the available method. It is, however, certain that the capillaries are under a marked nervous control which accounts for the abrupt alterations of their lumens.

NERVE CELLS IN THE VESSEL WALLS

The problem whether or not nerve cells are present in the vessel walls has been investigated for a long time. The relevant literary data are incoherent and often controversial. In a paper Stöhr commented as follows: "Im Laufe vieler Jahre habe ich nur ein einziges Mal in der Adventitia einer Arterie aus dem Plexus choroideus eine sehr kleine Ganglienzelle gesehen und abgebildet".* According to Glaser (1931), nerve cells occur only in the arteries supplying the large cavities of the body. Stöhr commented that there may be nerve cells in those areas but not so much in the adventitia as in the periadventitial connective tissue. This statement of Stöhr is correct in general. In the connective tissue bordering the larger arteries and veins, nerve cells and ganglia are actually often present. I observed it myself, mainly in my studies on the innervation of coronary and cerebral vessels. I should like to note, nevertheless, that nerve cells and well-developed ganglia are also present in the adventitia. In this context I refer to a contemporary publication of mine, stating that the cells described by Bethe as multipolar nerve cells from the vessels supplying the palatine mucosa of the frog are not nerve cells at all and that nerve cells do not occur in that localization in other organs either (Ábrahám, 1938, 1940).

Nerve cells and ganglia are fairly frequently seen in the coronary arteries and veins. But one should be careful in judging their positions, as the bulk of them is localized in the plexuses of the periarterial connective tissue rather than in the vessel wall itself. Very well-developed ganglia occur in large masses in the wall of the coronary sinus of man and animals.

Ganglion cells and ganglia occur besides the coronary vessels also in the aorta. I detected a large ganglion at the exit of the coronary artery from the aorta. The cells constituting the ganglion were Dogiel type 1 cells, surrounded by pericytes in a capsule-like fashion.

* "On only one occasion over a period of many years had I seen and drawn a very small ganglion cell in the adventitia of an artery from the chorioid plexus."

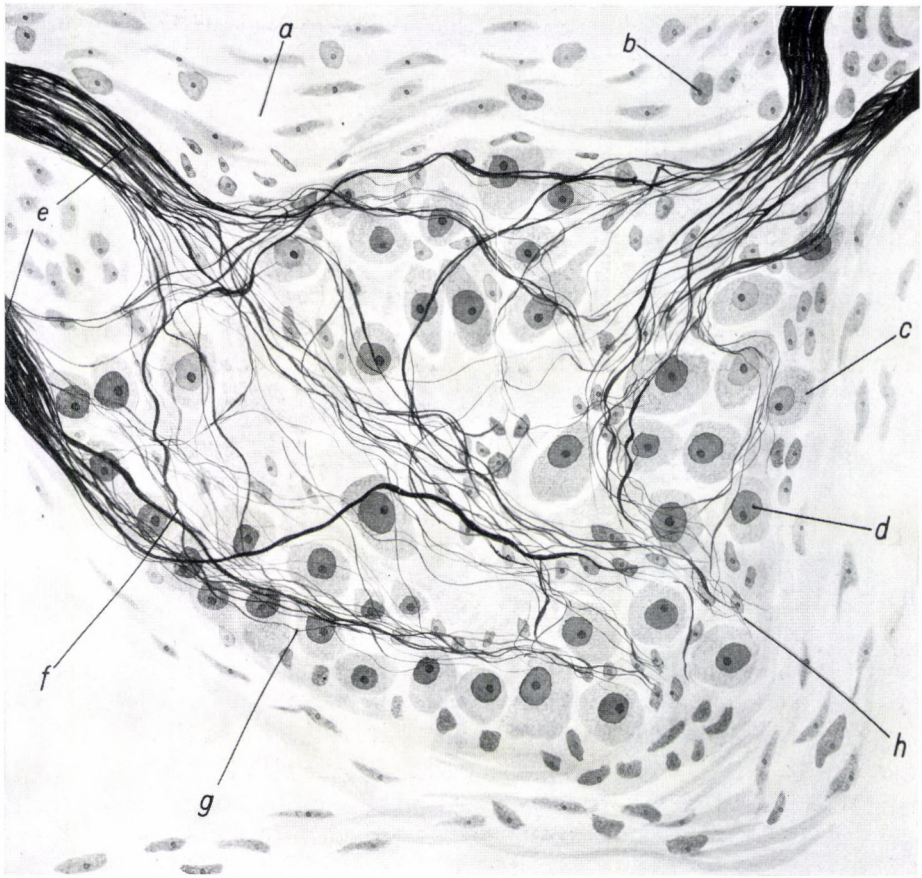

FIG. 122. *Gallus domesticus*. Ganglion in the wall of arteria carotis cerebralis. (a) Connective tissue; (b) nucleus of connective tissue cell; (c) nerve cell; (d) nucleus of nerve cell; (e) nerve bundle; (f) thick nerve fibre; (g) thin nerve fibre; (h) nerve fibre plexus. Bielschowsky–Ábrahám's method. Microscopic magnification 600×, reduced photographically to ½

I saw a ganglion also in the adventitia of the cat's aortic arch. The ganglial cells had eccentric, round nuclei and their processes resisted impregnation. Ganglia were seen also in the adventitia of the cerebral carotid artery of birds. They were large and occurred in a relatively large number along the vessel's descents (Fig. 122).

RECEPTORS IN THE VESSEL WALLS

Neurohistological studies prompted by certain results of experimental physiology have often revealed the presence of receptors (as well as effectors) in the vessel walls. As receptors are regarded the thicker nerve fibres passing in the adventitia and branching off in a tree-like fashion, especially in some more sensitive

vascular segments, forming plexuses here and there. Such plexuses are particularly rich in the aortic arch and carotid sinus, where they contain also thick myelinated fibres. In addition, plexuses of receptor nature occur in the coronary arteries, renal artery and cerebral vessels. As judged by their structure and position, the dendritically branching thick fibres, beaded here and there, seen in these plexuses are the receptors of the vessel wall. Obviously, they are the organs of pain sensation or may be even the sensory apparatuses of vascular reflexes. Beside these fibre systems constituting the general sensory elements of the vessel wall, there are also some special receptors occurring only in certain vascular segments and constituting the sensory apparatus of vital reflexes.

In general, two special receptor systems are known. One of them serves to signal changes of luminal size caused by pressure on the vessel wall. They are called pressure receptors (presso-receptors, baroreceptors, stretch receptors). Receptors belonging to the other system receive chemical stimuli (chemoreceptors). Since the receptors belonging to the two systems differ both structurally and in their positions, they are discussed separately below, first the pressoreceptors and secondly the chemoreceptors.

Pressoreceptors

In the cardiovascular system of higher vertebrates the pressoreceptors form two particularly sensitive reflexogenic zones, one in the wall of the aortic arch and another in the wall of the carotid sinus. Both consist of a system of richly branching thick fibres whose terminal rami attach by larger neurofibrillar end plates to the wall of vascular segments. A third reflexogenic zone is constituted by a system detected by the author of this volume in the pulmonary artery. References to this zone have been lacking in the available literature. The reflexogenic zones are described below in the sequence of aortic arch, carotid sinus and pulmonary artery.

Aortic Arch (Arcus aortae)

The aortic arch has been the earliest known receptor assembly of the vascular system. Firm experimental evidence has been presented that these receptors inhibit by reflectory action the elevation of blood pressure and heart rate. Closer studies of receptors and their connections were performed on the aortic arch of birds, dog, pig, calf, buffalo, goat, sheep and man. The results are described below.

Birds (Aves)

The vascular innervation of birds was studied on the following avian species: chicken (*Gallus domesticus*), turkey (*Meleagris gallopavo*), goose (*Anser domesticus*), duck (*Anas domestica*), whooper swan (*Cygnus olor*), hen harrier (*Circus cyaneus*), screech-owl (*Strix flammea*). In accordance with the nearly uniform histological structure of the vessels of these avian species, no notable

differences were found in their vascular innervation either. For this reason, in the foregoing chapter the vascular nerve supply of birds was discussed together with that of mammals. Roughly the same applies to the depressor nerve; since, however, this nerve is making its first well visible and easily accessible appearance in the birds it should be discussed separately from the formation of a similar structure and function in mammals. In this context it should be noted that in our hands, impregnation of the depressor nerve was successful only in the arterial trunks of the chicken (*Gallus domesticus*). In the other areas all attempts have failed. This must not be interpreted as a law or specific feature being due most probably to more fortunate conditions of impregnation in that particular case. The reason of the frequent failures rests with the fact that we actually had no footing as to the localization and appearance of depressor fibres. This is emphasized because Nonidez (1935) traced the terminal structures and connections of depressor fibres in serial sections from day-old chicks.

Nonidez detected the ending site of the depressor nerve in the aorta, at the exit of the arterial trunk. In this area he described nerve fibres and capsulated nerve endings with round cells. He considered them end structures of the depressor nerve and gave the tunica intima as their location.

As far as we are informed, since the studies by Nonidez nobody has dealt with the avian depressor system in adult birds, thus we are in no position to correlate with other data the observations made by us on the shape and descent of fibres, structure and connection of endings, as described below.

As we have seen on the preparations obtained from the artery-stems of the cock, fibres of the depressor nerve are thick, undulating and varying in diameter and cross section pattern. They enter the wall of the aortic arch in larger bundles accompanied by thin, smooth sympathetic fibres, pass on parallel for a while, then gradually separate and, either singly or accompanied by very thin sympathetic fibres, run a long winding path in the middle layer of the adventitia. Their descents show special thickenings, plate-like extensions, very thin side branchings and, in general, branch systems of medium richness. Terminal rami of the side branchings and of the ramifications of the main fibre's end branching are uniformly irregularly beaded and terminate in well-visible, sharply bordered plates. The end plates are dense, showing circular, elliptic or distinctly triangular shape (Fig. 123). Neither end fibres nor end plates anastomose. The end plates are sharply bordered against the elements of the host tissue. In every case, these endings are localized in the tunica adventitia, either close to the tunica media or, exceptionally, actually in the media itself. I believe that the endings described by Nonidez from day-old chicks as "capsulated nerve end bodies" and believed by him to be end structures of the depressor nerve, are actually paraganglia or, according to the recent terminology, chemoreceptors. We, too, found such structures in the arterial system of birds. We shall revert to them in a later chapter.

It should be noted that fibre and end systems similar to those described above occur also in the wall of the arterial trunk. This implies that depressor fibres are found not only in the aortic wall but also elsewhere, since unlike the situation in mammals, they do not form a coherent receptor area in birds (Fig. 124).

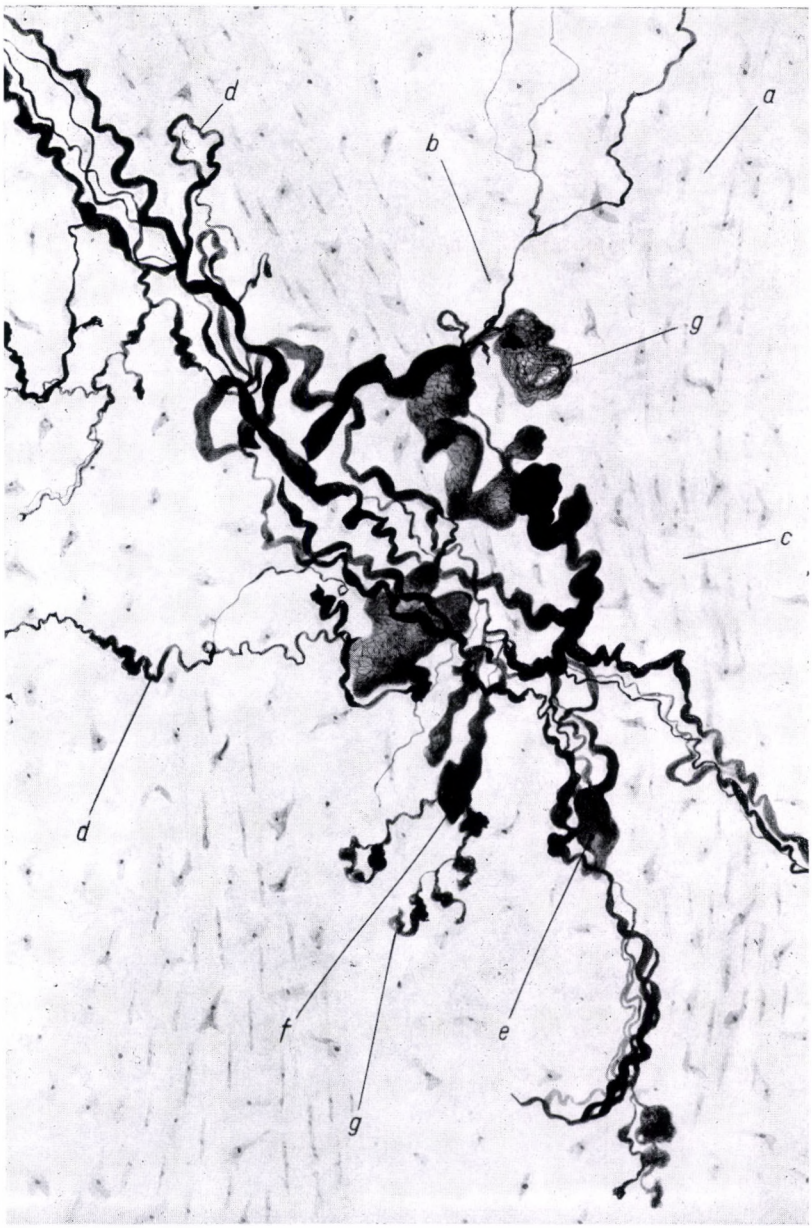

FIG. 123. *Gallus domesticus*. Aortic arch; pressoreceptors in the adventitia. (a) Connective tissue bundle; (b) nucleus of connective tissue cell; (c) smooth muscle tissue; (d) nerve fibre; (e) varix; (f) intermediary plate; (g) end plate. Bielschowsky–Ábrahám's method. Microscopic magnification 600×, reduced photographically to ½

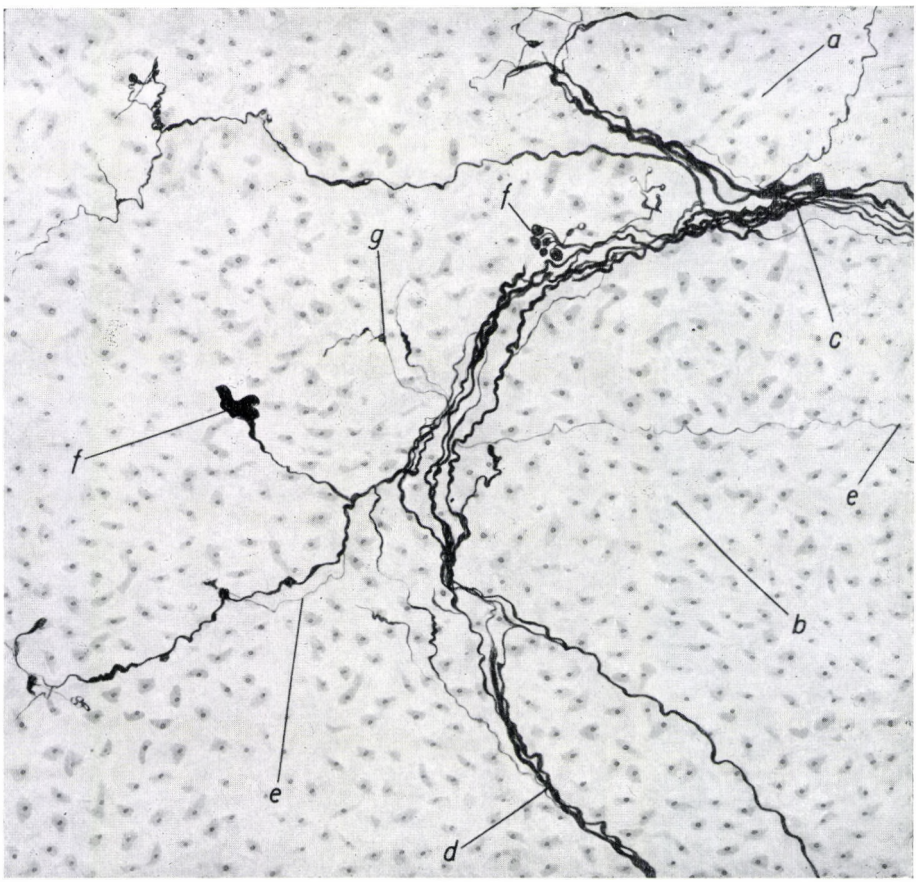

FIG. 124. *Gallus domesticus*. Arteria anonyma dextra; pressoreceptors in the adventitia. (a) Connective tissue; (b) nucleus of connective tissue cell; (c) nerve bundle; (d) thick nerve fibre; (e) thin nerve fibre; (f) nerve end plate; (g) varix. Bielschowsky–Ábrahám's method. Microscopic magnification 600×, reduced photographically to ½

Mammals (Mammalia)

In mammals, pressoreceptors of the aortic region show a marked similarity in origin, descent, structure and connections. As to their origin, in general all depressor fibres arise in the vagus, as a rule not in the vagal trunk itself but in some larger branch, mostly in the nervus laryngeus superior. The vagal depressor fibres pass to the aortic wall within the common vago-sympathetic sheath and together with sympathetic fibres they form a plexus on the wall. Only in the rabbit were depressor fibres seen to descend outside the vago-sympathetic sheath, in the form of two separate nerves (nervus depressor, nervus aorticus), one going to the anterior, the other to the posterior part of the aortic wall. In all mammals, depres-

sor fibres are thick myelinated fibres carrying large varices and special membrane-like extensions. The types of connections are in general uniform. In the majority of cases the endings are large neuofibrillar end plates conjugating with the adventitial tissue directly without the interference of any special tissue element.

Dog (*Canis familiaris*)

After their exit from the common vago-sympathetic sheath, bundles of the aortic nerve go to the aortic wall after subdivision in smaller bundles which pass on along the adventitial margin. As a rule, the fibre bundles are accompanied by sympathetic bundles constituted by thin, smooth, undulating fibres running closely to each other without branching. Beside these hair-tresslike bundles there are many others within which aortic fibres are passing in variable numbers. Thus aortic fibres enter the aortic wall either in the form of closed aortic bundles or of sympathetic trunks.

Fibres constituting the aortic bundles are thick, sometimes to an extent which even appears to be pathological. This is, however, obviously not the case as the same features were seen in each dog, this being particularly characteristic of the aortic fibres in that animal.

Aortic fibres leaving the bundles pass on singly or in pairs; on nearing the inner margin of the adventitia they begin to branch off. The individual, fibres show a rich ramification. Fibres of the side rami and trunks are varicose, forming here and there enormous beads. Ramification becomes more extensive towards the ends of the fibres and these terminal rami are closely intertwined with those of the adjacent fibre systems. Nevertheless, in adequately impregnated preparations the end systems belonging to the different fibres are well distinguishable from each other.

A typical feature of aortic nerves is that, unlike nerve fibres of other nature, the narrowed fibres may thicken over quite a long distance and this phenomenon is seen repeatedly along their path. Another typical feature is that some thick fibres abruptly subdivide into two, three or more branches which subdivide again after a shorter or longer path. On all kinds of aortic nerve fibres there are large varices, sometimes forming a mosaic-like pattern from pieces of varying sizes. In some varices the neurofibrils are sharply apparent, whereas in other cases only dense varices are seen along the fibre's whole descent. Not infrequently the markedly fibrillar and thickened fibre pieces are linked with each other only by a neurofibril-like delicate fibre. This phenomenon is not seen in other parts of the nervous system, being apparently related to the special position and role of aortic nerve fibres. The same applies to the rich branchings and to the morphology and structure of nerve endings.

Aortic fibres are characterized by the appearance of intermediate neurofibrillar plates and endings in their path. Intermediate neurofibrillar plates arise by the fibre's regional subdivision into neurofibrils not far from its termination. In the peripheral nervous system, similar structures are seen only in the path of fibres

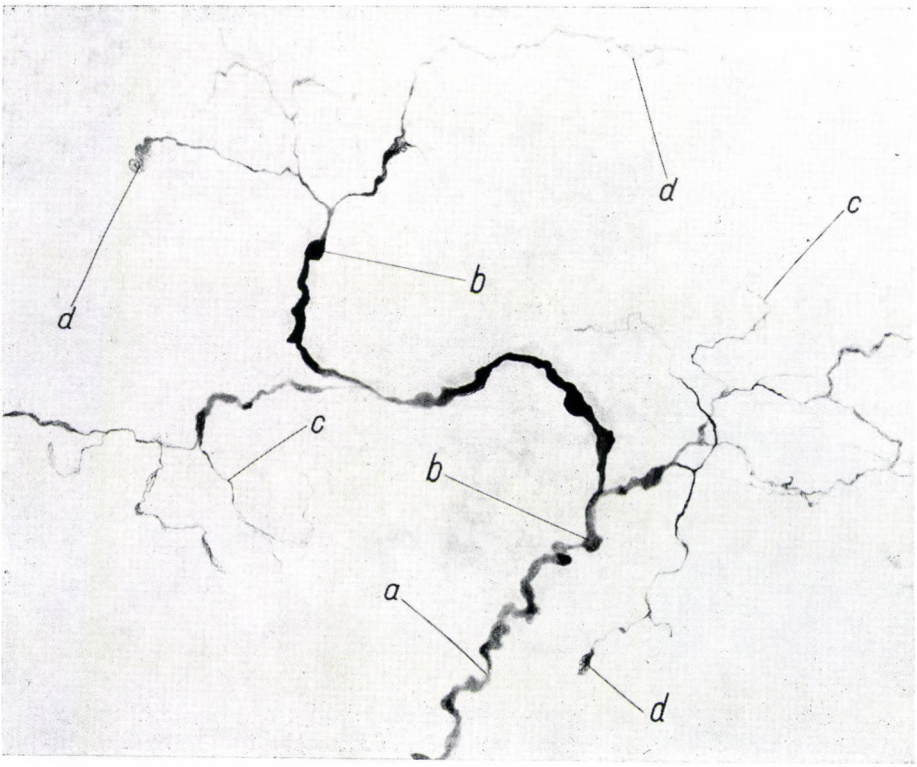

FIG. 125. *Canis familiaris*. Arcus aortae; system of pressoreceptors in the adventitia. (a) Axon; (b) varix; (c) terminal fibre; (d) neurofibrillar end plate. Bielschowsky–Ábrahám's method. Microscopic magnification 900×, reduced photographically to ½

originating in the sinus nerve. In the intermediary plates the neurofibrils separate from each other, arrange loosely, then unite again. Very likely this structure enhances the fibre's sensitivity.

The appearance of the nerve endings varies widely. Sometimes they subdivide into thin, smooth end fibres covering a long distance and disappearing near the outer margin of the media after having formed several loop-like structures, or terminated in small end bulbs. In the majority of the cases, however, the situation is different as many fibres fall asunder in numerous thin constituent fibres, impregnable as a whole only in thick sections. The thin fibres cover a long distance without notable varix formation and terminate in large end plates of ivy-leaf shape (Fig. 125). In most cases these plates are dense and homogeneous, but many of them appeared to be constituted partly, or entirely, by neurofibrils. Occasionally the latter form a network, viz. plexus. The number of end plates is particularly large. In thin sections they are seen to form large assemblies in the termination field of some smaller aortic bundles. Not infrequently, nerve pictures from the

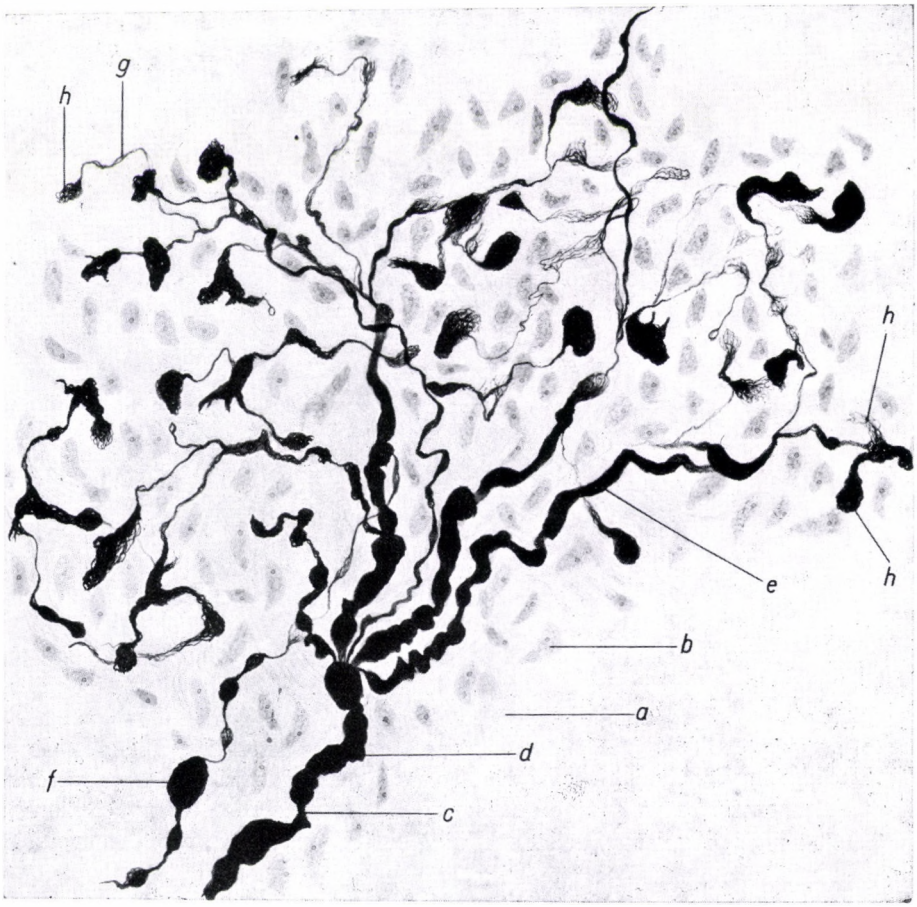

FIG. 126. *Canis familiaris*. Arcus aortae; nerve end plates in the adventitia. (a) Connective tissue bundle; (b) nucleus of connective tissue cell; (c) axon; (d) main branch; (e) lateral branch; (f) varix; (g) terminal fibre; (h) end plate. Bielschowsky–Gros' method. Microscopic magnification 800×, reduced photographically to ½

anterior surface of the aorta show enormous assemblies of endings, some of them allowing for a precise study of special connections and end formations.

Some of the endings are elongate lamella-like structures with loosened neurofibrils, others show fimbriated margins. The large number of endings of various morphology and the arrangement of aortic terminal fibre systems in relatively small areas account for the extraordinary sensitivity of this portion of the aortic arch as well as for the special inhibitory role played by the aortic nerve in the control of blood pressure, i.e. in the inhibition of pressure elevation.

To identify the precise structure of the fibres' endings, I examined them in well-impregnated preparations under very high magnification. These studies

revealed that, except for some dissimilar structures, most end plates are constituted by delicate neurofibrillar reticula whose structure is clearly seen also under the highest magnification (Fig. 126). Naturally, to obtain such pictures requires great technical skill not only in impregnation but also in the preparation of sections. Therefore, preparation of sections according to a predetermined scheme is of great importance. It should be considered prior to freezing that the aortic fibres are passing in the adventitia and the end plates attach flatly to the inner surface of the adventitia (or the outer surface of the media). Therefore, prior to sectioning the aortic arch should be cut longitudinally in two parts and, if required, frozen flat on the microtome's object support by means of a filter paper or some brain pulp allowing complete spreading and smoothing. This permits sections to be cut parallel with the surface. Also, care should be taken to keep intact the sections containing the adventitial portion directly adjacent to the media, since, as suggested also by the nerve's function, this part of the vessel comprises the nerve endings. In case a comprehensive picture is required of the fibres' descents, branchings and endings, thicker sections should be prepared, as otherwise their relations and connections escape observation. If all these aspects are considered and if adequate techniques are available for the correct performance of staining and impregnation, the pictures obtained will allow a closer study of not only the fibre branching, but also the end plates' structures.

At the innermost margin of the adventitia, the end plates abut the media thus strategically situated to register the smallest change of blood pressure. Naturally, sensitivity is the higher the larger the number of end plates which, owing to their dense location, convert the inner margin of the adventitia into a neurofibrillar veil. The histological finding that, owing to the stratified location of fibre systems, the endings constitute two or more such neurofibrillar veils, offers an explanation for the aortic nerve's regulatory role depending on its capacity to perceive even the slightest pressure exerted on the vessel wall.

Pig (*Sus scrofa domestica*)

Before going into details about innervation, we describe the histological structure of the aortic wall as our studies of depressors have shown that the aortic structure of the various mammals may be dissimilar in dependence of their way of life and ecological relations. Differences have been encountered in the structure of adventitia and media, the amount, descent and grouping of elastic fibres, thickness of the intima and structure and appearance of the endothelium.

The pig's aorta is characterized by the extreme thinness of the adventitia or even by its absence. This is surprising but a still more surprising phenomenon is the presence of a well-developed adventitial plate at the site where fibres from the aortic nerve enter the vessel wall. Apart from this the vessel wall exhibits the usual stratified structure. In the media, smooth muscle lamellae regularly alternate with elastic lamellae. These lamellae are numerous and the media is thick and strong. The intima is easily distinguishable from the media and has no typical

features except perhaps that the endothelial cells are very flat and the cell borders are vague.

Aortic fibres, accompanied by thin sympathetic fibres, enter the aortic wall in the region of the connective tissue lamella described above. This area is small but large enough to receive all branches of the aortic system together with a part of the endings. It extends on the aorta's anterior surface beneath the origin of the left subclavian artery, in the form of a relatively narrow strip descending to the vessel's concave side. This small, poorly circumscribed area was traced by cutting the whole arterial portion between the brachicephalic and the left subclavian arteries into small pieces which were then cut further by freezing microtome. Care was taken that all pieces should be sectioned. The sections were then impregnated. Thus, examinations of many carefully processed aortic arch specimens revealed that depressor fibres accumulate, and also end, in the narrow area described above.

Depressor fibres are myelin-sheathed. In every case, the myelin sheath is sharply conspicuous, homogeneous and extraordinarily thick. Its thickness constitutes one of the typical features of the pig's depressor fibres. This phenomenon is so conspicuous that viewing of a single fibre is conclusive of its origin from the pig's aortic arch. I have examined the depressor fibres of nearly all available mammals but in none of them have I found such a *especially* thick myelin sheath as in the aortic arch of the pig. Here and there this impression is still more intensified by the fact that large masses of neurilemmal nuclei are seen to attach closely to the myelin sheath. The thick fibres are occasionally accompanied by bundles of fine sympathetic fibres of varying thickness. In such cases the sympathetic fibres seem to wind around the neurilemma making in certain cases the impression that the thin sympathetic bundles would serve for the innervation of the neurilemma. Sometimes in the thick myelin sheath rings are seen of well-visible reticular structure which, as judged by their position and structure, appear to correspond to the larger rings of Golgi's funnel.

In the specific region of the adventitia, the thick myelinated fibres and unmedullated thin fibres pass for a while together before diverging and conjugating with the wall of the media in accordance with their natures and positions. Of the two kinds of fibres we may now consider the structure of the thick depressor type.

The descent and branching of the depressor fibres are typical for the pig. As a rule, the axon is thick, sometimes passing over a long distance without branching, sometimes branching off soon in a pattern so specific as to enable by itself the differentiation of the pig's aortic arch even from that of related animals. The thick myelinated sheath accompanies the axon sometimes up to its terminal branching. Here it usually disappears so that it has no role at all in the formation of rich end plexuses joined in, occasionally also by the terminal rami of several other fibres (Fig. 127).

The smaller and larger terminal rami which arise by branching, themselves branch off several times. On the terminal rami as well as on the preceding preterminal rami a temporary thickening of the axon (which involves a loosening of its

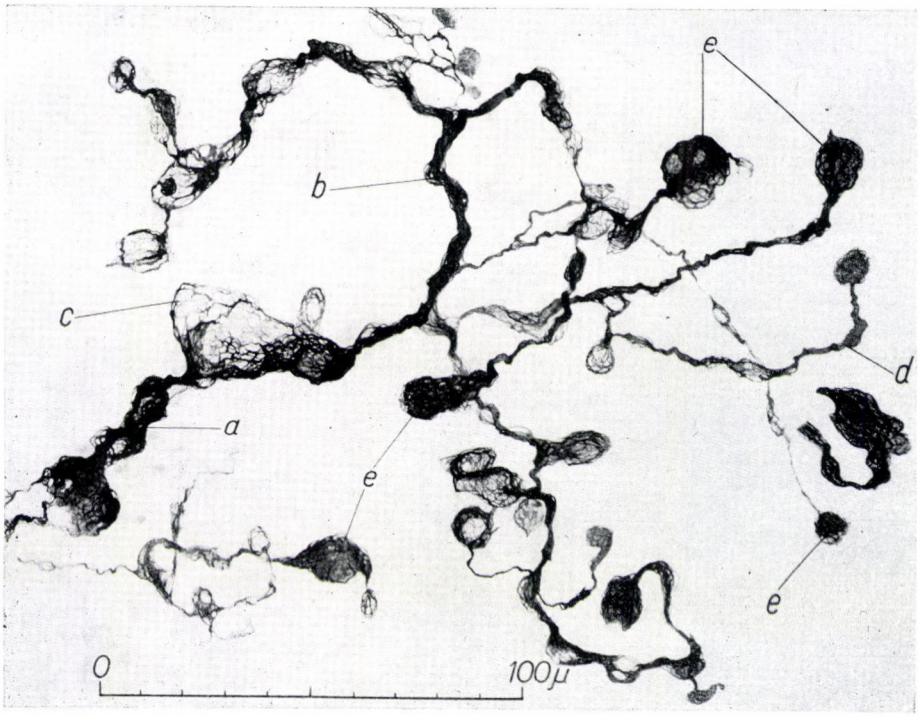

FIG. 127. *Sus scrofa domestica.* Receptors in the aortic arch. (a) Main nerve branch; (b) secondary nerve branch; (c) neurofibrillar intermediary plate; (d) end branch; (e) neurofibrillar end plate. Bielschowsky–Gros' method. Microscopic magnification 1150×, reduced photographically to ½

structure and the appearance of broad intermediary neurofibrillar plates in its descent) may often be seen. Several such intermediary plates may occur in the descent of the individual fibres. The thin, but occasionally conspicuously beaded, end fibre continues in a typical end system characterized by mushroom-shaped or ovoid dense end bulbs, which probably are neurofibrillar end plates (Fig. 128). The figure shows the branch systems of two thick fibres which, being intertwined with each other, secure a relatively large area for the depressor distribution. In the main fibres and in the side branches the neurofibrils are very prominent here and there. In the descent of fibres there are frequently elliptical or elongate intermediary plates which, together with the enormous mass of fibres of varying thickness, almost impose the appearance of nervous tissue upon that portion of the vessel wall. Almost all terminal ramifications end in a flower of flower-bunch-like pattern owing to the delicate network, i.e. net formed by the fibrils of the end plates.

In the pig's aortic arch the terminal fibre systems of the well-impregnated thick aortic fibres are occasionally so inextricably interwoven with each other that,



FIG. 128. *Sus scrofa domestica*. Nerve fibre plexus in the aortic arch. (a) Thick nerve fibre; (b) neurofibril; (c) intermediary plate; (d) terminal fibre; (e) end plate. Bielschowsky–Gros' method. Microscopic magnification 600×, reduced photographically to ½

although the components may be well distinguished under the microscope, their description or drawing is practically impossible. Photography is also inadequate as only a minor part of these structures may be visualized by this technique, being as a rule unsatisfactory for the understanding of the whole structure. Therefore, the true picture of these incomparably delicate and complicated structures can best be illustrated by drawings rendering their description comprehensible. However, in our vast material some preparations suitable for photography have been encountered. Such a picture is shown in Fig. 129. It shows two thick fibres and their terminal systems. The picture clearly reveals the myelin sheath of the main fibres as well as the delicate terminal rami, both dense and structured. There are also some complicated, yet well-defined pictures which yield a more



FIG. 129. *Sus scrofa domestica*. Baroreceptors in the wall of the aortic arch. (a) Thick fibre; (b) terminal fibre; (c) end plate. Bielschowsky–Gros' method. Microphotography.

comprehensive view of structure and connections and more conclusive information on the unity of structure and function. In such pictures the rich branch systems, the intermediary and end plate systems of the fibres may be studied together. The figure presented here seems to be particularly adequate for the purpose (Fig. 130). On the thick fibre shown in the figure the thick myelin sheath, Ranvier's invaginations, neurilemmal nuclei and the axon of varying diameter are clearly apparent. The latter divides into two branches after having lost its myelin sheath. The relatively thick "daughter" rami pass on diverging from each other, each showing regular alterations of their thickness along its descent. Subsequently both of them subdivide into numerous rami showing alternately thick and thin portions. From these rami arise fibres which are initially dense in structure, later on broaden in a lamella-like fashion showing fine fibrillary structure and finally, after gradual subdivision, attach to the vessel wall in the form of larger plates. The lamella-like broad terminal rami seem to be structures of prolonged end con-

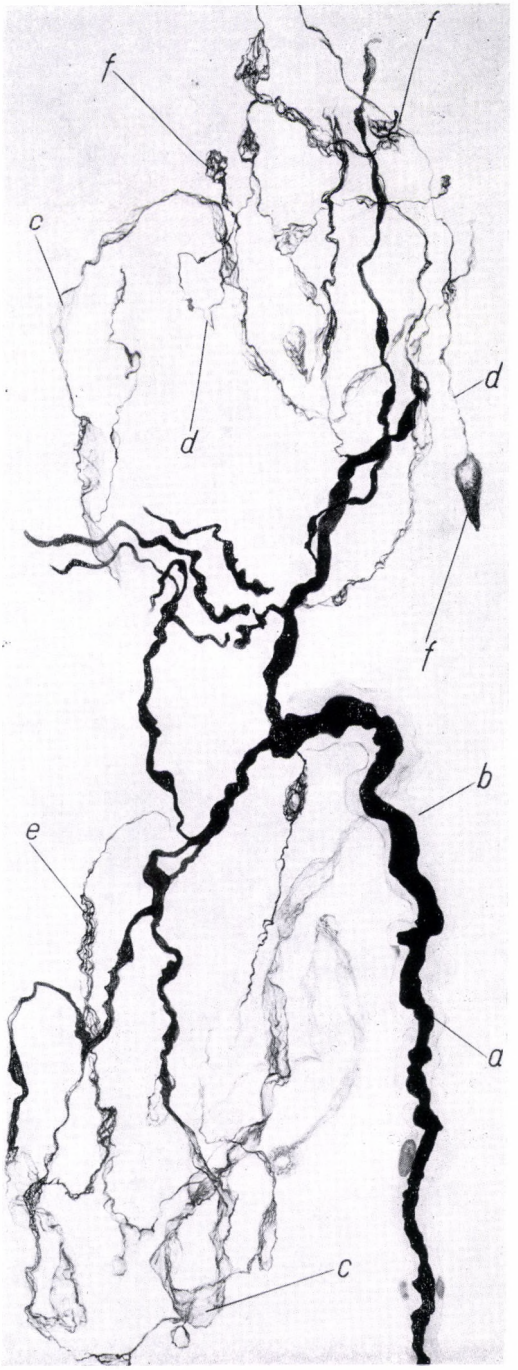

FIG. 130. *Sus scrofa domestica*. Nerve end organ in the aortic arch. (a) Axon; (b) myelin sheath; (c) intermediary plate; (d) end fibre; (e) neurofibril; (f) nerve end plate. Bielschowsky–Gros' method. Microscopic magnification 200×, reduced photographically to ½

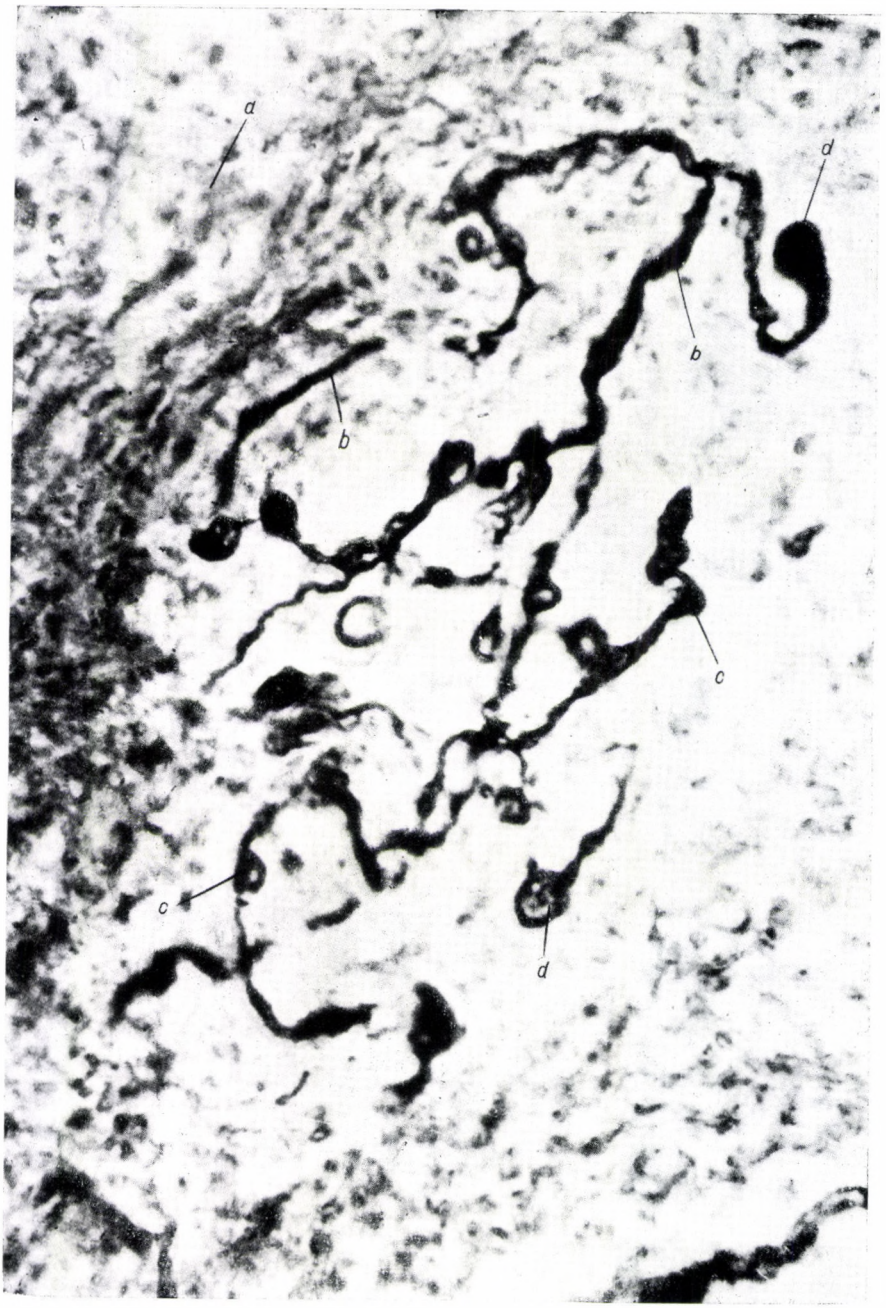

FIG. 131. *Sus scrofa domestica*. Aortic arch; receptors in the tunica adventitia. (a) Connective tissue; (b) nerve fibre; (c) varix; (d) end plate. Bielschowsky–Gros' method. Microphotography

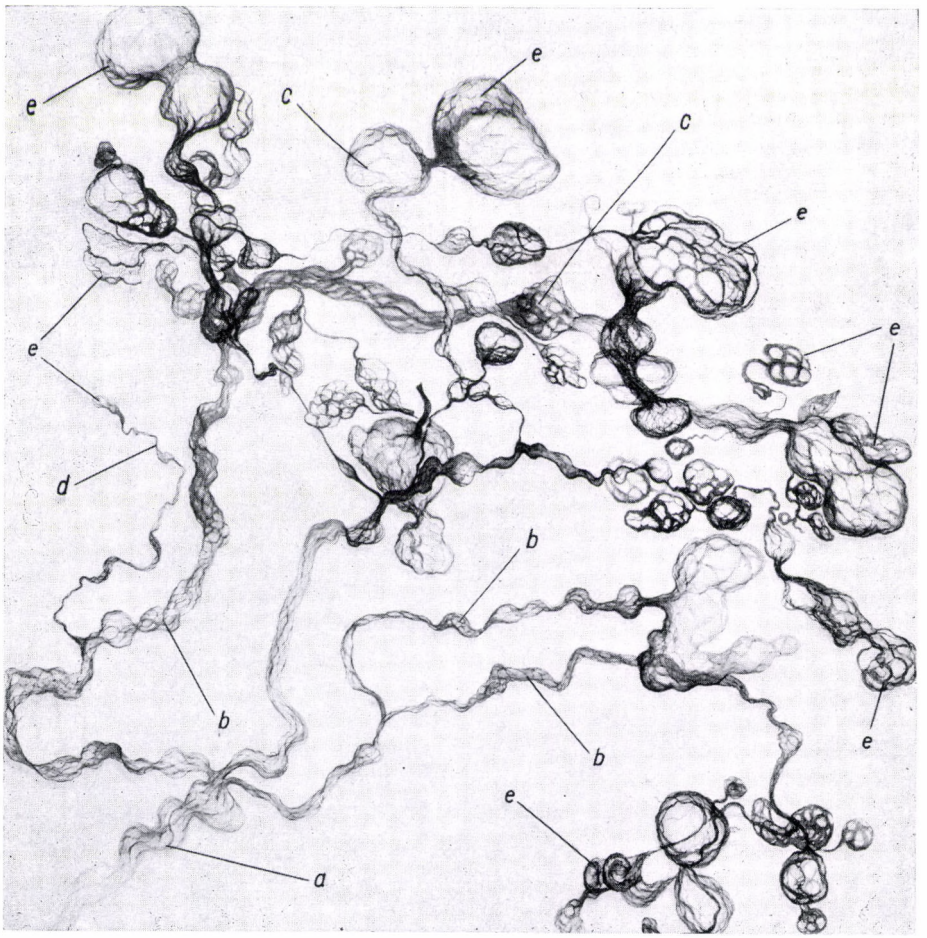

FIG. 132. *Sus scrofa domestica*. Baroreceptor in the aortic arch. (a) Thick nerve fibre; (b) neurofibril; (c) intermediary plate; (d) end fibre; (e) end plate. Bielschowsky–Gros' method. Microscopic magnification 600×, reduced photographically to ½

nections truly reflecting the extensive and close relationship of depressor fibres with the elements of the host tissue.

Thinner secondary fibres, derived by the branching of the main fibres, are characterized by the presence of round or oval intermediary neurofibrillar plates, adjacent to their endings (Fig. 131). The oval shape is of special importance, being a specific feature of the pig's aortic nerve end fibres. No such oval formations have been encountered in the aortic arch of any other mammal. In other animals and also in man, the plates are broad, elongate and often of ivy-leaf shape, whereas in the pig they are in the majority of cases spherical or ovoid. Naturally, the dense or neurofibrillar appearance of the plate in the microscopic picture depends

also on the section's thickness and impregnation (Fig. 132, Plate II/c, p. 63). The large round spheres attached to the branches by thin end fibres, like apples hanging on a long stem, are so characteristic of the pig's aortic nerve fibres that their presence in an unknown preparation is by itself a proof of its origin from the pig's aortic arch.

If one has the good fortune to obtain a microscopic picture which shows the whole end structure of a thick fibre, this is characterized by homogeneous beads, button-like bodies, regular neurofibrillar plates with elongate neurofibrillar ribbons here and there. Sometimes these structures are strikingly clear. Perhaps the most beautiful picture encountered in our material of the pig's aortic arch is that shown in the figure below (Fig. 133, Plate I/d, p. 48). This picture shows a thick fibre, thickening towards the periphery and dividing into daughter rami which broaden markedly here and there. The thickening of the main fibre may sometimes attain more than twofold of its original diameter. This is of interest because as yet similar structures have been encountered only in the crista acustica of the carp. There the thick fibres of the vestibular nerve, when reaching beneath the epithelium, thicken by 3–4-fold of their original diameter and from that conspicuously thick portion exit the side branches which, after rich ramifications, enter between the sensory cells of the crista. Circumstances are the same in the pig's aortic arch. The nerve fibre thickens markedly and divides into branches, which also thicken, either immediately after exit or somewhat later. At these sites the collateral branches thicken so markedly that sometimes they exceed by 2–3 times the dimension of the main fibre. From these enormously thickened lateral branches exit intermediary branches of similar structure as well as end rami carrying a vast system of terminals located in the connective tissue insula protruding into the media. In general, the terminals are dense or are reticular plates of varying lengths. Owing to their large mass, they lend the appearance of a coherent neurofibrillar terminal net to the vessel wall portion contacting with the fibre end system.

In the majority of cases, the terminal system of the individual depressor fibres does no t cover a larger area. Yet, sometimes the terminal rami may pass over a relatively long distance from the site of branching. Such relations are seen in the next figure (Fig. 134), which shows a myelinated lateral branch of a myelinated main fibre. The lateral branch is seen to subdivide into two new rami, each carrying a complete terminal system. Rami arisen from the lateral branch are relatively thin, non-myelinated and cover a fairly long distance before giving off their terminal branch systems. In the terminal rami, the neurofibrils are clearly apparent here and there and in their descent there are many intermediary plates, sometimes elongate or tapering, then again neurofibrillar in structure. The delicate terminal rami arisen by the subdivision of side branches continue in smaller or larger neurofibrillar plates which, bordered sharply against the surrounding tissues, attach to more extensive portions of the wall (Fig. 135).

Infrequently there have been encountered pictures showing monopodial branching, sometimes even two subsequent ones. In such cases the typical undulating descent of the thick fibre could be followed up over a longer distance. From the main fibre exited later four side branches in nearly completely monopodial fashion.



FIG. 133. *Sus scrofa domestica*. Baroreceptor in the aortic arch. (a) Thick nerve fibre; (b) terminal broadening; (c) neurofibril; (d) end plate. Bielschowsky's method. Microscopic magnification 400×, reduced photographically to ½

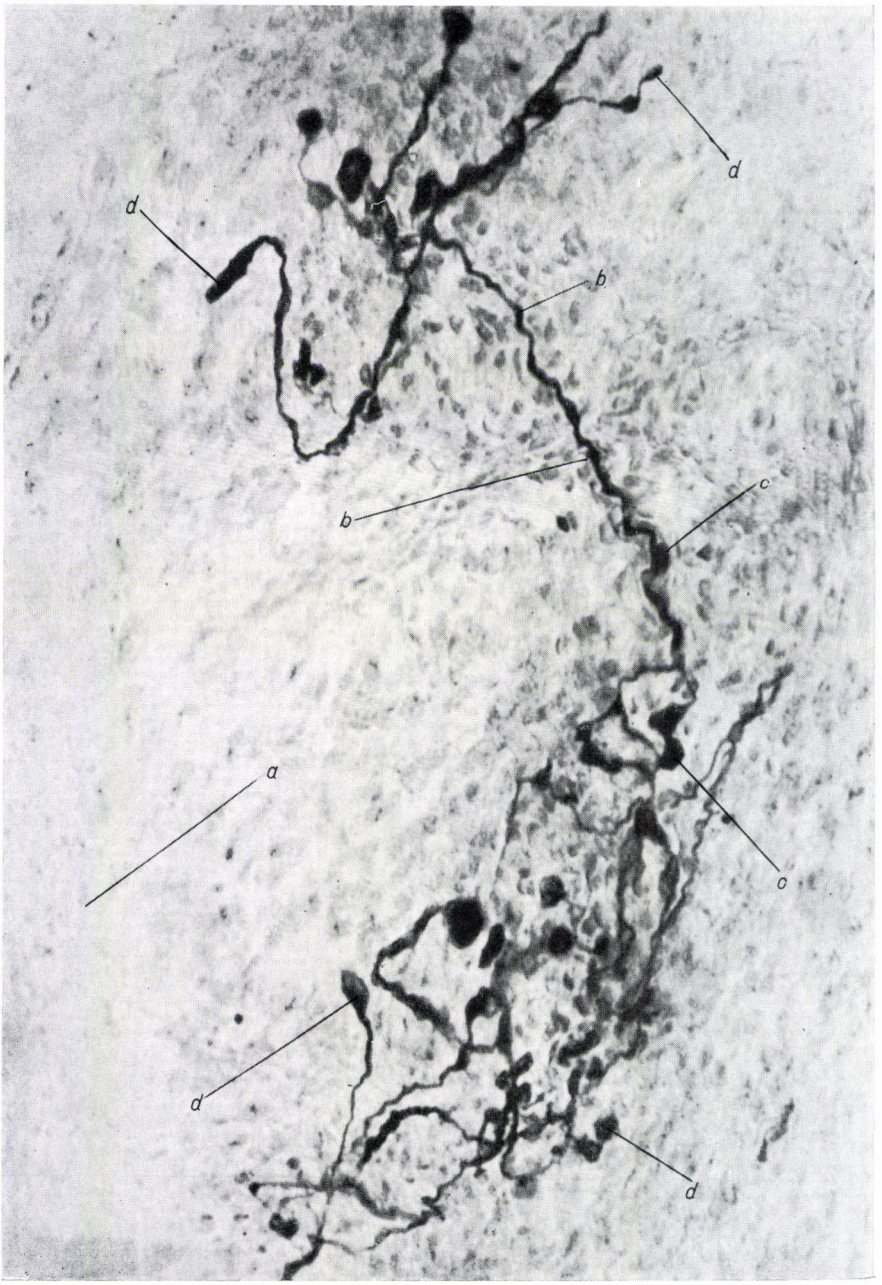

FIG. 134. *Sus scrofa domestica*. Aortic arch; repectors in the tunica adventitia. (a) Connective tissue; (b) nerve fibre; (c) varix; (d) end plate. Microphotography

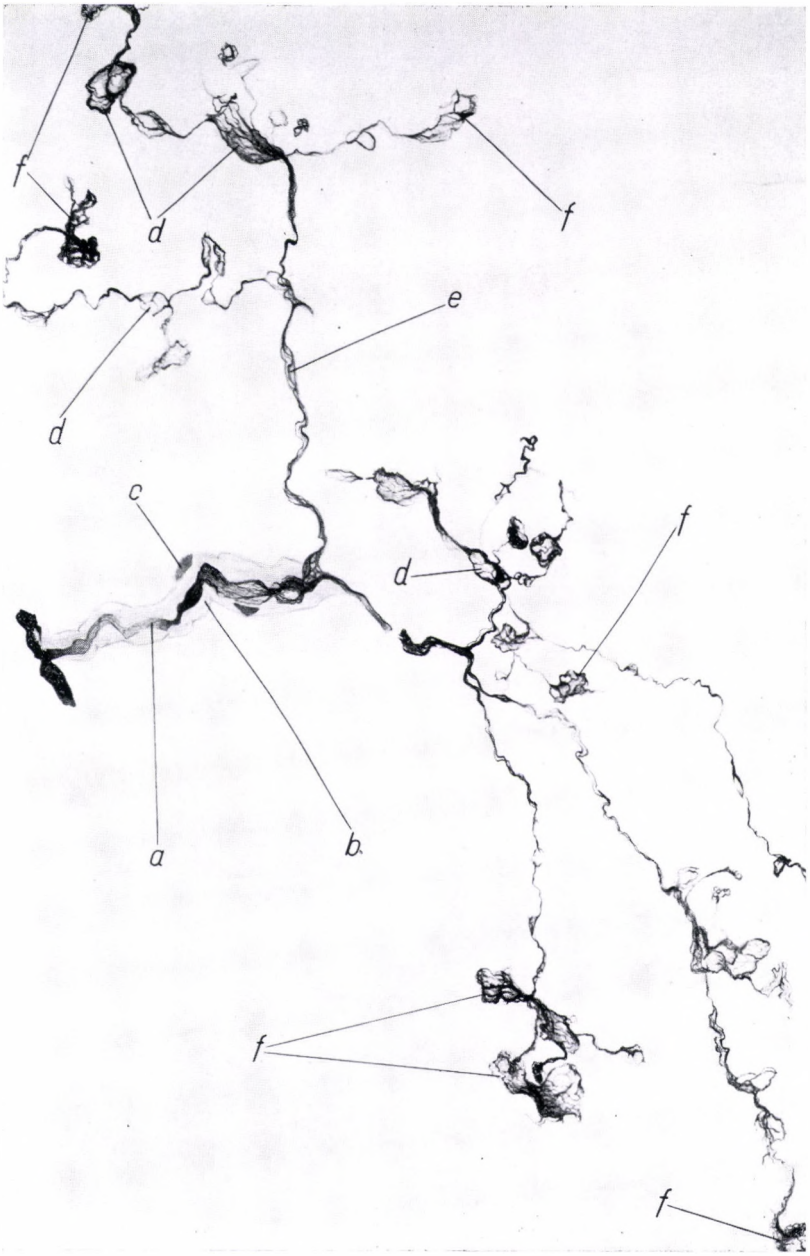

FIG. 135. *Sus scrofa domestica*. Baroreceptor in the aortic arch. (a) Axon; (b) myelin sheath; (c) nucleus of neurilemma; (d) intermediary plate; (e) neurofibril; (f) end plate. Bielschowsky's method. Microscopic magnification 400×, reduced photographically to ½

All of them were surrounded by myelin sheath and neurilemma. The neurilemmal nuclei, too, were well visible. Of the three fibres the middle one was the thickest and appeared to be of central character throughout. This was indicated by its subdivision into three branches, again in a monopodial fashion instead of covering a long distance as before. The branches were myelinated, the end rami started terminal ramification and plate formation after a variable length of descent. From the terminal rami exited delicate lateral branches in all directions in space. These often carried roundish, sometimes markedly elongate intermediary neurofibrillar plates from which sometimes extended delicate lateral processes. There is little doubt now that these seemingly unorganized plates are actually forming a coherent neurofibrillar system serving for the enhancement of parallel contact as well as for rendering the connection between vessel wall and nervous system more close and extensive. Naturally, the same function is shared also by the very variable and delicate neurofibrillar plates whose description is superfluous being well visible in the adjacent figure (Fig. 136).

In the pig's aortic arch, large intermediary plates are frequently present in the descent of depressor fibres. The identification of their precise nature is rather difficult. They may be supposed to originate from pathological alterations, functional arrangements, alteration involved in the pig's fattening or simply post-mortem phenomena. Anyway, it is of interest that although similar structures have been observed in the descents of all depressors hitherto examined, in no case were they comparable, either in size or frequency, to those found in the pig. Sometimes these plates are dense and homogeneous, sometimes markedly fibrillar or even fringed at their margins. Some of them are roundish, others elongate, irregular or winding. Sometimes they are conspicuously large and relatively homogeneous. They do not contain neurofibrils and in general they seem to be formed simply by a spilling of the neuroplasma at the given sites (Plate II/c, p. 63). This phenomenon is the more conspicuous as the fibres keeping the plates together are relatively thin. Since in the pig the phenomenon is not accidental but rather frequent, the investigator is naturally seeking for a feasible explanation of that uncommon phenomenon. The question is, whether the structure is normal or pathologic. The rarity of similar phenomena among the peripheral sensory nerve fibres is suggestive of their pathologic nature. Yet, one reasonably enquires why such formations appear only among the depressor fibres and in larger masses even there exclusively in the pig. At present, we are bound to leave these questions unanswered. Tentatively we may, however, state that in our opinion the phenomenon is not pathologic, being apparently due rather to age and, perhaps, also to obesity. Evidence remains to be derived from comparative morphological studies in relation to the way of life, general condition and age.

Having described some types of terminal structures, we are now concerned with their location, fine structure and connection with the individual histological layers of the vessel wall. According to our observations, receptors of the aortic wall are located along the inner surface of the adventitia where it conjugates with the media. This finding has been temporarily considered by us of general value, thus we observed from this angle the aortic nerve's terminal structures

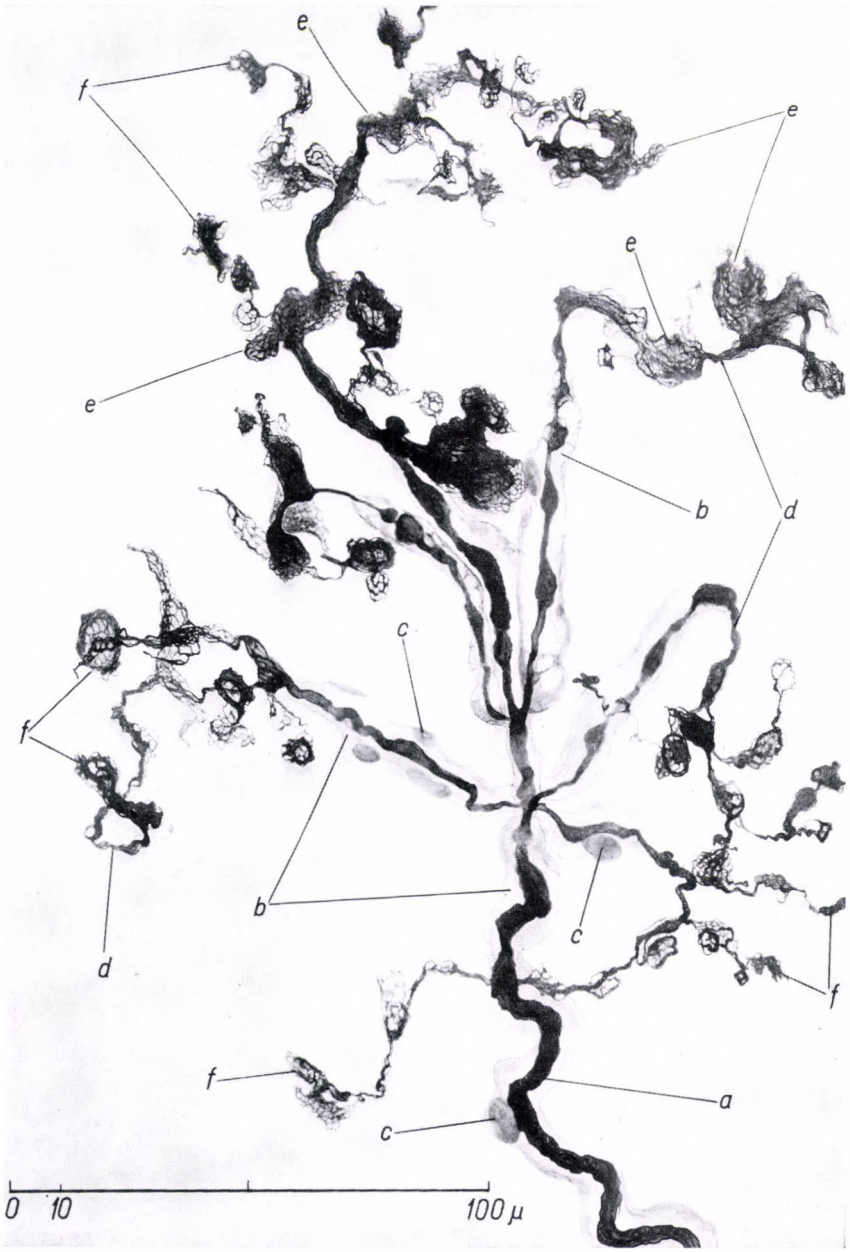

FIG. 136. *Sus scrofa domestica*. Baroreceptor in the aortic arch. (a) Axon; (b) myelin sheath; (c) nucleus of neurilemma; (d) terminal fibre; (e) intermediary plate; (f) end plate. Bielschowsky's method. Microscopic magni-fication 1150×, reduced photographically to ½

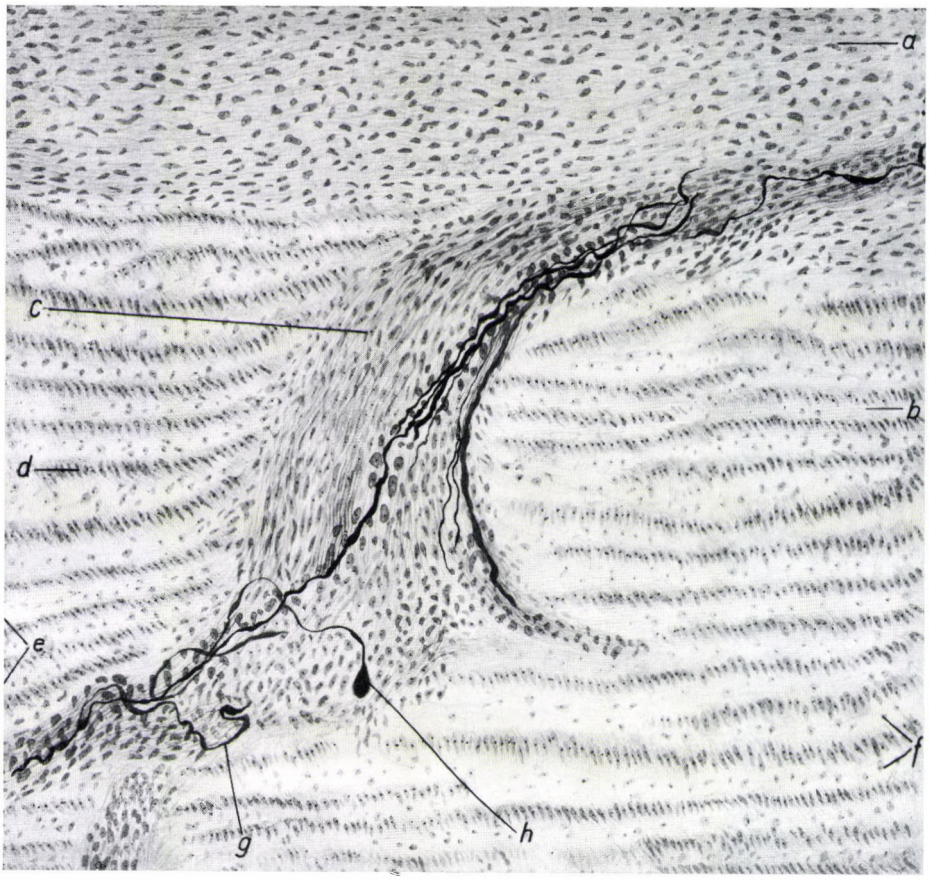

FIG. 137. *Sus scrofa domestica*. Transverse section of the aortic arch. (a) Tunica adventitia; (b) tunica media; (c) connective tissue bundle; (d) smooth muscle cells; (e) connective tissue fibres; (f) nuclei of connective tissue cells; (g) nerve fibre; (h) nerve ending. Bielschowsky–Gros' method. Microscopic magnification 600×, reduced photographically to ½

in all mammals examined. Later on the location of nerve fibre terminals was examined also in longitudinal and cross sections, revealing that occasionally the depressor fibres enter also the media. Simultaneously it was found that end plates occur in large numbers not only in the inner layer of the adventitia but also in the connective tissue septa between the media's muscle layers. This implies that the depressor fibres and vessel walls are associated more closely than originally believed. Their interconnection is close, primarily because endings occur also in the region of the media and secondly because beside the tangentially located, flat membranes there are also some end plates situated perpendicularly to the vessel wall.

The pig's aortic arch was examined also with respect to the position of depressor fibres. It was found that depressor fibres pass deep into the aortic wall, but in every case through a small insula of the adventitia extending into the media. Here the depressor fibres pass at right angles to the vessel wall's longitudinal axis through three-quarters of the media where they end freely within the connective tissue insula (Fig. 137).

Having clarified the site of ending of depressor fibres, let us consider the details of their structure. As outlined previously, the terminals themselves are spherical or elliptic, sometimes markedly elongate structures which in impregnated and gold-treated preparations exhibit occasionally a homogeneous, or sometimes a neurofibrillar appearance. If the terminal plates and their associated fibres are examined under high-power magnification, neurofibrils become apparent immediately before the termination of end fibres. The neurofibrils either pass parallel or run across and across each other to constitute a network. They may be studied also in the terminal plate where they form a loose plexus with each other. The terminal plates appear to be circumscribed units not connected with the host tissue. In their environment, cytological or histological structures suggestive of a structural or functional relationship are entirely absent.

Calf (*Bos taurus*)

In the calf, one part of the receptor field is found on the anterior, or lower portion of the aortic arch adjacent to the ligamentum arteriosum Botalli. The aortic nerve enters the aortic wall above that ligament, gives off branches and passes towards the arch's concave part and to the brachiocephalic trunk.

The fibres enter the adventitia from the periadventitial connective tissue at the arch's convex side, in the form of smaller and larger bundles accompanied by smooth, undulating sympathetic fibres of varying dimensions and in varying numbers.

In the adventitia they exit from the bundles and subdivide gradually into thinner branches. They are vagal sensory fibres and are accordingly conspicuously thick. A typical feature of them is the thick myelin sheath to which attaches a relatively thick neurilemma whose nuclei are spaced relatively closely to each other.

In every case, sensory fibres of the aorta have a typical appearance but seem to be still more special in the calf's aortic arch where they carry homogeneous varices of particular shape and arrangement over their entire descent. Experience has revealed that although these structures are in general characteristic of aortic receptors, they show quite particular forms in ruminants. Sometimes they appear as large folds in immediate sequence so as to lend the fibre the appearance of an accordion. In such cases the beads are arranged unilaterally like drumsticks beneath the thick myelin sheath (Fig. 138). Similar, but flatter and broader formations are frequently seen also in the fibre's terminal branch system. On the axon there are often indentations of varying sizes, sometimes very deep. Occasionally, the whole axon appears to be torn at the edges. Quite frequently in the



FIG. 138. *Bos taurus*. Nerve end body in the wall of the aortic arch. (a) Myelin sheath; (b) axon; (c) varix; (d) intermediary plate; (e) end plate; (f) branching; (g) loose coil; (h) nucleus of neurilemma. Bielschowsky–Gros' method. Microscopic magnification 930×, reduced photographically to ½



FIG. 139. *Bos taurus*. Aortic arch; receptors in the tunica adventitia. (a) Connective tissue; (b) axon; (c) varix; (d) end branch; (e) intermediary plate; (f) end plate. Bielschowsky–Gros' method. Microphotography

axon's path large angular homogeneous plates are seen connected with each other only by very thin linking pieces. Spherical, ovoid or elliptical thickenings, characterized by marked variation in shape and size, are still more frequently apparent. Less often, also large homogeneous beads, of spherical or elliptic shape, are seen in the axon's path. Similar formations being very scarce in other regions of the nervous system, one is bound to raise the question of what their precise role and actual importance might be. One may again consider the possibility of pathologic phenomena, but then all sensory fibres encountered in the calf's aortic arch should be considered pathologic. This is not entirely impossible, but we would then have to accept the proposition that pathologic alterations of the aortic sensory system are fairly common in adult cows.

The specially structured myelinated fibres usually branch off in a dichotomic fashion, often several times, then continue in gradually narrowing rami. Passing beneath or beside each other these rami form loose-structured end trees or coils of varying size whose narrowing terminal fibres end in triangular neurofibrillar end plates (Fig. 139).

The type of ramification constituted by three branches arising at the same site from the main fibre is not infrequent either. Such fibres usually ramify in the same tree-branch fashion throughout their further passage. Sometimes again the fibres show no particularities at all, descending in a slightly undulating way and showing smooth edges and only a few lateral rami. The fibre itself may be followed over a long distance, starting to give off branches only towards its end, but there it ramifies richly. The terminal rami run a long winding path and constitute a coil-like pattern. This is, however, no true coil as in its inner part there are many intermediary neurofibrillar plates and end plates. From such end systems smooth, thin ultraterminal fibres often arise which either enter other end systems or, after a shorter path, return to the original one.

There are some sensory fibres which pass on independently of other similar structures and show an end system which though complicated is yet clearly visible. Naturally, the appearance of end systems in the individual section depends not only on chance but also on the efficiency of the processing technique. The success of cutting is a matter of chance which determines whether the section will comprise complete or incomplete end systems. The impregnation technique, however, depends on the adequacy of the chemicals used as well as on the skill of the operator. If both the cutting and the impregnation have been successful, primary, lateral and terminal branches as well as end plates will be clearly apparent. A particularity of branch systems, resp. end branches, present in the aorta is that occasionally they may become unbelievably narrow, then again attain or even exceed their original diameters. Of the terminal branches the thicker ones are compact, seldom showing neurofibrils. Secondary or tertiary lateral branches are, on the other hand, usually markedly fibrillar (Fig. 140, Plate III/a, p. 237). The neurofibrils vary in thickness. Their descents are usually parallel, although they may show marked divergence from each other in places.

The tertiary rami continue in winding end branches which carry the terminals at their ends. The shape, size and structure of terminals may also vary within

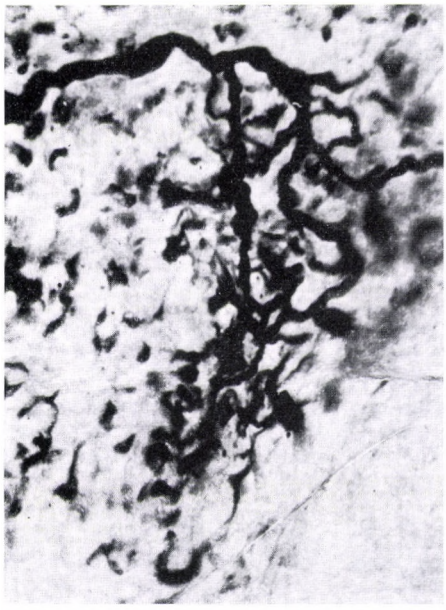

a



b

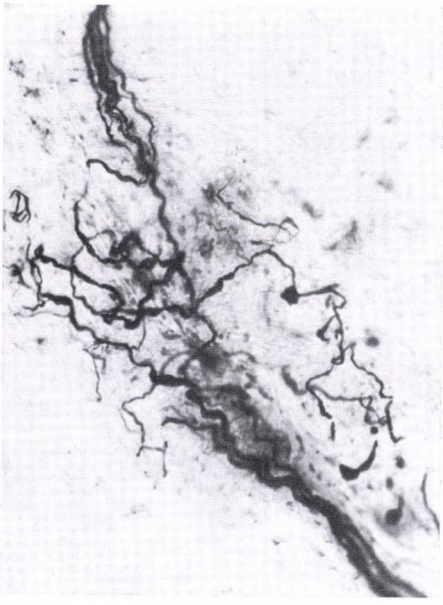

c

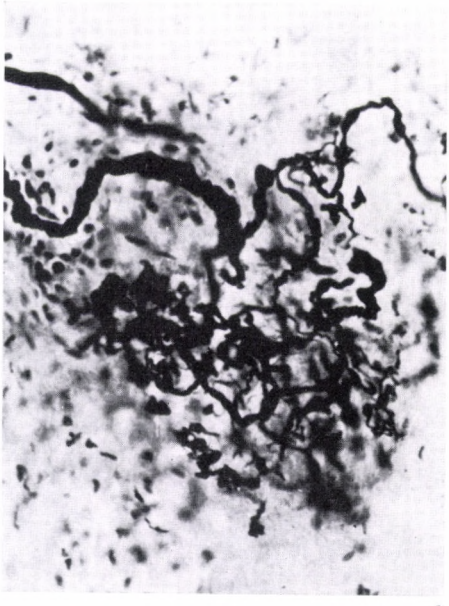

d

PLATE III

(a) *Bos taurus.* Arcus aortae; receptors in the adventitia
(b) *Bos taurus.* Arcus aortae; receptors in the adventitia
(c) *Homo.* Terminal system of nerve fibres in the aortic arch
(d) *Bos taurus.* Arcus aortae; receptors in the adventitia



FIG. 140. *Bos taurus*. Nerve end organ in the wall of the aortic arch. (a) Axon; (b) branching; (c) end plate; (d) intermediary plate; (e) varix; (f) neurofibrils. Bielschowsky–Gros' method. Microscopic magnification 315×, reduced photographically to ½

one and the same end system. At the ends of very thin end fibres there are end beads or plates, which may be dense or sometimes loose and fibrillar in structure. Some of the end plates are large and of angular shape; inside them the neurofibrils form a closed plexus. These plates are attached by delicate stems to some terminal fibres of the rich tree-like branch system like fruits on a tree. In respect of the



FIG. 141. *Bos taurus*. Nerve end organ in the wall of the aortic arch. (a) Main branch; (b) lateral branch; (c) end branch; (d) neurofibrils; (e) end plate; (f) intermediary plate. Bielschowsky–Gros' method. Microscopic magnification 675×, reduced photographically to $^1/_3$

varying positions and shapes of branchings we note the special circumstance that at the exit of the delicate terminal rami many of the main fibres show a triangular thickening (Fig. 141, Plate III/d, p. 237).

Chance and care may yield preparations showing beside the beaded main fibre and its entire terminal ramification also the end plates in almost complete number. Often even the fine structure of the end plates of special shape, dimension and position is clearly apparent. The latter are mostly large and triangular; occasionally they may extend processes of varying sizes. Naturally, other forms than the triangular shape are often seen (Fig. 142).

In the plates the neurofibrils form plexuses. These plexuses may be sufficiently clear as to allow their study even at the highest magnification. Therefore, considering that the nerve supply of the aortic arch consists not so much of a lamellar system extending in a single plane as of several rich nerve end tree systems, each of whose end branches terminate in neurofibrillar end plates, it may be easily imagined what a considerable area of the vessel wall may be linked with the nervous system even by the end system of a single thick fibre (Fig. 143).

Terminal systems constituted by the branch system of several sensory fibres are still more complicated. Pictures of such structures show rich systems comprising inextricably interwoven plexuses and practically innumerable intermediary and terminal plates. Naturally, there is a wide variation in their appearance depending on the system's constitution by one or two thick fibres. Since all end systems are characteristic of the calf, some more typical forms are described below.

Of the end systems constituted by several fibres those joined by a single thick fibre are of the simplest structure, yet they, too, comprise many "alien" fibres sent by similar end systems. The latter crisscross in the main fibre's end systems, to constitute plexuses. In these plexuees, uniformly involving the non-branching part of the main fibre as well as its terminal portion, many angular and oval end plates of varying dimensions are seen to conjugate either with the main fibre's or with the alien fibres' terminal branch system.

Sensory end systems constituted by several fibres may be more complicated owing to the fact that the nerve fibres occasionally join not only the peripheral part of the end system but may also accompany the main fibre as well as its branches. The end systems formed in such cases are so complicated that their precise drawing is practically beyond consideration. Should we, nevertheless, attempt their illustration by drawing, we do it because even the best photos are but weak and worthless imitations in comparison to the original microscopic picture. In the majority of the cases, photos indicate only the presence of nerve endings conjugated with each other and the host tissue as well. Naturally, this does not mean that we question the value of microphotography. We only note that it is not reliable enough for recording the structures and connections in so rich and morphologically so variable forms as, for example, the receptor apparatuses of the peripheral nervous system. In our opinion, drawing and microphotography are illustration methods mutually competing each other, whence they must not be used separately, only together. The illustration material of this book has been compiled on the basis of this principle. Anyway, we do not claim that

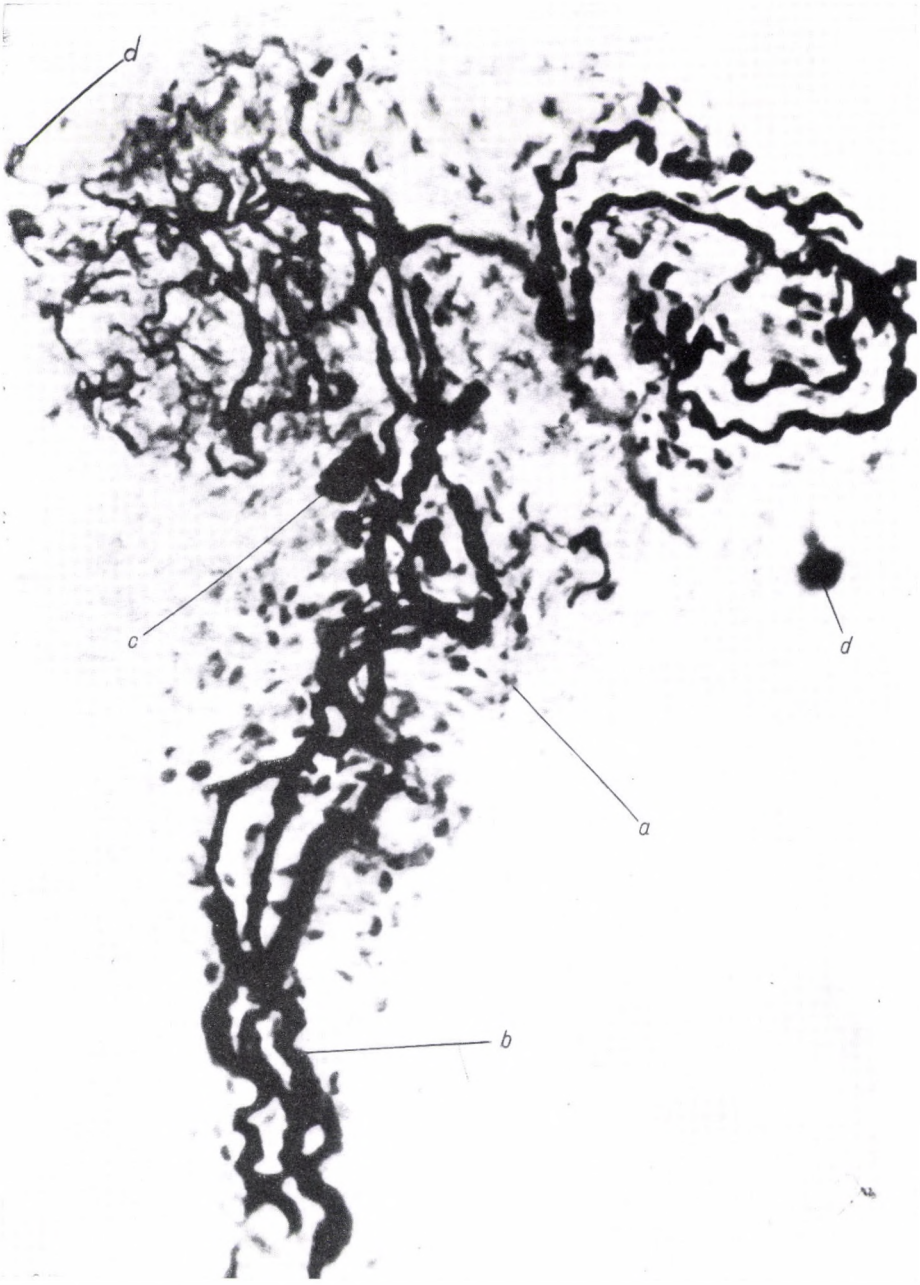

FIG. 142. *Bos taurus*. Arcus aortae; receptors in the tunica adventitia. (a) Connective tissue; (b) axon; (c) intermediary plate; (d) end plate. Bielschowsky–Gros' method. Microphotography



FIG. 143. *Bos taurus*. Nerve end organ in the wall of the aortic arch. (a) Axon; (b) varix; (c) end fibre; (d) intermediary plate; (e) end plate; (f) neurofibrils. Bielschowsky–Gros' method. Microscopic magnification 600×, reduced photographically to $^1/_3$

the drawings presented in this volume are particularly accurate or accomplished. The complicated structure of terminals, and the large mass of end plates and fibres of different calibres, could not be adequately depicted even by drawing. In this light even the best drawings seem to be but poor imitations when compared to the original. I mention this to exclude *ab ovo* the unprofessional opinions stating that

drawings usually represent more details than had been in the original preparation. In contrast, they actually represent only a small part of the details seen in unbelievably large masses and wonderful clearness in successful preparations. The fact that in neurohistology drawings are more appreciated than photos is that the latter allow no information on details.

In the majority of cases the sensory fibres go to the end apparatuses in groups and remain associated also on their further paths. Thus their end apparatuses link large areas of vessel walls and tissue layers with the fibre groups. Naturally, preparations showing the entire system of these fibres have only been seldom encountered. In most cases only the end system of one or the other receptor is seen. Nevertheless, even then the picture is rich enough in details to give precise information on the extent of physiological valency.

Sometimes several thick fibres pass adjacent to each other, then separate and become undulating. Later on the fibres again approach each other and through their intertwined various side branches form a complicated sensory end apparatus impossible to reproduce reliably either by photography or by drawing. Yet precise drawings may give a certain impression of the considerable mass of end fibres of different origin and arrangement in such complex but homonomous end plexuses. The end fibres are either sharply fibrillar throughout their whole lengths, or may show intermediary plates of variable shape in their paths. Intermediary plates as well as end plates render the system suitable for receiving stimuli from all directions (Fig. 144, Plate III/a, p. 237).

Among the end systems constituted by several main fibres, structures composed by the end systems of three or, more seldom, four thick fibres have often been encountered. In such cases the end plexuses are so dense that the branch systems belonging to the individual main fibres can only be followed with difficulty. Some branches appear to be mainly stimulus-conducting formations. Yet, even a few of these also contain end plates which are fibrillar in structure, angular in shape and which together with the intermediary plates constitute the receiving portion of the reception system.

Another not infrequent form of end systems is represented by the transition of the thick fibres' branches into obvious undulating terminal rami carrying spheroid or elliptic end plates on their delicate terminals. Both plates and terminal rami show neurofibrillation. The end plates are sharply bordered against each other as well as against the host tissue, any kind of transition being absent (Fig. 145, Plate III/b, p. 237).

In case of a successful microtechnical preparation, the appearance of coarser networks may be avoided in the microscopic picture and sometimes even the fibres of the end plexus may be visible in but very low number. End plates, however, may be visible in such large numbers that they seem to fill almost the entire field of vision. In these pictures the shapes, structures and connections of the end plates may be readily studied. It is particularly clearly seen that the end plates which mostly consist of small-mesh networks are independent.

The loose coil-like pattern formed of the thick fibres' terminal system is often embraced by the stem part of a markedly undulating thick fibre. Although this

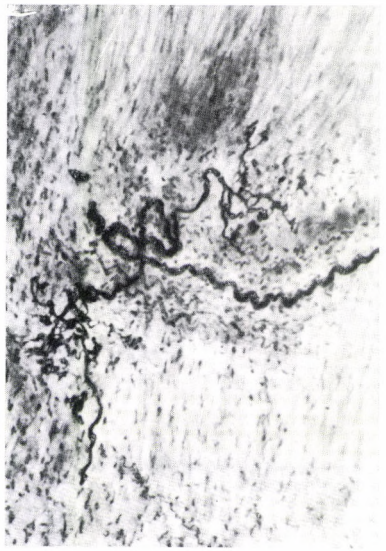

a

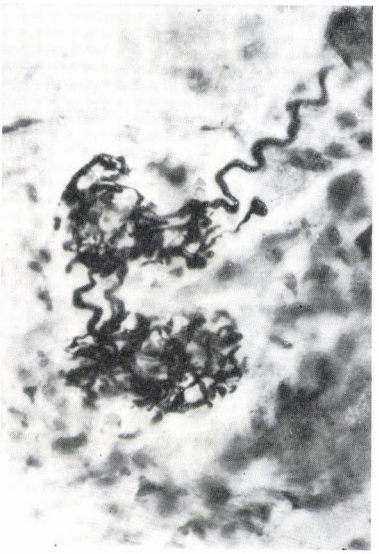

b

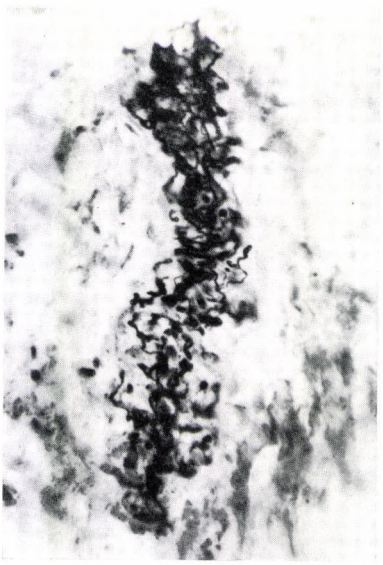

c



d

PLATE IV

(a) *Bos taurus.* Heart; Receptors in the endocardium of the right atrium
(b) *Felis domestica.* Heart; Receptors in the endocardium of the right atrium
(c) *Felis domestica.* Heart; Receptors in the endocardium of the right atrium
(d) *Sus scrofa domestica.* Arteria coronaria cordis; Ramus circumflexus. Receptors in the adventitia



FIG. 144. *Bos taurus*. Nerve end organ in the aortic arch. (a) Axon; (b) branching; (c) intermediary plates; (d) end plates; (e) varix; (f) end branch; (g) neurofibrils. Bielschowsky–Gros' method. Microscopic magnification 675×, reduced photographically to $^1/_3$



FIG. 145. *Bos taurus*. Nerve end organ in the wall of the aortic arch. (a) Axon; (b) neurofibrils; (c) varix; (d) branching; (e) end branch; (f) intermediary plate; (g) end plate. Bielschowsky–Gros' method. Microscopic magnification 675×, reduced photographically to ½

gives the impression that the end system as a whole is the terminal branch system of a single thick fibre, closer examination reveals that secondary branches joining the system from a lateral direction are always clearly visible.

With respect to the above discussed types of multi-fibre end systems we should like to emphasize that their grouping on the basis of being constituted by one or

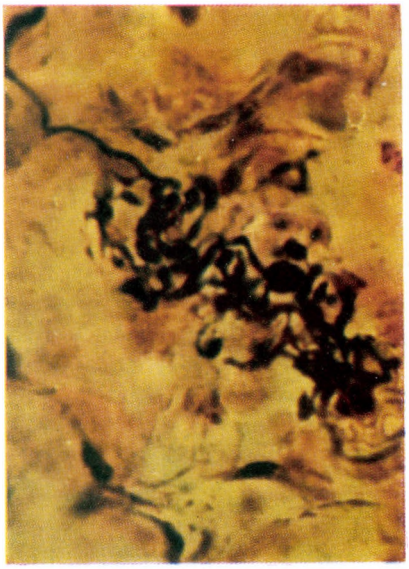

a



b



c

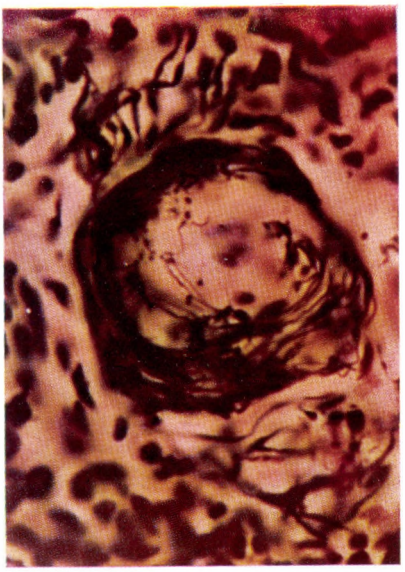

d

PLATE V

(a) *Felis domestica*. Nerve end organ in the right atrial endocardium
(b) *Homo*. Nerve plexus in the carotid body
(c) *Canis familiaris*. Sinus caroticus; nerve fibre system in the adventitia
(d) *Homo*. Nerve endings in the carotid body

more thick fibres is not always reliable. In some cases, fibres seen to pass in groups of two or three may belong to the intermediary branch system of a single fibre. This may be inferred from certain occasionally encountered pictures (Fig. 146). These pictures, covering as a rule a larger area, show that the rich system (looking like the end system of two descending thick fibres in parallel) actually belongs to a single fibre. The same is apparent in the previous figure, showing a thick fibre to divide into two similarly thick, smooth, slightly undulating fibres. Over a long distance these branches run parallel, then ramify several times. The new branches are beaded and distribute gradually to further rami. As a result of repeated ramifications, delicate end systems are formed, which are relatively loose in structure, their fibres run parallel and continue in tapering sharply fibrillar end plates. Hence in every case when such systems appear in preparations not showing the main fibre, they are considered multi-fibrous end apparatuses.

The end formations are usually roughly uniform. Most of them are triangular or multiangular flat plates but some of them are rather spherical or elliptic. Structurally they are neurofibrillar networks or nets. Neither inside, nor between them, were detected mural formations of specific or functionally important nature. To obtain reliable information on the end connection, one of our best preparations was examined under very high magnification and the microscopic picture was sketched (Fig. 147). The drawing was prepared by an instrument and it reflects the microscopic image as truly as possible. In our opinion, this picture, representing the entire end system of a single terminal fibre, speaks for itself and requires no explanation.

In addition to the above description of several types of end apparatuses, I should like to mention a structural peculiarity seen so far beside the calf only in the pig. This is the independent blood supply of certain receptor end apparatuses. The end system is surrounded by a capillary which borders it entirely against the adjacent areas. In certain cases, some parts of the end apparatus are outside the capillary loop, but mostly all constituents remain inside it. When I saw this phenomenon first, I considered it a chance observation and attached no importance to it, but having seen it repeatedly, now I consider it interesting and typical. I explain the phenomenon by the fact that here and anywhere, larger and more extensive nerve apparatuses require special nourishment and richer oxygen supply. Moreover, also owing to continuous functional activity also the production of metabolites and carbon dioxide is larger. Hence it is evident that end systems are surrounded by a separate capillary loop although no other capillaries are present in the adjacent areas of the microscopic picture (Fig. 148).

Stimulus-receiving systems, described in detail in the foregoing text, were detected in tangential sections obtained from the outward parts of the vessel wall. At first sight these pictures give the impression that the end plates are

FIG. 146. *Bos taurus*. Nerve end organ in the wall of the aortic arch. (a) Main branch; (b) lateral branch; (c) branching; (d) varix; (e) end plate; (f) neurofibrils; (g) intermediary plate; (h) end branch. Bielschowsky–Gros' method. Microscopic magnification 800×, reduced photographically to $^1/_3$


d
c
g
f
e
f
e
e
h
e
e
b
b
a



FIG. 147. *Bos taurus*. Neurofibrillar terminal system in the wall of the aortic arch. (a) End fibre; (b) intermediary plate; (c) end plate; (d) neurofibril. Bielschowsky–Gros' method. Microscopic magnification 1800×, reduced photographically to $^1/_3$

arranged in an outward to inward direction, forming several layers in the receptor field. Later on we prepared cross-longitudinal, then circular cross sections. These revealed that thick fibres and end systems penetrate as far as the middle of the aortic wall. Here they ramify and also their end plates are arranged transversely inside the vessel wall. Accordingly, end plate systems present in the calf's aortic arch arrange not only superficially above or beneath each other but also transversely, occupying a deeper position within the vessel wall.

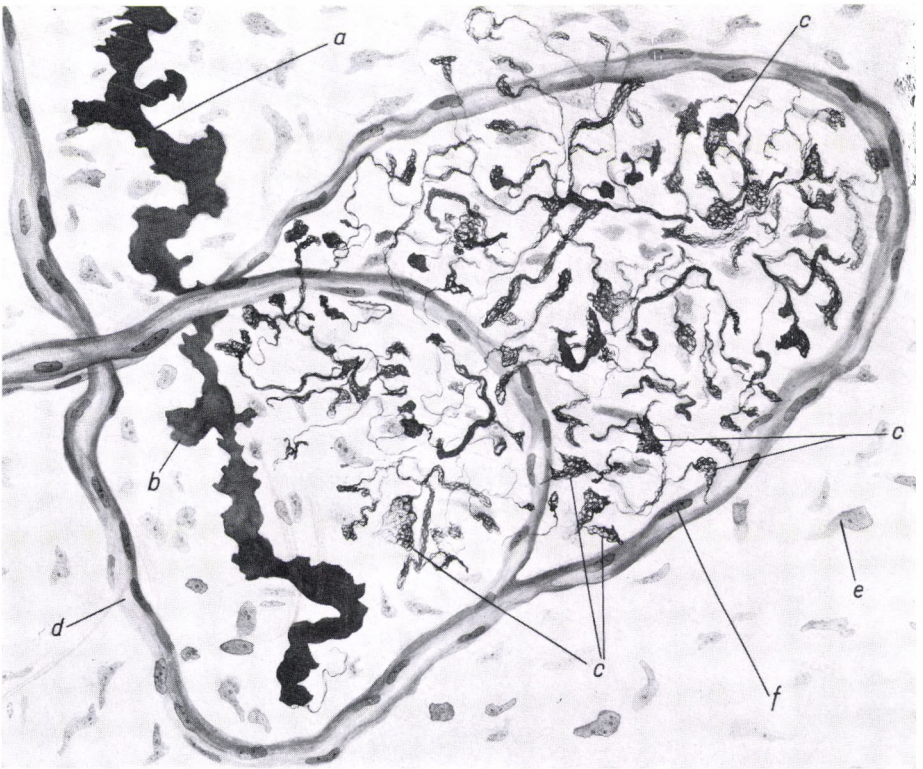

FIG. 148. *Bos taurus*. Capillary loop around the nerve end plates. (a) Axon; (b) varix; (c) end plate; (d) capillary; (e) nucleus of the connective tissue cell; (f) nucleus of the endothelial cell. Bielschowsky–Gros' method. Microscopic magnification 600×, reduced photographically to ½

Cross sections also revealed that end plate systems never extend beyond the middle of the vessel wall's thickness. Since Bersch claimed that receptory end apparatuses were localized in the intima, we examined these sections with special care. Numerous sections were impregnated and examined thoroughly but in no case were the thick fibres seen to extend beyond the middle of the vessel wall's thickness.

Bersch found in a small well-defined area in the intima of the rabbit's aortic arch 15–20 μ long, dense bodies of pear, club, spoon or cone shape, giving rise to numerous, wound fibres. In his opinion, these structures located near to the intima's endothelium and "wie die heliotropen Zweige einer Pflanze dem Licht"* they turned towards the endothelium, i.e. the lumen. These particular bodies were considered by Bersch nerve endings and termed "corpuscula originis nervi depressoris", although as stated by him "ein ununterbrochener Zusammenhang mit

* "like the heliotropic branches of a plant towards light".



FIG. 149. *Oryctolagus cuniculus.* Sensory nerve endings in the wall of the aortic arch. (a) Main fibre; (b) terminal fibre; (c) end plate; (d) smooth muscle cell; (e) nucleus of the smooth muscle cell. Bielschowsky–Gros' method. Microscopic magnification 1800×, reduced photographically to ½

den ausführenden Nervenfasern, die von der Media ab nach aussen zu verfolgen sind, nicht gefunden werden konnte".* In my opinion, the bodies whose pictures have been attached by Bersch to some of his publications are not nerve elements. If they are, the term "corpuscula originis nervi depressoris" is erroneous as the depressor nerve terminates rather than originates in the aorta's wall. I studied

* "... there was no connection detectable with the exiting nerve fibres which may be followed outwards from the media."

the innervation of the rabbit's aortic wall myself and found that there, too, the depressor fibres end in the media and their end structures do not differ notably from those encountered in other areas (Fig. 149). In contrast with all opposed views I state that during examinations on other material, I failed to detect nerve fibres in the tunica intima of the vessels of birds as well as of mammals. I, too, was surprised to have arrived at this conclusion as this infers the absence of nerve supply in a considerable area of the blood vessel's walls. Yet this is a fact in view of which theoretical considerations must retreat.

To throw a light on the function of receptors as derived from the vessel wall's structure as well as on the physiological role of the vessel wall, I prepared longitudinal and cross sections thereof. They revealed that the general pattern derived from histological examinations does not apply to the calf's aortic arch. Preparations stained with haematoxylin and eosin, van Gieson's or resorcin-fuchsin showed that the typical layers easily distinguishable in the arteries in general, and particularly in man, are absent in the calf. Outwards, the vessel wall is bordered by a well-developed periarterial connective tissue layer rich in fat cells, transforming gradually into collagenous connective tissue. This may be reasonably considered to be an adventitia. The tunica intima displays the general type of arterial intima, but conditions differ radically in the tunica media, as described below. Smooth muscle bundles of varying dimensions pass circularly and also longitudinally and between them layers of loose structure, constituted mainly by elastic fibres, are present. In view of this arrangement of the histological layers, our concept of the positions of receptor apparatuses may be put as follows. Receptor assemblies extend beneath and above each other not only in the adventitia but penetrate also into the media extending not only on the muscle bundles but also forming endings in the elastic layers between them. Owing to this position, the effects of both outward and inward pressure changes are conducted more rapidly to the afferent endings and also the movements of the wall's layers are more readily perceived.

Now that the localization, structure and positions of receptors have been described, the question arises where are the fibres supplying the receptor assemblies with nerve endings are coming from and what relationship they may have with the vagus, or the cervical sympatheticus. In this context it may be considered whether or not the calf has an independent aortic nerve and, if so, where this nerve arises, what path it takes and what relationship it has with the sympathetic nerve. A satisfactory answer to these questions is beyond the scope of neurohistology. Nevertheless, as certain literary reports have already pointed in the right direction and also these aspects have to be correlated to, and brought into harmony with, the organism as a whole, I have to survey them briefly in this volume, the more as a linking of anatomical and histological examinations usually offers a reasonable basis for predicting the probable trend, mode and extent of function.

The nerve claimed by certain literary reports to supply the above described receptor assemblies is actually the nervus depressor (aortic nerve), discussed in detail and often cited in another context in the foregoing text. Attempts to describe

the origin and descent of this nerve for the calf were made by Witi (1884), Dogiel (1911) and Perman (1924). It should be noted, however, that the findings of these authors hardly went beyond stating that all ruminants have a common vagosympathetic sheath and, as noted by Koch, "Ein Ramus aorticus ist bei ihnen am Halse nur schwer oder gar nicht zu finden".* The actual situation was most closely defined by Perman, who found that both the right and left vagus sent a thin branch to the origin of the common arterial trunk at the site where the arteria anonyma, arteria carotis communis and arteria subclavia sinistra arose. Thus, should the calf have any aortic fibres, they must pass in that branch. This is, however, valid only when the typical receptor apparatus is demonstrable in the branching area of the nerve in the vessel wall. As described above, there actually exists a complicated rich receptor field constituted by a system of nerve endings. Its localization is, however, not precisely within, but only adjacent to, the region suggested by Permann. Thus even in the absence of experiments in which the nerve was cut, they may reasonably be considered the end system of the nerve described by Permann. This would imply that the calf has got its own specific depressor fibres which enter the aortic wall together with the sympathetic fibres, and there they attach to the vessel wall's outer histological layers by end structures characteristic of the aortic nerve's receptors.

Buffalo (*Bos bubalus*)

In both anatomical and histological respect, the buffalo's aortic arch is very similar to that of the calf. The slight difference encountered relates mainly to the larger amount of smooth muscle tissue in the tunica media and a sharper bordering of muscle cell columns towards each other. Essentially the innervation is also similar but in the buffalo the aortic fibres are thicker, the alternately narrowing and thickening portions of the axons are still more obvious and the intermediary neurofibrillar plates are present in a larger number and more variable shapes in their descents. Nevertheless, these slight dissimilarities do not interfere with the essentially bovine character of the buffalo's innervation patterns. The species character is quite pronounced in the descents, structures and end systems of depressor fibres (Fig. 150). The thick, myelinated varicose fibres divide, after having lost their myelin sheaths, into numerous thin, less varicose, occasionally sharply fibrillar rami which conjugate with the vessel wall. The latter fibres become gradually thinner and run over a long distance, then attach in the form of smaller or larger end discs to connective tissue elements. The end formations differ slightly from those seen in the calf, as in the buffalo the characteristic large neurofibrillar end plates are hardly apparent. The end discs are sharply bordered against the adjacent tissue and conjugate directly therewith. Interstitial cells are absent and the end connections extend over the whole connective tissue (Fig. 151).

* "A ramus aorticus is found with difficulty, if at all, in their necks."

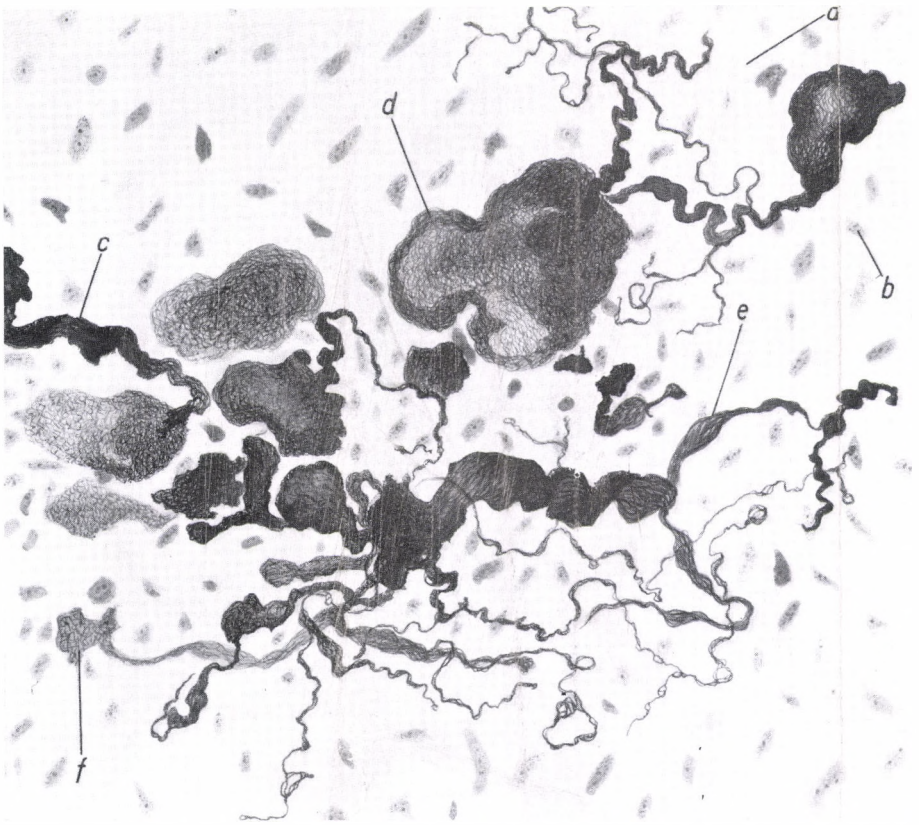

FIG. 150. *Bos bubalus*. Nerve end fibre system in the wall of the aortic arch. (a) Connective tissue; (b) nucleus of connective tissue cell; (c) nerve fibre; (d) nerve fibre plate; (e) neurofibrils; (f) nerve end plate. Bielschowsky–Gros' method. Microscopic magnification 400×, reduced photographically to ½

GOAT (*Capra ibex*)

The goat's aortic fibres are thick and their axons show a characteristic structure. Intermediary neurofibrillar plates connected here and there by a neurofibril-like axon are large and follow each other in a dense sequence. The myelin sheath is thick and disappears where larger neurofibrillar plates are making appearance close to each other (Fig. 152). The fibres branch off repeatedly, new rami arising on a thin base then broadening abruptly so that they exceed in thickness even the original fibre. The varices are large, their forms and features show variations even in the same fibre. The terminal connections are just the same as with the buffalo. The end branches are thin and have no varices, the voluminous end plates are missing.

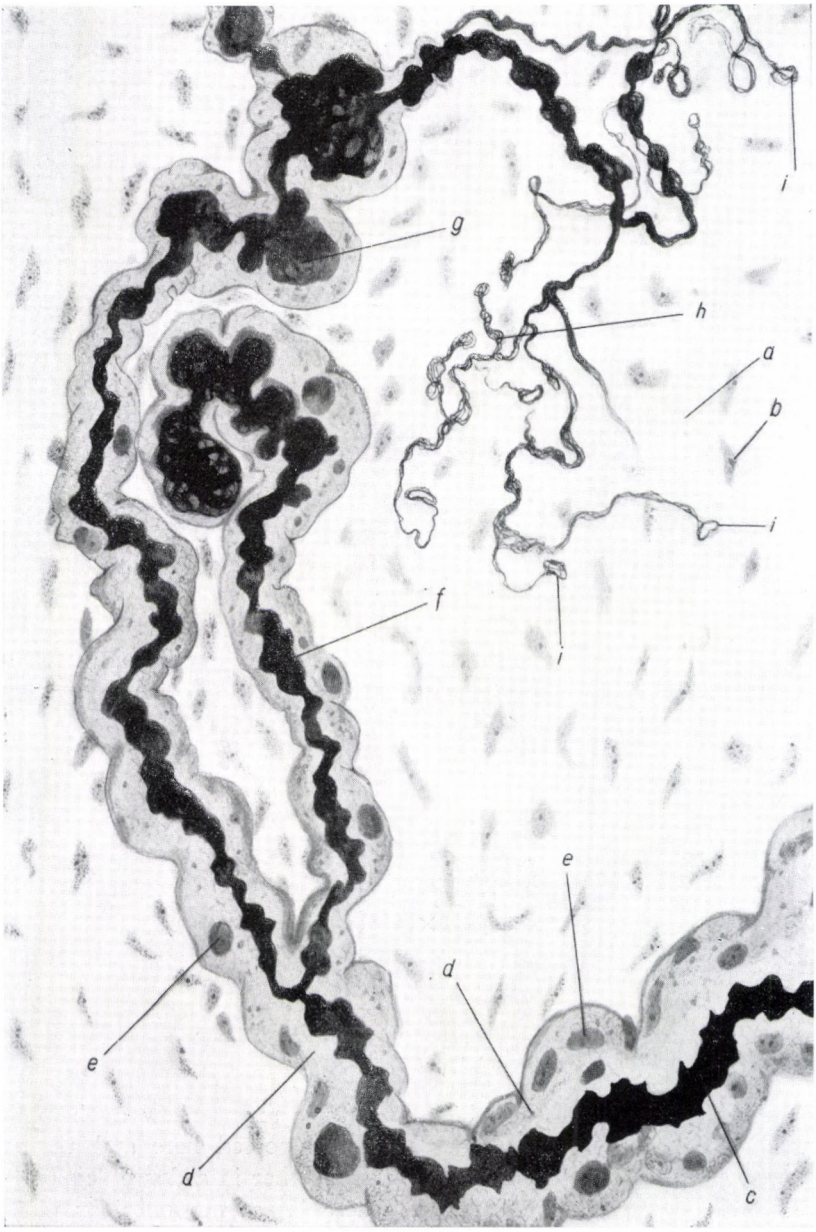

FIG. 151. *Bos bubalus*. Nerve terminal system in the aortic wall. (a) Connective tissue; (b) nucleus of connective tissue cell; (c) axon; (d) myelin sheath; (e) Schwann's nucleus; (f) varix; (g) intermediary plate; (h) neurofibrils; (i) end plate. Bielschowsky–Gros' method. Microscopic magnification 600×, reduced photographically to ½

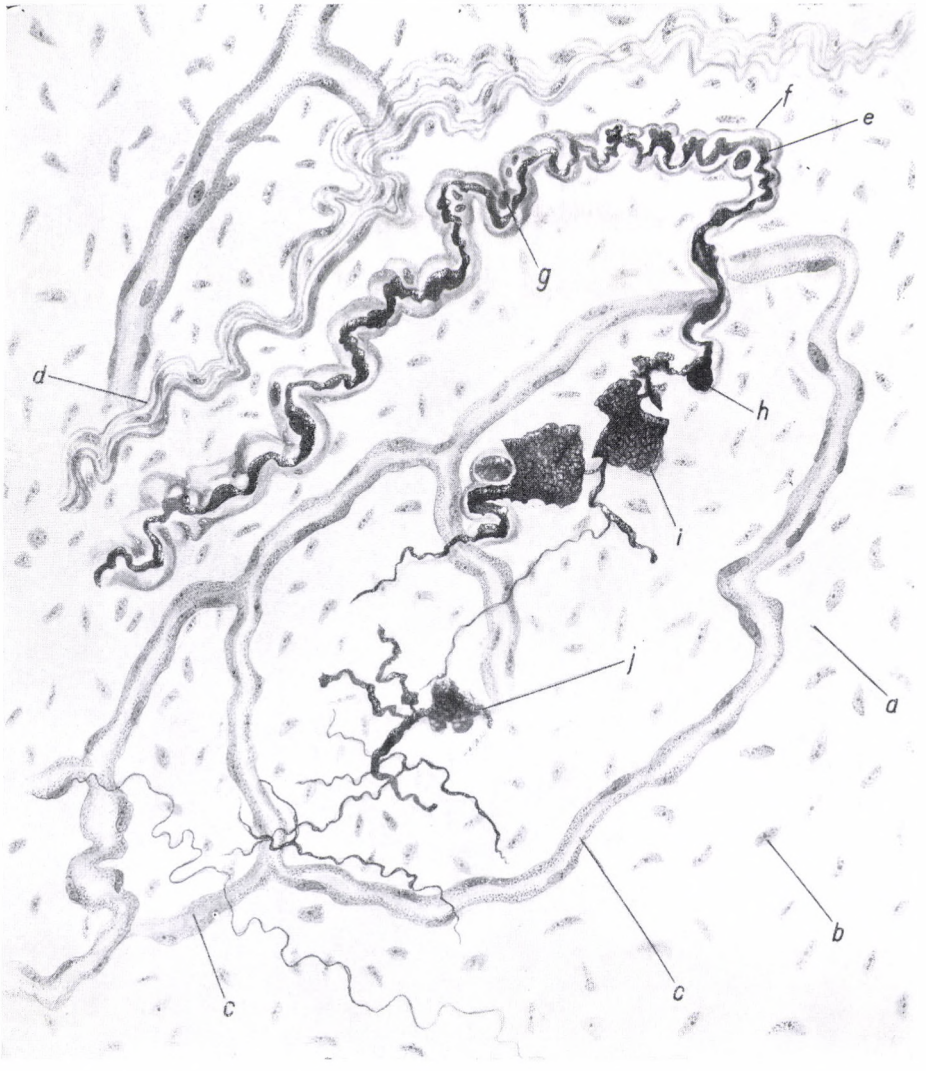

FIG. 152. *Capra ibex*. Nerve fibre terminal system in the wall of the aortic arch. (a) Connective tissue: (b) nucleus of connective tissue cell: (c) capillaries; (d) nerve fibre bundle; (e) axon; (f) myelin sheath; (g) Schwann's nucleus; (h) varix; (i) intermediary plate; (j) end plate. Bielschowsky–Gros' method. Microscopic magnification 400×, reduced photographically to ½

SHEEP (*Ovis aries*)

In the sheep, depressor fibres enter the adventitia separately in a rich bundle. Here they run a long winding path and mingle by repeated exchange with the sympathetic fibres. The mixed bundles thus arisen diverge from each other and form a rich system of networks traversing certain portions of the wall so

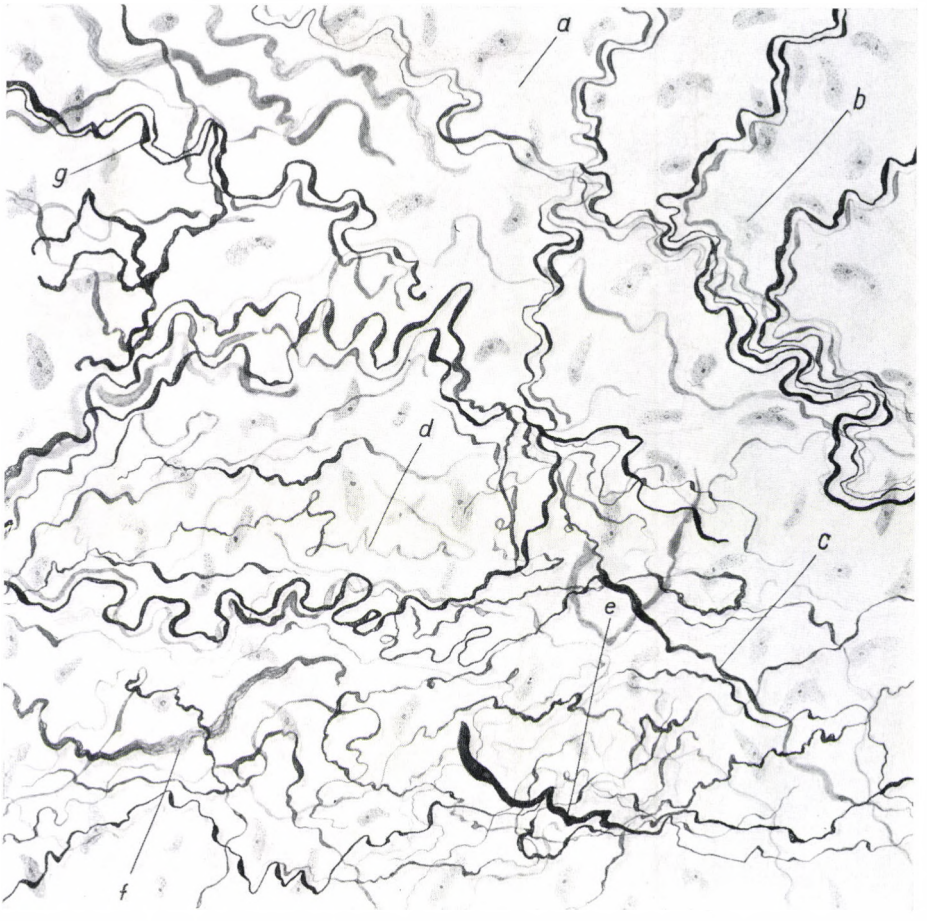

FIG. 153. *Ovis aries*. Nerve plexus in the aortic arch. (a) Connective tissue; (b) nucleus of connective tissue cell; (c) thick nerve fibre; (d) thin nerve fibre; (e) nerve fibre plexus; (f) neurofibrils; (g) varix. Bielschowsky–Gros' method. Microscopic magnification 400×, reduced photograhpically to ½

densely that the host tissue is hardly discernible. In these larger plexuses the thicker, more intensely impregnating, gradually branching vagal fibres are mostly clearly distinguishable from the smooth undulating typical sympathetic fibres. It ought to be mentioned here that the large, lamella-like broadened portions so characteristic of the axons of the dog, pig, calf, buffalo and goat, are absent in the depressor fibres of the sheep. Here, too, are seen varices of variable dimensions but they do not interfere with the fibre's morphology, being homogeneous and having essentially no bearing on the axon's diameter (Fig. 153). The relationship of depressor fibres with the vessel walls may be outlined as follows. Part of the fibres branch off several times and the rami, crisscrossing each other, constitute

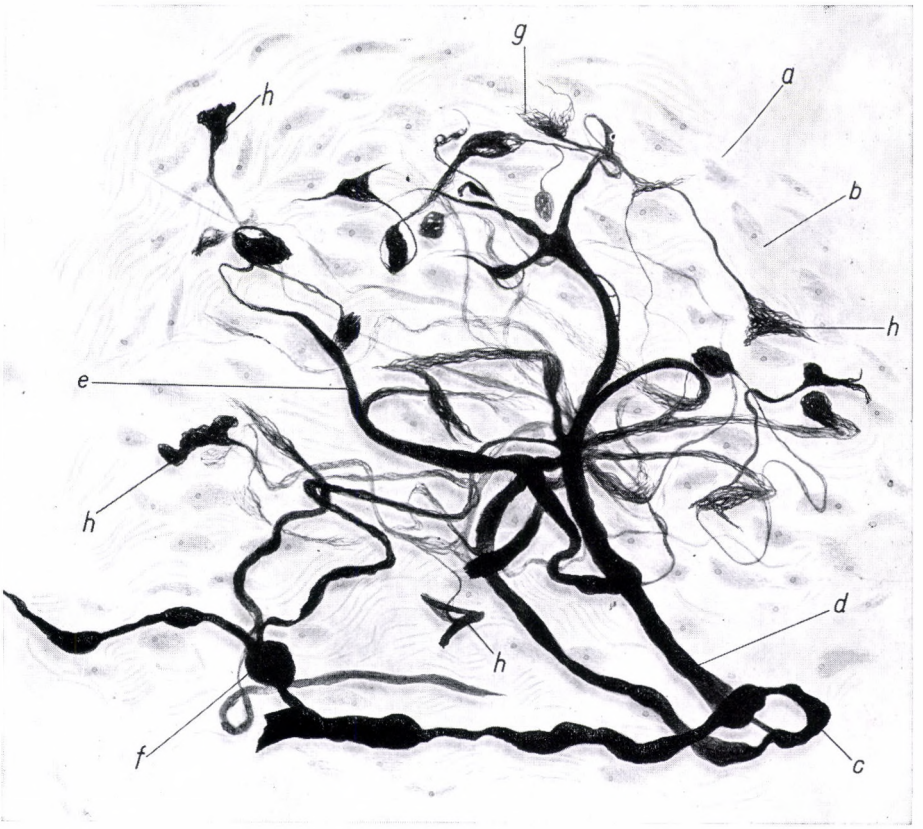

FIG. 154. *Ovis aries*. Nerve end plates in the wall of the aortic arch. (a) Connective tissue bundle; (b) nucleus of connective tissue cell; (c) axon; (d) main branch; (e) lateral branch; (f) varix; (g) neurofibrils; (h) end plate. Bielschowsky–Gros' method. Microscopic magnification 800×, reduced photographically to ½

an extensive, delicate, loose coil-like plexus, some fibres of which end in well-visible terminal bulbs or rings. The larger part of the fibres reach their destination groupwise, in bundles. Here they exit from the bundles singly or in pairs to constitute large coil systems, some of which are irregular, others slightly elongate and looser in structure. Again others, seen in a larger number, are well defined, roundish and denser in structure. In the latter, the ends of certain fibres are well visible (Fig. 154). The end formations are smaller or larger discs, some of which are more or less regular in shape, others elongate or chopped at the ends. The discs end freely and in their environment there are no end formations suggestive of the presence of interstitial cells or other special formations that were responsible for the conduction of impulses to the receptors.

Man (*Homo sapiens*)

The origin, descent and relationship with the jugular, vagal and sympathetic nerves of the aortic fibres supplying the aortic arch of man have been investigated by several authors. Yet all of them have failed to clarify or at least settle satisfactorily, this problem although it has been adequately elucidated in most of the animals. From the available experimental data Koch has drawn the following conclusions: "Beim Menschen ist bisher über den Verlauf der Aortafasern noch wenig bekannt. Auf Grund der Befunde erscheint es kaum möglich beim Menschen von einem eigentlichen Ramus aorticus zu sprechen. Die Aortennervenfasern dürften sich vielmehr auf verschiedene morphologische Nerven verteilen."* Thus it seems to be certain that humans also have aortic fibres, but only scanty data have been available on the site of the aortic arch's wall where they arrive with the vegetative fibres as well as on their relationship with the wall's histological layers. Of the studies performed on the human aortic arch, those by Seto (1937) should be mentioned separately. He demonstrated that thick myelinated fibres enter the wall of the human aorta and end in its adventitia in the form of neurofibrillar end plates. Seto's observations have been feasible in every respect, his results being derived by applying up-to-date techniques. Nevertheless, he, too, left most details unclarified. In view of this, I devoted a thorough study to the nerve connections of the human aortic arch, simultaneously with my examinations on birds and mammals.

My primary aim was to describe the forms of receptors and fine structures. Secondly, I wished to specify in detail the descent of aortic fibres, their modes of association with sympathetic fibres, the types of their end systems and the whereabouts of their terminations. As a matter of fact, this task seemed to be *ab ovo* intricate and time consuming, owing mainly to the lack of basic anatomical and neurohistological knowledge on the localization, path and termination of the aortic fibres in the vessel wall. Therefore I proceeded from my observations in mammals and cut the respective portions of the human aortic arch, supposed to comprise the end systems, into small pieces, carefully marking their precise localization. Subsequently, I sectioned and impregnated all blocks supposed to be of interest. Naturally, as in previous studies, depressor endings were found to be restricted to the area at the interface between the tunica media and adventitia, I impregnated only the sections obtained from that part of the wall. This was carried out with both the anterior and the posterior surface of the aortic arch's wall. I believe it does not need special explanation, how tiring and time-consuming this work had been, particularly when the frequent failures of impregnation are considered. Yet finally I succeeded in demonstrating that the aortic fibres' plexuses and end systems localize in the area enclosed by two roughly parallel lines drawn downwards from the truncus brachiocephalicus communis, and upwards from the liga-

* "In man, the descent of aortic fibres has been as yet inadequately known. On the basis of the available observations, the presence of a true ramus aorticus does not seem to be very likely. Aortic fibres may be distributed rather in various morphologic nerves."

mentum arteriosum Botalli, not including two narrow wall portions bordering the convexity and concavity of the arch. The bulk of endings was found in the area directly facing the ligamentum arteriosum. On the arch's posterior surface, relations were roughly similar to those found at the anterior one.

The nerve fibres, seen to intertwine the receptor areas, arrive from the periarterial connective tissue and enter the wall's convex side in the form of mixed bundles of varying dimensions. Here in the fat tissue they arrange in bundles so that the thick aortic fibres gradually separate from the fibre systems forming the mixed bundles. The latter gradually continue in branches, in some of which the aortic fibres still pass on in association with sympathetic fibres, whereas in others only the strongly impregnating thick aortic fibres are seen. Yet before this differentiation ensues, branch systems constituted by the two kinds of fibres join to form rich plexuses. Then the fibres constituting the plexuses gradually begin to arrange in a manner that fibres of similar origin approach each other and form groups. In this arrangement the thin, smooth vegetative fibres form thin branches which either pass along the vasa vasorum or at some distance from them pass through the adventitia and go towards the media. The thick fibres descend in an undulating fashion in bundles so that fibres of varying thickness go repeatedly across each other, then after a larger or smaller winding they return to the bundles. A specific feature of these fibres is their markedly varicose appearance and the formation of longer or shorter homogeneous plates in their descents.

Frequently, the three or more fibres constituting a bundle diverge from each other, become undulating and finally form an elongate loose coil. Not infrequently the end systems of two bundles meet and associate by forming an extensive coil system in which the fibres' endings are well seen (Fig. 155, Plate III/c, p. 237).

Also, human aortic fibres are characterized by varicosity and marked thickness. Sometimes the varices are so large as to show a cell-like appearance, sometimes again they are elongate and tapering. The aortic fibres are also characterized by alternate narrowing and thickening, either assuming their original calibre or, as common in mammals, even exceeding it. A further typical feature is the frequent branching, giving rise namely in the terminal portions to rich ramifications arising occasionally opposite to other similar systems. In the descent of these systems, neurofibrillar plates are frequently present, while infrequently very delicate, smooth fibre branchings also occur. The end fibres terminate in dense knots or neurofibrillar end plates which, as judged by their structures, may be considered the end organs of nerve in end connections (Fig. 156).

The aortic fibres are myelinated. In the majority of the cases the myelin sheath appears sharply also in impregnated preparations, naturally only on the main fibres. There is no myelin sheath on the secondary fibres and end fibres exiting in large masses from the main fibre. Both secondary fibres and end fibres are beaded and very rich in intermediary neurofibrillar plates (Fig. 157). The neurofibrils pass parallel in the intermediary plates and end plates and form networks in the latter (Fig. 158).

The ramifications of side branches are in general rich. In fortunate cases, tangential sections may show the entire end system of a side branch. In such cases, as



FIG. 155. *Homo*. Terminal system of nerve fibres in the aortic arch. (a) Nerve fibre; (b) varix; (c) myelin sheath; (d) neurilemmal nucleus; (e) neurofibrils; (f) nerve fibre plexus. Bielschowsky–Gros' method. Microscopic magnification 800×, reduced photographically to ½

shown in Fig. 159, the secondary fibre exiting from the main fibre gives off branches repeatedly, resulting in an enormous and structurally almost unique system of intermediary and terminal neurofibrillar plates linking the side branches with certain larger portions of the wall. In these end systems the appearance of neurofibrillar end plates is typical. Actually they are independent neurofibrillar networks not associated with similar plates and linking independently with the elements of the host tissue, viz. with the outer surface of the media. This is convincingly shown by the microscopic picture. There is no additional peripheral reticular system which would play a role in stimulus conduction, and whose multipolar cells—as claimed by certain authors—would anastomose and conjugate, like Cajal's interstitial cells, partly with the sympathetic and partly with the parasympathetic fibres

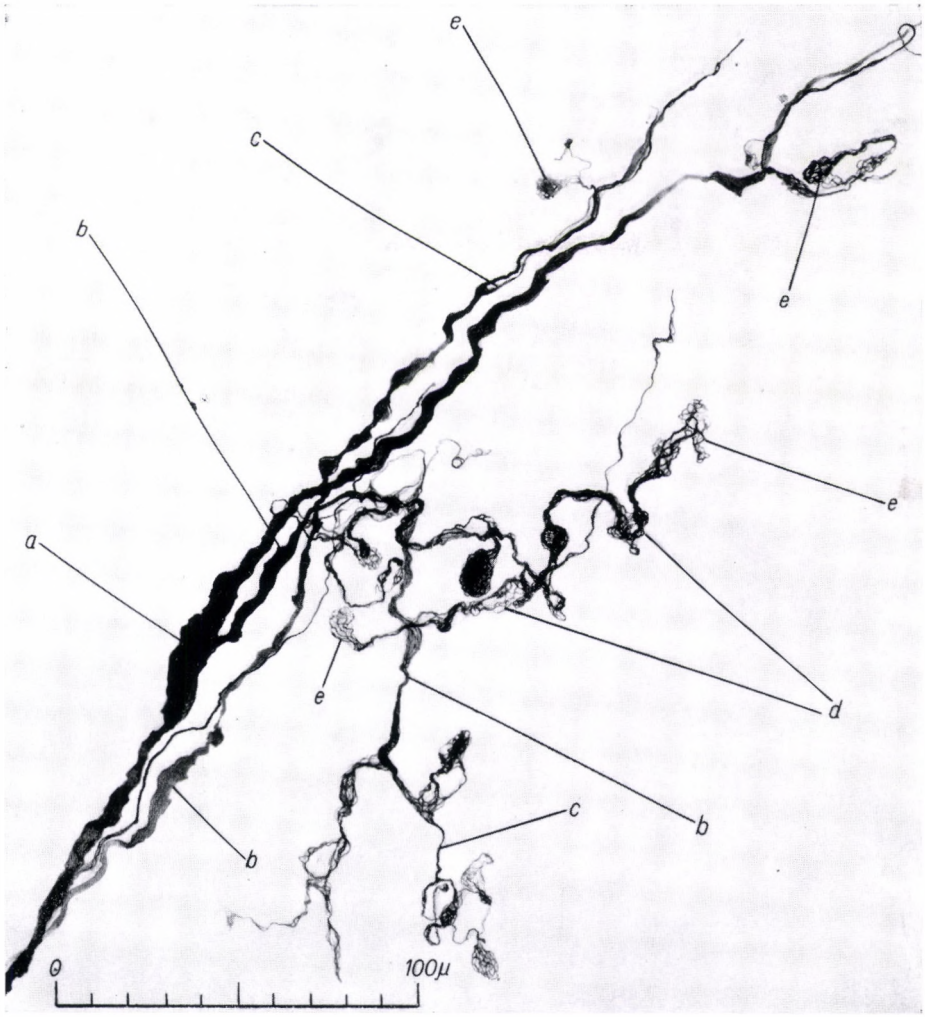

FIG. 156. *Homo*. Aortic arch; pressoreceptors in the adventitia. (a) Main branch; (b) side branch; (c) end branch; (d) intermediary plate; (e) end plate. Bielschowsky–Gros' method. Microscopic magnification 750×, reduced photographically to ½

(Fig. 159). The validity of this statement is amply proven by the preparations obtained from the aortic arch of individuals of different ages. In these preparations it is obvious that the fibres and the intermediary and end branches arising from their ramifications, as well as the end plates, are independent of each other. There are no anastomoses between the fibres or between the intermediary and end plates either. If a certain connection appears to exist between the individual fibres constituting the fibre systems, it is in every case a plexus and never a reticulum. Natu-

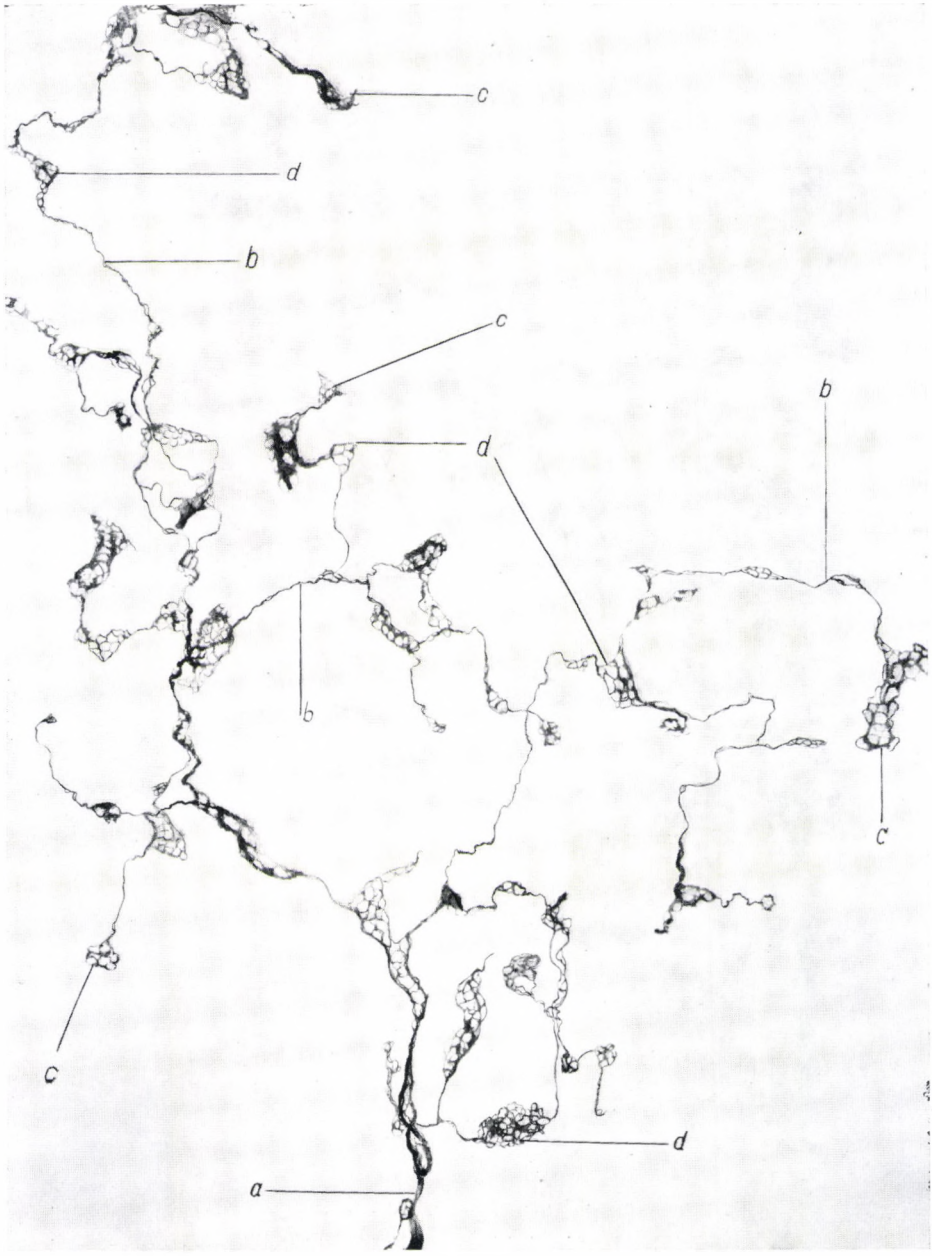

FIG. 157. *Homo*. Aortic arch; terminal system of nerve fibre in the adventitia. (a) Collateral; (b) end branch; (c) end plate; (d) intermediary plate. Bielschowsky–Gros' method. Microscopic magnification 1350×, reduced photographically to ½



FIG. 158. *Homo*. Aortic arch; nerve terminal system in the adventitia. (a) Nerve fibre; (b) intermediary plate; (c) neurofibrils; (d) end plate; Bielschowsky–Gros' method. Microscopic magnification 1420×, reduced photographically to ½



FIG. 159. *Homo.* Aortic arch; nerve fibre terminal system in he adventitia. (a) Nerve fibre; (b) neurofibrils; (c) varix, (d) intermediary plate; (e) end plate; (f) connective tissue; (g) nucleus of connective tissue cell. Jabonero's method. Microscopic magnification 300×, reduced photographically to $^2/_3$

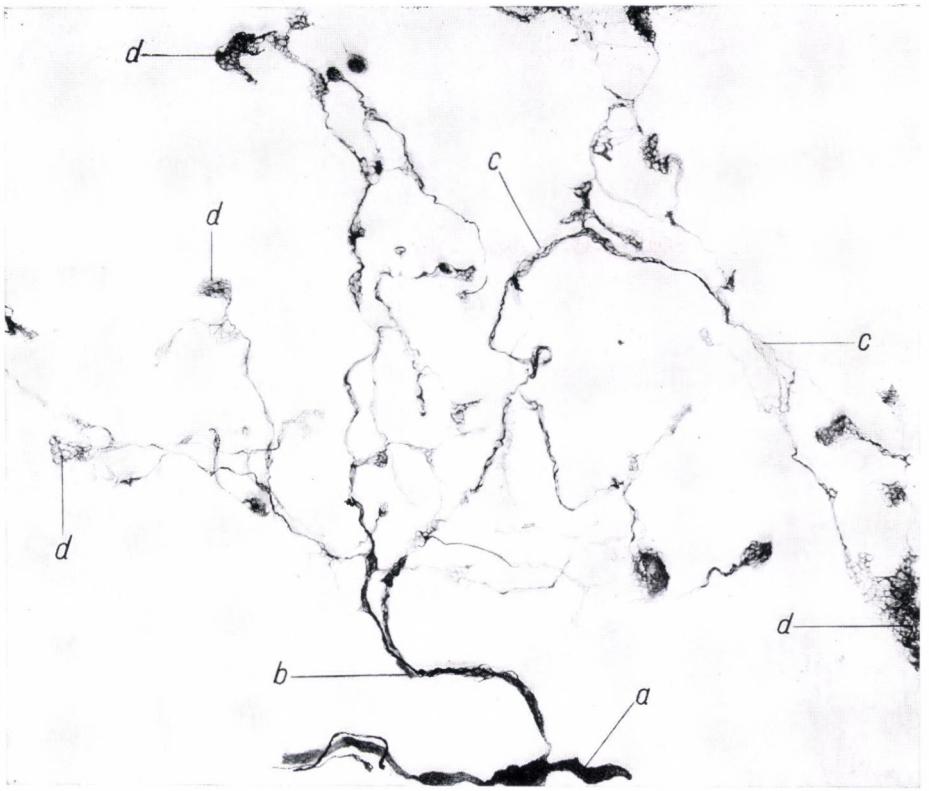

FIG. 160. *Homo.* Aortic arch; nerve fibre terminal system in the adventitia. (a) Main fibre; (b) side branch; (c) intermediary plate; (d) end plate. Bielschowsky–Gros' method. Microscopic magnification 900×, reduced photographically to ½

rally, all the aspects discussed above and also those to be discussed below, apply exclusively to impregnated preparations. I have not worked myself with methylene blue in this particular field, as on the basis of experiences obtained with this method elsewhere I still advocate my earlier view that this method, inclusive of its several modifications, is unsuitable for the investigation of delicate nerve structures. In general, pictures obtained by staining with methylene blue are helpful and beautiful, yet—owing to the thickness of the sections and the diffuse nature of staining—they are entirely unsuitable for making visible the fine structures and end connections.

Side branches, delicate end branch systems as well as neurofibrillar plates or plate systems carried by their terminal rami appear occasionally in an unexpected richness and accomplishment. Such configurations are seen particularly frequently in the aorta of elder persons and mainly in those whose media contains a notable amount of sclerotic granules (Fig. 160). In preparations obtained from these subjects, end plates appear in such a large number as to form a kind of



FIG. 161. *Homo.* Aortic arch; nerve end plate system in the adventitia. (a) Main branch; (b) side branch; (c) neurofibrillar end plate. Bielschowsky–Gros' method. Microscopic magnification 1000×, reduced photographically to ½

coherent neurofibrillar veil in the host tissue. This is apparent in the upper part of the above figure. Naturally this is only an illusion as the proper use of the micrometer screw would in every case convince the observer that the seemingly associated end plates are actually arranged at different levels, belong to different end rami and never anastomose with each other.

The shape and size of end plates are dissimilar. There are smaller as well as larger ones; in general they resemble ivy-leaves in shape, but also elliptic and oval forms are frequently seen. Sometimes they are spaced at a distance from each other, sometimes closely. Undoubtedly, the plates actually form much larger groups than those seen under the microscope. In every case, it has to be considered that the tangential sections used in our examinations are very seldom parallel with the vessel wall, however carefully they are cut. Thus in the majority of the cases the end plates are either transfixed or separated from each other by the cutting operation. Only exceptionally are sections obtained which are not only properly cut but also properly impregnated, thus revealing the end branch system and all associated neurofibrillar end plates with sufficient clarity (Fig. 161). One of these exceptionally successful preparations is shown in the previous figure: the neurofibrillar interconnections of the end system are clearly apparent. In our opinion, any further account of this figure would be superfluous as to the expert's eye it shows everything that can be shown at all by a histological preparation. The picture speaks for itself, giving a detailed information not only to the neurohistologist but to all those concerned with the structure and function of the nervous system. Also, it clearly shows how incomparably delicate and sensitive are the structures which register the pressure in the vessels' walls.

After having described the descents of aortic fibres, the forms, structures and arrangements of endings, we shall further discuss their location according to the histological layers of the wall, the depth of their penetration into the vessel wall and their relationship with the different elements of the host tissue. In answer to the first question we may state that the end plates localize exclusively in the adventitia, mainly at the site of its conjugation with the media. Naturally, there are also pictures giving the impression that the thick fibres and the associated end plate systems would localize in the media. This is, however, but an illusion proving that the border between the adventitia and media is not straight, the latter protruding in the former here and there in the form of islands, carrying also the sensory end systems. As to the second question, viz. the position of end plates, they appeared to be flat and to attach to the vessel wall with their flat surfaces.

Pathological Alterations in Human Aortic Fibres

Aortic fibres and also the end organs are characterized by the presence of varices of conspicuously large size, intermediary plates and homogeneous beads. Sometimes these appear in such large numbers that they give the impression of being pathological. This was suggested also by a survey of preparations obtained from the



FIG. 162. *Homo.* Aortic arch; nerve plexus in the adventitia. (a) Main branch; (b) side branch; (c) intermediary plate; (d) neurofibrils; (e) end branch; (f) end plate; (g) varix. Bielschowsky–Gros' method. Microscopic magnification 450×, reduced photographically to ½

aortic arch of persons of different age, sex and different causes of death. Since, however, particularities may be present at any age and in both sexes and considering that a similar variability has also been observed in many mammalian species, the pathological nature of these alterations has no satisfactory experimental support. Nevertheless, particularly in the wall of sclerotic aortic arches from elderly people, there are frequently fibre end formations whose origin seems to be closely associated with certain histological lesions clearly recognizable in other tissue elements of the vessel wall. Of these we mention first the marked calcification frequently seen in the form of dense granules and concretions appearing in a black colour in preparations impregnated with silver. Although the bulk of calcification appears in the tunica media, there is no doubt that this process takes place in the outer adventitia, although less obviously. In my opinion, this important physiological process gives rise to the variable and unusual nerve end systems seen in large masses particularly in the aortic wall of elder persons (Fig. 162). As shown in the figure, some of them form such complicated systems that their precise analysis is practically impossible. It is, however, obvious that the patterns formed by the ramification of the two thick fibres, the association of their branch systems, the unusual processes of the fibres as well as the forms and structures of terminations have developed under a certain local influence. The end system shown in the next figure (Fig. 163) is just as common as the former. It represents the end system of a relatively thin, delicately fibrillar depressor fibre, showing all its typical features as well as many others indicating the influence of external factors on the system's development. Also, the picture shown in Fig. 164 should be considered pathological. The shapes of the fibres as well as their form and the interconnection of the end plates all testify to the influence of alien factors on the system.

In some cases the degeneration of the end system can be precisely estimated. This phenomenon has been encountered mainly in elderly people (exhibiting signs of degeneration also in the thick fibres themselves), disintegration being particularly obvious mainly in the end systems. Degenerating end plates fall asunder in granules, but the end branches belonging to them remain more or less intact. The fact that degeneration has taken place is indicated not only by the pattern but also by an unusually strong impregnation of all elements in the system. In such cases, at the ends of terminal fibres are seen neuroplasmic granules and knots of variable size, impregnating deep black, and sometimes still suggesting the shape and structure of an end system. The fact that these systems showing an alveolar structure and black knots are actually conglomerations derived from the disintegration of nerve fibres is proved not only by the marked argentophilia but also by the fact that frequently the degenerating fibre systems are accompanied by decaying aortic fibres which, owing to degeneration, themselves display a marked affinity for silver nitrate. In these cases the depressor fibres had either completely or partly degenerated. The cause of these phenomena cannot be clarified by the available neurohistological methods. In any case it was repeatedly found that many clarified granules as well as conglomerations of varying sizes were scattered in the media of these aortic arches. It may well be supposed, therefore, that a mass depo-



FIG. 163. *Homo.* Aortic arch; nerve fibre terminal system in the adventitia. (a) Main fibre; (b) side branch; (c) end branch; (d) neurofibrils; (e) intermediary plate; (f) end plate; (g) varix. Bielschowsky–Gros' method. Microscopic magnification 800×, reduced photographically to ½

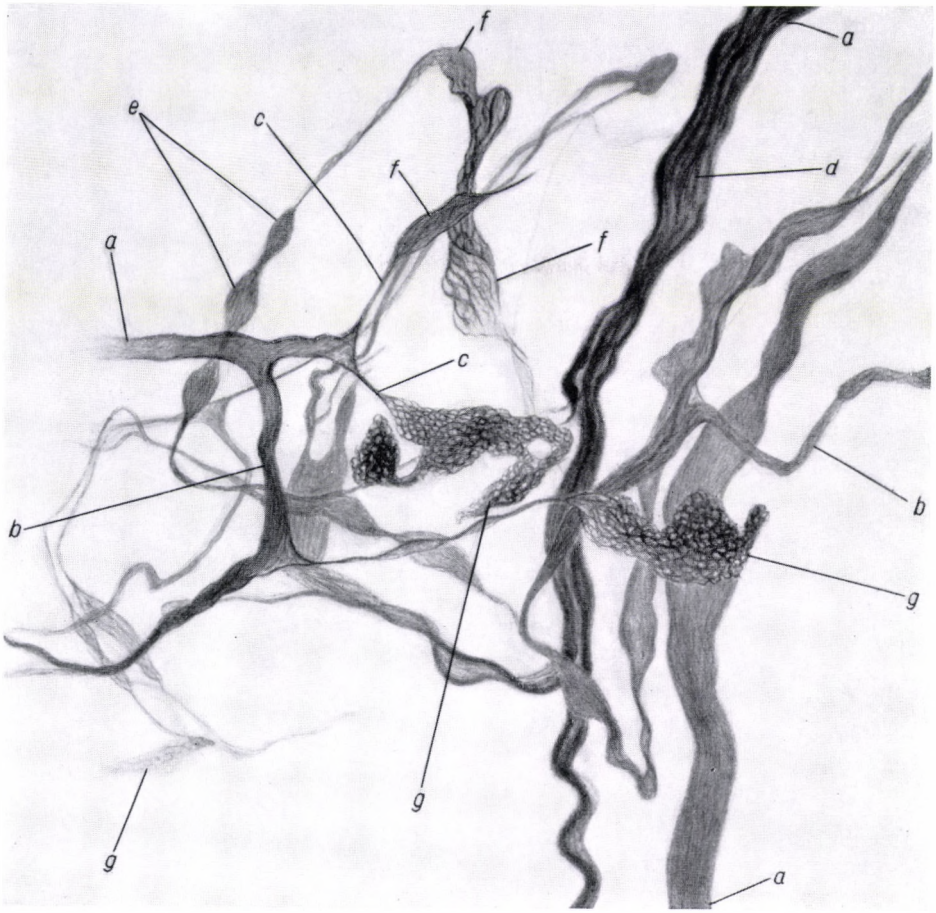

FIG. 164. *Homo.* Aortic arch. Nerve end plexus in the adventitia. (a) Main branch; (b) side branch; (c) end branch; (d) neurofibrils; (e) varix; (f) intermediary plate; (g) end plate. Bielschowsky–Ábrahám's method. Microscopic magnification 600×, reduced photographically to ½

sition of calcium in the arterial wall also influences the structure of the sensory end systems. This is also implied by the fact that in such cases signs of degeneration can also be seen in the vegetative ganglia localized in the periarterial connective tissue.

Cholinesterase Activity in the Aortic Arch

For the examination of cholinesterase activity, the pig's aortic arch proved to be the most suitable model, partly because it was easily accessible immediately after the animal's death and partly because the particular structures of fibres and

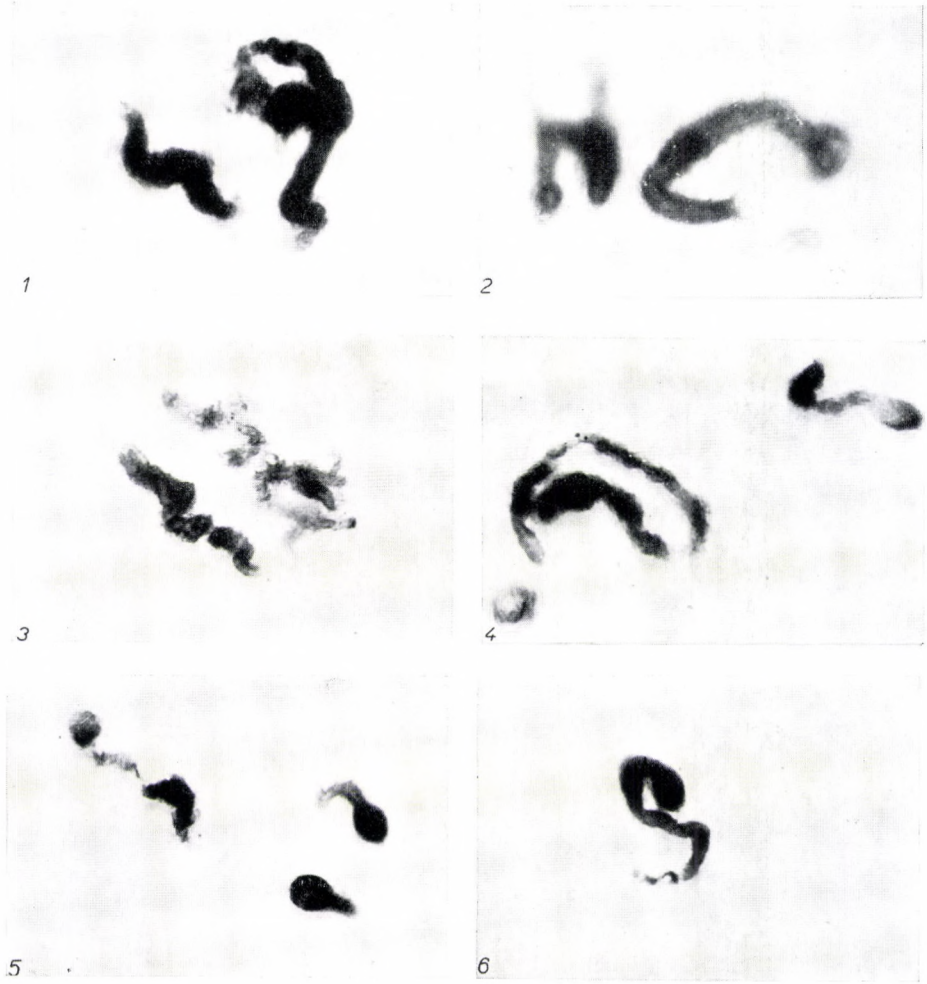

FIG. 165. *Sus scrofa domestica*. Aortic arch; cholinesterase activity in the adventitia. Pictures 1—6. Microphotographies. Koelle–Friedenwald–Gerebtzoff's method

end plates allowed firm conclusions to be made on the respective nerve fibres and end organs. This aspect deserves special consideration. In my opinion, at least in neurohistologically unclarified fields, neurohistological examinations and cholinesterase assay should be conducted in parallel. An objective evaluation of the cholinesterase assay pictures requires a profound knowledge in comparative neurohistology. In fact, pictures obtained by cholinesterase assay must correspond precisely to those obtained by impregnation. In areas where certain end apparatuses, irrespective whether motor or sensory, are either unknown or are not

demonstrable by the available methods of neurohistology, the pictures obtained by cholinesterase assay must be regarded as artefacts.

The examinations were performed with the method of Koelle and Friedenwald, as modified by Gerebtzoff. The buffer was adjusted to pH 5, and incubation took place at 40°C for 24–28 hr. The results were surprising. Many pictures were obtained in which the shapes and descents of aortic fibres were typical for the aortic fibres of the pig. These pictures indicate that cholinesterase activity, viz. acetylcholine production takes place also around the aortic fibres and their end systems. Repeated attempts resulted in pictures which were almost entirely identical with those obtained by impregnation (Fig. 165).

CAROTID SINUS (SINUS CAROTICUS)

The carotid sinus is an onion-shaped dilatation of the internal carotid artery's initial portion. Greater attention to its structure and function was attracted after Hering (1927, 1932) who demonstrated that the sinus reflexes (known as Hering's sinus reflexes) discovered by him are associated with the carotid sinus' wall. The nerve connections of that site had then been unknown to Hering but later histological examinations proved that he had been right in locating the receptors of sinus reflexes in the wall of the carotid sinus. The validity of Hering's hypothesis based on physiological experiments was confirmed later on also by F. de Castro and, almost simultaneously, by Sunder Plassmann. Their neurohistological studies in animal and man revealed that the wall of the carotid sinus comprised uniformly rich receptor areas whose very richness, together with their structure and interconnections, were suggestive of their suitability to initiate the sinus reflexes of Hering through the mediation of the effects of internal or external pressure on the sinus' wall. As it is known, one of Hering's sinus reflexes causes hypotension; another causes bradycardia.

In this institute, nerve connections in the wall of the carotid sinus have been repeatedly examined on a variety of materials. Part of our observations has already been published (1941, 1949). In this volume we summarize the results of our studies in birds, dog, pig, horse, calf, sheep and man. We describe first our observations on birds, next those on various mammals and finally on man.

Birds (Aves)

As shown earlier (Muratori, 1934; Nonidez, 1935), birds have no carotid sinus. In this context the carotid sinus is mentioned only to specify the location, viz. the area where up to now endings of the depressor fibres supplying the carotid area have been found. According to Muratori and Nonidez, this site is at the branching of the common carotid artery, viz. at the location where it divides into the external and internal carotid arteries. In birds, other names have been used to designate these branches but the main branchings in the head (carotis externa and carotis interna) are the same in birds as in all vertebrates higher than fishes.

The depressor fibres which, according to Nonidez go to the bifurcation in the form of a separate depressor branch, come partly from the vagus and partly from the nervus glossopharyngeus, but there are also particularly thin and smooth fibres which obviously belong to the fibre system of the jugular sympathetic nerve. Muratori and Nonidez found that these mixed nerve branches enter the carotid bifurcation and also end therein. Some of them, obviously derived from the vagus or the glossopharyngeal nerve, are thick, alternately broadening and narrowing, thus showing a typical "depressor" histological character. The thick fibres, accompanied by thin ones, branch over a part of the adventitia, ending partly in its inner portion and partly in the media, some of them even entering the intima. According to the descriptions and drawings of Nonidez, their terminals are smaller end knots or rings, attached to the nerve fibre system by very thin end fibres.

In this institute the localization and structure of depressor fibres in the avian carotid system have been examined on rich material: chicken (*Gallus domesticus*), turkey (*Meleagris gallopavo*), pigeon (*Columba domestica*), goose (*Anser domesticus*), wild goose (*Anser albifrons*), duck (*Anas domestica*), montagu's harrier (*Circus aeruginosus*), common coot (*Fulica atra*), gull (*Larus ridibundus*), common heron (*Ardea cinerea*), windhover (*Falco tinnunculus*). The study of frozen sections processed by various silver impregnation techniques yielded the following conclusions.

In the carotid bifurcation, at the origin of the internal carotid artery, masses of thick fibres forming a peculiar plexus are seen in the adventitia. These fibres run an undulating path and repeatedly criss-cross each other, in some places they wind and pass on in the opposite direction, then return and approach the media in the form of a coil-like bundle. At the border, i.e. inside the media, they start to ramify in a fashion seen neither in any other vascular segment, nor indeed in the entire area of the peripheral nervous system. The following happens: the thick fibre covers a fairly long distance without showing any obvious peculiarity in its appearance or structure; it impregnates homogeneously, its margins are smooth, it contains no neurofibrils and it is non-medullated. Later it abruptly divides into numerous delicate branches. These fibres pass on closely together, intertwine and generally speaking form a very long narrow plexus which may well be considered a reticulum by those inclined to the "reticular concept". Nevertheless, in every case, thorough examination under high magnification has convinced us that it is a plexus and not a reticulum. The parallel plexuses may be followed over a long distance but it also happens that some of them return in the area of the undivided main fibre and passing over it, the individual secondary fibres terminate separately. The greater part of delicate fibre bundles passes in a circular manner in the adventitia, i.e. media, and innervates it in a stratified fashion (Fig. 166). Concerning the individual thin fibres and the end fibres formed by their gradual narrowing, our preparations have shown that they pass circularly in the smooth muscle over a long distance, then part of them terminates in clearly visible, triangular plates which usually stain densely. There are also end fibres whose delicate thin terminal branches continue in small circular neurofibrillar nets. As the end system of each thin fibre comprises several terminal fibres, some pictures give

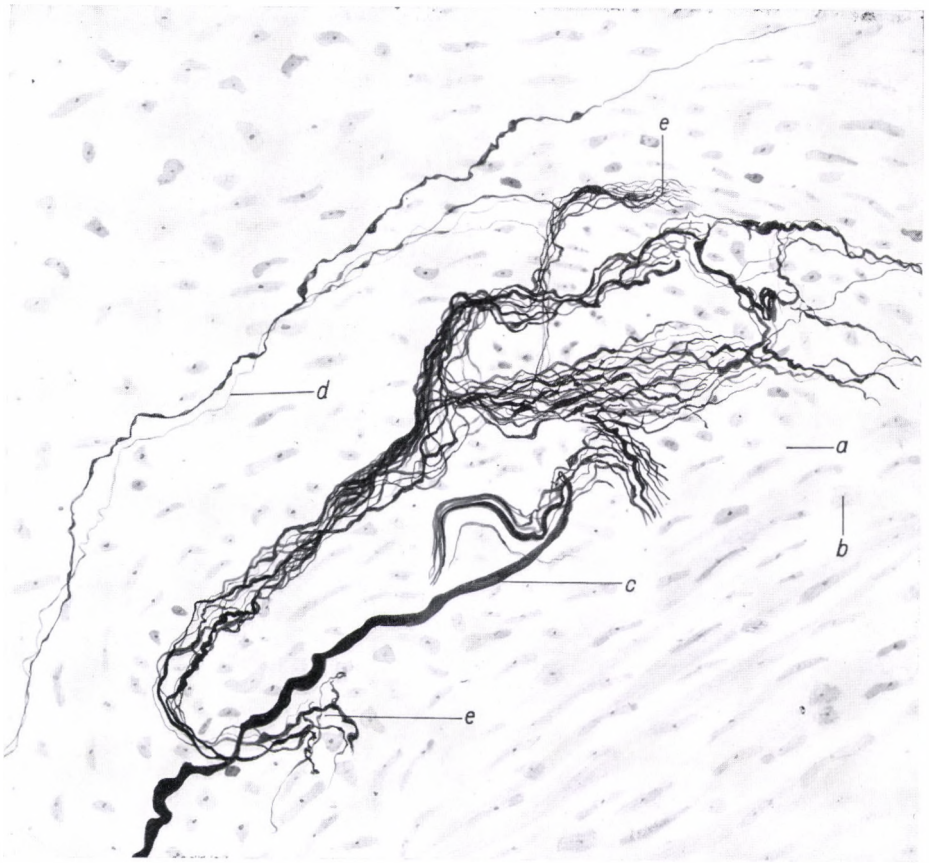

FIG. 166. *Circus aeruginosus.* Arteria anonyma; nerve end plexus in the adventitia. (a) Connective tissue; (b) nucleus of connective tissue cell; (c) thick nerve fibre; (d) thin nerve fibre; (e) nerve end plexus. Bielschowsky–Ábrahám's method. Microscopic magnification 600×, reduced photographically to ½

the impression that a coherent veil-like neurofibrillar net extends over a certain part of the smooth muscle. This again is illusory, for the individual end rami and end plates seen within the coils are independent, neither of them anastomosing with each other. These observations do not agree with the descriptions of Nonidez. To bring these dissimilar views in harmony would be beyond the scope of this book. Nonidez examined the cervico-thoracal region of one-day-old chicks in serial sections, using the method of Cajal. We impregnated the vessels of adult birds in frozen sections. The pictures published in this volume were all made from single sections, this being exclusive of all errors that may result from the misinterpretation of serial sections and the combinative drawings compiled from them. In any case, further examination is required to eliminate the discrepancies between our experimental results and those of Nonidez, and to bring them in harmony with each other.

Mammals (Mammalia)

The carotid sinus of mammals is a dilatation of varying size at the origin of the internal carotid artery, immediately at the beginning of the bifurcation. Its wall is usually thinner than is the arterial wall elsewhere. Its histological structure corresponds to that of an ordinary cephalic artery with the difference that its adventitia is somewhat thicker and in the region of the media the muscle cells are somewhat more sharply bordered against each other. It is very rich in nerves and vessels. Its nerve supply comes partly from the jugular sympathicus, partly from the sinus nerve which is one branch of the nervus glossopharyngeus and partly from the vagus. These fibres of different origins form a rich plexus in the outer layer of the adventitia. In the plexus there are conspicuously thick myelinated fibres, predominating mainly at the internal margin of the adventitia and forming here, as well as on the media's outer surface, very large sensory nerve end systems.

Dog (*Canis familiaris*)

The dog's carotid sinus is a well-developed roundish dilatation found at the initial portion of the internal carotid artery. Its histological structure corresponds to the generally known structure of the arterial wall with the difference that this part is much thinner than the other portions of the arteries of the head. Also, the adventitia and intima are thinner and in comparison to other portions the same applies to the media. The nerve fibres, arising partly in the glossopharyngeal, partly in the vagus nerve and partly in the jugular sympathicus seem to intertwine the adventitia nearly completely and form a rich plexus at the interface between the adventitia and the media. The plexus, constituted by thick as well as thin fibres, is in some places so rich that in tangential sections viewed by low-power magnification hardly anything is seen of the connective and smooth muscle tissues. In some places again the plexus is looser, consisting mainly of glossopharyngeal and vagus fibres of a particular appearance by which they may be distinguished at first sight from the fibres belonging to the sympathetic system (Fig. 167, Table V/c, p. 247). The thick fibres which come from the special receptors of the vessel wall are characterized by varicosity, this feature being, however, less conspicuous than in the case of the aortic fibres. These thick fibres of the sinus nerve carry beads of varying sizes on their axons, in some of them even neurofibrils can be clearly seen. A further character of these fibres is their frequent branching. The rami thus formed intertwine repeatedly, constituting rich end-fibre systems (Fig. 168). The end systems are constituted by terminal fibres and by end plates which appear in variable forms. The latter are variable in size, and length; sometimes they are dense, sometimes loosely fibrillar. The borders of the plates are either fimbriated and carry processes of varying lengths or are smooth and sharply bordered against the surrounding tissues. Neither the end branches nor the end plates anastomose. No specialized mediatory cells are seen, the end plates being attached directly to the connective tissue.

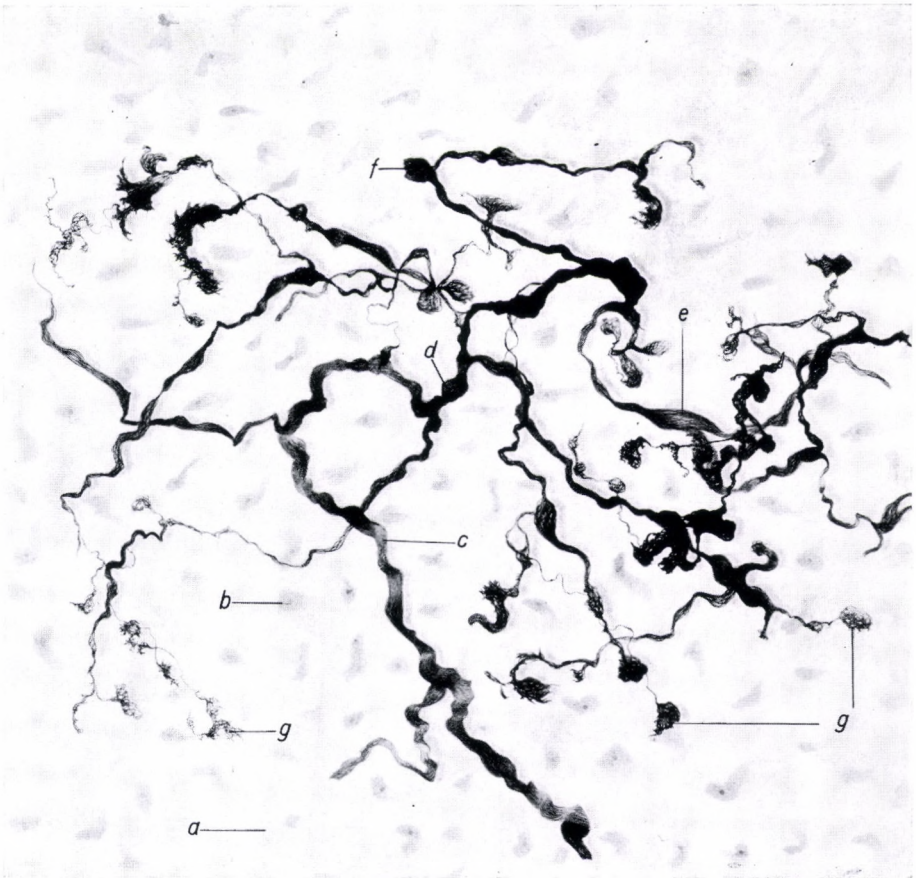

FIG. 167. *Canis familiaris*. Sinus caroticus; nerve fibre system in the adventitia. (a) Connective tissue; (b) nucleus of connective tissue cell; (c) axon; (d) varix; (e) neurofibrils; (f) intermediary plate; (g) end plate. Bielschowsky–Ábrahám's method. Microscopic magnification 600×, reduced photographically to ½

Pig (*Sus scrofa domestica*)

The pig's carotid sinus is slightly elongate, its lumen dilated and its wall relatively thick. In comparison with the other two layers, the media is thick and dense. The innervation is particularly rich. Perhaps due to the thickness of the muscle layer, systems of well-developed plexuses are seen not only in the adventitia but also on the outer surface of the media. The glossopharyngeal thick varicose fibres and the thin sympathetic fibres contribute equally to this plexus formation. The thick fibres branch off in profusion to form a complex plexus system in which both the branch systems and end plates are seen separately. The branches and end fibre systems bear a certain resemblance to the formations described in the

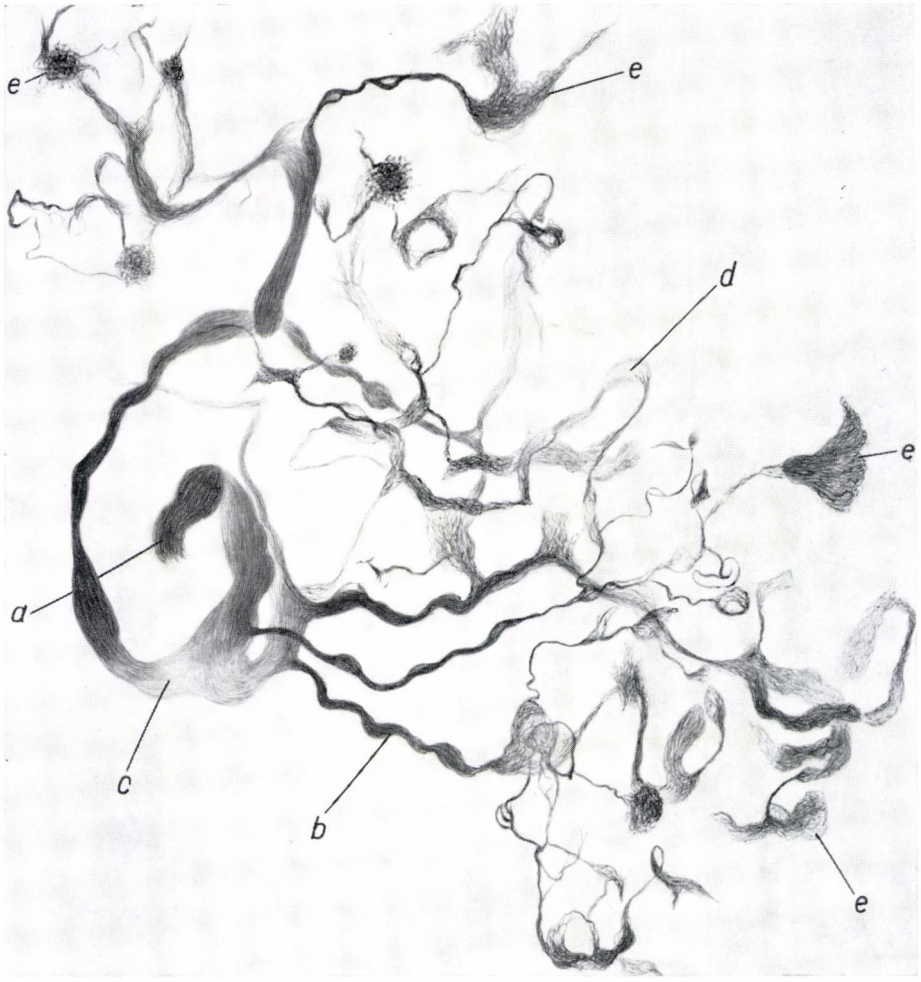

FIG. 168. *Canis familiaris*. Sinus caroticus. Nerve end plates in the adventitia. (a) Main branch; (b) side branch; (c) neurofibrils; (d) intermediary plate; (e) end plate. Bielschowsky–Ábrahám's method. Microscopic magnification 1300×, reduced photographically to ½

dog. There are, however, certain dissimilarities, particularly in the descent, grouping and structure of the fibres. By these structures the sensory nerve end systems of the pig are clearly distinguishable from those of the dog (Fig. 169). The end structures are in general uniform, distinction of types being hardly possible. Neither the end fibres nor the end plates anastomose and specialized stimulus-conducting connective tissue cells are not visible either.

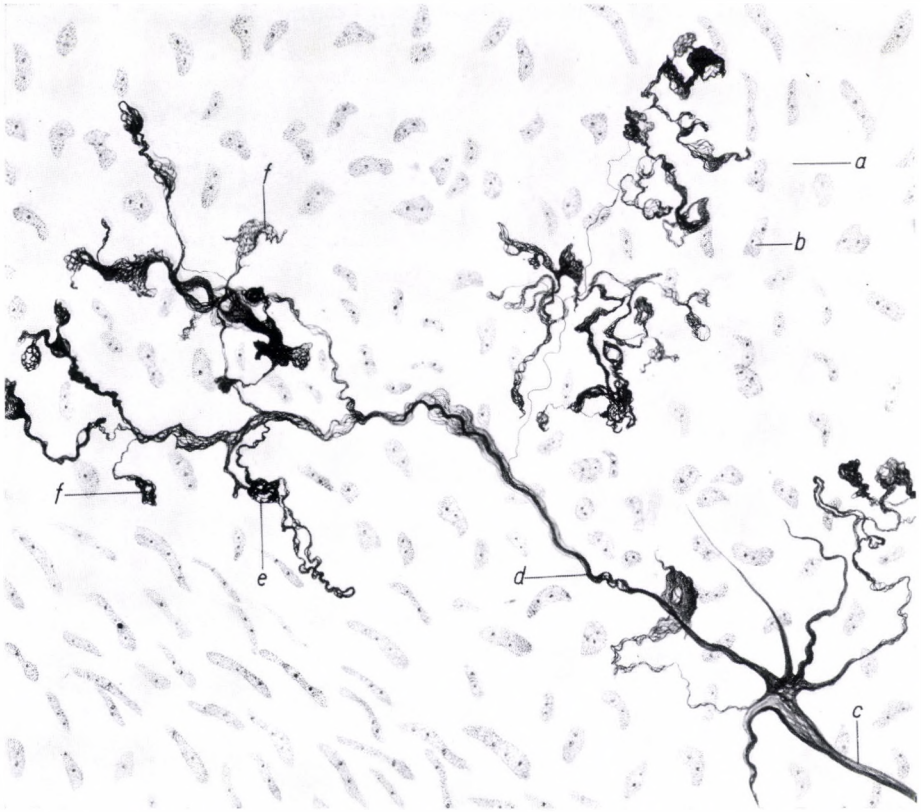

FIG. 169. *Sus scrofa domestica*. Sinus caroticus; nerve fibre terminal system in the adventitia. (a) Connective tissue; (b) nucleus of connective tissue cell; (c) main branch; (d) side branch; (e) intermediary plate; (f) end plate. Bielschowsky–Ábrahám's method. Microscopic magnification 600×, reduced photographically to ½

Horse (*Equus caballus*)

The carotid sinus of the horse is a larger dilatation. Its wall is thick and the adventitia well developed. Its nerve supply is particularly rich, perhaps in keeping with the physical activity of the animal. The plexus is rich comprising many fibres. This applies both to the glossopharyngeal and sympathetic elements. The majority of the fibres show features such as are seen in the depressor nerve but less distinctly than in the dog (Fig. 170). The varices are not large, being elongate and vague in appearance in some places. Neurofibrils can only exceptionally be detected in the axons. The thick fibres show here and there particular formations, specific for the horse, in that they arrange circles, then continue in straightly descending end fibres. Sometimes two or more such systems are seen in close coaptation. Essentially these systems are particular coil-like formations, some of them loose, inner-

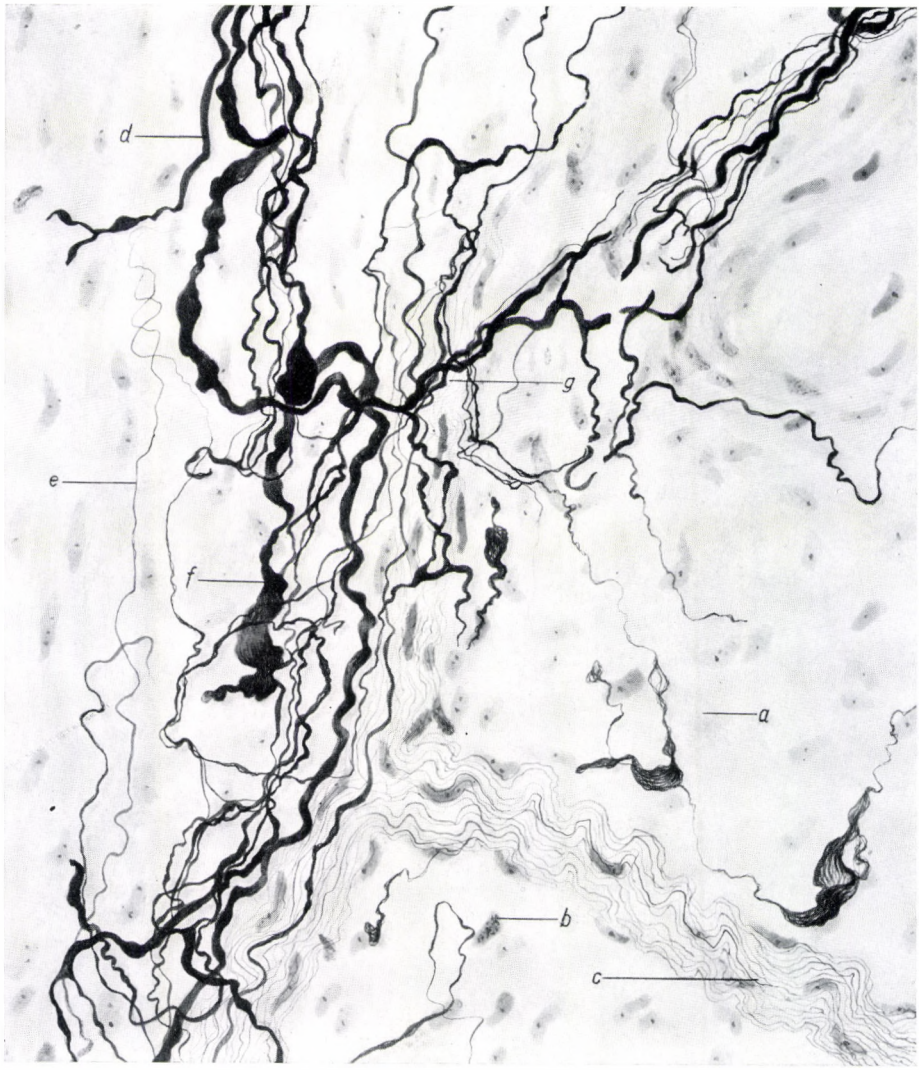

FIG. 170. *Equus caballus*. Sinus caroticus; nerve fibre plexus in the adventitia. (a) Connective tissue; (b) nucleus of connective tissue cell; (c) nerve fibre bundle; (d) thick nerve fibre; (e) thin nerve fibre; (f) varix; (g) nerve fibre plexus. Bielschowsky–Ábrahám's method. Microscopic magnification 300×, reduced photographically to ½

vating larger areas. In the preparations examined no specific nerve end formations were detected; moreover neurofibrillar end plates were only infrequently seen. In general, the end fibres derived by repeated branchings terminate in discs of varying size and shape, sometimes round, sometimes elongate. In most cases neurofi-

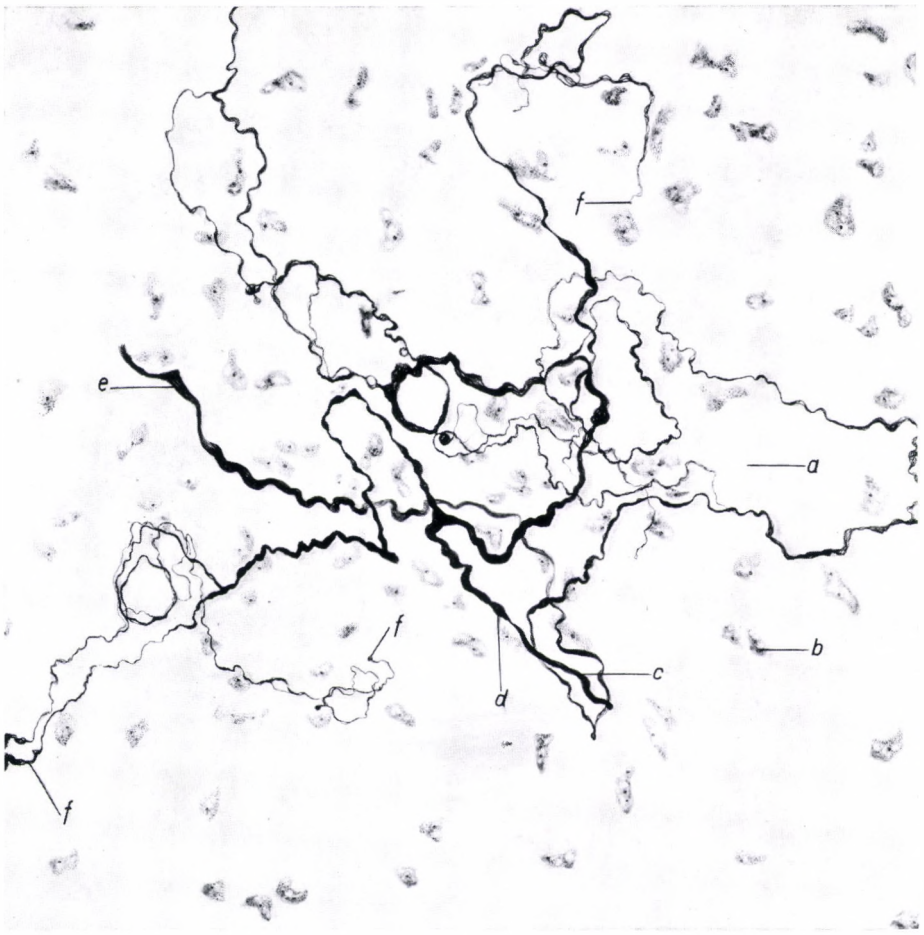

FIG. 171. *Equus caballus*. Sinus caroticus; nerve fibre plexus in the adventitia. (a) Connective tissue; (b) nucleus of the connective tissue cell; (c) axon; (d) varix; (e) neurofibrils; (f) nerve ending. Bielschowsky–Ábrahám's method. Microscopic magnification 400×, reduced photographically to ½

brils are clearly seen in both formations. Large masses of end discs are visible at the interface between media and adventitia, where they are attached to the connective tissue elements directly, without any special mediator cells (Fig. 171).

Calf (*Bos taurus*)

The carotid sinus of the calf, "occipital sinus" according to de Castro (1928), appears as an elongate distension at the origin of the occipital artery. The thickness of its wall corresponds with the large size of the animal, the muscle layer's struc-

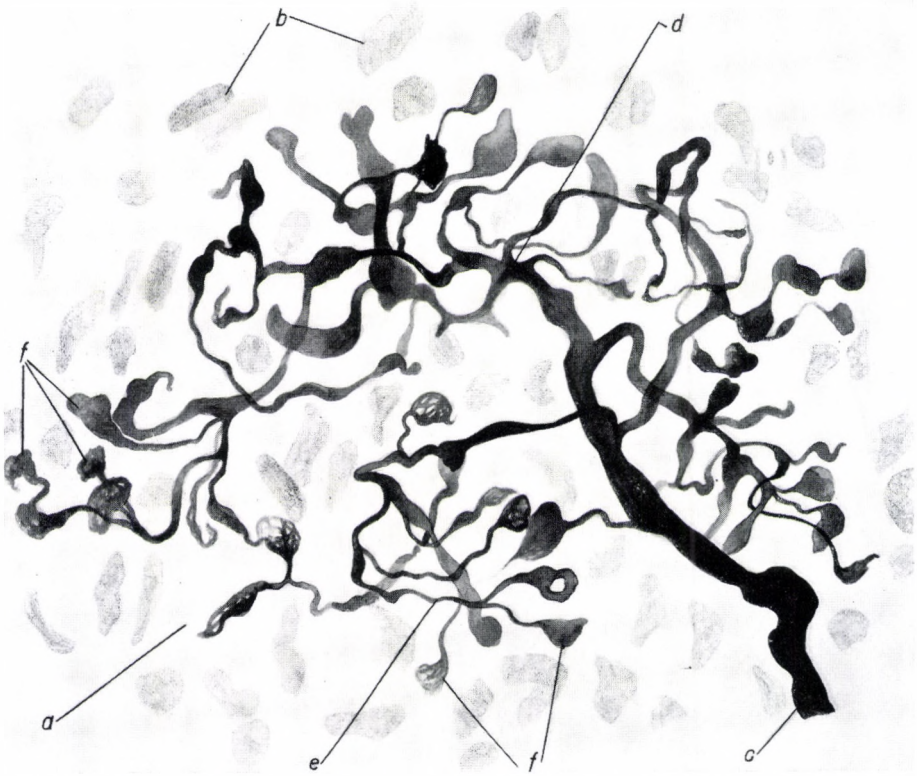

FIG. 172. *Bos taurus*. Sinus caroticus. Nerve end plate system in the adventitia. (a) Connective tissue; (b) nucleus of connective tissue cell; (c) nerve fibre; (d) branching; (e) end branch; (f) end plate. Bielschowsky–Ábrahám's method. Microscopic magnification 900×, reduced photographically to ½

ture is loose. In the nerve plexus, whose bulk is localized at the inner part of the adventitia, thick and thin fibres differ sharply from each other. This dissimilarity is particularly conspicuous at the sites where the end branch system of the thick fibres starts to form terminal structures. The sympathetic fibres joining the plexus are thin, undulating and are attached here and there closely to each other or, in other cases, they mingle with the end branches of the thick fibres to form a loose coil-like plexus. The end fibre system of the thick fibres is particularly dense. Occasionally the fibres accompany each other so closely that their individual pathways are hard to follow. It is, however, obvious that there are characteristic triangular broadenings on the branches and neither these formations nor the branches themselves show any anastomosis. End systems showing this structure may extend in a longitudinal direction constituting one of the typical end system patterns specific for the calf's carotid sinus (Fig. 172). In addition, another type of end apparatus of somewhat looser structure may occur, which carries fewer branches, numerous intermediary neurofibrillar plates and conspicuous varices. In these end

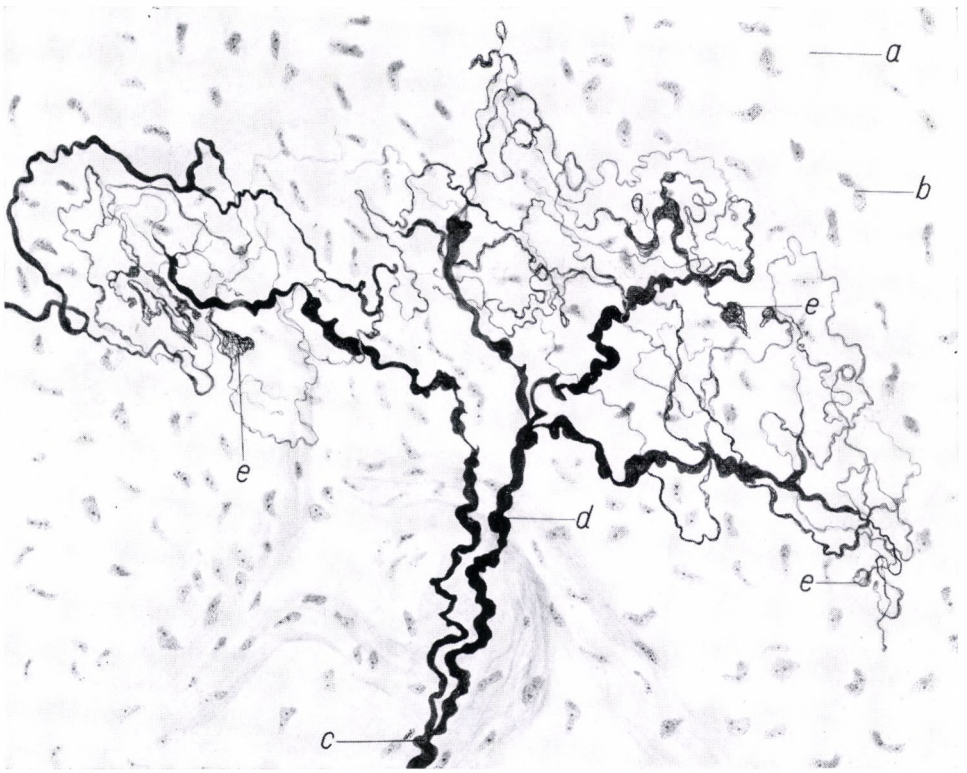

FIG. 173. *Ovis aries*. Sinus caroticus. Nerve end fibre system in the adventitia. (a) Connective tissue; (b) nucleus of the connective tissue cell; (c) axon; (d) varix; (e) end plate. Bielschowsky–Ábrahám's method. Microscopic magnification 600×, reduced photographically to ½

formations the terminals also are clearly defined. The latter are large neurofibrillar plates, which resemble both in shape and structure those described above for the calf's aortic arch. In every case, the end plates are found in the connective tissue where they are attached to the connective tissue elements directly without the interpolations of a special stimulus conducting cell formation.

Sheep (*Ovis aries*)

The carotid sinus of the sheep is less conspicuous than that of mammals described above. Its wall is thin; though the adventitia is relatively thick the muscle of the media is sparse. The adventitia is almost covered by undulating nerve fibres which form in some places loose, in others, dense coils. Of the fibres which constitute the plexus, the characteristically beaded thick fibres are particularly conspicuous. Their repeated rich branchings may be readily followed, particularly in

thicker sections. Many forms of branchings can be seen. Usually, the thick fibre sent to the vessel wall from the glossopharyngeal nerve via the sinus nerve divides first into two branches of similar size. Some of the branches thus derived continue in delicate end fibres which terminate in large plates or in smaller, clearly visible rings. In some cases thick fibres divide at once into several branches at the same site. All these branches show a very thin initial portion which then becomes thicker and forms characteristic varices like those seen on the thick fibres of the aortic arch (Fig. 173). There are, however, end systems also carrying many intermediary neurofibrillar plates and – perhaps owing to their position – also numerous end plates. In such cases, the neurofibrillar structure of the thicker branches is visible as well as the end plates of varying size, shape and structure at the end of the terminal fibres. Anyway, in such cases, we were also able to demonstrate clearly the functionally important fact that neither the end fibres nor the end plates did anastomose. The end plates are sharply bordered against each other and are attached flatly to the adventitial portion facing the media. In the carotid sinus of the sheep there are certain particular receptor apparatuses which are unique among the known receptors of the sinus region and which are sufficiently specific for the sheep that the picture of a single nerve end system would leave no doubt as to its origin. Essentially these formations are either single or, more usually, double end coils whose smoothly descending fibres end in delicate fibrillar end plates. Neurofibrillar structure is obvious in the fibres belonging to such end systems, both in the larger branches and in smaller ones arisen by their ramification. The fibres do not exhibit the usual depressor features, viz. the repeated alteration in thickness, their branching being gradual, the end fibres' structure readily detectable and the neurofibrils clearly visible (Fig. 174).

Man (*Homo sapiens*)

In man, the carotid sinus is constituted by an onion-shaped swelling (bulbus carotidis) of the internal carotid artery. This formation was known already by the ancient anatomists who considered it a pathological alteration. A more thorough physiological and morphological study of the human carotid sinus was started when, after some vain attempts, Hering demonstrated experimentally the localization of sinus reflex receptors in that portion of the wall. A further impetus to research was given by the discovery of another important receptor assembly, the glomus caroticum in the bifurcation, close to the receptor area of the sinus reflexes.

At present the wall of the carotid sinus is in general well known. All data available on its comparative anatomy and histology have been compiled in the book by Adams (1958), its physiological aspects in the physiology by Heymans and Neil (1958), in which are discussed thoroughly and systematically also the recent results concerning the electrical impulse activity of the sinus nerve fibres running from the area of the carotid bifurcation. However, even these two excellent books have left some problems unsettled, whose clarification requires further tenacious research.

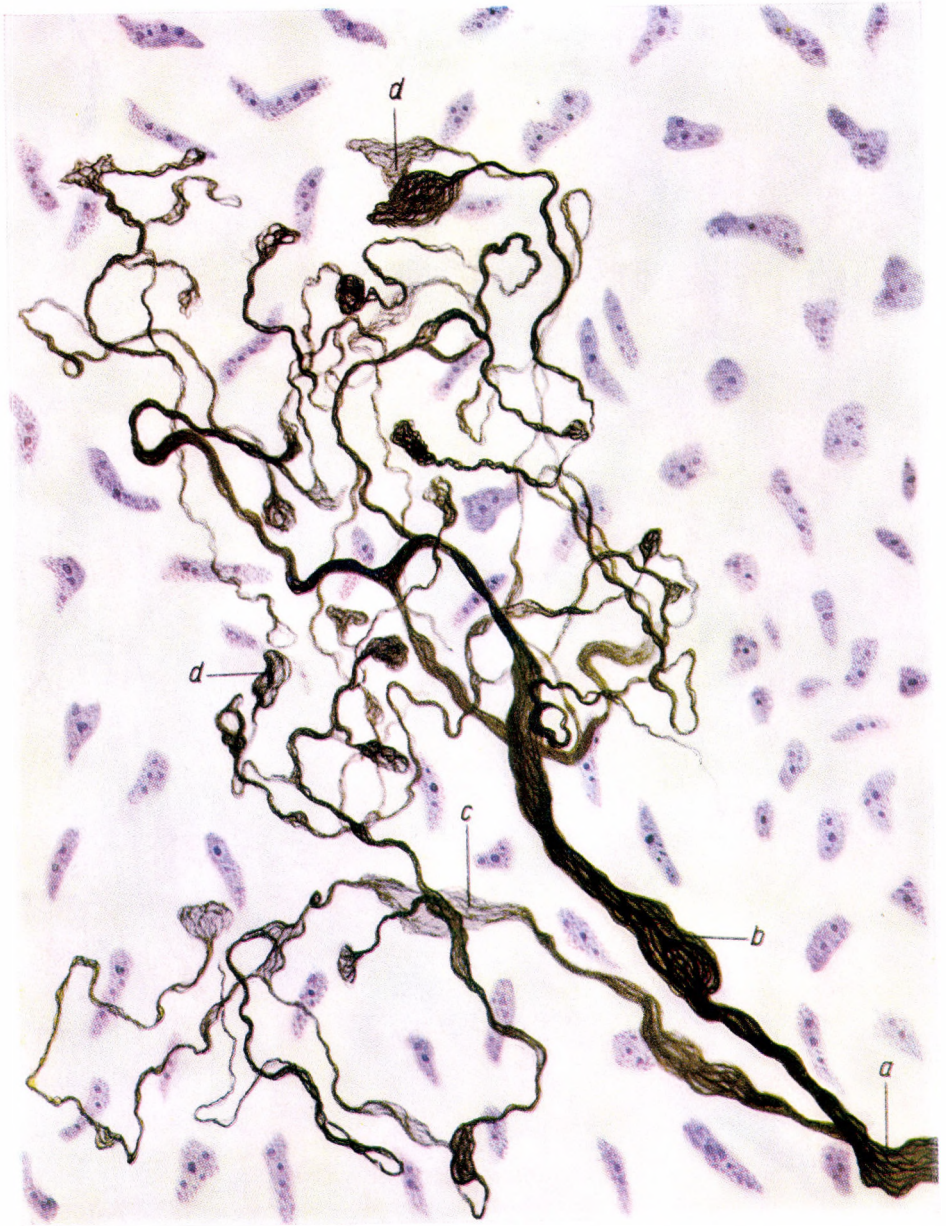

FIG. 174. *Ovis aries*. Sinus caroticus; nerve end plate system in the adventitia. (a) Axon; (b) neurofibrils; (c) intermediary plate; (d) end plate. Bielschowsky–Ábrahám's method. Microscopic magnification 900×, reduced photographically to ½



FIG. 175. *Homo.* Sinus caroticus. Nerve plexus in the adventitia. (a) Connective tissue; (b) nucleus of the connective tissue cell; (c) thick nerve fibre; (d) thin nerve fibre; (e) nerve fibre plexus. Bielschowsky–Gros–Cauna's method. Microscopic magnification 400×, reduced photographically to ½

Below we attempt to solve some of the problems encountered in the nerve connections of the human carotid sinus, viz. we try to describe how the nerve fibres entering the carotid sinus conjugate with the vessel wall. First we describe the normal conditions, then the pathological alterations in general and cardiovascular diseases in particular.

Histologically, the wall of the carotid sinus is identical with that of other arterial portions, but it is thinner and consequently its histological layers are also thinner except for the tunica media which, in comparison with the other two, is relatively well developed. The tunica adventitia is the richest of the three layers in nerve

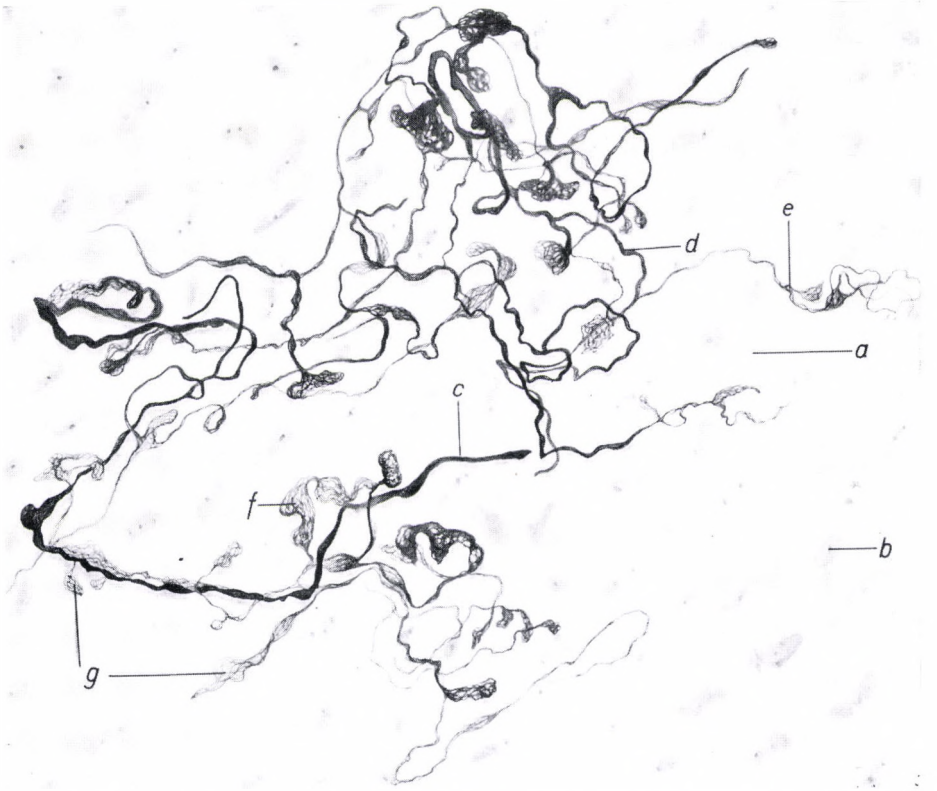

FIG. 176. *Homo.* Sinus caroticus; nerve end plate system in the adventitia. (a) Connective tissue; (b) nucleus of connective tissue cell; (c) main branch; (d) side branch; (e) end fibre; (f) intermediary plate; (g) end plate. Bielschowsky–Gros–Cauna's method. Microscopic magnification 600×, reduced photographically to ½

fibres. Relatively few nerve fibres are present in the tunica media and the tunica intima is practically nerve-free in man as in other mammals.

The nerve fibres originating from the glossopharyngeal and vagus nerves and from the superior cervical sympathetic ganglion reach the carotid sinus' wall. There the fibres of different origin mingle with each other and form a rich plexus. In this plexus as a rule two kinds of fibres may be distinguished, one conspicuously thick, the other being thin. In certain areas of the adventitia the two types of fibres are so closely intertwined that their anatomical pathway can be clarified only with difficulties (Fig. 175). Sometimes fibres constituting the bundles arising in the sinus nerve keep together for some distance and start to divide and to form the dendritic branchings typical of depressor fibres only later on. As a rule, the branching is dichotomic, but not infrequently smaller or larger lateral branches are seen to leave the parent fibre on either side. These lateral rami then branch

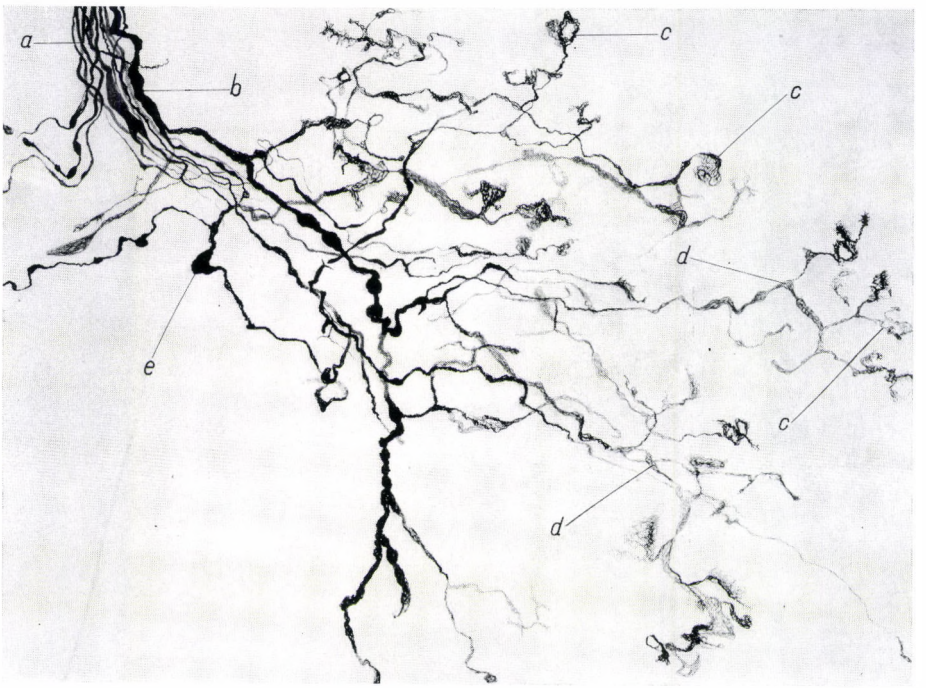

FIG. 177. *Homo.* Sinus caroticus; nerve end fibre system in the adventitia. (a) Nerve bundle; (b) nerve fibre; (c) neurofibrillar end plate; (d) neurofibrils; (e) varix. Bielschowsky–Gros' method. Microscopic magnification 600×, reduced photographically to ½

repeatedly and, as the branches intertwine repeatedly, they give rise to a plexus so rich as to cover the adventitia's inner surface almost entirely (Fig. 176).

In successful preparations of sections parallel to the surface of the adventitia, the entering bundle with all its fibres and the fibres' branch systems together with terminal rami and plates may be clearly seen. Nerve pictures of this kind show that there is a complete absence of any anastomoses between the rami, the terminal branches or the end plates. All the nerve fibres descend independently and their terminal fibres all have separate end plates. In the end plates the neurofibrils are clearly visible, forming a closed plexus. The plates are sharply bordered against the connective tissue elements. Such fibre and terminal systems give clear and convincing pictures on the shape, descent and conjugation with the host tissue of nerve bundles entering the sinus wall (Fig. 177). These systems account for the extraordinary sensitivity of the sinus wall, evidenced also by the fact that the large end plates attach flatly to the inner adventitial surface. Since the nerve bundles formed in the outer adventitia are large and the fibre systems develop at different levels, it is natural that in the connective tissue end plate systems follow each other in subsequent layers.

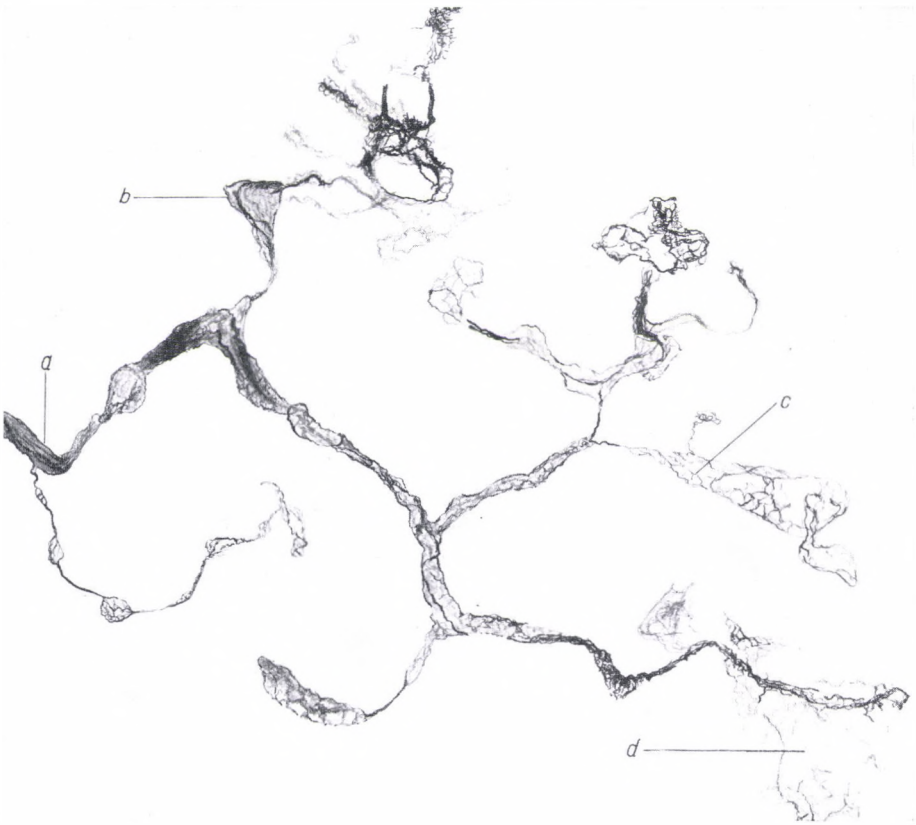

FIG. 178. *Homo.* Sinus caroticus; nerve fibre end plate system in the adventitia. (a) Nerve fibre; (b) varix; (c) neurofibrils; (d) neurofibrillar end plate. Bielschowsky–Gros' method. Microscopic magnification 1800×, reduced photographically to ½

When examined with higher magnification, the (mostly) ivy-leaf shaped end plates as well as the attached delicate end rami show a markedly neurofibrillar structure. In the terminal rami the neurofibrils pass more or less parallel, whereas in the end plates they form a network (Fig. 178).

Branch systems formed by the ramifications of thick fibres are sometimes so closely intertwined that their survey presents the greatest difficulties. Nevertheless, even in such cases it is obvious that the individual fibres of the system end in peculiar plates in which the neurofibrils form a network.

De Castro, who was the first to investigate these end systems, distinguished two types of endings of the carotid sinus' thick nerve fibres. He described the first as diffuse ramification (appareils terminaux à arborisation diffuse), the second as circumscribed ramification (appareils sensitifs à ramification circonscrite). Sunder-Plassmann, too, advocated the existence of two types, but unlike de Castro he put

the circumscribed form (circumscripte Form) first, and the diffuse form (diffuse Form) second. For my part, after thorough examinations for over a year, I failed to distinguish types among the nerve end systems located in the carotid sinus' wall. In fact, a reasonable basis for differentiation was lacking as the end systems appeared to be highly similar in bulk, structure and conjugation forms. Recently, however, after further studies on an extensive material, we seem to have detected some morphological basis for type differentiation. We found that part of the thick fibres form branch systems readily followed over a long distance, as shown in Fig. 177. All end branches of these systems continue in circumscribed neurofibrillar plates. The other type forms a plexus system whose end connections are also constituted by neurofibrillar plates. The first type of systems is uniform, readily detectable, enabling an easy interpretation of the function and particular sensitivity of the attached fibre system. Systems of the second type are non-uniform and difficult to demarcate from each other but, as they show a certain uniformity in the mode of forming plexuses, they may be acknowledged to be a type. To give some information on the forms, and on the wide variation of forms revealed by the nerve end systems of the second type, we give a short description on some highly particular and complicated nerve end apparatuses below.

Some of the fibres arising from the bundles run a straight path, giving off side branches in all directions. The lateral rami branch off repeatedly, the thin branches thus arisen intertwine with each other and continue in neurofibrillar end plates. In the latter the neurofibrils form a closed network. End plates are very numerous, they are elongate in shape and their margins are sometimes segmented, sometimes thin and smooth (Fig. 179). The figure gives a true picture of the conditions found.

Sometimes two or three thick fibres cover a long distance on one and the same path in close proximity. The fibres exhibit characteristic thickenings and, here and there, varices. On the associated fibres, namely towards their ends, thick branch systems arise, branching off gradually and the thicker and thinner systems constitute a rich system of plexuses accompanying the associated fibres along nearly their entire descents. In the plexus there are relatively few end fibres and accordingly also few terminals. Depending on the fibre's position and nature, however, polymorphous end plates of varying sizes are also apparent within which the neurofibrillar network is clearly seen (Fig. 180). The associated fibres and their end systems display a very characteristic picture in certain instances. These relatively infrequently encountered formations may be justly considered "types". Whilst in the configurations, described formerly lateral branches were seen to exit from the main fibres and the end systems arose from these lateral branches, i.e. from the terminal ramification of the main fibre, in the case of an association of two or more fibres all end branches were given off simultaneously, arising at the same site. The rami were smooth, passed distantly from their origins, then branched and ended in neurofibrillar end plates. The dimensions of the end plates were variable, their structures relatively uniform, but greater differences were encountered in their shapes and measurements (Fig. 181). In some cases, the end systems of several thick fibres meet each other. In such instances the main fibres as well as

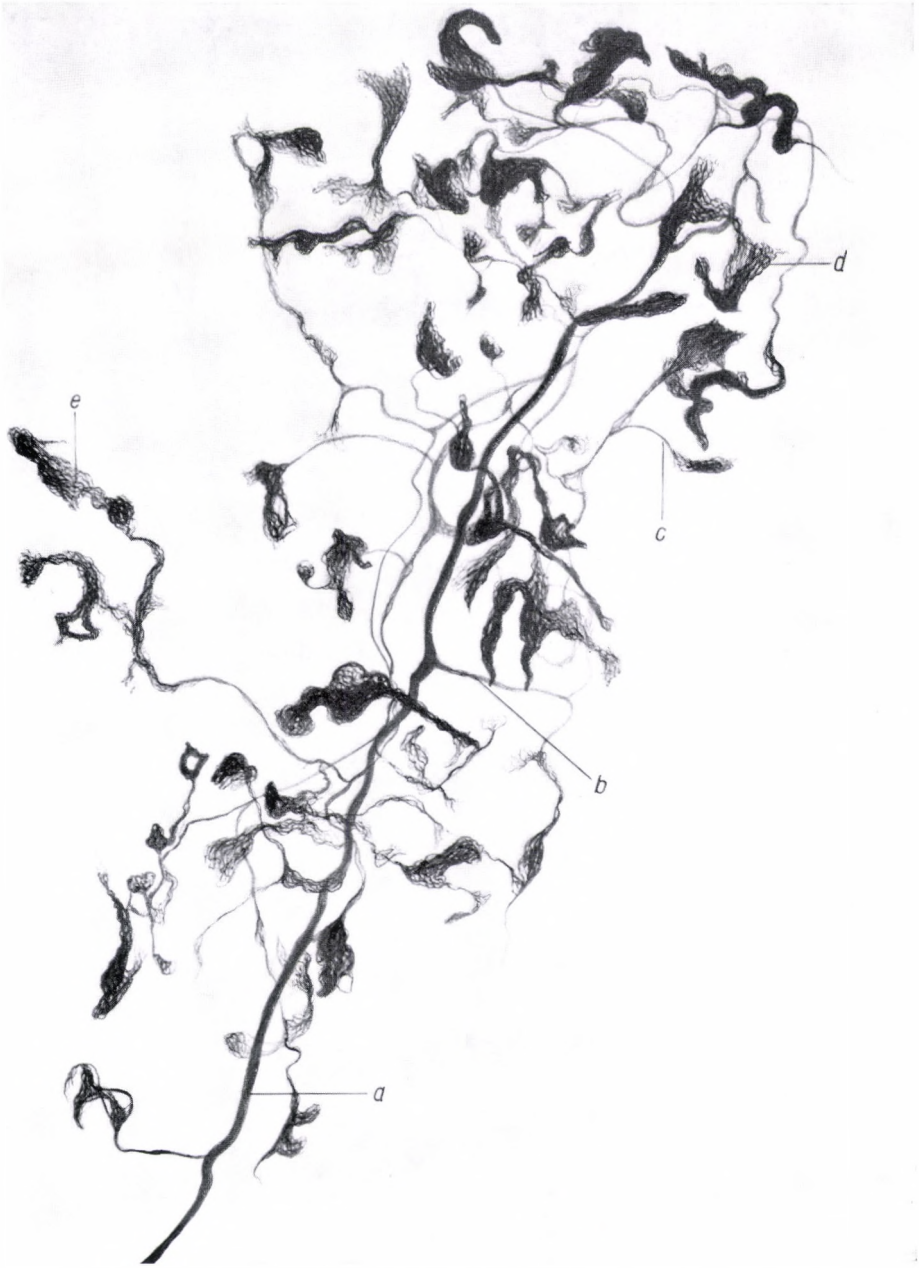

FIG. 179. *Homo.* Sinus caroticus; nerve end plate system in the adventitia. (a) Main branch; (b) side branch; (c) end branch; (d) end plate; (e) neurofibrils. Bielschowsky–Gros–Cauna's method. Microscopic magnification 600×, reduced photographically to ½

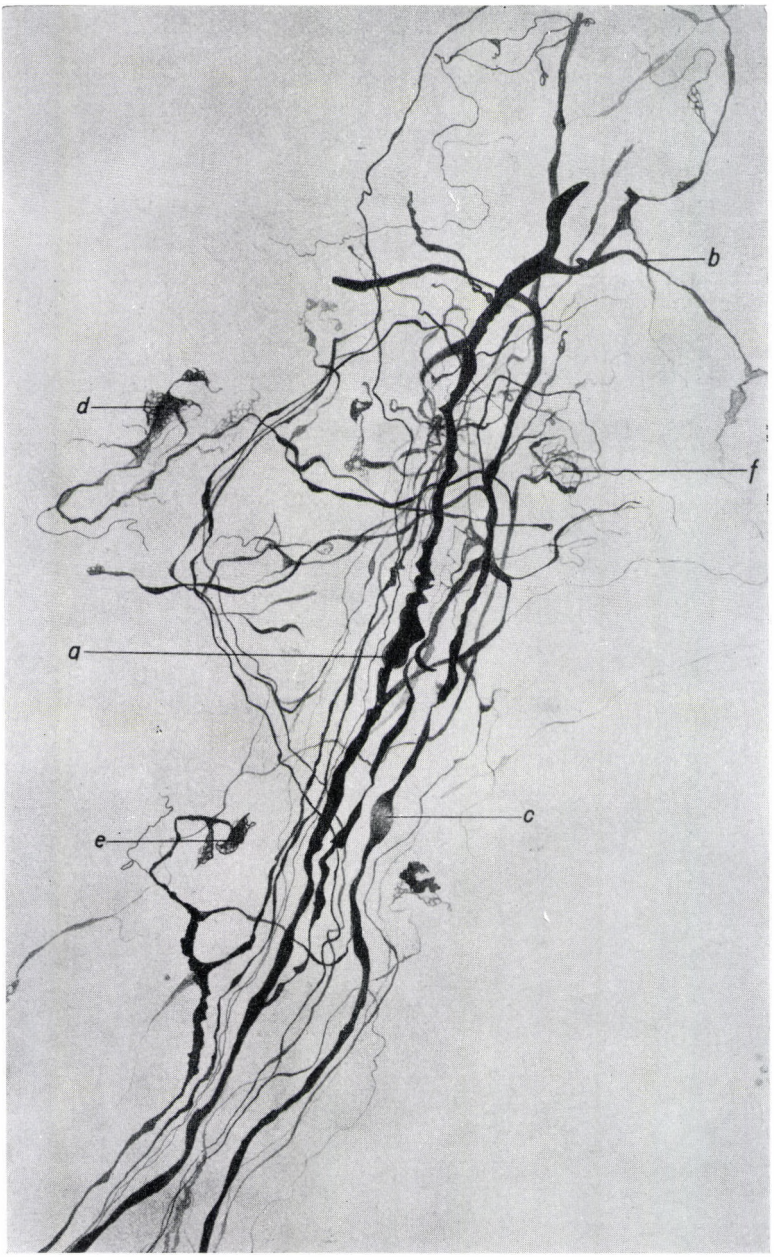

FIG. 180. *Homo.* Sinus caroticus; nerve plexus in the adventitia. (a) Nerve fibre; (b) end fibre; (c) varix; (d) intermediary plate; (e) end plate; (f) nerve fibre plexus. Bielschowsky–Gros; method. Microscopic magnification 800×, reduced photographically to $^1/_3$



FIG. 181. *Homo.* Sinus caroticus; nerve end plates in the adventitia. (a) Main branch; (b) varix; (c) side branch; (d) end branch; (e) intermediary plate; (f) neurofibrils; (g) end plate. Bielschowsky–Gros–Cauna's method. Microscopic magnification 600×, reduced photographically to ½

their end systems become so inextricably interwoven that their origins and the sequence of their connections can be hardly clarified. Nevertheless, even in these conditions we could clearly distinguish here and there sharply fibrillar thick fibres of varying diameters, intermediary neurofibrillar plates and occasionally also the end plates. Of the latter, some were roundish, others elongate, occasionally tapering or chopped at the end. In the end plates there is a well-visible neurofibrillar structure (Fig. 182).

When the above nerve end organs or similar other nerve endings are examined under a higher magnification in appropriate preparations, the most delicate terminal rami and the attaching end plates appear with an unusual clarity. In the majority of cases, such pictures remind one of a giant reticular system in which end fibres and end plates attach to each other and which in their totality form an enormous network whose components link with each other in a continuity. This is the general picture obtained with a single adjustment of the microscope. A more thorough study of these apparent anastomoses by careful use of the micrometer screw, however, always yields firm evidence of a definite absence of a reticulum. Even in the most complicated pictures, careful examination will reveal that the end



FIG. 182. *Homo.* Sinus caroticus; nerve fibre plexus in the adventitia. (a) Main branch; (b) side branch; (c) end branch; (d) neurofibrils; (e) intermediary plate; (f) end plate. Bielschowsky–Gros–Cauna's method. Microscopic magnification 800×, reduced photographically to ½



FIG. 183. *Homo.* Sinus caroticus; nerve end plate system in the adventitia. (a) Nerve fibre; (b) intermediary plate; (c) neurofibrils; (d) end plate. Bielschowsky–Gros–Cauna's method. Microscopic magnification 800×, reduced photographically to ½

fibres never continue in each other and their end plates localize in every case beneath, or above, but always separate from, each other (Fig. 183). The clarification of this problem which is functionally very important as well as the proper interpretation of the microscopic pictures, requires adequately impregnated preparations. Membranes or thick, inadequately impregnated sections will never give a true picture of the actual conditions. Workers advocating the presence of a peripheral reticulum in the carotic sinus may never have been in possession of preparations authentically revealing the actual conditions as anybody who has ever seen

an impeccable preparation would not claim the presence of a reticulum; such a feature is not seen in our preparations.

In the foregoing we have repeatedly expressed our conviction that a peripheral terminal reticulum does not exist. The sole reason for emphasizing this repeatedly is that attempts to prove the presence of a peripheral terminal reticulum in relation to the carotid sinus are still being made by some contemporaries. On the basis of our studies, conducted uninterruptedly for more than 25 years in this field and in general in the field of cardiovascular innervation, we may state that in the wall of the carotid sinus neither neurohistological anastomoses nor reticulum are present.

According to our most recent investigations, the forms of the nerve fibres' end arborizations and the features of neurofibrillar end plates, end bulbs and endings suggest the presence of two kinds of limitary nerve end systems in the wall of the carotid sinus.

These two forms of end systems have been well distinguishable in carotid sinus specimens from very aged persons or from those who died of cardiovascular disease. The first form of end system is constituted by a few smooth, thick myelinated fibres, showing thickenings of varying sizes in their descents. The fibres cover quite long distances without arborization, forming numerous loops and later on a loose plexus of great extent. The fibres ramify only near their ends. Here they give off delicate end branches, some of which are thick with a sharp neurofibrillar structure. The end fibres terminate in small end plates with well-visible neurofibrillar plexuses. In elderly subjects, as well as in those suffering from the conditions mentioned above, the course and termination of the system are both subject to deformation. The end plates become smaller, assume an elongate shape and are losing sharp definition against the surrounding connective tissue elements (Fig. 184).

The second form of end system encountered in the wall of the human carotid sinus shows entirely different features. The thick myelinated fibres exiting from the nerve fibre bundle descend separately and pass far from the bundle before they arborize. These fibres are as a rule very thick, carry only very few varices and show a sharp neurofibrillar structure throughout their entire descent. Their end arborizations are extremely rich. The form and features of these end formations are in general very specific. The fibres arising from the bifurcation of the main fibre form again a bifurcation and this form of branching continues up to the very fine end branches which terminate in neurofibrillar end plates. In the descents of the branches varices of different sizes are apparent and the fibres are markedly variable in diametre. The main characters of this type of end system are the rich end arborization and the great number of neurofibrillar end plates. The latter are very large, varying and irregular in shape, with distinctly visible neurofibrillation and marked argentophilia, particularly in aged patients or in those with diseases of the cardiovascular system (Fig. 185).

Electronmicroscopically, numerous small nerve trunks were found in the adventitial tissue of the carotid sinus, isolated from the other tissue elements by a thin perineural sheath consisting of four to five layers.

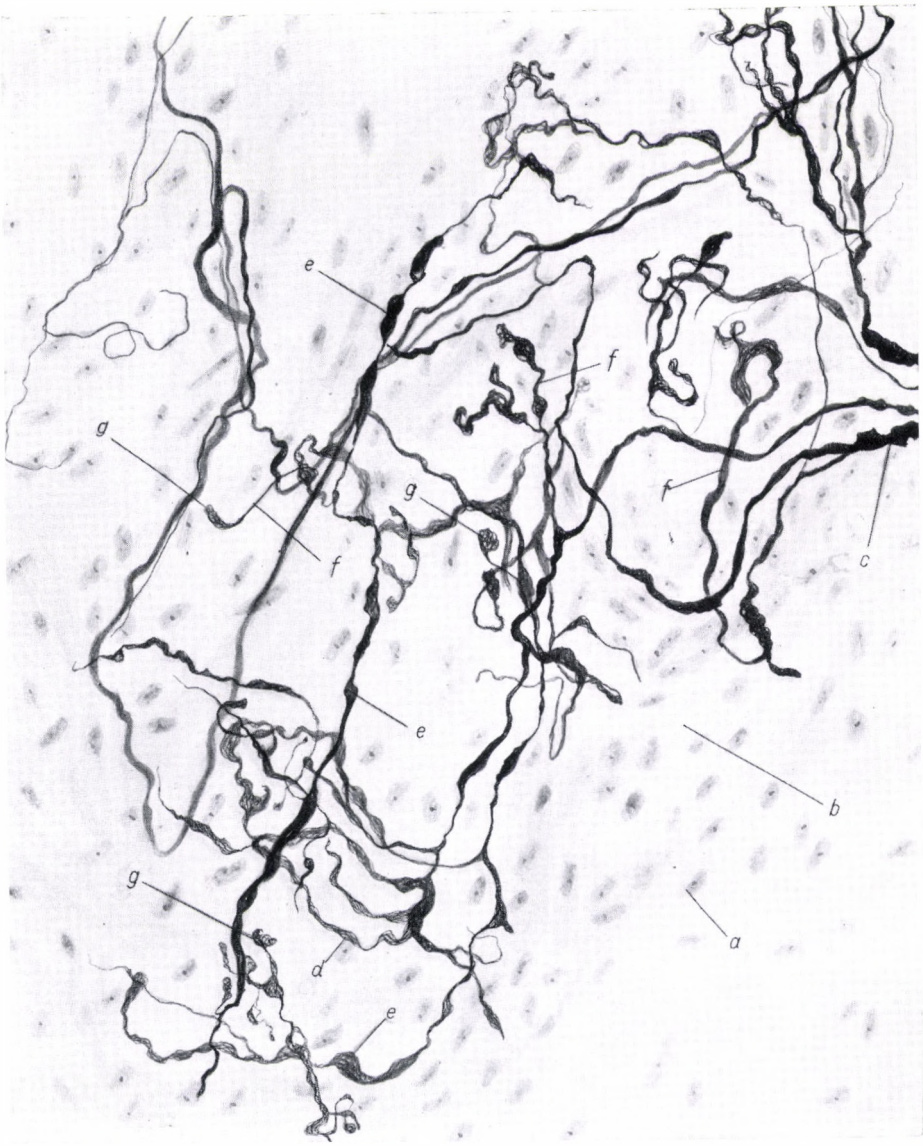

FIG. 184. *Homo.* Sinus caroticus; nerve fibre end system in the adventitia. (a) Nucleus of the connective tissue cell; (b) connective tissue fibre; (c) axon; (d) neurofibrils; (e) varix; (f) nerve end fibre; (g) neurofibrillar end plate. Cauna's method. Microscopic magnification 300×, reduced photographically to $^2/_3$

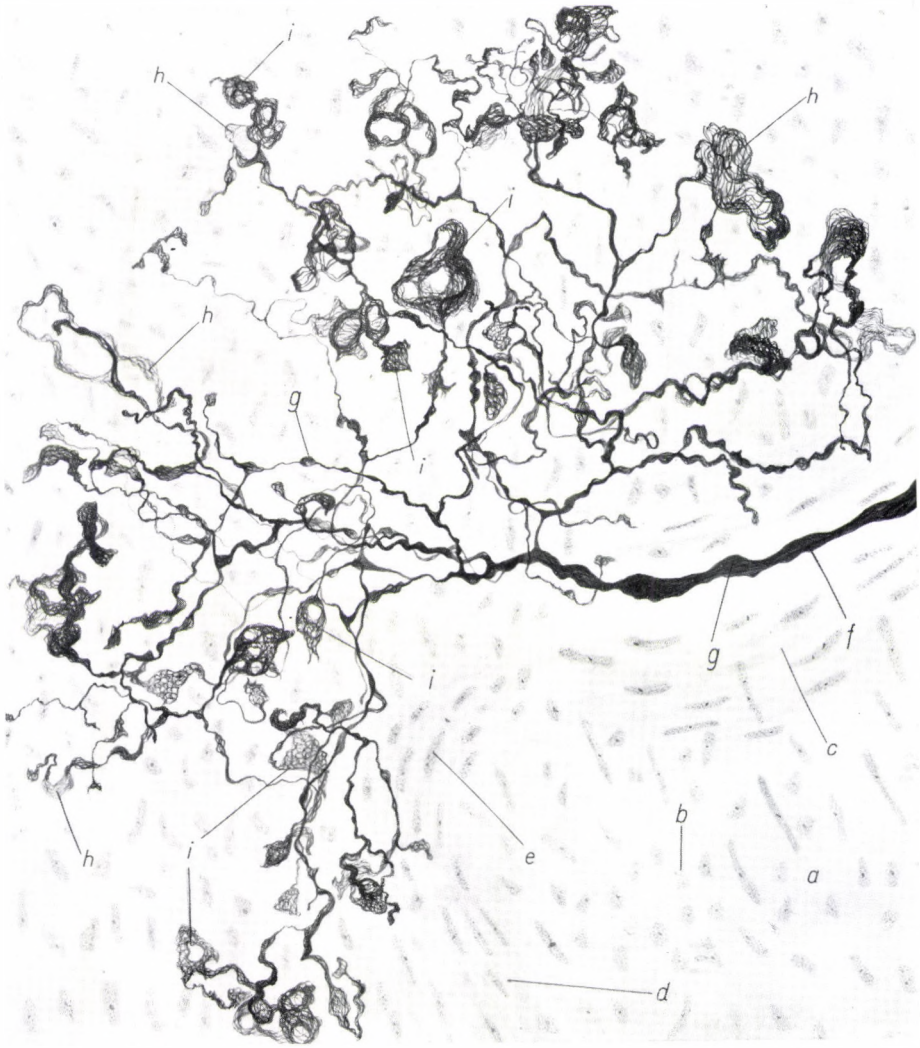

FIG. 185. *Homo.* Sinus caroticus; nerve end fibre system in the adventitia. (a) Connective tissue; (b) nucleus of the connective tissue cell; (c) smooth muscle tissue of the media; (d) smooth muscle cell; (e) nucleus of the smooth muscle cell; (f) axon; (g) varix; (h) neurofibrils; (i) neurofibrillar end plate. Bielschowsky-Gros-Cauna's method. Microscopic magnification 400×, reduced photographically to ½

Inside the sheath, one or two small myelinated axons as well as numerous unmedullated nerve fibres, arranged in groups of four to six axons, are present. The unmedullated axons are embedded in cytoplasmic envelopes of Schwann cells. Here and there also the mesaxonic boundaries, connecting the inner Schwann envelope of the axons with the outer surface of the Schwann cells, are apparent.

In the extra-perineural space, the most common tissue elements have been large fat cells, characterized by eccentric nuclei and immense amounts of homogeneous electron-dense lipid material inside their cytoplasms. Also histiocytes, characterized by large phagocytic vacuoles and tubular mitochondria and fibroblasts in a more or less close contact with the collagenous fibres, are present in the loose connective tissue. The identification of receptor endings amongst these various tissue elements required a very thorough examination of a large number of ultrathin sections obtained from scores of blocks from the adventitial tissue.

As shown by electron microscopy, the receptor end system is a small bundle constituted by extremely thin unmedullated axons, measuring 0·2–0·5 μ in diameter and lacking Schwannian elements. Accordingly, these fibres should be categorized as free axons. We have arrived at the same conclusion by light microscopy. Some of the axons were particularly enlarged. Both the unmedullated axons and their enlargements attached to bundles of collagenous fibrils.

Pathological Alterations of the Sensory Nerve Fibres of the Human Carotid Sinus

During the past years we have examined nerve interconnections in the carotid sinus of numerous persons of both sexes and various ages. Nerve connections of very variable shapes and structures have been encountered. All of them were, however, identical. In every case, fibres sent by the sinus nerve were thick with large varices connected by thin axons, they formed rich branch systems with thin terminal rami carrying large end plates with a closed neurofibrillar system. Nevertheless, in addition to these general characters many particularities and formations have been encountered which, in our judgment, were due to pathological processes. We may justly suppose that pathological conditions of varying duration leave durable marks in the nerve fibres as well as in their end structures. The existence of such effects and their role in the changes and transformations of nerve plates in the carotid sinus' wall are inferred by scores of alterations encountered in the nerve pictures. Nevertheless, an objective base for this implication could be derived only from a systematic study of the presence and nature of alterations in the carotid sinus' nerve supply in persons of both sexes, at different ages and in certain pathological conditions. In this institute, such examinations have been conducted several times, but not systematically and not for that specific purpose. Therefore, the figures below are presented just to prove the existence of such alterations, without specifying their general and local causes (Fig. 186). I believe there is sufficient reason to consider the picture presented above as pathologic. Figure 186 shows a thick dense fibre which after a long path divides into two branches. One of them, seen at the left side of the figure, gives off several rami of varying sizes. The descents of these rami, as well as their relations to each other, are complicated. Yet all end fibres carry varices of varying lengths, showing clearly a neurofibrillar structure. The lengths and structures of the end fibres are variable but each broadens at the end to an end plate whose shape is sometimes round, sometimes piriform or shovel-like. The position, grouping, and shape of end plates, the particular



FIG. 186. *Homo.* Sinus caroticus; nerve end fibre system in the adventitia. (a) Main branch; (b) side branch; (c) neurofibrils; (d) end plate. Bielschowsky's method. Microscopic magnification 1200×, reduced photographically to ½

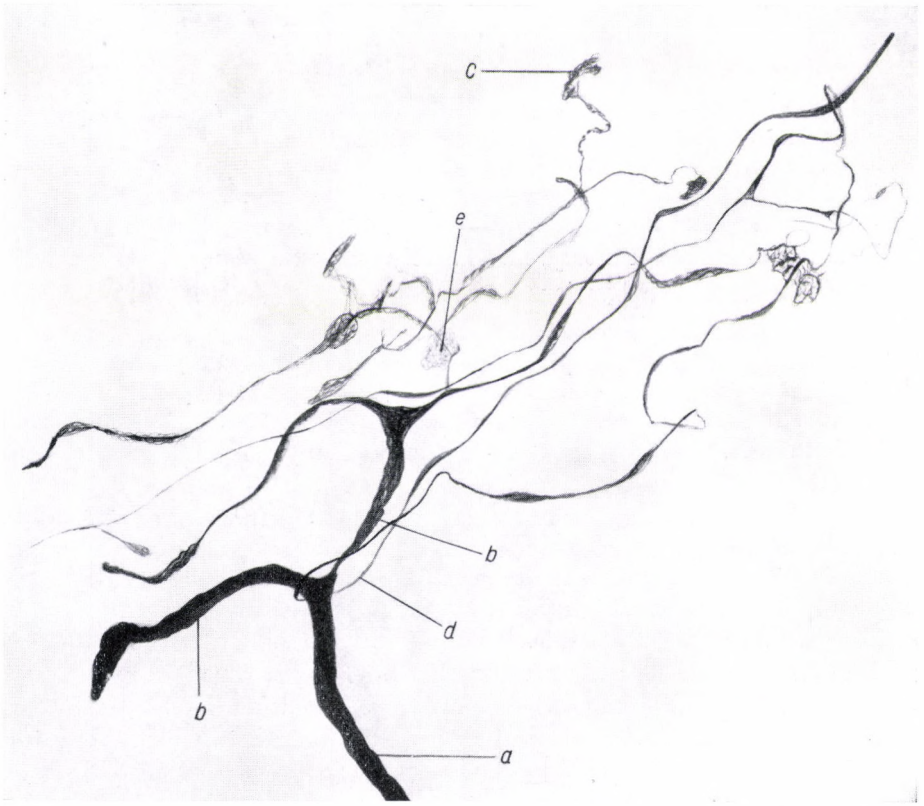

FIG. 187. *Homo.* Sinus caroticus; nerve fibre system in the adventitia. (a) Main branch; (b) side branch; (c) end plate; (d) parallel contact; (e) neurofibrils. Bielschowsky–Gros' method. Microscopic magnification 800×, reduced photographically to ½

variation of the fibre's thickness and in general the marked disarrangement of the whole end system, which is our very first impression, support our assumption of a pathologically altered nerve end organ.

The nerve end connection shown in Fig. 187 is also considered pathological. A thick fibre is seen to divide into two branches. One of them was cut, the other passes on. Its initial portion is very thin, but further on it broadens markedly, and divides into two branches: the left one was cut, the right gives off further rami. The latter become thin and after covering a long distance they end in neurofibrillar end plates. The above formations are not at all unusual and their development must not be ascribed to pathological influences. The particularity of this system is constituted by the fact that the main fibre is approached laterally by a thick varicose fibre which winds around it right at the site of branching, then returns, ramifies and the rami disappear in the connective tissue.

COMMON CAROTID ARTERY (ARTERIA CAROTIS COMMUNIS)

Hering regarded the carotid sinus as the sole site of origin of sinus reflexes. Essentially he was right, but examinations of the carotid's portions in the region of the sinus have convinced us that not only the carotid sinus but also the adjacent portion of the common carotid artery as well as the internal carotid artery are involved in the generation of reflexes.

In the common carotid artery, immediately below the sinus, there are many sensory nerve bundles and various nerve endings. As a rule, the bundles consist of two to three or perhaps more myelinated fibres. The fibres are thick and so are their myelin sheaths. Their appearance bears a resemblance to the fibres of the carotid sinus which implies their belonging to the fibre systems of one and the same nerve. The nerve fibres usually branch off after a short path. The rami become gradually thinner, then form a plexus which shows many lamellar thickenings and whose end fibres terminate in neurofibrillar plates.

In the wall of the common carotid artery, coil-like structures are not infrequent either. Some of them are of loose structure, consisting of relatively few thick fibres belonging to the system of a single myelinated fibre. The connective tissue surrounding the coil is sometimes arranged in a fashion as if the end system would be encapsulated. This is only an illusion as actually the coils are uncapsulated and beside them smaller and denser coils may be present. Occasionally dense elongate coil systems arise by the ramification of one or more adjacent fibres and the intertwining of their branches. More frequently plexuses formed either by the terminal branch system of a single fibre, or by the conjugation of two different fibres are seen. Beside them, there are scores of formations constituted sometimes by end fibres, then again by end fibres and intermediary fibre portions. The formations described above indicate that in the wall of the common carotid artery the system of thick fibres may give rise to all kinds of end formations.

In the descent of the fibres constituting the system, neurofibrils are well visible already at a 600× magnification, namely in the intermediary plates and neurofibrillar end plates (Fig. 188). The latter are much smaller than those in the carotid sinus; they do not show the typical ivy-leaf shape and are much lower in number than in the carotid sinus. In view of these differences, the question may be raised whether the thick fibres passing in the wall of the common carotid artery are actually of glossopharyngeal origin or whether they belong to the vagal system. The latter seems to be the more probable explanation. In this case the differences presented above suggest differences of origin, too. It should be added that—although there is obviously a certain similarity—these terminal sturctures are by no means identical with those described from the aortic arch.

Similar conditions have been encountered in the common carotid artery of the calf. There, too, the region of the bifurcation is markedly rich in nerves. This applies to the nerve supply of the smooth muscles and vasa vasorum but particularly to that of the capillaries, particularly to sensory fibres which appear here in large numbers and in considerable variety. Here, too, the sensory elements are

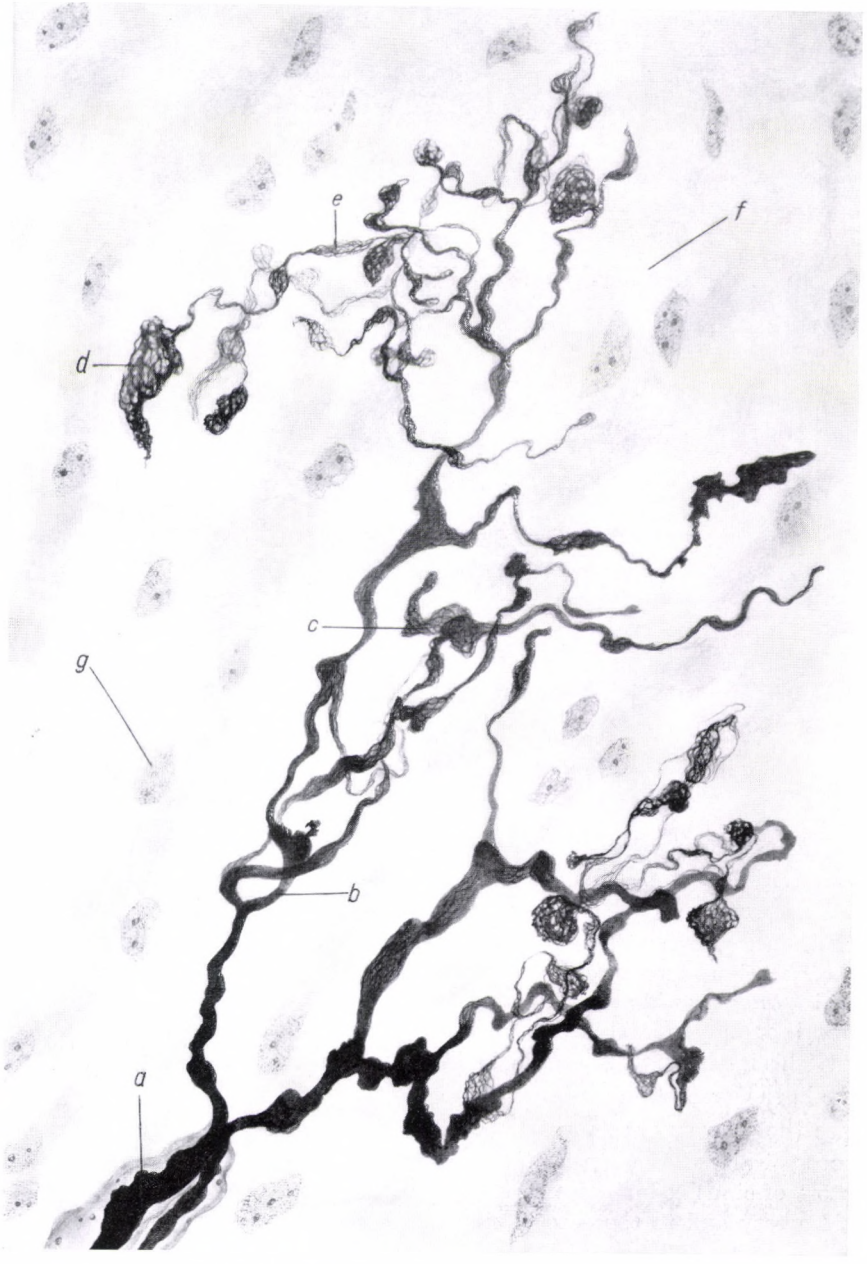

FIG. 188. *Homo.* Carotis communis; nerve plexus in the adventitia. (a) Main branch; (b) side branch; (c) intermediary plate; (d) end plate; (e) neurofibrils; (f) connective tissue; (g) nucleus of connective tissue cell. Bielschowsky–Gros' method. Microscopic magnification 600×, reduced photographically to $^{2}/_{3}$

myelinated fibres being, however, much thinner than the similar structures in the common carotid artery of man, and also their way of branching exhibits certain particularities. In general, nerve pictures are characterized by a rich branch system, the shortness and undulating descent of branches and the close connection of terminal branch systems with each other. Occasionally the terminal branch systems of two adjacent fibres are so inextricably intertwined that their demarcation requires a very close study under very high magnification. The fibres nearly intertwine with each other and consequently also their endings are so deeply hidden in the fibre network as to render the identification of their shapes and structures almost impossible. It may be stated, however, that the triangular fibre end plates are smaller, and the neurofibrillar network seen in them is denser, than in man. The plates are sharply bordered against each other and against the elements of connective tissue as well. Yet there is an obvious difference as both the end systems and neurofibrillar end plates are seen in much smaller numbers in the calf than in man.

EXTERNAL CAROTID ARTERY

The external carotid artery is not much less sensitive than the common carotid artery. In man, sensory endings are also found in that location. They are dendritic branchings terminating in elongate neurofibrillar plates. The extraordinarily delicate fibres arisen from the branchings may be followed over a long distance without continuing in end plates. The endings are not typical, but their structure is undoubtedly suggestive of a sensory nature, thus they belong to the fibre system of the vagal or glossopharyngeal nerve.

INTERNAL CAROTID ARTERY

Similarly thick fibres and nerve endings of sensory character are found in the wall of the internal carotid artery, at the site where it attaches to the carotid sinus. The nerve fibres are not so characteristic as in the portion discussed above, but their structures are more delicate. This applies to the shape of single fibres and varices, namely to lateral rami which are characterized by extraordinary thinness. In the internal carotid artery the characteristic end bodies present in the carotid sinus and common carotid artery are not seen; moreover, the typical end fibres are absent. This implies that the suprasinal portion of the internal carotid artery plays no role in the generation of sinus reflexes.

Since the sensory elements found in the external and internal carotid artery are not typical and occur in relatively low numbers, it is highly probable that the receptors of sinus reflexes are restricted to the terminal portion of the common carotid artery and to the carotid sinus.

PULMONARY ARTERY (ARTERIA PULMONALIS)

The pulmonary artery, too, belongs to the arteries with muscular wall. Its wall is thick and richly supplied with nerves in birds, mammals and man alike. Nerve plexuses which almost entirely cover the outer surface of the adventitia consist

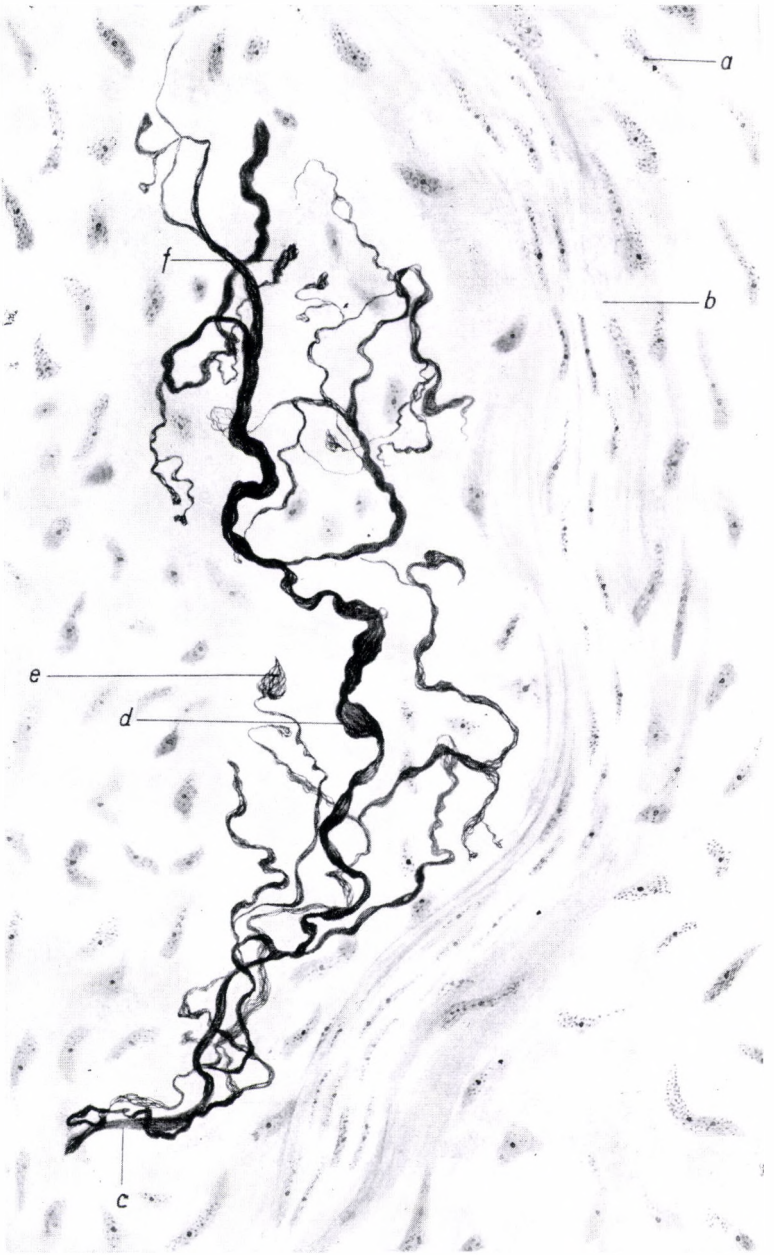

FIG. 189. *Homo.* Arteria pulmonalis; nerve end system in the adventitia. (a) Nucleus of connective tissue cell; (b) connective tissue fibre; (c) thick nerve fibre; (d) varix; (e) neurofibrils; (f) end plate. Bielschowsky–Gros' method. Microscopic magnification 600×, reduced photographically to ½

of thick trunks and bundles. Both the former and the latter comprise sympathetic fibres carrying Schwann cell nuclei. Characteristic fibres are uniformly absent in trunks, bundles and smaller rami as well. This was observed by us in birds, pig and sheep, and up to very recently also in man. Lately, during a survey of our preparations we observed in the wall of the human pulmonary artery beside sympathetic fibres also the presence of some thick, here and there markedly broadening fibres which differed radically in descent, path and appearance from the sympathetic fibres forming larger trunks and bundles. Still more recent examinations have shown that these thick fibres form particular sensory nerve endings which in structure, bulk and forms of end connections remind us of pressoreceptors whilst differing from them in certain important features. So far two forms, radically differing from each other, have been distinguished among these end systems detected previously neither in the pulmonary artery nor elsewhere. One of them belongs to the group of nerve endings with coil-like terminals, while the other shows a dendritic structure. Their structures and connections are described below.

Of the nerve end systems present in the wall of the pulmonary artery in the inner adventitial layer near to the media, one type is plexus-like, the other an arborization ending in plates.

The first type of end system is constituted by the end branchings of thick, smooth, homogeneously impregnating fibres. Essentially the thick fibres (which definitely lack all "depressor" features) divide into numerous thin rami after having covered a long path. The newly formed rami intertwine with each other, run over a long distance and surround a larger portion of another main fibre. Their structure is reminiscent of some of the genital nerves where the thin nerve fibres form spools around the central thick, markedly argentophilic fibres. From the long spool-like plexus exit individual fibres which end in triangular terminal plates near to the main fibre. Similar end plates may also occur within the plexus itself (Fig. 189).

The second type of end structure is also formed by thick fibres so that they give off numerous lateral rami which again branch off repeatedly and become gradually thinner. Occasionally the thin terminal rami become undulating and end in relatively large end plates. The plates are dense and bordered sharply against each other and the host tissue. Neither the terminal fibres nor the end plates anastomose with each other (Fig. 190).

The sensory nerve endings described above have no structural relationship whatever with systemic pressoreceptors and indeed differ from them in several respects. There are no large varices in their descents, neither do thick and thin portions alternate, no neurofibrillar structure is apparent in their fibres and end plates. Neurofibrillar intermediary plates are absent. Yet their structure, position and connections are suggestive of their pressoreceptor nature. If so, reflexogenic zones are present also in the wall of the pulmonary artery, which is in keeping with recent physiological results.

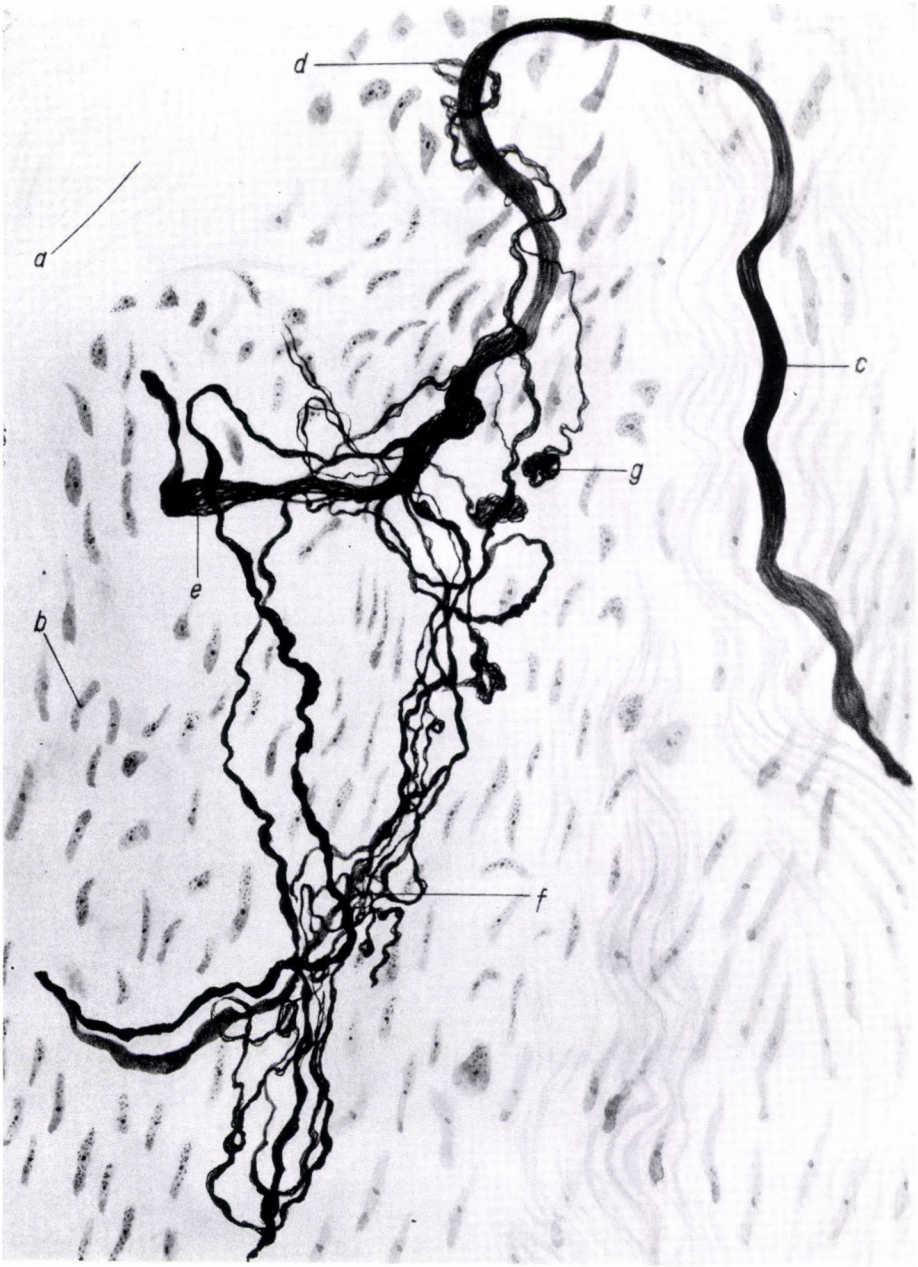

FIG. 190. *Homo.* Arteria pulmonalis; nerve end system in the adventitia. (a) Connective tissue fibre; (b) nucleus of connective tissue cell; (c) thick nerve fibre; (d) spiral; (e) neurofibrils; (f) nerve plexus; (g) end plate. Bielschowsky–Gros' method. Microscopic magnification 600×, reduced photographically to ½

Are there Interstitial Cells Present in the Reflexogenic Areas?

In the foregoing we have stated that aortic fibres descend independently of each other and are attached directly to the outer layers of the vessel wall. Although this has been shown by several hundreds of preparations and proved to be exclusive of all opposed concepts, we stress it repeatedly, owing to the fact that certain authors are still supporting the interstitial cell theory of Cajal, claiming that these interstitial cells should be considered nerve cells and that on the periphery, "reticula" (Nervennetz) are exerting the function of local receptors and as such they synapse with the fibres of the ortho- and parasympathetic systems. In this respect I have stated my position several times before. My opinion has not changed in the meantime, it has rather become still more firm. Without going into details of this complex of problems I state again that in higher invertebrates and vertebrates no true terminal reticula whatever are present. All pictures presented to prove this concept are defective and derive from the misinterpretation of microscopic pictures obtained by inadequate processing of the specimens. I can prove the validity of my statement to anybody with a desire for objective knowledge by several thousands of methlyene-blue stained and impregnated preparations obtained from various organs of higher invertebrates and vertebrates.

I do not want to discuss here the multi-processed, anastomosing interstitial cells of Cajal, which according to Meyling form a true peripheral nerve reticulum both in the reflexogenic zones of the aorta and in the carotid sinus. In my opinion they are connective tissue cells bearing all the features typical of connective tissue cells but none of those by which nerve cells can be differentiated from all other kinds of cells. Here I wish to emphasize only that during examinations for more than 25 years I consistently failed to detect the above terminal reticulum in vessel walls. I never saw a structure of that kind in the many thousands of preparations examined. According to my examinations, in man and animals alike, afferent fibres end independently in neurofibrillar end plates both in the aortic arch and carotid sinus without conjugating with any kind of interstitial cells. In fact, in preparations over-impregnated with the Bielschowsky–Gros' method, large processed cells which anastomose with their processes as described by Meyling are apparent in large masses in the endocardium, the aortic arch and in the carotid sinus alike but in my judgment these have no relationship whatever with the end systems of the afferent fibres. I still assert that these cells are multi-processed connective tissue cells which differ radically from nerve cells both in their appearance and structure and have no demonstrable relationship either with ortho- or with parasympathetic fibres.

Hence the fact that the baroreceptor fibres end independently of each other as well as of all other end structures, does not require a special explanation. Concerning the concept of Meyling on the nerve connections in the carotid sinus I may state again what I have already said in connection with the aortic fibres. Further to this, I wish to emphasize that in the reflexogenic area of the carotid sinus' wall there is no nerve reticulum, the afferent fibres end freely in independent neurofibrillar end plates attaching to the outer connective tissue layer of the vessel wall

without the mediation of any specialized anastomosing cell system. I am aware of several inconsistent opinions, yet I state that in such cases evidence is served exclusively by the preparations. I have studied the nerve system's histological structure in almost the entire animal kingdom for about 30 years. I have scrutinized several tens of thousands of preparations from Turbellaria up to man but in no case and no specimen did I see a reticulum in a satisfactorily convincing form. Each structure having at first sight made the impression of being a reticulum was in due course identified as a network (plexus) in which all fibres have remained independent throughout. The fate of plexuses, with their fibre constituents, may be dissimilar in different organs or positions, yet the fact remains that the thick fibres of plexuses localized in reflexogenic areas continue in independent terminal fibres which in every case end freely and separately.

Baroreceptors and Hypertension

As outlined in the foregoing, the nerve fibres and end plates constituting the baroreceptors sometimes show different signs of degeneration or disintegration. It was supposed that these phenomena give rise to changes in blood pressure as well as in the morphology and physiology of the cardiovascular system. This implied a relationship of baroreceptor degeneration with hypertension and associated conditions.

A closer approach to this problem was made by investigating autopsy specimens from persons who had died of diseases due to changes in the morphology and physiology of the cardiovascular system (vitium cordis, myodegeneratio cordis, arteriosclerosis, thrombosis, embolia, hypertension, emollitio cerebri, apoplexia). In this material, examination of baroreceptors both in aortic arch and carotid sinus yielded the following results:

In all conditions listed above, degeneration of receptor fibres as well as of their neurofibrillar end plates was observed in a varying extent. In the first stage of pathologic alteration, nerve fibres became enormously thick, formed loop-like configurations or sometimes loose coils in their courses, assumed a vivid red colour upon impregnation with silver and sometimes exhibited small white vesicles inside the neuraxon.

In some nerve pictures, the baroreceptors showed very remarkable signs of degeneration. In the fibres big spheres, highly resembling nerve cells and smaller and larger thickenings with neurofibrillar structure, were apparent. These characteristic thickenings, alternating with thin intercalated pieces of the neuraxon, were present over the entire course of the nerve fibre. Among the thick fibres were seen some thin ones with unchanged diameters, forming loose plexus-like structures in the path of nerve bundles.

In the descents of nerve fibres, not infrequently elongate irregular thickenings were seen. Also, very fine and straight side branches were apparent along the thick receptor fibres. There were also spike-like formations observed on both sides of the fibres. By the end of the degeneration process, vertical indentations appeared in the


d
d
e
d
e
d
e
a
b
c

path of fibres which diverged from each other quite distantly so that they seemed to be divided into quadrangular bodies connected with each other by very thin and fine pieces of the neuronal axon. Subsequently, the fibres exhibited a marked argentophilia and the neuraxons fell to pieces of varying sizes.

Degeneration was very conspicuous also with the neurofibrillar end plates. The regular end arborization of the end fibres sometimes assumed a loose coil form, the end plates themselves became larger and the neurofibrils appeared very sharply both in end fibres and end plates. The latter developed remarkable argentophilia. By the end of degeneration, the neurofibrils fell into pieces and small vesicles appeared in large numbers over the whole area of end plates. This kind of accumulation of small vesicles was regularly observed in material from very aged persons with very advanced sclerotization of the tunica media (Fig. 191).

In certain diseases, both the end fibres and end plates of baroreceptors in the carotid sinus showed a special form of degeneration. A typical condition in this respect was embolia of the pulmonary artery due to thrombosis of the lateral femoral vein. All preparations obtained from the carotid sinus of a patient having died of this condition showed a general advanced degeneration. Irregular thickenings of different forms appeared in the course of the whole main fibre. In some places the thickenings were extremely large and separated from each other by very thin, occasionally quite long, pieces of neuraxon. The very thin side branches arising from the main fibre maintained, however, their original diameters for quite a long distance and ended in end plates of great extension.

The end plates of end fibres became extremely large, sometimes confluent and, owing to their remarkable argentophilia, appeared very sharply all over the loose connective tissue. All end plates consisted exclusively of small vesicles but also the greatest part of the end fibres had changed into small vesicles. This phenomenon is quite unique. No similar pictures whatever have been encountered in the course of our studies. We believe that the general and peculiar degeneration phenomena shown by baroreceptors in the carotid sinus are due to anoxia resulting from the occlusion of the pulmonary artery. The feasibility of this assumption seems to be supported by the finding that in the carotid sinus of the patient described above, all baroreceptors were degenerated (Fig. 192).

By the end of the degeneration process, small vesicles are making an appearance over the entire course of the end fibres. Simultaneously, the structures of end plates become dense and knots of varying sizes appear in certain portions of end plates and end fibres. It is remarkable that by the time the end fibres seem to be entirely degenerated, their end plate systems appear to be still only half-way to complete degeneration. This phenomenon implies a certain physiological and morphological independence of the receptor fibres' end systems. This, based on our concept, is explicable by a close physiological relationship between connective tissue cells and end plates.

←

FIG. 191. *Homo.* Sinus caroticus; nerve end fibre system in the adventitia. (a) Nucleus of the connective tissue cell; (b) connective tissue fibre; (c) axon; (d) varix; (e) degenerating neurofibrillar end plates. Bielschowsky-Gros-Cauna's method. Microscopic magnification 400×, reduced photographically to $^2/_3$

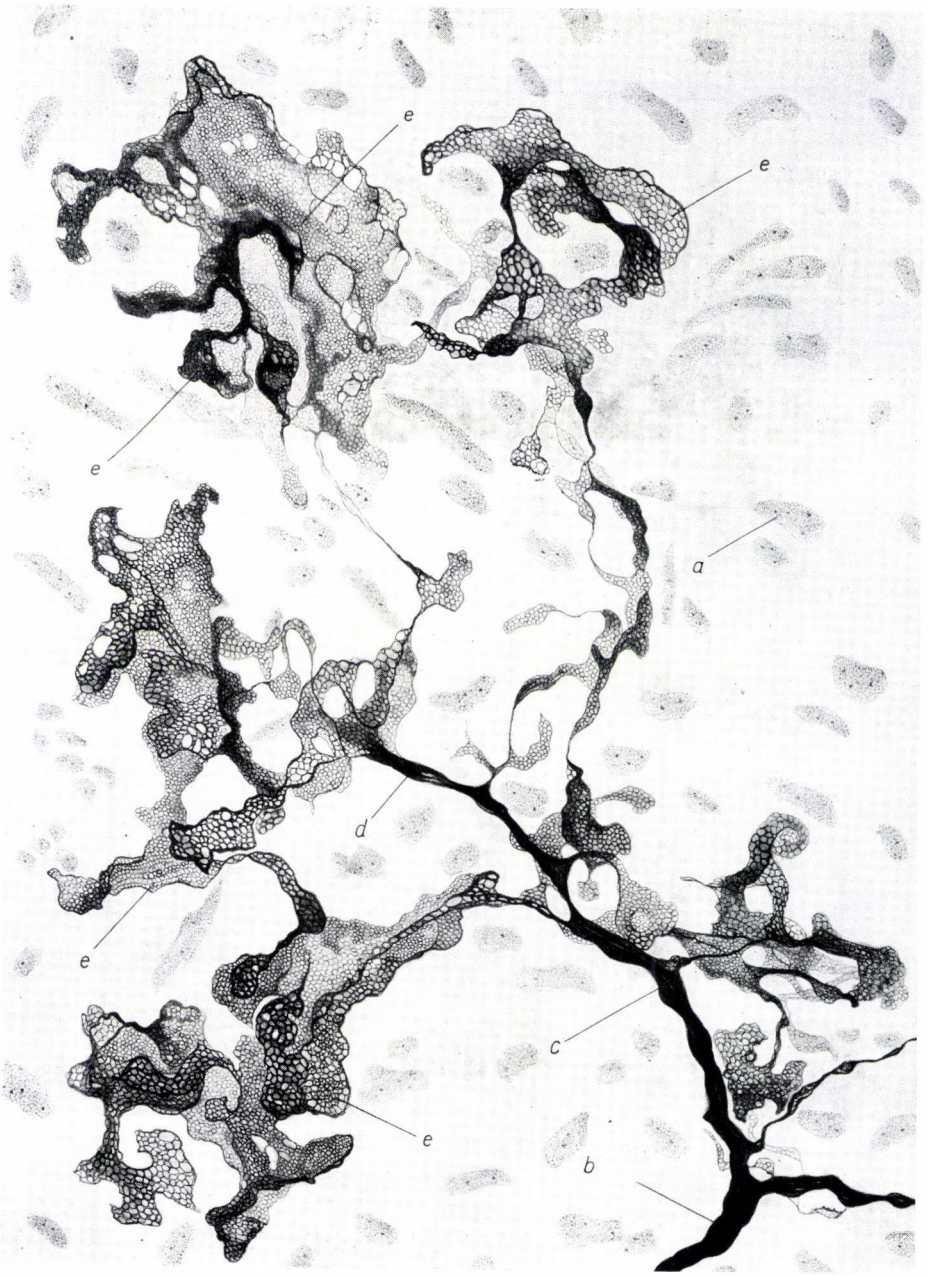

FIG. 192. *Homo*. Sinus caroticus. Pathologically changed nerve end system in the adventitia. (a) Nucleus of the connective tissue cell; (b) axon; (c) varix; (d) neurofibrils; (e) pathological enlarged degenerated neurofibrillar end plate. Jabonero's method. Microscopic magnification 800×, reduced photographically to ½

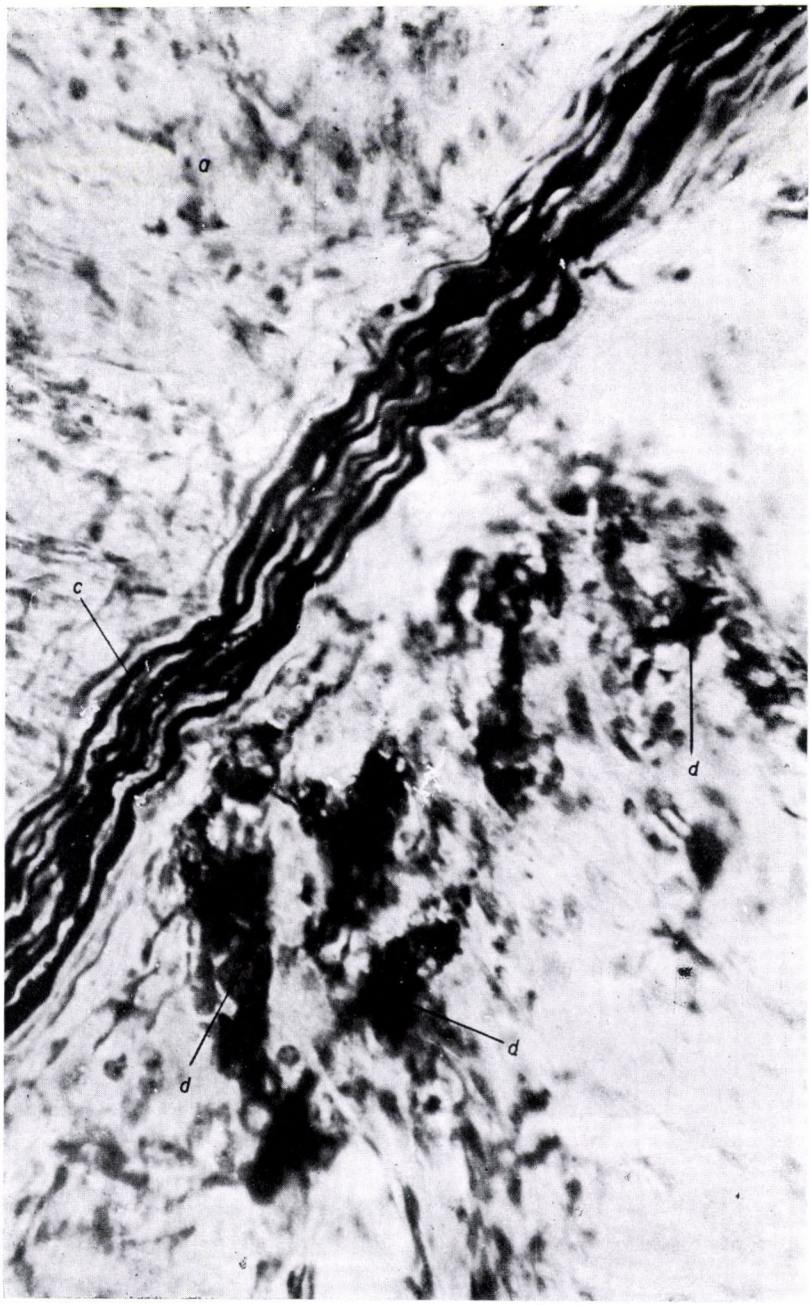

FIG. 193. *Homo.* Aorta; degenerated nerve fibre end system in the adventitia. (a) Connective tissue; (b) nerve fibre bundle; (c) depressor fibre; (d) degenerated nerve fibre end plates. Microphotography

In the last stage of degeneration the end plates themselves disintegrate. During this process the finest end fibres disappear and the neurofibrils seen in the end plates split into tiny pieces. The latter become confluent and peculiar knots make their appearance in the site of end plates. These knots, located close to each other, melt together giving rise to knots of considerable size in the site of end systems, wherein the fragments of the end fibres are quite clearly apparent. Such pictures have been encountered mainly in specimens obtained from apoplectic individuals.

Following their disintegration, end plates belonging to a given end system melted together and large irregular argentophilic knots arose in place of the end plates. Sometimes the broken pieces of thick nerve fibres could be seen adjacent to disintegrated end fibres and end plates, respectively (Fig. 193).

The regular occurrence of baroreceptor degeneration in hypertension implies a close morphological and physiological relationship between the two phenomena. This is easily explicable in respect of the aortic arch. The baroreceptor fibre supply of the aortic arch originates mainly in the vagus, thus degeneration should start either from the ganglion nodosum vagi or from the ganglion jugulare vagi, or in both. Accordingly, functional deficiency of the first inhibitor system should be due to degeneration of vagal ganglion cells. A closer examination of these ganglia will be carried out shortly.

In respect of the carotid sinus, the above phenomena are less readily explicable than with the aortic arch. In the carotid sinus, beside degenerated baroreceptor fibres some entirely intact ones were also found. Degenerated and intact baroreceptors were sometimes seen on one and the same microscopic slide. In view of this, we offer the following explanation. As already described in the foregoing, in the wall of the carotid sinus there are baroreceptor systems of two different origins, sent from the vagal and glossopharyngeal nerve, respectively. Degeneration may involve one, or both. In the case observed by us, receptors of only one system were degenerated. The question is, which of the two systems was actually involved. This remains to be clarified by a closer study of ganglia from the glossopharyngeal and vagal nerves.

We believe that a detailed investigation of vagal and glossopharyngeal ganglia connected with the baroreceptors obtained from patients who died of vascular diseases will throw a light on this problem before long. Nevertheless, our present knowledge already permits the conclusion that vascular hypertension is associated with a degeneration of the baroreceptor system.

Pressoreceptors and Phylogenesis

According to both clinical and experimental observations, pressoreceptors, called also baroreceptors, serve for the perception of internal and external pressure on the vessel wall, namely of blood pressure. Their special structures, surprising multitude and special localizations imply a particular sensitivity of the vessel portions in which they are present. The multitude and stratified arrangement of endings also imply that, as the sensory apparatuses of reflex paths in the area of

the aortic arch and carotid sinus, they are particularly suitable for the initiation of reflex processes. Also, the mass of nerve fibres, the giant systems of endings, the refinement and richness of connections and the position and multitude of end plates suggest that the baroreceptors act as interoceptor assemblies of specialized structure, and are closely dependent also on the way of life and conditions of adaptation of the animal. Undoubtedly, hard and lasting work, running, and in general movement systems and labours associated with remarkable fluctuations of blood pressure exert an influence on the work of the heart, the actual state of blood pressure and naturally also on the baroreceptors playing the role of inhibitors in the circulatory system. Should this be the truth – which may hardly be doubted – it certainly should imply the presence of certain specific features indicative of genetic relationships and the trend of phylogenesis. This they actually do. Examining the formation, particularly the end systems of pressoreceptors either in phylogenetically related or unrelated species, we may detect in the descent of fibres as well as in the structure, position and number of end plates certain typical features which are characteristic of the individual species and also indicative of their degree of relationship. For example, the close relationship of the calf and buffalo is indicated by the striking resemblance of axons, myelin sheathing, patterns of branching, and particular varices of aortic receptor fibres as well as by the shape of end fibres, the number, location and shape of end plates. Also, they bear a certain resemblance with the goat, namely in respect of the fibre's thickness, and the structure of axon and myelin sheath. The goat displays, however, well-defined particularities not seen in the buffalo or calf, in that the thick fibres passing in the aortic arch are accompanied almost along their entire path by a well-distinguishable neurilemma and myelin sheath, containing elongate nuclei. At the last branching both of them disappear and here is seen a phenomenon quite specific for the goat, viz. at the site where the fibre's sheath disappeared, the fibres gave off simultaneously several very thin, smooth terminal rami. These pass adjacent to one another for a short distance, then diverge and in the majority of cases continue in a bulky but loose coil. Later on they exit from that coil with unaltered diameters, pass on and end in densely neurofibrillar end plates of varying sizes. This formation did not appear in the aortic arch of any other examined mammal. It may have been developed in the course of adaptation to a new way of life after having parted from the common precursor. Further typical structures are constituted by the sheep's receptor apparatuses both in the aortic arch and in the carotid sinus' wall. Both of them are characterized by distinctly coil-like structures. Of these those encountered in the aortic arch are as a rule double and densely woven but in every case their constituent fibres end freely. The coils demonstrable in the wall of the sheep's carotid sinus wall are larger, looser and so typical that—as already mentioned above—their ovine origin is detectable at first sight. A comparison of these conditions in sheep and goat revealed notable structural differences between the two species.

In the pig, the baroreceptors are not only special but also quite characteristic. This applies particularly to those found in the aortic wall. Their most conspicuous feature is the extraordinary thickness of the myelin sheath. No similarly thick medullation was ever seen in any other species. The other typical feature is the

circular or spherical shape of nearly all intermediary plates. Further to this, the end plates are roundish, large and their neurofibrillar network is loose. Naturally, similar formations are also seen in the carotid sinus, but the latter bear a certain resemblance with similar apparatuses in other mammals.

The above observations permit the conclusion that the structures, end formations, numbers and positions of aortic receptors are dissimilar in certain mammalian species. These differences are not sharp in the genetically closely related species, but are quite conspicuous in genetically unrelated ones. It is assumed that the examination of this problem in more detail and on larger material will be a great aid for the clarification of genetic relationships and also a useful tool for pursuing certain problems of phylogenesis. In the course of my comparative neurohistological studies I have repeatedly offered that means and also emphasized that the clarification of phylogenetic problems must not be derived solely from the knowledge and evaluation of external features but should be extended also to the internal features and structures as well as to their alterability by function and environmental factors. In my opinion the settling of these problems should be based on fields characterized by a high degree of stability associated with differentiation and a slowly progressive variability. Such a field is the nervous system. I am convinced that as soon as the investigation of the nervous system is conducted with greater intensity and in a larger field than at present, through comparative studies, there will be revealed many characters, properties, consistencies and inconsistencies which will throw a light on relationship and alterations due to environmental factors thus promoting the progress of research on evolution.

5. CHEMORECEPTORS

THE second group of specialized receptor apparatuses is constituted by the chemoreceptors. Based on their localization and structure, these may be divided into two groups: the glomus caroticum and the similar smaller nerve end apparatuses localized mainly in the adventitia of the larger arterial trunks, namely in the truncus arteriosus, arteria anonyma, aortic arch and arteria pulmonalis. The latter are summarized under the general term "accessory glomera". Below we describe first the glomus caroticum, then the accessory glomera on the basis of observations made by us in human and animal material, in the sequence of birds, mammals and man.

GLOMUS CAROTICUM

The carotid glomus is a dense body of special structure and function. It is localized at the upper end of the common carotid artery, usually in the vicinity of the carotid bifurcation, and consists of connective tissue, islands of roundish epitheloid cells and nerve fibres.

Birds (Aves)

The carotid glomus of birds is found close to the common carotid artery, near the bifurcation, immediately above the ultimobranchial body. Essentially it is a roundish, slightly elongate dense body, encased by a connective tissue capsule constituted by collagenous bundles. Its blood supply is provided by the uppermost portion of the common carotid artery. The proper tissue of the glomus inside the capsule consists of mostly roundish islands of spherical cells separated by connective tissue columns originating in the capsule. It should be noted that the glomus' division into smaller or larger islands is first observable in birds, yet in a much less distinct and conspicuous manner than in the mammals to be discussed below. The cells are attached closely to each other and in impregnated preparations sometimes they contain minute granules. Otherwise the plasma is homogeneous and the nucleus—namely the nucleolus—is very conspicuous.

The main feature of the carotid glomus is its markedly abundant nerve supply. As described by Muratori (1934) and Nonidez (1935), the fibres innervating the glomus are special rami from the vagal ganglion nodosum, which after entering the glomus branch off richly. The fibres forming the rami are thick, smooth and undulating. Some fibres branch in a dendritic fashion at the organ's margin within the connective tissue capsule but also beneath it, and form loops of varying sizes. Arborizations are particularly well visible in the glomi of young birds where the

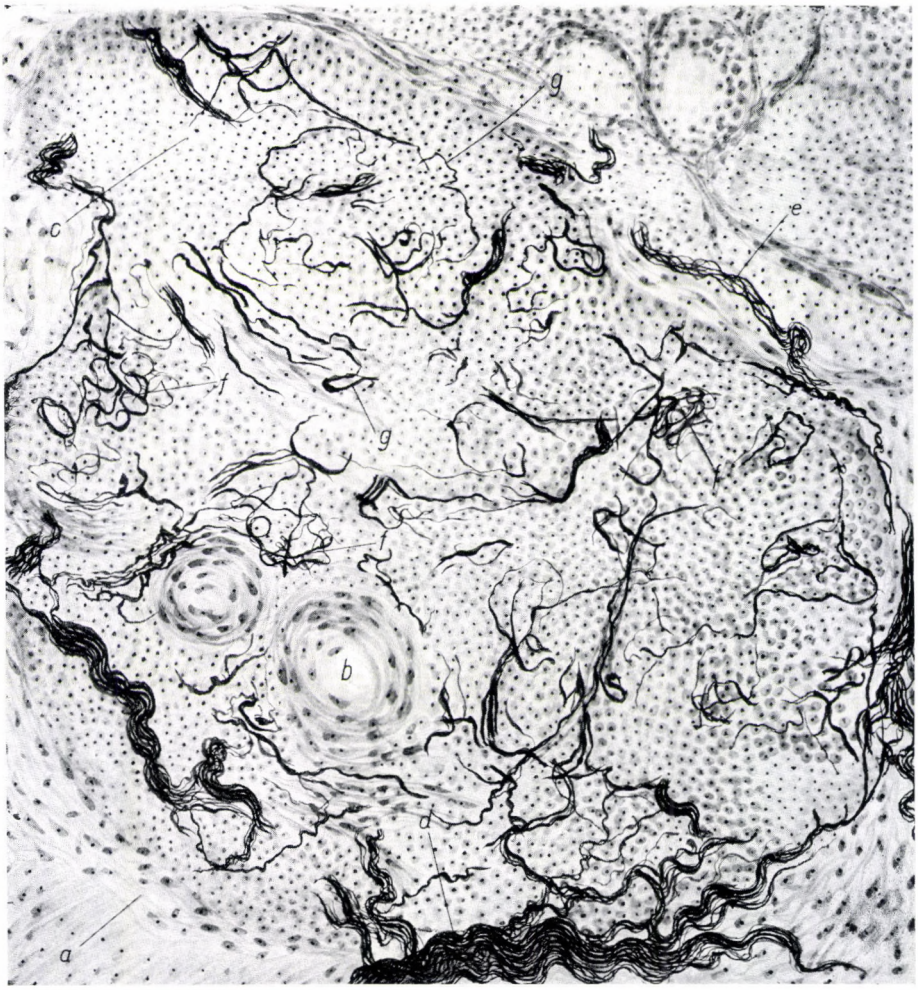

FIG. 194. *Columba domestica.* Glomus caroticum. (a) Connective tissue capsule; (b) artery; (c) glomus cell; (d) nerve bundle; (e) plexus periglandularis; (f) plexus intraglomerularis; (g) nerve fibre. Bielschowsky–Ábrahám's method. Microscopic magnification 240×, reduced photographically to ½

complicated and especially rich fibre system typical of the glomi of adult birds had not yet developed. Around, but also inside, the smaller islands, coil-like arrangements of nerve fibres are so numerous that their descents are traced only with the greatest difficulties. Nevertheless, in each case it was demonstrable that apart from dendritic branchings, these fibres bore no dendritic characters, viz. abrupt thickening, narrowing, varicosity, neurofibrillar intermediary and end plates were absent. Careful examinations revealed only that the fibres becoming gradually thinner after each branching run a long winding path around, or inside, the com-

partment's borders, then end in end knots, bulbs, or rings of varying sizes. These end formations were described first by Nonidez from the glomus of newly hatched chicks. Examination in adult birds have proved the validity of Nonidez's findings showing that the fibres end on, and between, the glomus cells actually in the forms described by Nonidez (Fig. 194).

Mammals (Mammalia)

In mammals and man, the carotid glomus is essentially a small hidden organ. It was discovered by Haller in 1743 and owing to its resemblance to a ganglion he actually had considered it one. Later, the investigators refused this concept, but the glomus' true nature is still unknown. Luschka (1862) considered it a gland and accordingly termed it "glandula intercarotica". He claimed that the carotid glomus was a cavernous organ with thick walls, associated closely with the jugular part of the sympathetic nervous system. Kohn (1900) called it a paraganglion. The same opinion was stated by Watzka (1934), who named it "paraganglion caroticum". According to Kohn (1903), paraganglia are secondary organs of the peripheral nervous system and on the basis of their histological structures they may be divided into three groups. To the first group belong those originating from the sympathetic nervous system. These are the chromophilic and adrenaline-producing paraganglia located in the abdominal and pelvic cavities. The second group is constituted by paraganglia whose plexuses arise partly in the sympathetic and partly in the cerebral nervous system, and only part of their cells is chromaffin, the remainder not staining with chromium salts. With the third group are classified the paraganglia located exclusively, or prevalently, in the cerebral nervous system. The cells of these ganglia display no affinity whatever for chromium salts.

The carotid glomus of mammals is localized at the carotid bifurcation. It is invisible externally. In this respect the horse is an exception as evidenced by our studies performed on various domestic mammals [dog (*Canis familiaris*), calf (*Bos taurus*), sheep (*Ovis aries*), horse (*Equus caballus*)]. In the latter, the carotid glomus is a macroscopically well visible, relatively large dense body, protruding from the bifurcation, thus being readily excised for histological studies. The glomus' histological structure is essentially the same in mammals as in birds. The insubstantial differences encountered are summarized below. In mammals, the glomus cells are relatively large, usually elongate, elliptic, with a foamy cytoplasm. The connective tissue capsule is thicker, the septa dividing the cell islands are more dense, the nerve fibres relatively thin (Fig. 195).

The glomus' nerve supply is extraordinarily rich. The connective tissue capsule is traversed by a multitude of rich fibre systems and nerve trunks. The fibres passing in the trunks gradually loosen to form extensive plexuses. It appears that these fibres have two different origins, part of them being thick, part thin. The former belong to the fibre system of the glossopharyngeal and vagus nerve, whereas the latter are of sympathetic origin. The sympathetic origin of the majority of fibres passing in the trunks is shown, beside their external appearance, also by



FIG. 195. *Ovis aries*. Glomus caroticum. (a) Connective tissue capsule; (b) glomerulus; (c) chemoreceptor cells; (d) nerve bundle; (e) periglomerular nerve plexus. Bielschowsky–Ábrahám's method. Microscopic magnification 480×, reduced photographically to ½

the fact that in the descent of plexuses larger ganglia of the sympathetic type are apparent (horse, pig) (Fig. 196). The ganglia are elongate and occur usually at the margins of the connective tissue capsule where some of them may be arranged in a row-like sequence. The nerve cells are large, mostly multipolar and show numerous particular forms both in pig and horse. Cell forms that have practically lost all features of a nerve cell occur particularly often in the ganglia of the horse. Since, however, here and there also normal ganglia, i.e. ganglion cells, are seen, we believe that the peculiar appearance of the rest is due to ageing. In both



FIG. 196. *Equus caballus*. Nerve cells and nerve plexus in glomus caroticum. (a) Connective tissue bundle; (b) nucleus of connective tissue cell; (c) nerve bundle; (d) nerve fibre; (e) nerve cell; (f) process of nerve cell; (g) special nerve cell; (h) ganglion. Bielschowsky–Ábrahám's method. Microscopic magnification 200×, reduced photographically to ½

the horse and pig, single nerve cells are seen beside the ganglia also in the descent of nerve trunks and bundles. As a rule, these cells are attached to the nerve trunks by strongly thickened processes.

In mammals as in birds, nerve fibres traversing the glomus cell islands form extraordinarily rich plexuses constituted particularly at the margins of the islands by nerve fibres of very variable thickness. The fibres forming plexuses inside the islands are extraordinarily thin and most microscopic pictures suggest their conjugation with the surface of glomus cells in the form of free endings, i.e. pericellular coils. Further below we deal in detail with the carotid body of dog and man.

Dog (*Canis familiaris*)

The carotid body of the dog is an ovoid, elongate solid body located in the carotid bifurcation very close to the origins of the occipital and ascending pharyngeal arteries, connected with the arterial wall by a thin layer of loose connective tissue. The body itself is surrounded by a relatively thin connective tissue capsule. The matrix of the body comprises cells known in the literature as "glomic", "typical" or "epitheloid" cells. The glomic cells present in the dog's carotid body are rounded or slightly elongate cells with roundish central nuclei. The cells do not extend processes and have no neurofibrils in their cytoplasms.

In the dog's carotid body the following nerve supply was found. Receptor fibres originating from the vagal and glossopharyngeal nerves form on the body's surface a rich and loose plexus (plexus superficialis), whose fibres run parallel with the surface. Fibres arising from this superficial plexus (plexus periglandularis) in the internal part of the body form loose or sometimes dense plexuses around the glomeruli (plexus periglomerularis), then enter the glomeruli forming therein a loose plexus (plexus intraglomerularis) whose end fibres are in intimate contact with the glomic cells. Numerous appropriately impregnated sections have shown that the end rami of receptor fibres terminate in the glomeruli. The terminals assume the form of end bulbs or end rings. End bulbs and end rings appear as roundish bodies located between, or sometimes on, the glomic cells. No nerve end formations, either of nerve fibres or neurofibrils, were detected inside the cytoplasm of glomeric cells.

In the dog's carotid body, beside end bulbs and end rings conjugating with glomeric cells, sensory nerve end systems were also detected which apparently play an important role in the organ's physiological function. One sensory nerve end system was found along the arteries and a sensory end plate system in the area of the glomeruli.

The sensory nerve end system located around the arteries is essentially a spiral structure constituted by some thick nerve fibres embracing the wall of the artery over a considerable distance. The nerve fibres forming the spiral are thick, undulating, of varying diameter, winding in some places around the entire circumference of the vessel. This system may be feasibly called a periadventitial sensory end system, responsible for the perception of stretch and dilatation of blood vessels, control of blood flow towards the glomeruli and blood circulation in the carotid

body. So far no similar sensory nervous system has been encountered in our material. Since the nerve fibres constituting this system are thicker than those innervating the glomus cells, we have assumed that the perivascular spirals belong to the vagal nervous system.

The nerve end plate system found in the dog's carotid body is quite unusual. One peculiarity is that the end fibres forming the end plates are enormously thick and occur quite seldom in the glomerular system of the carotid body. The other peculiarity is that the end plates are of the same structure as the end plates of pressoreceptors, the only difference being that in the carotid body they are much smaller. In some areas of the glomeruli end plates occur in large numbers and are sharply bordered against each other. In our opinion, based on morphological findings, these end systems are pressoreceptor systems. In view of these circumstances it seems to be feasible that the carotid body serves not only for the perception of certain chemical stimuli, but also for the perception of pressure exerted by the blood vessels situated around the carotid body in the bifurcation.

Man (*Homo sapiens*)

The carotid glomus of man, belonging according to Watzka to the second group of paraganglia is located in the bifurcation of the common carotid artery at the posterior part of the medialis so that its upper portion protrudes over the branching and touches the wall of the internal carotid artery (Riegele). It is elongate oval in shape. Its histological structure has been known fairly precisely on the basis of descriptions by Marchand (1891), Schaper (1892), de Castro (1926), Riegele (1928), Sunder-Plassmann (1930), Watzka (1934), Meyling (1936), Ábrahám (1942), de Kock (1954) and others. Its examination is relatively easy, no particular difficulties being encountered in sectioning and staining. No special techniques are required for its processing. Histologically, its structure is readily examined after staining with haematein and eosin.

The human glomus is encased by a relatively thick connective tissue capsule which extends its processes (septa) into the organ, dividing it into smaller or larger, roundish or elongate islands, the so-called glomeruli. The tissue constituting the septa is called interglomerular tissue, to distinguish it from the capsule. From the interglomerular tissue, delicate bundles go to the glomeruli actually responsible for the organ's function.

The glomeruli consist of large polygonal oval or roundish cells being well defined only in fresh condition. In materials from several days old cadavers, usually available for neurohistological examination, only the nuclei of the cells are clearly apparent. In such material, reliable examination of the cytoplasm can be performed infrequently and even then only under high magnification. In preparations from stored specimens the cells are shrunken, their cytoplasm shows uneven borders and, as seen in preparations obtained by Bielschowsky's method, retracted from the cell membrane. In his injection preparations, Schaper found part of the cells arranged along the vessels like a simple cylindrical

epithelium. This phenomenon is apparent also in impregnated preparations. This was mentioned already by de Castro, who thought, however, that at certain sites the capillary walls were constituted by the glomerular cells themselves. The above observations inferred a very close connection of glomerular cells with the blood vessels. A feasible explanation for this phenomenon would be offered by regarding the carotid glomus actually as an endocrine gland.

As evidenced by Riegele and Watzka, part of the glomerular cells are chromaffin. This implies that their cytoplasms maintain best their shapes in solutions of chromic acid where they assume a yellowish-brown colour (Henle's reaction). According to Riegele, the cytoplasm reduces chromates which simultaneously fix the cell contents. With other methods of fixation, the contents leak from the cell, and deformation ensues. This phenomenon occurs also in cases when the specimen is not fixed immediately after death in an appropriate chromate solution. The presence of chromaffin cells was denied by de Castro who on this basis opposed the paraganglionic concept of the glomus caroticum.

The glomerular cells decompose rapidly. This was explained by Kohn by the diffusion of cell contents in the surroundings. As known from the examinations of Riedel and Wiesel, the cell contents are easily extracted from the cells in a preparation. The chromaffin cells are not the exclusive constituents of the glomeruli, containing also cells resisting the staining with chromium. For this reason Watzka classified the human carotid glomus with the second group of paraganglia.

The carotid glomus is richly supplied with blood. Its blood supply is provided by a small artery, known as the glomus artery, which usually exits from the bifurcation of the common carotid artery, but may also arise in the external carotid artery (Luschka, Heppner); Marchand described a case when it originated in the internal carotid artery.

According to Riegele, the glomus artery enters the organ as a rule at its bottom pole, then divides into numerous branches which form a rich network in the capsule. From this network exit smaller arteries to the interglomerular connective tissue, penetrating therefrom into the glomeruli where they subdivide to capillaries among the rows of cells described above. The capillaries unite to form small veins already inside the glomeruli and these join the veins passing in the interglomerular connective tissue. These veins are passing outward, while their calibres increase and unite with the venous plexus surrounding the glomus.

The above survey implies that the location, position and structure of the human carotid glomus have been fairly well known. Yet Berkelbach van der Sprenkel (1934) raised the question "Was ist eigentlich das Glomus caroticum?"* and answered, "Das wissen wir eigentlich nicht"** . Therefore the carotid glomus still presents a wide scope for research. Below we describe our observations made on the innervation of the human carotid glomus using various silver impregnation techniques.

The carotid glomus, as had already been observed earlier, receives its nerve supply partly from the ramus caroticus of the glossopharyngeal nerve, partly

*"What actually is the carotid glomus?"
** "That we do not actually know."

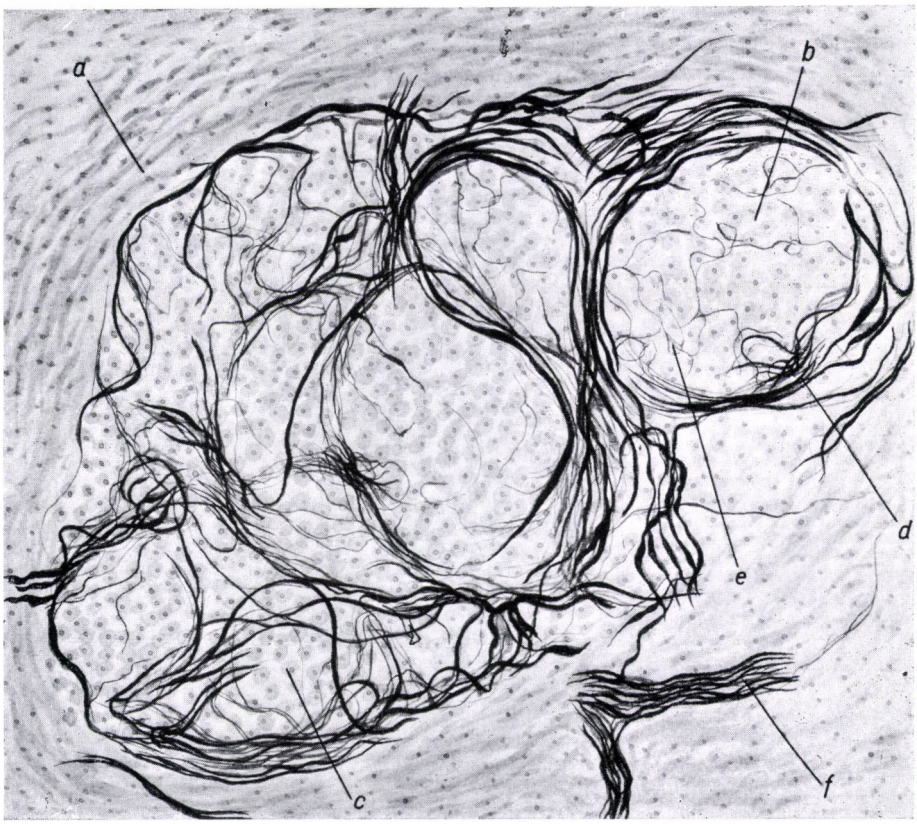

FIG. 197. *Homo.* Glomus caroticum. (a) Connective tissue capsule; (b) glomerulus; (c) chemoreceptor cells; (d) periglomerular plexus; (e) intraglomerular plexus; (f) nerve bundle. Bielschowsky–Gros–Cauna's method. Microscopic magnification 480×, reduced photographically to ½

from the laryngeus superior of the vagus or from the vagus itself. In addition, fibres are sent by the upper jugular ganglion of the sympathetic trunk and very likely sometimes also by the glossopharyngeal nerve itself. The fibres originating from the different nerves form a plexus around the glomus, called plexus periglandularis (Fig. 197). This plexus consists of bundles of varying thickness, attaching closely to each other and frequently also exchanging their fibres. Along the fibres passing in smaller or larger trunks tapering nuclei are apparent which are the nuclei of the Schwann sheath. According to earlier investigators there are smaller and larger ganglia in the descent of the bundles. In human material, I saw no ganglia myself but inconsistently with the views of Wilson and Billingsley I may state that single ganglion cells actually do occur in the plexus. The latter are clearly recognizable in haematein–eosin-stained and impregnated preparations. As judged by their outer appearance and structure these cells seem to belong to the sympathetic system.

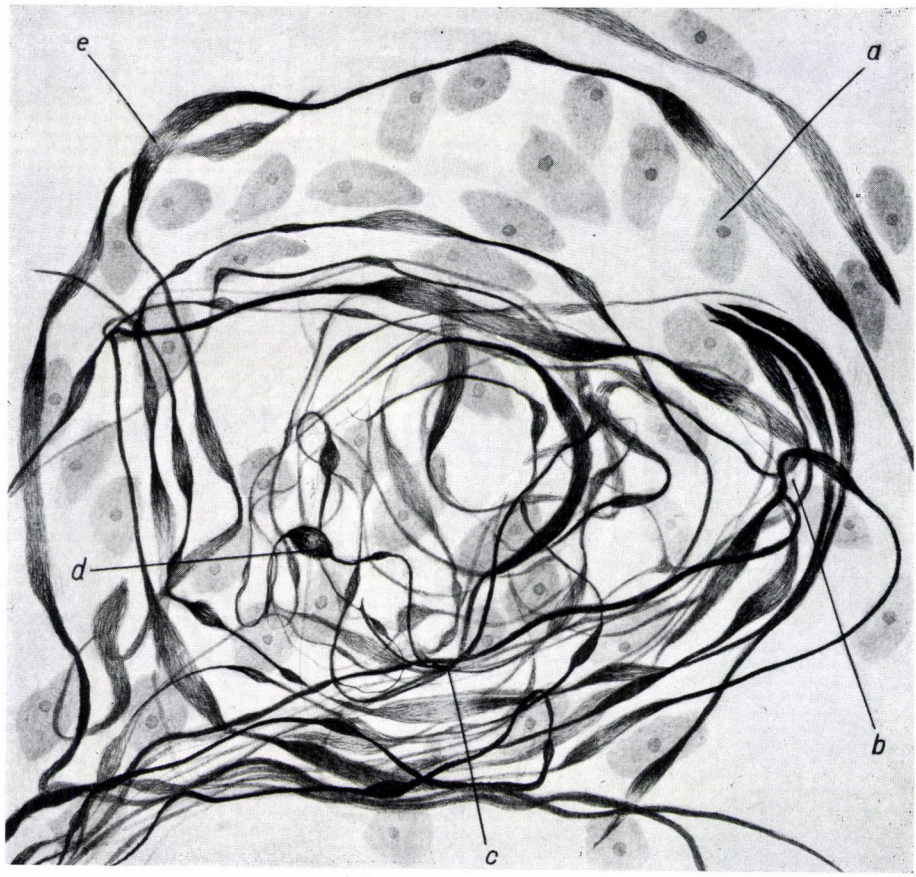

FIG. 198. *Homo.* Glomus caroticum. (a) Chemoreceptor cell; (b) periglomerular plexus; (c) intraglomerular plexus; (d) varix; (e) neurofibrils. Bielschowsky–Gros–Cauna's method. Microscopic magnification 1350×, reduced photographically to ½

From the periglandular plexus smaller trunks are passing to the borders of the glomeruli where they go nearly in a circle on the cell border and constitute the periglomerular plexus. The fibres of this plexus usually pass on, traversing occasionally the whole glomerulus or, more often, they return from its border. Inside the glomerulus the entering and returning fibres form a dense variable plexus known in the literature as intraglomerular plexus (Fig. 198).

Figure 199 presents an 1800× magnified clear view of the intraglomerular plexus' structure and its junction with the cells. The cells seen in the figure are surrounded by an almost regularly-shaped coil constituted by varicose, sharply fibrillar nerve fibres. The coil's structure infers its sensory nature as well as the presence of tactile cells. These and similar coils may be present in such abundance

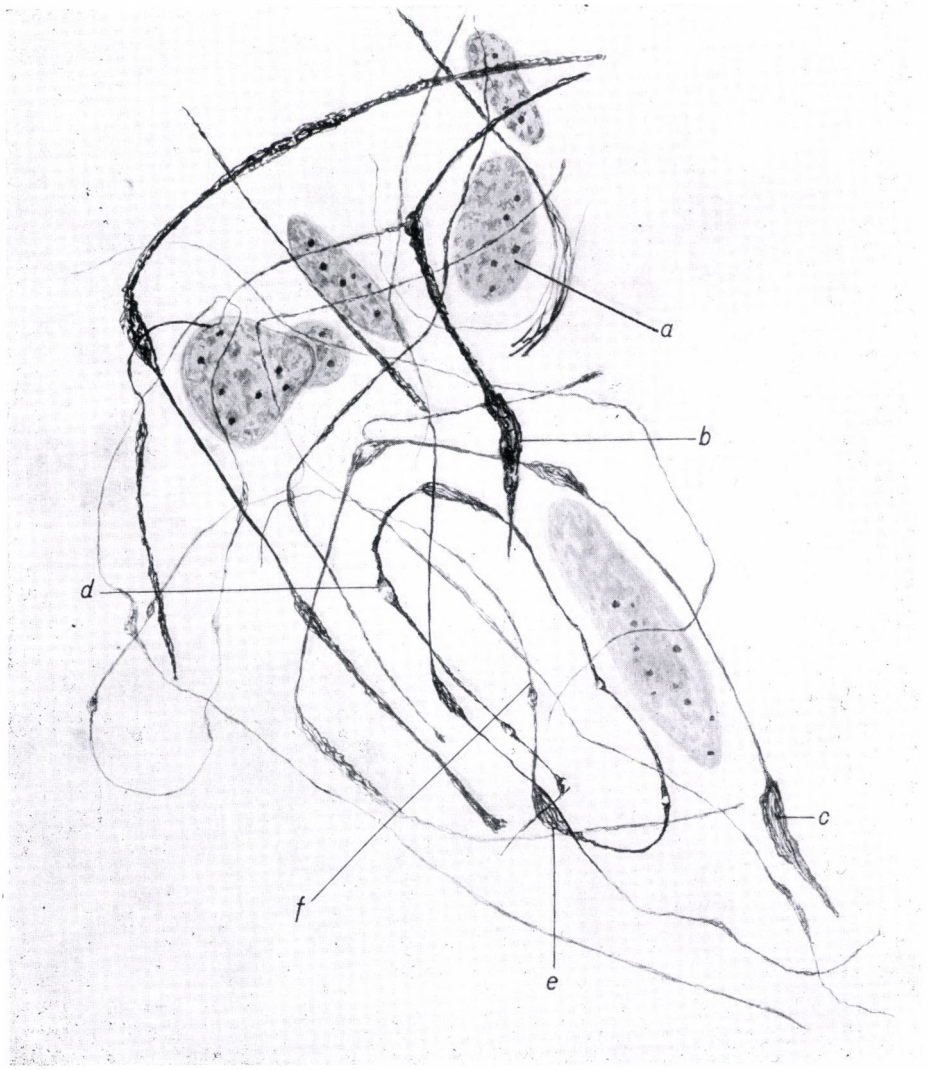

FIG. 199. *Homo.* Glomus caroticum. Intraglomerular nerve coil. (a) Chemoreceptor cell; (b) nerve fibre; (c) neurofibrils; (d) varix; (e) intermediarly pate; (f) nerve fibre coil. Bielschowsky–Gros' method. Microscopic magnification 1800×, reduced photographically to ½

and variety within a single glomerulus, that their correct copying by drawing is practically beyond consideration (Fig. 199).

The intraglomerular coils are not bordered against each other, being most frequently linked by fibres, some of them passing further and ending in the next glomerulus' system. Thus the adjacent glomeruli are closely linked with each



FIG. 200. *Homo*. Nerve plexus in the glomus caroticum. (a) Connective tissue; (b) nucleus of connective tissue cell; (c) chemoreceptor cell; (d) nerve fibre; (e) periglandular plexus; (f) periglomerular plexus; (g) intraglomerular plexus. Bielschowsky–Ábrahám's method. Microscopic magnification 600×, reduced photographically to ½

other and form a coherent physiological unit irrespective of their apparent independence and separation (Fig. 200).

All coil structures are variable, being constituted by such large masses of thick and thin fibres as to render the identification of their structure and function nearly impossible. Therefore, in order to settle this problem it should be clarified whether the nerve fibres do end in the carotid glomus, and if they do, how. After a thorough examination of the preparations we answered the first item in the affirmative.

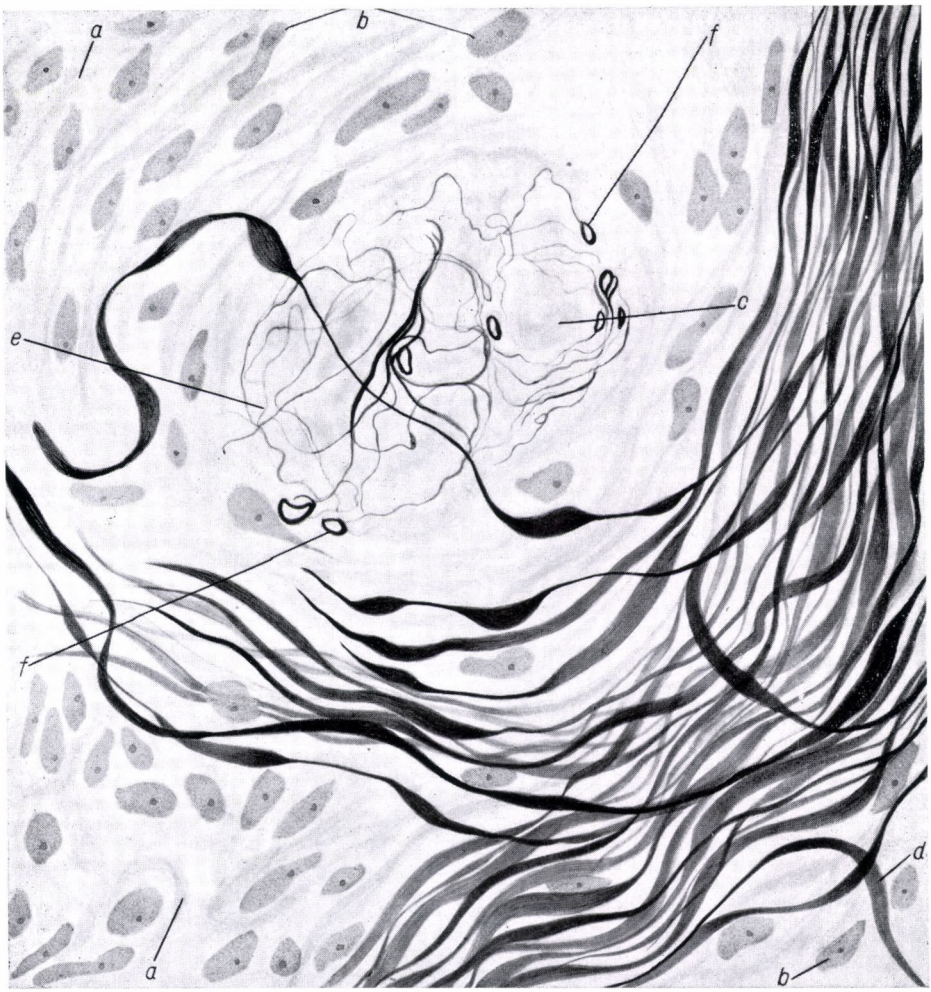

FIG. 201. *Homo*. Nerve endings in the carotid glomus. (a) Connective tissue; (b) nucleus of connective tissue cell; (c) chemoreceptor cell; (d) nerve fibre; (e) nerve plexus; (f) nerve ending. Ábrahám's method. Microscopic magnification 1350×, reduced photographically to ½

We found that the delicate varicose fibres, constituting the plexus forming sometimes a pericellular bag around the cell, ended freely either between, or on, the cells. According to our examinations the terminals are end knots, bulbs or rings, well visible in the thinner sections under a high magnification. These endings appeared in larger numbers, particularly in the central part of the intraglomerular plexuses (Fig. 201, Plate V/b, p. 247).

Beside the smaller end bulbs and end rings in some cases the fibres ended in a flower-like pattern formed by wraith-like neurofibrils surrounding the dense, angular end body.

As with the experience obtained form animal material (rat, guinea-pig, hedgehog, cat, dog, pig, sheep, cattle, horse), the bulk of the glomeruli consists of glomus cells. Beside them, there are also relatively many capillaries and sinusoids present. The latter are most conspicuous in the relatively thicker sections, nevertheless they might also be encountered with unexpected clearness within the glomeruli as well as in the interglomerular and periglomerular connective tissue. Such phenomena were observed mainly in histological preparations from glomera of individuals suffering from respiratory troubles (cor pulmonale).

It is usual to distinguish among the glomus cells chief and accessory cells (Adams, 1958). The greater part of the glomeruli consists of chief cells, while accessory cells are located usually near the capillaries and the sinusoids probably even forming the wall of the latter, as described by most of the authors.

The chief cells are polygonal or spherical, relatively large cells. They have different diameters in different species of mammals. In man, the diameter varies from 7·5 to 8 μ (Mártinez). The nucleus is spheroidal, conspicuous and bordered sharply by a nuclear membrane. As stated by de Kock (1954): "... the nucleus remains unstained with most stains and contains up to three nucleoli". The cytoplasm is occasionally granulated. Some workers have observed mitotic forms. Certain authors observed the cells to be sharply bordered against each other, while according to others they anastomosed through their processes and protrusions, and have even formed syncytia. The independence of the cells in contrast to their syncytial character has been advocated by de Castro (1926, 1951), de Winiwarter (1926), Zimmermann (1942), Watzka (1943), Hollinshead (1943, 1945), and Ostermann (1952). The syncytial theory has been maintained by White (1935), Meyling (1936, 1938), and Mártinez (1939). There are authors (Hollinshead, 1943) claiming to have seen fine connective tissue elements to separate the cells. Others, however, have even seen capsular cells around the glomus cells. As mentioned in the book on *Comparative Anatomy* by Adams, there was an author (Clermont, 1955) who stated "that the cells of the carotid body possess longer processes, true non-medullated axis cylinders".

The number of mammalian species having two different types of chief cells in their carotid glomus is relatively high, according to certain authors (Sato, 1932). One type is the so-called "light", the other the "dark". In the literature, the former is usually remembered as "chromophobic", while the latter as "chromophilic" type. The protoplasm of the light cells stains poorly with eosin, the nucleus contains little chromatin and the number of nucleoli is one or two. The dark cells are intensively stained by eosin, and have small, chromatin-rich nuclei (de Castro, 1929). The existence and the relative incidence of these two cell types have been related to the age or sex and some even state that their incidence is related to the number of hours elapsed between death and the time of the specimen's fixation. Others, as stated by Adams, "... regard the 'light' and 'dark' types of different origin". Langer thinks that the two cell types are actually two different appearances of one and the same cell type.

In the chief cells, mitochondria are frequent which according to the electron microscopic study of Lever and Boyd (1957) are different in the light and the dark

cells. There are certain authors who have described in the glomus cells Nissl granules, neurofibrils, neurofibrillar networks and some even lipid inclusions and pigment granules.

In the second group of glomus cells are included the accessory glomus cells. To these belong the type 2 glomus cells described by de Kock. These cells are " . . . ordinarily ovoid or elongated, and usually somewhat smaller" as stated by de Kock (1954). They are present between the sinusoids or capillaries and the type 1 cells, though in a much lower number than the cells belonging to type 1, or to the chief cells. As a rule, three to six type 2 glomus cells are present in one glomerulus per twenty to thirty type 1 cells. The former attach so closely to the walls of the capillaries that they seem to be part of the vessels' walls. Their nuclei stain readily and contain usually one centrally localized nucleolus. According to de Kock, it is particularly characteristic for these cells that "nerve fibrils, simple and beaded, ramify across and/or through the cell". Some have classified also the interstitial cells of Cajal with the accessory cells. De Kock attaches great importance to these cells, particularly in respect of the nerve interconnections. Two types of these cells have been discovered by her in the carotid glomus (cat, sheep, rat). She mentions one type as "stellate", and the other as "non-stellate". According to her description, in impregnated preparations these cells are embedded ". . . in the neurofibrillar plexus of the glomerular tissue in close proximity to both types of glomus cells".

According to the literary data, nerve cells and fuchsinophilic cells should also be regarded as accessory cells. Fuchsinophilic cells contain granules intensively staining with fuchsine (Hollinshead, 1945). De Kock (1954) detected in impregnated preparations certain cells which she designated fuchsinophilic, i.e. "red" cells.

The occurrence of nerve cells of sympathetic origin has been described (Boyd, 1937) in the connective tissue surrounding the carotid glomus and more seldom in that between the glomeruli.

Up to now we have not attempted a closer study on cytological conditions in the carotid glomus, our chosen field being rather its innervation, that is the clarification of the nature of relationship between the individual end fibres of the rich nerve fibre systems sent to the glomerular region and the glomus cells which, based on this view, we have considered roughly uniform in shape and structure. Yet at present we are in a position to comment objectively on this question, having collected in the meantime sufficient material for doing so. In this country, Dr. Wiltner (Kékestető) and Dr. Niedermüller (Gyöngyös) have recently routinely performed glomectomy for the treatment of asthma bronchiale. Part of the removed glomera were submitted to my laboratory for histological diagnosis, thus I had the possibility to study perfectly fresh material by cytological as well as neurohistological methods.

In order to get more familiar with the morphology and fine structure of the much studied and much discussed glomus cells, we have prepared serial sections from appropriately fixed specimens and performed several staining studies with different methods presently available. For neurohistological studies the specimens were fixed in 10 per cent neutral formalin and the material was used to prepare

frozen sections. The preparations obtained were impregnated by the number II Ábrahám procedure, described in the first part of this volume. The 30 μ thick impregnated frozen sections were then embedded and used for the preparation of serial 5 μ thick sections which were stained with carmine or haematoxylin in order to permit the examination of the end system and the connections of the nerve fibres' terminal fibres with the glomus cells, very well impregnated by the method applied. A detailed study of the specimens and histological preparations thus obtained permitted the following conclusions in respect of the cytological and neurohistological problems outlined above.

In both human and animal specimens, glomus cells were in general found to be very similar, having a homogeneous protoplasm and being of a polygonal or spherical morphology. The distinction of chief and accessory cells appeared to be only partly justified, type 2 cells of de Kock (1954) being only vaguely distinguishable from the chief cells on the basis of the features given in the literature. Nevertheless, there are certainly some cells here and there which differ from the chief cells mainly in respect of the shape of their nuclei and in their staining reactions. It is mainly the structure and the staining characters of the nuclei which seem to permit such a differentiation.

The chief cells are sharply bordered against each other and there was no sign whatever of anastomosis. The nucleus is a spherical homogeneous body localized in the middle of the cell and being usually poorly stained by common nuclear stains. In the cytoplasm there are smaller or larger vacuoles, their presence is, however, neither general nor specifically characteristic. The cells do not have processes, there are no tigroid granules in their cytoplasms, neither are there neurofibrils nor neurofibrillar networks detectable. The differentiation of light and dark glomus cells did not seem to be justified on the basis of the cytoplasm's staining. The incidence of cells of one or another staining was sporadic and seemed to be the result of certain external or internal factors or, of the latter's changes.

As to the nerve supply of glomeruli, I would emphasize the following in accordance with my previous statements: In man, the nerve supply of glomeruli of the carotid glomus is particularly rich. Among the animals examined (rat, guinea-pig, cat, dog, swine, sheep, calf, horse) none had exhibited a richness of nerve supply comparable to that in man's carotid glomus. In the latter, particularly in thicker sections, the glomeruli consisting of glomus cells are traversed by such a multitude of nerve fibres of different calibres that they hardly allow for the detection of the glomus cells themselves.

The nerve fibres, which practically overflowed the interglomerulal connective tissue and the interior of the glomeruli, may exhibit remarkable alterations in persons of different ages, suffering from different diseases. In certain cases, all nerve fibres are especially thin, smooth, forming concentric and elongate coil systems which either cross each other or form regular circles. In other cases, however, part of the fibres are thin, smooth-edged, while others exhibit smaller or larger, sometimes extraordinarily long varices connected with each other through shorter or longer thin connecting pieces. Fibres exhibiting varices and indentations similar to those

apparent in pressoreceptor fibres are not infrequent either, particularly in aged persons.

All kinds of nerve fibres ramify near their site of junction with the glomus cells. The branches become remarkably thin, constituting a plexus hardly visible even microscopically. In that plexus, the terminals of nerve fibres are very difficult to trace in autopsy material. As described above, naturally also in such materials have been detectable delicate end fibres ending in relatively large and conspicuously sharp end rings and also end rings whose junctions with the nerve fibres were not visible. Thus, at first sight it was surprising that in freshly fixed specimens the number of end rings was extraordinarily high. While examining these preparations, I wondered about why I could so seldom see the ends of the nerve fibres, respectively the latter's connections with the glomus cells in specimens obtained from autopsies. I think I am right in supposing that in preparations obtained from cadavers, the endings are poorly detectable even in perfectly impregnated preparations because these, being in close connection with the cells, are disintegrated simultaneously with the latter.

The ring-shaped endings of nerve fibres are detectable everywhere in the glomeruli, particularly on their periphery where multitudes of them make an appearance when viewed through the microscope, located either at varying distance or quite close to each other. The actual relationship of these endings, i.e. rings, with the cells, is difficult to clarify even by examinations made on fresh material. A very intimate connection between cells and endings is at least doubtful. Fibres may probably end in the cells, but terminals may be located as well on the cell's surface, without entering its cytoplasm. The intimate connection of nerve fibres with glomus cells, as well as the strong influence of the nervous system on glomus cells, are suggested by the presence of numerous nerve endings inside the glomeruli. On the basis of recently obtained microscopic pictures I do not hesitate to suppose, or rather state, that each glomus cell has its own nerve connection and probably even more than one nerve fibre may end on, or in, one glomus cell (Fig. 202, Plate V/d, p. 247).

Accordingly, my concept on the end connections of nerve fibres in the glomerular area correlates well with that of de Castro (1929) with the difference, though, that on, between, or perhaps also in, the cells I have not seen menisci (menisques terminaux) like him but distinct rings or rather end knots, i.e. end spheres.

Thus I am obviously in no position to agree with Meyling (1938), Goormaghtigh (1939) and de Kock (1954) who stated that the interstitial cells are playing the role of mediator between the nervous system and glomus cells. I do not agree either with the view that the intermediary cells—if there are any—are embedded "in the neurofibrillar plexus of the glomerular tissue in close proximity to both type glomus cells" and that ". . . one or more interstitial cells seem invariably intercalated between the point of entry of the fibre into the glomerulus and the glomus cells themselves".

On the basis of my preparations I cannot confirm the statement by de Kock (1954) that ". . . fine branches pass to enter the cytoplasm of the glomus cells". Also, I failed to detect among the glomus cells any neurofibrillar plexus synapsing

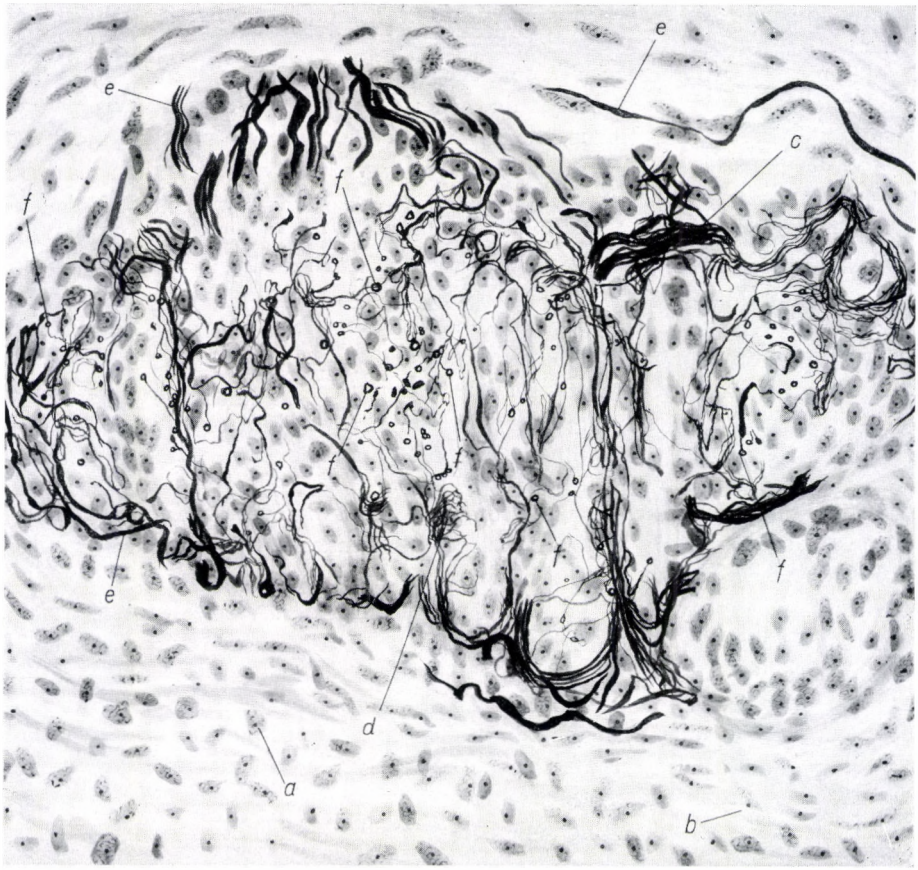

FIG. 202. *Homo*. Glomus caroticum. (a) Nucleus of connective tissue cell; (b) connective tissue fibre; (c) plexus periglomerularis; (d) plexus intraglomerularis; (e) nerve fibre; (f) nerve ending. Ábrahám's method. Microscopic magnification 600 ×, reduced photographically to 1/2.

with the end branches of the glossopharyngeal nerve (Meyling). There are no interstitial cells and even if there are any, they have no role in the conduction of impulses. In fact, they are simple connective tissue cells whose processes may anastomose but there is no evidence whatever for their nervous nature. The non-existence of an "independent" neurofibrillar plexus not connected with the end fibres of the glossopharyngeus is evidenced by the degeneration ensuing in the cat after nerve transfixion. The same was demonstrated electronmicroscopically by Ross (1957), showing that the end fibres of the glossopharyngeus end directly and freely on the surface of the glomus cells.

It should be noted in this context that in a capsular vein of the human carotid glomus we have found a nerve ending showing a structure identical with the pressoreceptor-type nerve endings occurring in large masses in the aortic arch and carotid sinus. This end formation as well as those detected by us in the capsular

arteries of the carotid glomus in sheep and dog, is suggestive of the presence in the carotid glomus' vessel system of rich sensory nerve end systems responsible for the control of blood flow through the glomus in accordance with the actual physiological state, through stimuli from the nervous centres in the medulla oblongata and the respective portions of the sympathetic nervous system.

Once the structure of the carotid glomus was elucidated, the question was justly raised what purpose this hidden and complicated organellum might serve. It was considered by Arnold a haemangioma, whilst by Kose and Stilling a chromophilic organ. After having destroyed the carotid glomus of experimental animals, Vassale, Lanzilotta and Massaglia observed glycosuria in them. In experimental animals injected intravenously with glomus extract, Frugoni observed hypotension and bradycardia. The opposite was stated by Mullon who reported elevation of blood pressure in horses given glomus extract. The experiment by Mullon was successfully reproduced by Lansilotta. In young cats, Fischer and Betge extirpated bilaterally the bifurcation region of the carotid artery and 6 weeks later the animals developed inappetence, poor dentition and retardation of growth. Also, their bones were porose, calcium-poor and the usual ossification centres were missing. Inconsistently with these observations Klug claimed to have found neither physical nor clinical signs in young dogs after extirpation of the carotid bifurcation region as well as the common carotid artery. From this he concluded that the carotid glomus is of no vital importance and regarded it accordingly as an accessory organ intermediate between the thymus gland and adrenals.

De Castro, who examined the carotid glomus first in 1926, concluded that this organ performs the function of a gland. As an explanation he offered that the glomerular cells are not so much chromaffin as epitheloid cells, showing a cytoplasmic vacuolization. In his opinion, the cytoplasmic mitochondria as well as the nuclear alterations were indicative of the glomerular cells' glandular function. As a further support of his hypothesis, de Castro referred to the specific sensory nerve endings detected by him in the walls of the carotid glomus' arteries and regarded them as endings of glossopharyngeal or vagal fibres. He supposed that changes in the blood pressure or composition of blood would produce a stimulation of these sensory endings which is then conducted through the centripetal fibres of the glossopharyngeal nerve to the medulla oblongata, where through the efferent fibres of the same nerve a stimulus is conducted to the carotid glomus' cells, initiating their secretory activity. The secretion is then carried to the blood stream and distributed throughout the organism.

De Castro resumed his examinations of the carotid glomus in 1928, and based on his newer findings revoked his earlier views. He stated that there are no centrifugal secretory fibres in the intercarotid nerve arising in the glossopharyngeus, but it consists exclusively of receptors. Therefore the carotid glomus is not so much a gland as a sensory organ serving the perception of the "qualitative changes" taking place in the blood.

Sunder-Plassmann (1930), who examined the histological structure of different carotid glomera by staining and impregnation techniques, reported inconsistent results and noted that the function of the carotid glomus "keineswegs restlos

geklärt ist" ("is by no means perfectly elucidated"). He stated that the glomus cannot be the anatomical basis of Hering's sinus reflexes, as the specific receptor is located in the carotid sinus' and not in the glomus' wall. Yet, as judged by its structure and abundant blood and nerve supply, it cannot be an accessory organ.

In the investigation of glomus function, the experiments of Heymans and Bouckaert (1939) have been a great step forward. They detected in the carotid glomus certain receptors which, depending on the actual blood level of CO_2, exerted reflectorically either a stimulatory or a paralysing action on the respiratory centre in the medulla oblongata. Heymans and Bouckaert proceeded from the known physiological fact that out of the chemical factors carbon dioxide and oxygen are playing the most important role in the regulation of circulatory functions. The respiratory centre of the medulla oblongata is stimulated by CO_2-rich blood, while paralysed sometimes to the grade of apnea by CO_2-poor blood. Heymans and Bouckaert experimented on dogs and set up an ingenious system by isolating the carotid sinus from the circulation, leaving the nerve supply intact. Flow of CO_2-rich or CO_2-poor blood through the isolated carotid sinus stimulated, respectively suppressed, the respiratory centre, even causing apnea. The stimulatory effect on the carotid sinus was observed even when the CO_2 content of the blood was below the physiological level. Hence these experiments evidenced the presence in the carotid sinus of specific receptors, influencing reflectorically the respiratory centre. The same experiments proved that the chemoreceptors of the carotid sinus are localized in the region of the carotid glomus, as already assumed by de Castro on the basis of his morphological studies. The receptors of Hering's sinus reflexes operated by the pressure exerted on the vessel wall, localize in the sinus wall. Also, the experiments by Heymans and Bouckaert proved that after artificial embolization the carotid sinus' region lost its chemosensitivity, while its pressure sensitivity remained unimpaired.

The studies by Heymans and Bouckaert have pointed out the right approach to the structure and function of the carotid glomus, "this mysterious tissue" (Heymans and Neil, 1958). In the meantime, dozens of workers have conducted tenacious research to give a reliable and definitive answer to the innumerable questions arisen in this context. These questions, put in various forms by workers of different fields, may be essentially grouped with two problem complexes. As put by L. Ross (1957), one of them is "the mechanism of the response of the cell to lowered blood oxygen tension", the other "the means whereby the chemoreceptor cell initiates an impulse along the afferent nerve fibre". Both complexes are being extensively studied and there is hope of arriving at definitive conclusions before long.

ACCESSORY GLOMERA

The designation "accessory glomus" has been applied to island-like formations of varying sizes seen in the adventitia of the pulmonary artery and large arteries or in the associated periarterial connective tissue, namely in the fat tissue accumu-

lated therein. Structurally, the connective tissue bundles arrange as a rule in a capsule-like manner around the insulae. Inside the capsules, the matrix is constituted by small, roundish or slightly elongate cells attaching closely to each other. The nuclei and, especially, the nucleoli of the cells are very conspicuous in silver-impregnated preparations. Usually one or more myelinated nerve fibres enter the capsule and once inside, they give off numerous rami which become thinner and form a rich plexus in the insula. Accessory glomera occur in larger numbers in insulae where the arteries branch or give off larger branches.

Birds (Aves)

According to our findings, in the arterial system of birds accessory glomera occur in the outer adventitia of the arterial trunk, arteria anonyma and aorta, near the periarterial connective tissue. All of them are smaller or larger cell insulae, occurring in groups, pairs or singly, in varying extensions. Their structure corresponds to that of the glomus, being encased by a thick capsule formed of collagenous bundles, containing numerous vessels and nerve trunks of varying thicknesses. Nerve bundles and branches exiting from the latter constitute a rich plexus which, according to our observations, contains neither ganglia nor single nerve cells. From the connective tissue capsule surrounding the organellum exit bundles which surround the individual cell insulae. The main constituents of the glomeruli are the glomus cells. They are roundish, with very conspicuous nucleoli, homogeneous cytoplasms and circumscribed margins. They are arranged close to each other.

Nerve fibres entering the cell insulae from the plexuses surrounding the organellum, i.e. the cell insulae, are occasionally very thick, their borders are smooth and undulating, with relatively frequent dichotomic branchings in their descents, resulting in a gradual narrowing of the fibres. The thin fibres form in some places loops, in other places elongate plexuses. The terminal rami often intertwine with each other and form dense plexuses whose single fibres conjugate closely with the epitheloid cells (Fig. 203).

The first survey of our preparations prompted us to assume that there are no nerve endings in the cell insulae, the linking organ being the nerve plexus in which we failed to detect endings of the fibres. Later on, however, after careful examination at higher magnification, we discovered nerve endings between, or around, the cells. These endings appeared to belong to two types: coils and end bulbs. The former, seen only under very high magnification, are very delicate loose coils constituting the terminal structure of a single fibre and surrounding the cell entirely. Such formations were seen relatively infrequently but in every case they appeared as true endings conjugating with the cell surface over a large area. The other type of endings are the end bulbs which—as suggested also by their name—are in most cases roundish in shape, but some of them are elongate or even tapering.

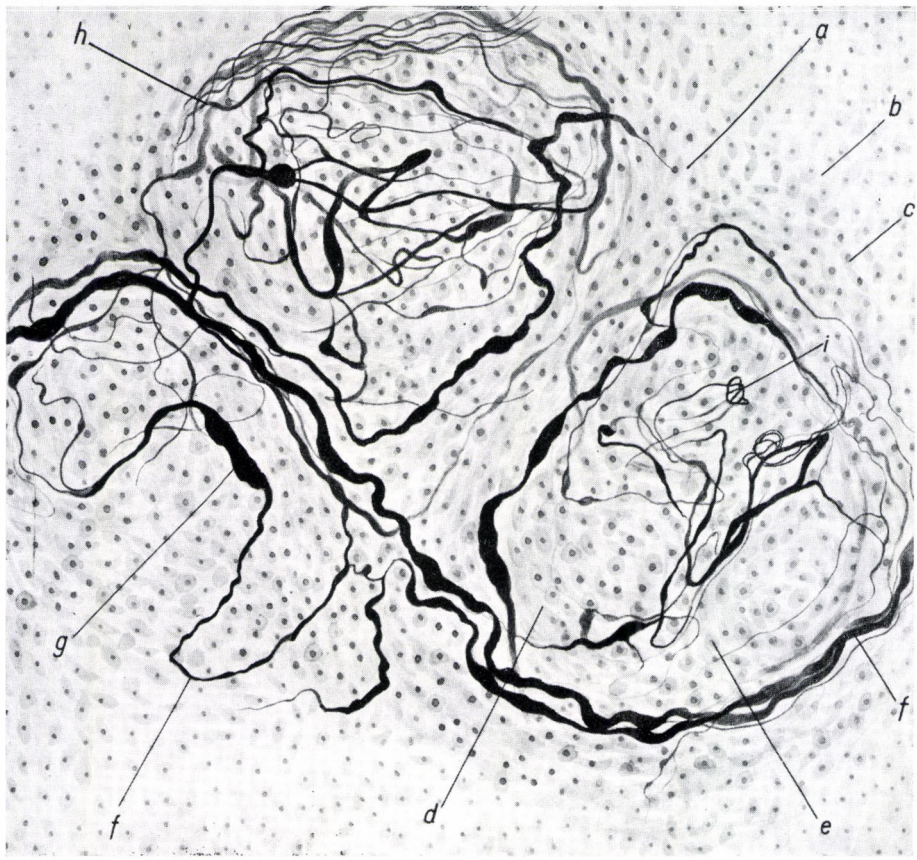

FIG. 203. *Ardea cinerea*. Accessory glomus in the aortic wall. (a) Connective tissue capsule; (b) connective tissue; (c) nucleus of connective tissue cell; (d) glomerulus; (e) chemoreceptor cell; (f) nerve fibre; (g) varix; (h) periglomerular plexus; (i) intraglomerular plexus. Bielschowsky–Ábrahám's method. Microscopic magnification 600×, reduced photographically to ½

Mammals (Mammalia)

In mammals, we found accessory glomera in the pulmonary artery, aortic arch and endocardium. In the pulmonary artery, namely of the cat and pig, accessory glomera were found in a larger number where the artery divided into two branches. In that region, numerous accessory glomera were detected in the fat tissue surrounding the pariarterial connective tissue along the descent of the arteries, particularly of the cat. These glomera were relatively small, roundish tissue complexes whose nerve elements yielded particularly well to impregnation. A larger number of accessory glomera was found also in the pig. They were localized mainly at the branchings of the pulmonary artery in the periarterial connective tissue

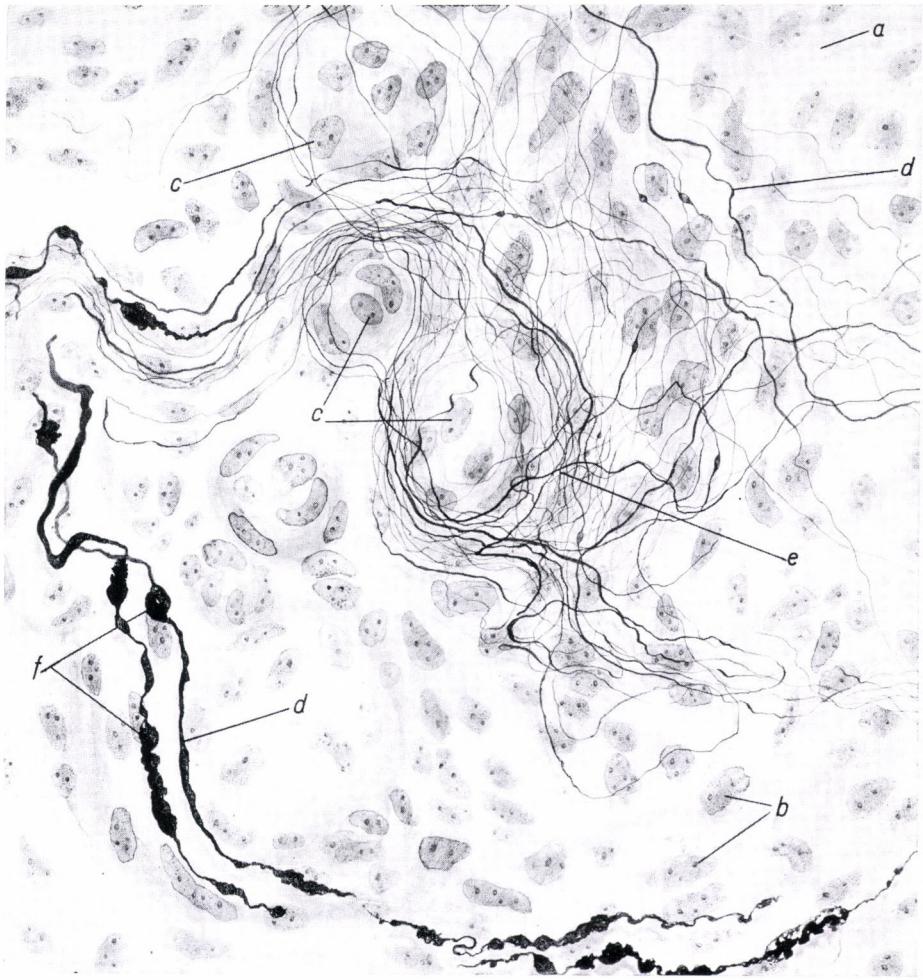

FIG. 204. *Homo.* Arcus aortae; chemoreceptors in the adventitia. (a) Connective tissue; (b) nucleus of connective tissue cell; (c) chemoreceptor cell; (d) nerve fibre; (e) nerve fibre plexus; (f) varix. Bielschowsky–Gros' method. Microscopic magnification 800×, reduced photographically to ½

and in the outer adventitia. The accessory glomera found in the pig were relatively large, elongate and the protoplasm of glomus cells was of a foamy structure. Innervation was poorer and nerve fibres impregnated less readily than in the cat.

Man (*Homo sapiens*)

In man, accessory glomera were found in large numbers in the outer adventitia of the aortic arch. They were also described by Seto under the name "paraganglia". These bodies as well as their constituent cells are relatively small similar to the

glomus cells in general. Nevertheless, the nerve supply of human accessory glomera is incomparably more rich than that described for other mammals in the foregoing. Nerve fibres arriving at the organella in a myelin sheath, branch off and form a very dense coil system among the glomus cells. In the glomus the ends of nerve fibres are invisible (Fig. 204).

Apart from some very slight dissimilarity, the structures of accessory glomera are essentially identical with that of the carotid glomus. This consistency is suggestive of their being considered chemoreceptors, too. This is supported also by the fact that in every case, numerous precapillary arteries and capillaries have been detected around the glomera.

INNERVATION OF THE HEART VESSELS

The blood supply of the heart is provided by the coronary and intracardial arteries. All these vessels are very rich in nerve fibres, in general richer than the vessels supplying the other parts of the body with blood. Of the heart vessels we describe in detail the innervation of coronary arteries, sinus coronarius cordis, vena cordis magna and intracardial vessels, as observed by detailed examination of respective specimens from pig, calf, roe-deer and man.

Coronary Vessels

The innervation of the coronary vessels differs from the general schedule of vessel innervation. Therefore, the nerve connections of the coronaries are discussed separately below. The relevant differences may be summarized as follows: the nerve supply of the coronaries is in general richer than that of other vessels. The tunica media of the former is particularly richly innervated. Nerve cells of special structures are present in the periarterial plexuses and here and there also in the vessel wall.

Coronary Arteries

The nerve connections of the coronary arteries (arteriae coronariae cordis) were examined on a variety of materials (calf, roe-deer, pig, man). These studies were very time-consuming, but by tenacious work we succeeded in obtaining preparations which allowed the clarification of all details of nerve connections.

Examination of the innervation of coronary arteries are rendered particularly difficult by the fact that vessels from larger animals are very hard and the frozen sections prepared from them resist impregnation even more than the usual materials. With specimens from man, difficulties have been encountered mainly in the cutting procedure. It is known that in the majority of cases sclerotization results in a marked hardening of these vessels. In the impregnated preparations, mainly in those obtained from older subjects, the tunica media was scattered with smaller

or larger calcium granules or concretions, staining black by impregnation. Also, the specimen may be so hard as to resist cutting by the microtome blade. In a case when we prepared longitudinal tangential sections from a human coronary artery, we noticed that the knife's edge was fractured ! I immediately started to search the reasons of this uncommon phenomenon. I examined the frozen vessel wall very thoroughly and detected a slightly luminescent homogeneous body in the adventitia. This I removed with a dissecting needle and noted with surprise that it was a stone of a size relatively large in context of the vessel's measurements and of its position therein. This stone blunted the edge of the microtome knife (Fig. 205).



FIG. 205. *Homo*. Stone recovered from the wall of the arteria coronaria cordis. Photography

Both in man and animals, the conditions of innervation were examined by a uniform procedure in frozen tangential sections impregnated by different modifications of Bielschowsky's method. In the preparations prepared in large numbers, the following observations were made on nerve connections.

Around the coronary arteries, particularly of man, a rich periarterial nerve plexus is present. Most of the fibres constituting the plexus pass parallel to the vessel's longitudinal axis, while the minority link the larger trunks and vessels with each other, taking various directions. In the trunks, bundles and nerve branches passing in the plexus, two kinds of fibres are apparent, one of them thicker, the other thinner. The larger part of the fibres is smooth, undulating and arranged in a hair-tress-like pattern. The smaller part of the fibres is thick, varicose, straight, here and there fibrillar, and in most cases impregnates more strongly than the thinner ones (Fig. 206). The thin fibres belong to the sympathetic, the thick ones to the vagal sensory system. It is of interest that, particularly in specimens from animals, thick vagal parasympathetic fibres impregnate deep black, while the sympathetic fibres stain pale, thus being readily distinguishable from each other.

In the periarterial plexus particularly of man, numerous ganglia and nerve fibres are apparent. Most of these nerve cells are multi-processed and may be classified as Dogiel type I. The dendrites are conspicuously short and mostly end very close to the cell in dendrite plates. The neurite is thick and enters the nerve trunk. Some of the cells, particularly in human material, show a peripheral confluence of dendrites, giving rise to cell formations known in the literature as windowed cells. Nerve cells, singly or in pairs, are seen relatively frequently also along the paths of nerve trunks. They are multipolar and their dendrites are extraordinarily short.

Nerve trunks supplying the vessel wall run directly at the border, i.e. in the outer layer, of the adventitia. Their positions and trends are suggestive of their

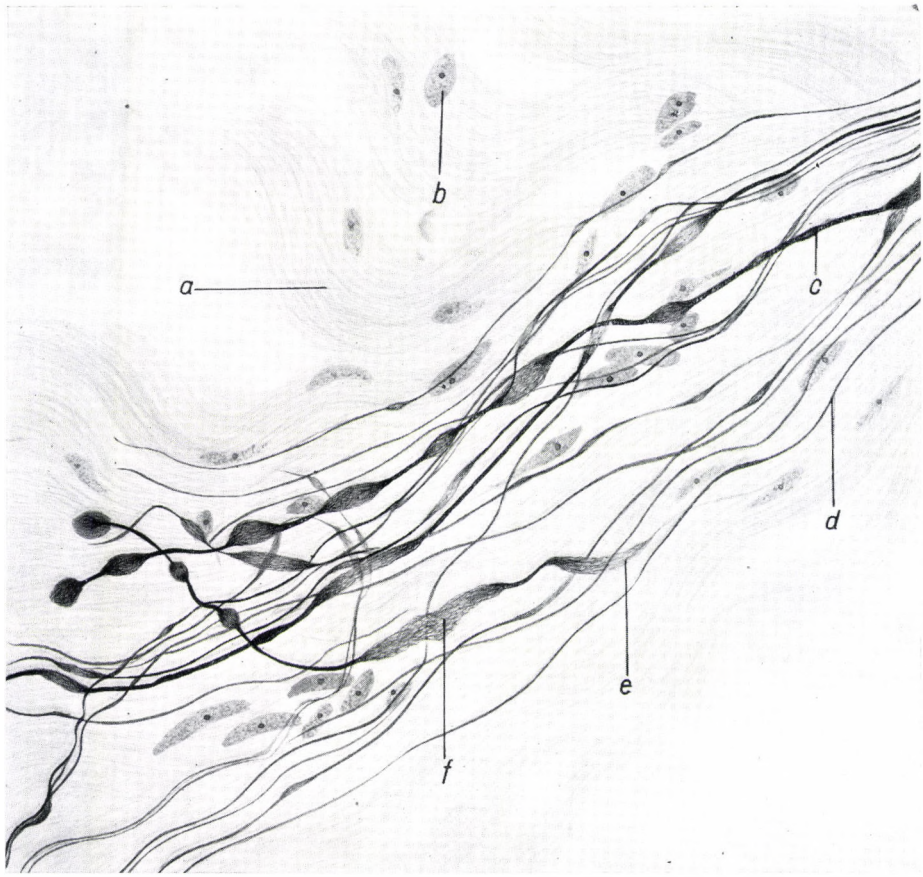

FIG. 206. *Homo*. Arteria coronaria cordis dextra; nerve fibre plexus in the adventitia. (a) Connective tissue bundle; (b) nucleus of connective tissue cell; (c) thick nerve fibre; (d) thin nerve fibre; (e) varix; (f) neurofibrils. Bielschowsky–Gros–Cauna's method. Microscopic magnificaton 800×, reduced photographically to ½

coming directly from the cardiac plexus. From the trunks exit here and there bundles which crisscross in the outer adventitia. These bundles, and the smaller bundles exiting from them in large masses, constitute a plexus containing a different fibre system which becomes looser at the inner border of the adventitia to form even looser and more extensive plexuses in which the pressoreceptor-type darkly impregnating thick fibres are well distinguishable from the paler, smooth, thin fibres (Fig. 207).

From the plexus at the inner border of the adventitia exit masses of fibre systems whose single fibres run parallel in the connective tissue, becoming denser and denser inwardly. From these loose plexuses exit here and there very delicate fibres which, crisscrossing each other, form a very dense plexus whose like was not

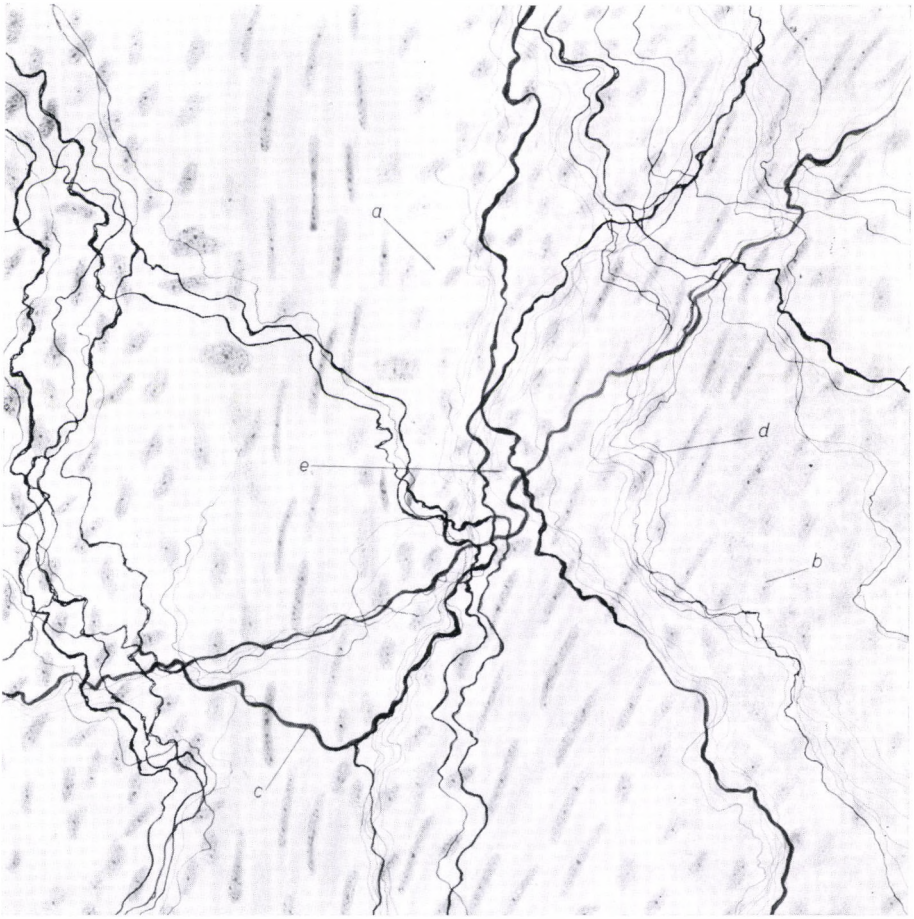

FIG. 207. *Bos taurus*. Arteria coronaria cordis sinistra; nerve fibre plexus in the adventitia. (a) Connective tissue; (b) nucleus of connective tissue cell; (c) thick nevre fibre; (d) thin nerve fibre; (e) nerve fibre plexus. Bielschowsky–Gros–Cauna's method. Microscopic magnification 800×, reduced photographically to ½

seen in any other artery. In these plexuses the mass of overstriding delicate fibres presents a nerve picture which at first sight may be considered a reticulum by the superficial observer. Again, this is an illusion. In every case, thorough examination under high magnification has revealed that this is a plexus and not a reticulum. It should be noted, however, that these plexuses should be considered true end plexuses whose single end fibres, disappearing between the connective tissue elements, are receptors of the adventitia. This extremely delicate plexus is in some places so dense that its survey was impossible even at the highest magnification.



FIG. 208. *Sus scrofa domestica*. Arteria coronaria cordis. Ramus circumflexus; receptors in the adventitia. (a) Connective tissue; (b) nucleus of connective tissue cell; (c) nerve fibre; (d) nerve ending. Bielschowsky–Ábrahám's method. Microscopic magnification 600×, reduced photographically to ¾

In the adventitial plexus, constituted similarly to the arteries by an outer coarser and an inner more delicate and loose plexus, fibres of different thickness and appearance are present. The two types of fibres are apparent in the wall of each coronary artery, but their dissimilarity is particularly conspicuous in the coronary artery of the pig and calf. In the pig, the larger and smaller nerve trunks and plexuses contain beside large masses of thin fibre bundles also smooth, readily impregnable dense thick fibres in a relatively large number. In some places they exit from the trunks, i.e. bundles in groups, and pass on in the inner adventitia, then

occasionally diverge and end in well-visible dense, round knots in the connective tissue or—less frequently—in the media (Fig. 208, Plate IV/d, p. 244).

Thick fibres are fairly frequent in the connective tissue as well as in the smooth muscle layer of the pig's coronary arteries; endings are, however, scarce. The idea that the reason for this should be sought in technical conditions is not wholly improbable, nevertheless the endings' scarcity may as well be explained by the small number of thick fibres present.

Thick fibres appear in particular abundance and with special features in the calf's coronary vessels. Their descents are non-uniform, showing alternately thick and thin portions. The broadened portions are as a rule fibrillar, the interportions homogeneous. Particularly in the base, but also in other parts of the trunks, the thick fibres are frequently seen to divide into two branches, each passing on with another dividing bundle. In general, these fibres run a long path without branching, as is well visible in tangential sections obtained from the adventitial area. In the calf's coronary artery, some of the thick fibres are occasionally as thick as those seen elsewhere only in the aortic arch and carotid sinus. Occasionally, also the forms of these thick fibres' branchings and the connections of the branch system with the connective tissue are clearly apparent (Fig. 209). As shown in the figure, the conspicuously thick fibre is homogeneous, smooth and straight in descent. After having covered a longer distance, it thickens slightly, then divides into three branches which run parallel quite far. Later on they become gradually thinner and after having given off their end branches, continue in a rich end plexus system whose single end fibres form a plexus hardly discernible microscopically, then disappear between the connective tissue elements without forming any end structures.

It seems to be certain that the thick fibres most clearly apparent in the calf's coronary artery and also those seen in the pig's coronary artery, are receptors of the arteria coronaria cordis constituting the receptive end system of reflexes generated in this vessel. Beside these reflexogenic fibre systems, in the loose outer adventitia there are also bundles and plexuses formed by thin fibres passing between the connective tissue cells with large nuclei. These fibres, together with a part of the delicate plexuses located in the inner adventitia, belong to the end organ system of presso- and algoreceptors.

Nerve supply is much poorer in the tunica media than in the adventitia, though the media of coronary vessels is relatively thick and apparently poor in elastic elements. Nerve plexuses become richer at the junction of the media with the adventitia. Actually, nerve impulses go from the outer to the more extensive inner part of the muscle layer. Naturally, this must not be interpreted as if the tunica media were nerve-free. Here, too, are seen some smaller bundles, thinner fibres and more sparse plexuses. In the outer part there are also very delicate plexuses, appearing occasionally in an unbelievable abundance, giving the impression that Stöhr's concept of the supply of each smooth muscle cell by a separate nerve fibril is true.

Beside the nerve end systems controlling the movements of the vessel wall, the media contains also sensory apparatuses. Pictures have been occasionally encount-

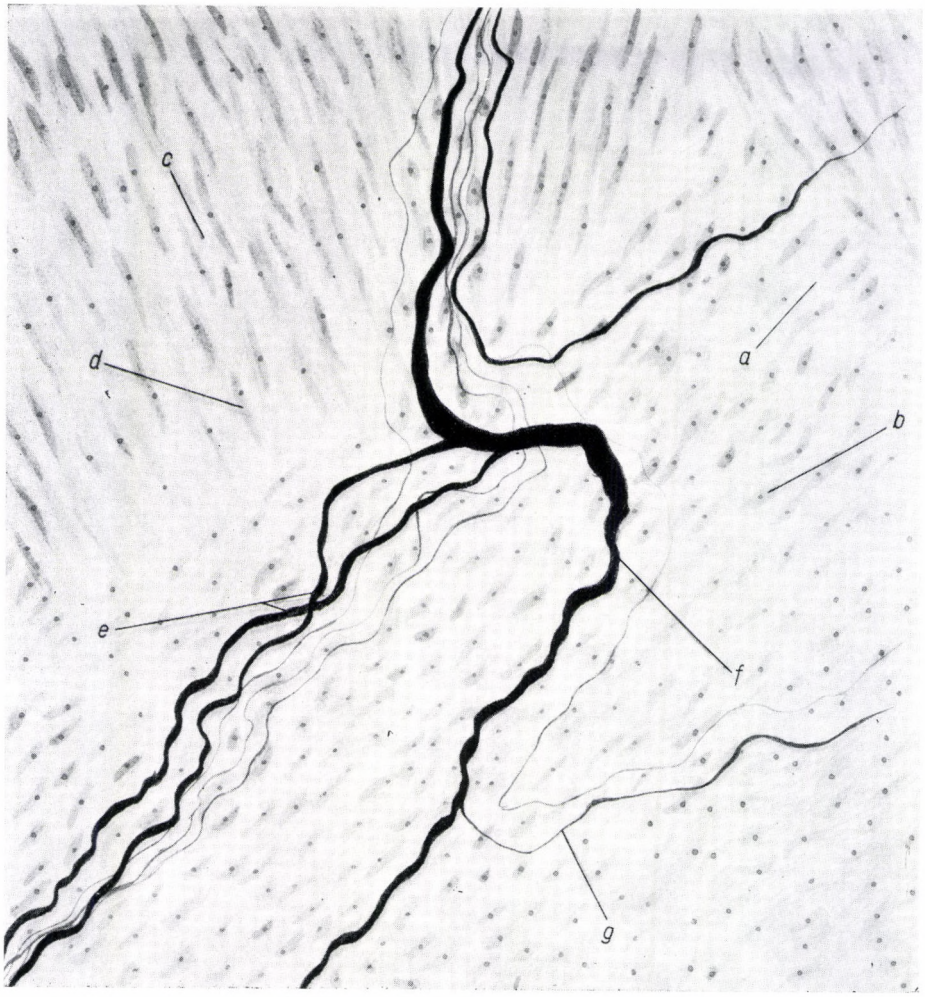

FIG. 209. *Bos taurus*. Arteria coronaria cordis sinistra; nerve fibre plexus in the adventitia. (a) Connective tissue; (b) nucleus of connective tissue cell; (c) smooth muscle cell; (d) nucleus of the smooth muscle cell; (e) nerve bundle; (f) thick nerve fibre; (g) thin nerve fibre. Bielschowsky–Gros–Cauna's method. Microscopic magnification 600×, reduced photographically to ½

ered, showing the passage of deep black impregnated and richly branching fibres in the tunica media. Their terminal branches ended in end rings. These end rings remind one of those seen in the end systems of pressoreceptors. In our opinion they are sensory end organs belonging to the vagal sensory fibre system which here, too, plays naturally a receptive role.

The third layer of the coronary arteries is the tunica intima. It is a thin connective tissue layer containing no nerve elements whatever, neither in animals, nor in man.

In the walls of the coronary arteries ganglia are also present, though in a small number (calf, pig).Beside the ganglia single or perhaps more nerve cells have been fairly frequently seen either inside, or adjacent to, the larger nerve trunks of the coronary arteries of the calf and pig. In every case, the ganglia are present in, or along, the larger nerve trunks. They are as a rule elongate formations whose structure is suggestive of a sympathetic origin. Most of the cells are multipolar and belong to the group Dogiel type 1.

The vessels in the coronary arteries' walls (vasa vasorum) are richly supplied with nerves. Along the larger arteries and veins pass strong nerve bundles, accompanying these vessels along their entire descents. From these trunks, i.e. bundles, exit here and there smaller rami which innervate the veins and capillaries. The connections of nerve fibres and vasa vasorum correspond to the general scheme of vascular nerve connections. Pictures showing larger capillary, i.e. precapillary, plexuses are more typical. They are surrounded by such a rich system of nerve fibres and among them delicate plexuses, whose like is hardly found in other vessel groups of a similarly small calibre. The capillary vessels are accompanied by thin single nerve fibres which here and there approach the vessel wall quite closely, sometimes contacting it, sometimes diverging never to return.

Sinus Coronarius Cordis

The wall of the coronary sinus consists of endothelium, connective tissue and muscle tissue. The endothelial cells are flat, as in the heart's cavities in general. The connective tissue layer is thick, constituted mainly by connective tissue bundles, the muscle tissue is built up by striated muscle fibres which are attached to the myocardial elements directly without transition. Both in the connective tissue and among the muscle bundles, very much fat is present particularly in man. The coronary sinus' wall, whose innervation was examined by us on specimens from calf and man, is relatively poorly supplied with nerves. As in the larger veins (vena cava superior, vena cava inferior), so here, only nerve trunks and bundles are seen which pass parallel to the vessel's longitudinal axis after having conjugated with each other here and there. Delicate plexuses are absent. Fibres passing in the trunks, bundles, and nerve branches are thin, smooth and undulating, their appearance being suggestive of a sympathetic origin (Fig. 210).

Both in man and animals, the wall of the coronary sinus is characterized by the presence of ganglia and nerve cells, occurring in large numbers in the connective tissue along, or apart from, the nerve trunks. In man, single nerve cells are seen even in the muscle; in the majority of the cases these nerve cells exhibit quite remarkable forms.

As to the ganglia and nerve cells the following may be said. In the calf's coronary sinus, ganglia are quite numerous. In general they are large, readily impregnable and display a typical sympathetic character. The cells are large and mostly multipolar. Among the cell forms, two well-defined types may be distinguished. One of them is markedly elongate on one pole, while broadened and rounded on the other.



FIG. 210. *Bos taurus*. Nerve fibre plexus in the wall of sinus coronarius cordis. (a) Connective tissue; (b) nucleus of connective tissue cell; (c) capillary; (d) nerve trunk; (e) nerve bundle; (f) nerve cell; (g) nucleus of nerve cell; (h) ganglion; (i) nerve plexus. Bielschowsky–Gros–Cauna's method. Microscopic magnification 320×, reduced photographically to ½

In every case, the processes extend on a broad base from the elongate side. One process, in a central position, is relatively thick and passes very far from the cell body becoming gradually thinner as if it were a neurite The rest of the processes arise on a broad base, narrow gradually and end near the cell. The other cell form

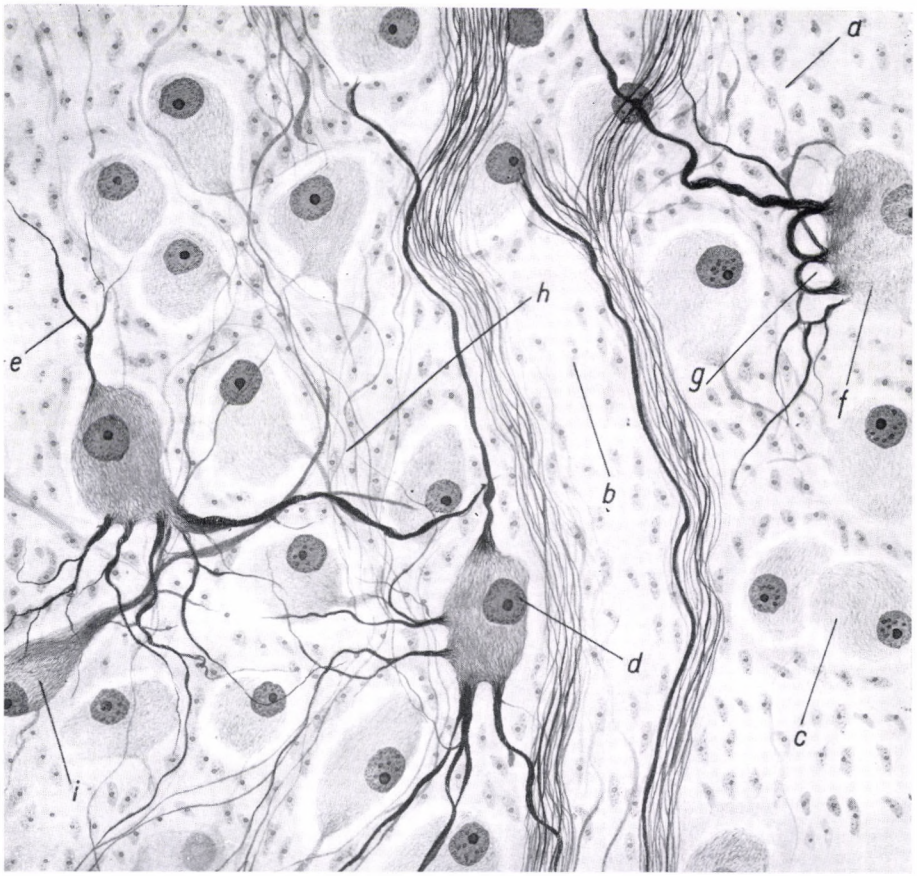

FIG. 211. *Bos taurus*. Ganglion in the wall of the sinus coronarius cordis. (a) Connective tissue; (b) nucleus of connective tissue cell; (c) nerve cell; (d) nucleus of nerve cell; (e) process of nerve cell; (f) fenestral cell; (g) fenestra (window); (h) nerve fibre plexus; (i) neurofibrils. Bielschowsky–Gros–Cauna's method. Microscopic magnification 400×, reduced photographically to ½

has a roughly polyedral body, its processes are uniformly distributed over its surface, arise on a broad base, soon become thinner and end in a tapering manner near the cell. Naturally, also the cells belonging to the second type have in every case a single process extending far from the cell and playing the role of a neurite.

In the wall of the calf's coronary sinus, so-called fenestral cells are present fairly frequently (Fig. 211). In general they are much large than the others, carry numerous processes which arise on a broad base and which narrow quickly. The window-like lattices arise by the confluence of pairs of processes not far from the cell's body. One of the cells' processes, which may well be considered a neurite owing to its connections, is longer than the rest and passing further enters a nerve trunk.



FIG. 212. *Homo*. Special nerve cell in the wall of the sinus coronarius cordis. (a) Striated muscle fibre; (b) nucleus of striated muscle fibre; (c) nerve cell; (d) dendritic plate; (e) process; (f) nucleus of satellite cell; (g) neurofibrils. Bielschowsky–Gros–Cauna's method. Microscopic magnification 800×, reduced photographically to ½

In the intraganglial plexus the preganglionic fibres are clearly distinguishable from the other paler fibres by their deep black colour assumed upon impregnation. The preganglionic fibres run a winding path between the cells, then divide into delicate varicose end rami which form pericellular plexuses on the cells, thus giving rise to synapses. Postganglionic fibres are thin, arranged in a hair-tress-like pattern, and exit from the ganglia in the form of thick bundles.

The ganglia present in the wall of the human coronary sinus are relatively small, consisting mostly of two to three cells. They occur repeatedly along the descent of one and the same nerve trunk. Most cells are multipolar but exceptionally also bipolar and unipolar forms have been encountered. Among the cells peculiar forms are very frequent; in ganglia of aged persons hardly any cells were seen to show the typical features of the neuron in an unaltered form. In general, their dendrites are short, lamella-like and rounded at their ends. Others are thinner and, melting together at a notable distance from the cell, they give rise to a cell form resembling the fenestral cells (Fig. 212). The supposition seems to be justified that the particular cell forms encountered in large masses in man are senile pathological forms.

Vena Cordis Magna

Based on our examinations in pig, calf and man, the nerve connections of the vena cordis magna may be described as follows. In the perivascular tissue, being in the overwhelming majority of cases extraordinarily rich in blood vessels, conspicuously thick nerve trunks are passing embedded in fat tissue. The number of nerve trunks seen along the vena cordis magna was the largest in man, next in the pig and finally in the calf. The perivascular plexuses contained ganglia exclusively in the pig. These ganglia are conspicuously large and numerous, one, or sometimes two, of them being apparent in each section. Their structure is indicative of their sympathetic origin. Cells constituting the plexuses are in most cases multipolar and always display a remarkable argentophilia. Particular and irregular forms are frequent, e.g. in the heart of the pig (Fig. 213).

From the perivascular plexus large nerve bundles and branches go to the outer adventitia where they conjungate closely with each other by mutual exchange of fibres. The nerve bundles frequently cross each other, become on such occasions looser and by exchange of fibres they form extensive plexuses. Most of the nerve fibres passing in the nerve bundles and trunks are smooth and undulating. Undulation is especially marked at the crossings.

Among the nerve fibres passing in the outer adventitia, many thick fibres have been encountered, showing occasionally quite pronounced argentophilia, particularly in the pig. The numbers of thick fibres, as well as their relations with the thin ones, are variable. They were found in largest numbers in the pig. Sometimes the thick fibres exit from the bundles, run a winding path and occasionally may be followed over a longer distance. Their appearance, structure and remarkable argentophilia are suggestive of their vagal sensory nature, although they have no myelin sheath. This has been evidenced by the extraordinarily interesting and rich, yet readily surveyable, nerve end apparatus detected by us in the wall of the human vena



FIG. 213. *Sus scrofa domestica*. Vena cordis magna; ganglion in the adventitia. (a) Connective tissue; (b) connective tissue bundle; (c) nucleus of connective tissue cell; (d) nerve cell; (e) nerve fibre; (f) nerve trunk; (g) nerve bundle; (h) fat cell; (i) nucleus of fat cell. Bielschowsky–Gros–Cauna's method. Microscopic magnification 300×, reduced photographically to ½

cordis magna and which according to its position, structure and shape seems to be a novelty in neurohistology (Fig. 214). The thick fibre passing in a larger nerve bundle exits therefrom and immediately gives off several lateral branches which ramify repeatedly near the main fibre, then end in round or elliptic end plates, the latter showing clearly visible neurofibrils. The other smaller part of the branches goes far from the site of branching, then after several smaller or larger windings becomes quite narrow and continues in large elliptic end plates. In the latter, which seem to end intracellularly, reaching even the nuclear membrane, neurofibrils are apparent. This end organ, whose like has not yet been detected in any artery or vein, does not resemble any of the nerve end formations known up to

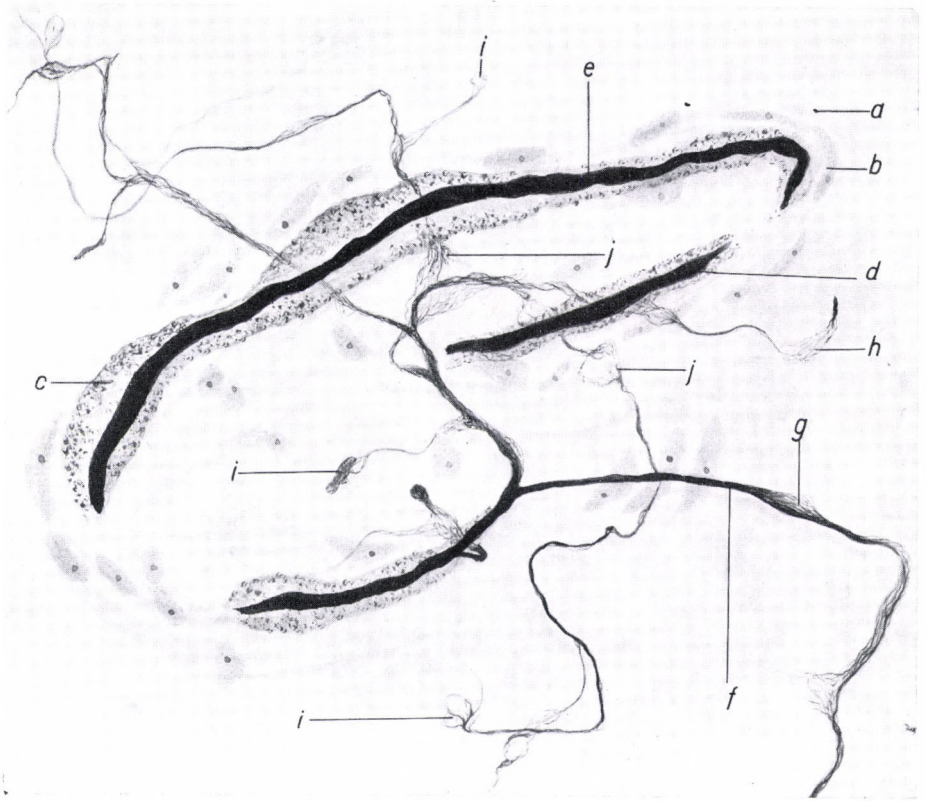

FIG. 214. *Homo*. Vena coronaria cordis magna; sensory nerve end organ system in the adventitia. (a) Connective tissue fibre; (b) nucleus of connective tissue cell; (c) myelin sheath; (d) axon; (e) main branch; (f) side branch; (g) varix; (h) neurofibrils; (i) end plate; (j) intermediary plate. Bielschowsky–Gros–Cauna's method. Microscopic magnification 1350×, reduced photographically to ½

now. Although essentially it is a rich dendritic end system, it does not resemble the pressoreceptors. Its complicated structure and bulk are suggestive of its special receptor nature serving for the perception of impulses conducted to the wall of the vena cordis magna (Fig. 215).

In the well-developed muscle layer of the vena cordis magna, the interlamellar plexus is also detectable. As compared to the outer plexus, this one consists of thinner nerve bundles and branches forming a looser and poorer plexus constituted mainly by sympathetic fibres. The bulk of sympathetic fibres is found in the inner part of the plexus. From this part, thin fibre bundles or, occasionally, single fibres go to the media's muscle layer where they conjugate with each other to form plexuses. The single fibres exiting from the plexuses become gradually thinner, then disappear on the surface of smooth muscle cells without forming any kind of terminal structure. In the intima no nerve fibres are present.



FIG. 215. *Homo.* Vena coronaria cordis magna; sensory nerve end fibre system in the adventitia. (a) Nerve fibre; (b) varix; (c) neurofibril; (d) nerve ending. Bielschowsky–Gros–Cauna's method. Microscopic magnification 1350×, reduced photographically to ½

Intracardial Vessels

The heart wall is very richly supplied with vessels, particularly in mammals. Both the cardiac arteries and veins are accompanied by thick nerve trunks whose fibres seem to be of sympathetic origin as judged by their appearance. In the wall of arteries there are numerous nerve bundles of varying sizes, consisting mainly of thin, smooth, undulating fibres. Beside them, in the bundles passing along, or inside, the vessel walls, there are thick fibres branching off here and there, thus giving the general impression that they would belong to the cerebrospinal nerve system and perform a sensory function.

Nerve fibres passing in the walls of the arteries form a triple network also in the heart, like in other organs of vertebrates. The outermost plexus is localized in the peripheral part, the middle one near the inner surface of the adventitia, while the inner one provides for the nerve supply of the media's smooth muscle elements. The two outer layers show no special features whatever. The grouping, arrangement and relation to the host tissue of the fibres are essentially the same as those observed in other similar formations. The innervation of the media is, however, dissimilar, being unusually abundant in nerves. In the media the network system is so rich that its like is hardly seen in the extracardial vessels. From the smaller and larger nerve bundles forming the plexuses exit rami which, by conjugation with each other, form secondary plexuses. From these exit single fibres forming delicate end plexuses whose single fibre elements are closely connected with the muscular elements of the media. The interpretation of this connection is very difficult, but the absence of a terminal reticulum may be definitely stated. The innervation of veins resembles that of the arteries, except that the veins' walls are—in accordance with their structure—poorer in nerve fibres (Fig. 111).

Along the capillaries single nerve fibres pass, accompanying them over a long distance in an undulating manner. Beside the accompanying fibres some others are seen to run on the vessel wall and attach to the capillary elements of the adventitia.

INNERVATION OF RENAL VESSELS

Both renal arteries and veins are richly supplied with nerves. The innervation of the vessel walls corresponds to the usual picture of vascular innervation. A notable difference is constituted only by the fact that in the renal vessels, namely in the arteries, the nerve supply of the vessel wall is richer than elsewhere in the organism. This abundance is particularly conspicuous in frogs and lizards, where in the arterial walls as well as outside them, nerve fibres are present in such large numbers as comparable only to the aortic arch of certain mammals (cat, dog, fox). As a matter of fact, the nerve supply is richest within or along the walls of the vessel trunks, as clearly seen when surveying the renal vessels from the pelvis up to the vasa afferentia. A description of the innervation of renal arteries, veins and capillary vessels in all vertebrates higher than fishes is presented below.

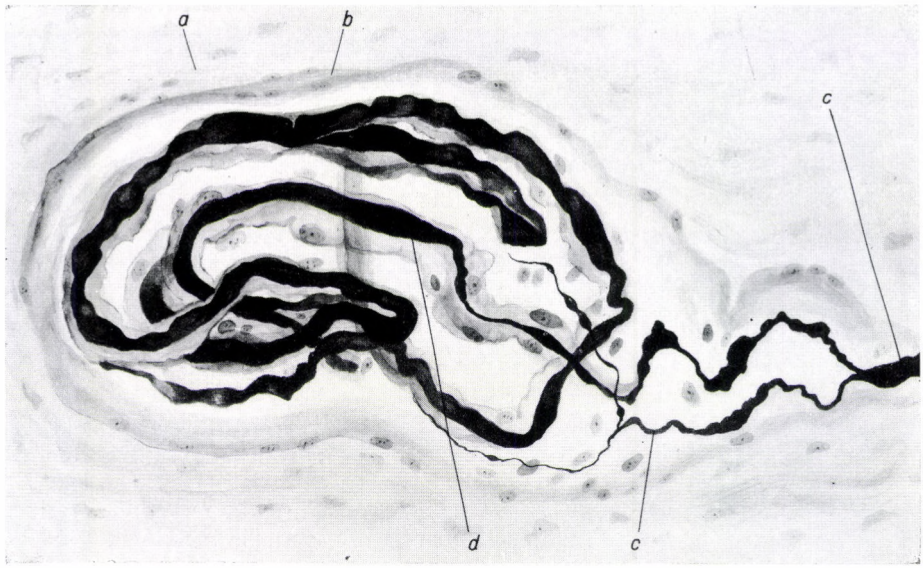

FIG. 216. *Homo.* Arteria renalis; nerve end organ in the adventitia. (a) Connective tissue; (b) connective tissue capsule; (c) nerve fibre; (d) nerve fibre coil. Bielschowsky–Gros' method. Microscopic magnification 600×, reduced photographically to ½

Renal Arteries

The general nerve picture seen in the wall of the arteria renalis and in its macroscopically visible branches corresponds essentially to that found in the walls of vessels in other localizations. Here, too, three networks (plexuses) may be distinguished, located without sharp demarcation in the outer and inner adventitia near the media and in the media itself.

The outer plexus is as a rule not dense, being rather loose in structure in the majority of the cases. It is constituted by two kinds of fibres, some of them being thick, the majority thin and vegetative in appearance. The thick fibres often branch in a dichotomic manner and the delicate thin fibres thus arisen disappear between the connective tissue fibres. The endings, although invisible, are obviously of sensory function and as such may well be considered the general receptors of the vessel wall. Beside them there are also special free or encased loose coils which arise from the terminal branching of thick varicose fibres; no similar structures have been detected in the wall of any other artery. I described such formations (1943) from the wall of the human renal artery, and designated them pressoreceptors as judged by their structure (Fig. 216).

Similar nerve end-formations were reported by Jansky in the renal artery of the albino rat. They are specialized nerve end organs whose like are also found elsewhere in the blood vessel system, but they have been infrequently encountered in

the renal artery. As judged by their structures, they should be some kind of pressoreceptors which, as the receptors of vascular reflex paths, should play a role in the generation of special vascular reflexes and particularly in the control of blood pressure.

The inner adventitial plexus is constituted mainly by thin and smooth fibres of sympathetic character, part of them passing in the walls of the vasa vasorum, part grouping at the border of the media to form the inner adventitial plexus. From the latter exit the fibres forming the medial plexuses.

The medial plexus is a loose network constituted by thin varicose fibres which often cross each other and conjugate with the smooth muscle cells (Fig. 217). In every case, the individual fibres remain independent throughout. In fact, neither the preterminal nor the terminal thin fibres do anastomose, and only infrequently is there evidence of the forms of their connections. This is explicable partly by the fact that for known reasons the examinations are not performed on serial sections and partly by the uncertainty involved in the identification of the often encountered end spheres or bulbs, as one never knows whether they are true endings or varices or knots of some other nature which may have lost connection with the central part of the nerve fibre in consequence of cutting. It may be stated, nevertheless, that the end connection between the nervous system and smooth muscle cells is provided by an extremely delicate and loose plexus system whose end fibres attach epilemmally to the smooth muscle cells, but the possibility of a hypolemmal junction cannot be excluded either.

The innervation of the larger arteries (interlobar and arciform arteries) arising by the branching of the renal artery corresponds to that of the renal artery, except that the latter contains a larger number of nerve fibres in their walls being supplied with fibres also from the plexuses running along them. The number of fibres is lower in the interlobular artery, namely in the portions near the surface of the renal cortex. In the wall of the blood vessels the nerve fibres form plexuses characteristic of the artery wall described above. These plexuses differ in size and form in the different sections of blood vessels. In this context we should like to point out that in the course of the blood vessel's branching, also the nerve fibres supplying the main vessel give off branches to provide for the nerve supply of the newly formed vessel rami. The smaller or larger bundles sent by the main fibre mix with the individual plexus forms and pass on in the wall of the blood vessel. Occasionally nerve fibres entering the adventitia diverge from each other, then meet again and leave the blood vessel after having covered a certain distance. In the adventitia no special branchings and sensory endings are apparent although it may be reasonably assumed that the fibres constituting the outer adventitial plexus are mainly sensory in nature, serving for the perception of vessel wall motions and blood pressure. In the wall of the intrarenal arteries no specialized nerve endings are present.

The innervation of the media is also relatively rich, the loose plexuses yield well to impregnation but with the end connections the same difficulties have been encountered as in the renal artery. However excellent the section and successful the impregnation was, one can never be sure whether the peculiar formations appar-

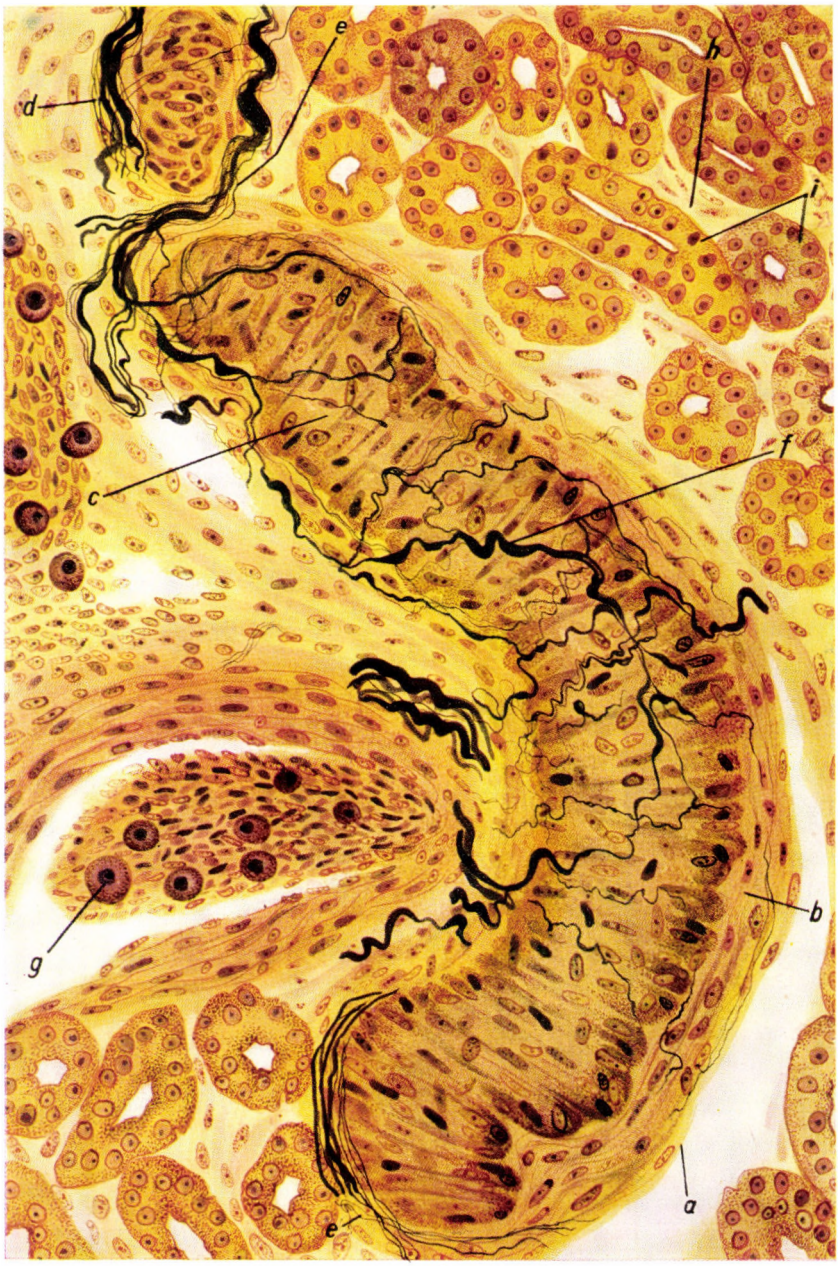

FIG. 217. *Varanus griseus*. Cross section of kidney, blood vessel innervation. (a) Artery; (b) adventitia; (c) media; (d) nerve bundle; (e) thin fibre; (f) thick fibre; (g) wandering cells; (h) connective tissue; (i) renal tubule. Bielschowsky–Ábrahám's method. Microscopic magnification 300×, reduced photographically to ½

ent in the finished preparation are actually endings or cut pieces of nerve fibres. This offers an explanation for the inconsistent theories advanced in the literature in this respect. Smirnow, who reported that nerve fibres "freie motorische Endigungen auf den glatten Muskelzellen der Media bilden"*, found also sensory nerve end structures "in den Bindegewebsbündeln der Adventitia und der Media"**, which appear "in Form von Quästchen und Büscheln aus varikösen Nervenfaden"***. Smirnow described the latter from the adventitia and media of the renal artery and vein, and also from the branches of the renal artery supplying the region of the renal sinus. In addition, he saw nerve end organs of sensory nature in the adventitia of the arcus arteriosus (arteria arciformis) and arteria interlobularis, close to the site where the latter is leaving the arteria arciformis. He claimed to have found them also in the adventitia of the larger arteries passing in the renal capsule. The data presented by Smirnow on sensory endings could not be confirmed by later investigators (Knoche, Mitchell, de Muylder, Dolezel, Ábrahám).

Inconsistent opinions have been formed concerning the endings of nerve fibres supplying the media. Knoche denied the presence of nerve endings in the smooth muscle tissue and claimed the presence of a terminal reticulum here also. According to de Muylder, "fan-like, knob-like, club- or ring-like terminal enlargements" are apparent on the muscle cells. Dolezel has treated the problem very cautiously, but his description, and particularly its illustrations, seem to support the existence of free endings. My opinion is that as the end fibres do not anastomose, no terminal reticulum is present here either. Although it is rather difficult to make visible the endings and to interpret adequately the nerve pictures, I assert that the only possible form of end connection is either that the delicate end fibres terminate in end bulbs or knobs, or they disappear in the muscle cells without showing any terminal structure. It ought to be emphasized in this context that in the media of the renal arteries nerve fibre formations definitely looking like terminals, have been encountered in fairly large numbers (Plate II/d, p. 63).

Nerve fibres are present in a remarkably lower number around, and also in, the interlobular arteries. This applies still more to the vasa afferentia which, nevertheless, are also accompanied by nerve fibres. Further fibres located in the vessel wall itself are present, too. The fibres' number is, however, low in both areas, being sometimes only a single one present in either of them, as observed by several investigators. Naturally this is not actually true, as conditions in the arterial wall are the same as described above. All that may be reasonably supposed is that these arteries, being either terminal or preterminal ones, are poorer in nerves than the others. Concerning the vasa afferentia it should also be noted that only shorter portions of their nerve fibres yield to impregnation and even these only seldom. Certain nerve pictures indicate that the thick fibres also accompany the vasa afferentia, in a narrowed calibre, though. Circumstances are about the same with the vasa efferentia, whose nerve fibres appear singly and still less often. Infrequent-

* "form free motor endings on the smooth muscle cells of the media"
** "in the connective tissue bundles of the adventitia and media"
*** "as rami and bushes constituted by varicose nerve fibres"

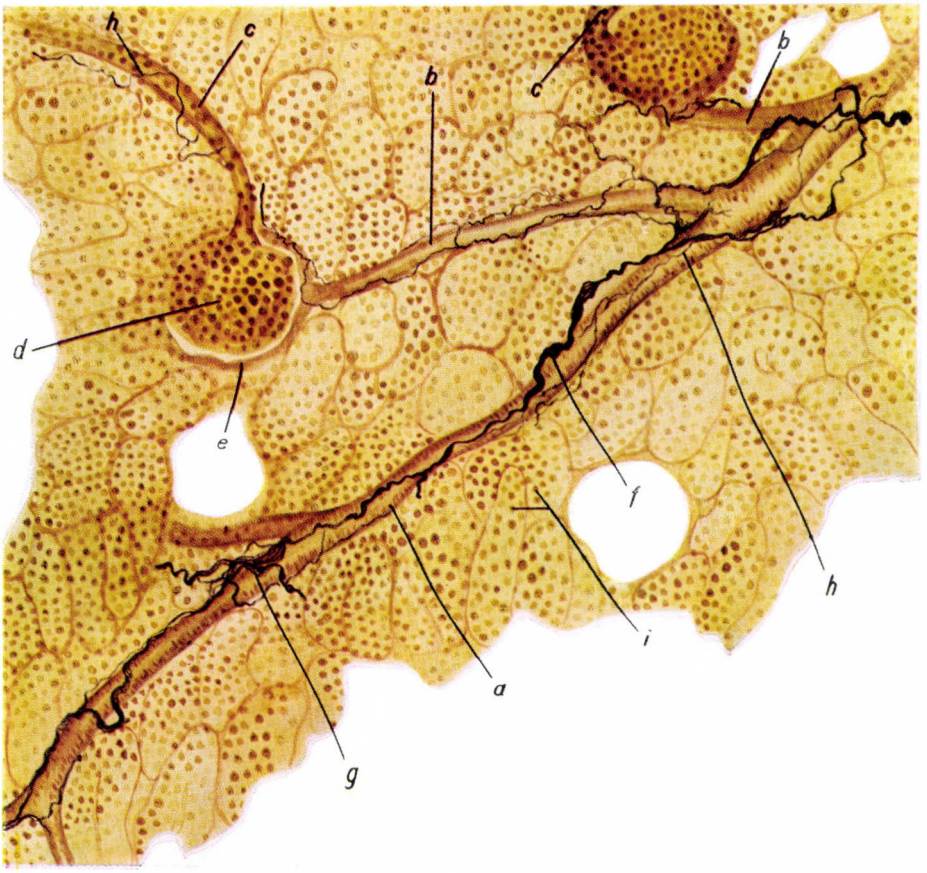

FIG. 218. *Epimys rattus norvegicus*. Kidney, cortical substance. (a) Arteria interlobularis; (b) vas afferens; (c) vas efferens; (d) glomerulus; (e) Bowman's capsule; (f) thick nerve fibre; (g) nerve plexus; (h) thin nerve fibre. Bielschowsky's method. Microscopic magnification 160×, reduced photographically to ½

ly some nerve fibres were seen to start from the end of the vas afferens, pass along the Bowman's capsule and continue on the vas efferens (Fig. 218).

In the discussion of the arterial layers we should also like to include the intima, usually omitted from the descriptions of the vessel's nerve connections. Presently we treat it because Smirnov described from the renal artery of the cat, dog and squirrel (*Eutamias asiaticus*) a nerve plexus in the intima which "unter dem Endothel selbst liegt".* According to Smirnow, from that plexus exit fibres, some of which "in Form kleinerer Knöpfe dem Anscheine nach auf dem Niveau der Endothelzellen endigten"**. Other neurohistologists deny the presence of nerve

* "is located beneath the endothelium itself".
** "ended in the form of small knobs apparently on a level with the endothelial cells".

fibres in the intima. One of them, Mitchell (1951), commented as follows: "Definite nerve filaments or endings were not found in the intima of the renal vessel." For my part, I have found the intima nerve-free, here as well as in other cases. The same was asserted by de Muylder, stating that "Not a single fibre was ever seen coming in close contact with the intima".

The Juxtaglomerular Apparatus

As a result of certain histological studies during the recent decades, cell groups have been discovered in the neighbourhood of Malpighian bodies. It seemed that these cells may presumably play an important role in the control of blood flow through the renal glomeruli. In the literature they were named as "Polkissen" (Zimmermann, 1939), Macula densa, paravascular (paraportal) cells (Becher, 1936) and footlet-plasmodium or Goormaghtighian cell groups (Goormaghtigh, 1932). The description of the structure and position of these formations is beyond the scope of this book, yet I have to treat them shortly as certain workers expressed the opinion that these cell groups—singly or in association—had regulatory influence on the blood flow through the polar vessels and glomeruli. This would be preconditioned by assuming that their regulatory action is under nervous control which would infer their connection with the nervous system. According to Knoche (1950, 1951) and Gömöri and Oltványi (1951), such nerve connections do actually exist. Knoche described on the "Polkissen", paravascular cell groups, Macula densa and Goormaghtighian footlet-plasmodium fine unmedullated nerve fibres whose delicate rami conjugated with the cell groups in question by a "terminal reticulum" as put in Knoche's terminology. Gömöri and Oltványi stated that from the nerve plexus passing along the vas efferens, fibres are going to the Goormaghtighian epitheloid cell groups, ending apparently on these cells or forming at least windings on their surfaces. In my opinion these statements are essentially right inasmuch as from the fibres passing along, or inside the wall of, the vas efferens, fine rami are actually going to the epitheloid cells forming the "Polkissen" in the afferent polar portion of the artery. Naturally, the same may be true also for the paravascular cell groups which were claimed by Becher (1936) to have no nerve connections. The passage of terminal rami from thicker or thinner nerve fibres to the cell groups located in the angle between vas afferens and efferens, considered by Goormaghtigh to be related with the Meissner body in their totality, seems to be quite feasible also to me. Nevertheless, the presence of an extensive terminal network seen by Knoche in the region of the Goormaghtighian cell group and called by him "afferent terminal reticulum" seems to be unacceptable. In my opinion the very fibres constituting the "afferent terminal reticulum" of Knoche are not nerve fibres at all. I venture to assert this because I saw such fibres also in the kidneys of the dog and later on I became convinced that they are argentophilic fibres appearing in large masses among the cells with relatively large nuclei. Thus, although we do not doubt that there is not, nor can be, any kind of connection between the juxtaglomerular cells and finer or less fine, unmedullated

sensory or not sensory nerve fibres, we feel bound to assert that even by very thorough survey of our preparations we failed to detect in the cell groups in question nerve connections that singly or together could have been defined as receptive, reflexogenic organs. Anyway, in this context we should like to note that in the lack of proper knowledge of sensory innervation we consider also the receptive role of epitheloid cells in the "Polkissen" unfounded. If there is in the polar artery entering the glomerulus any regulatory apparatus including the rate of blood flow through changes of the lumen, then in our opinion it should be located in the wall of the artery rather than scattered around the glomeruli. As a matter of fact, that kind of regulatory apparatus may be present despite its not being demonstrable structurally. The vas afferens, too, has a media and an adventitia, both of which are necessarily under nervous control. Since this influence cannot be other than sensory in the adventitia, whilst sensory or motor alike in the media, it is quite natural that the lumen constricting reflex action involves also the preglomerular portion of the arterial system, presumably even earlier than elsewhere in the intrarenal arteries. The circumstance that specific nerve endings are absent does not exclude the presence of sensory fibres in this region, especially as numerous investigators have stated that myelinated fibres accompany the vessels up to the vas afferens. Hence like everywhere in the blood vessels, the regulation may originate also here from the vessel wall.

Renal Veins

The innervation of renal veins corresponds to that of the arteries except that the former contain much less nerve fibres owing to the thinness and poor muscle supply of their walls. Using vital staining with methylene blue, Smirnow described from the adventitia of renal veins in fishes and amphibia bush-like sensory nerve end systems in fairly large numbers. Smirnow reported "büschelförmige sensible Nervenendigungen"* also in the interlobular vein of dogs and cats. According to Knoche, in the adventitia of veins there is "ein dichtes mit Schwannschen Zellen ausgestattetes Geflecht markloser Nervenfaser,"** whose fibres "von der die Muskelzellen einer Vene versorgenden Faser nicht zu trennen sind".*** Knoche asserted the presence between the muscle cells of a terminal nerve net (reticulum), bearing a resemblance to reticula found on the wall of the urinary tubules. De Muylder (1952) described "subendothelial" nerve endings in the renal veins of mice and human fetuses. He distinguished three types among these endings which he failed to detect in adult animals. He considered them sensory nerve end apparatuses which, being the sensory end organs of certain vascular reflexes, control the rate of blood flow in given areas. For my part, I consistently failed to detect sensory nerve endings in the renal veins of adult vertebrates. The illustrations published by de Muylder in his book *The Neurility of the Kidney* (Fig. 21) are in my opinion not nerve pictures.

* "bush-shaped sensory nerve endings".

** "a dense plexus of unmedullated nerve fibres containing Schwann's nuclei".

*** "cannot be separated from those of a main fibre supplying a vein".

Renal Capillaries

The nerve connections of the capillary vessels present a not less intricate problem in the kidney than elsewhere. According to Smirnow, "Die Blutkapillaren sowohl der Rinder substanz und der Nierenkapsel wie auch namentlich die Capillaren der Marksubstanz werden auf ihrer ganzen Ausdehnung von marklosen Nervenfäserchen umflochten".* Smirnow stated that this was particularly conspicuous in the medullary substance where the capillaries arranged regularly over long tracks along the tubules going to the tops of the papillae. This statement of Smirnow has been essentially right except that no plexuses are present around the capillary vessels. As a rule, along the capillaries pass single fibres being unmedullated, descending in an undulating manner and touching the capillaries here and there. Around the capillaries, Mitchell found no "fine nerve plexuses, corresponding to those described by some writers". Knoche established that the interconnection between the capillaries' walls and nervous systems is brought about by a "nervöses Terminalreticulum".**

INNERVATION OF CEREBRAL VESSELS

The investigation of the nerve connections of the cerebral vessels was started by the morphologists relatively late, although several physiologists had proved the intracerebral blood pressure to be affected by the sympathetic nervous system. Brachet (1830) was the first to observe cerebral hyperaemia after cutting the jugular sympathetic nerve. Evidence that unilateral section of the sympathetic nerve results in temperature elevation in the respective cerebral hemisphere, was presented by Claude Bernard (1859). Jensen (1904) proved that the jugular sympathicus is the vasoconstrictor nerve of the corresponding hemisphere. Based on various experimental observations, Weber (1908), Kurusu (1928) and later on several other workers (Farbes, Wolf and Gobb) established that from the jugular sympathicus vasomotor fibres go to the brain. On the other hand, certain investigators (Knoll, Roy, Sherrington, Bayliss and Hill) have denied the presence of a vasomotor mechanism in cerebral vessels.

In the study of cerebral vascular innervation, morphologists had for a long time lagged far behind the physiologists. Koelliker (1863) was the first who saw a small nerve fibre in the pia mater. Next Morrison presented a short report on the presence of nerve fibres in the cerebral arteries' walls. The feasibility of Morrison's findings was confirmed by contemporary examinations by Gulland, Obersteiner and Huber.

The studies by Rohnstein (1900) had temporarily retarded the research of this complex problem. Based on the examination of various animals by different methods

* "The capillary vessels of the renal cortex and capsule alike and particularly the capillaries of the medullary substance, are intertwined with unmedullated nerve fibres over their entire descents".

** "nervous terminal reticulum".

he concluded that "Die in der Pia oder zwischen Pia und Hirnsubstanz liegenden Gefässe, selbst die grösseren unter ihnen, sind alle frei von Nerven".* Later on he even offered the general statement that "Verf. aber konnte nicht das Vorkommen eigener Nerven an den Blutgefässen der grossen Nervencentren constatieren".**

The statements by Rohnstein had soon proved incorrect. This was natural as they were lacking all kinds of physiological, morphological and theoretical support. It required a special school of thought to assume that, in the end branches of the internal carotid artery and vertebral artery, nerve connections cease immediately after their entrance in the cerebral region. Thus it was natural that several contemporaries of Rohnstein started to examine the meninges and the cerebral substance itself for the nerve connections of their vessel supply. One of these contemporaries was Hunter (1900), who succeeded in demonstrating the presence of nerve fibres along the cerebral vessels of the grey matter by vital methylene blue staining. He also found nerve plexuses in the vessels traversing the pia mater, but failed to demonstrate their presence in those supplying the cerebral white matter. According to Hunter, vessels lose their nerve supply at their entrance in the white matter. Otherwise he was right in stating that in the wall of the cerebral vessels the nerve fibres form plexuses, exhibit neurofibrillar structure and divide into delicate rami. Hunter failed to clarify whether the nerve fibres passing along the cerebral vessels were medullated or unmedullated. Lapinsky (1915) was confronted with much the same problem. By the methylene blue staining technique, he demonstrated the presence of nerve fibres in the meninges, chorioid plexus, in the vessels supplying the cerebral cortex and the substance (matter) of the centrum Vieusseni, but failed to identify their origin. Studying the nerve supply of the pia mater, Stöhr (1928) noted that the vessels supplying the pia mater are abundantly provided both with motoric and sensory nerve endings, but he, too, found the cerebral vessels nerve-free. The findings of Berger (1928) correspond to those of Stöhr. Hassin (1929) agreed with the statements of Stöhr and Berger, adding that no nerve fibres are present on the pia mater's capillary vessels either. Based on examinations of the medulla oblongata and spinal cord, Clark (1929) described nerve fibres from the wall of the blood vessels noting that these were obviously continuities of the nerve fibres passing in the walls of vessels supplying the pia mater. In his opinion, these fibres were postganglionic axons originating in the cells of the jugular sympathetic ganglia.

Examining cats, guinea-pigs and albino mice, Grigorjeva (1932) found that on the cerebral vessels, including capillaries, thin unmedullated nerve fibres are passing: "Die Fasern begleiten das Gefäss auf einer langen Strecke, verlassen nirgends seine Wand und bilden feine Geflechte".*** On the capillaries she often detected bulb-like nerve endings. She noted that nerve fibres passing on, and

*"vessels localized in the pia or between the pia and cerebral substance, even the largest ones, are all free of nerves".

**"The author, however, failed to detect the presence of specific nerves on the blood vessels supplying the large nerve centres".

***"The fibres accompany the vessel over a long track, do not diverge from its wall anywhere and form delicate plexuses".

inside, the vessel walls "gehören ihrer morphologischen Struktur nach zu den sympathischen Nerven. Sie sind die Fortsetzung der Nerven aus den Gefässgeflechten der Hirnbasis und der weichen Hirnhäute."*

Studying the diencephalon, Hagen (1955) found that in the adventitia of cerebral arteries passed nerve bundles constituted by delicate unmedullated fibres. In the muscle layer of the arteries he saw numerous nerve fibres of the calibre of a neurofibril which, in his opinion, ended in a terminal reticulum. Beside them he saw, also in the arterial wall, nerve elements penetrating the endothelium.

Hagen laid particular stress on the above statements by noting that: "Immerhin weisen die vorliegenden morphologischen Resultate darauf hin, dass neben der efferenten und afferenten Regulation der Gefässe innerhalb der Gehirnsubstanz auch eine direkte nervöse Faserbindung zwischen der Wand jener Gefässe und der jeweiligen Gehirnregion besteht."** The above survey shows that the innervation of blood vessels supplying the central nervous system corresponds both in respect of location and origin to that of blood vessels supplying the other regions of the body. It is also obvious that in spite of the seeming uniformity, the nerve connections of the cerebral vessels exhibit certain particularities and minor differences, deriving from their location, environment and particularly their function.

Studying the meninges and brain of the chicken, turkey, rat, cat and man, we, too, have detected differences, particularities and previously unknown forms of interconnections, particularly of the afferent fibres. They are described below with references to the available literary data. The nerve connections of meningeal and cerebral vessels are not discussed separately, but together from a uniform point of view. Below we describe the arteries, veins and finally the capillaries.

Cerebral Arteries

The histological structure of cerebral arteries corresponds to that of arteries supplying the other parts of the body, except that the former's walls are in general thinner, owing mainly to the thinness of the adventitia and intima. In comparison with the other two layers, the media is thick. As to the innervation in general, it should be noted that cerebral vessels, namely those passing on the brain's surfaces, are markedly rich in nerve fibres. An extraordinary abundance of nerves was detected in vessels arising directly in the internal carotid artery as they carry the bulk of nerve fibres sent by the jugular sympathetic nerve. Smaller arteries formed by repeated branchings have a poorer nerve supply, yet are richer in nerves than arteries of similar calibre in other parts of the body. Nerve connections are discussed in the sequence of the vessel wall's histological layers. First we describe the nerve supply of the adventitia and secondly that of the media.

* ". . . belong morphologically to the sympathetic nerves. They are the continuities of nerves from the vascular plexuses of the brain base and soft meninges."

** "Anyway, the available morphological results indicate that beside the efferent and afferent control of vessels in the brain matter there is also a direct nerve fibre junction between the wall of those vessels and the respective brain region."

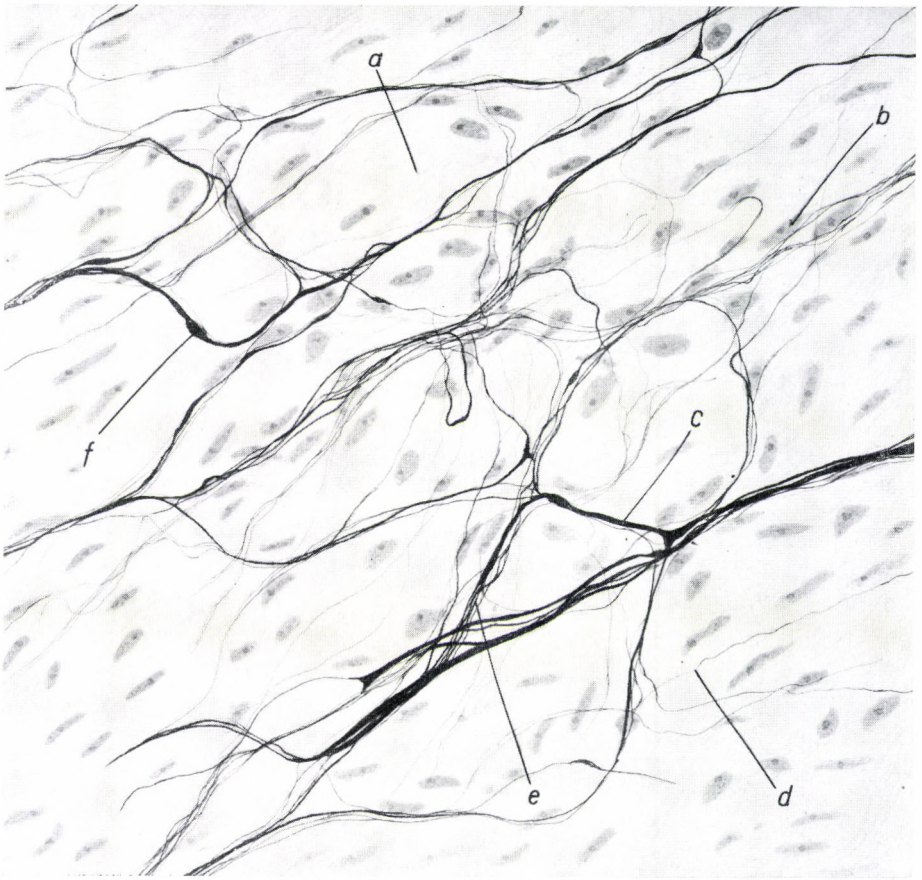

FIG. 219. *Meleagris gallopavo.* Arteria carotis cerebralis; nerve plexus in the adventitia. (a) Connective tissue fibre; (b) nucleus of connective tissue cell; (c) thick nerve fibre; (d) thin nerve fibre; (e) nerve fibre plexus; (f) varix. Bielschowsky–Ábrahám's method. Microscopic magnification 600×, reduced photographically to ½

The adventitia of the larger vessels (arteria basilaris, arteria cerebri media, arteria cerebri anterior, arteria cerebri posterior) is extraordinarily rich in nerve fibres. In man and animals alike, adequately impregnated preparations reveal such a large mass of nerve fibres that the basal tissue is hardly visible. This applies particularly to birds, namely to the bigger ones (chicken, turkey, goose, duck), where a hardly surveyable plexus system is passing in the outer adventitia (Fig. 219). The majority of the fibres are thin, smooth and unmedullated but beside them there are also some thick fibres, readily distinguishable from the sympathetic ones by their alternating diameter, frequent varices and frequent branchings. Although we have not yet detected their endings, their whole appearance, namely

the dendritic branchings, suggest that they are the sensory organs of the blood vessel reflex paths.

In birds, the arteria carotis cerebralis, corresponding to the arteria basalis, is of particular interest because ganglia are repeatedly found in its wall. These ganglia are readily impregnated, their cells are large and most of them multipolar. The particularity of the ganglia, or the whole system, is that immediately along the artery passes a well-developed nerve trunk, giving off to each individual ganglion a relatively thick branch whose fibres end as preganglionic fibres around the ganglial cells. Close to the entering nerve bundle a separate bundle exits from the ganglion, which then associates with the nerve trunk. We attach great importance to the ganglial system of innervation of cerebral vessels, viz. the presence of ganglia ensures the adequate sympathetic nerve supply to the trunk, gradually losing its fibres by giving off branches to the vessels (Fig. 122).

The outer adventitial plexus is still very rich in mammals, although it is somewhat poorer than in birds. Essentially it consists also in mammals of longitudinally descending nerve fibre trunks and bundles, which pass in parallel fashion with the vessels' longitudinal axis in such a way that the individual bundles are repeatedly linked by smaller branches. Most of the fibres passing in the trunks are smooth sympathetic fibres, but here appear also some thick fibres which, judging from their structure, belong to the cerebrospinal system.

The outer adventitial plexus of the vessels supplying the brain base is richest in man. The brain's bulk, its special function and the consequent thickness of the vessels explain the extraordinary abundance of nerve fibres which is particularly conspicuous in the region where the nerve trunk sent from the cervical sympathetic enters the vessel wall after having passed alongside it. The majority of the fibres are smooth and of sympathetic appearance but among them there are also some thick fibres which form sensory end systems in the wall of small arteries, arisen by branching. The outer adventitial plexus is easily visible both in the vessel running in the brain and the meninges.

The innervation of arteries passing in the cerebral tissue was studied on specimens taken from different parts of the brain (cerebrum, cerebellum) and impregnated *in toto* together with their end rami. Since the latter were too small for cutting, they were fixed *in toto*. Some of these preparations were successful, showing a continuation of the plexus revealed in the main artery, being relatively rich, namely in the vessels supplying the grey matter. Also, it was found that in some places the nerve fibres form coherent plexuses in which the Schwann nuclei and overstriding fibres—nearly as thin as neurofibrils—were clearly apparent (Fig. 220).

The nerve fibres could be readily followed also in smaller arteries, up to the macroscopically visible ramifications. In the precapillaries, the number of nerve fibres was much less and all of them belonged to the sympathetic system. Thick fibres and sensory nerve fibre formations were not seen on the precapillary arteries.

The interlamellar plexus lies directly on the media. In birds also this system is very rich. Dichotomically branching thick fibres are seen also here, but the majority of the fibres are thin sympathetic ones. From the plexus which lies, as

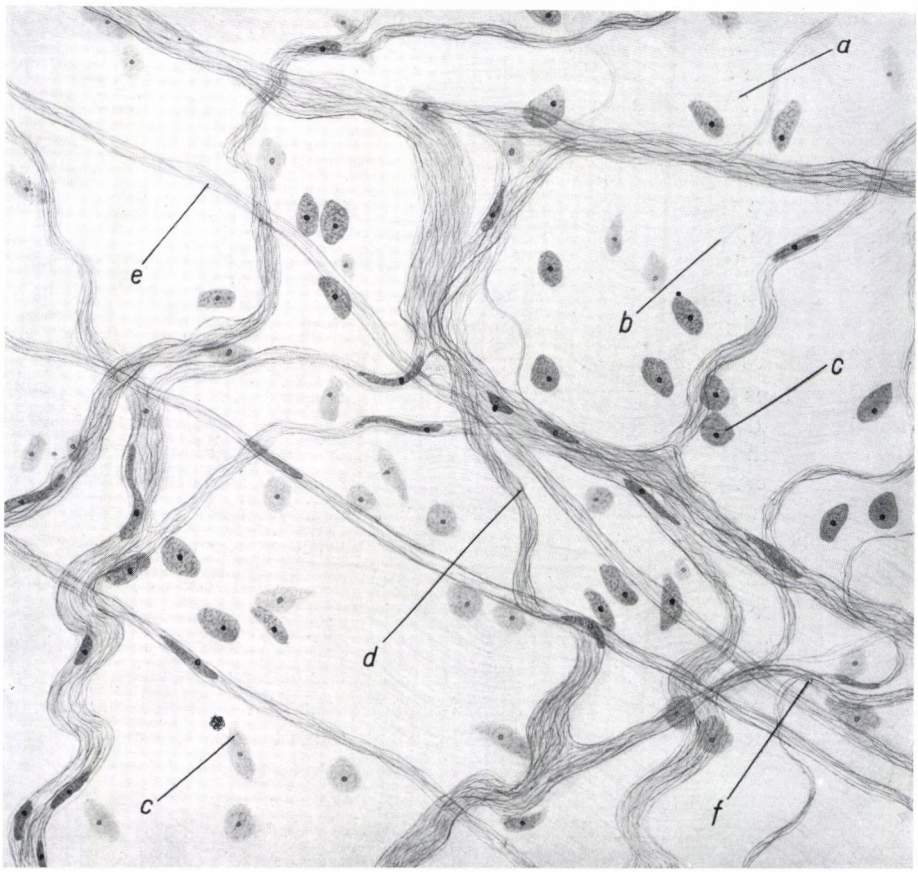

FIG. 220. *Homo*. Small artery in the Fossa Sylvii; innervation. (a) Adventitia; (b) connective tissue fibre; (c) nucleus of connective tissue cell; (d) nerve fibre bundle; (e) nerve fibre; (f) nerve fibre plexus. Bielschowsky–Gros' method. Microscopic magnification 600×, reduced photographically to ½

mentioned above, directly on the media, thin fibres go into the media where they form a very delicate plexus. The fibres constituting the plexus run parallel to the smooth muscle cells' longitudinal axis, to be attached closely to their surfaces, then become gradually narrower and disappear without forming any typical end structure. There is no terminal reticulum present.

In the plexus lying on the tunica media, some conspicuously thick repeatedly branching fibres have been detected, especially in birds. The branches continue in markedly divergent rami which may be followed over a long distance then end on the smooth muscle cells by forming very small end knots (Fig. 221).

The nerve plexuses innervating the walls of the cerebral vessels are constituted mainly by unmedullated fibres. No myelin sheaths either were seen on the thick

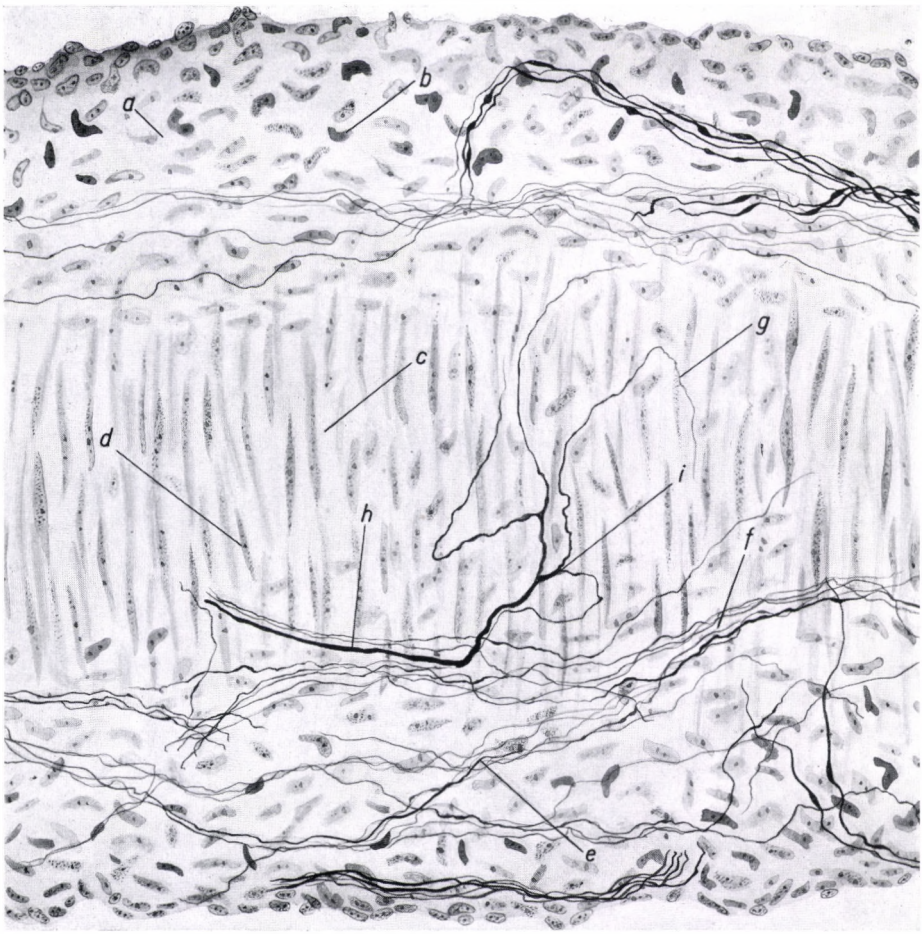

FIG. 221. *Gallus domesticus.* Nerve plexus in the wall of the arteria carotis cerebralis. (a) Tunica adventitia; (b) nucleus of connective tissue cell; (c) tunica media; (d) nucleus of smooth muscle cell; (e) nerve plexus in the adventitia; (f) nerve plexus in the media; (g) thin nerve fibre; (h) thick nerve fibre; (i) dendritic branching. Bielschowsky–Ábrahám's method. Microscopic magni- fication 400×, reduced photographically to ½

fibres mentioned above, yet we are bound to assert the presence of myelinated fibres in the cerebral arteries, too, including not only those passing in the brain base and meninges but also those in the cerebral tissue. We saw the myelin sheaths very clearly on the axons of nerve fibres passing on small arteries drawn out from the cerebral cortex.

Considering the functional classification of the nerve fibres described above, we may state that the thin sympathetic fibres are efferent, viz. vasomotor fibres, whereas the thick ones are the sensory elements of the vessel wall. As shown in

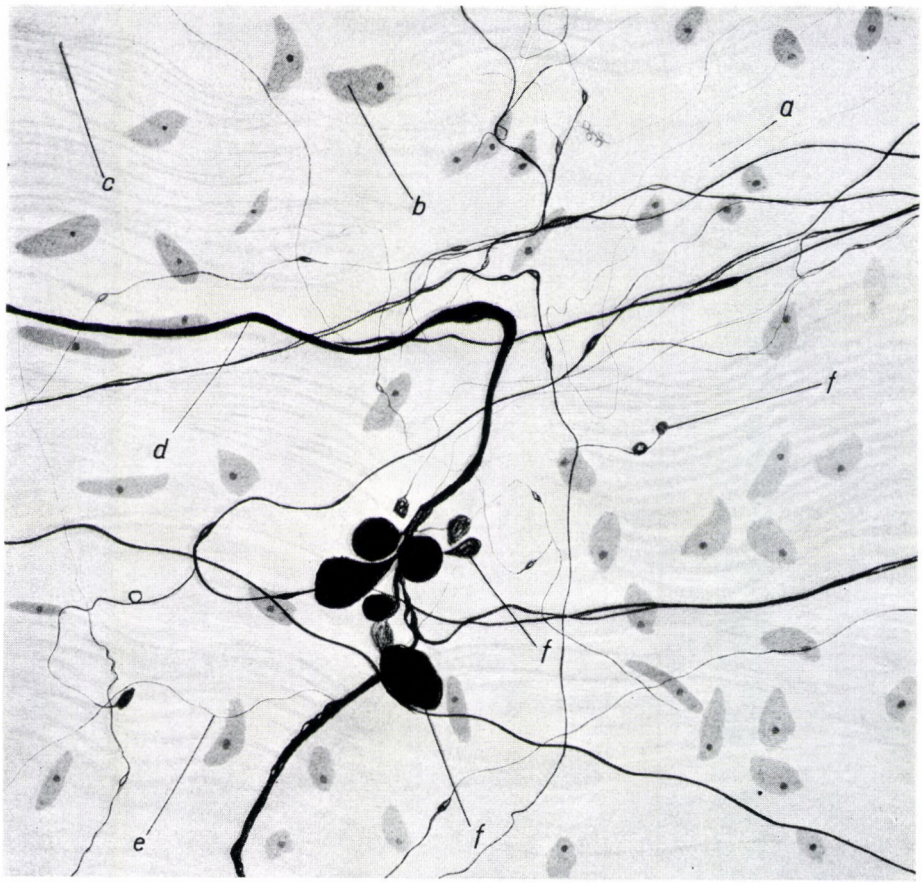

FIG. 222. *Homo*. Small vein in the cerebral cortex; nerve fibre plexus in the vessel wall. (a) Connective tissue; (b) nucleus of connective tissue cell; (c) connective tissue bundle; (d) thick nerve fibre; (e) thin nerve fibre; (f) nerve ending. Bielschowsky–Gros' method. Microscopic magnification 800×, reduced photographically to ½

the illustrations, the latter arborize, being attached to the vessel wall, namely the tunica media, at several sites. Beside them we saw also loose coil-like nerve end formations and considered them to be special sensory end apparatuses of the vessel wall. We failed to detect any nerve elements in the intima.

Cerebral Veins

The wall of the cerebral veins is thin. In preparations impregnated *in toto*, the nuclei of endothelial cells are also easily seen on the walls of postcapillary veins. The veins are rich in nerve fibres which, however, do not form larger trunks,

passing as a rule in small branches constituted by two to three fibres. There are also numerous single fibres passing over long distances and exhibiting in their pathway distant roundish varices. Cerebral veins, namely the smaller ones and in particular the postcapillary veins, are characterized by rich afferent innervation. Veins containing very variable afferent nerve end formations are seen, particularly in the chorioid plexus. We examined these formations on smaller veins removed from human chorioid plexus. The specimens were impregnated *in toto*, cut in sections, straightened and fixed. Some of the preparations thus obtained showed large numbers of sensory fibres and sensory nerve endings.

In the wall of a small vein obtained from the chorioid plexus, we detected a variety of sensory endings. Of these the knot-like endings, large loose coils and small coils appeared to be quite typical. The knot-like formations were of variable dimensions. In general they were dense, arranged close to each other and formed together a nest-like structure. Their appearance was unusual. I have never encountered similar structures during my whole neurohistological work. They may have been pathologically enlarged nerve end bulbs (Fig. 222). Beside them, end knots of smaller or larger sizes have been frequently present, showing a roundish, elongate or tapering shape. The latter bore a resemblance to the generally known knot-like nerve fibre endings. Infrequently also thin fibres running over a long distance were seen to end in smaller coils. In addition, loose coil-like structures, arisen by the intertwining of fibre systems constituted by the terminal ramification of a single fibre, have been encountered fairly often.

Cerebral Capillaries

On the basis of studies by Grigorjeva, Hadjioloff, Dokov, Tchakharoff and others, the cerebral capillaries are fairly well known both in general and in detail. It was demonstrated that cerebral capillaries running in the meninges as well as those supplying blood to the central nervous system's grey and white matters are innervated by sympathetic fibres. Some of these fibres accompany the vessels, some of them pass on the vessel walls and occasionally end in terminal bulbs. The same was found by us except that in our silver-impregnated preparations no endings were seen on the capillaries.

REFERENCES

The Heart

ÁBRAHÁM, A. (1937) A gerincesek intracardialis idegrendszere (The intracardiac nervous system of vertebrates). *Magy. Tud. Akad. Math. Term. Tud. Ért.* **56,** 320.

ÁBRAHÁM, A. (1938) Über die mikroskopische Innervation der Herzmuskulatur der Wirbeltiere. *Arb. Ung. Biol. Forsch.-Inst.* **10,** 468.

ÁBRAHÁM, A. (1940) Die Sinusgegend des menschlichen Herzens und ihr Nervensystem. *Z. Zellforsch.* **31,** 146.

ÁBRAHÁM, A. (1956) Über die Probleme in der Histologie des vegetativen Nervensystems. *Acta biol. Univ. Szeged* **2,** 111.

ÁBRAHÁM, A. (1957) The structure of cardiac ganglia. *Acta biol. Acad. Sci. hung.* **7** (Suppl. 1), 11.

ÁBRAHÁM, A. (1958) The microscopical innervation of the vertebrate heart. *15th Int. Congress of Zool. London,* 33

ÁBRAHÁM, A. (1959) Zur Frage der interneuronalen Synapsen in den vegetativen Ganglien. *Z. mikr.-anat. Forsch.* **65,** 574.

ÁBRAHÁM, A. (1961) A szív beidegződése (Innervation of the heart). *Magy. Tud. Akad. Biol. Orv. Oszt. Közl.* **12,** 207.

ÁBRAHÁM, A. (1965) The structure of the synapses in the heart of the European pond turtle (Emys orbicularis). *Symp. Biol. Hung.* **5,** 69.

ÁBRAHÁM, A. and ERDÉLYI, L. (1957) Über die Struktur und die Innervation des Reizleitungssystems im Herzen der Säugetiere. *Acta biol. Univ. Szeged* **3,** 275.

ÁBRAHÁM, A. and ERDÉLYI, L. (1959) Localization of acetylcholinesterase in the cardiac conducting system of Ungulata. *Acta morph. Acad. Sci. hung.* **8,** 403.

ÁBRAHÁM, A. and HORVÁTH, I. (1959) Über die mikroskopische Innervation des Herzens von Süßwasser-Knochenfischen. *Z. mikr.-anat. Forsch.* **65,** 1.

ÁBRAHÁM, A. and STAMMER, A. (1957) Die mikroskopische Innervation des Vogelherzens. *Acta biol. Univ. Szeged.* **3,** 247.

ADAMS, V. E. (1937) A contribution to the anatomy of the avian heart as seen in the kiwi (A. australis) and the yellow-crested penguin (M. antipodum) *Proc. Zool. London* **107,** 417.

AIBA, K. (1954) Supplement to the observations on the sensory innervation of human heart. *Arch. histol. jap.* **6,** 213.

AKKERINGA, L. J. (1949) The nervous system of the Purkinje fibres in the heart. *Acta neerl. Morph.* **6,** 289.

ALTMAN, PH. L. 1959. *Handbook of circulation.* Dittmer–Grebe, Philadelphia–London.

ALVARI, A. (1950) On the venous network of the human heart and its arteriovenous anastomoses. *Ann. Med. exp. Fenn.* **28** (Suppl. 1), 88.

ANDERSCH, C. 1792/93. *Fragmentum descriptionis nervorum cardiacorum (glossopharyngeus, vagus, etc.)* T. Soemmerring. In „Scriptores Neurologici Minores Selecti sive Opera Minora" C. F. Ludwig, Vol. II. 113.203. Lipsiae apud 10. Frid. Iunium.

ANUFRIEW, W. N. (1928) Die Herznerven der Katze. *Z. Anat. Entwickl.-Gesch.* **86,** 639.

ARGAUD, R. (1911) Sur l'innervation de la zone auriculaire droite qui répond à l'origine de la systole cardiaque. *C. R. Soc. Biol. (Paris)* **70,** 568.

ARGAUD, R. (1911) Sur la présence des ganglions nerveux dans l'épaisseur de la valvule de Thébésius chez Ovis aries. *C. R. Soc. Biol. (Paris)* **70,** 699.

ARGAUD, R. (1911) Sur l'appareil nerveux et la structure de la valvule de Thébésius chez l'homme. *C. R. Soc. Biol. (Paris)* **70,** 748.

ARGAUD, R. (1911) Note sur l'innervation intra-cardiaque. *C. R. Soc. Biol. (Paris)* **71,** 638.

ARGAUD, R. 1912. *Nerfs du coeur.* Traité d'anatomie humaine de Poirier et Charpy. 2. Paris.

ARNOLD, E. (1909) Zur Morphologie des Glykogens des Herzmuskels nebst Bemerkungen über dessen Struktur. *Arch. mikr. Anat.* **73,** 726.

ARNOLD, J. (1865) Über die feineren histologischen Verhältnisse der Ganglienzellen in dem Sympathicus des Frosches. *Virchows Arch. path. Anat.* **32,** 3.

ARNOLD, J. (1874) Ein Beitrag zur feineren Struktur der Ganglienzellen. *Virchows Arch. path. Anat.* **41,** 203.

ARNSTEIN, C. and LAWDOWSKY, N. (1887) Über die Fortsätze der Nervenzellen in den Herzganglien. *Arch. mikr. Anat.* **29,** 609.

ARPINO, G. (1932) Ricerche nuove sul tessuto specifico del cuore. *Anat. Anz.* **74,** 268.

ARPINO, G. (1934) Osservazioni sul nodo seno-atriale e sul nodo di Tawara. *Arch. Zool. ital.* **10,** 385.

ARPINO, G. (1934) Die Innervation des Sinusknotens bei Delphinus delphis. *Anat. Anz.* **77,** 241.

ASCHOFF, L. (1908) Über den Glykogengehalt des Reizleitungssystems des Säugetierherzens. *Verh. dtsch. path. Ges.* 150.

ASCHOFF, L. (1910) Referat über die Herzstörungen in ihren Beziehungen zu den spezifischen Muskelsystemen des Herzens. *Verh. dtsch. path. Ges.* **12,** 3.

ASCHOFF, L. 1911. *Pathologische Anatomie.* G. Fischer, Jena.

ASCHOFF, L. and TAWARA, S. (1906) *Die heutige Lehre von den pathologisch-anatomischen Grundlagen der Herzschwäche,* G. Fischer, Jena.

ATHANASIOU, D. J. and DZIALLAS, P. (1955) Hypolemmale Ringbinden im Reizleitungssystem des Schafherzens. *Z. Zellforsch.* **43,** 214.

AVIADO, D. M. and SCHMITT, C. F. (1959) Cardiovascular and respiratory reflex from the left side of the heart. *Amer. J. Physiol.* **196,** 726.

AZOULAY, L. (1894) Les nerfs du coeur de l'homme. *C. R. Soc. Biol. (Paris),* **1,** 338.

BABASKIN, A. W. 1951. *Histologische Veränderungen des Herzens bei Tieren bei Ausschaltung der sensiblen Leitstränge.* Arb. 5. All.-Kongr. Anat. Hist. Embryol. Med. Staatsverlag Moskau–Leningrad. 449.

BABMINDRA, V. P. (1965) Structure of afferent innervation of sympathetic ganglia. *Arch. Anat. Gistol. Embriol.* **49,** 10, 77.

BACHMANN, G. (1922) The distribution of the vagus nerves to the sinoauricular junction of the mammalian heart. *Amer. J. Physiol.* **50,** 468.

BAINBRIDGE, F. A. (1915) The influence of venous filling upon the rate of the heart. *J. Physiol. (Lond.)* **50,** 65.

BALLIN, L. R. and KATZ, L. N. (1941) Observations on the localization of the receptor area of Bainbridge reflex. *Amer. J. Physiol.* **135,** 202.

BAUD, C. A. and HAENNI, A. (1952) Apparition de l'ultrastructure spécifique dans le myocarde embryonnaire en relation avec les premières contractions. *C. R. Soc. Biol. (Paris).*

BAUD, C. A., CLYMAN, B., DAYER, L., BAUMANN, J. A. and POSTERNAK, J. (1957) Activité cholinestérasique et innervation du coeur de la Tortue. *Helv. Physiol. Acta* **15** (Suppl.), 10.

BEAMS, H. W., EVANS, T. C., JANNEY, C. D. and BARKER, W. W. (1949) Electron microscope studies on the structure of cardiac muscle. *Anat. Rec.* **105,** 59.

BENNINGHOFF, A. (1921) Beiträge zur vergleichenden Anatomie und Entwicklungsgeschichte des Amphibienherzens. *Morph. Jb.* **61,** 355.

BENNINGHOFF, A. 1923. *Über die Beziehungen des Reizleitungssystems und der Papillarmuskeln zu den Konturfasern des Herzschlauches.* Verh. anat. Ges. 32. Verslg. Heidelberg. 185.

BENNINGHOFF, A. 1930. Das Herz. In W. MÖLLENDORFF: *Handbuch der mikroskopischen Anatomie des Menschen.* VI/1. 161. Springer, Berlin.

BENNINGHOFF, A. 1933. Das Herz. In L. BOLK, E. GÖPPERT: *Handbuch der vergleichenden Anatomie der Wirbeltiere.* VI. 467. Urban–Schwarzenberg, Berlin–Wien.

BERGMANN, W. and FREY, M. 1960. *Handbuch der inneren Medizin.* Bd. 1–5. Springer, Berlin.

BERKLEY, H. J. (1894) On complex nerve terminations and ganglion cells in the muscular tissue of the heart ventricles. *Anat. Anz.* **9,** 33.

BETHE, A. (1900) Über die Neurofibrillen in den Ganglienzellen von Wirbeltieren und ihre Beziehung zu den Golginetzen. *Arch. mikr. Anat.* **55,** 513.

BEZOLD, A. 1863. *Untersuchungen über die Innervation des Herzens.* W. Engelmann, Leipzig.

BIBORSKY, J. (1939) Sur la structure histologique de la paroi du sinus veineux et la topographie de ses ganglions chez le Gade. *Bull. Int. Acad. Sc. Cracovie Zool.* **6–7,** 10.

BIDDER, F. (1848) Über die Herznerven des Frosches. *Müllers Arch.* 130.

BIDDER, F. (1852) Über funktionell verschiedene und räumlich getrennte Nervenzentren im Froschherzen. *Müllers Arch.* 163.

BIDDER, F. (1866) Zur Kenntnis des Froschherzens und seiner Nerven. *Du Bois-Reymond's Arch.* 1.

Bielig, W. (1931) Untersuchungen über die Herztätigkeit der Fische. *Z. vergl. Physiol.* **15,** 488.

Blackhall-Morison, A. (1926) Note on the innervation of the human heart. *J. Anat. (Lond.)* **60,** 143.

Blair, D. M. and Davies, F. (1935) Observations on the system of the heart. *J. Anat. (Lond.)* **69,** 303.

Blaschko, H. (1929) Über die Wirkungsweise der Herznerven bei den Fischen. *Z. vergl. Physiol.* **1,** 357.

Bodrova, N. V. (1950) Données sur la morphologie expérimentale de l'appareil nerveux du coeur des Poissons et des Reptiles. *Trudi. Inst. Zool. USSR.* **3,** 128.

Boeke, J. (1913) Die doppelte efferente Innervation der quergestreiften Muskelfasern. *Anat. Anz.* **44,** 343.

Boeke, J. (1925) Die Innervation des Herzbeutels und Hisschen Bündels beim Schildkrötenherz. Verslagen d. Afdeeling Naturkunde *Königl. Acad. Wiss. Amsterdam.* **33,** 933.

Boeke, J. (1926) The innervation of the muscle fibres of the myocardium and of the atrioventricular bundle of His in the heart of the tortoise. *Proc. Acad. Amsterdam.* **28,** 32.

Boeke, J. (1926) Noch einmal das periterminale Netzwerk, die Struktur der motorischen Endplatte und die Bedeutung der Neurofibrillae. *Z. mikr.-anat. Forsch.* **7,** 95.

Boeke, J. (1930) Die angebliche doppelte Innervation der quergestreiften Muskelfasern bei Reptilien besonders bei Python. *Z. mikr.-anat. Forsch.* **21,** 597.

Boeke, J. (1933) Innervationsstudien V. Der sympathische Grundplexus und seine Beziehungen zu den quergestreiften Muskelfasern und zu den Herzmuskelfasern. *Z. mikr.-anat. Forsch.* **34,** 330.

Botár, J. (1947) Les nerfs du coeur du lion. *C. R. Ass. Anat.* **34,** 79.

Botár, J. (1963) Über die Innervation der Herzmuskulatur und ihre Veränderungen. *Z. mikr.-anat. Forsch.* **70,** 168.

Botár, J. and Becker, A. (1939) Die Faserstruktur der Herznerven beim Maki-Affen. *Anat. Anz.* **88,** 494.

Botazzi, F. (1907) Über die Innervation des Herzens von Scyllium canicula und Maja squinado. *Zbl. Physiol.* **14,** 665.

Bourgery, J. M. 1844. *Traité complet de l'anatomie de l'homme.* C. A. Delaunay, Paris.

Braeucker, W. (1927) Der Brustteil des vegetativen Nervensystems und seine klinisch-chirurgische Bedeutung. *Beitr. Klin. Tuberk.* **66.**

Braeucker, W. (1932) Das extracardiale Nervensystem des Kaninchens. *Verh. dtsch. Ges. Kreislaufforsch.* 322.

Breemen, V. L. van (1953) Intercalated discs in heart muscle studied with electron microscope. *Anat. Rec.* **117,** 49.

Brinley, J. F. (1930) The effect of cyanide on the cardiac rhythm of embryos of Fundulus heteroclitus. *Physiol. Zool.* **3,** 283.

Bronk, D. W. and Ferguson, L. K. (1932) Impulses in cardiac sympathetic nerves. *Proc. Soc. exp. Biol. (N. Y.)* **30,** 339.

Bronk, D. M., Margaria, R. and Solandt D. Y. (1936) The activity of the cardiac sympathetic centres. *Amer. J. Physiol.* **117,** 237.

Brugsch, Th. 1958. *Kardiologie. Lehrbuch der Herz- und Gefäßkrankheiten.* Hirzel, Leipzig.

Brünner, H. (1963) Die Übergangsstellen der Purkinjeschen Fasern in die Arbeitsmuskulatur des Herzens. *Acta anat. (Basel)* **52,** 102.

Brünner, H. (1963) Das Zahlenverhältnis der Herzmuskelfasern zu den Purkinjeschen Fasern im Moderatorband und M. papillaris anterior im rechten Ventrikel des Schafherzens. *Acta anat. (Basel)* **52,** 117.

Bullard, H. (1921) On the occurrence and physiological significance of fat in the muscle fibres of the normal myocardium and atrioventricular system: interstitial granules (mitochondria) and phosphorlipides in cardiac muscle. *Amer. J. Anat.* **19,** 1.

Burian, F. (1924) Zur Histologie des Sinusknotens des menschlichen Herzens. *Anat. Anz.* **59,** 306.

Cajal, Ramón Y. S. R. (1890) Sobre las terminaciones nerviosas del corazón de los batracios y reptiles. *Gaceta Sanitaria de Barcelona,* 10. Aug.

Cajal, Ramón Y. S. R. (1891) Terminaciones nerviosas en el corazón de los mammiferos. *Gaceta Sanitaria de Barcelona,* 10 April.

Capenhaver, W. M. and Truex, R. C. (1952) Histology of the atrial portion of the cardiac conducting system in man and other mammals. *Anat. Rec.* **114,** 601.

Carbonell, M. L. (1956) Esterases of the conductive system of the heart. *J. Histochem. Cytochem.* **4,** 87.

CARLSON, A. J. (1904) Contributions to the physiology of the heart of the California Hagfish (Bdellostoma Dombeyi). *Z. allg. Physiol.* **4,** 259.

CARLSON, A. J. (1905) Die Ganglienzellen des Bulbus arteriosus und der Kammerspitze beim Salamander (Necturus maculatus.) *Pflügers Arch. ges. Physiol.* **109,** 51.

CHABAROWA, A. J. (1952) Über die sensible Innervation des Herzens des Menschen und einiger Säugetiere. *Trud. Inst. Physiol. I. P. Pawlowa Acad. Nauk SSSR.* **1,** 552.

CHABAROWA, A. J. (1955) The nature of pericapsular nerve endings. *Dokl. Akad. Nauk SSSR. Otd. Biol.* **102,** 629.

CHABAROWA, A. J. (1958) Experimentell-morphologische Studien über die afferente Innervation des Epicards der Herzkammern. *Z. mikr.-anat. Forsch.* **63,** 571.

CHABAROWA, A. J. (1960) Über die rezeptorischen Felder im Herzen. *Z. mikr.-anat. Forsch.* **67,** 434.

CHABAROWA, A. J. (1960) Die afferente Innervation des Herzens. *Z. mikr.-anat. Forsch.* **66,** 236.

CHABAROWA, A. J. (1963) *The afferent innervation of the heart.* (Transl. from Russian). Basil Haigh. New York.

CHRISTENSEN, G. C. (1952) Circulation of blood through the canine kidney. *Amer. J. Vet. Res.* **13,** 47.

CONTI, G. (1948) Etudes sur la morphologie des cellules des ganglions sympathiques intramuraux du coeur humain. *Acta anat. (Basel)* **5,** 255.

CONTI, G. (1950) Cellules ganglionnaires sympathiques du système spécifique du coeur humain. *Acta anat. (Basel)* **10,** 315.

COUTEAUX, R. and LAURENT, P. (1957) Etude au microscope électronique du coeur de l'Anguille: observations sur la structure du tissu musculaire de l'oreillette et son innervation. *C. R. Acad. Sci. (Paris)* **245,** 2097.

COUTEAUX, R. and LAURENT, P. (1958) Observations au microscope électronique sur l'innervation cardiaque des Téléostéens. *Bull. Ass. Anat. (Nancy)* **98,** 230.

CYON, E. DE: 1905. *Nerfs du coeur. Anatomie et physiologie.* Alcan, Paris.

DAVIES, F. and FRANCIS, E. T. B. (1952) The conducting system of the vertebrata heart. *Biol. Rev.* **21,** 173.

DAVIES, F., FRANCIS, E. T. B. and KING, T. S. (1951) Ventricular nerve cells in mammals. *Nature (Lond.)* **167,** 113.

DAVIES, F., FRANCIS, E. T. B. and KING, T. S. (1952) Neurological studies of the cardiac ventricles of mammals. *J. Anat. (Lond.)* **86,** 130.

DEL CASTILLO, J. and KATZ, B. (1955) The membrane potential changes in the frog's heart produced by inhibitory nerve impulses. *Nature (Lond.)* **175,** 1035.

DELCHEF, J. (1904) Sur la pulsation du sinus veineux chez l'Anguille. (Anguilla fluviatilis). *Arch. int. Physiol.* **2,** 123.

DEMOOR, L. and HEYMANS, J. F. (1895) Etude de l'innervation du coeur des vertébrés à l'aide de la méthode de Golgi. *Arch. Biol. (Liège)* **13,** 619.

DOGIEL, A. S. (1877) Die Ganglienzellen des Herzens bei verschiedenen Tieren und beim Menschen. *Arch. mikr. Anat.* **14,** 470.

DOGIEL, A. S. (1882) Die Nervenzellen und Nerven des Herzventrikels beim Frosch. *Arch. mikr. Anat.* **21,** 305.

DOGIEL, A. S. (1896) Zwei Arten sympathischer Nervenzellen. *Anat. Anz.* **15,** 140.

DOGIEL, A. S. (1898) Die sensiblen Nervenendigungen im Herzen und in den Blutgefäßen der Säugetiere. *Arch. mikr. Anat.* **52,** 44.

DOGIEL, A. S. (1899) Zur Frage über den feineren Bau der Herzganglien des Menschen und der Säugetiere. *Arch. mikr. Anat.* **53,** 237.

DOGIEL, A. S. (1907) Einige Daten der Anatomie des Frosch- und Schildkrötenherzens. *Arch. mikr. Anat.* **70,** 780.

DOGIEL, A. S. (1912) Das Verhältnis des Nervensystems zur Herztätigkeit beim Hunde, Kalbe und Menschen. *Pflügers Arch. ges. Physiol.* **142,** 109.

DOGIEL, A. S. (1914) Die Anordnung und Funktion der Nervenzellen des Herzens des Menschen und der Tiere. *Pflügers Arch. ges. Physiol.* **144,** 155.

DOGIEL, A. S. and ARCHANGELSKY, K. (1906) Der bewegungshemmende und der motorische Nervenapparat des Herzens. *Pflügers Arch. ges. Physiol.* **113,** 1.

DOGIEL, J. and TUMANZEW, J. (1890) Zur Lehre über das Nervensystem des Herzens. *Arch. mikr. Anat.* **36,** 483.

DOLGO-SABUROW, B. A. (1952) Einige Aufgaben der neuzeitlichen Morphologie der afferenten Innervation. *Arch. Anat. Histol. Embryol.* **29,** 8.

DRENNAN, M. R. (1927) The auriculo-ventricular bundle in the bird's heart. *Brit. med. J.* 221.

DRUMMOND, J. 1859. In Todd, R. B. *Cyclopaedia of anatomy and Physiology*. 5. Longman, Brown, Green, Longmans and Roberts, London.

DU BOIS, F. S. and FOLEY, J. O. (1936) The motor and sensory fibres in the vagus nerve of the cat. *Anat. Rec.* **64,** 14.

DU BOIS, D. S. and FOLEY, J. O. (1936) Experimental studies on the vagus and spinal accessory nerves in the cat. *Anat. Rec.* **64,** 285.

DUMONT, L. (1954) L'innervation cholinergique du tissu nodal. *C. R. Acad. Sci. (Paris)* **238,** 1263.

DUMONT, L. (1955) L'innervation cholinergique des régions nodales du coeur. *C. R. Ass. Anat.* **41,** 375.

DUMONT, L. (1957) Localisation histochimique d'acétylcholinestérase dans les régions nodales du coeur de mammifère. *Ann. Histochim.* **2,** 19.

DUMONT, L. and DROUIN, M. (1954) Localisation histochimique de l'acétylcholinestérase dans le muscle cardiaque. *C. R. Acad. Sci. (Paris)* **238,** 274.

DZIALLAS, P. and ATHANASION, P. J. (1955) Über hypolemmale Ringbinden im Reizleitungssystem des Schafsherzens. *Z. Zellforsch.* **43,** 214.

EAST, T. and BAIN, C. 1959. *Recent advances in cardiology*. Churchill, London.

ECCLES, J. C. 1957. *Physiology of the nerve cells*. J. Hopkins, Baltimore.

ECKHARD, C. (1867) Zur Entwicklungsgeschichte der Herzmuskulatur. *Z. rat. Med. Dritte Reihe* **29,** 55.

ERICH, H. 1914. *Vorkommen von Vater-Pacinischen Körperchen in der Wand der Pfortader eines menschlichen Neugeborenen*. Diss. med. Bonn.

EIGER, M. (1923) Les ganglions et les cellules nerveuses sous endocardiaques; leur rôle dans l'automatisme du coeur. *Arch. suisse Neur.* **13,** 223.

ELLENBERGER, W. and BAUM, H. 1911. *Handbuch der vergleichenden mikroskopischen Anatomie der Haustiere*. Springer, Berlin.

ENGEL, L. (1910) Beiträge zur normalen und pathologischen Histologie des Atrioventricularbündels. *Beitr. path. Anat.* **48,** 499.

ENGELMANN, TH. W. (1875) Über die Leitung der Erregung im Herzmuskel. *Pflügers Arch. ges. Physiol.* **11,** 465.

ERES, B. M. (1938) Sur le problème de l'innervation intramurale du coeur chez les vertébrés. *Arch. Russ. d'Anat.* **18,** 461.

ESVELD, L. W. VAN (1926) On the presence of ganglion-cells in the circular muscle of the intestine of the cat. *Proc. kon. ned. Acad. Wet.* **29,** 178.

ESVELD, L. W. VAN (1928) Über die nervösen Elemente der Darmwand. *Z. mikr.-anat. Forsch.* **15,** 1.

EVANS, D. H. L. and MURRAY, I. G. (1954) Histological and functional composition of the vagus nerve of the rabbit. *J. Anat. (Lond.)* **88,** 320.

EVERSBUSCH, G. (1916) Anatomische und histologische Untersuchungen über die Beziehungen der Vorhofsganglien zu dem Reizleitungssystem des Katzenherzens. *Dtsch. Arch. Klin. Med.* 120.

FAHR, T. (1908) Zur Frage der atrioventriculären Muskelverbindung im Herzen. *Verh. dtsch. path. Ges.* **12** *Tagg. Kiel.* 1908. 153.

FAHR, T. (1909) Über die Ganglien des menschlichen Herzens. *Münch. med. Wschr.* **56,** 1509.

FAHR, T. (1910) Zur Frage der Ganglienzellen im menschlichen Herzen. *Zbl. Herz- u. Gefäßkr.* **2,** 195.

FALLOPIUS, G. 1600. *Opera omnia*. A. Wecheli, Francofurti.

FANGE, R. and OSTLUND, E. (1954) The effect of adrenaline, noradrenaline, tyramine and other drugs on the isolated heart from marine vertebrates and a cephalopod. *Acta Zool. Stockh.* **35,** 289.

FATTORUSSO, V. (1941) L'innervation sympathique du myocarde et du faisceau de His. *Bull. Soc. vaud. Sci. nat.* **61,** 421.

FATTORUSSO, V. (1943) L'innervazione del muscolo involontario e del tessuto specifico cardiaco (fascio atrioventriculare) nei mammiferi. *Arch. ital. Anat. Embriol.* **48,** 339.

FAWCETT, D. W. and SELBY, C. C. (1957) Observations on the fine structure of the turtle atrium. *Anat. Rec.* **127,** 291.

FEDELE, M. (1914) Ricerche sull' innervazione del cuore. I. Rettili e Batraci *Atti R. Accad. Sci. fis. mat. Napoli,* **II. 15,** 1.

FEYRTER, F. (1952) Die normale und pathologische Anatomie der vegetativen nervösen Peripherie unter besonderer Berücksichtigung der intercalären Elemente (Boeke). *Acta neuroveg. (Wien)* **4,** 165.

FIELD, F. J. (1950) The nervous component of the atrioventricular bundle. *J. Anat. (Lond.)* **84,** 65.
FIELD, F. J. (1951) The nervous component of the atrioventricular bundle. *J. Anat. (Lond.)* **85,** 105.
FIELD, F. J. (1953) Observations on the nervous component of the atrioventricular bundle in cat, and on the innervation of the myocardium. *J. Anat. (Lond.)* **87,** 451.
FILOTTO, U. (1955) Sulla fine innervazione del cuore, con particolare riguardo al problema della conduzione. *Biol. lat.* **8,** 815.
FLEISCHHACKER, H. and KLAUSGRABER, F. 1959. *Herz- und Gefäßkrankheiten.* Lehmann, München.
FRANCILLON, M. R. (1928) Zur Topographie der Ganglien des menschlichen Herzens. *Z. Anat. Entwickl.-Gesch.* **85,** 131.
FREEDMAN, B. (1952) Microscopy of synapses of nonexcised frog heart. *Proc. Soc. exp. Biol. (N.Y.)* **80,** 399.
FRIEDBERG, CH. K. 1958. *Diseases of the heart.* Saunders, Philadelphia–London.
FUKUTAKE, K. (1925) Beiträge zur Histologie und Entwicklungsgeschichte des Herznervensystems. *Z. Anat. Entwickl-Gesch.* **76,** 592.
GAD, J. and HEYMANS, C. (1890) Über das Myelin, die myelinhaltigen und myelinlosen Nervenfasern. *Arch. Anat. Physiol.* 530.
GAETANI, L. DE (1911) Le faisceau auriculo-ventriculaire chez l'homme. *Arch. ital. Biol.* **36,** 97.
GAETANI, L. DE (1913) Sulla struttura del fascio atrio-ventricolare. *Mon. Zool. Ital.* **23,** 243.
GASK, G. E. and ROSS, I. P. 1936. *Die Chirurgie des sympathischen Nervensystems.* Johann Ambrosius Barth, Leipzig.
GASKELL, W. H. (1883) On the innervation of the heart with special reference to the heart of the tortoise. *J. Physiol.* **4,** 43.
GAUPP, E. 1904. *Anatomie des Frosches* I–IV. Friedrich Vieweg. Braunschweig.
GEHUCHTEN, A. VAN (1902) Les fibres inhibitives du coeur appartiennent au nerf pneumogastrique et pas au nerf spinal. *Névraxe* **4,** 303.
GÉRAUDEL, E. (1928) Les veines des cardio-necteurs. *Arch. Mal. Coeur,* **21,** 148.
GEREBTZOFF, M. A. (1953) Recherches histochimiques sur les acétylcholines et cholinestérases. *Acta anat. (Basel)* **19,** 366.
GEREBTZOFF, M. A. (1956) Recherches sur l'innervation cholinergique comparée du coeur de mammifère et de tortue. *Ann. Histochim.* **1,** 166.
GERLACH, L. (1876) Über die Nervenendigungen in der Musculatur des Froschherzens. *Virchows Arch. path. Anat.* **36,** 3.
GITTER, A. (1933) Untersuchungen über die Herztätigkeit der Fische. *Z. vergl. Physiol.* **18,** 654.
GLASER, W. (1914) Der intramurale Nervenapparat des Herzens. *Dtsch. Arch. klin. Med.* **117,** 26.
GLOMSET, D. I. and BIRGE, R. F. (1945) A morphologic study of the cardiac conduction system. IV. The anatomy of the upper part of the ventricular septum in man. *Amer. Heart. J.* **29,** 526.
GLOMSET, D. I. and CROSS, K. R. (1952) Morphologic study of the cardiac conduction system. VI. The intrinsic nervous system of the heart. *Arch. internat. Med.* **89,** 923.
GLOMSET, D. I. and GLOMSET, A. T. A. (1940) A morphologic study of the cardiac conduction system in ungulates, dog and man. I. The sinoatrial node. *Amer. Heart. J.* **20,** 389.
GLOMSET, D. I. and GLOMSET, A. T. A. (1940) A morphologic study of the cardiac conduction system in ungulates, dog and man. II. The Purkinje system. *Amer. Heart. J.* **20,** 677.
GOERTTLER K. (1961) Struktur und Bedeutung der Purkinjefasern im Herzen. *Verh. Dtsch. Ges. Kreisl.-Forsch.* **27,** 295.
GOORMAGHTIGH, N. and PANNIER R. (1939) Les paraganglions du coeur et des zones vasosensibles carotidiennes et cardio-aortiques chez le chat adulte. *Arch. Biol. (Liège).* **50,** 4.
GOTTSCHICK, J. 1952. *Die Leistungen des Nervensystems.* G. Fischer, Jena.
GOVAERTS, J. (1936) Contribution à l'étude de l'innervation sympathique du coeur. *Arch. int. Méd. exp.* **11,** 629.
GOVAERTS, J. (1936) Étude oscillographique de l'activité électrique des nerfs cardiaques en connexion avec le névraxe. *C. R. Soc. Biol. (Paris)* **122,** 445.
GRAMENIZKI, M. I. (1934) Anatomisch-histologische mikrokopische Untersuchungen am schlagenden Froschherzen. *Z. Zellforsch.* **21,** 314.
GREVING, R. (1951) Über die Kontinuität von Ganglienzellen das Terminalreticulum und das Synapsen-Problem. *Acta neuroveg. (Wien)* **3,** 507.

GREVING, R. and DRESSLER, W. (1954) Das plasmodiale nervöse Terminalnetz in der Submucosa des menschlichen Rektums. *Acta neuroveg (Wien)* Suppl. **6,** 64.

GYÉVAI, A. T. (1958) Herzstudien I. Histologie und Histochemie des Herzens von erwachsenen Triturus cristatus. *Acta biol. Acad. Sci. hung.* **8,** 333.

GYÉVAI, A. T. (1958) Herzstudien II. Untersuchungen von überlebenden Herzabschnitten des Triturus cristatus. *Acta biol. Acad. Sci. hung.* **8,** 343.

GYÉVAI, A. T. (1960) Herzstudien III. Histologische und histochemische Untersuchungen am Herzen von Abramis brama. *Acta biol. Acad. Sci. hung.* **11,** 35.

HAAS, G. (1911) Über die Gefäßversorgung des Reizleitungssystems des Herzens. *Anat. Hefte* **43,** 629.

HABERLAND, L. (1916) Die Physiologie der atrioventrikulären Verbindungen des Kaltblüterherzens. *Arch. Physiol.* 367.

HALLER, A. 1762. *Elementa physiologiae corporis humani;* tomus quartus — cerebrum, nervi, musculi. F. Grasset, Lausannae.

HALPERN, M. H. (1953) The sinoatrial node of the rat heart. *Anat. Rec.* **123,** 425.

HAUSMANN, E. (1956) Über die Anatomie der Herznerven. *Z. Anat. Entwickl.-Gesch.* **119,** 263.

HAUSMANN, E. (1956) Über die Anatomie der Herznerven. *Z. Anat. Entwickl.-Gesch.* **119,** 263.

HEINBECKER, P. (1930) The effect of fibres of different types in the vagus and sympathetic nerves of the heart. *Amer. J. Physiol.* **93,** 656.

HEINBECKER, P. (1931) The effect of fibres of specific types in the vagus and sympathetic nerves on the sinus and atrium of the turtle and frog heart. *Amer. J. Physiol.* **98,** 220.

HEINBECKER, P. and BISHOP, G. H. (1935) Studies on the extrinsic and intrinsic nerve mechanisms of the heart. *Amer. J. Physiol.* **144,** 212.

HEINBECKER, P. and O'LEARY, H. (1933) The mammalian vagus nerve, a functional histological study. *Amer. J. Physiol.* **106,** 623.

HERING, H. E. 1927. *Die Karotissinusreflexe auf Herz und Gefäße.* Theodor Steinkopff, Dresden–Leipzig.

HERING, H. E. 1932. *Der Blutdruckzüglertonus in seiner Bedeutung für den Parasympathicustonus und Sympathicustonus.* Georg Thieme, Leipzig.

HERMANN, H. (1949) Mikroskopische Beobachtungen an den Herzganglien des Menschen bei Coronarsklerose. *Virchows Arch. path. Anat.* **316,** 341.

HERMANN, H. (1950) Mikroskopische Studien an menschlichen Herzganglien. Ein Beitrag zur Individualanatomie. *Z. Anat. Entwickl.-Gesch.* **114,** 511.

HERMANN, H. (1950) Mikroskopische Beobachtungen über Altersveränderungen an menschlichen Herzganglien. *Z. Anat. Entwickl.-Gesch.* **114,** 685.

HERMANN, H. (1951) Mikroskopische Befunde an menschlichen Herzganglien bei verschiedenen Erkrankungen. *Dtsch. Z. Nervenheilk.* **165,** 127.

HERZOG, E. (1954) Bedeutung und Kritik des nervösen, vegetativen Terminalreticulums (Stöhr). *Acta neuroveg. (Wien)* **10,** 110.

HEYMANS, J. F. (1893) Über die Innervation des Froschherzens. *Arch. Anat. Physiol.* (Physiol. Abt.) 391.

HILLARP, N. A. (1946/47) Structure of the synapse and the peripheral innervation apparatus of the autonomic nervous system. *Acta anat. (Basel)* **2** (Suppl. 4), 1.

HINTSCHE, E. (1954) Volumetrische Untersuchungen an amitotisch geteilten Kernen des Reizleitungssystems. *Z. mikr.-anat. Forsch.* **60,** 522.

HIRSCH, E. F. (1963) The innervation of human heart. IV. 1. The fibre connections of the nerves with the perimysal plexus (Gerlach–Hofmann), 2. The role of nerve tissues in the repair of infarcts. *Arch. Path.* **75,** 378.

HIRSCH, E. F. (1963) The innervation of human heart. V. A comparative study of the intrinsic innervation of the heart in vertebrates. *Exp. molec. Path.* **2,** 384.

HIRSCH, E. F. and BORGHARD-ERDLE, A. M. (1961) The innervation of human heart. I. The coronary arteries and myocardium. *Arch. Path.* **71,** 384.

HIRSCH, E. F. and BORGHARD-ERDLE, A. M. (1962) The innervation of human heart II. The papillary muscles. *Arch. Path.* **73,** 100.

HIRSCH, E. F. and BORGHARD-ERDLE, A. M. (1962) The innervation of human heart. III. The conductive system. *Arch. Path.* **74,** 427.

HIRSCH, E. F. and ORME, I. F. (1947) Sensory nerves of the human heart. *Arch. Path.* **44,** 325.

HIRSCH, E. F., WILLMEN, V. L., JELLINEK, M. and COOPER, T. (1963) The terminal innervation of the heart. I. Quantitative correlations of the myocardial catecholamines with the perimysal plexus in the normal cardiac tissues of the rabbit and dog and in the heart of dog after total extrinsic denervation. *Arch. Path.* **76,** 677.

HIRSCHFELD, L. 1853. *Névrologie, ou description et iconographie du système nerveux et des organes des sens de l'homme, avec leur mode de préparation.* J. B. Baillière, Paris.

HIS, W. (1892) Über die Entwicklung des Sympathicus bei Wirbeltieren mit besonderer Berücksichtigung der Herzganglien. *Verhandl. d. anat. Ges. Wien.*

HIS, W. (1893) Die Tätigkeit des embryonalen Herzen und deren Bedeutung für die Lehre von den Herzbewegungen beim Erwachsenen. *Arb. med. Klin. Z. (Leipzig)* **14.**

HIS, W. and ROMBERG, F. (1909) Beiträge zur Herzinnervation. *Fortschr. Med.* **8,** 374–416.

HOFFMAN, B. F. and CRANEFIELD, P. F. 1960. *Electrophysiology of the heart.* McGraw-Hill, New York–Toronto–London.

HOFMANN, F. B. (1902) Das intracardiale Nervensystem des Frosches. *Arch. Anat. Physiol. (Anat. Abt.)* **54.**

HOFMANN, H. K. (1902) Beitrag zur Kenntnis der Purkinjeschen Fäden im Herzmuskel. *Z. wiss. Zool.* **71,** 486.

HOLL, M. 1911. *Makroskopische Darstellung des atrioventiculären Verbindungsbündels am menschlichen und tierischen Herzen.* Deutsche Akad. Wiss., Wien.

HOLMES, A. H. (1921) The auriculo-ventricular bundle in mammals. *J. Anat. (Lond.)* **55,** 269.

HOLMES, R. L. (1956) Receptor nerve endings in the adult dog heart. *J. Anat. (Lond.)* **90,** 588.

HOLMES, R. L. (1956) Further observations on the nerve endings in the adult dog heart. *J. Anat. (Lond.)* **90,** 600.

HOLMES, R. L. (1957) Structures in the atrial endocardium of the dog which stain with methylene blue and the effects of unilateral vagotomy. *J. Anat. (Lond.)* **91,** 259.

HOLMES, R. L. (1957) Cholinesterase activity in the dog heart wall. *J. Anat. (Lond.)* **91,** 588.

HOLMES, R. L. (1957) Nerves of the rodent heart and ductus arteriosus. *J. Anat. (Lond.)* **91,** 606.

HOLMES, R. L. (1957) Cholinesterase activity in the atrial wall of the dog and cat heart. *J. Physiol. (Lond.)* **137,** 421.

HORVÁTH, I. (1959) Az idegrendszer experimentális vizsgálata a békák szívén (Experimental studies on the nervous system in the frog's heart). *Állattani Közl.* **47,** 93.

HOSHI, T. (1924) Über die Nervenendigungen des Herzens und der Nebenniere. *Trans. Jap. path. Soc.* **14,** 123.

HOSHI, T. (1926) Über die Nervenendigungen an der Herzmuskulatur. *Tohoku Igaku Zasshi* **6,** 34.

HOSHIKO, T., SPERELAKIS, N. and BERNE R. M. (1959) Evidence for non-syncytial nature of cardiac muscle from impedance measurements. *Proc. Soc. exp. Biol. (N. Y.)* **101,** 602.

HOVELACQUE, A. 1927. *Anatomie des nerfs craniens et rachidiens et du système grand sympathique chez l'homme.* G. Doin et Cie., Paris.

HUTTER, O. F. and TRAUTWEIN, W. (1955) Effect of vagal stimulation on the sinus venosus of the frog's heart. *Nature (Lond.)* **176,** 512.

IONESCU, D. and ENACHESCU, M. (1928) Untersuchungen bei Säugetieren und beim Menschen über die aus dem Brustgrenzstrang des Sympathicus unterhalb des Ganglion stellatum entsprungenen Herznerven. *Z. Anat. Entwickl.-Gesch.* **85,** 476.

IWANOW, I. F. and RADOSTINA, T. N. (1933) Sur la morphologie du système nerveux autonome du tube digestif chez certains mammifères et quelques oiseaux. *Trav. Lab. Rech. biol. Univ. Madrid* **28,** 303.

IZQUIERDO, J. J. (1930) On the influence of the extra-cardiac nerves upon the sinu-auricular conduction in the heart of Scyllium. *J. Physiol.* **69,** 29.

JACQUES, P. (1894) Recherches sur les nerfs du coeur chez la grenouille et les mammifères. *J. Anat. (Paris)* **30,** 622.

JAMES, TH. N. (1964) Anatomy of the a-v node of the dog. *Anat. Rec.* **148,** 15.

JARISCH, A. and RICHTER, H. (1939) Die afferenten Bahnen des Veratrineffekts in den Herznerven. *Arch. exper. Path. Pharmakol.* **176,** 355.

JARISCH, A. and ZOTTERMAN, Y. (1948) Depressor reflexes from the heart. *Acta physiol. scand.* **16,** 31.

JOHNSTONE, P. N. and WAKEFIELD, F. H. (1922) On the character of the Purkinje fibers in various regions of the atrio-ventricular bundle. *Anat. Rec.* **24,** 223.

JOHNSTONE, P. N. WAKEFIELD, F. H. and CURREY, A. U. (1923) On the comparation vascularity of heart muscle and the Purkinje fibers. *Anat. Rec.* **25,** 55.

JONES, A. M. 1960. *Modern trends in cardiology.* Butterworths, London.

JONES, T. (1927) Intramuscular nerve elements of the ventricular muscle. *J. Anat. (Lond.)* **61,** 247.

JULLIEN, A. and RIPPLINGER, J. (1956) De l'action des nerfs vagues ou de type vagal sur le fonctionnement du coeur chez les Mollusques et les Poissons, et ses rapports avec la production eventuelle d'un médiateur: l'acétylcholine. *Bull. Biol.* **90,** 33.

KASAHARA, I. (1927) Vergleichend-anatomische Studien über die Nervenendigungen im Herzmuskel. *Mitt. med. Akad. Kioto* **11,** 55.

KASAHARA, I. (1927) Nervous apparatus in the specific muscle of the heart. *Trans. jap. Path. Soc.* **17,** 426.

KASAHARA, I. (1928) Nervenendigungen in der Intima des Herzens. *Mitt. med. Akad. Kioto* **2,** 991.

KASEM-BECK, A. N. (1882) Beitrag zur Kenntnis der Struktur und der Funktion des Herzens der Knochenfische. *Z. wiss. Zool.* **37,** 247.

KASEM-BECK, A. N. (1885) Zur Kenntnis der Herznerven. *Arch. mikr. Anat.* **24,** 11.

KASEM-BECK, A. N. (1887) Über das Vorkommen von Ganglien und einzelnen Nervenzellen auf den Herzventrikeln des Menschen, der Säugetiere und der Vögel. *Zbl. med. Wiss.* **42,** 785.

KAYLOR, C. T. (1945) Studies on the innervation of the guinea pig heart. *Anat. Rec.* **91,** 284.

KAYLOR, C. T. (1946) Observations on the nerve supply to the atrioventricular bundle in the guinea pig heart. *Anat. Rec.* **94,** 541.

KEATINGE, W. R. (1959) The effect of increased filling pressure on rhythmicity and atrioventricular conduction in isolated heart. *J. Physiol. (Lond.)* **149,** 193.

KEITH, A. and FLACK, M. (1907) The form and nature of the muscular connections between the primary divisions of the vertebrate heart. *J. Anat. Physiol.* **41,** 172.

KEITH, A. and MACKENZIE, I. (1910) Recent researches on the anatomy of the heart. *Lancet* **1,** 101.

KENT, A. F. S. (1893) Researches on the structure and function of the mammalian heart. *J. Physiol. (Lond.)* **14,** 233.

KIETZ, D. (1963) Zur Frage der Lagekonstanz der Herzganglien bei Säugern nach Untersuchungen an Myotis oxygnathus, Rattus norvegicus var. albus und Felis domestica. *Morph. Jahrbuch* **105,** 185.

KING, A. B. (1939) Nerve endings in the cardiac muscle of the rat. *Bull. Johns Hopk. Hosp.* **65,** 489.

KING, T. S. (1954) The sinoatrial node in the rat. *Amer. Heart J.* **48,** 785.

KING, T. S. and COAKLEY, J. B. (1958) The intrinsic nerve cells of the cardiac atria of mammals and man. *J. Anat. (Lond.)* **92,** 353.

KIRSCHE, W. (1955) Messungen an ring- und kugelförmigen Endapparaten im Ganglion stellare des Menschen. *Z. mikr.-anat. Forsch.* **61,** 541.

KIRSCHE, W. (1955) Synaptische Endigungen im Ganglion coeliacum des Menschen. *Z. mikr.-anat. Forsch.* **61,** 624.

KIRSCHE, W. (1958) Synaptische Formationen in den Ganglia lumbalia des Truncus sympathicus vom Menschen einschließlich Bemerkungen über den heutigen Stand der Neuronenlehre. *Z. mikr.-anat. Forsch.* **64,** 707.

KIRSCHE, W. (1960) Die Neuronentheorie. *Münch. med. Wschr.* **102,** 2266.

KISCH, B. (1948) Electrographic investigations of the heart of fish. *Exper. med. Surg.* **6,** 31.

KISCH, B. (1950) Reflex cardiac inhibition in the ganoid Acipenser sturio. *Amer. J. Physiol.* **160,** 552.

KISCH, B. (1954) Studies in comparative electronmicroscopy of the heart. I. Pipefish and rat. *Exp. Med. Surg.* **12,** 335.

KISELJEWA, A. F. (1953) Der rezeptorische Apparat des Menschenherzens. *Woprosy Physiol.* **5,** 122.

KISTIN, A. D. (1949) Observations on the anatomy of the atrioventricular bundle and the question of other muscular atrioventricular connections in normal human hearts. *Amer. Heart J.* **37,** 849.

KLUG, F. (1881) Über die Herznerven des Frosches. *Arch. Anat. Physiol.* (Anat. Abt.) 330.

KNOCHE, H. (1958) Beitrag zum Bau der neurovegetativen Endformation. *Z. mikr.-anat. Forsch.* **64,** 110.

KOCH, W. (1909) Über die Blutversorgung des Sinusknotens und etwaige Beziehungen des letzteren zum Atrioventrikularknoten. *Münch. med. Wschr.* **56,** 2362.

KOCH, W. 1922. *Der funktionelle Bau des menschlichen Herzens.* Urban–Schwarzenberg, Berlin–Wien.

KOEHNLEIN, H. (1933) Untersuchungen über die Herztätigkeit der Fische. *Publ. Staz. Zool. Napoli* **13,** 129.

KOELLE, G. B. and FRIEDENWALD, J. S. (1949) A histochemical method for localizing cholinesterase activity. *Proc. Soc. exp. Biol. (N. Y.)* **70,** 617.

KOELLIKER, A. (1863) On the termination of the nerves in muscles, as observed in the frog and on the disposition of the nerves in the frog's heart. *Proc. roy. Soc.* **12,** 65.

KOELLIKER, A. 1902. *Handbuch der Gewebelehre des Menschen.* W. Engelmann, Leipzig.

KOLATAT, T., KRAMMER, K. and MUHL, N. (1907) Über die Aktivität sensibler Herznerven des Frosches und ihre Beziehungen zur Herzdynamik. *Pflügers Arch. ges. Physiol.* **264,** 127.

KOLFF, W. M. (1908) Untersuchungen über die Herztätigkeit bei Teleostien. *Arch. ges. Physiol.* **122,** 37.

KONDRATJEW, N. S. (1926) Zur Frage über die intrakardiale Innervation der Vögel. *Z. Anat. Entwickl.-Gesch.* **79,** 753.

KONDRATJEW, N. S. (1930) Über Formbildungstypen des kardialen, nervösen Grundgeflechtes bei verschiedenen Gruppen der Wirbeltiere. I. *Z. Anat. Entwickl.-Gesch.* **93,** 429.

KONDRATJEW, N. S. (1933) Über Formbildungstypen des kardialen, nervösen Grundgeflechtes bei verschiedenen Gruppen der Wirbeltiere. II. *Z. Anat. Entwickl.-Gesch.* **100,** 712.

KONDRATJEW, N. S. and ERES, B. (1938) Zur Lehre von Herzinnervation in den Klassen der Amphibien und Reptilien. *Arch. J. Anat.* **17,** 446.

KRAUSE, R. 1921/26. *Mikroskopische Anatomie der Wirbeltiere.* I–IV. Walter de Gruyter Co., Leipzig.

KREHL, L. and ROMBERG, E. (1892) Über die Bedeutung des Herzmuskels und der Herzganglien für die Herztätigkeit des Säugetieres. *Naunyn-Schmiedebergs Arch. exp. Path. Pharmak.* **30.**

KULBS, A. (1913) Über das Reizleitungssystem im Herzen der Fische. *Charité Ann.* **37,** 24.

KULCHITSKY, K. I. (1960) Blood supply and innervation of the heart in the condition of experimental myocardial infarction. *Anat. Rec.* **136,** 226.

KULTSCHITZKY, N. (1924) Nerve endings in muscle. *J. Anat. (Lond.)* **58,** 152.

KUNO, Y. and BRUCKE, TH. (1914) Der funktionelle Nachweis des Nervus depressor beim Frosch. *Pflügers Arch. ges. Physiol.* **157,** 117.

KUNTZ, A. 1950. *A Textbook of neuro-anatomy.* Lea and Febiger, Philadelphia.

KUNTZ, A. and KEPLER, A. H. (1929) Observations on the occurrence of thoracic sympathetic cardiac nerves in man. *Anat. Rec.* **42,** 26.

KUNTZ, A. and MOREHOUSE, A. (1930) Thoracic sympathetic cardiac nerves in man; their relation to cervical sympathetic ganglionectomy. *Arch. Surg.* **20,** 607.

LAHOUSSE, F. (1886) Die Struktur des Nervenplexus in der Vorhofscheidewand des Froschherzens. *Arch. Anat. Physiol.* (Physiol. Abt.)

LANDAU, E. (1949) Quelques notes sur l'innervation du myocarde. *Cardiologie (Basel)* **14,** 243.

LANDAU, E. (1949/50) L'innervation du coeur. *Cardiologie (Basel)* **15,** 222.

LANDAU, E. (1950) Contribution à l'innervation du coeur. Fibres myelinisées. *Acta anat. (Basel)* **9,** 227.

LANDAU, E. (1951) Contribution à l'innervation du coeur. Fibres myelinisées. *Acta anat. (Basel)* **9,** 227. **13,** 119.

LANGERHANS, P. (1873) Zur Histologie des Herzens. *Virchows Arch.* **58,** 65.

LANGLEY, J. N. 1900. In Schäfer, E. A. *Textbook of physiology.* **11,** 616. Y. J. Pentland, Edinburgh.

LANGLEY, J. N. (1903) The autonomic nervous system. *Brain* **26,** 1.

LANGLEY, J. N. 1921. *The autonomic nervous system.* Heffer and Sons, Cambridge.

LASOWSKY, J. M. (1931) Normale und pathologische Histologie der Herzganglien des Menschen. *Virchows Arch. path. Anat.* **279,** 464.

LAURENS, H. (1915) The connecting system of the reptile heart. *Anat. Rec.* **9,** 427.

LAURENT, P. (1952) L'innervation cardiaque de la Tanche (Tinca vulgaris). *Arch. Zool. exp. gén.* **89,** 63.

LAURENT, P. (1954) Histologie topographique de l'innervation cardiaque de divers Téléostéens marins et d'eau douce. *Bull. Muséum,* **26,** 579.

LAURENT, P. (1956) Mode de terminaison et signification fonctionnelle des fibres myélinisées innervant sans relais ganglionnaires le tissu musculaire de l'oreillette des Téléostéens. *C. R. Acad. Sci. (Paris)* **243,** 534.

LAURENT, P. (1957) L'innervation auriculaire du coeur des Téléostéens. *Arch. Anat. micr. Morph. exper.* **46,** 50.

LAURENT, P. (1957) Activité de fibres afférentes dans le nerf cardiaque d'un Téléostéen. *J. Physiol. (Paris)* **49,** 1.

LAURENT, P. (1957) Le rôle de la région sino-auriculaire dans le fonctionnement cardiaque chez les Téléostéens. *Physiol. comp. Oecol.* **4,** 346.

LAURENT, P. (1959) Effets de l'excitation du bout central du nerf cardiaque chez un Téléostéen. *J. Physiol. (Paris)* **51,** 508.

LAURENT, P. (1961) Analyse pharmacologique au niveau de l'oreillette isolée de poisson-chat, de l'innervation cardiaque efférente. *C. R. Acad. Sci. (Paris)* **253,** 196.

LAURENT, P. (1962) Contribution à l'étude morphologique et physiologique de l'innervation du coeur des Téléostéens. *Arch. Anat. micr. Morph. exper.* **51,** 339.

LAWRENTJEW, B. J. (1925) Über die Erscheinung der Degeneration und Regeneration im sympathischen Nervensystem. *Z. mikr.-anat. Forsch.* **2,** 201.

LAWRENTJEW, B. J. (1927) Die Faserendigungen des N. vagus im Säugetierherzen. *Anat. Anz.* **64,** 59.

LAWRENTJEW, B. J. (1929) Die Beteiligung des Vagus an der Herzinnervation. *Z. mikr.-anat. Forsch.* **16,** 383.

LAWRENTJEW, B. J. (1929) Experimentell-morphologische Studien über den feineren Bau des autonomen Nervensystems. I. Die Beteiligung des Vagus an der Herzinnervation. *Z. mikr.-anat. Forsch.* **16,** 383.

LAWRENTJEW, B. J. (1929) Experimentell-morphologische Studien über den feineren Bau des autonomen Nervensystems II. Über den Aufbau der Ganglien der Speiseröhre nebst einigen Bemerkungen über das Vorkommen und die Verteilung zweier Arten von Nervenzellen in dem autonomen Nervensystem. *Z. mikr.-anat. Forsch.* **18,** 233.

LAWRENTJEW, B. J. (1934) Experimentell-morphologische Studien über den feineren Bau des autonomen Nervensystems. IV. Weitere Untersuchungen über die Degeneration und Regeneration der Synapsen. *Z. mikr.-anat. Forsch.* **35,** 71.

LAWRENTJEW, B. J. and GURWITSCH-LASOWSKAJA, A. G. (1930) Zur Frage der Innervation des Atrioventricularbündels His–Tawaras bei Säugetieren. *Z. mikr.-anat. Forsch.* **21,** 585.

LAWRENTJEW, B. J. and NESSONOW, G. J. (1936) An attempt to form double synapses between sympathetic nerve cells. *Bull. Biol. Med. exp. USSR* 1, **89.**

LEE, R. (1849) On the ganglia and nerves of the heart. *Philos. Trans. I,* **43.**

LENCASTRE, A. DE (1943) Algunas observacaes sobre a innervacao do coracao humano. *Folia anat. (Coimbra)* **18,** 8, 1.

LEONTOWITSCH, A. W. (1929) Zur Frage über die Nervenendkörperchen im Herzen des Frosches. *Z. Zellforsch.* **9,** 277.

LEONTOWITSCH, A. W. (1930) Über die Ganglienzellen der Blutgefäße. *Z. Zellforsch.* **11,** 23.

LERICHE, R., FONTAINE, R. and KUNLIN, J. (1932) Étude expérimentale de la sensibilité, de l'épicarde et de l'endocarde. *C. R. Soc. Biol. (Paris)* **110,** 1.

LEWIS, T. 1925. *The mechanism and graphic registration of the heart beat.* Shaw Sons Ltd., London.

LIPP, W. (1951) Studien zur Herzinnervation I. Die Innervation der Pulmonalisklappen. *Acta anat. (Basel)* **13,** 30.

LISSAUER, M. (1909) Über die Lage der Ganglienzellen des menschlichen Herzens. *Arch. mikr. Anat.* **74,** 217.

LLOYD, W. (1930) The form and function of the auriculo-ventricular bundle in the rabbit. *Amer. J. Anat.* **45,** 379.

LÖWITT, M. (1882) Beiträge zur Kenntnis der Innervation des Herzens. *Pflügers Arch. ges. Physiol.* **29.**

LUCCHI, G. DE (1938) Contributo alla conoscenza della fina innervazione del pericardio. *Atti. Mem. Accad. Sci. Padova N. S.* **54,** 151.

LUDWIG, C. (1848) Über die Herznerven des Frosches. *Müllers Arch.* **139.**

MACKENZIE, J. (1910) The "nodal tissue" of the vertebrate heart. *J. Path.* **14,** 404.

MACKENZIE, J. (1910) Zur Frage des Koordinationssystems im Herzen. *Verh. dtsch. path. Ges.* **14,** 90.

MACKENZIE, J. 1913. *The excitatory and connecting muscular system of the heart.* 17. Internat. Med. Kongr.

MAKSUDOVA, M. A. (1936) Zur Frage über das morphologische Substrat der funktionellen Verbindung der autonomen Vagusfasern mit intramuralen Ganglienzellen des Herzens. *Anat. Anz.* **83,** 19.

MALL, E. P. (1912) On the development of the human heart. *Amer. J. Anat.* **13,** 211.

MARCUS, H. (1925) Über die Innervation des Herzmuskels. *Anat. Anz.* **59,** 145.

MARCUS, H. (1925) Über den feineren Bau des menschlichen Herzmuskels. *Z. Zellforsch.* **2,** 203.

MARMORSTEIN, M. (1930) Über gewisse topografisch-anatomische Besonderheiten der Herznerven beim Hunde und Kaninchen. *Z. Anat. Entwickl.-Gesch.* **93,** 734.

MARTINOFF, W. (1914) Die Nervenendapparate im Perikardium des Menschen und der Säugetiere. *Arch. mikr. Anat.* **84.**

MATSUO, Y. (1956) Histological study on the innervation of the heart of hedgehog. *Arch. hist. jap.* **11,** 341.

MCFARLAND and ANDERS (1913) The morbid histology of the cardiac nervous ganglia. *J. med. Res.* **27.**

MCQUEEN, J. M. (1913) Beobachtungen über das Herz eines Elasmobranchiers (Raja clavata). *Z. Biol.* **62,** 32.

MEIKLEJOHN, J. (1913) On the innervation of the nodal tissue of the mammalian heart. *J. Anat. Physiol.* **48,** 1.

MEIKLEJOHN, J. (1914) On the topography of the intracardiac ganglia of the rat's heart. *J. Anat. Physiol.* **48,** 378.

MEYER, R. DE (1952) Contribution à l'étude du tissu nodal du coeur des oiseaux. *Arch. Biol. (Liège)* **63,** 455.

MEYLING, H. A. (1948) The structure of autonomic nervous tissue in the right atrium of the heart in some mammals. *J. Anat. (Lond.)* **83,** 66.

MEYLING, H. A. (1953) Structure and significance of the peripheral extension of the autonomic nervous system. *J. comp. Neurol.* **99,** 495.

MEYLING, H. A. (1957) The conducting system of the heart in hoofed animals. *Cornell Veterinarian* **47,** 419.

MICHAILOW, S. (1907) Ein neuer Typus von eingekapselten sensiblen Nervenendapparaten. *Anat. Anz.* **31.**

MICHAILOW, S. (1908) Das intracardiale Nervensystem des Frosches und die Methode von Ramón y Cajal. *Int. Mschr. Anat. Physiol.* **25,** 351.

MICHAILOW, S. (1908) Zur Frage über den feineren Bau des intracardialen Nervensystems der Säugetiere. *Internat. Mschr. Anat. Physiol.* **25,** 44.

MICHAILOW, S. (1911) Die Nerven des Myokardiums und experimentelle Untersuchungen an vagotomierten Tieren. *Folia neurobiol. (Leipzig)* **5.**

MICHAILOW, S. (1912) Innervation des Herzens im Lichte der neuesten Forschungen. *Z. wiss. Zool.* **99,** 539.

MILLER MALCOLM, R. and KASAHARA, M. (1964) Studies on nerve endings in the heart. *Amer. J. Anat.* **115,** 217.

MILLS, T. W. (1886) The heart of the fish compared with that of Menobranchus with special reference to reflex inhibition and independent cardiac rhythm. *J. Physiol. (Lond.)* **7,** 81.

MINKER, E. and ÁBRAHÁM, A. (1958) Vagotomische Untersuchungen an Katzen. *Acta Biol. Univ. Szeged* **4,** 115.

MITCHELL, G. A. G. (1949) The discoverers of the thoracic cardiac nerves. *Edinb. med. J.* **56,** 156.

MITCHELL, G. A. G. (1950) The nerve supply of the kidney. *J. Anat. (Lond.)* **84,** 70.

MITCHELL, G. A. G. (1951) The intrinsic renal nerves. *Acta anat. (Basel)* **13,** 1—15.

MITCHELL, G. A. G. (1953) Visceral nerves demonstrated by combined intravital and supravital techniques. *Acta anat. (Basel)* **18,** 81.

MITCHELL, G. A. G. (1953) The innervation of the heart. *Brit. Heart. J.* **15,** 159.

MITCHELL, G. A. G., BROWN, R. and COOKSON, F. B. (1953) Ventricular nerve cells in mammals. *Nature (Lond.)* **172,** 812.

MITCHELL, G. A. G. (1955) Cardiac innervation. *Manch. Univ. Med. Sch. Gaz.* **34,** 61.

MITCHELL, G. A. G. 1956. *Cardiovascular innervation.* E. and S. Livingstone Ltd., Edinburgh–London.

MITCHELL, G. A. G. 1956. *Anatomy of the autonomic nervous system.* E. and S. Livingstone Ltd., Edinburgh–London.

MIZERES, N. J. (1955) Isolation of the cardioinhibitory branches of the right vagus nerve in the dog. *Anat. Rec.* **123,** 437.

MOHR, E. (1954) Localisation histochimique des cholinestérases du coeur. *C. R. Soc. Biol. (Paris)* **148,** 629.

MOHR, E. and GEREBTZOFF, M. A. (1954) Recherches histochimiques sur les acétylcholines et cholinestérases. 3. Localisation dans le coeur de Mammifère. *Acta anat. (Basel)* **22,** 143.

MOISSEJEFF, E. (1926) Zur Kenntnis des Carotissinus-Reflexes. *Z. ges. exp. Med.* **53,** 696.

MOLLARD, J. (1908) Les nerfs du coeur. *Rev. gén. Histol.* **3,** 79.
MÖNCKEBERG, J. G. 1908. *Untersuchungen über das Atrioventricularbündel im menschlichen Herzen.* G. Fischer, Jena.
MÖNCKEBERG, J. G. (1911) Beitrag zur normalen und pathologischen Anatomie des Herzens. *Verh. dtsch. path. Ges.* **13,** 66,
MÖNCKEBERG, J. G. (1921) Das spezifische Muskelsystem im menschlichen Herzen. *Erg. Path.* **19,** 328.
MÖNCKEBERG, J. G. 1926. *Handbuch der normalen und pathologischen Physiologie.* Springer, Berlin.
MÖNCKEBERG, J. G. 1924. *Die Erkrankungen des Myokards und des periferischen Muskelsystems.* In Lubarsch, O., Henke, F.: *Handbuch der speziellen Pathologie, Anatomie und Histologie.* **2,** 290.
MORIN, F. and BONIVENTO, E. (1940) Ricerche sull' innervazione del pericardio. *Arch. ital. Anat. Embriol.* **43,** 56.
MORISON, A. (1912) On the innervation of the sino-auricular node (Keith–Flack) and the auriculo-ventricular bundle (Kent–His). *J. Anat. (Lond.)* **46,** 319.
MUIR, A. R. (1954) The development of the ventricular part of the conducting tissue in the heart of sheep. *J. Anat. (Lond.)* **88,** 381.
MUIR, A. R. (1955) The sino-atrial node of the rat heart. *Quart. J. exp. Physiol.* **40,** 378.
MUIR, A. R. (1957) Observations on the fine structure of the Purkinje fibres in the ventricles of the sheep's heart. *J. Anat. (Lond.)* **91,** 251.
MÜLLER, L. R. (1911) Beiträge zur Anatomie, Histologie und Physiologie des Nervus vagus, zugleich ein Beitrag zur Neurologie des Herzens, der Bronchien und des Magens. *Dtsch. Arch. klin. Med.* **101,** 421.
MÜLLER, L. R. 1924. *Die Lebensnerven.* Springer, Berlin.
MURATORI, G. (1936) Il fondamento istologico recettore dei riflessi arteriosi pressocardio regolatori. *Atti. Soc. med.-chir. Padova* **14,** 1.
MURATORI, G. (1937) Osservazioni istologiche e considerazioni embriologiche dei recettori aortici degli Amnioti. *Anat. Anz.* **83,** 367.
MURATORI, G. (1937) Contributi morphologici allo studio dei recettori aortico-arteriosi dei riflessi cardio pressoregolatori. *Arch. ital. Anat. Embriol.* **38,** 387.
MUZJ, A. (1913) Sulle espansioni nervose del cuore. *G. int. Sci. med.* **35,** 586.
NAGAYO, M. (1910) Der Glykogenbefund des Sinusknotens. *Mitt. med. Ges. Tokyo* 126.
NAMES, TH. N. (1965) Anatomy of the sinus node, atrio-ventricular node and os cordis of the beef heart. *Anat. Rec.* **153,** 361.
NANDY, K. and BOURNE, G. H. (1963) A study of the conducting tissue in mammalian hearts. *Acta anat. (Basel)* **53,** 217.
NEIL, E. and ZOTTERMAN, Y. (1950) Cardiac vagal afferent fibres in the cat and the frog. *Acta physiol. scand.* **20,** 160.
NEUBAUER, J. E.: 1786. *Opera anatomica collecta.* I. C. Krieger Jr. Francofurti et Lipsiae.
NETTLESHIP, W. A. (1936) Experimental studies on the afferent innervation of the cat's heart. *J. comp. Neurol.* **64,** 115.
NONIDEZ, J. F. (1939) Studies on the innervation of the heart. I. Distribution of the cardiac nerves with special reference to the identification of the sympathetic and parasympathetic postganglionics. *Amer. J. Anat.* **65,** 361.
NONIDEZ, J. F. (1941) Studies on the innervation of the heart. II. Afferent nerve endings in the large arteries and veins. *Amer. J. Anat.* **68,** 151.
NONIDEZ, J. F. (1943) The structure and innervation of the conductive system of the heart of the dog and rhesus monkey as seen with a silver impregnation technique. *Amer. Heart. J.* **26,** 577.
OETS, J. (1950) Electrocardiograms of fishes. *Physiol. Comp. Oecol.* **2,** 181.
OKADA, G. (1931) Über die motorische Nervenendigung im Herzmuskel beim Kaninchen. *Okayama Igakkai Zasshi* **43,** 397.
OKAMURA, CH. (1929) Über die Ganglienzellen in der Herzwand. *Z. Anat. Entwickl.-Gesch.* **89,** 344.
OPENCHOWSKY, T. von (1883) Beitrag zur Kenntnis der Nervenendigungen im Herzen. *Arch. mikr. Anat.* **22,** 408.
OPPENHEIMER, B. G. and OPPENHEIMER, A. (1912) Nerve fibrils in the sino-auricular node. *J. exp. Med.* **16.**
OSTLUND, E. (1954) The distribution of catecholamines in lower animals and their effect on the heart. *Acta physiol. scand.* **31,** (Suppl. 1), 112.
PAINTAL, A. S. (1953) A study of right and left atrial receptors. *J. Physiol. (Lond.)* **120,** 596.

PAINTAL, A. S. (1955) A study of ventricular receptors and their role in the Bezold reflex. *Quart. J. exp. Physiol.* **40,** 348.

PALUMBI, G. (1940) La fine innervazione del nodo seno-atriale in Talpa europaea. *Boll. Soc. ital. Biol. sper.* **15,** 234.

PALUMBI, G. and VERGA, G. (1940) La fine innervazione del nodo seno-atriale in Talpa europaea. *Arch. ital. Anat. Embriol.* **43,** 119.

PANNESE, E. (1955) Osservazioni istochimiche sull' apparecchio di conduzione cardiaco. *Acta histochem. (Jena)* **2,** 102.

PANNIER, R. (1935) Notes générales sur le système ganglionnaire du coeur. *C. R. Soc. Biol. (Paris)* **120.**

PANNIER, R. (1940) Contribution à l'étude de l'innervation presso- et chémosensible des oreillettes et des vaisseaux de la base du coeur. *Arch. int. Pharmacodyn.* **64,** 476.

PARKER, F. (1958) An electron microscope study of coronary arteries. *Amer. J. Anat.* **103,** 247.

PERMAN, E. (1924) Anatomische Untersuchungen über die Herznerven bei den höheren Säugetieren und beim Menschen. *Z. Anat. Entwickl.-Gesch.* **71,** 382.

PERMAN, E. (1924) Zur Depressorfrage. *Z. Anat. Entwickl.-Gesch.* **75,** 263.

PIANESE, G. (1892) I nervi le reti e le terminazioni nervose del pericardio e il dolere nella pericardite. *Giorn. internat. d. Scienze med.* **14,** 1.

PICK, J. (1959) Some comments on the carotid sinus and other vascular reflexes. *Amer. Pract. Digest. Treatm.* **10,** 451.

PISSKUNOFF, N. N. (1911) Zur Frage nach den Ganglien in den Herzkammern von Vögeln. *Anat. Anz.* **38,** 394.

PLECHKOVA, E. K. (1936) On the morphology of the antagonistic innervation of the heart. Preliminary communication. *Bull. Biol. Méd. exp.* **1,** 402.

PLECHKOVA, E. K. (1948) Die Receptoren des Myocards und der Coronargefäße. In: Die Morphologie der sensorischen Innervation der inneren Organe. *Akad. Med. Nauk. SSSR.* **46.**

PRAKASH, R. (1957) Structure, development and phylogeny of the impulse conducting (connecting) tissue of the vertebrate heart. *J. anat. Soc. India* **6,** 65.

PREYER, J. (1932) Über die Wirkungsweise der Herznerven bei den Fischen. *Z. vergl. Physiol.* **18,** 1.

PURKINJE, J. E. (1845) Mikroskopisch-neurologische Beobachtungen. *Müllers Arch. Anat. Physiol.* **12,** 281.

RANVIER, L. 1880. *Appareils nerveux terminaux des muscles de la vie organique. Coeur sanguin.* Collège de France, Paris.

RAWLINSON, H. E. (1931) The latter development of the sinus venosus and the relation of the sino-atrial node to it in the calf heart. *Anat. Rec.* **49,** 79.

REMAK, R. (1839) Über die Ganglien der Herznerven des Menschen und deren physiologische Bedeutung. *Wschr. ges. Heilk.* **10,** 149.

REMAK, R. (1844) Neurologische Erläuterungen. *Müllers Arch. Anat. Physiol.* **463.**

RENON, E. and GÉRAUDEL, E. (1913) Recherche du noeud de Keith et Flack et du faisceau de His en fibrilles élastiques. *C. R. Soc. Biol. (Paris)* **27.**

RETZER, R. (1907) Some results of recent investigations on the mammalian heart. *Anat. Rec.* **1.**

RETZIUS, G. (1892) Über den Typus der sympathischen Ganglienzellen der höheren Tiere. *Biol. Untersuchungen. Neue Folge* **3,** 57.

RETZIUS, G. (1892) Zur Kenntnis der motorischen Nervenendigungen. Die motorischen Nervenendigungen im Herzen. *Biol. Untersuchungen.* Neue Folge **3,** 50.

REYNIER, P. 1880. *Des nerfs du coeur.* Parent, Paris.

RIPPLINGER, J. (1951) Recherches sur le centre d'initiation des contractions cardiaques chez les Poissons et ses rapports avec l'innervation extrinsèque du coeur. *C. R. Soc. Biol. (Paris)* **145,** 1189.

ROBB, J. S. (1953) Specialized (conducting) tissue in the turtle heart. *Amer. J. Physiol.* **178,** 7.

ROHNSTEIN, O. (1900) Zur Frage nach dem Vorhandensein von Nerven an den Blutgefässen der grossen Nervencentren. *Arch. mikr. Anat.* **55,** 86.

ROSKAM, J. (1919) La pulsation du coeur chez l'Anguille. *Arch. Int. Physiol.* **15,** 116.

ROSSI, L. (1954) Sistema nervoso settale e conduzione atrio-ventriculare. *Biol. lat. (Milano)* **7,** 894.

ROSSI, L. 1954. *Sistema di conduzione e nervi nel cuore dell'uomo.* Casa Editrice Ambrosiana, Milano.

Rossi, L. (1955) Atrioventricular conduction system and nerves in the human heart. *Sci. med. ital.* **3,** 514.

Rossi, L. (1955) Système de conduction et nerfs dans le coeur humain. *Sci. med. ital.* **3,** 540.

Rossi, L. (1955) Reizleitungssystem und Nerven des Herzens beim Menschen. *Sci. med. ital.* **3,** 543.

Rossi, L. (1955) Immagini della periferia neurovegetativa nella regione de nodo de Tawara umano. *Atti. Soc. ital. Pat.* **4,** 617.

Rossi, L. (1955) I fondamenti anatomo-patologici del blocco atrioventricolare. *Biol. lat. (Milano)* **8,** 1069.

Rossi, L. (1960) Sistema nervoso e di conduzione nel cuore senile. *G. Geront.* **23,** (Suppl.) 75.

Rothberger, J. and Winterberg, H. (1910) Über die Beziehungen der Herznerven zur atrioventriculären Automatic. *Pflügers Arch. ges. Physiol.* **135,** 559.

Saccomanno, G. (1943) The components of the upper thoracic sympathetic nerves. *J. Comp. Neurol.* **79,** 355.

Sappey, Ph. C. 1872. *Traité d'anatomie descriptive.* 2e ed. Vol. III. Névrologie, Organes des sens. A. Delahaye, Paris.

Sato, H. (1954) Innervation of heart in dog. *Tohoku J. exp. Med.* **59,** 343.

Sato, K. (1920) A study of nerve endings in the heart muscle of man. *Shinshu Igaku Zasshi* **19.**

Scaglia, G. (1927) L'apparato nervoso contenuto nel sistema atrio-ventricolare di Bos taurus. *Arch. ital. Anat. Embriol.* **24,** 658.

Scarpa, A. 1794. *Tabulae Neurologicae ad Illustrandam Historiam Cardiacorum Nervorum, Noni Nervorum Cerebri, Glossopharyngaei et Pharyngaei ex Octavo Cerebri. J. B. Comini,* Ticini.

Schaefer, H. (1950) Electrophysiologie der Herznerven. *Ergebn. Physiol.* **46,** 71.

Schiebler, T. H. (1953) Histochemische Untersuchungen der Purkinjefasern von Säugern. *Z. Zellforsch.* **39,** 152.

Schiebler, T. H. (1955) Histologische, histochemische und experimentelle Untersuchungen am Atrioventricularsystem von Huf- und Nagetieren. *Z. Zellforsch.* **43,** 243.

Schimert, J. (1937) Die Nervenversorgung des Myocards. *Z. Zellforsch.* **27,** 246.

Schumacher, S. v. (1902) Zur Frage der Herzinnervation bei den Säugetieren. *Anat. Anz.* **21,** 430.

Schumacher, S. v. (1902) Die Herznerven der Säugetiere und des Menschen. *Sitzungsber. Akad. Wien. Mathem. Naturw. Kl.* **3,** 111.

Schumacher, S. v. (1924) Zur Depressorfrage. *Z. Anat. Entwickl.-Gesch.* **75,** 259.

Schurawlew, A. N. (1928) Die Herznerven des Hundes. *Z. Anat. Entwickl.-Gesch.* **86,** 655.

Schwalbe, G. 1881. *Lehrbuch der Neurologie.* E. Besold, Erlangen.

Sciacea, A. (1953) Studio morphologico della disposizione e della variazione quantitativa del tessuto specifico in seno al tronco commune de fascio di Paladino–His. *Arch. Ital. Anat. Embr.* **58,** 162.

Semenov, S. P. (1958) Über die postembryonale Entwicklung der Herzhofrezeptoren der Katze. *Z. mikr.-anat. Forsch.* **63,** 672.

Serfaty, A. and Raynauc, P. (1957) Réflexe aéro-cardiaque chez la Truite de rivière (Salmo trutta L.) *J. Physiol. (Paris),* **49,** 378.

Seto, H. (1935) Über zwischen Aorta und Arteria pulmonalis gelegene Herzparaganglien. *Z. Zellforsch.* **22,** 213.

Seto, H. (1936) Mikroskopische Studien zur Innervation des menschlichen Herzens. *Arb. anat. Inst. Sendia* **19,** 1.

Seto, H. (1937) Über die afferenten Nerven im Aortenbogen und im Herzen beim Menschen im Hinblick auf die Aorten- und Herzreflexe. *Arb. anat. Inst. Sendai* **20,** 1.

Seto, H. 1963. *Studies on the sensory innervation (human sensibility).* Igaku Shoin, Tokyo, Ch. C. Thomas, Springfield, Ill.

Shaner, R. F. (1930) The development of the atrioventricular node, bundle of His, and sino-atrial node in the calf, with a description of a third embryonic node-like structure. *Anat. Rec.* **44,** 85.

Sjöstrand, F. S., Andersson-Cedergren, E. and Dewey M. M. (1958) The ultrastructure of the intercalated discs of frog, mouse and guinea pig cardiac muscle. *J. Ultrastruct. Res.* **1,** 271.

Skramlik, E. (1931) Untersuchungen über die Herztätigkeit. *Z. vergl. Physiol.* **14,** 675.

Skramlik, E. (1932) Über die Wirkungsweise der Herznerven bei den Fischen. I, II. *Z. vergl. Physiol.* **10,** 344. (1929) **16,** 489.

Skramlik, E. (1935) Über den Kreislauf bei den Fischen. *Ergebn. Biol.* **11,** 1.

SMIRNOW, A. E. (1890) Die Struktur der Nervenzellen im Sympathicus der Amphibien. *Arch. mikr. Anat.* **25,** 407.

SMIRNOW, A. E. (1895) Über die sensiblen Nervenendigungen im Herzen bei Amphibien und Säugetieren. *Anat. Anz.* **10,** 23.

SMIRNOW, A. E. (1900) Zur Frage von der Endigung der motorischen Nerven in den Herzmuskeln der Wirbeltiere. *Anat. Anz.* **18,** 105.

SMIRNOW, A. E. (1905) Einige Bemerkungen über die Existenz von Ganglienzellen in den Herzventrikeln des Menschen und einiger Säugetiere. *Arb. anat. Inst. Wiesbaden* **27,** 297.

SOBOTTA, J. and MCMURRICH, J. P. 1907. *Atlas and text-book of human anatomy.* W. B. Saunders Co. Philadelphia.

SPALTEHOLZ, W. 1924. *Die Arterien der Herzwand. Anatomische Untersuchungen an Menschen- und Tierherzen.* S. Hirzel, Leipzig.

SPERELAKIS, N., HOSHIKO, T. and BERNE, R. M. (1960) Nonsyncytial nature of the cardiac muscle membrane resistance of single cells. *Amer. J. Physiol.* **198,** 531.

SSINELNIKOW, R. (1928) Die Herznerven der Vögel. *Z. Anat. Entwickl.-Gesch.* **86,** 540.

SSINELNIKOW, R. (1928) Das intramurale Nervensystem des Vogelherzens. *Z. Anat. Entwickl.-Gesch.* **86,** 563.

STANNIUS, F. H. 1849. *Das peripherische Nervensystem der Fische.* Rostock.

STARLING, E. H. 1918. "*The Law of the Heart*". Linacre Lecture, London.

STEFANELLI, A. (1929) Le piastre motrici a grappolo e loro significato con considerazioni sulle espansioni motrici del miocardio. *Arch. ital. Anat. Embriol.* **27,** 180.

STÖHR, PH. 1928. *Nervensystem.* In W. MÖLLENDORFF: *Handbuch der mikroskopischen Anatomie des Menschen.* IV/1. Springer, Berlin.

STÖHR, PH. 1932. *Nerves of the blood vessels, heart, meninges, digestive tract and urinary bladder.* P. B. Hoeber, J. W. Penfield, NewYork.

STÖHR, PH. 1957. *Mikroskopische Anatomie des vegetativen Nervensystems.* In W. MÖLLENDORF: *Handbuch der mikroskopischen Anatomie des Menschen.* IV/5. Springer, Berlin–Göttingen–Heidelberg.

STOTLER, W. A. and MCMAHON, R. A. (1947) The innervation and structure of the conductive system of the human heart. *J. comp. Neurol.* **87,** 57.

STRICHT, O. and VAN DER TODD, T. W. (1919) The structure of normal fibres of Purkinje in the adult human heart and their pathological alteration in syphilitic myocarditis. *Johns Hopk. Hosp. Rep.* **19,** 1.

SUMMERFIELD, T. K. and COAKLEY J. B. (1958) The intrinsic nerve cells of the cardiac atria of mammals and man. *J. Anat. (Lond.)* **92,** 353.

SUNDER-PLASSMANN, P. (1933) Über neuro-vegetative Receptorenfelder im Kreislaufregulationsmechanismus und durch deren Ausschaltung experimentell erzeugte, morphologisch faßbare Veränderungen im sympathischen Nervensystem. *Z. ges. Neurol. Psychiat.* **147,** 414.

SUTULOV, L. S. and SUTULOV, G. L. (1960) Reactivity and plasticity of nervous tissue in experimental conditions. *Anat. Rec.* **136,** 286.

SWAN, J. 1830, 1834. *The nerves of the human body* (Revised ed. 1834). Longman, Rees, Orme, Brown, Green and Longman, London.

SZENTÁGOTHAI, J., DONHOFFER, A. and RAJKOVITS, K. (1955) Die Lokalisation der Cholinesterase in der interneuronalen Synapse. *Acta histochem. (Jena)* **1,** 272.

TANDLER, J. 1913. *Anatomie des Herzens.* In BARDELEBEN: *Handbuch der Anatomie.* G. Fischer. Jena.

TANG, E. (1922) Beiträge zum feineren Bau der Purkinjeschen Fasern im Herzen der Vögel. *Anat. Anz.* **55,** 385.

TARDIEU, G. and TARDIEU, C. 1948. *Le système nerveux végétatif.* Masson et Cie, Paris.

TAWARA, S. 1906. *Das Reizleitungssystem des Säugetierherzens.* G. Fischer, Jena.

TCHENG, K. T. (1949) Caractères des fibres de l'innervation cardiaque chez les mammifères. *Arch. Sci. med.* **2,** 368.

TCHENG, K. T. (1949) Innervation sensitive du noeud auriculo-ventriculaire de Tawara chez l'agneau. *Cardiologia (Basel)* **14,** 290.

TCHENG, K. T. (1949) Innervation du faisceau de His chez l'agneau *C. R. Soc. Biol. (Paris)* **143,** 1559.

TCHENG, K. T. (1950) Innervation du myocarde et du faisceau de His chez deux mammifères, le mouton et le chat. *Cardiologia (Basel)* **15,** 227.

TCHENG, K. T. (1950) Étude histologique de l'innervation cardiaque chez le chien. *C. R. Soc. Biol. (Paris)* **144,** 882.

TCHENG, K. T. (1950) Innervation du myocarde ventriculaire chez le chat nouveau-né. *C. R. Soc. Biol. (Paris)* **144,** 162.

TCHENG, K. T. (1951) Innervation of the dog's heart. *Amer. Heart. J.* **41,** 512.

TCHENG, K. T. (1951) Synapses interneuronales dans les ganglions cardiaques. *Acta Anat. (Basel)* **11,** 431.

TESTUT, L. 1929. *L'Anatomie Humaine.* Huitième édition **12,** Paris.

TESTUT, L. and LATARJET, A. 1948. *Traité d'anatomie humaine.* 2, G. Doin et Cie. Paris.

THANE, G. D., 1895. Quain's "*Elements of anatomy*". Tenth edition. vol. III. Part. 2. London. Longmans, Green et Co.

THESEN, J. (1896) Étude sur la biologie du coeur des Poissons osseux. *Arch. Zool. exp. gén.* **3,** 122.

TINEL, J. 1937. *Le système nerveux végétatif.* Masson et Cie, Paris.

TRUEX, R. C. and COPENHAVER, W. M. (1947) Histology of the moderator band in man and other mammals with special reference to the conduction system. *Amer. J. Anat.* **80,** 173.

TRUEX, R. C. (1959) Chromaffin tissue of the sympathetic ganglia and heart. *Anat. Rec.* **108,** 687.

TRUEX, R. C., NOLAN, F. G., TRUEX, R. C. JR., SCHNEIDER, H. P. and PERLMUTTER, H. I. (1961) Anatomy and pathology of the whale heart with special reference to the coronary circulation. *Anat. Rec.* **141,** 325.

TSCHERWOWA, I. A. (1955) Über die Nervenapparate der rechten und linken Herzvorkammer. *Dokladi Nauk SSSR* **103,** 321, (1955) **103,** 709.

TSUNODA, T. and KASAHARA, I. (1928) Vergleichend-anatomische Studien über die Nervenendigungen des Herzmuskels, sowie über die Nervenversorgung des spezifischen Herzmuskelgewebes. *Z. Zellforsch.* **7,** 177.

TUFTS, J. M. (1922) Some observations upon the structure of the Purkinje fibres. *Anat. Rec.* **22,** 363.

TUMANZEW, A. and DOGIEL, J. (1890) Zur Lehre über das Nervensystem des Herzens. *Arch. mikr. Anat.* **36,** 483.

UNGAR, R., (1924) Zur Anatomie der spezifischen Muskelsysteme im Menschenherzen. *Lotos. Prag.* **72,** 209.

VAJDA, J. (1966) Innervation of lymph vessels. *Acta morph. Acad. Sci. hung.* **14,** 197.

VALEDINSKY, A. (1905) Zur Frage über die Nervenknoten im Herzventrikel einiger Säugetiere. *Anat. Hefte* **27,** 287.

VALEDINSKY, A. (1910) Einige Ergänzungen zur Frage nach der Gegenwart und der Verteilung der Herzganglien in den Herzkammern einiger Säugetiere und des Menschen. *Anat. Anz.* **37,** 465.

VALENTIN, G. G. 1843. *Traité de névrologie. Vol. IV. of Encyclopédie Anatomique* (Transl. by A. J. L. JOURDAN). J. B. Baillière, Paris.

VERGA, G. (1942) Osservazioni nella innervazione del sistema di connessione seno-atriale ed atrioventricolare del cuore dei mammiferi. *Arch. ital. Anat. Embriol.* **47,** 854.

VERMES, E. (1925) Makroskopisch-anatomische Untersuchungen an Elefant- und Nilpferdherzen. Ein Beitrag zur vergleichenden Anatomie des Reizleitungssystems des Säugetierherzens. *Anat. Anz.* **60,** 11, 241.

VESALIUS, A. 1543. *De humani generis fabrica.* J. Oporinum, Basiliae.

VIEUSSENS, R. 1716. *Neurographia universalis.* J. Certe, Lugduni.

VIGNAL, W. (1881) Recherches sur l'appareil ganglionnaire du coeur des Vertébrés. *Arch. Physiol. norm. path.* **8,** 694.

VIRÁGH, SZ. and PORTE, A. (1961) Structure fine du tissu nerveux dans le coeur du rat. *Z. Zellforsch.* **55,** 263.

VIRÁG, SZ. and PORTE, A (1961) Éléments nerveux intra-cardiaques et innervation du myocarde. *Z. Zellforsch.* **55,** 282.

VITALI, G. (1937) Contributo allo studio del sistema muscolare specifico del cuore. Le espansioni nervose nelle fibre di Purkinie in Ovis aries. *Anat. Anz.* **84,** 88.

WAHLIN, B. 1935. Das Reizleitungssystem und die Nerven des Säugetier-Herzens. Inaug. Diss. Uppsala.

WALLS, E. B. (1942) Specialized conducting system in the heart of the golden hamster (Cricetus auratus) *J. Anat. (Lond.)* **76,** 4.

WALTER, J. G. 1783. *Tabulae nervorum thoracis et abdominis.* G. J. Deckeri, Berolini.

WALTER, J. G. 1819. *Plates of the thoracic and abdominal nerves* (reduced from the original "*Tabulae nervorum thoracis et abdominis*", 1783). Burgess and Hill, London.

WEBER, A. (1950) Résultats de différentes techniques dans l'étude de l'innervation du coeur des mammifères. *Cardiologia (Basel)* **15,** 223.

WEARN, J. T., ZSCHIESCHE, L. S. (1928) The extent of the capillary bed of the heart. *J. exper. Med.* **47,** 273.

WEBER, A. (1955) Aspects microscopiques nouveaux du tissu nerveux, fournis par la technique d'imprégnation argentique utilisée à l'Institut d'Anatomie de Genève. *Rev. neurol.* **93,** 817.

WEBER, E. H. 1815. *Dissertatio inuguralis medica de anatomia comparata nervi sympathici.* C. H. Reclam, Lipsiae.

WENSING, C. J. G. (1965) Innervation des atrioventriculären Reizleitungssystems beim Schwein. *Zbl. Vet.-Med.* **12,** 531.

WHITTERIDGE, D. (1948) Afferent nerve fibres from the heart and lungs in the cervical vagus. *J. Physiol. (Lond.)* **107,** 496.

WILLIS, T. 1664. *Cerebri anatome, cui accessit nervorum descriptio et usus.* J. Flesher. Londini.

WILSON, J. G. (1909) The nerves of the atrio-ventricular bundle. *Proc. roy. Soc. B.* **81,** 151.

WITT, L. DE (1909) Observations on the sino-ventricular connecting system of the mammalian heart. *Anat. Rec.* **3,** 475.

WOLHYNSKI, F. A. (1926) Innervation des Herzkammer- und Vorhofsseptums des Kalbes. *Z. Anat. Entwickl.-Gesch.* **86,** 608.

WOLHYNSKI, F. A. (1928) Die Herznerven des Kalbes. *Z. Anat. Entwickl.-Gesch.* **86,** 579.

WOLLARD, H H (1926) The innervation of the heart. *J. Anat. (Lond.)* **60,** 345.

WOROBIEW, W. P. 1917. *Zur Topographie der Nervenstämme und Ganglien des Herzens beim Menschen.* Charkow.

WOROBIEW, W. P. (1925) Die Nerven des menschlichen und tierischen Herzens. *Münch. med. Wochenschr.* **2,** 1440.

YOKOCHI, K. (1925) Demonstrationen der Ganglienzellen im Herzen verschiedener Wirbeltiere. *Jap. J. med. Sci.* **2,** 62.

YOUNG, J. Z. (1931) On the autonomic nervous system of Teleostean fish (Uranoscopus scaber). *Quart. J. micr. Sci.* **74,** 491.

YOUNG, J. Z. (1933) The autonomic nervous system of Selachians. *Quart. J. micr. Sci.* **75,** 571.

ZIMMERMANN, A. (1923) Adatok a szívizomzat ingervezető rendszerének összehasonlító anatómiájához (Contributions to the comparative anatomy of the impulse conducting system of the heart muscles). *Math. Term. Tud. Ért.* **40,** 38.

ZITZLSPERGER, S. (1943) Interstitielle Zellen (Cajal) im Papillarmuskel des menschlichen Herzens. *Z. mikr.-anat. Forsch.* **53,** 1.

ZLABEK, K. (1934) Contribution à la connaissance de la structure du myocarde des Poissons. *C. R. Soc. Biol. (Paris)* **117,** 178.

The Blood Vessels

ÁBRAHÁM, A. (1930) Die Innervation des Darmkanals der Gastropoden. *Z. Zellforsch.* **30,** 273.

ÁBRAHÁM, A. (1936) Beiträge zur Kenntnis der Innervation des Vogeldarmes. *Z. Zellforsch.* **23,** 737.

ÁBRAHÁM, A. (1938) Über die mikroskopische Innervation der Gaumenschleimhaut der Frösche. *Z. Zellforsch.* **27,** 745.

ÁBRAHÁM, A. (1940) Gibt es Nervennetze? *Z. Zellforsch.* **30,** 273.

ÁBRAHÁM, A. (1941) Receptorok a sinus caroticus falában (Receptors in the wall of the sinus caroticus). *Állattani Közl.* **38,** 179.

ÁBRAHÁM, A. (1942) Über das Nervensystem des Glomus caroticum beim Menschen. *Acta zool. Univ. Szeged* **1,** 32.

ÁBRAHÁM, A. (1943) Idegvégtestek az arteria renalis falában (Nerve end organs in the wall of the renal artery). *Állattani Közl.* **40,** 242.

ÁBRAHÁM, A. (1945) Pressoreceptorok az aortaívben (Pressoreceptors in the aortic arch). *Állattani Közl.* **42,** 14.

ÁBRAHÁM, A. (1949) Receptors in the wall of the blood vessels. *Acta biol. Acad. Sci. hung.* **1,** 157.

ÁBRAHÁM, A. (1949) Beiträge zur Kenntnis der sensiblen Endorgane der Sinusreflexe von Hering. *Z. Zellforsch.* **34,** 208.

ÁBRAHÁM, A. (1950) The innervation of the blood vessels. *Acta morph. Acad. Sci. hung.* **1,** 250.

ÁBRAHÁM, A. (1951) Die intramuralen Nerven der Kranzgefäße. *Acta zool. Univ. Szeged* **3,** 13.

ÁBRAHÁM, A. (1951) Further investigations on the structure and the endings of the nervus depressor in man. *Acta biol. Acad. Sci. hung.* **1,** 165.

ÁBRAHÁM, A. (1951) The comparative histology of the stellate ganglion. *Acta biol. Acad. Sci. hung.* **2,** 311.

ÁBRAHÁM, A. (1951) The endings of the nervus acusticus in the labyrinth of the carp. *Z. Zellforsch.* **35,** 396.

ÁBRAHÁM, A. (1952) Az aortaideg szerkezete és végződésformái a kutya artériás törzseiben (Structure and endings of the nervus aorticus in the arterial trunks of the dog). *Ann. biol. Univ. hung.* **1,** 325.

ÁBRAHÁM, A. (1953) Die Innervation der Blutgefäße. *Acta biol. Acad. Sci. hung.* **4,** 69.

ÁBRAHÁM, A. (1953) Blood pressure and peripheral nervous system. *Acta biol. Acad. Sci. hung.* **4,** 307.

ÁBRAHÁM, A. (1955) Über die Stelle und Struktur der Rezeptoren im Aortenbogen des Rindes. *Acta biol. Univ. Szeged* **1,** 125.

ÁBRAHÁM, A. (1956) Über die Struktur und die Endigungen der Aorticusfasern im Aortenbogen des Menschen mit Berücksichtigung der Cholinesterase-Aktivität der Pressorezeptoren. *Z. mikr.-anat. Forsch.* **62,** 194.

ÁBRAHÁM, A. (1958) Beiträge zur Kenntnis der Interoceptoren im Bereiche des cardiovaskulären Systems. *Acta biol. Univ. Szeged* **4,** 179.

ÁBRAHÁM, A. (1958) Die mikroskopische Innervation der Niere des Varanus griseus Daud. *Z. mikr.-anat. Forsch.* **64,** 296.

ÁBRAHÁM, A. (1958) The microscopical innervation of the reflexogenic areas in the mammal's arterial system. *15th. Int. Congress. of Zool. London,* 27.

ÁBRAHÁM, A. 1959. *Morphologische Grundlagen der nervalen Nierenregulation 3—38.* In H. Dutz': *Nierenfunktion und Nervensystem.* VEB Verlag Volk und Gesundheit, Berlin.

ÁBRAHÁM, A. (1959) Zur Frage der interneuronalen Synapsen in den vegetativen Ganglien. *Z. mikr.-anat. Forsch.* **65,** 574.

ÁBRAHÁM, A. (1961) Struktur und Endigungsformen der Fasern des Nervus aorticus im Aortenbogen des Schweines. *Z. mikr.-anat. Forsch.* **67.**

ÁBRAHÁM, A. and MINKER, E. (1958) Über die Innervation des Darmkanales des medizinischen Blutegels (Hirudo medicinalis). *Z. Zellforsch.* **47,** 367.

ÁBRAHÁM, A. and SIN, L. (1955) Microscopic innervation of fixed vascular grafts. *Acta morph. Acad. Sci. hung.* **5,** 103.

ÁBRAHÁM, A. (1965) Contributions to the knowledge of the nerve supply of human glomus caroticum. *Acta morph. Acad. Sci. hung. Suppl.* **13,** 46.

ÁBRAHÁM, A. (1966) Silberverfahren zur Imprägnation der Elemente des Nervensystems. *Z. wiss. Mikr.* **67,** 184.

ÁBRAHÁM, A. (1966) Electron microscopic studies of the human glomus caroticum. *Acta morph. Acad. Sci. hung.* **14,** 347.

ÁBRAHÁM, A. 1967. *The structure of baroreceptors in pathological conditions in men.* In Baroreceptors and Hypetension. 273. *Proceedings of an International Symposium held at Dayton. Ohio.* 16—17 *November* 1965. Oxford—New-York

ÁBRAHÁM, A. 1968. *Species characteristics in the structure of the nervous system in the carotid body.* In Torrance R. W., *Arterial Chemoreceptors, held in Oxford on* 18—21 *July* 1966. Blackwell Sci. Publ. Oxford—Edinburgh.

ADAMS, W. E. (1957) The carotid sinus reflex in the hedgehog (Erinaceus europaeus). *J. Anat. (Lond.)* **91,** 207.

ADAMS, W. E. 1958. *The comparative morphology of the carotid body and carotid sinus.* Charles C. Thomas. Springfield, Illinois.

ADAMS, W. E. (1962) The carotid sinus–carotid body problem in the Chelonia (with note on a foramen of Panizzae in Dermochelys). *Arch. int. Pharmacodyn.* **139,** 28.

ADDISON, W. H. F. (1939) On the histology of the mammalian carotid sinus. *Biol. Bull. Wood's Hole.* **77,** 314.

ADDISON, W. H. F. (1945) The arterial relations of the glomus caroticum in the rabbit. *Anat. Rec.* **91,** 264.

ADDISON, W. H. F. and COMROE, J. H. JR. (1937) The vascular relations of the glomus caroticum in the dog. *Anat. Rec.* **67,** (Suppl. 3), 2.

AGABABOW, A. (1892) Die Innervation des Ciliarkörpers. *Anat. Anz.* **8,** 555.

AGABABOW, A. (1912) Über die Nerven der Augenhäute. *Graefes Arch. Ophthalm.* **83,** 317.

Akkeringa, L. J. (1930) Die Lage der Neurofibrillen am peripheren Ende der Nervenbahn. *Z. mikr.-anat. Forsch.* **19,** 183.

Allan, F. D. (1955) The innervation of the human ductus arteriosus. *Anat. Rec.* **122,** 611.

Amoroso, E. C., Bell, F. R., King, A. S. and Rosenberg, H. (1951) The aortic and sinus nerves of the lion and badger. *J. Anat. (Lond.)* **85,** 411.

Andrzejewski, C. (1955) Histologische Studien zur vegetativen und cerebralen Innervation des Innenohres und seiner Gefäße beim Menschen und beim Hund. *Z. Zellforsch.* **42,** 1.

Anokhin, P. K. and Shumilina, A. I. (1962) Physiological peculiarities of aortic arch baroreceptor information on the state of blood pressure. *Arch. int. Pharmacodyn.* **140,** 1.

Antonescu, C. V. (1935) Innervation of the carotid sinus of dog. *Clujul med.* **16,** 348.

Appenzeller, O. (1964) Electron microscopic study of the innervation of the auricular artery in the rat. *J. Anat. (Lond.)* **98,** 87.

Ara, G. (1935) Ricerche sulla funzione del glomo carotideo. *Arch. Fisiol.* **33,** 325.

Argaud, R. (1928) Terminaisons nerveuses dans les artères. *C. R. Soc. Biol. (Paris)* **87,** 673.

Argaud, R. (1935) Structure du sinus carotidien chez le cheval. *Ann. Anat. path. med. chir.* **13,** 1035.

Argaud, R. (1941) Considération sur la signification anatomique du glomus carotidien. *Bull. Histol. Techn. micr.* **18,** 3.

Arnold, J. (1865) Über die Struktur des Ganglion intercaroticum. *Virchows Arch. path. Anat.* **33,** 190.

Arnold, J. 1871. *Das Gewebe der Organe. Muskeln.* In Stricker: *Handbuch der Gewebelehre.* Berlin.

Arnstein, C. (1887) Methylenblaufärbung als histologische Methode. *Anat. Anz.* **2,** 551.

Aronson, H. (1890) Über die Nerven und Nervenendigungen in der Pia mater. *Zbl. med. Wiss.* **28,** 594.

Aschoff, L. and Goodhard, G. (1909) Vorkommen von Paraganglien im peripherischen Stamm des N. vagus. *Dtsch. med. Wschr.* 1461.

Aszódi, Z. and Pauncz, L. (1923) Chemisches über die Zugehörigkeit der Carotisdrüsen zu dem Adrenalsystem. *Biochem. Z.* **136,** 159.

Awichow, S. V. and Tomilina, T. N. (1962) Reflexes from carotid chemoreceptors upon insulin level in blood. *Arch. int. Pharmacodyn.* **139,** 53.

Bachmann, R., Scharrer, E. and Scharrer, B. 1954. *Die Nebenniere. Neurosekretion.* In W. Möllendorf: *Handbuch der mikr. anat. des Menschen.* VI/5. Springer, Berlin.

Bakay, V. jr. (1941) Die Innervation der Pia mater, der Plexus chorioidei und der Hirngefäße mit Berücksichtigung des Einflusses des sympathischen Nervensystems auf die Liquorsekretion. *Arch. Psychiatr. Nervenkr.* **113,** 412.

Bakay, V. jr. (1942) Über die Nerven der Aorta ascendens. *Z. Anat. Entwickl.-Gesch.* **111,** 461.

Baldwin, F. M. (1919) Variation in the carotid arteries of the rabbit. *Anat. Rec.* **16,** 309.

Ballowitz, E. (1894) Vorkommen echter peripherischer Nervenendnetze. *Anat. Anz.* **9,** 165.

Ballowitz, E. (1899) Über polytome Nervenfaserteilung. *Anat. Anz.* **16,** 541.

Barbieri, N. A. (1898) L'innervation des artéries et des capillaires. *J. Anat. (Paris)* **34,** 5.

Bayliss, W. M. (1893) Physiology of depressor nerve. *J. Physiol. (Lond.)* **14,** 303.

Bayliss, W. M. (1899) Origin of the vaso-dilatator fibres. *J. Physiol. (Lond.)* **23,** Suppl.

Bayliss, W. M. (1900/1) Origin from spinal cord of vaso-dilatator fibres. *J. Physiol. (Lond.)* **26,** 173.

Bayliss, W. M. (1906) Innervation der Gefäße. *Ergebn. Physiol.* **5,** 322.

Bayliss, W. M. (1908) Reciprocal innervation in vaso-motor reflexes. *Proc. Roy. Soc. B.* **80,** 339.

Bayliss, W. M. 1923. *The vasomotor system.* Longmans, London.

Beale, L. S. (1864) On the ultimate distribution and function of fine nerve fibres. *Quart. J. micr. Sci.* **4,** 11.

Beale, L. S. (1872) Nerves and capillary vessels. *Phil. Trans. Roy. Soc. Lond. Monthly Micr. J.* **7,** 45.

Beaufays, J. (1937) Die Endausbreitung des vegetativen Nervengewebes in der gesunden Tube und seine Veränderungen bei Entzündungen der Tube. *Arch. Gynäk.* **164,** 624.

Becher, H. (1936) Über Wirkung und Bedeutung besonderer regulatorischer Einrichtungen an der arteriola afferens der menschlichen Niere. *Erg. H. Anat. Anz.* **83,** 134.

Bennett, H. S., Luft, J. H. and Hampton, J. C. (1957) Morphological classification of vertebrate blood capillaries. *Amer. J. Physiol.* **196,** 381.

BENNINGHOFF, A. (1926) Über die Formenreihe der glatten Muskulatur und die Bedeutung der Rougetschen Zellen an den Capillaren. *Z. Zellforsch.* **4,** 125.

BENNINGHOFF, A. 1930. *Blutgefäße.* In W. MÖLLENDORF: *Handbuch der mikroskopischen Anatomie des Menschen.* VI/1. I. Springer, Berlin.

BENNENGHOFF, A. 1933. *Gefäßsystem.* In L. BOLK, E. GÖPPERT: *Handbuch der vergleichenden Anatomie der Wirbeltiere.* VI. 375. Urban–Schwarzenberg, Berlin–Wien.

BERGER, H. (1924) Zur Innervation der Pia mater und der Gehirngefäße. *Arch. Psychiatr. Nervenkr.* **70,** 216.

BERGGLAS, B. (1925) Über die Nerven in der Adventitia der Arterien. *Z. Anat. Entwickl.-Gesch.* **77,** 481.

BERKELBACH VAN DER SPRENKEL, H. 1934. *Nebenniere und Paraganglien.* 2. 777. In Bolk, Göppert, etc. *Handbuch der vergleichenden Anatomie der Wirbeltiere.* Urban Schwarzenberg. Berlin—Wien.

BERSCH, A. (1954) Histologische Untersuchungen über den Ursprung des Nervus depressor in der Intima aortae des erwachsenen Kaninchens. *Z. mikr.-anat. Forsch.* **60,** 289.

BESTUGUINA, A. A. (1965) Some histological and histochemical characteristics of receptors of cerebral arteries. *Arch. Anat. Gistol. Embriol.* **49,** 34.

BETHE, A. (1895) Nervenendigungen im Gaumen und in der Zunge des Frosches. *Arch. mikr. Anat.* **44,** 185.

BETHE, A. 1903. *Allgemeinen Anatomie und Physilogie des Nervensystems.* G. Thieme, Leipzig.

BETHE, A. (1938) Gibt es bei Wirbeltieren Nervennetze? *Z. Zellforsch.* **28,** 412.

BEVAN, J. A. (1962) Action of lobeline and capsaicine afferent endings in the pulmonary artery of the cat. *Circulat. Res.* **10,** 792.

BHADURI, J. L. and BISWAS, B. (1954) The main cervical and thoracic arteries of birds. *Anat. Anz.* **100,** 337.

BIANCONI, R. and GREEN J. H. (1959) Pulmonary baroreceptors in the cat. *Arch. ital. Biol.* **97,** 305.

BINET, L. and DEJOURS, P. (1962) Le rôle des chemorécepteurs arteriels dans le contrôle de la respiration pulmonaire chez l'homme. *Arch. int. Pharmacodyn.* **139,** 318.

BOEKE, J. (1911) Beiträge zur Kenntnis der motorischen Nervenendigungen. *Intern. Mschr. Anat. Physiol.* **28,** 377.

BOEKE, J. 1922. *Zur Innervation der quergestreiften Muskelfasern bei den Ophidiern.* Libro en Honor R. y Cajal. Madrid.

BOEKE, J. (1927) Die morphologische Grundlage der sympathischen Innervation der quergestreiften Muskelfasern. *Z. mikr.-anat. Forsch.* **8,** 561.

BOEKE, J. (1930) Some remarks on the papers by H. J. WILKINSON on the innervation of the striped muscle fibres. *J. comp. Neurol.* **51,** 299.

BOEKE, J. (1932) Quelques remarques à propos de l'article de H. J. WILKINSON sur l'innervation du muscle strié. *Bull. Histol.* **8,** 100.

BOEKE, J. (1932) Some remarks on the efferent innervation of the blood vessels. *Proc. kon. ned. Akad. Wet.* **35,** 812.

BOEKE, J. (1932) Some observations on the structure and innervation of smooth-muscle fibres. *J. comp. Neurol.* **56,** 27.

BOEKE, J. (1933) Innervationsstudien IV. Die efferente Gefäßinnervation und der sympathische Plexus im Bindegewebe. *Z. mikr.-anat. Forsch.* **33,** 275.

BOEKE, J. 1933. *Problems of Nervous Anatomy.* Oxford Univ. Press, London.

BOEKE, J. (1936) Zur Nervenversorgung der Augenhäute. *Z. mikr.-anat. Forsch.* **39,** 477.

BOEKE, J. (1938) Sympathetic ground plexus and reticuline fibres. *Anat. Anz.* **86,** 150.

BOEKE, J. (1938) Über die Verbindung der Nervenzellen untereinander und mit den Erfolgsorganen. *Anat. Anz.* **85,** 111.

BOEKE, J. (1940) Sympathischer Grundplexus contra Terminalreticulum. *Acta neuroveg. (Wien)* **2,** 32.

BOISSEZON, P. 1942. *La zone réflexogène carotidienne. Étude anatomique et histologique.* Marqueste, Toulouse.

BOOKER, W. M., FISHER, E., CAFFEY, W. LINARES, R. and BRIANT, J. (1962) Studies on the secretion of catecholamines during carotid sinus reflex involvement. *Arch. int. Pharmacodyn.* **139,** 336.

BOROWSKAJA, A. J. (1935) Versuch einer Erforschung der Innervation der Blutgefäße mit der Methode der Degeneration der postganglionären Fasern des autonomen Nervensystems. *Arch. russ. Anat.* **14,** 474.

Boss, J. and Green, J. H. (1954) Nervous structures in recently described baroreceptor areas of the right common carotid artery in the cat. *J. Physiol. (Lond.)* **124,** 43.

Boss, J. and Green, J. H. (1954) The modification of the arterial wall in baroreceptor areas. *J. Physiol. (Lond.)* **125,** 42.

Boss, J. and Green, J. H. (1956) The histology of the common carotid baroreceptor areas of the cat. *Circulat. Res.* **4,** 12.

Botár, J. 1966. *The Autonomic Nervous System.* Akadémiai Kiadó, Budapest.

Botezat, E. (1882) Innervation der Blutkapillaren. *Z. mikr.-anat. Forsch.* **21,** 165.

Botezat, E. (1908) Über die Innervation der Blutkapillaren. *Anat. Anz.* **32,** 394.

Boucek, R. J., Takashita, R. and Fojaco, R. (1963) Relation between microanatomy and functional properties of the coronary arteries (dog). *Anat. Rec.* **147,** 200.

Boucek, R. J., Takashita, R. and Fojaco, R. (1964) Functional anatomy of the ascending aorta and the coronary ostia (dog). *Amer. J. Anat.* **114,** 273.

Boyd, J. D. (1937) Observations on the human carotid sinus and its nerve supply. *Anat. Anz.* **84,** 386.

Boyd, J. D. (1941) The nerve supply of the mammalian ductus arteriosus. *J. Anat. (Lond.)* **75,** 457.

Boyd, J. D. and Lewis, P. R. (1957) The fine structure of the carotid body glomus cells in the rabbit. *J. Anat. (Lond.)* **91,** 594.

Braeucker, W. 1923. *Anatomische Untersuchungen des ganzen sympathischen Nervensystems.* Verhandl. 8. Tagung d. bayr. Chirurg. Juli.

Braeucker, W. (1927) Der Brustteil des vegetativen Nervensystems und seine klinisch-chirurgische Bedeutung. *Beitr. Klin. Tuberk.* **66,** 1.

Bremer, L. (1882) Die Nerven der Capillaren der kleineren Arterien und Venen. *Arch. mikr. Anat.* **21,** 663.

Brettschneider, H. (1959) Elektronmikroskopische Untersuchungen an marklosen vegetativen Nervenfasern. *Anat. Anz.* Erg.-H. **106–107,** 166.

Brettschneider, H. (1962) Elektronmikroskopische Untersuchungen über die Innervation der glatten Muskulatur des Darmes. *Z. mikr.-anat. Forsch.* **68,** 333.

Brettschneider, H. (1964) Die Gefäßinnervation als ein Beispiel für die feinere Morphologie der vegetativen Endformationen. *Verh. Anat. Ges.* **113,** 150.

Brettschneider, H. (1964) Elektronmikroskopische Studien zur vegetativen Gefäßinnervation. *Anat. Anz.* Erg.-H. **112,** 54.

Brettschneider, H. (1965) Elektronmikroskopische Untersuchungen über die Feinstruktur vegetativer Synapsen an Blutgefäßen. *Symp. Biol. Hung.* **5,** 109.

Brodie, T. G. and Dixon, W. E. (1904) Contributions to physiology of lungs. *J. Physiol. (Lond.)* **30,** 476.

Brodie, T. G. and Cullis, E. (1911) The innervation of the coronary vessels. *J. Physiol. (Lond.)* **43,** 313.

Brown, M. E. (1937) The occurrence of arterio-venous anastomoses in the tongue of the dog. *Anat. Rec.* **69,** 287.

Brüning, F. and Stahl, O. (1922) Physiologische Wirkung der Exstirpation des periarteriellen sympathischen Nervengeflechtes. *Klin. Wschr.* **2,** 1402.

Brüning, F. and Stahl, O. (1923) Vagus und Sympathicus. *Klin. Wschr.* **2,** 272.

Brüning, F. and Stahl, O. 1924. *Chirurgie des vegetativen Nervensystems.* Springer, Berlin.

Brüning, F. (1925) Drei Jahre periarterieller Sympathectomie. *Dtsch. med. Wschr.* **47,** 1516.

Brüning, F. (1927) Das Problem der Gefäßinnervation. *Dtsch. med. Wschr.* **49,** 962.

Bruno, G. (1951) Sulla innervazione dei seni della dura madre. *Monit. zool. ital.* **60,** (Suppl.) 111.

Buch, E. (1929) Studies on the nerves of blood vessels. *Acta path. microbiol. scand.* Suppl. **2,** 9.

Buck, R. C. (1958) The fine structure of endothelium of large arteries. *J. biophys. biochem. Cytol.* **4,** 187.

Bullón, A. and Stiefel, E. (1955) Über die efferente Innervation der glatten Muskulatur. *Acta neuroveg. (Wien)* **12,** 375.

Bullón, A. R. (1956) Experimentelle Studien über die Innervation der kleinen Blutgefäße. *Acta neuroveg. (Wien)* **14,** 133.

Busch, E. (1929) Studies on the nerves of the blood-vessels with especial reference to periarterial sympathectomy. *Acta path. microbiol. scand.* **2,** 1.

Busch, E. (1938) The innervation of the intracranial blood vessels. *Acta psychiat. scand.* **13,** 131.

CAJAL, Y RAMÒN, S. 1911. *Histologie du systeme nerveux de l'homme et des vertébrés* (Traduit de l'Espagnol par Azoulay, L.) A. Maloine, Paris.

CASTRO, F. DE (1926) Sur la structure et l'innervation de la glande intercarotidienne (glomus caroticum) de l'homme et des mammifères, et sur un nouveau système d'innervation autonome du nerf glossopharyngien. *Trab. Lab. Invest. biol. Univ. Madrid* **24,** 365.

CASTRO, F. DE (1928) Sur la structure et l'innervation du sinus carotidien de l'homme et des mammifères. Nouveaux faits sur l'innervation et la fonction du glomus caroticum. *Trab. Lab. Invest. biol. Univ. Madrid* **25,** 331.

CASTRO, F. DE (1929) Über die Struktur und Innervation des Glomus caroticum beim Menschen und den Säugetieren. *Z. Anat. Entwickl.-Gesch.* **89,** 250.

CASTRO, F. DE (1940) Neue Beobachtungen über die Innervation der Carotisgegend. Die Chemo- und Pressoreceptoren. *Trab. Inst. Cajal* **32,** 297.

CASTRO, F. DE (1950) Die normale Histologie des peripheren vegetativen Nervensystems. Das Synapsen-Problem. *Verh. Dtsch. Ges. Path.* **34,** 1.

CASTRO, F. DE (1951) Sur la structure de la synapse dans les chémocepteurs: leur mécanisme d'excitation et rôle dans la circulation sanguine locale. *Acta physiol. scand.* **22,** 14.

CASTRO, F. DE (1962) Sur la vascularisation et l'innervation des corpuscules carotidiens aberrants. *Arch. Int. Pharmacodyn.* **139,** 212.

CASTRO, F. DE and RUBIO, M. 1968. *The anatomy and innervation of the blood vessels of the carotid body and the role of chemoreceptive reactions in the autoregulation of the blood flow.* In Torrance, R. W.: *Arterial Chemoreceptors, held in Oxford on* 18—21 *July* 1966. Blackwell Sci. Publ. Oxford—Edinburgh.

CECCHERELLI, G. (1902) Sulle piastre motrici e sulle fibrille ultraterminali nei muscoli della lingua di Rana esculenta. *Monit. zool. ital.* **13,** 246.

CECCHERELLI, G. (1904) Sulle expansioni nervose di senso nella mucosa della lingua dell'uomo. *Anat. Anz.* **25,** 56.

CELESTINO DA COSTA, A. (1935) Paraganglia and carotid body. *J. Anat. (Lond.)* **69,** 479.

CHARLIER, R. 1961. *Coronary vasodilators.* Pergamon Press, Oxford–London.

CHEN, T. C. R. (1962) The stimulating effect of dinitro-orthocresol, dinitro-phenol and paranitro-phenol on the aortic chemoreceptors in dogs. *Arch. int. Pharmacodyn.* **140,** 521.

CHENG, Y. M. (1957) A histological study on afferent innervation of the large blood vessels. *Arch. jap. Chir.* **26,** 75.

CHENG, Y. M. and KIMURA, CH. (1958) A histological study on the afferent innervation of the large blood vessels. *Acta neuroveg. (Wien)* **17,** 8.

CHERNIGOVSKY, V. N. (1962) Evolutionary aspect in the study of chemoreception of the glomus caroticum. *Arch. int. Pharmacodyn.* **140,** 20.

CHIARINI, C. N. (1965) Ricerche anatomiche sull'innervazione delle zone pressoreceptive seno-carotide, aortiche e polmonari nel ratto. *Arch. ital. Anat. Embriol.* **70,** 237.

CHOROBSKI, I. and PENFIELD, W. (1932) Cerebral vasodilatator nerves and their pathway from the medulla oblongata, with observations of the pial and intracerebral vascular plexuses. *Arch. Neurol. (Chic.)* **28,** 1257.

CHRISTENSEN, K. (1956) Terminal nervous structure in the walls of blood vessels. *Anat. Rec.* **124,** 273.

CHRISTENSEN, K. and HURBLUT, D. W. (1957) Experimental studies of interstitial cells and the innervation of blood vessels. *Anat. Rec.* **127,** 277.

CHRISTENSEN, K. and LEWIS, E. (1951) Intercranial vascular nerves from cranial nerve roots. *Anat. Rec.* **109,** 279.

CHRISTENSEN, K., LEWIS, E. and KUNTZ, A. (1951) Innervation of the renal blood vessels in the cat. *J. comp. Neurol.* **95,** 373.

CHRISTENSEN, K., POLLEY, E. H. and LEWIS, E. (1952) The nerves along the vertebral artery and innervation of the blood vessels of the hindbrain of the cat. *J. comp. Neurol.* **96,** 71.

CIACCIO, G. O. (1864) On the distribution of nerves to the skin of the frog. *Trans. micr. Soc. (London)* **12,** 15.

CLARA, M. (1927) Die arterio-venösen Anastomosen der Vögel und Säugetiere. *Ergebn. Anat.* **27,** 246.

CLARK, S. L. (1928) Nerve endings in the chorioid plexus of the fourth ventricle. *J. comp. Neurol.* **47,** 1.

CLARK, S. L. (1929) Innervation of the blood vessels of the medulla and spinal cord. *J. comp. Neurol.* **48,** 2.

CLARK, S. L. (1929) Innervation of the blood vessels of the medulla and spinal cord. *J. comp. Neurol.* **48,** 247.

Clark, S. L. (1931) Innervation of the pia mater of the spinal cord and medulla. *J. comp. Neurol.* **53,** 129.

Clark, S. L. (1934) Innervation of the chorioid plexus and the blood vessels within the central nervous system. *J. comp. Neurol.* **60,** 21.

Clark, S. L. 1939. *Die arterio-venösen Anastomosen.* Johann Ambrosius Barth, Leipzig.

Clermont, D. (1955) Le corpuscule carotidien. *Toulouse med.* **56,** 129.

Coates, A. E. (1932) Observations on the distribution of the arterial branches of the peripheral nerves. *J. Anat. (Lond.)* **66,** 499.

Code, C. F. and Dingle, W. T. (1935) The carotid sinus nerve. *Proc. Mayo Clin.* **10,** 129.

Code, C. F., Dingle, W. T. and Moorhouse, V. H. K. (1936) The cardiovascular carotid sinus reflex. *Amer. J. Physiol.* **115,** 249.

Coleridge, J. C. G., Hemingway, A., Holmes, R. L. and Linden R. J. (1957) The location of atrial receptors in the dog: a physiological and histological study. *J. Physiol. (Lond.)* **136,** 174.

Coleridge, J. C. G., Kiold, C. and Sharp, J. A. (1961) The distribution connections and histology of baroreceptors in the pulmonary artery with some observations on the sensory innervation of ductus arteriosus. *J. Physiol. (Lond.)* **156,** 591.

Collet, P. and Pierre, M. (1933) Le nerf dépresseur sino-carotidien du cheval. *Bull. Soc. sci. vét. (Lyon)* **36,** 337.

Comroe, J. H. (1939) The location and function of the chemoreceptors of the aorta. *Amer. J. Physiol.* **127,** 176.

Cookson, F. B. A. (1953) The intrinsic arrangement of the nerves supplying the mammalian lung. *B. Sci. Thesis Univ. Manchester.*

Coupland, R. E. and Holmes, R. L. (1957) The use of cholinesterase techniques for the demonstration of peripheral nervous structures. *Quart. J. micr. Sci.* **98,** 327.

Couvreur, E. and Ducultry, J. (1924) L'innervation cardiaque chez les crocodiliens. *Arch. int. Physiol.* **24,** 104.

Dahl, E. and Nelson, E. (1964) Electron microscopic observations on human intracranial artery. *Arch. Neurol.* **10,** 158.

Daly, I. B. de (1954) The problem of transmission at chemoreceptors. VI. Acetylcholine and transmission at chemoreceptors. *Pharmacol. Rev.* **6,** 79.

Daly, I. B. de, Lambertson, C. J. and Schweitzer, A. (1953) Some observations on the carotid body flow in the cat. *Amer. J. med. Sci.* **226,** 230.

Daly, I. B. de, Ludany, G., Todd, A. and Verney, E. B. (1958) Sensory receptors in the pulmonary vascular bed. *Quart. J. exp. Physiol.* **27,** 123.

Danielopolu, D., Aslan, A., Marcou, I., Proca, G. G. and Manesco, E. (1927) Les zones réflexogènes carotidiennes. *Presse méd.* **35,** 1585.

Danielopolu, D., Marcou, J. and Proca, G. G. (1931) Sur l'innervation des coronaires. Rôle des filets sympathiques et des filets parasympathiques. *C. R. Soc. Biol. (Paris)* **107,** 419.

Dearnaley, D. P., Fillenz, M. and Woods, R. I. 1968. *The identification of dopamine in the carotid body of the rabbit.* In Torrance R. W.: *Arterial Chemoreceptors, held in Oxford on* 18—21 *July* 1966. Blackwell Sci. Publ. Oxford—Edinburgh.

Diamond, J. (1955) Observations on the excitation by acetylcholine and by pressure of sensory receptors in the cat's carotid sinus. *J. Physiol. (Lond.)* **130,** 513.

Diamond, J. and Howe, A. (1956) Chemoreceptor activity in the aortic bodies of the cat. *J. Physiol. (Lond.)* **134,** 319.

Dolezel, S. (1954) Verästelung und Endigungen der Nervenfasern in der Niere der weißen Ratte. *Čs. Morfol.* **2,** 1.

Dolgo-Saburow, B. A. 1963. *Innervation der Venen.* Volk u. Gesundheit, Berlin.

Domingo, M. A. and Schmidt, C. F. (1955) Reflexes from stretch receptors in blood vessels, heart and lungs. *Physiol. Rev. (Baltimore)* **35,** 247.

Donáth, T. (1966) Adrenergic innervation of extra- and intracerebral vessels. *Acta morph. Acad. Sci. hung.* **14,** 348.

Dowgjallo, N. (1926) Materialien zur Frage der Gefäßinnervation I. Innervation der Gefäße der Bauchhöhle bei Katzen. *Anat. Anz.* **61,** 466.

Dowgjallo, N. (1929) Über die Nerven der harten Hirnhaut des Menschen und einiger Säuger. *Z. Anat. Entwickl.-Gesch.* **89,** 453.

Dowgjallo, N. (1932) Beiträge zur Lehre von der Innervation des peripherischen Blutgefäß-Systems. *Z. Anat. Entwickl.-Gesch.* **97,** 9.

Dripps, R. D. and Comroe, J. H. (1944) The clinical significance of the carotid and aortic bodies. *Amer. J. Med. Sci.* **208,** 681.

DUTZ, H. (1959) *Nierenfunktion und Nervensystem.* VEB Verlag Volk u. Gesundheit, Berlin.

ELIAS, H. 1959. *The structure of blood vessels.* In: A. A. LUISADA's *Cardiology*, I. McGraw-Hill Book Co. New York.

ELLIOT, C. B. (1965) Miniature endocrine amphifers as end-organs of the involuntary nervous system. The functional linkage between adrenal medulla and glomus jugulare. Dept. of Clin Path. Galgary. (Gen. Hosp. Alberta) *Laryngoscope.* **75,** 1817.

EVERSBUSCH, G. (1916) Anatomische und histologische Untersuchungen über die Beziehungen der Vorhofsganglien zu dem Reizleitungssystem des Katzenherzens. *Dtsch. Arch. klin. Med.* **120,** 38.

FEYRTER, F. 1951. *Über die Pathologie der vegetativen nervösen Peripherie und ihrer ganglionären Regulationsstätten.* Maudrich, Wien.

FISHER, A. W. F. (1965) The intrinsic innervation of the pulmonary vessels. *Acta anat. (Basel)* **60,** 481.

FISHER, A. W. F., BIRKS, E. I. and ANDERSON R. H. (1963) Monoamine oxidase activity within the cardiac plexuses. *J. Anat. (Lond.)* **97,** 616.

FLEISCH, A. (1962) Fibres nerveuses afférentes situées dans la paroi des vaisseaux sanguins. *Arch. int. Pharmacodyn.* **139,** 447.

FLOYD, W. F. and NEIL, A. (1952) The influence of the sympathetic innervation of the carotid bifurcation on chemoceptor and baroceptor activity in the cat. *Arch. int. Pharmacodyn.* **91,** 230.

FOLKOW, B. (1960) The efferent innervation of the cardiovascular system. *Dtsch. Kreisl.-Forsch.* **25,** 84.

FORBES, H. S. and WOLFF, H. G. (1928) Cerebral circulation III. The vasomotor control of cerebral vessels. *Arch. Neurol. (Chic.)* **19,** 1057.

FORBES, H. S. and COBB, S. S. (1938) Vasomotor control of the cerebral blood vessels. *Brain* **61,** 221.

FRANKLIN, K. J. 1937. *A monograph on veins.* Ch. C. Thomas, Springfield, Ill.

FUNKE, J. (1904) The carotid body; anatomy, histology, embryology and tumors arising from it. *Amer. Med. (Philad.)* **8,** 109.

GANSLER, H. (1961) Phasenkontrast- und elektronenmikroskopische Untersuchungen zur Innervation der glatten Muskulatur. *Acta neuroveg. (Wien)* **22,** 192.

GANZ, P. (1964) Über die Indikation zur Glomektomie und deren Ergebnisse bei der Behandlung des Asthma bronchiale. *Zbl. Chiurg.* **89,** 1042.

GANZ, P. (1965) Exstirpation des Glomus caroticum zur Behandlung des Asthma bronchiale. *Med. Welt.* **669.**

GASK, G. E. and ROSS, J. P. 1934 *The surgery of the sympathetic nervous system.* Baillière, Tindall, Cox. London.

GASK, G. E. and ROSS, J. P. 1936. *Die Chirurgie des sympathischen Nervensystems.* Johann Ambrosius Barth, Leipzig.

GASKELL, W. H. (1886) On the structure, distribution and function of the nerves which innervate the visceral and vascular system. *J. Physiol. (Lond.)* **7,** 19.

GASKELL, W. H. 1916. *The involuntary nervous system.* Monographs on Physiology. Longmans, London.

GERARD, H. W. and BILLINGSLEY, P. R. (1923) The innervation of the carotid body. *Anat. Rec.* **25,** 391.

GERO, J. and GEROVÁ, M. (1962) The role of parameters of pulsating pressure in the stimulation of intracarotid receptors. *Arch. int. Pharmacodyn.* **140,** 35.

GILDING, H. P. (1932) The course of the vasoconstrictor nerves to the periphery. *J. Physiol. (Lond.)* **74,** 34.

GLASER, W. (1914) Über die Nervenverzweigung innerhalb der Gefäßwand. *Dtsch. Z. Nervenheilk.* **50,** 305.

GLASER, W. (1914) Die Nerven in den Blutgefäßen des Menschen. *Arch. Anat. Physiol. (Anat. Abt.)* 189.

GLASER, W. (1926) Intramurale Innervation der Kranzgefäße. *Z. Anat. Entwickl.-Gesch.* **79,** 797.

GLASER, W. (1928) Über die motorische Innervation der Blutgefäße der Milz nebst einigen Bemerkungen zur intramuralen Nervenversorgung der Blutgefäße im Knochenmark. *Z. Anat. Entwickl.-Gesch.* **87,** 741.

GOERING, H. 1834. Dissertatio inauguralis anatomica-physiologica de nervis vasa praecipue extremitates adeuntibus. Jena.

GOLTZ, F. (1871) Über gefäßerweiternde Nerven. *Pflügers Arch. ges. Physiol.*

GOORMAGHTIGH, N. and PANNIER, R. (1936) Le paranganglion épicardiaque de penitschka est irrigué par du sang artériel. *C. R. Soc. Biol. (Paris)* **123,** 1261.

GOORMAGHTIGH, N. (1939) La structure glomique du glomus carotidien. *Acta brev. neerl. Physiol.* **9,** 208.

GOORMAGHTIGH, N. and PANNIER, R. (1939) Les paraganglions du coeur et des zones vasosensibles carotidienne et cardio-aortique chez le chat adulte. *Arch. Biol. (Paris)* **50,** 455.

GOSSES, J. (1938) The glomus caroticum. *Acta neerl. Morph.* **1,** 38.

GOTTSCHICK, J. 1952 *Die Leistungen des Nervensystems.* G. Fischer, Jena.

GRANT, R. T. and REGNIER, M. (1926) The comparative anatomy of the cardiac coronary vessels. *Heart.* **13,** 285.

GRANT, R. T. and THOMPSON, R. H. S. (1963) Cholinesterase and the nerve supply to blood vessels in the rabbit's external ear. *J. Anat. (Lond.)* **97,** 7.

GREENBERG, S. R. (1953) Studies on cardiac innervation. *Anat. Rec.* **115,** 312.

GREENBERG, S. R. (1956) A fiber analysis of the vagus cardiac rami and the cervical sympathetic nerves in the dog. *J. comp. Neurol.* **104,** 33.

GREVING, R. 1935. *Makroskopische Anatomie und Histologie des vegetativen Nervensystems.* In: *Handbuch der Neurologie*, Springer, Berlin.

GREVING, R. (1939) Beitrag zur Gefäßinnervation auf Grund histologischer Untersuchungen. *Z. Neurol.* **167,** 465.

GRIGORJEVA, T. (1932) Histologische Untersuchungen über die Innervation der Hirngefäße. *Z. mikr.-anat. Forsch.* **28,** 418.

GRIGORJEVA, T. (1949) Über die Innervation der Kapillaren. *Ber. Akad. Wiss. USSR* **68,** 589.

GRIGORJEVA, T. 1954. *Innervation of blood vessels.* Medgiz, Moscow.

GRIGORJEVA, T. A. 1962. *The innervation of blood vessels.* Pergamon Press. New York–Oxford–London–Paris.

GROSSER, O. (1901) Zur Anatomie und Entwicklungsgeschichte des Gefäßsystems der Chiropteren. *Anat. Hefte* **17,** 205.

GSCHEIDLEN, A. (1877) Beiträge zur Lehre von den Nervenendigungen in den glatten Muskelfasern. *Arch. mikr. Anat.* **14,** 321.

GUAZZI, M. and ZANCHETTI, A. (1966) Regulation of circulation by carotid sinus, aortic, and cardiopulmonary receptors. *Acta neuroveg. (Wien)* **28,** 197.

GULLAND, G. L. (1898) The occurrence of nerves in intracranial blood vessels. *Brit. med. J.*

GUSTAFSSON, B. E. and HALLEN, L. G. (1955) Histological evolution of different methods for preservation of arterial grafts. *Lund's Univ. Arskrift.* **4,** 1.

HADJIOLOFF, A., DOKOV, V. K. and TSCHAKAROFF, E. L. (1954) Contribution à l'étude de l'innervation des capillaires du cerveau. *Acta morph. Acad. Sci. hung.* **5,** 525.

HAGEN, E. (1949) Beobachtungen zur pathologischen Histologie des vegetativen Nervensystems bei verschiedenen Erkrankungen des Gefäßapparates. *Z. Anat. Entwickl.-Gesch.* **114,** 420.

HAGEN, E. (1955) Mikroskopische Beobachtungen über die Innervation der Gefäße in der Substanz des menschlichen Zwischenhirns und in der Pia mater. *Z. Anat. Entwickl.-Gesch.* **118,** 223.

HAGEN, E. (1962) Zur normalen und pathologischen Histologie der Gefäßnerven in operativ entfernten menschlichen Grenzstrangganglien. *Acta anat. (Basel)* **49,** 162.

HAGER, H. (1961) Elektronenmikroskopische Untersuchungen über die Feinstruktur der Blutgefäße und perivasculären Räume im Säugetiergehirn. *Acta neuropath. (Berl.)* **1,** 9.

HAHN, O. and HUNCZEK, W. (1925) Anatomische Untersuchungen über die Nervenversorgung der Extremitätengefäße. *Bruns' Beitr. klin. Chirurg.* **133,** 2.

HALLER, A. 1764. *Elementa physiologica*, lib. X. sect. **6,** vol. 4, Lausanne.

HARVEY, W. 1928. *De Motu Cordis* (1628); *De Circulatione Sanguinis* (1649) issued on the occasion of the tercentenary celebration. Nonesuch Press, London.

HARTING, K. (1930) Bemerkungen über das Vorkommen von Nervennetzen im Endausbreitungsgebiet der intramuralen Nerven. *Z. mikr.-anat. Forsch.* **45,** 104.

HASSIN, G. B. (1929) The nerve supply of the cerebral blood vessels. A histologic study. *Arch. Neurol.* **22,** 375.

HAUSS, W. G., KREUZIGER, H. and ASTEROTH, H. (1949) Über die Reizung der Pressorecptoren im Sinus caroticus beim Hund. *Z. Kreisl.-Forsch.* **38,** 28.

HAUSS, W. H. and SCHMITT, G. (1962) Über Electroneurogramme, die vom Carotissinus des Menschen abgeleitet wurden. *Arch. int. Pharmacodyn.* **139,** 487.

HEGGIE, I. F. 1952. *Vascular architecture of the kidney. In visceral circulation.* A Ciba Foundation Symposion. Churchill Ltd., London.

HEPPNER, C. L. (1869) Über den feineren Bau der glandula carotica. *Virchows Arch. path. Anat.* **46,** 401.

HERING, H. E. (1923) Der Carotisdruckversuch. *Münch. med. Wschr.* **70,** 1287.

HERING, H. E. (1924) Der Sinus caroticus an der Ursprungsstelle der Carotis interna als Ausgangsort eines hemmenden Herzreflexes und eines depressorischen Gefäßreflexes. *Münch. med. Wschr.* **71,** 701.

HERING, H. E. (1925) Über die Wand des Sinus caroticus als Reizempfänger und den Sinusnerv als zentripetale Bahn für Sinusreflexe. *Dtsch. med. Wschr.* **51,** 28.

HERING, H. E. 1927. *Die Carotissinusreflexe auf Herz und Gefäße* Th. Steinkopff, Dresden.

HERING, H. E. 1932. *Der Blutdruckzüglertonus in seiner Bedeutung für den Parasympathicustonus und Sympathicustonus.* Georg Thieme, Leipzig.

HESS, A. 1968. *Electron microscopic observations of normal and experimental cat carotid bodies.* In Torrance R. W.: *Arterial Chemoreceptors, held in Oxford on* 18—21 *July* 1966. Blackwell Sci. Publ. Oxford—Edinburgh.

HESS, W. R. 1930. *Die Regulierung des Blutkreislaufes.* G. Thieme. Leipzig.

HETT, J. (1943) Zur feineren Innervation der arterio-venösen Anastomosen in der Fingerbeere des Menschen. *Z. Zellforsch.* **33,** 151.

HEYMANS, C. 1929. *Le sinus carotidien et les autres zones vasosensibles réflexogènes.* Presse Univ., Paris.

HEYMANS, C. 1946. *Sur le rôle des presso- et des chimico-récepteurs vasculaires dans la régulation de la respiration.* Conférence Nobel, Stockholm.

HEYMANS, C. (1951) Sur la régulation de la pression artérielle et l'hypertension. *Medicina (Parma)* **6,** 749.

HEYMANS, C. (1951) Sur la pharmacologie des ganglions végétatifs. *Arch. int. Physiol.* **59,** 561.

HEYMANS, C. (1951) Chemoreceptors and regulation of respiration. *Acta physiol. scand.* **22,** 4.

HEYMANS, C. (1952) Sur le rôle des chimico-récepteurs en pharmacologie et en physiologie. *Actualités Pharmacol.* **5,** 111.

HEYMANS, C. (1952) Nouveaux aspects de la régulation physiologique de la pression artérielle et de l'hypertension. *Bull. Acad. Roy. Méd. Belgique* **17,** 417.

HEYMANS, C. 1953. *The pressoreceptors of the carotid sinus.* J. M. Found. New York.

HEYMANS, C. 1954. *Some new aspects of reflex blood pressure regulation and hypertension.* Churchill Ltd. London.

HEYMANS, C. (1960) Reflexogenic areas of the cardiovascular system. *Pers. Biol. Med.* **3,** 409.

HEYMANS, C. and BOUCKAERT, J. J. 1934. *La sensibilité réflexogène des vaisseaux aux excitants chimiques.* Hermann et Cie, Paris.

HEYMANS, C. and BOUCKAERT, J. J. (1939) Les chémorécepteurs du sinus carotidien. *Ergebn. Physiol.* **41,** 28.

HEYMANS, C., BOUCKAERT, J. J. FARBER, S. and HSU, Y. (1936) Influence réflexogène de l'acétylcholine sur les terminaisons nerveuses chimicosensitives du sinus carotidien. *Arch. int. Pharmacodyn.* **54,** 129.

HEYMANS, C., BOUCKAERT, J. J., and REGNIERS, P. 1933. *Le sinus carotidien et la zone homologue cardio-aortique.* G. Doin, Paris.

HEYMANS, C., BOUCKAERT, J. J. and WIEZUCHOWSKI, M. (1937) Réflexes vasomoteurs médullaires d'origine vasculaire barosensible. *Arch. int. Pharmacodyn.* **55,** 233.

HEYMANS, C. and HEUVEL–HEYMANS, G. (1950) Action of drugs on arterial wall of carotid sinus and blood pressure. *Arch. int. Pharmacodyn.* **83,** 520.

HEYMANS, C. and HEUVEL–HEYMANS, G. (1951) New aspects of blood pressure circulation. *Circulation* **4,** 581.

HEYMANS, C. and NEIL, E. 1958. *Reflexogenic areas of the cardiovascular system.* Churchill Ltd., London.

HEYMANS, C. and NEIL, E. 1962. *Cardiovascular and pulmonary reflexes.* In "*Cardiovascular functions*". London.

HEYMANS, C. and VLEESCHHOUWER, G. R. DE (1956) Visceral receptors. *Ann. Rev. Physiol.* **18,** 387.

HEYMANS, C., VLEESCHHOUWER, G. R. DE and SCHAEPDRYVER, A. F. (1960) Abdominal baro- and chemosensitivity in dogs. *Circulation* **8,** 347.

HEYMANS, C., VLEESCHHOUWER, G. R. DE and SCHAEPDRYVER, A. F. (1962) Baroreceptive vasomotor reflexes arising from the thyroid artery in dogs. *Arch. int. Pharmacodyn.* **138,** 320.

HILDENBERG, F. (1958) Neurohistologische Studien über die Pressorezeptoren des Carotissinus bei Hypertonikern. *Acta neuroveg. (Wien)* **19,** 1.

HILL, C. J. (1927) A contribution to our knowledge of the enteric plexuses. *Philos. Trans. Roy. Soc. London.* **215,** 355.

HINSEY, J. C. (1929) Observations on the innervation of the blood vessels in skeletal muscle. *J. comp. Neurol.* **47,** 23.

HIRSCH, L. (1925) Über die Nervenversorgung der Gefäße im Hinblick auf die Probleme der periarteriellen Sympathectomie. *Arch. klin. Chirurg.* **137,** 281.

HIRSCH, L. (1926) Über den feineren Bau der Nerven der großen Extremitätengefäße. *Arch. klin. Chirurg.* **139,** 225.

HIS, W. (1863) Über die Endigung der Gefäßnerven. *Virchows Arch. path. Anat.* **28,** 427.

HOFFMANN, F. B. (1898) Die Innervation des Herzens und der Blutgefäße. *Nagels Handb. Physiol.* **1,** 1.

HOLLINSHEAD, W. H. (1939) The origin of the nerve fibres to the glomus caroticum of the cat. *J. Comp. Neur.* **71,** 417.

HOLLINSHEAD, W. H. (1940) Chromaffin tissue and paraganglia. *Quart. Rev. Biol.* **15,** 156.

HOLLINSHEAD, W. H. (1940) The innervation of the supracardial bodies in the cat. *J. comp. Neurol.* **73,** 37.

HOLLINSHEAD, W. H. (1940) A note on the blood supply of the supracardial bodies in the kitten. *Anat. Rec.* **76,** 283.

HOLLINSHEAD, W. H. (1942) A comparative study of the glomus coccygeum and the carotid body. *Anat. Rec.* **84,** 1.

HOLLINSHEAD, W. H. (1942) A comparative study of the carotid body of the cat. *Amer. J. Anat.*, **73,** 185.

HOLLINSHEAD, W. H. (1943) A cytological study of the carotid body of the cat. *Amer. J. Anat.* **73,** 185.

HOLLINSHEAD, W. H. (1945) Effects of anoxia upon carotid body morphology. *Anat. Rec.* **92,** 255.

HOLLINSHEAD, W. H. and SAWYER, C. H. (1945) Mechanisms of carotid body stimulation. *Amer. J. Physiol.* **144,** 79.

HONJIN, R. (1956) On the nerve supply of the lung of the mouse with special reference to the structure of the peripheral vegetative nervous system. *J. comp. Neurol.* **105,** 587.

HOU-JENSEN, H. M. (1930) Die Verästelung der Arteria renalis in der Niere des Menschen. *Z. Anat. Entwickl.-Gesch.* **91,** 1.

HOVELACQUE, A. 1927. *Anatomie des nerfs craniens et rachidiens et du système grand sympathique.* Gaston Doin Co., Paris.

HOWE, A. (1956) The vasculature of the aortic bodies in the cat. *J. Physiol. (Lond.)* **134,** 311.

HUBER, G. C. (1899) Observations on the innervation of the intracranial vessels. *J. comp. Neurol.* **9,** 1.

HUNTER, W. (1901) On the presence of nerve fibres in the cerebral vessels. *J. Physiol. (Lond.)* **26,** 465.

HÜRTHLE, K. (1889) Untersuchungen über die Innervation der Hirngefäße. *Arch. ges. Physiol.* **44,** 578.

IRVINE, G., LEVER, J. D. and MUMTAZUDDIN, A. (1965) Muscle surface specializations and the neuromuscular relationship in coronary and splanchnic arterioles. *J. Anat. (Lond.)* **99,** 409.

IWANOFF, G. F. (1925) Zur Anatomie und Histologie der Nebenorgane der menschlichen sympathischen Nerven. *Z. Anat. Entwickl.-Gesch.* **75,** 435.

JABONERO, V. (1947) Morfologia del teritorio de accion eficaz del sistema neurovegetativo periferico. *Trab. Inst. nac. Cienc. méd. (Madrid)* **9,** 237.

JABONERO, V. (1948) Études sur le système neurovégétatif periphérique I. *Acta anat. (Basel)* **61,** 15.

JABONERO, V. (1948) Études sur le système neurovégétatif périphérique II. Innervation efférente des vaisseaux sanguins et de la musculature lisse. *Acta anat. (Basel)* **6,** 376.

JABONERO, V. (1951) Innervation efférente des vaisseaux sanguins. *Cardiologia (Basel)* **19,** 209.

JABONERO, V. (1951) Observationes sobre la inervacion de la region carotidea humana. *Arch. Méd. exp.* **14,** 59.

JABONERO, V. (1952) Die interstitiellen Zellen des vegetativen Nervensystems und ihre vermutliche Analogie zu anderen Elementen. *Acta neuroveg. (Wien)* **5,** 1.

JABONERO, V. 1953. *Der anatomische Aufbau des peripheren neurovegetativen Systems.* Springer, Wien.

JABONERO, V. (1954) Le syncytium nerveux des voies végétatives efférentes. *Acta neuroveg. (Wien)* **8,** 291.

JABONERO, V. (1954) Études sur le système neurovégétatif périphérique. VIII. Innervation efférente de la musculature lisse. *Acta neuroveg. (Wien)* **10,** 136.

JABONERO, V. (1955) Études sur les synapses du système neurovégétatif périphérique. I. Les synapses dans les ganglions sympathiques. *Z. mikr.-anat. Forsch.* **61,** 360.

JABONERO, V. (1955) Études sur les synapses du système neurovégétatif périphérique. II. Les synapses interneuronales dans les ganglions intramuraux du tube digestif. *Z. mikr.-anat. Forsch.* **61,** 549.

JABONERO, V. (1955) Die anatomischen Grundlagen der peripheren Neurosecretion. *Acta neuroveg. (Wien)* Suppl. **6,** (Colloquium) 160.

JABONERO, V. (1956) Efferente Innervation der Blutgefäße. *Acta neuroveg. (Wien)* **14,** 16.

JABONERO, V. (1956) Studien über die Synapsen des peripheren vegetativen Nervensystems. III. Das distale nervöse Syncytium und die plexiforme Synapse auf Distanz. *Z. mikr.-anat. Forsch.* **62,** 407.

JABONERO, V. (1959) Die plexiforme Synapse auf Distanz und die Bedeutung der sogenannten intercalären Zellen. *Acta neuroveg. (Wien)* **19,** 276.

JABONERO, V., LOPEZ PRIETO, R., PEREZ CASAS, A. and BENGOECHEA, M. E. (1961) Neue Beobachtungen über die Endigungsweise der efferenten vegetativen Nervenbahnen. *Z. mikr.-Anat. Forsch.* **67,** 1.

JANSKY, M. (1954) Renálni nervova pleten a sousedni nervové pletene u krysy (The renal nervous plexus and the neighbouring plexuses of the rat). *Čs. Morfol.* **2,** 96.

JEGOROW, I. (1892) Zur Lehre von der Innervation der Blutgefäße. *Du Bois' Arch.* Suppl. 69.

JEPPSSON, P. G. and OLIN, T. (1960) Cerebral angiography in the rabbit. *Lund's Univ. Årskrift.* **14,** 1.

JOELS, N. and NEIL, E. (1962) The action of high tensions of carbon monoxide on the carotid chemoreceptors. *Arch. int. Pharmacodyn.* **139,** 528.

JOELS, N. and NEIL, E. (1963) The action of acetaldehyde on the chemoreceptors of the carotid glomus. *J. Physiol. (Lond.)* **168,** 234.

JOELS, N. and NEIL, E. 1968. *The idea of a sensory transmitter* In Torrance R. W.: *Arterial Chemoreceptors, held in Oxford on* 18—21 *July* 1966. Blackwell Sci. Publ. Oxford—Edinburgh.

JONES, T. (1936) The structure and mode of innervation of capillary blood vessels. *Amer. J. Anat.* **58,** 227.

JONESCO, T. 1923. *Le sympathique cervico-thoracique.* Masson et Cie., Paris.

JONESCO, T. and JONESCU, D. (1926) Experimentelle Untersuchungen über die afferenten kardioaortalen Bahnen und über den physiologischen Nachweis der Existenz des Depressors als isolierter Nerv beim Menschen. *Z. ges. exp. Med.* **48,** 490.

JORIS, H. 1906. *Les nerfs des vaisseaux sanguins.* Bull. Acad. roy. Med. Belg.

JUHÁSZ-NAGY A. and SZENTIVÁNYI, M. (1961) Localisation of the receptors of the coronary chemoreflex in the dog. *Arch. int. Pharmacodyn.* **131,** 39.

JUNG, F. (1934) Physiologische Versuche über Pressoreceptoren an der Karotisteilungsstelle bei Vögeln. *Z. Kreisl.-Forsch.* **26,** 328.

KANTER, M. (1957) Neue morphologische Ergebnisse über die peripherischen Nervenausbreitungen und ihre Deutung. *Acta Anat. (Basel)* **31,** 397.

KATSAROS, B. and LOESCHKE, H. (1965) Über die Wirkung der Pressoreceptoren des Carotis-Gebietes der narkotisierten Katze auf die Atmung nach isolierter Ausschaltung der Chemoreceptoren. *Pflügers Arch. ges. Physiol.* **252,** 193.

KAUTZKY, R. (1949) Die Bedeutung der Hirnhautinnervation. *Dtsch. Z. Nervenheilk.* **161,** 506.

KAUTZKY, R. (1951) Ein Grundplan der cerebrospinalen Innervation der Hirnhäute und Hirngefäße. *Z. Anat. Entwickl.-Gesch.* **115,** 570.

KEIFFER, J. H. (1922) Le système nerveux ganglionnaire de l'utérus humain. *Bull. Acad. roy. Méd. Belg.* **20,** 522.

KENNEY, R. A., NEIL, E. and SCHWEITZER, A. (1951) Carotid sinus reflexes and cardiac output in dogs. *J. Physiol. (Lond.)* **114,** 27.

KERPER, A. H. (1926) The innervation of arteries of the extremities. *Anat. Rec.* **32,** 235.

KERPER, A. H. (1927) The distribution of unmyelinated nerve fibres to the arteries of the extremities. *Anat. Rec.* **35,** 17.

KESSEL, J. 1914. *Blutgefäße.* In STRICKER: *Handbuch der Gewebelehre,* Wien.
KIMURA, CH. (1956) Vascular sensitivity. *Acta neurog. (Wien)* **14,** 170.
KISS, F. (1931) The relationship between vagus and sympathicus in the vertebrates. *J. Anat. (Lond.)* **66,** 153.
KISS, F. (1952) Histology of the blood vessels. *Acta morph. Acad. Sci. hung.* **1,** 165.
KISS, F. and SATTLER, J. (1955) Morphological data concerning the structure of cerebral vessels. *Acta morph. Acad. Sci. hung.* **4,** 255.
KITAHABA, T. (1959) A histological study on the innervation of the large blood vessels of the abdomen. *Arch. jap. Chirurg.* **28,** 1560.
KNOCHE, H. (1950) Über die feinere Innervation der Niere. *Z. Anat. Entwickl.-Gesch.* **195,** 97.
KNOCHE, H. (1951) Über die feinere Innervation der Niere des Menschen. *Z. Zellforsch.* **36,** 448.
KNOCHE, H. (1952) Über die feinere Innervation der Arteria uterina des Menschen. *Z. Zellforsch.* **37,** 205.
KNOCHE, H. (1954) Untersuchungen über die Endigungsweise cerebrospinaler und vegetativer Nervenfasern. *Z. Zellforsch.* **40,** 162.
KNOCHE, H. (1961) Lichtmikroskopische Untersuchungen über die Innervation der Retinagefäße. *Z. mikr.-anat. Forsch.* **67,** 595.
KNOCHE, H. (1966) Beitrag zur Kenntnis der Gefäßversorgung der aortico-pulmonalen Glomera. *Z. mikr.-anat. Forsch.* **74,** 283.
KNOCHE, H. and SCHMITT, G. (1963) Über Chemo- und Pressoreceptorenfelder am Koronarkreislauf. *Z. Zellforsch.* **61,** 524.
KNOCHE, H. and BLÜMCKE, S. (1964) Neuroreceptor-Areale in der Wand der Arteria pulmonalis. *Z. Zellforsch.* **62,** 514.
KNOCHE, H. and SCHMIDT, G. (1964) Zur Kenntnis des Nervengewebes in der Wand des Sinus caroticus. *Z. Zellforsch.* **63,** 22.
KOCH, E. 1931. *Die reflektorische Selbststeuerung des Kreislaufes.* Th. Steinkopff. Dresden–Leipzig.
KOCK, L. L., DE (1951) Histology of the carotid body. *Nature (Lond.)* **167,** 611.
KOCK, L. L., DE (1954) The intraglomerular tissues of the carotid body. *Acta anat. (Basel)* **21,** 101.
KOCK, L. L. DE (1958) The carotid body of certain birds. *Acta anat. (Basel)* **35,** 161.
KOCK, L. L. DE (1959) The arterial vessels of the neck in the pilot whale (Globicephala mealena Traill) and the tortoise (Phocaena phocaena L.) in relation to the carotid body. *Acta anat. (Basel)* **36,** 274.
KOCK L. DE and DUNN, A. E. G. 1968. *Electron-microscopic investigation of the nerve endings in carotid body.* In Torrance R. W.: *Arterial Chemoreceptors, held in Oxford on* 18—21 *July* 1966. Blackwell Sci. Publ. Oxford—Edinburgh.
KOELLIKER, A. V. (1854) Untersuchungen über die letzten Endigungen der Nerven. *Z. wiss. Zool.* **12,** 149.
KOHN, A. (1903) Die Paraganglien. *Arch. mikr. Anat.* **62,** 263.
KOJI–UCHISONO (1964) Innervation of the blood capillary in the heart of the dog and rabbit. *Jap. J. Physiol.* **14,** 587.
KOROTKOW, A. G. (1964) Zur Entwicklung des nervösen Apparates der Aorta in der Phylogenese. Innervation der Aortenwand der Amphibien. *Anat. Anz.* **114,** 483.
KOSE, W. (1902) Über das Vorkommen einer »Carotisdrüse« und der »chromaffinen Zellen« bei Vögeln. *Anat. Anz.* **22,** 162.
KOSE, W. (1904) Über die »Carotisdrüse« und das »chromaffine Gewebe« der Vögel. *Anat. Anz.* **25,** 609.
KOSE, W. (1907) Die Paraganglien bei den Vögeln. *Arch. mikr. Anat.* **69,** 665, 790.
KOTSUKA, K. and NAITO, H. (1962) On the vasodilator action of efferent "Sympathicus via Posterior Root" — efferent sympathetic double innervation of bull frog's blood vessel. *Acta neuroveg. (Wien)* **23,** 454.
KOVÁCS, T., KÖVÉR, A. and BALOGH, G. (1960) A cholinesterase lokalizációjának vizsgálata különböző típusú izmokban (Investigations into the localization of cholinesterase in various muscle types). *Kísérl. Orvostud.* **3,** 296.
KRAMER, J. G. and TODD, T. W. (1914) The distribution of nerves to the arteries of the arm. With a discussion of the clinical value of result. *Anat. Rec.* **8,** 243.
KRAMER, K. (1960) Die afferente Innervation und die Reflexe von Herz und venösem System. *Dtsch. Kreisl.-Forsch* **25,** 142.
KRIMKE, J. 1884. *Die Nerven der Capillaren.* Diss. München.

KUNTZ, A. (1951) Afferent innervation of peripheral blood vessels through sympathetic trunks. *South. med. J. (Bgham, Ala.)* **44,** 673.

KUNTZ, A. 1953. *The autonomic nervous system.* Lea and Febiger, Philadelphia.

KUNTZ, A. (1955) The anatomical basis of reflex vasomotor activity and pain of vascular origin. *Sth. med. J. (Bgham, Ala.)* **48,** 338.

KUO–TCHANG, TCHENG, TA–YUON CHEN and SIANG–KIFIT (1965) Intramural baroreceptors of the pulmonary arteries in birds. *Sci. Simica* **14,** 938.

KUPRIANOV, V. V. 1959. *Der Nervenapparat der Gefäße des kleinen Kreislaufs.* Medgiz, Leningrad.

KURUSU, M. (1928) Über die Innervation der Hirngefässe. *Mitt. Med. Akad. Kyoto.* **2,** 15.

KURUSU, M. and HAMADA, J. (1929) Der histologische Nachweis der Gefäßnerven des Gehirns. *Mitt. med. Akad. Kioto* **3,** 33.

KURUSU, M. and HAMADA, J. (1942) L'innervation des vaisseaux. *Schweiz. med. Wschr.* **2,** 1335.

KYTMANOFF, K. A. (1901) Über die Nervenendigungen in den Lymphgefäßen der Säugetiere. *Anat. Anz.* **19,** 369.

LAMMERS, H. J. and SMITHIUS, TH. (1956) Étude d'une anastomose artériovéneuse au niveau interlobaire du rein humain. *C. R. Ass. Anat.* **91,** 836.

LANDGREN, S. (1952) The baroceptor activity in the carotid sinus nerve and the distensibility of the sinus wall. *Acta physiol. scand.* **26,** 35.

LANDGREN, S. and NEIL, E. (1952) The effect of chemical stimulation of the carotid bodies on the heart rate of the cat. *Acta physiol. scand.* **25,** 286.

LANDSMEER, J. M. F. (1951) Vessels of the rat's hypophysis. *Acta Anat. (Basel)* **12,** 82.

LANGE, S. J., DE (1907) Opstijgende degeneratie na gedeeltelijke doorsnijding van het ruggemerg. *Versl. Kon. Akad. v. Wetensch. Amsterdam* **16,** 350.

LANGENDORFF, W. (1907–8) Über die Innervation der Coronargefäße. *Zbl. Physiol.* **21,** 551.

LANGLEY, J. N. (1895) Further observations on the secretory and vasomotor fibres of the foot of the cat with notes on other sympathetic nerve fibres. *J. Physiol. (Lond.)* **17,** 269.

LANGLEY, J. N. 1900. *Sympathetic and other related systems of nerves.* In SCHÄFER: *Textbook of Physiology* II. 616. Y. J. Pentland, Edinburgh.

LANGLEY, J. N. (1909) Degenerative changes in nerve-endings in striated muscle, in nerve plexuses on arteries and in nerve fibres of frog. *J. Physiol. (Lond.)* **38,** 504.

LANGLEY, J. N. (1913) The vascular dilatation caused by the sympathetic end course of vasomotor nerves. *Ergebn. Physiol.* **58,** 70.

LANGLEY, J. N. 1922. *Das autonome Nervensystem.* Springer, Berlin.

LAPINSKY, M. (1905) Über die Gefäßinnervation der Hundepfote. *Arch. mikr. Anat.* **65,** 623.

LAPINSKY, M. (1913) Zur Innervation der Hirngefäße. *Arch. Anat. Physiol.* (Suppl.) **16,** 3.

LAPINSKY, M. (1923) Zur Frage über die Lokalisation der motorischen Funktionen im Rückenmark. *Dtsch. Z. Nervenheilk.* **79,** 129.

LAPINSKY, M. and CASSIRER, R. (1901) Über den Ursprung des Halssympathicus im Rückenmark. *Dtsch. Z. Nervenheilk.* **19,** 137.

LASSMAN, G. (1965) Neuere Befunde über die Nervenversorgung der Irisgefäße des Kaninchens. *Symp. Biol. Hung.* **5,** 133.

LASSMANN, G. (1965) Neue Befunde über die Nervenversorgung des Gefäßsystems. *Acta neuroveg (Wien)* **27,** 546.

LAUBMAN, W. (1924) Gefäßnerven zu den oberflächlichen Arterien des Kopfes. *Anat. Anz.* **57,** 213.

LAUSING, A. I. 1959. *The arterial wall.* W. Wilkins, Baltimore.

LAWRENTJEW, B. J. (1925) Über die nervöse Natur und das Vorkommen der sogenannten interstitiellen Zellen (Cajal, Dogiel) in der glatten Muskulatur. *Vorhand. koninkl. Akad. Wetensch. Amsterdam (Naturwiss. Abt.)* **28,** 1.

LAWRENTJEW, B. J. (1926) Über die Verbreitung der nervösen Elemente in der glatten Muskulatur. *Z. mikr.-anat. Forsch.* **6,** 467.

LAWRENTJEW, B. J. (1934) Einige Bemerkungen über Fortschritte und Aufgaben der Erforschung des autonomen Nervensystems. *Z. mikr.-anat. Forsch.* **36,** 651.

LAWRENTJEW, B. J. (1937) Some theoretical problems of the structure of the nervous tissue. *Arch. biol. Nauk.* **48,** 194.

LAWRENTJEW, B. J. and BOROWSKAJA, A. I. (1936) Die Degeneration der postganglionären Nervenfasern des autonomen Nervensystems und deren Endigungen. *Z. Zellforsch.* **23,** 761.

LAZIRTHES, G. (1956) Étude critique des nerfs vasodilatateurs. *Acta neuroveg. (Wien)* **14,** 74.

LEGAIT, E. and DOLLANDER, A. (1948) Innervation des vaisseaux de la base du cerveau chez la cobaye. *C. R. Ass. Anat.* **34,** 325.

LEHMAN, J. CHR (1864) Über die Nervenendigungen und das Vorkommen von mikrosopischen Ganglien in den Gefäßwandungen. *Z. wiss. Zool.* **14,** 97.

LENHOSSÉK, M. 1894. *Beiträge zur Histologie des Nervensystems.* Y. F. Bergmann, Wiesbaden.

LEONTOWITSCH, A. (1906) Zur Frage der Gefäßinnervation bei Rana esculenta. *Internat. Mschr. Anat. Physiol.* **23,** 1.

LEONTOWITSCH, A. (1930) Über die Ganglienzellen der Blutgefäße. *Z. Zellforsch.* **11,** 23.

LERICHE, R. (1914) Über die Dehnung und Durchschneidung der perivaskulären Nerven etc. *Dtsch. Z. Chir.* **132,** 88.

LERICHE, R. (1920) Effets de la sympathectomie péricarotidienne interne etc. *Presse méd.* **301.**

LERICHE, R. (1920) Traitement de certains ulcérations spontanées des moignons par la sympathectomie périart. *Presse méd.* 765.

LERICHE, R. 1943. *Physiologie pathologique et chirurgie des artères: principes et méthodes.* Masson et Cie., Paris.

LEVER, J. D., BOYD, J. D. and LEWIS, P. R. (1957) The fine structure of the carotid body glomus cells in the rabbit. *J. Anat. (Lond.)* **91,** 594.

LEVER, J. D., LEWIS, P. R. and BOYD, J. D. (1959) Observations on the fine structure and histochemistry of the carotid body in the cat and rabbit. *J. Anat. (Lond.)* **93,** 478.

LEVER, J. D., MUMTAZUDDIN, A. and IRVINE, G. (1965) Neuromuscular and intercellular relationships in the coronary arterioles. A morphological and quantitative study by light and electron microscopy. *J. Anat. (Lond.)* **99,** 829.

LIACHOVETZKY, S. M. (1939) On the innervation of the pia mater of the human brain. *Arch. Anat. (Moscow)* **20,** 84.

LIEK, E. (1925) Kritische Bemerkungen zur heutigen Sympathicus-Chirurgie. *Arch. klin. Chir.* **137,** 220.

LJETNIK, S. (1925) Die Verteilung der Nervengeflechte in der Adventitia der Gefäße. Zur Frage der periarteriellen Sympathectomie. *Anat. Anz.* **59,** 467.

LUCA SAMUEL, CH. 1810. *Quaedam observationes anatomicae circa nervos arterias adeuntes et comitantes.* H. L. Broenner Frankfurt.

LUISADA, A. A. 1961. *Development and structure of the cardiovascular system.* McGraw-Hill, London.

LUSCHKA, H. (1862) Über die drüsenartige Natur des sogenannten Ganglion intercaroticum. *Arch. Anat. Physiol.* 405.

LYON, E. P. (1926) A study of the circulation, blood pressure and respiration of sharks. *J. gen. Physiol.* **8,** 279.

LYSSENKOW, N. K. (1939) On the morphology of Hering's sinus nerve. *Sechenov physiol. J. USSR* **27,** 166.

MAILLET, M. (1953) Le réseau sympathique terminal du rein (Rana escul.) *C. R. Ass. Anat.* **74,** 474.

MARCUS, H. (1909) Über den Sympathicus. *Sitzungsber. Ges. Morph. Physiol. München* **1.**

MARIO P. and DOMINGO, A. (1962) Stimulation of aortic chemoreceptors by ganglion stimulants. *Arch. int. Pharmacodyn.* **140,** 259.

MARTINEZ, G. M. (1939) Contribucion a la histologia normal y patologica del glomo carotideo. *Bol. Soc. Biol. Conception* **13,** 107.

MASSAGLIA, A. (1916) Über die Funktion der sogenannten Carotisdrüse. *Frankfurt. Z. Path.* **18,** 333.

MATHEW, A. P. (1944) Ductus caroticus in the pigeon. *Curr. Sci.* **13,** 213.

MAWAS, J. (1952) Sur l'innervation vaso-motrice de la chorioide. *C. R. Ass. Anat.* **38,** 679.

MCDOWALL, R. S. J. (1962) The function of the carotid sinus. *Arch. int. Pharmacodyn.* **140,** 168.

MCNAUGHTON, F. L. (1938) The innervation of the intracranial blood vessels and dural sinuses. *Res. Publ. Ass. nerv. ment. Dis.* **18,** 178.

MEYER-ARENDT, J. (1948) Zur Pathohistologie der Nervenendigungen im Glomus caroticum. *Frankfurt. Z. Path.* **59,** 389.

MEYLING, H. A. (1936) The glomus caroticum and sinus caroticus of the horse. *Proc. Acad. Sci. (Amst.)* **39,** 706.

MEYLING, H. A. (1936) Bau und Innervation von Glomus caroticum und Sinus caroticus. Eine Untersuchung unter Benützung spezifischer Nervenfärbungsmethoden. *Acta neerl. Morph.* **1,** 193.

MEYLING, H. A. (1938) Bau und Innervation von Glomus caroticum und Sinus caroticus. Eine Untersuchung unter Benutung specifischer Nervenfärbungs Methoden. *Acta neerl. morph.* **1,** 193.

MEYLING, H. A. (1955) Structure and significance of the peripheral extension of the autonomic nervous system. *J. comp. Neurol.* **99,** 495.

MEYLING, H. A. (1955) Das periphere Nervennetz und sein Zusammenhang mit den ortho- und parasympathischen Nervenfasern. *Acta neuroveg. (Wien)* **6,** 35.

MICHAILOW, S. (1908) Zur Frage über die Innervation der Blutgefäße. *Arch. mikr. Anat.* **72,** 540.

MICHAILOW, S. S. (1965) Einige Gesetzmäßigkeiten der afferenten Innervation der extra- und intracranialen Venenbildungen. *Acta morph. Acad. Sci. hung.* **13,** 217.

MICHELAZZI, M. (1934) Sull' innervazione dei vasi cerebrali. *Pathologica* **26,** 203.

MICHELAZZI, M. (1934) Particolare reperto nell'innervazione delle arterie cerebrali. *Pathologica* **26,** 513.

MILLEN, J. W (1948) Observation of the innervation of blood vessels. *J. Anat. (Lond.)* **82,** 68

MITCHELL, G. A. G. (1951) The intrinsic renal nerves. *Acta anat. (Basel)* **13,** 1.

MITSUI, S. (1929) Studies on the nerves of the blood vessels. *J. Orient. Med.* **10,** 49.

MÖLLMANN, H. (1966) Beitrag zur Kenntnis der Pressoreceptoren an der Wand des Truncus pulmonalis (Kaninchen). *Z. mikr.-anat. Forsch.* **74,** 274.

MOORE, D. M. and RUSKA, H. (1956) The fine structure of capillaries and small arteries. *J. biophys. biochem. Cytol.* **3,** 457.

MOOTZ, W. O. (1965) Lichtmikroskopische Untersuchungen zur Innervation der Pfortader der weißen Ratte. *Z. mikr.-anat. Forsch.* **73,** 462.

MORISON, A. (1898) On the innervation of intracranial blood vessels. *Edinb. med. J.* **4,** 413.

MORISON, A. (1898) The innervation of intracranial blood vessels. *Lancet* **2,** 52.

MOTT, J. C. (1949) The gross anatomy of the blood vascular system of eel. (Anguilla anguilla). *Proc. Zool. Soc. (Lond.)* **120,** 503.

MÜLLER, L. R. and GLASER, W. (1913) Über die Innervation der Gefäße. *Dtsch. Z. Nervenheilk.* **46,** 325.

MURATORI, G. (1932) Innervazione del glomo carotico studiata sperimentalmente. *Boll. Soc. ital. Biol. sper.* **7,** 1143.

MURATORI, G. (1932) Contributo all'innervazione del tessuto paragangliare annesso al sistema del vago e all'innervazione del seno carotideo. *Anat. Anz.* **75,** 115.

MURATORI, G. (1933) Contributo istologico allo studio dei riflessi aortici e della carotide. *Boll. Soc. ital. Biol. sper.* **8,** 1.

MURATORI, G. (1933) Ricerche istologiche sull'innervazione del glomo carotico. *Arch. ital. Anat. Embriol.* **30,** 573.

MURATORI, G. (1934) Contributo istologico all'innervazione della zone arteriosa glomo-carotidea. *Arch. ital. Anat. Embriol.* **33,** 421.

MURATORI, G. (1937) Contributi morfologici allo studio dei recettori aortico-arteriosi dei riflessi cardio-pressoregulatori. *Arch. ital. Anat. Embr.* **38,** 387.

MURATORI, G. (1962) Histological observations on the cervico-thoracic paraganglia of Amniotes. *Arch. int. Pharmacodyn.* **140,** 217.

MUYLDER, C. G. DE 1952. *The neurility of the kidney.* Blackwell Sc. Publ., Oxford.

NAATANEN, E., ERIKSON, S. and KALTIOKALLIO, K. (1952) Some observations on the formation and topography of the portal vein. *Med. Anthropol. (Helsinki)* **32,** 11.

NAKAYA, T. (1942) Über die feineren Gefäße in der Niere und ihre funktionelle Bedeutung. *Jap. J. med. Sci. Anat.* **9,** 107.

NAKAYAMA, K. (1961) Die Chirurgie des Glomus caroticum bei Asthma bronchiale. *Münch. med. Wschr.* **103,** 181.

NAPOLITANO, M. (1954) The innervation of the ocular blood vessels in the cat. *Anat. Rec.* **118,** 332.

NEIL, E. and ZOTTERMAN, Y. (1950) Cardiac vagal afferent fibres in the cat and the frog. *Acta physiol. scand.* **20,** 160.

NEIL, E. (1954) The carotid and aortic vasosensory areas. *Arch. middl. Hosp.* **4,** 16.

NEIL, E. (1957) *Chemoreceptors and circulation.* In R. J. S. MCDOWALL's "*Circulation of the blood.*" Longmans Green, London.

NELEMANS, F. A. and DOGTERUM, J. (1955) Structure and function of the peripheral autonomic nervous system. *Acta neuroveg. (Wien) Suppl.* **6,** 101.

NESTEROWSKY, J. (1875) Über die Nerven der Leber. *Virchows Arch. path. Anat.* **63,** 412.

NIKIFOROWSKY, P. M. (1913) On depressor nerve fibres in the vagus of the frog. *J. Physiol. (Lond.)* **45,** 459.

NONIDEZ, J. F. (1935) The aortic (depressor) nerve and its associated epitheloid body, the glomus aorticum. *Amer. J. Anat.* **57,** 259.

NONIDEZ, J. F. (1935) The presence of depressor nerve in the aorta and carotid of birds. *Anat. Rec.* **62,** 47.

NONIDEZ, J. F. (1936) Observations on the blood supply and the innervation of the aortic paraganglion of the cat. *J. Anat. (Lond.)* **70,** 215.

NONIDEZ, J. F. (1936) The nervous "terminal reticulum". A critique. I. Observations on the innervation of the blood vessels. *Anat. Anz.* **82,** 348.

NONIDEZ, J. F. (1937) The nervous "terminal reticulum". A critique. III. Observations on the autonomic ganglia and nerves with special reference to the problem of the neuro-neuronal synapse. Concluding remarks. *Anat. Anz.* **84,** 315.

NONIDEZ, J. F. (1937) Identification of the receptor areas in the venae cavae and pulmonary veins which initiate reflex cardiac acceleration. (Bainbridge's reflex.) *Amer. J. Anat.* **61,** 203.

NONIDEZ, J. F. (1937) Distribution of the aortic nerve fibres and the epitheloid bodies (supracardial "paraganglia") in the dog. *Anat. Rec.* **69,** 299.

NOTHNAGEL, H. (1867) Die vasomotorischen Nerven der Gehirngefäße. *Virchows Arch. path. Anat.* **40,** 203.

OBERSTEINER, H. (1895) Die Innervation der Gehirngefäße. *Arb. neurol. Inst. Univ. Wien* **5,** 116.

OBERSTEINER, H. (1897) Die Innervation der Gehirngefäße. *Arb. neurol. Inst. Univ. Wien.* **16,** 215.

ODERMATT, W. (1922) Die Schmerzempfindlichkeit der Blutgefäße und die Gefäßreflexe. *Bruns' Beitr. klin. Chirurg.* **127,** 1.

OHMORI, D. (1924) Über die Entwicklung der Innervation der Genitalapparate als peripheren Aufnahmeapparat der genitalen Reflexe. *Z. Anat. Entwickl.-Gesch.* **70,** 347.

OKAMURA, CH. (1930) Über den Nervenapparat der Gefäßwand. *Z. Anat. Entwickl.-Gesch.* **91,** 528.

OOI, H. (1934) Beiträge zur histologischen Forschung über die vasomotorischen Nerven in den spezifischen Blutgefäßen I. Über die Innervation vasomotorischer Nerven in den Hirnblutgefäßen. *Mitt. med. Akad. Kioto* **10,** 729.

OOI, H. (1934) Beiträge zur histologischen Forschung über die vasomotorischen Nerven in den spezifischen Blutgefäßen. II. Über das Verhalten der Nerven in den Nabelschnurgefäßen. *Mitt. med. Akad. Kioto* **10,** 736.

ORTMAN, R. (1959) Allgemeine Anatomie der Herz- und Gefäßnerven. *Verh. dtsch. Ges. Kreisl.-Forsch.* **25,** 15.

OSOLIN, P. (1930) Über den mikroskopischen Aufbau der Blutgefäße bei den Vögeln. *Z. mikr.-anat. Forsch.* **21,** 157.

OSTERMANN, E. (1952) *Mikroskopische Untersuchungen über die Carotisdrüse des Rindes.* Inaug. Diss. Mainz.

PALKAMA, A. and HOPSU, V. K. (1965) The presence of a carotid body-like structure between the right subclavian and common carotid arteries. *Ann. Med. exp. Fenn.* **43,** 169.

PALME, F. (1934) Die Paraganglien über dem Herzen und im Endigungsgebiet des Nervus depressor. *Z. mikr.-anat. Forsch.* **36,** 391.

PALME, F. (1935) Über ein verlagertes Epithelkörperchen des Menschen am Paraganglion supracardiale. *Anat. Anz.* **79,** 288.

PALME, F. (1944) Zur Funktion der brachiogenen Reflexzonen für Chemo- und Pressoreception. *Z. ges. Med.* **113,** 415.

PALUMBI, G. (1940) La fine vascolarizzazione ed innervazione del glomo carotideo dei mammiferi. *Comment. pontif. Acad. Sci.* **4,** 289.

PANSINI, A. (1952) Le espansioni nervose pericarotidee in feti umani a termine. *Quad. Anat. prat.* **7,** 73.

PANSINI, A. (1953) Espansioni nervose pericarotidee in feti umani a termine. *Monit. zool. ital.* **61,** 285.

PARKER, F. (1958) An electron microscopic study of coronary arteries. *Amer. J. Anat.* **103,** 247.

PASTORI, G. (1929) Ein bis jetzt noch nicht beschriebenes sympathisches Ganglion und dessen Beziehungen zum Nervus conari sowie zur Vena magna Galeni. *Z. Neurol.* **123,** 81.

PAUNCZ, L. (1923) Pathologisch-anatomische Veränderungen der Carotisdrüse. *Virchows Arch. path. Anat.* **241,** 76.

PENFIELD, W. (1932) Intracerebral vascular nerves. *Arch. Neurol. Psychiat. (Chic.)* **27,** 30.

PENFIELD, W. (1935) A technique for demonstrating the perivascular nerves of the pia mater and cerebral nervous system. *Amer. J. Path.* **11,** 1007.

PENFIELD, W. and MCNAUGHTON, F. (1940) Dural headache and innervation of the dura mater. *Arch. Neurol.* **44,** 43.

PENITSCHKA, W. (1930) Paraganglion aorticum. *Med. Klin.* **26,** 1312.

PENITSCHKA, W. (1931) Vorweisungen von Paraganglion verschiedener Art. *Anat. Anz. Ergänzungsh.* **71,** 237.

PENITSCHKA, W. (1931) Paraganglion aorticum supracardiale. *Z. mikr.-anat. Forsch.* **24,** 24.

PESONEN, N. (1953) The microscopic structure of the veins functionally considered. *Med. Anthropol. (Helsinki)* **38,** 10.

PETERSON, L. H. (1962) Some studies of the regulation of cardiovascular functions. *Arch. int. Pharmacodyn.* **140,** 281.

PICKERING, G. W. 1955. *High blood pressure.* Churchill, London.

PINES, J. L. (1924) Über die Innervation des chromaffinen Gewebes des Sympathicus und über das sympathico-chromaffine System im allgemeinen. *Arch. Psychol.* **70,** 636.

PLECHKOVA, E. K. (1936) Receptors of the coronary vessels and of the myocardium in mammals. *Bull. Biol. Méd. exp. USSR.* **1,** 404.

POLLEY, E. H. (1955) The innervation of blood vessels in striated muscle and skin. *J. comp. Neurol.* **103,** 253.

POTTS, L. W. (1915) The distribution of nerves to the arteries of the leg. *Anat. Anz.* **47,** 138.

PURKINJE, J. E. (1836) Über Flimmerbewegungen im Gehirn. *Müllers Arch. Physiol.*

PURKINJE, J. E. (1845) Mikroskopisch-neurologische Beobachtungen. *Müllers Arch. Physiol.* **281.**

RACHMANOW, A. W. (1901) Zur Frage der Nervenendigungen in den Gefäßen. *Anat. Anz.* **19,** 555.

RAMIREZ, A. B. (1956) Experimentelle Studien über die Innervation der kleinen Blutgefäße. *Acta neuroveg. (Wien)* **14,** 133.

RANVIER, L. 1889. *Traité de technique d'histologie.* F. Savy, Paris.

REISER, K. A. (1932) Der Nervenapparat im Processus vermiformis nebst einigen Bemerkungen über seine Veränderungen bei chronischer Appendicitis *Z. Zellforsch.* **15,** 761.

REISER, K. A. (1938) Die Neuronenlehre im Lichte neuerer histologischer Forschung. *Dtsch. med. Wschr.* **64,** 487.

REISER, K. A. (1952) Bemerkungen zum Feinbau der vegetativ-nervösen Peripherie. *Acta neuroveg. (Wien)* **4,** 179.

REMAK, R. 1844. *Observationes anatomicae et microscopicae de systematis nervosi structura* Berolini Reimerianis.

RHODIN, J. A. G. (1962) Fine structure of vascular walls in mammals with special reference to smooth muscle component. *Physiol. Rev. Suppl.* **42,** 43.

RIEGELE, L. (1928) Die Nerven des Glomus caroticum beim Menschen mit kurzer Übersicht über den histologischen Aufbau des Organs. *Z. Anat. Entwickl.-Gesch.* **86,** 124.

RIEGELE, L. (1932) Die Bedeutung des reticulo-endothelialen Syncytiums als Scheidenplasmodium des fibrillären nervösen Endnetzes in Leber, Milz und Nebenniere. *Z. Zellforsch.* **15,** 311.

RIJNDERS, H. (1933) Über das Nervenmaterial in der Wand des Bulbus caroticus. *Acta brev. neerl. physiol.* **3,** 22.

ROBERTS, J. T. 1959. *Arteries, veins and lymphatic vessels of the heart.* In A. A. LUISADA: *Cardiology,* I. McGraw-Hill Book Co., New York.

ROSS, L. (1957) An electron microscopic study of carotid body chemoreceptors. *Anat. Rec.* **127,** 481.

ROSS, L. (1958) A cytological and histological study of the carotid body of the cat. *Anat. Rec.* **129,** 433.

ROSS, L. and HUNT, T. E. (1954) Histochemical study of the carotid body of the rat and cat. *Anat. Rec.* **118,** 436.

ROSSATTI, B. and D'AGOSTINI, N. (1953) Effetti legatura dell'arteria carotide commune sulla circolazione sanguina e sulla struttura del glomo carotideo. *Arch. Sci. biol. (Bologna)* **37,** 496.

ROSSI, O. (1922) On the afferent paths of the sympathetic nervous system. *Journ. Comp. Neurol.* **34,** 493.

RUSSEL, H. (1942) Notes on the carotid body. *Edinb. med. J.* **49,** 366.

RUSSU, I. G. and VAJDA, N. (1963) Der nervöse Endapparat der reflexogenen Blutgefäßzonen. *Acta anat. (Basel)* **54,** 32.

SAMARASINGHE, D. D. (1965) The innervation of the cerebral arteries in the rat: an electron microscope study. *J. Anat. (Lond.)* **99,** 815.

SANTY, P. and MARION, P. (1951) A propos de l'innervation des artères coronaires. *Lyon chir.* **46,** 474.

SARTER, J. (1957) Beitrag zur normalen und pathologischen Histologie der Endausbreitung des vegetativen Nervensystems. *Acta anat. (Basel)* **30,** 681.

SCHABADASCH, A. (1930) Intramurale Nervengeflechte des Darmrohrs. *Z. Zellforsch.* **10,** 321.

SCHALTENBRAUD, G. 1955. *Plexus und Meningen.* In W. MÖLLENDORFF: *Handbuch der mikroskopischen Anat. des Menschen.* IV/2. 1. Springer, Berlin.

SCHAPER, A. (1892) Beiträge zur Histologie der Glandula carotica. *Arch. mikr. Anat.* **40,** 287.

SCHAPIRO, B. (1931) Über die Innervation des Plexus chorioideus. *Z. Neurol.* **136,** 539.

SCHARF, J. H. (1951) Die Paraganglien am Ganglion nodosum vagi und dessen Umgebung beim erwachsenen Menschen. *Z. Zellforsch.* **36,** 141.

SCHIMERT, J. (1937) Untersuchungen über den Ursprung und die Endausbreitung der Nerven der Iris. *Z. Zellforsch.* **25,** 247.

SCHIMERT, J. (1938) Die "Syncytielle Natur" des vegetativen Nervensystems. *Z. mikr.-anat. Forsch.* **44, 85.**

SCHMID, H. (1929) Anatomischer Bau und Entwicklung der Plexus chorioidei in der Wirbeltierreihe und beim Menschen. *Z. mikr.-anat. Forsch.* **16,** 413.

SCHMIDT, C. H. and COMROE, J. H. (1940) Functions of the carotid and aortic bodies. *Physiol. Rev.* **20,** 115.

SCHNEIDER, R. (1950) Über die Beziehungen der Epithelkörperchen zum Glomus caroticum der Vögel. *Anat. Anz. Ergänzungsh.* **97,** 189.

SCHNEIDER, R. (1951) Über die Beziehungen zwischen Epithelkörperchen und Glomus caroticum bei verschiedenen Vogelarten. *Z. mikr.-anat. Forsch.* **57,** 104.

SCHÖNBACH, G. and LANGENDORF, H. (1955) Das Verhältnis von Innenradius und Wandstärke in den kleinen Blutgefäßen. *Abhandl. Math. naturwiss. Kl. (Mainz)* 159.

SCHUMACHER, S. v. (1938) Über die Bedeutung der arteriovenösen Anastomosen und der epitheloiden Muskelzellen. *Z. mikr.-anat. Forsch.* **43,** 107.

SCHWALEW, V. N. (1965) Actual problems of morphology and nature of the nervous apparatus of kidney. *Arch. Anat. Gistol. Embriol.* **49,** 7, 54.

SCHWARZ-KARSTEN, H. (1944) Die Entwicklung des Paraganglion caroticum und der Paraganglien am Herzen des Schweines. *Z. Anat. Entwickl.-Gesch.* **113,** 39.

SETO, H. (1935) Über zwischen Aorta und Arteria pulmonalis gelegene Herzparaganglien *Z. Zellforsch.* **22,** 213.

SHARPEY-SCHAFER, E. (1921) L'innervation des vaisseaux pulmonairs. *Arch. int. Physiol.* **18,** 14.

SLEPKOW, J. J. (1952) Die sensible Innervation der Vasa vasorum der Aorta thoracalis des Menschen. *Dokl. Akad. Nauk. SSSR* **86,** 1173.

SMIRNOW, A. E. (1901) Über die Nervenendigungen in der Niere. *Anat. Anz.* **19,** 347.

SNESSAREW, P. (1929) Über die nervösen Elemente der Pia mater im Gebiet der Medulla oblongata des Menschen. *Z. Anat. Entwickl.-Gesch.* **90,** 768.

SNESSAREW, P. (1929) Über die Pigmentzellen Piae matris beim Menschen, ihren Zusammenhang mit den Nervenfasern, ihre Genese und Function. *Z. Zellforsch.* **9,** 683.

SPRENKEL, H. B. VAN 1934. *Sympathisches Nervensystem-Paraganglien, Glomus caroticum.* In L. BOLK, E. GÖPPERT: *Handbuch der vergleichenden Anatomie.* 2. Urban und Schwarzenberg. Berlin–Wien.

STAHL, O. (1926) Spätergebnisse der periarteriellen Sympathectomie. *Dtsch. Z. Chir.* **197,** 280.

STERLING, E. W. 1957. *Plastic arterial grafts.* Thomas, Springfield, Ill.

STÖHR, PH. (1921) Über die Innervation der Pia mater und des Plexus chorioideus des Menschen. *Z. Anat. Entwickl.-Gesch.* **63,** 565.

STÖHR, PH. (1922) Beobachtungen über die Innervation der Pia mater des Rückenmarkes und der Telae chorioideae des Menschen. *Z. Anat. Entwickl.-Gesch.* **64,** 555.

STÖHR, PH. 1928. *Das Peripherische Nervensystem.* In W. MÖLLENDORFF: *Handbuch der mikroskopischen Anat. des Menschen.* IV/1. **202.** Springer, Berlin.

STÖHR, PH. (1930) Mikroskopische Studien zur Innervation des Magen-Darmkanals. *Z. Zellforsch.* **12,** 66.

STÖHR, PH. (1932) Mikroskopische Studien zur Innervation des Magen-Darmkanals. II. Über die Nerven des menschlichen Magens und ihre Veränderungen beim Ulcus. *Z. Zellforsch.* **16,** 123.

STÖHR, PH. (1933) Mikroskopische Beobachtungen über die Nerven der Blutgefäße. *Fortschr. dtsch. Wiss.* **9.**

STÖHR, PH. (1933) Mikroskopische Anatomie der Gefäßnerven. *Verh. dtsch. Ges. Kreislaufforsch.* **51.**

STÖHR, PH. (1933) Zur Nervenversorgung der Blutgefäße. *Dtsch. med. Wschr.* **59,** 1625.

STÖHR, PH. (1935) Beobachtungen und Bemerkungen über die Endausbreitung des vegetativen Nervensystems. *Z. Anat. Entwickl.-Gesch.* **104,** 133.

STÖHR, PH. (1935) Observations anatomiques sur l'innervation des vaisseaux sanguins. *Bull. Soc. franç. Derm. Syph.* **42,** 1165.

STÖHR, PH. (1938) Die mikroskopische Innervation der Blutgefäße. Zeitschr. ges. Anat. 3. *Ergebn. Anat. Entwickl.-Gesch.* **32,** 1.

STÖHR, PH. (1939) Über den Bau sensibler Nervenendigungen in der Pia mater des Menschen. *Z. Zellforsch.* **30,** 78.

STÖHR, PH. (1939) Über "Nebenzellen" und deren Innervation in Ganglien des vegetativen Nervensystems, zugleich ein Beitrag zur Synapsenfrage. *Z. Zellforsch.* **29,** 569.

STÖHR, PH. (1941) Zusammenfassende Ergebnisse über die normale und pathologische Histologie der sympathischen Ganglienzellen und der Endapparate im vegetativen Nervensystem. *Z. Anat. Entwickl.-Gesch.* **33,** 135.

STÖHR, PH. (1948) Mikroskopische Studien zur Innervation des Magen-Darmkanals. *Z. Zellforsch.* **34,** 1.

STÖHR, PH. (1950) Bemerkungen über die Endigungsweise des vegetativen Nervensystems und über den Aufbau des Organismus. *Acta neuroveg. (Wien)* **1,** 74.

STÖHR, PH. (1950) Innervation der Blutgefäße. *Nauheimer Fortbildungs-Lehrgänge.* **15,** 1.

STÖHR, PH. (1954) Zusammenfassende Ergebnisse über die Endigungsweise des vegetativen Nervensystems. *Acta neuroveg. (Wien)* **10,** 21.

STRAUSS, E. (1940) Bedeutung der Druckamplitude und des Herz-Reflexes für die reflektorische Selbststeuerung des Kreislaufes. *Arch. Kreisl.-Forsch.* **6,** 65.

STRESEMAN, E. 1927/34. *Zirkulationsorgane (Sauropsida).* In KÜKENTHAL W.–KRUMBACH, I.: *Handbuch der Zoologie.* VII/2. 200. De Gruyter and Co., Berln–Leipzig.

SUNDER-PLASSMANN, P. (1930) Untersuchungen über den Bulbus carotisibei Mensch und Tier im Hinblick auf die "Sinusreflexe" nach H. E. HERING. Ein Verg eich mit anderen Gefäßstrecken; die Histopathologie des Bulbus carotidis des Glomus calroticum. *Z. Anat. Entwickl.-Gesch.* **93,** 567.

SUNDER-PLASSMANN, P. (1933) Der Nervenapparat des Sinus caroticus und des Glomus caroticum vom Menschen der verschiedenen Altersstufen und Foetus humanus, von verschiedenen Tieren und von Kaninchen vor und nach Durchschneidung des Sinusnerven. *Verh. dtsch. Ges. Kreisl.-Forsch.* **69,** 3.

SUNDER-PLASSMANN, P. 1953. *Sympathicus Chirurgie.* G. Thieme, Stuttgart.

SZENTÁGOTHAI, J. (1957) Einige Bemerkungen zur Struktur der peripheren Endausbreitung vegetativer Nerven. *Acta neuroveg. (Wien)* **15,** 41.

TAKINO, M. (1933) Vergleichende Studien über die Struktur der Arteriae und Venae pulmonales, die Blutgefäßnerven der Lunge und die Nerven der Bronchien bei verschiedenen Tierarten, besonders über die Beziehung der Blutgefäßnerven zu den glatten Muskeln der Blutgefäße. *Acta Scholae med. Univ. Kioto* **15,** 321.

TAKINO, M. (1933) Über die Innervation der Lungengefäßwand, besonders über das Vorkommen der Ganglienzellen an der Gefäßwand der Venae pulmonales und über die Verbreitungszustände der Lungenblutgefäßnerven bei der Fledermaus. I. Mitteilung. *Acta Sch. med. Univ. Kioto* **15,** 303.

TAKINO, M. (1933) Über die Innervation der Blutgefäße der Lunge beim Vogel (Taube und Haushuhn), besonders über das Vorkommen der Ganglienzellen in oder an der Wand der Venae und Arteriae pulmonales und über die Verbreitung der Blutgefäßnerven daselbst. II. Mitteilung. *Acta Sch. med. Univ. Kioto* **15,** 308.

TAUBERT, J. (1960) Die Plasmastruktur vegetativ-nervöser Endformationen im nativen Einschlußpräparat. *Acta neuroveg. (Wien)* **22,** 71.

TCHENG, K. T. and FU, S. L. (1962) The structure and innervation of the aortic body of the yellow breasted bunting. *Scientia Sinica* **11,** 221.

TCHENG, K. T. and FU, S. K. (1963) Supracardial encapsulated receptors of the aorta and the pulmonary artery in birds. *Scientia Sinica* **12,** 73.

TCHENG, K. T. and FU, S. K. (1963) On the vasculature of the aortic bodies in birds. *Scientia Sinica* **12,** 339.

TCHIBUKMACHER, N. B. (1938) Surgical anatomy of carotid sinus nerve and intercarotid ganglion. *Surg. Gynec. Obstet.* **67,** 740.

Tello, J. F. (1922) Die Entstehung der motorischen und sensiblen Nervenendigungen. *Z. Anat. Entwickl.-Gesch.* **64,** 348.

Tello, J. F. (1924) Développement et terminaison du nerf dépresseur. *Trav. Lab. Rech. Biol. (Madrid).* **22,** 1.

Temesrékási, D. (1955) Die Synaptologie der Dünndarmgeflechte. *Acta morph. Acad. Sci. hung.* **5,** 53.

Temesrékási, D. (1956) Vergleichend-histologische Untersuchungen an den Nervenelementen der Speiseröhre, *Z. mikr.-anat. Forsch.* **62,** 661.

Temesrékási, D. (1959) Untersuchungen über die Degeneration der peripheren vegetativen Endformationen im Bereiche der menschlichen Nasenmuscheln. *Z. mikr.-anat. Forsch.* **65,** 33.

Temesvári, A., Soltész, L. and Robicsek, F. (1955) Chirurgische Behandlung des Raynaud-Syndroms der oberen Extremität. *Chirurg. J.* **26,** 70.

Terni, T. (1927) Il corpo ultimobranchiale degli uccelli. Ricerche embriologiche, anatomiche e istologiche su Gallus dom. *Arch. ital. Anat. Embriol.* **24,** 407.

Terni, T. (1931) Il simpatico cervicale degli amnioti. Ricerche di morfologia comparata. *Z. Anat. Entwickl.-Gesch.* **96,** 289.

Thane, G. D. 1896. In Quain's *Elements of Anatomy.* Longmans, Green Co, London.

Torii, H. (1962) Electron microscopic observations of the s–a and a–v nodes and Purkinje fibers of the rabbit. *Jap. Circulat. J.* **26,** 39.

Torsten, T. (1962) Some biophysical considerations on presso-receptors. *Arch. int. Pharmacodyn.* **140,** 563.

Toussaint, F. J. P. and Toussaint, F. Y. (1959) Essais d'imprégnation du système nerveux trachéo-broncho-pulmonaire chez l'homme et chez l'animal. *Acta tuberc. belg.* **50,** 179.

Truex, R. C. (1936) Sensory nerve terminations associated with peripheral blood vessels. *Proc. Soc. exp. Biol. (N. Y.)* **34,** 699.

Tschernjachiwsky, A. (1929) Note sur le développement du système nerveux du coeur, la terminaison du nerf dépressuer et l'innervation du sinus carotidien. *Trab. Lab. invest. biol. Univ. Madr.* **26,** 75.

Tsuge, K. (1949) The innervation of the carotid body. *No Shinkei.* 1. **369.** (In Japanese).

Vajda, J. (1966) Innervation of lymph vessels. *Acta morph. Acad. Sci. hung.* **14,** 197.

Verity, M. A. and Bevan, J. A. (1962) Distribution of nerve endings in the pulmonary artery of the cat. *Science* **135,** 785.

Vieussens, R. 1716. *Neurographia universalis.* J. Čerte, Lugduni.

Volodka, N. S. (1954) Zur Innervation der vorderen Vena cava bei Hund und Katze. *Arch. Anat. (Moscow)* **3,** 27.

Walter, R. S. 1935. *The anatomy of the nervous system.* Philadelphia–London.

Walter, P. (1956) Das morphologische Verhalten vegetativ-nervöser Elemente im Duodenum des Rindes. *Acta neuroveg. (Wien)* **15,** 79.

Walter, P. (1957) Über das Auftreten von Vakuolen in peripheren vegetativen Nervenfasern bei nativer Einschlußfärbung. *Acta neuroveg. (Wien)* **15,** 215.

Wang, S. C., Mazzella, H. and Heymans, C. (1952) Hemodynamic studies on the carotid sinus pressoreceptive reflex. *Arch. int. Pharmacodyn.* **89,** 114. (1952); **90,** 1.

Watzka, M. (1933) Vergleichende Untersuchungen über den ultimobranchialen Körper. *Z. mikr.-anat. Forsch.* **34,** 485.

Watzka, M. (1934) Vom Paraganglion caroticum. *Anat. Anz. Ergänzungsh.* **78,** 108.

Watzka, M. (1938) Über die Entwicklung des Paraganglion caroticum der Säugetiere. *Z. Anat. Entwickl.-Gesch.* **108,** 61.

Watzka, M. 1943. *Die Paraganglien.* In W. Möllendorff's *Handbuch der mikroskopischen Anatomie des Menschen.* Springer Verlag, Berlin.

Weber, A. (1952) Instabilité des terminaisons nerveuses dans les synapses intracellulaires du système végétatif. *C. R. Soc. Biol. (Paris)* **146,** 883.

White, E. G. (1935) Die Struktur des Glomus caroticum seine Pathologie und Physiologie und seine Beziehung zum Nervensystem. *Beitr. path. Anat.* **96,** 177.

White, J. C., Smithwick, R. H. and Simeone, F. A. 1952. *The autonomic nervous system.* Kimpton, London.

Wiedehopf, O. (1923) Experimentelle Untersuchungen über die Wirkung der periarteriellen Sympathektomie der Extremitäten. *Bruns' Beitr. klin. Chirurg.* **130,** 999.

Williams, D. J. 1935. *The innervation of the cerebral circulation in man.* M. D. Thesis. Univ. Manchester.

Willinger, E. 1964. *Die peri phere Innervation.* Schwalbe et Co. Basel–Stuttgart.

Willis, T. 1964. *Cerebri anatome cui accessit nervorum descriptio et usus.* J. Fischer, London.

WINDER, E. V. (1937) On the mechanism of stimulation of carotid gland, chemoreceptors. *Amer. J. Physiol.* **118,** 389.

WINIWARTER, H. DE (1926) Signification du ganglion carotidien. *C. r. Soc. Biol. Paris,* **94,** 407.

WINIWARTER, H. DE (1934) Origine et signification du ganglion carotidien. *C. r. Assoc. Anat. 29 Réun.* 519.

WINIWARTER, H. DE (1939) Origine et développement du ganglion carotidien. *Arch. Biol. (Paris)* **50,** 67.

WITT, L. DE (1900) Arrangement and terminations of nerves in the oesophagus of mammalia. *J. comp. Neurol.* **10,** 382.

WITZLEB, E. (1953) Über die Erregung der Presso- und Chemoreceptoren in der Carotissinusregion durch l-Adrenalin und l-Noradrenalin. *Pflügers Arch. ges. Physiol.* **257,** 244.

WOLHYNSKI, F. A. (1937) Zur Frage nach der Abhängigkeit des Baues der Bifurkation der Carotis communis und des Sinus caroticus beim Menschen von ihrer Funktion. *Anat. Anz.* **83,** 261.

WOOLLARD, H. H. (1926) The innervation of blood vessels. *Heart.* **13,** 320.

WOOLLARD, H. H., and WEDDEL, G. (1935) The composition and distribution of vascular nerves in the extremities, *J. Anat. (Lond.)* **69,** 165.

WOROBIEW, W. P. 1925. *Methodik der Untersuchungen an Nervenelementen der makro- und makro-mikroskopischen Gebiete.* O. Rothacker, Berlin.

ZIMMERMANN, K. W. (1933) Über den Bau des Glomerulus der Säugetiere. *Z. mikr. anat. Forsch.* **32,** 176.

ZIMMERMANN, A. (1942) A glomus caroticum összehasonlitó anatómiájához (A contribution to the comparative anatomy of the glomus caroticum). *Math. term. tud. Ért.* **60,** 900.

ZLÁBEK, K. (1957) The arrangement of the intraglomerular blood vessels in the kidney. *Rev. Czech. Med.* **3,** 273.

ZWEIFACH, B. W. (1938) A note on the distribution of nerves to the small blood vessels in the mesentery of the frog. *Anat. Rec. Philadelphia. Suppl.* **70,** 104.

AUTHOR INDEX

Ábrahám 1, 23, 30, 89, 107, 133, 179, 204, 209, 325, 334, 361
Adams 286, 332
Aeby 106
Agababow 177
Akkeringa 107, 121, 206
Andersch 88
Anghy 1
Arnold 176, 337
Arnstein 177
Aschoff 106

Bakay 183
Ballowitz 177
Barbsdale 206
Bayliss 175
Beale 176, 206
Beaufays 180
Becher 363
Benninghoff 107, 116–7
Beremer 206
Berends 86
Bergglas 175
Berkelbach 326
Bernard, Claude 365
Bersch 251, 252
Bethe 209
Bielschowsky 2, 5, 23
Billingsley 327
Bodian 1
Boeke 55, 107, 133, 179, 182–3, 185, 201, 206
Bonivento 180
Borowskaya 180–1, 189–90
Botezat 206
Bouckaert 338
Bourgery 88
Brachet 365
Bräunig 106
Bremer 177
Brettschneider 183, 189, 190
Breucker 87, 175
Brodie 179
Brüning 175
Bullard 117
Bulion 189
Burkitt 201
Busch 174–5, 178, 192, 196, 206

Cajal, Ramòn y 1, 6, 23, 177, 333
Castro, de 206, 283, 291, 325–6, 332, 335, 337
Cauna 1, 5, 89
Ceccherelli 206
Chabarova 107, 138, 160
Ciaccio 176, 206
Clara 204
Clark 179, 206
Clermont 332
Csermely 1
Currey 116
Cyon 88

Demoor 133
Dixon 179
Dogiel 177–9, 201, 254
Dokov 373
Doležel 6, 361
Don 206
Drummond 86
Duckworth 107
Dumont 128, 130

Eich 201
Engel 107, 127
Erdélyi 133
Esveld, Van 180
Eversbusch 111

Fahr 106
Fallopius 85–6
Flack 106, 111
Francillon 161
Fukutake 133, 177

Gad 177, 206
Galen 85
Gask 175
Gaskell 106
Géraudel 107, 109, 116
Gerneck 206
Gerebtzoff 9, 128, 130
Gieson, van 9
Glaser 177, 206, 209
Goering 174, 178

Gömöri 363
Goormaghtigh 335, 363
Greving 166, 182
Grigorjeva 373
Gros 1–2, 5, 23, 89
Grosser 204
Grünhagen 206
Gurwitsh 107

Haas 107
Hadjioloff 373
Hahn 175
Haller 86, 321
Halpern 108
Harting 180
Hass 116
Hayashi 180
Heppner 326
Hering 275, 304
Herzog 182
Heymans 177, 286, 338
Hill 180
Hinsey 206
Hippocrates 106
Hirsch 175, 177
Hirschfeld 86, 88
His 106–7, 176, 206
Hofmann 133, 177
Holl 107, 115
Hollinshead 332–3
Holmes 133
Hoshi 133
Hovelaque 86, 88
Hunczer 175

Iwanow 180

Jabonero 1, 23, 89, 183, 185, 187, 189
Jansky 358
Jaques 39
Jensen 365
Jone 133
Joris 206

Kappis 175
Keifer 202
Keith 106–7, 111
King 115
Kirsche 30–31, 41, 166
Klein 206
Klug 337
Knoche 183, 189, 361, 363, 365
Koch 107–8, 116–7, 254, 260
Kock, de 325, 332–3, 335
Koelliker 106, 176
Kolmer 179
Kolossow 180
Kondratieff 175
Korpássy 1
Kose 337
Kostowieczki 201
Kramer 175, 177
Krause 34
Krimke 206
Kroetz 179
Krümmel 179
Kuntz 108
Kytmanoff 177

Lange 107
Langley 175
Lansilotta 337
Lapinsky 177, 191
Lasowskaya 107
Lawrentiew 107, 111, 133, 169, 180–1, 183, 189, 190, 206
Lehmann 176
Leonardo da Vinci 115
Leontowitsch 177
Leriche 175
Lipmann 176
Ljetnik 175
Luca 174
Luschka 321, 326

Machus 175
Mackenzie 107
Mallory 9, 108
Marchand 179, 325–6
Martinez 332
Masson 204
McMurrich 88
Meiklejohn 107
Melichow 175
Meyling 107, 121–2, 183, 187, 206, 310, 325, 332, 335
Michelazzi 201
Michelis 206
Michailow 39, 133, 177, 206
Millen 175, 178, 192, 201, 206
Mitchell 86–7, 361, 364, 365
Mohr 128, 130
Mollard 86, 88
Mönckeberg 107, 109
Morison 107, 127
Muir 108
Müller 88
Mullon 337
Muratori 275–6, 319
Muylden, de 361, 363–4

Neil 338
Nesterowsky 206
Neubauer 86
Niedermüller 333
Nonidez 107, 181, 206, 212, 275–7, 319, 321

Ohno 206
Ohmori 115
Okada 133
Oltványi 363
Onescu 87
Operchowsky 39
Oppenheimer 107, 111
Ostermann 332
Ottaviani 180

Pacini 201, 204
Permann 254
Petersen 107
Pines 179
Pinsky 179
Pletchkova 107
Potts 175
Purkinje 105, 173

Rachmanow 201
Radostina 180
Ranson 1, 6
Ranvier 39, 106, 176
Rein 175
Reiser 180, 182, 201
Remak 86, 173
Renon 117
Retzer 106
Reynier 86, 88
Rieder 175
Riegele 180, 325–6
Romanes 1, 6
Roos 175
Ross 336
Rossi 179

Sabussow 180
Saccomanno 87
Sappey 88
Sato 133, 332
Scarpa 86, 88
Schadabasch 1, 180, 206
Schaefer 107, 113, 120
Schandler 107
Schaper 325
Schiebler 131
Schief 175
Schimmert 189
Schinde 115
Schoeneberg 109
Schumacher 204
Schwalbe 88
Senac 86
Seto 3, 107, 121–2, 135, 166, 260, 341
Siehler 177, 206
Smirnov 39, 133, 177, 362, 364–5
Sobotta 88
Spalteholz 109, 116
Sprenkel, Van 326
Stahl 175
Stilling 337
Stöhr 107, 133, 176–9, 180, 182, 189, 192, 199, 201–2, 204, 206, 208–9, 222, 347, 366
Sunder-Plassmann 180, 206, 291, 325, 337
Swann 87–8
Szentágothai 183, 185

Tandler 115
Tardieu, C. 88
Tardieu, G. 88
Taubert 183, 189
Tawara 106–7
Tchakharoff 373
Tcheng 56
Temesrékási 183, 187
Thane 86
Tinel 88
Todd 177
Tomas 206

Ungar 116

Valentin 88
Vesalius 85
Vieussens 86

Wakefield 116
Walter 86, 88, 182–3, 189
Wassermann 201
Watzka 321, 325–6, 332
Wearn 116
Weber 87
Wenkebach 106
White 332
Wiederhopf 175
Wilkinson 201, 206
Willis 86
Wilson 107, 327
Wiltner 333
Winiwarter, de 332
Witi 254
Witt, de 133
Wolhinsky 107
Woollard 107, 178, 191–2, 202, 206
Worobiew 175

Yamanda 108
Yoshitoshi 201

Zimmermann 107, 109, 332, 363
Zschiesche 116
Zwaifach 206

SUBJECT INDEX

Ábrahám's procedure 5
Accessory cells 332
"Accessory glomus" (-era) 338–9
Acetylcholinesterase
  activity
    in nerve plexus Fig. 23
    localization 83
  in buffalo 128
  in calf 128
  in guinea pig 128
  in horse 128
  in rabbit 128
  in stimulus-conducting system 128
  positive
    nerve trunk 129
  reaction Fig. 76
    in Aschoff–Tawara nodule 130
      atrioventricular bundle 131
      sinoatrial node 128
    on nerve cells Fig. 75
Adventitia *(see also* Tunica adventitia) 4, 176–9, 194–6, 204, 209, 232, 269, 271, 276, 278, 281, 288, 290, 341, 343, 345, 347, 357–9, 361, 364, 367, 369
  in amphibia 23
    bony fishes 9
    reptiles 46
    veins 201
  of cerebral arteries 367
    heart bulb 158
  sensory elements 18
Adventitial area 347
Adventitial plexus of vessels 369
"Afferent terminal reticulum" 363
Albino rat 189, 358
  cerebral vessels 366
Amphibia 22–3
  atrial septum 26–34
  atrium 24
  ganglia 41
  heart 22
  heart bulb 22, 37
  intracardiac nerve fibres 39
  pericardium 43
  receptors 158
  sensory endings 156
  venous sinus 22
  ventricle 22
Anamnia 187
Anas domestica Figs. 43, 48
Anastomoses
  arteriovenous, in mammals 204
  in end plates 278, 308
  peripheral 187
Anatomy of heart nerves 86
Anulus fibrosus in mammals 115
Aorta 217, 267, Fig. 193
  in mammals 88
Aortic arch 88, 113, 153, 196, 201, 211, 215, 219, 230, 233, 251, 260, 263, 270–1, 285–6, 317, 319, 340–1, Figs. 113, 116, 123, 125–6, 131, 134, 137, 139, 142, 156–63, 165, 204, Plates I, II, III, V
  cholinesterase activity 273
  in calf 236
  in mammals 86
  in man 260–75
Aortic fibres
  in dog 196, 215
  in man 260–73
  in pig 219–20
Aortic nerve 230
  bundle 215
Aperture 8
Apoplexia 311
Apparatus
  interoceptive 83
  juxtaglomerular 363
Apteryx (Owen) 74
Arcus arteriosus 361
Ardea cinerea Figs. 47, 118, 203
Argentophilia 54, 298, 313
  in connective tissue 104
  in ganglion cells 353
  in reptiles 54
  of nerve fibres in adventitia 353
  of processes of cells 90
  of vagal system 353
  vena cordis magna 353
Arrectores plumarum Figs. 107–8
Arteria *(see also* Artery)
  anonyma 254, Fig. 166
    dextra Fig. 124
  basilaris 368–9
  brachiocephalica 219
  carotis cerebralis 369, Fig. 219
    communis 254
  cerebri anterior 368
    media 368

Arteria *(cont.)*
cerebri posterior 368
coronaria cordis Figs. 121, 208
dextra Fig. 206
sinistra 89, Figs. 207, 209
interlobularis 361
pulmonalis Figs. 189–90
renalis 179, 211, Fig. 216
subclavia sinistra 254
Arterial bulb
in bony fishes 7–8, 18–9
of carp's heart 8
Arterial portion
from amphibia 178
from birds 178
from fishes 178
from reptiles 178
Arterial trunk 254
in amphibia 37
in bony fishes 8
Arterial walls in reptiles 53
Arteriosclerosis 311
Arteriovenous anastomoses 204–6
Artery
arciform 359
capsular 336
carotid 278
common 87, 275
external 306
internal 275–6, 286, 304, 306, 366
cerebral 209–10, 366–7
coronary 65, 85
left 89
right 89
in calf 116
in horse 116
in man 116
in pig 116
in left atrium Fig. 111
innervation 174–200, 304–9, 342–9, 357–63, 367–72
in right atrium Fig. 115
interlobar 359
interlobular 359
intrarenal 359
nerve fibres in wall 53
occipital 283
pulmonary 201, 211
splenic 179
thyroid 87
vertebral 366
Aschoff–Tawara nodule 117, 122
acetylcholinesterase activity 128, 130
atrial nodule 117
in calf 117, 120
in horse 116–7
in man 117
innervation of Fig. 70
stimulus-conducting system 117
ventricular
Atrial endocardium
in birds 69
Atrial endocardium *(cont.)*
in cat 146
in fox 139
in horse 148
in mammals 94–6
in man 94, 135
in reptiles 50
Atrial epicardium
in birds 65
in mammals 90
Atrial lumen
in amphibia 25
in bony fishes 14
Atrial muscles in bony fishes 8
Atrial myocardium
in amphibia 25
in birds 67, 69
in bony fishes 12
in mammals 90
in reptiles 49
sinoatrial node 109
Atrial nodule in birds 81–2
Atrial plexus
endocardial 89
epicardial 89
myocardial 89
Atrial septum Fig. 80
in amphibia 23, 25–6, 31–2, 34, 41
in birds 69–70
in mammals 97–9
in reptiles. 50 57
innervation 34
Atrial surface 76
Atrial wall
in amphibia 23
in birds 65
in bony fishes 8
in reptiles 47, 57
Atrioventricular bundle
in dog 128
in horse 123
in man 127
innervation 123
nerve supply 131
Atrioventricular funnel Fig. 6
in bony fishes 8, 15–8
Atrioventricular orifice
in bony fishes 12
Atrioventricular system 106, 115–20
histology 116–20
innervation 120–7
orifice 12
Atrioventricular valves 172
in amphibia 25
Atrium
Aschoff–Tawara nodule 115
in amphibia 25–26
in birds 65
in bony fishes 7–8, 12–5, 18
in cat 143
in mammals 85, 90–6
in reptiles 43, 47–50

Auerbach's plexus 187
Auricle, right 108
Auricular rings in birds 74
Australian ostrich 74
Autonomy of avian heart 83
Axon, structure 317

Badger 179, 196
Baroreceptor *(see also* Pressoreceptor) 211
Baroreceptor fibres 310
Baroreceptors 113, 173
  and hypertension 311–6
  degeneration 311
  in aortic arch 311, Figs. 128, 132–3, 135–6, Plate IV
  in carotid sinus 311
Basal plexus 55, 183
Beasts of prey, aortic arch 196
Best's carmine staining 108, 110
Bicuspid valve 85
Bidder's ganglion 34, 36, 41
Bielschowsky's method 1, 23, 64, 79, 180, 192, 325, 343
Bielschowsky–Ábrahám 4–5, 8, 79, 108, 204
Bielschowsky–Gros 8, 310
Bielschowsky–Gros–Cauna 5
Bifurcation carotid 276, 286
Birds *(Aves)* 64, 69, 211, 275, 339, 368
  accessory glomera 342–3
  acetylcholinesterase in stimulus-conducting system 83
  chemoreceptors 319
  depressor fibres 275
  ganglia 84
  heart 64
    atrial system 50
    atrium 47
    autonomy 83
    muscular valve 74
    nerve endings of myocardium 78–9
    pressoreceptors 211
    sinus caroticus 275
    stimulus-conducting system 9
    ventricle 70–3
    ventricular system 73
Black-headed gull *(Larus ridibundus)* 64
Black stork *(Ciconia nigra)* 64
Blood pressure, inhibition 217
Blood vessel reflex path 369
Blood vessels
  nerve cells in walls 210
  receptors in walls 210
Boeke's basal plexus 183–5, 187
Bony fishes *(Teleostei)* 7
  arterial bulb 18
  atrioventricular funnel 15
  atrium 12
  cholinesterase activity 22
  ganglia 19
  venous sinus 9
  ventricle 17
Bos bubalus (see Buffalo) Figs. 150–1
Bos taurus (see Calf) Figs. 68, 70, 75, 92–94, 138–48, 172, 207, 209, 211, Plates II (63), IV (244), V (247)
Bouin and Müller's fixing fluid 9
Bowman's capsule 362
Brachiocephalic trunk 233
Bradycardia 275, 337
Brain base 371
Buffalo *(Bos bubalus)* 254
  His' bundle 132
Bulbus arteriosus in bony fishes 8
Bulbus carotidis 286

Cajal's interstitial cells 262, 310
Calcification on human aortic wall 271
Calcium deposition in media 271
Calcium granules in media 343
Calf *(Bos taurus)* 87, 107, 109, 111, 113–7, 153, 233, 283, 321
  acetylcholinesterase activity 128
  aorta 198
  aortic arch 347
  arteria coronaria cordis 346–7
  Aschoff–Tawara nodule 115–7, 121–2
  common carotid artery 335
  coronary artery 179, 347
  depressor fibres 153–4
  endocardium 153
  glomus caroticum 321
  heart stimulus-conducting system 107
  His' bundle 115, 122
  innervation of aortic wall 252
  myeline sheath 155
  nerve connections of coronary arteries 342
    end system 155
    plexus 284
  nervus depressor 253
  neurilemma 153
  neurofibrillar end plates 153, 155–6
  neurofibrils 285
  os cordis 115
  receptors in endocardium 153
  reticulum 156
  sensory endings 155
  sinoatrial system 107
  sinus caroticus 283–4
  special cells 156
  stimulus-conducting fibres 130
  terminal branches 155
  trigonum fibrosum dextrum 115
  varices 284
  vasa vasorum, innervation 304
  vena cordis magna 353
  V-shaped sinoatrial node 109
Canis familiaris (see Dog) Figs. 63, 81, 111, 113, 115, 125–6, 167–8
Canis vulpes (see Fox) 53–4, 82–3

Capillary (-ies) 52, 69, 105, 176, 206–9
elements of adventitia 357
in glomeruli 331, 333
innervation Fig. 120
innervation in calf 304
loop Fig. 148
renal 365
vessels, nerve connections 365
with accompanying fibres 207
Capra ibex (see Goat) Fig. 152
"Capsulated nerve end bodies" 212
Capsule-less end system in cat 146
Cardiac plexus in mammals 88–9
Cardiac receptors
in endocardium 158
in epicardium 158
Carotid body
blood circulation 324
glomerular system 324
of dog 324
Carotid sinus 275
Carotis communis Fig. 188
Carp *(Cyprinus carpio)* 8–9, 16, 19
epicardium 12, 157
cardiac receptors 157
myocardium 12
Cat *(Felis domestica)* 143, 196
accessory glomera 340
aortic arch 208–9
atrial endocardium 146
atrial system 138
atrium 143
capsule-less end system 146
cerebral vessels 366
degeneration of sensory end system 105
endocardium 147
epicardium 102, 147
innervation of renal vessels 351
media of aortic arch 196
myelinated fibres 146
neurofibrillar end plates 143, 146
receptors in endocardium 105
renal arteries 179
sensory end system 143
splenic artery 179
stimulus-conducting system 107
sympathetic system 105
synapses 169
ultraterminal fibres 90
vagotomy 107
Cattle, Aschoff–Tawara nodule 126
Cells
bipolar 59
in uterine veins 202
chromophilic 332
chromophobic 332
Dogiel's type I 107, 130, 161, 209, 349
interstitial 154, 184, 190, 254, 262
interstitial of Ramón y Cajal 262, 310
multipolar 59, 262, 349
Cells *(cont.)*
paraportal 363
paravascular 363
polygonal 69
Schwannian 184, 189, 300, 313
unipolar 60
Central vagal fibres 41
Centrum Vieusseni 366
Cerebellum 369
Cerebral arteries, innervation 369
Cerebral capillaries 373
Cerebral veins 372–3
Cerebral vessels 365
innervation 365–7
Cerebrospinal origin, plexus 196
Cerebrum 369
Cervical sympathetic
in amphibia 39
in birds 64
in bony fishes 24
Chemical factors 338
Chemoreceptor (-s) 150, 204, 211, 324
localization and structure 319
system in horse 148
Chicken *(Gallus domesticus)* 211–2, 276, 368
Cholinergic efferent end apparatus 130
Cholinergic nerve 129, 131
fibres 128
Cholinesterase activity 22–3
in amphibia 41
in aortic arch 273
in cells' processes 130
Cholinesterase assay 274–5
Cholinesterase test in bony fishes 22
Chordae tendinae 85
Chromatin in birds 66
Chromatophores in amphibia 23
Chromium salts 321
Circular groove in bony fishes 8
Circus aeruginosus *(see* Marsh-harrier) Figs. 49, 166
Coils
in renal artery 358
in reptiles 64
Coil-like end structure 105
Coil-like end system in horse 148
Coil-like endings in dog 139
Coil-like formations, cerebral vessels 281, 372–3
Collagenous bundles 90
in bony fishes 9
Collagenous connective tissue 47
Collagenous fibres 37, 71, 73, 102
in ventricular myocardium 102
Columba domestica Figs. 107–8, 194
Common bat *(Myotis myotis)* 89
Common buzzard *(Buteo buteo)* 65
Common cage-bird *(Streptopelia decaocto)* 64
Common carotid artery 304–6
Common coot *(Fulica atra)* 64, 276

Common cormorant *(Phalacrocorax carbo sinensis)* 64
Common heron *(Ardea cinerea)* 64, 203, 276
Common snake *(Tropidonotus natrix)* 43, 57, 59
Conducting system, ventricular 74
Conus arteriosus in bony fishes 8
Coronary arteries 7, 179, 211
  adventitia 347
  calcium granules 343
  intima 347
  media 343, 347
  nerve plexus in media 196
  wall 346
Coronary sinus 115
  wall in man 166
Coronary vessels 65, 90, 159
  innervation 342–9
Cor pulmonale 332
"Corpuscula originis nervi depressoris", Bersch 251–2
Coupland and Holmes' method 83, 128, 131–2
Cow *(Bos taurus)* 89, 108
Crista acustica in carp 226
Crista terminalis 109, 111
Crow *(Corvus frugilegus)* 65
Crus commune 115, 134
  innervation 122
  of pig 131
Crus dextrum et sinistrum 115
Cuvieri ducts in bony fishes 7, 9
Cyprinus carpio Figs. 1–7, 9, 10

Degeneration
  after vagal section 34
  of baroreceptors
    in carotid sinus 313
    in hypertension 316
  of end system in man 271
Dendrit plates 343
Dendritic continuity 166
Dendrits 100
Depressor afferent system in amphibia 38
Depressor endings, tunica media 260
Depressor fibres
  in birds 275–6
  in pig 219
  vagal 113, 214
Diencephalon 367
Discs in amphibia 37
Disintegration of end plates 316
Distal synapses 186
Dog *(Canis familiaris)* 89, 106–7, 115, 215–8, 278, 321
  aorta 196
  aortic arch 196
  aortic fibres 215
  Aschoff–Tawara nodule 115
  atrioventricular system 128
Dog *(cont.)*
  carotid sinus 139
  end plates 139
  receptors, endocardial 130
  sinus caroticus 278
Dogiel I type 107, 130, 161, 163, 209, 343, 349
Domestic cat *(Felis domestica)* 89
Domestic duck *(Anas anas)* Fig. 43
Duck *(Anas domestica)* 64, 211, 276, 368

Eberth's line 99, 110–1, 120
Efferent endings 132
Efferent fibres, intracardial 159
Efferent vagal fibres 40
Ehrlich's and Golgi's method 39
Ehrlich's vital methylene blue 22
Elastic fibres
  in endocardium 104
  in myocardium 103
  in venous sinus 9
Elastic elements 347
Elastic membrane 37
Elliptic end plates 354
Embolia 311
Embolia cerebri 311
Embolization of carotid sinus 338
Emollitio cerebri 311
Emys orbicularis Figs. 26, 28, 30–1, 33–4, 37, 39, 109
End apparatus
  cholinergic, efferent 130
  of preganglionic fibres 64
  sensory 71
End baskets 64
End bulb
  hypolemmal 38
  in amphibia 22, 39
  in birds 71
  in bony fishes 18, 21
  in mammals 92, 96, 104–5, 120, 123, 133, 159
  in media 198
  in myocardium 18
  in reptiles 55, 64
  in sheep 286
  of vagal fibres 55
  subendocardial 105
End bulb apparatus, Vater–Pacini type 201, 204
End bulbs or rings in bony fishes 17
End clubs 166
End discs 254, 282–3
  in amphibia 26
End fibre plexus Fig. 43
End fibres
  in amphibia 34–5, 41
  in birds 71
  in mammals 189, 278, 286
  in man 261
  in veins 204

End fibres *(cont.)*
of vegetative nervous system 191
varicose 34, 254
End muscular spindle 138
Endings
afferent 122
efferent 122
intracytoplasmic 133
Endocardial layers Fig. 58
Endocardium
atrial, in birds 81
duplication 74
in amphibia 25–6, 36–8
in birds 69, 71, 73, 76, 79, 81, 158
in bony fishes 9, 12, 14
in calf 115, 116
in mammals 90, 93–5, 97–8, 104–5, 139
in reptiles 50, 156
in sinoatrial node 111
in ventricular septum 105, 127
receptors 135
sensory elements 18
ventricular 73, 104
Endothelial cells 139, 367
in amphibia 25, 34
in bony fishes 9, 15, 17
in capillaries 207
in mammals 96, 98, 104
in reptiles 54
Endothelium
in amphibia 23
in birds 69–70, 74
End plate system 223
End plates 60, 138, 141, 146, 240, 242–3, 248, 250–1, 261, 269, 278, 282, 290
elliptic 243
in calf 153, 284, 285
in mammals Fig. 57
neurofibrillar 298
polymorphous 292
structure 218
triangular 105
End plexus 121–2, 191–2, 243, 345
in amphibia 37
in bony fishes 18
in reptiles 61
End ring *(see also* Terminal ring)
End rings 17–8, 34–5, 37–8, 43, 50, 52, 55–6, 61, 68, 70, 73, 79, 112–3, 120, 122, 132–3, 158–9, 166, 169
afferent 122
coil-like 139
efferent 122
epilemmal 113, 122
hypolemmal 73, 122, 150
in amphibia 35, 37
in birds 68
in reptiles 55–6
intracytoplasmic 133
plate-like 113
sensory 43, 123, 135
End rings *(cont.)*
or end spheres 132
End spheres 359
End structures 135
End system
capsule-less 146
degeneration in human aortic fibres 271
Environmental factors 318
Enzymatic activity in postganglionic fibres 128
Epicardial epithelium in birds 79
Epicardial plexus 90, 92, 100
Epicardium
in amphibia 25, 34–7
in birds 65, 69, 71, 83–4, 158
in bony fishes 12, 15, 17
in mammals 89–90, 99, 102, 104, 108
in reptiles 47, 58, 61
innervation 135
of musk-rat 165
Epimys rattus norvegicus Figs. 56, 59, 218, Plate II (63)
Epithel 7
in amphibia 34
in reptiles 47
Epithelial cells in amphibia 25
Epithelial layer in birds 65, 73
Epithelium in mammals 99, 104, Fig. 61
Epitheloid cells 324, 339, 363
Equus caballus Figs. 6–7, 74, 89, 170–1, 196, Plate V (247)
Evolutionary level 158
Eye 187
muscles 179

Fasciculus anterior et posterior 116
Felis domestica Figs. 52, 57, 61, 78–80, 84–8, 96, 103, 116
Fenestral cells 351
Fiber zibethicus Figs. 62, 100
Fibres *(see* also Nerve fibres)
afferent 160–1
cerebrospinal 176, 196
collagenous 37, 103
efferent 159
elastic 65, 104, 117
in mammals 105, 107
in ventricular myocardium 103
myelinated 35, 37, 40
myeline-sheathed 24, 35
of nerve plexuses in media 192
parasympathetic 108, 130
pericellular 64
postganglionic 40, 41, 87, 128, 187
preganglionic 64, 87, 159, 171, 353
sensory, in amphibia 26, 43
sympathetic 35, 40, 65, 150
ultraterminal 90
varicose 114
in amphibia 25
in reptiles 53

Fibre system of thoracic interspinal ganglia 161
Fibrous ring in birds 74
Fieldfare *(Turdus pilaris)* 65
Flamingo *(Phoenicopterus roseus)* 64
Fossa, oval 115
Fossa Sylvii Fig. 215
Fox *(Vulpes vulpes)* 89, 139
Frog 176
  heart 39
    innervation 23
  vagus 41
Fuchsinophilic cells 333

Galen's heart nerve 85
Gallus domesticus Figs. 51, 112, 122–4, 221
Ganglion (-ia) 127, 161
  Bidder's 34, 36, 41, 161
  cardiac 159
    in mammals 36, 38
  cervicale inferius 87
    medium 87
    superius 87, 128
  cholinesterase reaction 128, 130
  glossopharyngeal 316
  in amphibia 41–2
  in birds 65, 82, 84
  in bony fishes 19–22
  in cat 105–7
  in frog's heart 161
  in heart wall 161, 166
  in mammals Fig. 53
    in ungulates 111
  intracardiac 39, 159
    in amphibia 39
    in reptiles 46, 56–64
  jugular 87
  of coronary arteries 349
  of gastrointestinal system 166
  on sinoatrial node 161
  paravertebral 86
  thoracic interspinal 161
  upper, thoracic 87
  vagal 316
  vegetative 107
Ganglion Fig. 211
  cells Fig. 103
    in reptiles 59
    intracardial 7
  in amphibia 30, 36, 41–42
  in atrial epicardium 161
  in epicardium Fig. 98
  in reptiles Fig. 35
  intervertebral 87
  jugulare vagi 316
  Ludwig's 161
  nodosum vagi 316, 319
  of sinus coronarius cordis Fig. 97
  Remak's 161
  stellatum 87
  sympathetic 289
Garden snail *(Helix pomatia)* 30
Gastropodes 190
Genetic relationship 318
Gerebtzoff–Coupland–Holmes' test 23
Giant plates 163
Glandula intercarotica 321
Glomectomy, asthma bronchiale 333
Glomera
  accessory 319
    in birds 339
    in mammals 340
    in man 341
Glomerulus (-i) 324–5, 329, 334
  nerve supply 334
Glomus (-era) 339
  in aortic wall Fig. 203
Glomus caroticum 319, Figs. 194–5, 197–9, 202
  in birds 319–21
  in mammals 321
  in man 286, 325
Glomus cells 324, 335, 342
  accessory 333
Glycogen
  content 117
    of atrial nodule 117
  in stimulus-conducting fibres 80
Glycosuria 337
Goat *(Capra ibex)* 107, 160, 225
  aortic fibres 255
  intermediary neurofibrillar plates 255
  neurofibrillar end plates 255
  neurofibril-like axon 255
Golgi's funnel 219
Golgi's method 207
Golgi's preparation 179
Gömöri's chromohematoxylin stain 9
Gömöri's chromohematoxylin-phloxin granules 41
Gömöri's chromohematoxylin-phloxin technique 22–3
Goormaghtighian cell groups 363
Goose *(Anser domesticus)* 64, 211, 276, 368
Granulation, tigroid 187
Gros' method 108
Gros–Cauna's method 108
Guinea pig *(Cavia cobaya)* 89
  acetylcholinesterase 128
  Aschoff–Tawara nodule 115
Gull *(Larus ridibundus)* 276

Haemangioma 337
Hair arrector muscle 179
  innervation 179
Heart
  auricles
    in bony fishes 7
    in mammals 85

Heart *(cont.)*
auricle, right 108–9
automatism 106
bulb in amphibia 23, 37
cardiac plexus 88–9
cartilage 115
cavities 34
fibres, parasympathetic preganglionar 88
ganglia 21, 41, 57, 87, 161
in amphibia 30, 41
in birds 79
in bony fishes 19
in mammals 85, 161
in reptiles 58
nerves
anatomy 86
histology 89
sympathetic 86
vagus 86
phylogenetic aspects 157–8
receptors 135
appearance in mammals 158
phylogenesis 157–8
reflexes 139
shape and structure 7
in birds 64
in bony fishes 18
in buffalo 254
in calf 107, 153
in carp 157
in cat 108
in dog 105
in frog 22, 39, 41
in horse 148
in mammals 85
in mouse 106
in pig 150
in pigeon 83
in reptiles 43
in sheep 107, 150, 153
in tortoise 58, 61, 122
interoceptors 158
wall 86
Heidenhain's Susa 8, 108
Helix pomatia Fig. 16
Hematoxylin and eosin 253
Hen *(Gallus domesticus)* 65
Hen harrier *(Circus cyaneus)* 211
Henle's reaction 326
Hering's sinus reflexes 275, 338
His' bundle 106, 115–7, 123, 126–7, 130–3, Figs. 67–8
in buffalo 132
in horse 134
in pig 134
Homo Figs. 97, 101–2, 117, 121, 155–64, 175–91, 193, 197–200, 202, 204–6, 212, 214–6, 220, 222, Plates III (237), V (247)
Horse *(Equus caballus)* 89, 108–10, 113–7, 148, 281
Horse *(Equus caballus) (cont.)*
arteria coronaria dextra 116
Aschoff–Tawara nodule 115–6
atrial endocardium 150
atrioventricular bundle 123, 125
carotid sinus, media 281–3
chemoreceptor system 148
glomus caroticum 321
His' bundle 115–6, 134
neurofibrillar end plates 282
nuclear degeneration and regeneration 125
plexus in Aschoff–Tawara nodule 121
sensory nerve endings 123
sinoatrial system, innervation 113
sinus caroticus 281
stimulus-conducting fibres 130
system, histology 107
trigonum fibrosum dextrum 115
Hypertension 311
Hypolemmal bulbs in amphibia 25
Hypolemmal end bulbs in bony fishes 16
Hypolemmal end rings in reptiles 56
Hypotension 337

"Independent" neurofibrillar plexus 336
Inhibitor 317
Inhibitor system 316
Innervation
in vessel's media in bony fishes 18
of arteries 177–8
tunica adventitia 194–6
tunica intima 200–4
tunica media 196–9
of atrial myocardium Figs. 6–7
of atrioventricular system 115–6
of blood vessels 174–7
of capillaries 177
of cerebral capillaries 373
vessels 177, 365
of coronary arteries 177
of heart
in amphibia 22
in birds 64
in bony fishes 7
in mammals 85
in reptiles 43
of heart vessels 342
of human heart 133–4, 166
of intracardial vessels 177
of renal vessels 177, 357
of sinoatrial system 108
of sinus coronarius cordis 342
of veins 177, 201–4
of vena cordis magna 353
of vessels 173
segmental 175
Interconnections of afferent fibres 367
Interlamellary plexus, adventitial 196

Intermediary
branch system 248
neurofibrillar plates 225, 295
plates 243
in calf 284
in man 308
in sheep 280
on aortic fibres 269
Intermediate neurofibrillar plates 215–6, 220
Interoceptor 317
Interstitial cells 154, 185, 190, 254, 262
mediator 335
Intersynaptic space 190
Intestinal innervation 86
Intestinal submucosa 208
Intima of cerebral arteries 367
Intracardiac arteries 342
innervation 357
Intracardiac nerve fibres in amphibia 40
Intracardiac receptors, enzyme activity 133
Intracardiac vessels 357
Intradendritic elements 100
Intraglomerular apparatus 363
Intraglomerular coils 329

Jabonero's silver carbonate method 6, 108
Jackdaw *(Colaeus monedula)* 65
Juxtaglomerular apparatus 363

Keith–Flack node (nodulus sinoauricularis) 106–8
Kidney Fig. 218, Plate II (63)
of dog, nerve fibres 363
Koelle–Friedenwald's method, modified by Gerebtzoff 9, 128, 275
Knob-like endings 192

Lacunar matrix (spongiosa) in bony fishes 8
Lamella-like structures 217
Lamina propria
in amphibia 23
in bony fishes 9
Lemnoblast 185
Lepus cuniculus Fig. 106
Ligamentum arteriosum Botalli 233, 260
Lizard 52, 177
Long-eared owl *(Asio otus)* 65
Loop of vessels 204, Fig. 119
Ludwig's ganglion 41

Magpie *(Pica pica)* 65
Malpighian bodies 363
Mammals 36, 85, 278
accessory glomera 342–3
atrial septum 97
atrium 90
carotid sinus 278
chemoreceptors 32
Mammals *(cont.)*
ganglia 161
heart nerves, anatomy 86
histology 89
sympathetic 86
phylogenesis 158
pressoreceptors 214–5
vagal cardiac rami 88
ventricle 99
ventricular septum 104
Man *(Homo sapiens)* 87, 89, 106, 108, 115–7, 161, 260–9, 286–301
accessory glomera 341
alteration on sinus caroticus 301
aortic arch 260
aortic fibres 260
carotid glomus 286
cerebral veins 372
chemoreceptors 325–8
common carotid artery 304–6
coronary arteries 342–9
coronary sinus 353
external carotid artery 306
glomeruli in glomus caroticum 325
glomus caroticum 325–38
neurofibrillar end plates 260
pathological aortic fibres 269
periarterial nerve plexus 343
pressoreceptors 260
pulmonary artery 306
receptors 260
renal arteries 358
sinus caroticus 286, 288, 291
sinus coronarius cordis 349
tunica intima 288
tunica media 288
vena cordis magna 353–4
vessel wall's structure 253
Marsh-harrier *(Circus aeruginosus)* 65
Media 178, 180, 233, 281, 308, 347, 357–8, 361, 370
depressor fibres (in rabbit) 252
in aorta (in pig) 128
in arteries 196
in birds 276
in bony fishes 11, 18
in buffalo 254
in calf 253
in cerebral arteries 196
in coronary arteries 196
in dog 218
in man 260–2, 269, 271
in reptiles 46
in sinus caroticus in man 288
in veins 201
in vena cava superior in dog 139
smooth muscle cells 179
Medulla oblongata 366
Meissner body 363
Meleagris gallopavo Figs. 110, 219
Membrane
elastic 37

Membrane *(cont.)*
nuclear 332
postsynaptic 186, 190
presynaptic 186, 190
Methylene blue 360
Micro-cells 111
Mitochondria 332, 337
in birds 69
Moderator fascicle 115
Mole *(Talpa europaea)* 89, 161, 169–70
Montagu's harrier *(Circus macrourus)* 65
Morphological basis 292
Mouse
His' bundle 106
renal veins 364
Multipolar ganglion cells 19, 59
Multipolar nerve cells 20, 343
Muscle cells
in media 178
smooth 23
Muscle fibres
mechanical 79
striated 18
Muscles of the eye 179
Muscles, papillary 85
Muscular columns in bony fishes 8
Muscular valve 68, 74, 81, Figs. 46–8
Muscular valves in birds 65, 68, 74–9, 81–82
Musculus subaorticus Jerisch 115
Musk-rat 165
Myocardial layer 97
of ventricular septum 105
Myocardial plexus 71, 89, 92, 104
Myocardium
border 113
in amphibia 25–6, 33–4, 36–7, 39
in birds 67–71, 79
in bony fishes 12, 15, 17, 18
in mammals 87, 90, 92, 95, 98–9, 102, 104–5, 115, 127, 139, 159
in pig 113
in reptiles 50–3, 55
of ventricular septum 105
proprioceptors 17
receptors 137
septal in birds 73
ventricular
in birds 72, 84
in bony fishes 17
Myodegeneratio cordis 311
Myofibrils 91, 117
acetylcholinesterase 129
crossing 117
in birds 66, 69, 73
in mammals 91
striation 110, 117
Myogenic theory 120
Myeline sheath 36, 141, 146, 178, 219, 221, 223, 230, 261, 317, 342, 353, 370–1
Myeline sheath *(cont.)*
in cerebral vessels 366
in human aortic fibres 261
secondary fibres 261
Myelinated fibres 141, 226, 254, 261
in cerebral arteries 371
in man 261
in wall of human aorta 260
Myelinated nerve fibres 338
Myeline-sheathed nerve fibres in amphibia 25

Nerve, vestibular 226
Nerve bundles 9
in reptiles 46
Nerve cells Fig. 196
acetylcholinesterase activity 130
Dogiel's type I 107, 130
end plexuses 61
in atrial wall Fig. 2
in coronary arteries 209
in ganglia 107
in vessel walls 209
multipolar 19
in bony fishes 19
of stimulus-conducting system 111
specialized Figs. 101–2
unipolar 85
in reptiles 60
Nerve connections
in adventitia 191
in coronary arteries 342
in tunica media 191
of arteries 178
of capillary vessels 365
of vena cordis magna 353
Nerve end body Fig. 138
Nerve end bulbs 166, 169, 373
Nerve end coil in cat Fig. 87
Nerve end fibres in amphibia 34
Nerve end fibre system Figs. 150, 177, 186
Nerve endings *(see also* Endings) 125, 159
capsulated 212
free 133–4
in Aschoff–Tawara node 122
in mammals 90
of myocardium
in amphibia 39
in birds 78
in bony fishes 18
in mammals 133–4
in reptiles 55–57
Nerve end knob Fig. 73
Nerve end organ Figs. 80–1, 85, 88, 90–5, 128, 140–1, 143–6
Nerve end plates Fig. 154
Nerve end plate system Figs. 174, 176, 178, 183

Nerve end plexus Fig. 164
Nerve end structure in stimulus-conducting system 135
Nerve end system 292
Nerve fibre bundle Fig. 37
Nerve fibres 169, Fig. 33
afferent 338
and nerve endings Fig. 34
capillaries of heart 357
efferent 113
endings 192
epicardium 40
in atrial wall Fig. 3
in atrium of mammals 90
in birds 76
in glomus caroticum 319
in kidney of dog 363
in myocardium Fig. 5
in tunica adventitia 176, 253
in tunica intima 253
in tunica media 174, 196
in vena saphena magna 202
intracardial origin 159
of capillaries 206
of cerebral vessels 366
of valves 173
ortho- and parasympathetic 310
pathological alterations 301–3
sympathetic 86
unmedullated 363
Nerve fibre plexus Figs. 4, 16–7, 20–1, 26, 30, 65, 71–2, 74, 128, 182, 210
Nerve fibre terminal system Fig. 152
Nerve intercarotid 337
Nerve interconnections 74
nets, peripheral 192
Nerve plexus Figs. 2, 11, 18, 22, 28–9, 31, 36, 44–5, 47, 96, 99, 105–6, 153, 175, 330, Plate II
in bony fishes 10–12, 17
in mammals Figs. 55, 62
in venous sinus Fig. 8
Nerve reticulum in reflexogenic area 310
Nerve system, cerebrospinal 357
Nerve terminal system Fig. 151
Nerve trunk 30, 34, 45, 69, 74, 130
Nerve trunks in amphibia 36
Nervous system
gastrointestinal 30
orthosympathetic 310
parasympathetic 310
stimulus-conducting system 122
vegetative 30
terminal formation 189
nerve connections 189
Nervus accessorius 88
Nervus aorticus
in rabbit 214
receptor 254
Nervus cardiacus
crassus 87
inferior seu parvus 87
medius seu magnus 87
superior 87
Nervus depressor 252–3
in birds 211–3
in rabbit 251
vagi 88
Nervus glossopharyngeus 276, 278–9, 281, 286, 321, 336–7
Nervus laryngeus
inferior 88
superior 88
Nervus recurrens
in mammals 85–86
vagi 87
Nervus septalis dorsalis in amphibia 27, 34
Nervus septalis ventralis in amphibia 27
Nervus sympathicus *(see also* Sympathicus)
Nervus vagus, receptors in calf 253
Net, neurofibrillar 277
Network 216
epicardial 100
neurofibrillar 248, 292
Network system 279, 357
Neuraxon 311, 313
vesicle 311
Neurilemma 317
in calf 153
Neurilemmal nuclei 153, 223, 230
in pig 219
Neurofibrils 139, 184, 220, 226, 230, 233, 236, 240, 276, 278, 286, 290–2, 301, 304, 331
bundles 183
in amphibia 25
in bony fishes 11–2
in calf 153
in reptiles 55
Neurofibrillar end bulbs in bony fishes 18
Neurofibrillar end plates 113, 135, 138, 141, 142, 146–7, 240, 282, 292, 303
in calf 306
in cat 143, 146
in goat 255
in man 260
in myocard 137
in reptiles 60
in sheep 150
Neurofibrillar interconnections of end system 269
Neurofibrillar net in birds 277
Neurofibrillar network 318
Neurofibrillar plates 161, 171
intermediary 216, 220, 251, 254–5, 284–6
in common carotid artery 304–5
in elder persons 267
in man 261–2, 267, 298, 304
Neurofibrillar plexus in bony fishes 18

Neurofibrillar reticula 218
Neurofibrillar terminal system Fig. 147
Neurofibrillar veil 269
Neurohistology 166
Neuromuscular system 179
Neurosecretion 23, 187
in amphibia 41–2
in bony fishes 23
Night heron *(Nycticorax nycticorax)* 64
Nissl granules 191, 333
Node
sinoatrial 110–1, 113
artery 110
innervation 111

Oesophagus 87
Orifice of aorta 130
Ortho- and parasympathetic fibres 310
system 310
Os cordis in calf 115
Osmic acid 39
Ossification centre 337
Ovis aries Figs. 60, 91, 119, 153–4, 173–4, 195

Palatine mucosa of frog 183, 208–9
Papillary muscle, septal 115
Paraganglion (-ia) 212, 321, 325, 341
Paraganglion caroticum 321
Parasympathetic fibres 262
Parasympathetic system 310
Paravascular (paraportal) cells 363
Paravertebral ganglia 87–8
Pars corticalis of spongiosa, in bony fishes 8
PAS reaction 108, 110, 117
Pathological alteration of carotid sinus 301
Pathological processes of sensory nerve fibre 301
Pectinate muscle in bony fishes 8
Peewit *(Vanellus vanellus)* 64
Periadventitial sensory end system 324
Periarterial neurectomy 175
Pericardial cavity in bony fishes 7
Pericardium
in amphibia 43
in mammals 85, 173
Pericellular apparatus in reptiles 58–9
Pericellular bag 329
Pericellular basket 30, 170
in amphibia 41
Pericellular fibres in reptiles 64
Pericellular plexus 170, Fig. 104, Plate II (63)
in reptiles 61–2
Pericellular spirals
in amphibia 34
in reptiles 62
Pericytes 209
Perineural space,
extra- 301

Peripheral nervous system 176
Peripheral vegetative paths 191
Periterminal net 183
Phalacrocorax carbo sinensis Figs. 45, 50
Pheasant-cock *(Phasianus colchicus)* 65
Phoenicopterus roseus Fig. 46
Phrenic nerve 172
Phylogenesis 30
of cardiac receptors 157–8
pressoreceptors 316–8
Phylogenetic continuity 71
Pia mater, capillary vessels 366
Pig *(Sus scrofa domestica)* 107, 108–10, 113–4, 116, 165, 218, 279
acetylcholinesterase reaction 128
aortic arch 226, 233
nerve end fibres 225
arteria coronaria cordis 346–7
Aschoff-Tawara node 115–6, 121–2
innervation 120–1
atrioventricular system 115
bundle of Wenkebach 109
cholinergic nerves 130
cholinesterase activity 273
coronary arteries 179, 196, 342, 346
crus commune 131
depressor fibres 226, 230, 232
glomus caroticum 322
His' bundle 115–6, 122, 134
heart cartilage 115
interoceptor 133
nerve connections 362
neurilemmal nuclei 219
pressoreceptors 218–33
Purkinje fibres 127
sinoatrial system 11, 113
sensory endings 170
sinus caroticus 279
stimulus-conducting fibres 130
trigonum fibrosum dextrum 115
vegetative fibres 219
vena cordis magna 353
Pigeon *(Columba domestica)* 65, 276
heart 83
Pike 19
Pike-perch *(Lucioperca lucioperca)* 8
Plates, neurofibrillar 155, 216, 220, 254–5, 261, 298, 304
Plexus (-es) 158, Fig. 38
adventitial 178, 196, 346, 359
in bony fishes 10
in mammals 196
in man 369
atrial 65
atrioventricular 107
coil-like 284
epicardial 71, 100, Fig. 41
in adventitia 276
in birds 65
in reptiles 51
interlamellar 178, 355
intraganglial 253

Plexus *(cont.)*
intraglomerular 324, 328, 331
medial 359
myocardial 104
of atrial system 70
periarterial 342–3
Plexus cardiacus 88
in mammals 89
profundus 89
profundus seu posterior 88
superior 89
Plexus cardiacus superficialis, seu anterior 88
Plexus chorioideus 209, 373
Plexus coronarius
dexter 89
sinister 89
Plexus endocardialis 73, Fig. 63
in birds 73, 83
in mammals 89
Plexus epicardialis 65, 71
in mammals 89–90, 92
Plexus extracardialis 85
Plexus myentericus Fig. 109
Plexus myocardialis 71, Figs. 27, 48, 54
in mammals 89
in reptiles 55
Plexus nervosus
in mammals Fig. 55
on coronary artery 86
Plexus periglandularis 324, 327–8
Plexus periglomerularis 324, 328
Poachard *(Anas platyrhyncha)* 64
"Polkissen" 363–4
Pond tortoise *(Emys orbicularis)* 44, 46, 55, 57–8, 61, 64, Fig. 37
Postganglionic fibres 40–1, 87, 128, 187
and distal syncytium 185
Pouched valves in bony fishes 15
Precapillary arteries 342
Preganglionic fibres 21, 55, 64, 67, 159, 171, 369
in reptiles 64
Pressoreceptors 335, 344, 355, 358–9
and phylogenesis 315–8
in aortic arch 211
in birds 211–3
in buffalo 254
in dog 215–8
in heart wall 113
in mammals 214
in man 260–9
in pig 211–3
in pulmonary artery 308
in sheep 257
in vessel walls 211–2
Process (-es)
cholinergic 130
in aortic arch 310
in atrium 90
in endocardium 310
Process (-es) *(cont.)*
in ganglia 85
in mammals 86
Processus tendineus aortae 115, 120
Proprioceptors
in heart wall 113
of myocardium Fig. 80
in bony fishes 17
Pseudo-cholinesterase activity 133
Pseudo-chordae tendinae 116
Pulmonary artery 306–9
Pulmonary veins
innervation 24
of birds 204
Purkinje bundles 105
Purkinje cells 82, 105, 115
Purkinje fibre bundles in birds 82
Purkinje fibre network in birds 81
Purkinje fibres 73, 83, 115–7, 122, 127–8, 131–2
acetylcholinesterase reaction 131–2
in birds 69, 70, 81, 83
in mammals 105, 115, 117, 122, 127, 131-2
Python 57
Python reticulatus Figs. 29, 32, 36, 40, Plate II (63)

Rabbit *(Lepus cuniculus)* 89, 107
acetylcholinesterase 128
aortic arch 251
depressor fibres 214
innervation of aorta 252
intima of aortic arch 251
pericardium 173
stimulus-conducting system 107
Rami cardiaci
in mammals 86, 87–8
inferiores 88
superiores 88
Ramification, circumscribed (appareils sensitifs à ramification circonscrite) 291
Ramification, diffuse (appareils terminaux à arborisation diffuse) 291
Ramòn y Cajal's method 39
Ramus aorticus
in man 260
in ruminants 254
Ramus cardiacus in amphibia 27, 34
Ramus caroticus 326
Ramus septi fibrosi 116
Rana ridibunda Figs. 11–2, 14–6, 8, 20–4, 120
Rat *(Epymis rattus)* 89, 95, 107, 115
albino 189
heart 107
intestinal innervation 189
sinoatrial node 108
Ranvier's invagination 223

Receptor(-s) 133
epicardial 135
in adventitia Plate I (48)
in aortic arch Fig. 127
in birds 65
in endocardium Fig. 57
in mammals 139–57
in plexus epicardialis Fig. 78
in vessel walls 209–11
intracardial 133
myocardial 137
of aortic wall 230
of arteria coronaria cordis 347
of atria in amphibia 34
of heart 135
of heart in endocardium, in pig 150
of heart wall 37
of muscular valve Fig. 47
of vertebrates 157
special 233
Receptor apparatus 139
bulbar wall 38
in aortic arch 317
Receptors, cardiac, phylogenesis 157–8
Receptor elements in bony fishes 11
Receptor end apparatus in intima 251
Receptor end system 301
in calf 148
in pig 248
Receptor function in reptiles 49
Receptor system Fig. 61
in vertebrate heart 36
Reflexogenic area 196
interstitial cells 310
Reflexogenic zone
of aorta 310
of carotid sinus 310
sensitive 211
wall of arteria pulmonalis 308
Regal python 44, 62, Fig. 26
Reiser–Stöhr's terminal reticulum 107, 133
Remak's ganglion 41
in amphibia 25
in mammals 161
Renal arteries 358–63
in cat 362
in dog 362
in man 358
in media 350
in squirrel 362
Renal capillaries 365
Renal veins 364
of mice 364
Renal vessels
innervation 357–63
intima 363
Reptiles *(Reptilia)* 43–5, 69
arterial portions 178
atrial septum 50
lung 19
venous sinus 45
ventricle 51
Resorcin-fuchsin 253
Respiratory centre 338
Reticular plates 226
Reticulum (-la) 122–3, 191–2, 276, 310–1, 345
problem 156

Salmonidae 8
Sarcolemma 34, 39, 66, 70, 72–3, 79, 91, 120, 126
in birds 66
Sarcoplasma 66, 73, 91, 120
in birds 66
Sauropsida 69
plexuses 158
Schadabasch's procedure 1, 23
Schwann cells 300, 308, 313
Schwann envelope 301
Schwann sheath 327
Schwann-type nuclei 204
Schwannian elements 183
Schwannian membrane 183
Schwannian nuclei 190, 369
Schwannian plasmodium 190
Sclerotization 342
Sclerotic granules in media 267
Screech-owl *(Strix flammes)* 211
Secondary fibres
myelin sheath 261
of human aorta 261
Secretory activity 337
Senile pathological forms in man 353
Sensory apparatus 316
Sensory elements in adventitia 18, 195
of cerebral vessels 372
of myocardium 18
Sensory end apparatuses in veins 201
Sensory endings 160
in cat 105
endocardium 107
heart 135
His' bundle 123
mammals 104, 113–4, 123
Sensory end organ Fig. 84
Sensory end system Fig. 91
myocardial, in cat 137
Sensory fibres
in amphibia 26, 43
in myocardium 105
Sensory nerve endings 173, 337
Sensory nerve end organ Figs. 82–4, Plate I (48)
Sensory nerve end plates Fig. 66, Plate I (48)
Sensory nerve end system
in atrial myocardium Fig. 79
in mammals 280
Sensory organs in bony fishes 17
Sensory plexuses 157

Sensory system 135, 160
in birds 69
Sensory terminal organs in bony fishes 17
Sensory type endings in fox 139
Sensory vagal system 11, 40
in amphibia 34
in cat 105
Septum atriorum 111, 137
in amphibia 23
in reptiles 50, 57
Septum membranaceum cordis 115
Septum narium Fig. 110
Septum ventriculorum (*see also* Ventricular septum)
Sheath
of Schwann 180, 327
vagosympathetic 88
Sheep *(Ovis aries)* 89, 106–7, 150, 257–9, 285, 321
coil 150
system 154
depressor fibre 255, 257
glomus caroticum 321
neurofibrillar end plates 150
receptor apparatus 286
sensory end apparatus in endocardium 150
sinus caroticus 285
varices 280
Silur *(Silurus glanis)* 8, 19
atrium 12
epicardium 12
myocardium 12
Silurus glanis Fig. 8
Silver impregnation 5–6, 8, 22, 373
method modified by Ábrahám, Cauna, Dolezel, Gros, Jabonero 2, 4–6, 30, 44
Single nervous cells in amphibia 27
Sinoatrial node *(see also* Keith and Flack) 106–14, 120, 128
acetylcholinesterase 128
artery 110
histology 109
in birds 81
in calf 109–11, 113
in horse 109–10, 113–4
in mammals 81, 128
in pig 109–11, 113–4
innervation 108, 111–4
myocardium 108
nerve endings 120
vein, upper, hollow 103, 108
Sinoatrial nodule
in birds 81
of avian heart 81
Sinoatrial valves in amphibia 25
Sinus
caroticus 304, Figs. 167–9, 170–3, 179, 180–1, 187, 191–2
Sinus caroticus *(cont.)*
in mammals 278
in man 298
carotid 278
Cajal's interstitial cells 310
human, pathological alterations 301
in birds 275
in calf 283
in dog 139
in horse 281–3
in pig 279
in sheep 285–6
internal carotid artery 306
nerve connections 310
nerve endings in wall 298
peripheral reticulum 298
reflexes 304
coronarius cordis 349–53
in calf 349, 351
innervation 342
coronary in calf 349–53
nerve 278, 289, 301
occipital 283
reflex 286
renal 361
venous
in amphibia 22, 25, 30–2, 41
in birds 64
in bony fishes 9–12, 18–9
in mammals 85
in reptiles 43, 45–6
Sinusoid (-s) in glomeruli 331, 333
Small artery Fig. 220
Small veins Fig. 222
Snail 30, 50
Specialized nerve cells Fig. 99
Special nerve cells Fig. 212
Sphincter, atrial muscle 8
Sparrow *(Passer domesticus)* 65, 70
Sparrow hawk *(Accipiter nisus)* 65
Spatium intervalvulare Henlei 115
Spinal fibres 29–31, 33–4, 41
in amphibia 30, 41
Spinal segments 86
Spirals 33–61
in birds 30
in mammals 30
in reptiles 30, 61–2, 64
pericellular 34
in amphibia 33–4
in reptiles 62
Spleen 180
innervation 86
Spongiosa in bony fishes 8
Spotted salamander *(Salamandra maculosa)* 22
Staining
gold chlorid 177
methods 1, 6, 22–3, 44, 108
neurohistological 177
methylene blue 177
van Gieson 9, 108, 110, 117, 253

Staining *(cont.)*
with Best's carmine 108, 110, 117
with Ehrlich's vital methylene blue 22
with Gömöri's chromohematoxylin-phloxin 9, 22–3
with hematein-eosin 110, 117, 325, 327
with iron hematoxylin 9
by Heidenhain 108, 117
with Mallory's stain 9. 108
with resorcin-fuchsin 43
with vital methylene blue by Schadabasch 1, 13, 193, 366
Steppe monitor *(Varanus griseus)* 43, 46, 54, 57–8, 61
Stimulus-conducting fibres 107, 110–1, 115, 117, 120, 125, 134, Fig. 49
glycogen in Fig. 67
in calf 111
in cat 124
in cow 111
in horse 125
in pig 111
nerve endings 134
nuclei 109–10
Stimulus-conducting substances 185
Stimulus-conducting system 122, 135, Fig. 50
acetylcholinesterase
in birds 83
in mammals 128–33
blood supply 107
histochemical behaviour 128, 133
in birds 69, 74, 79–83
in mammals 105–8, 122
in man 107
in pig 132
nerve end structure 135
sensory endings 107
Stimulus conductors in amphibia 31
Stimulus-producing centre 81
Stimulus-receiving system 248
Stöhr's terminal reticulum 107, 133, 180, 182, 192, 199, 204, 206
Stork 70
Stretch receptors 211
Striation of atrial myocardium 91
Subcavities of heart cavity in amphibia 34
Sulcus, atrioventricular 161
Sulcus coronarius 161
in bony fishes 8
Sulcus terminalis 109, 111
Sus scrofa domestica (see Pig) 89, Figs. 55, 65–6, 69, 71–3, 76, 90, 99, 127–37, 150, 165, 169, 208, 213, Plates I, II, IV
Sympathetic cervical 7, 9, 39, 64
Sympathetic fibres 24, 86, 178–9, 284
aortic fibres 261
arteria pulmonalis 308
in amphibia 40
in birds 65
in mammals 104
in pig 219
Sympathetic fibres *(cont.)*
in reptiles 55
myeline-free 178, 203
ventricular muscles (in mammals) 106
Sympathetic heart nerves 87
Sympathetic nerves 55, 86–87
and aorta fibres 260
and aorta nerve 253
in pig 279
jugular 365
Sympathetic nerve supply of heart 86
Sympathetic system
adventitial plexus 195
of cat 105
Sympathetic trunk 56, 87
extracardial 55
Synapse (-s) 11, 120, 130, 159, 166, Fig. 39
auf Distanz 185
in amphibia 30, Fig. 23
in reptiles 61
of large transmission area 31, 41, 64, 166, 170
of small transmission area 41, 166, 170
within ganglia 22
Synaptic formation, spiral fibres 31
Syncytium, Schwann cells 187
System
atrioventricular 106, 115
myocardial 79
in birds 79
of plexuses 132
of vagal nerve 41
sinoatrial 108–9

Talpa europaea Figs. 98, 104–5, Plate II (63)
Tawara branches 115, 131
Tawara branch
and myocardium 115
septum ventriculorum 116
Tench, intestines 182
Tendons 85
Terminal branches 178
Terminal fibres 121, 159, 179, 271, 292, 317, 339, 348
varicose 34
in amphibia 25
in birds 70
Terminal nerve rami 176
Terminal plexus 122
in birds 339
in myocardium in bony fishes 18
Terminal rami, lamella-like 223
Terminal ramification 220
Terminal reticulum 18, 180–2, 189, 192, 201, 206
afferent 363
in amphibia 25
in bony fishes 18
in carotid sinus 298
in cerebral arteries 370

Terminal reticulum *(cont.)*
in tunica media 199
in vascular nerves 180
in veins 180
peripheral 298
Terminal sensory organ
in bony fishes 17
in cats 102
Terminal sphere 112–3
Terminal structures 121
Terminal system 290
of nerve fibres Fig. 155, Plate III (237)
Thebesian foramina 116
Thorel's branch 109
Thorel's bundle 109
Thrombosis 311
Tortoise 46, 50, 53, 57, 106–7
heart 57, 61–2
Trabecula septomarginalia 115–6
Trachea 87
Transmission area 169
in reptiles 64
Tricuspidal valve 85, 115
Trigonum, in pig 115
Trigonum fibrosum dextrum 115
Truncus arteriosus
accessory glomera 319
chemoreceptors 319
in amphibia 37
in birds 339
in bony fishes 7–8
Truncus brachiocephalicus communis 260
Trunk
brachiocephalic 233
sympathetic 87, 128, 327
Tunica adventitia 194–6
in amphibia 23
in bony fishes 9
in dog, on sinus caroticus 278
innervation in man 195, 288
Tunica intima 200
in amphibia 23
in bony fishes 9, 18
of arteries 200
of coronary arteries 348
Tunica media 196–9
depressor endings 260
in amphibia 23
in arteria pulmonalis 308
in arteries 191
in bony fishes 9
in buffalo 9
in cerebral arteries 196, 370
in coronary vessels 342, 347
in man 285, 288
in veins 201
nerve endings 192
fibres 174
supply 347
Tunica, muscular 176
Turbellaria 310
Turkey *(Meleagris gallopavo)* 65, 211, 276, 368
Turtle dove *(Turtur turtur)* 64
Type 2 cells of de Kock 334

Ultraterminal fibres 236
Ungulates
ganglia 111
stimulus-conducting fibres 113
Unipolar nerve cells
in amphibia 29
in bony fishes 21
in reptiles 50
Unmedullated fibres 367, 370
Uterine tube 180

Vagal cardiac rami 88–9
Vagal fibres
central 159
efferent 40
end bulbs 55
in atrial septum 99
myeline-sheathed 24, 155
parasympathetic 343
Vagal fibre system in amphibia 34
Vagal nerve endings in reptiles 55
Vagal nerve fibre system in bony fishes 18
Vagal nerve supply of heart 88
Vagal sensory system 160
afferent fibres 160
in amphibia 40
in atria of birds 34
Vagal system in fox 141
Vagal trunk in reptiles 55
Vagosympathetic sheath 88, 214–5, 254
Vagotomy 55, 143, 146, 160, 166
bilateral 41
degeneration of nerve cells 41
in amphibia 41
in cat 160
in frog 32, 34, 41
in mammals 159
in reptiles 44–5, 54–5, 64
Vagus 7, 39
and aortic nerve 253
and external carotid artery 306
carotid glomus 326
in amphibia 32, 34, 40–1
in birds 64
in bony fishes 9
in calf 254
in mammals 85–8, 135
Valves 172–3
in birds 74
in bony fishes 7, 12, 15, 17
in mammals 85, 90
medial 115
on ostium arteriosum in bony fishes 8
on ostium atrioventriculare in bony fishes 8
of arterial trunks 172

Valve
of lower hollow vein 85
sinoatrial, in amphibia 25
Valvula Eustachii 85
Valvula Thebesii 85
Valvular endothelium
in amphibia 25
in bony fishes 15
Vanellus vanellus Figs. 41, 44
Van Gieson's stain 108, 110, 117
Varanus griseus Figs. 27, 35, Plate I
Varicose fibres in reptiles 53
Varix (Varices) 1, 38–9, 50, 53, 64, 74, 146, 153, 155, 215–6, 281, 284, 317, 334, 343
in amphibia 37
in birds 72
in reptiles 64
on human aortic fibres 261
Vas afferens 363–4
Vas efferens 363
Vasa afferentia 357, 361
Vasa vasorum 203, 261
end bulbs 204
in venous sinus 9
of coronary arteries 349
renal arteries 359
Vascular nerve supply 176
Vascular reflex 259
Vasoconstrictor nerve 365
Vasomotor fibres 365
Vater–Pacini type end apparatus 201, 204
Vegetative fibres in bony fishes 18
Vegetative ganglia in atrioventricular system 107
Vegetative nervous system 30, 179, 190
in amphibia 30
Veins *(see also* Vena) 201–4
capsular 336
cerebral 372–3
hepatic in bony fishes 7
hollow, upper 81, 85
innervation 201–4, 357
interlobular 364
pulmonary 133
renal 364
sympathetic fibres 203
Vena cava 165
inferior 349
superior 349
upper 139
Vena cordis magna 353, Fig. 213
innervation 342
Vena coronaria cordis magna Figs. 214–5
Vena pulmonalis Fig. 118
Vena saphena magna 203, Fig. 117
Venous heart in bony fishes 7, 18
Venous sinus 9–11, Fig. 1
in amphibia 23, 31, 41
in birds 64
in mammals 85
in reptiles 43, 45–7
Ventricle
in amphibia 23, 34–7, 41
in bird 70–3
in bony fishes 7–8, 17–8, 20
in mammals 85, 99–104, 115
in reptiles 43, 51
Ventricular endocardium
in birds 70–4
in cat 105
in mammals 104–5, 119
in reptiles 54
Ventricular epicardium
in birds 71
in bony fishes 17
in mammals 99–100
in reptiles 51–4
in birds 74
Ventricular muscles
in bony fishes 8, 116
sympathetic fibres 107
Ventricular myocardium
in amphibia 36
in birds 71, 82–3
in bony fishes 18
in frog 33
in mammals 102, 105
in reptiles 50, 53
Ventricular septum 73, 115
in birds 74, 80–2
in mammals 104–5
Ventricular surface 76
Vertebrate, heart, receptor system 36
Vessels in amphibia 23
Vital staining with methylene blue 364, 366
Vitium cordis 311

Water frog *(Rana ridibunda)* 22
Water rail *(Rallus aquaticus)* 64
Wenkebach's bundle 109
White stork *(Ciconia alba)* 64
Whopper swan *(Cygnus olor)* 211
Wild duck *(Bucephala clangula)* 64
Wild goose *(Anser albifrons)* 276
Wild goose *(Anser fabalis)* 64
Windhover *(Falco tinnunculus)* 276

Zenker's fixing fluid 9

Responsible for publication: Gy. Bernát
Director of the Publishing House of the Hungarian Academy of Sciences and of the Academy Press
Responsible editor: B. Faragó · Technical editor: I. Csörgő · Jacket and cover: Edit Székely
63653 · Type Extended 9/11 pt · Academy Press, Budapest

FROM THE REVIEWS OF THE GERMAN EDITION

"This book is the outcome of long experience in the histological structure of the nervous system, and especially of the autonomic periphery . . . Discussion of the comparative histology of the autonomic periphery and the theories relating to its structure give the book additional importance. It is excellently printed on good paper and contains an extensive bibliography and index."

Excerpta Medica, Amsterdam

". . . The book can be thoroughly recommended . . ."

Journal of Anatomy, London

"Die ausgezeichnete Monographie stammt von einem berufenen Verfasser, der sich seit mehr als 35 Jahren der Erforschung der histologischen Struktur des Nervensystems gewidmet hat... Die übersichtlich gegliederte und von einer klaren Diktion beherrschte Monographie ist eine wertvolle Bereicherung der einschlägigen Fachliteratur. Autor, Übersetzer und Verlag sind zu dem gelungenen Werk zu beglückwünschen."

Biologisches Zentralblatt, Leipzig

"... Ein ganz ausgezeichnetes Werk. Druck- und verlagstechnisch einwandfrei".

Wiener medizinische Wochenschrift, Wien

". . . Der Autor des Buches hat als einer der prominenten Vertreter der klassischen Neuro-Histologie gezeigt, daß auch im Zeitalter der Elektronenmikroskopie mit klassischen histologischen Methoden etwas Dauerhaftes und Wertvolles geschaffen werden kann . . ."

Zentralblatt für die gesamte Neurologie und Psychiatrie, Heidelberg

DISTRIBUTORS

KULTURA

BUDAPEST 62, P. O. B. 149

